Coarctation aortique
Interruption de l’arche aortique

Xavier IRIART
Service des cardiopathies congénitales de l’enfant et de l’adulte
CHU de Bordeaux

Coarctation aortique

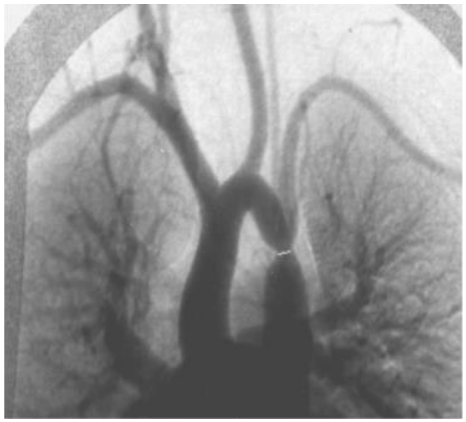

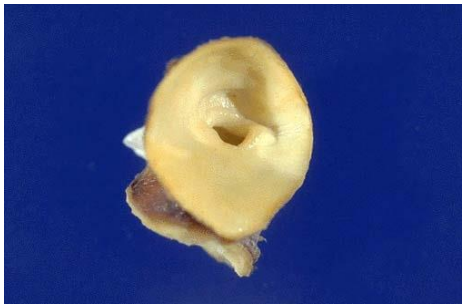

5 à 7,5 % des CC

Garçons/ filles: 2-3/1

15 % des Turner

Lésions associées : 2/3

- hypoplasie de l'arche
- CIV
- bicuspidie aortique
- anomalies mitrales, syndrome de Shone.

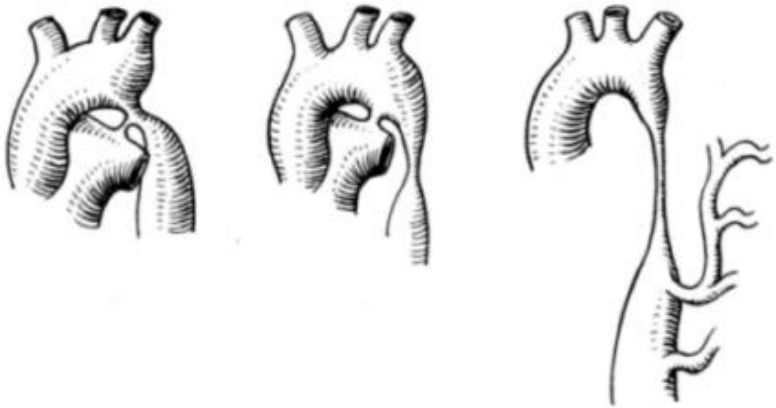

Formes anatomiques

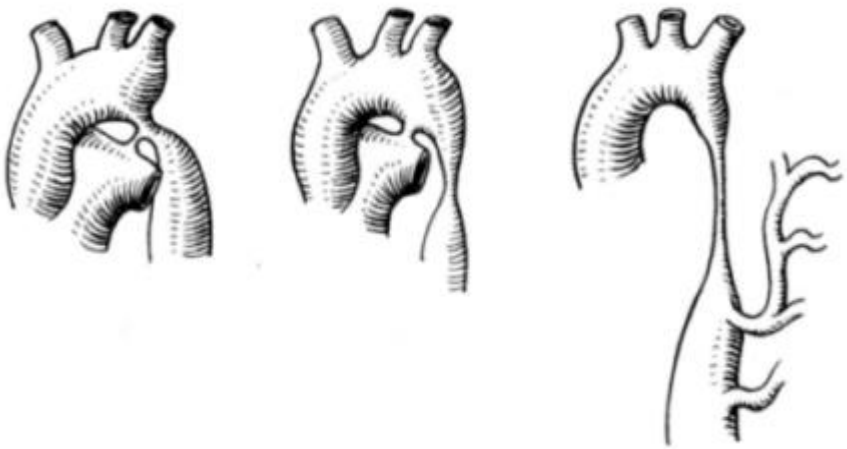

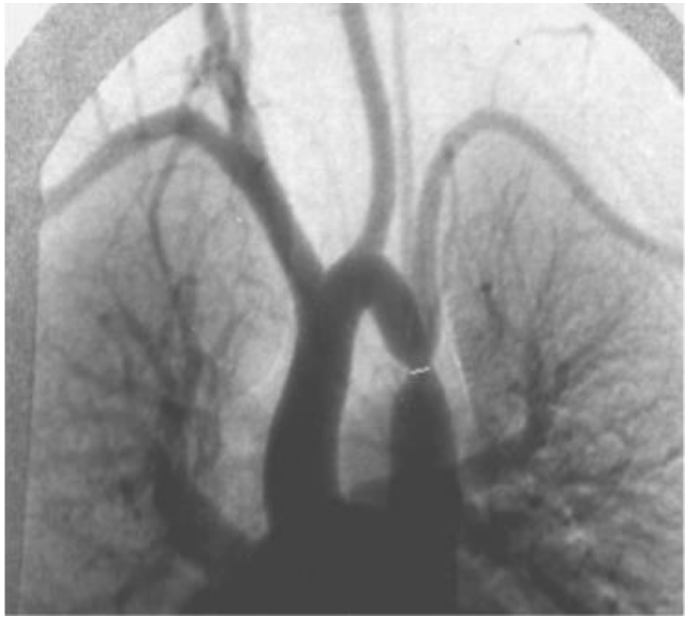

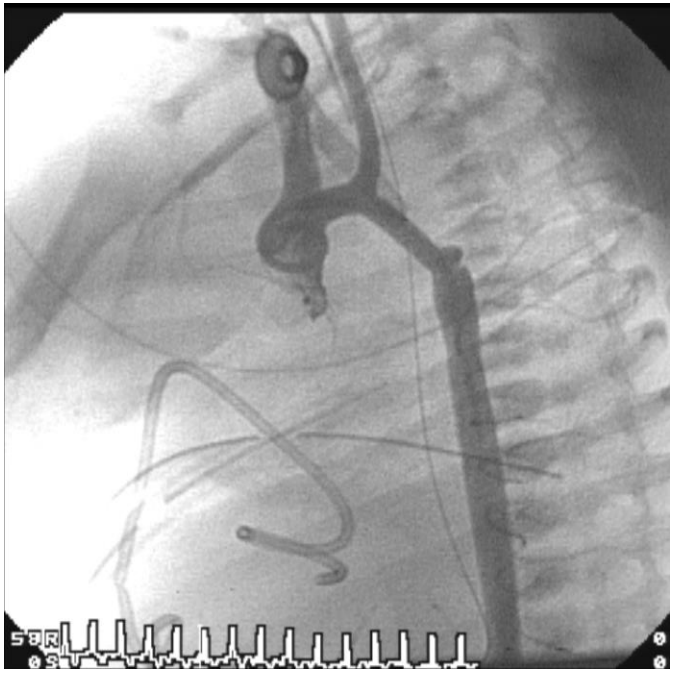

Physiopathologie

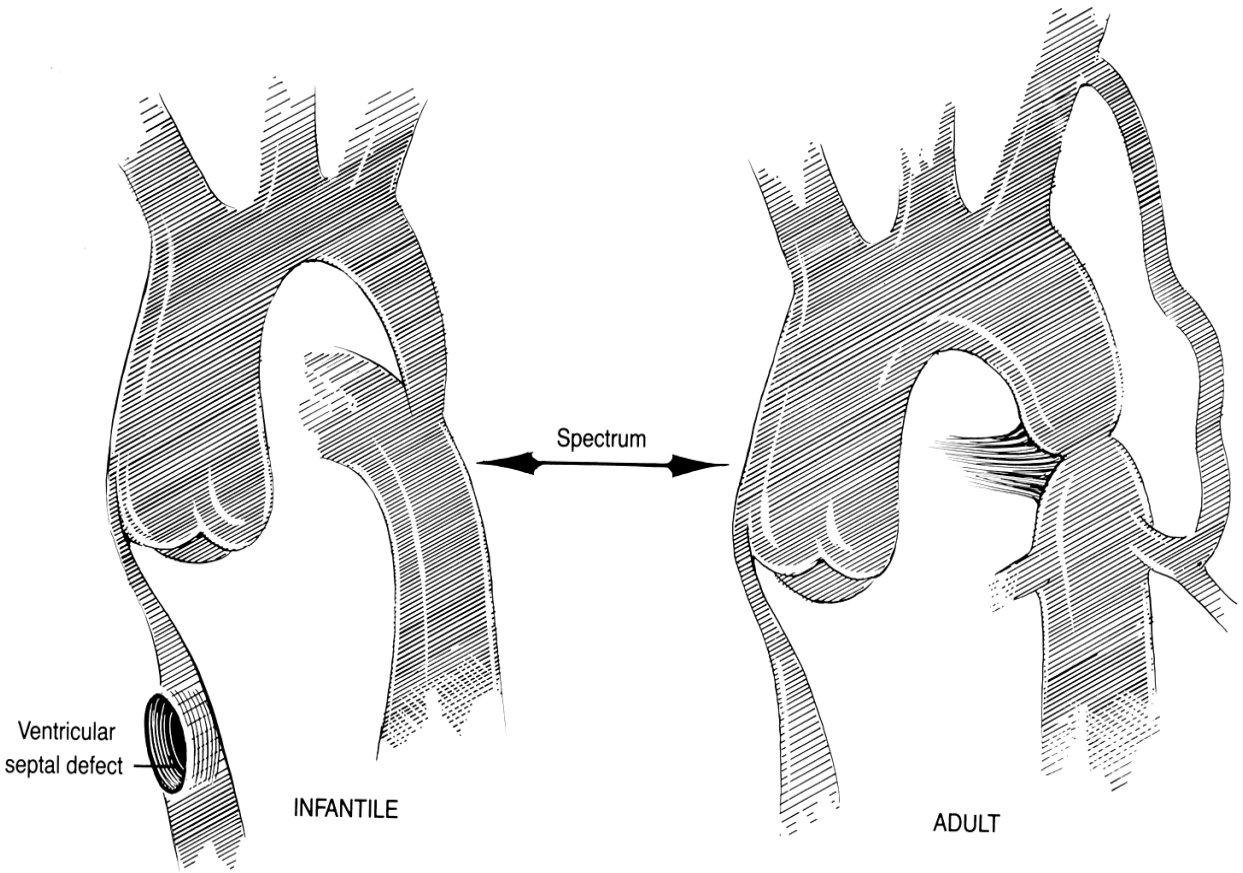

COARCTATION : mode de présentation

– *Nouveau né:*
  - Latence 7-15 jours
  - (+ précoces si anomalie associées)
  - insuffisance cardiaque voire collapsus
  - Diagnostic clinique difficile
  - Absence des pouls fémoraux
  - Asymétrie tensionnelle difficile à mettre en évidence

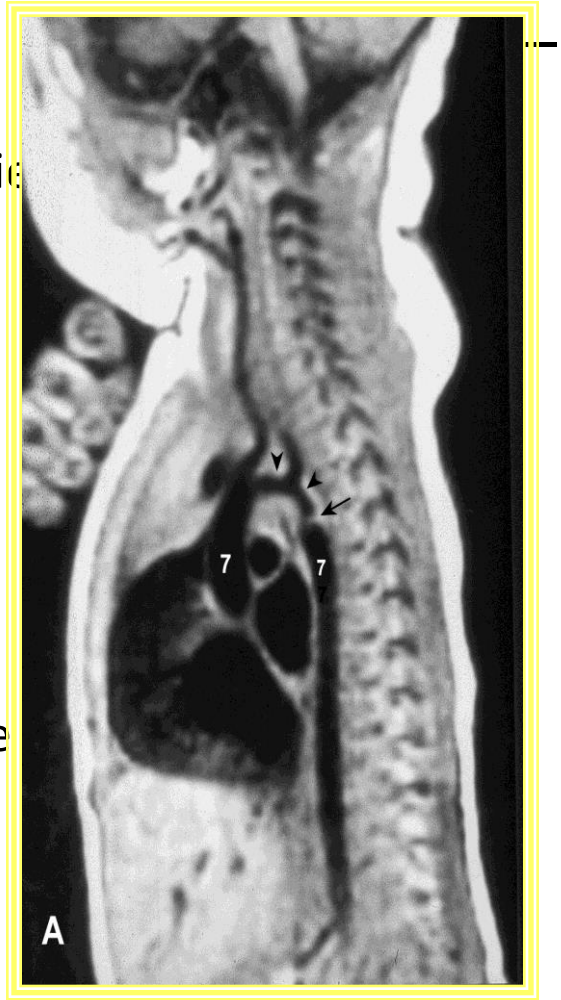

– Enfant:
  - Asymptomatique le plus souvent
  - Souffle systolique (dos)
  - HTA membre supérieur Droit.
  - Abolition pouls fémoraux
  - Asymétrie tensionnelle
  - HVG echo

COARCTATION : mode de présentation

- Grands enfants
  - HTA
  - Insuffisance cardiaque très rare

- Adultes
  - <u>HTA</u>
  - Coronaropathie
  - Insuffisance cardiaque
  - Anévrysme des artères cérébrales

Coarctation
radio thoracique

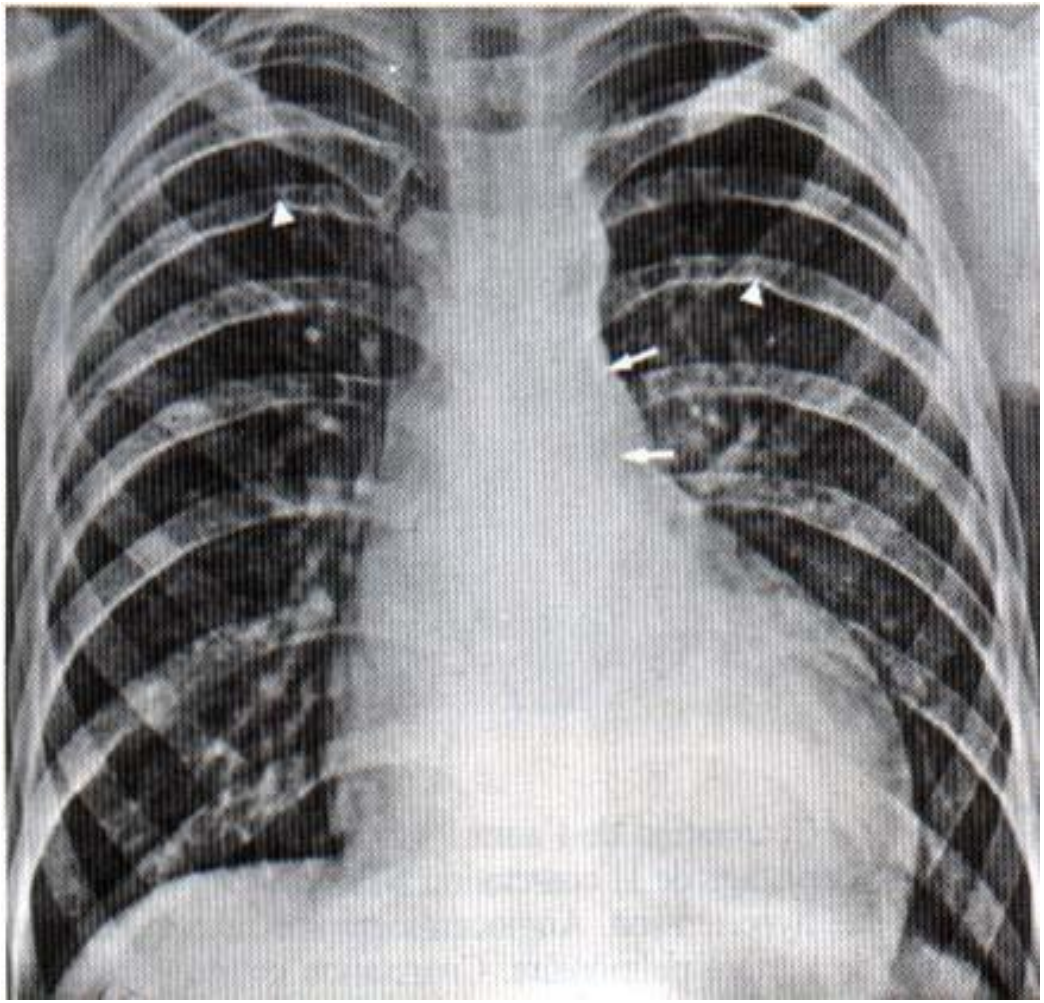

COARCTATION AORTIQUE
explorations

- Echocardio-doppler:
  - siège et étendue
  - retentissement sur le VG
  - anomalies associées
- IRM/ TDM
  - Siége et étendue
  - Collatérales
  - Anomalies associées

Arche aortique: anatomie

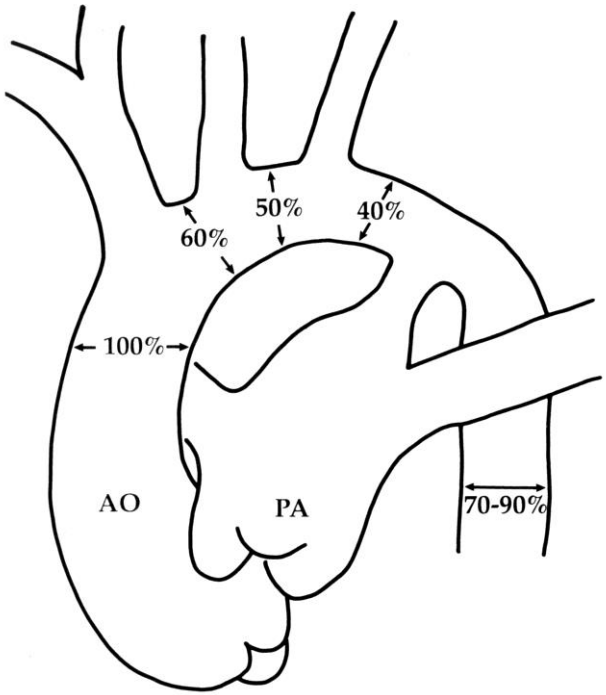

Fig 1. Minimal relative diameters of the normal thoracic aorta (AO) *in infancy.* (PA = *pulmonary artery.*) *(Adapted from Moulaert AJ, Bruins CC, Oppenheimer-Dekker A. Anomalies of the aortic arch and ventricular septal defects. Circulation 1976;53:1101–5, by permission.)*

Diamètre minimal

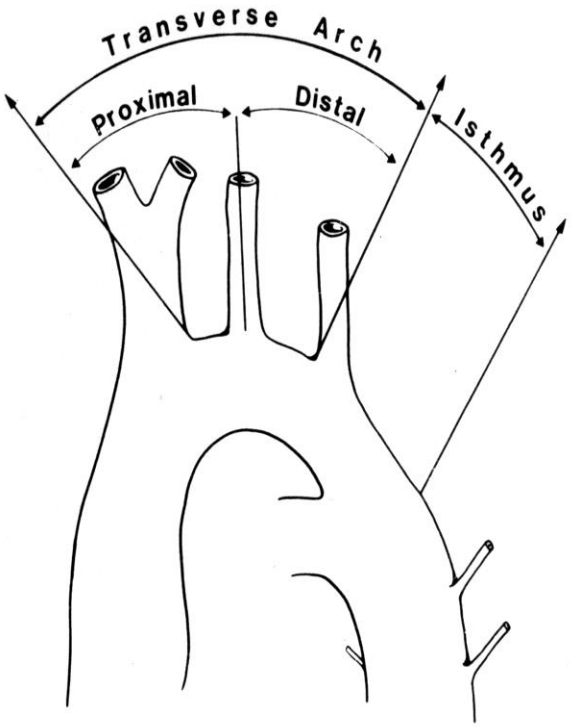

Fig. 1. Aortic arch anatomy in neonates.

définitions

Coarctation néonatale: échographie

- Lésions associées
  - obstacles étagés du cœur G (BA, hypoplasie aorte horizontale , shone…)
  - Shunts: CIV, CIA

- Fonction VG:
  - VG inadapté hypokinétique à parois minces
  - Estimation de la POG (vélocité du FO)

- HTAP

- Canal artériel

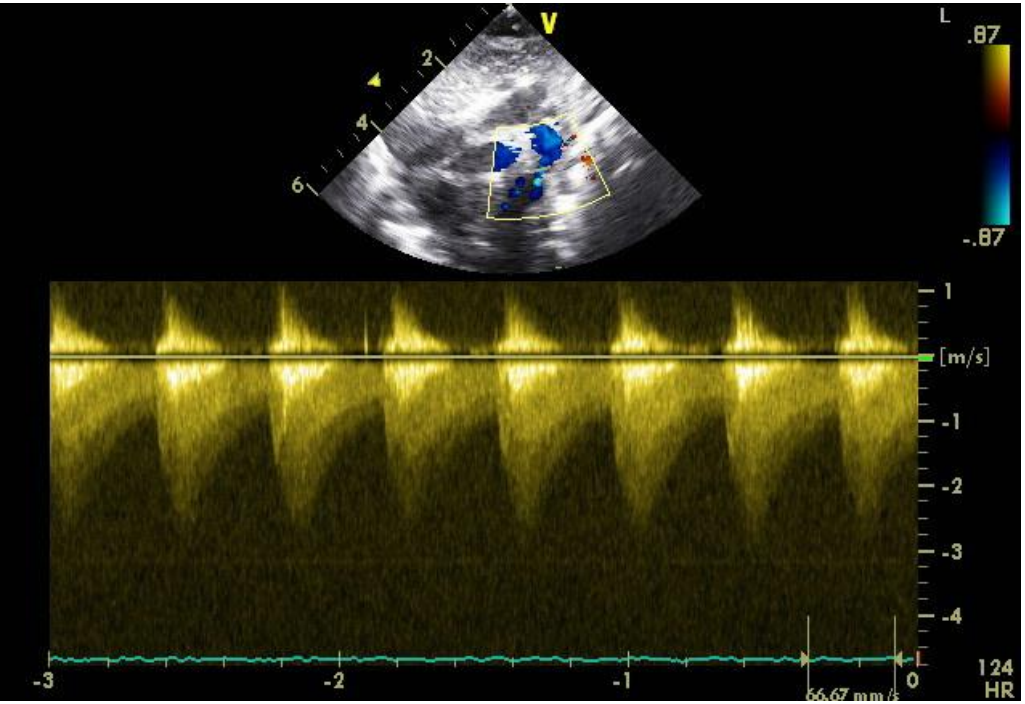
V
L
.87
-.87
2
4
6
1
[m/s]
-1
-2
-3
-4
-3
-2
-1
0
66.67 mm/s
124
HR

Hypothèses physiopathologiques

- Théorie hémodynamique:
  - Hypoperfusion anténatale de l'arche aortique (sténose aortique, mitrale, FOP)

- Hypothèse mécanique :
  - rôle du tissu ductal

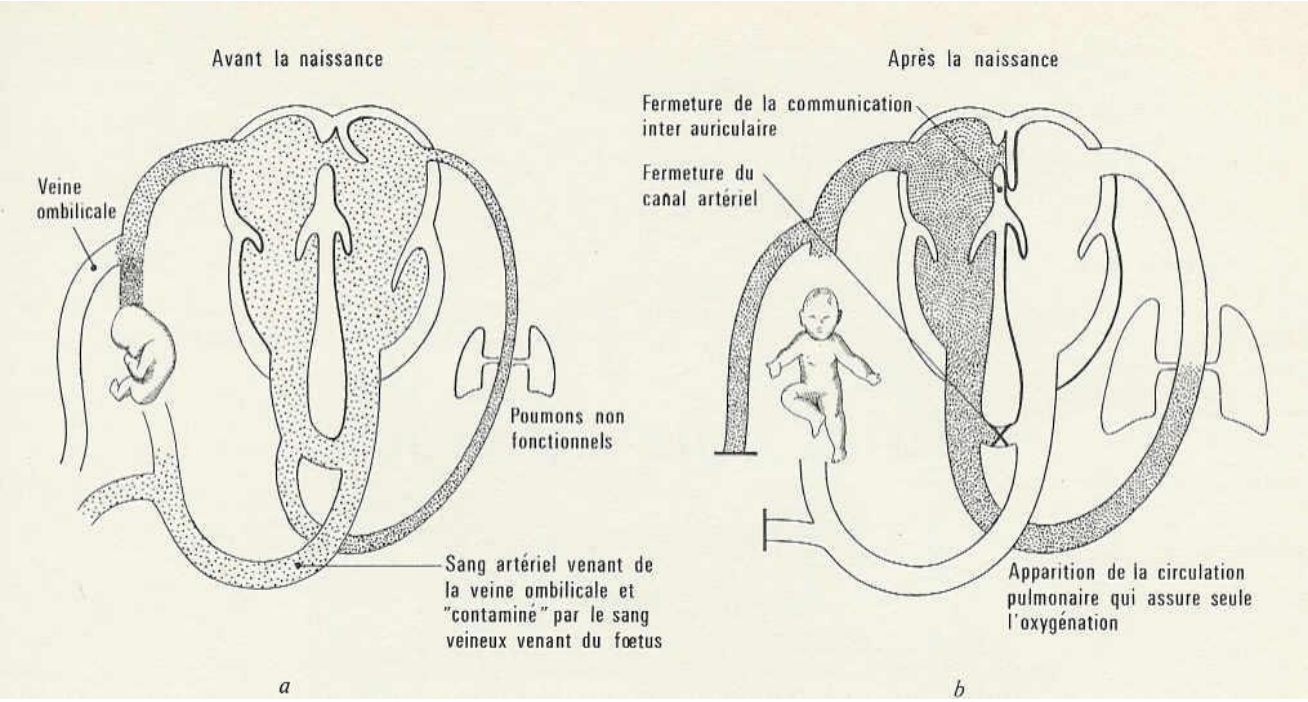

LES POINTS CLES

- Comprendre l'importance de la circulation transitionnelle
- Comprendre le fonctionnement de la cardiopatl
- Comprendre l'anatomie

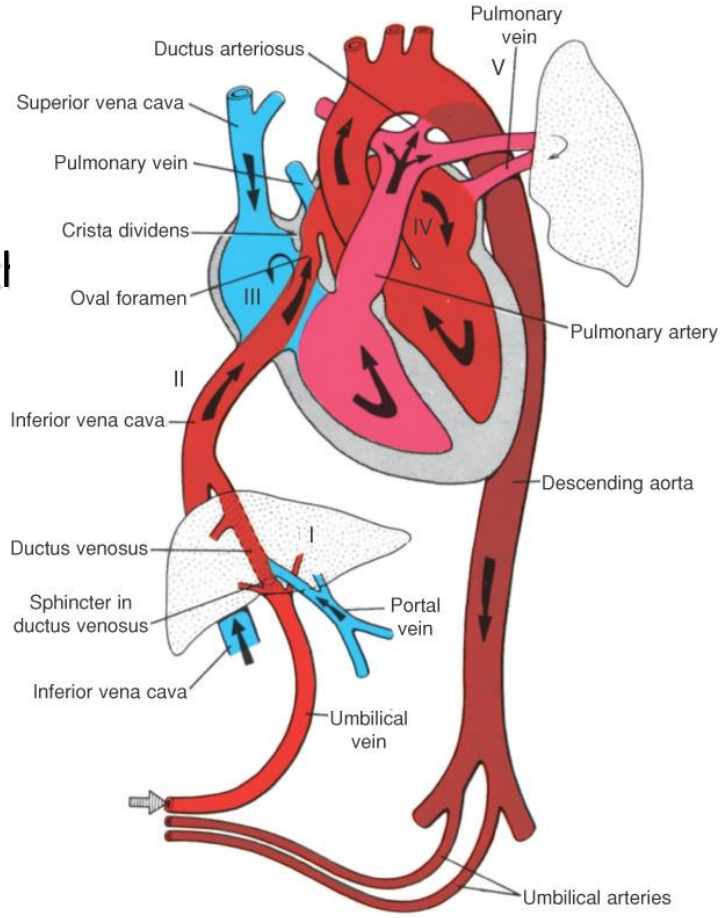

Tableau clinique

- <u>Choc cardiogénique post natal</u>
  - Pathologie ducto dépendante:CoA, IAAo

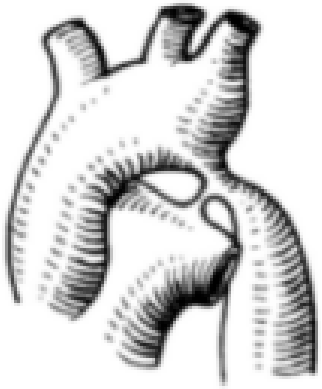

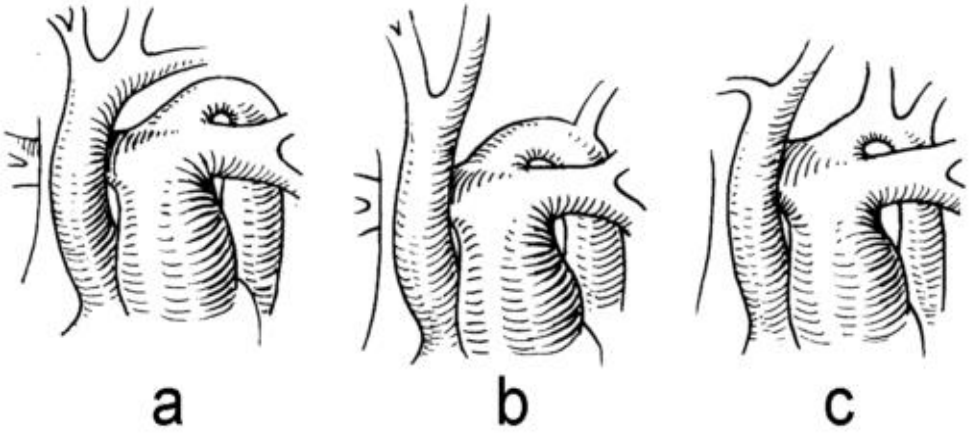

L’évolution idéale

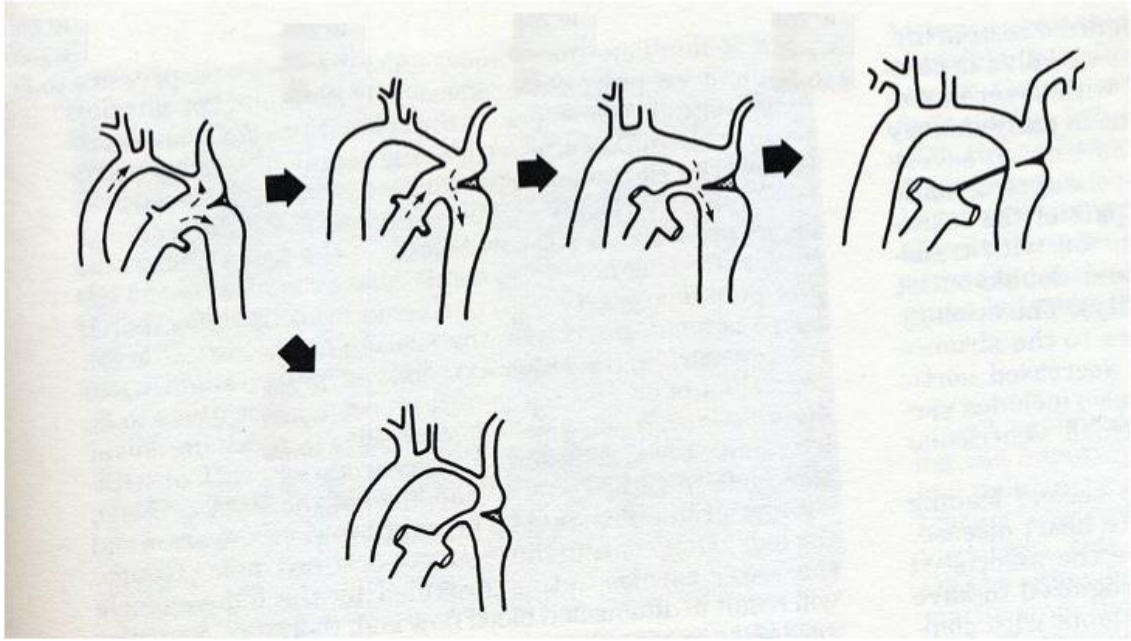

Asymétrie ventriculaire à l’échographie anténatale.

Naissance dans un centre disposant d’un service de chirurgie cardiaque pédiatrique.

Atmosphère de coarctation à la naissance.

Apparition de la coarctation à la fermeture du CA.

Introduction de Prostine en attendant la chirurgie.

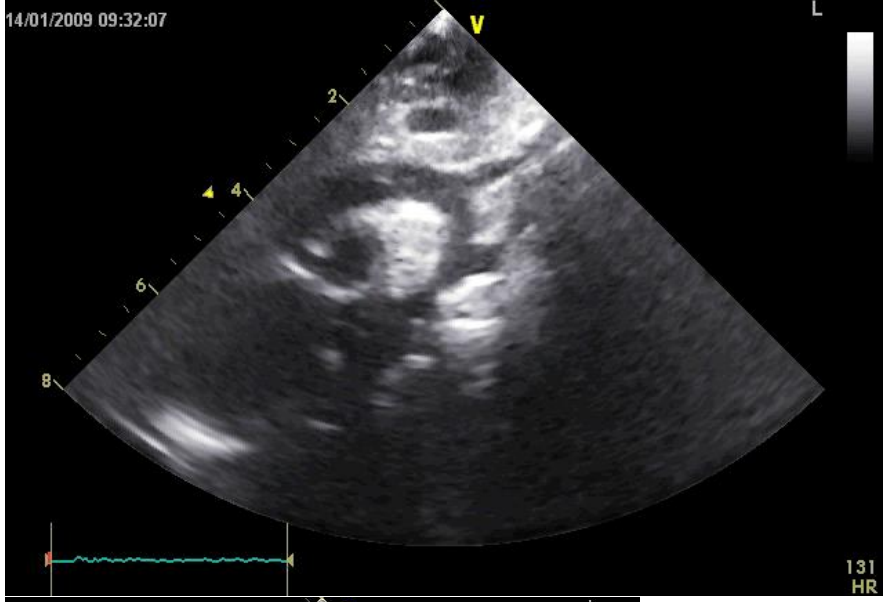
14/01/2009 09:32:07
V
L
2
4
6
8
131
HR

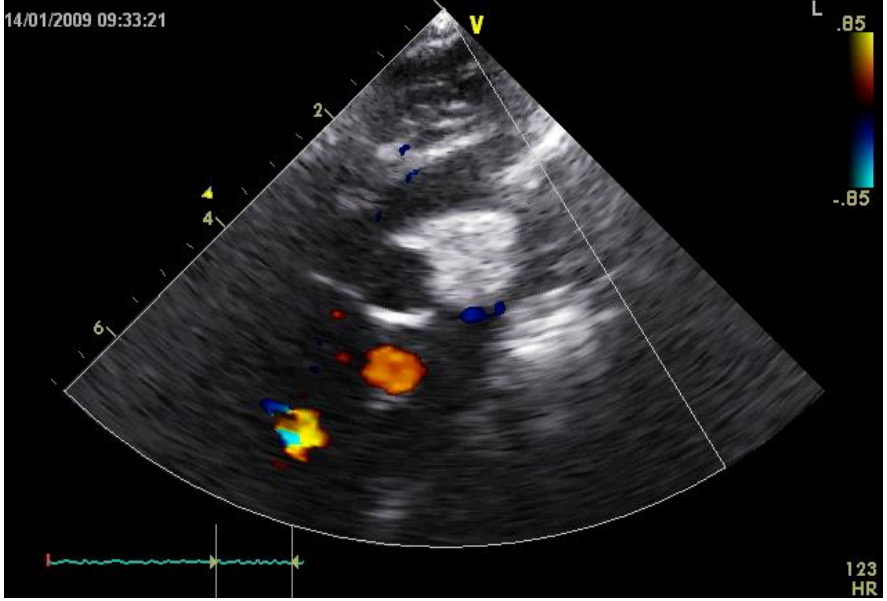
14/01/2009 09:33:21
V
L
.85
-.85
2
4
6
123
HR

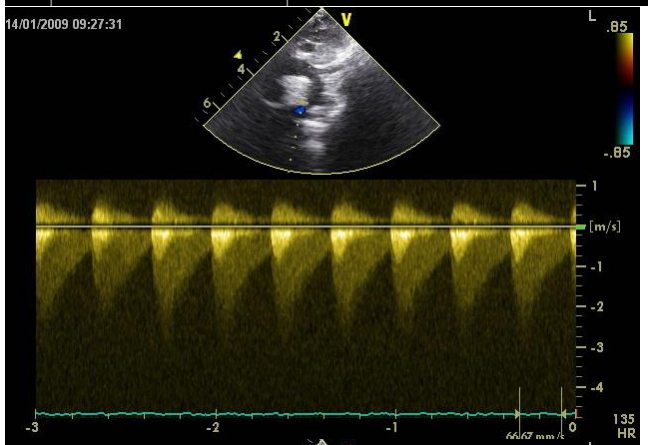
14/01/2009 09:27:31
V
L
.85
-.85
2
4
6
1
[m/s]
-1
-2
-3
-4
-3
-2
-1
0
135
HR

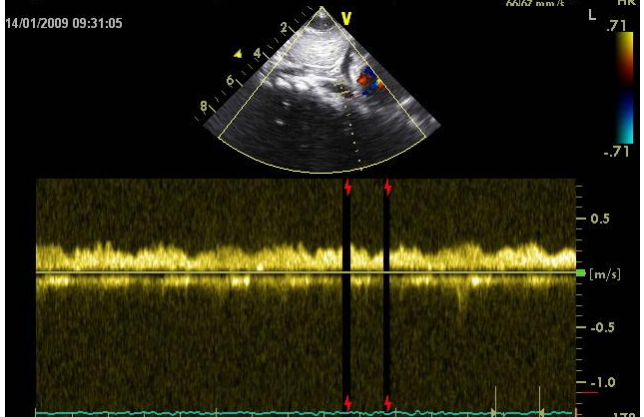
14/01/2009 09:31:05
V
L
.71
-.71
2
4
6
8
0.5
[m/s]
-0.5
-1.0

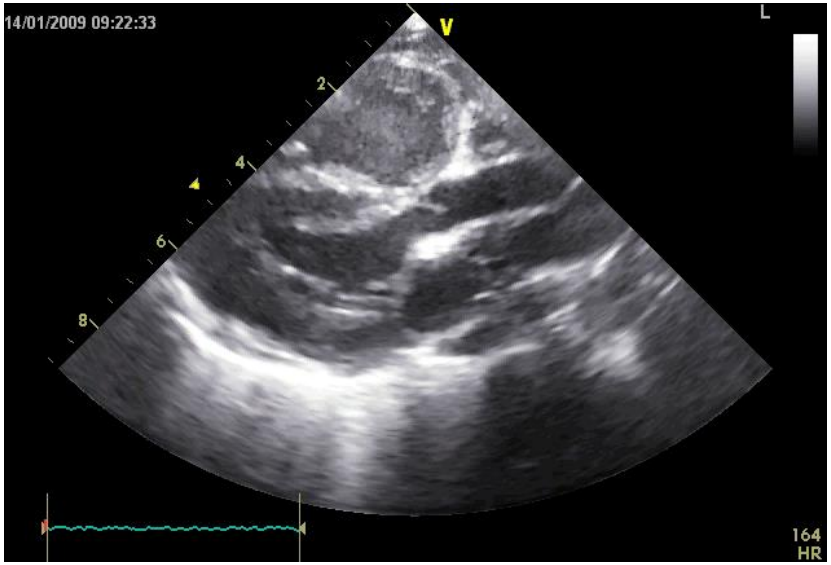
14/01/2009 09:22:33
V
L
2
4
6
8
164
HR

L'évolution FREQUENTE

- Pas de diagnostic anténatal.
- Naissance sans problème.
- Sortie de la maternité à 3 jours de vie.
- Fermeture du CA et coarctation au domicile.
- Aggravation de l'état général.
- Urgences- abolition des pouls fém- écho- réanimation…….

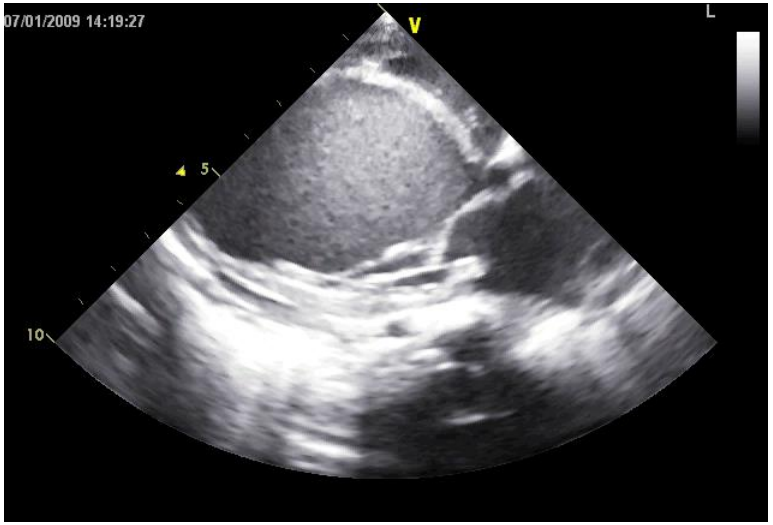

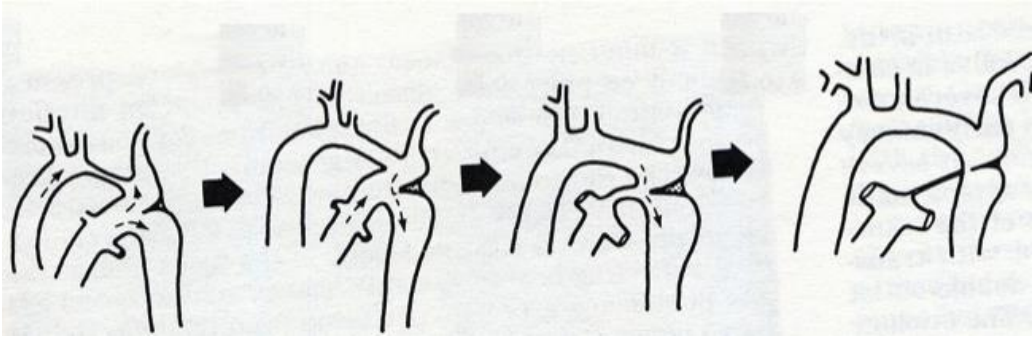

Missed Diagnosis of Critical Congenital Heart Disease

Ruey-Kang R. Chang, MD, MPH; Michelle Gurvitz, MD; Sandra Rodriguez, MS

Arch Pediatr Adolesc Med. 2008;162(10):969-974.

Among 152 infants with a missed CCHD diagnosis, the median age at death was 13.5 days. More than 50% of patients with a missed CCHD diagnosis (n = 78) died at home or in the hospital emergency department. The most common diagnoses were HLHS and coarctation of aorta. There were an average of 10 patients with missed CCHD diagnoses and 20 patients with late diagnoses in California per year. The total annual number of patients with missed or late diagnoses decreased in 1989-1999 and remained unchanged in 2000-2004.

Coarctation néonatale: prise en charge thérapeutique

La prise en charge d'une coarctation néonatale en défaillance cardiaque est d'abord réanimatoire.

La perfusion de PgE1 permet de lever (partiellement) la coarctation . Débuter PGE1 = 0,05 µg/kg/min

La réanimation (ventilation, dobu) a pour but de stabiliser l'hémodynamique du nouveau-né avant la chirurgie.

Sidi D et al. Arch Fr Pediatr. 1987;44:21-5
Laugier et al. Therapie 1991;46:231-3
Hascoet JM et al. Acta Paediatr. 1992;81:938-40

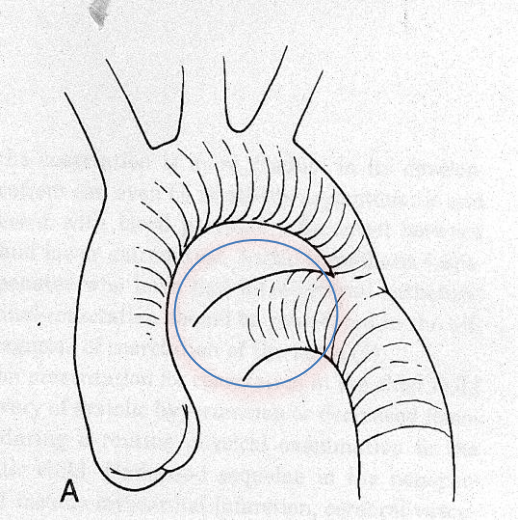
A

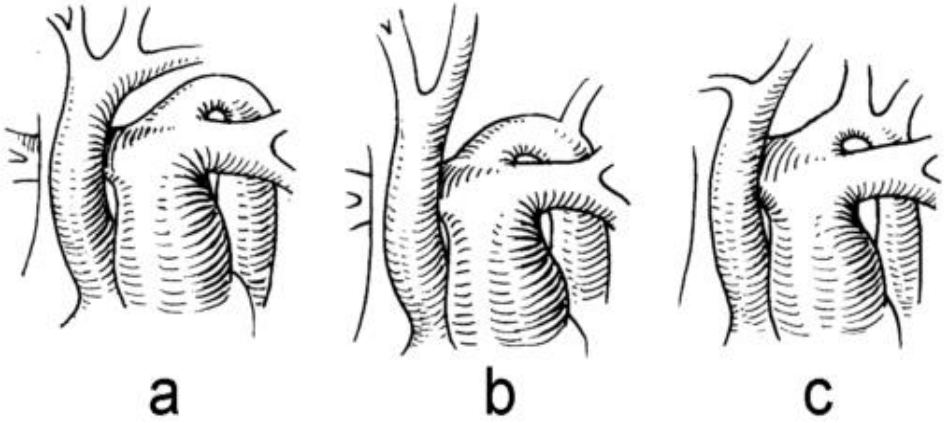
a
b
c

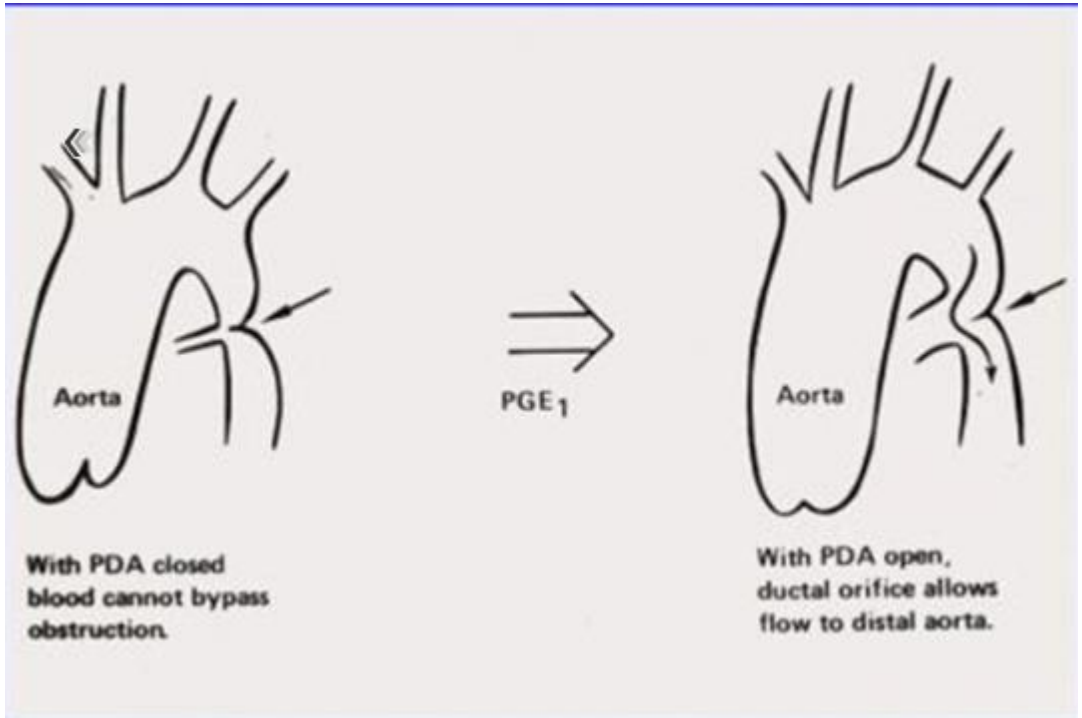
Aorta
PGE1
Aorta
With PDA closed blood cannot bypass obstruction.
With PDA open, ductal orifice allows flow to distal aorta.

Coarctation néonatale

La PgE1 vise à :

- lever (partiellement) la coarctation
- maintenir un débit systémique par canal shuntant AP-AO

Débuter
PGE1 = 0,05 µg/kg/min

Traitement

- Médical
- Chirurgical:
  - techniques: Crafoord, Waldhausen,
  - résultats
  - Complications
- Angioplastie percutanée

Objectifs du traitement chirurgical

- Lever l’obstacle
- Réséquer le tissu ductal en totalité
- Corriger l’hypoplasie de la crosse
- Traiter les malformations associées

Résultats

Mortalité :

- 1 à 2 % si isolée
- < 10 % si anomalies intracardiaques complexes associées

Recoarctations :

- 10 à 20% des Coarctations néonatales

Ghez O, Arch Mal Cœur 2005

Coarctations: long terme

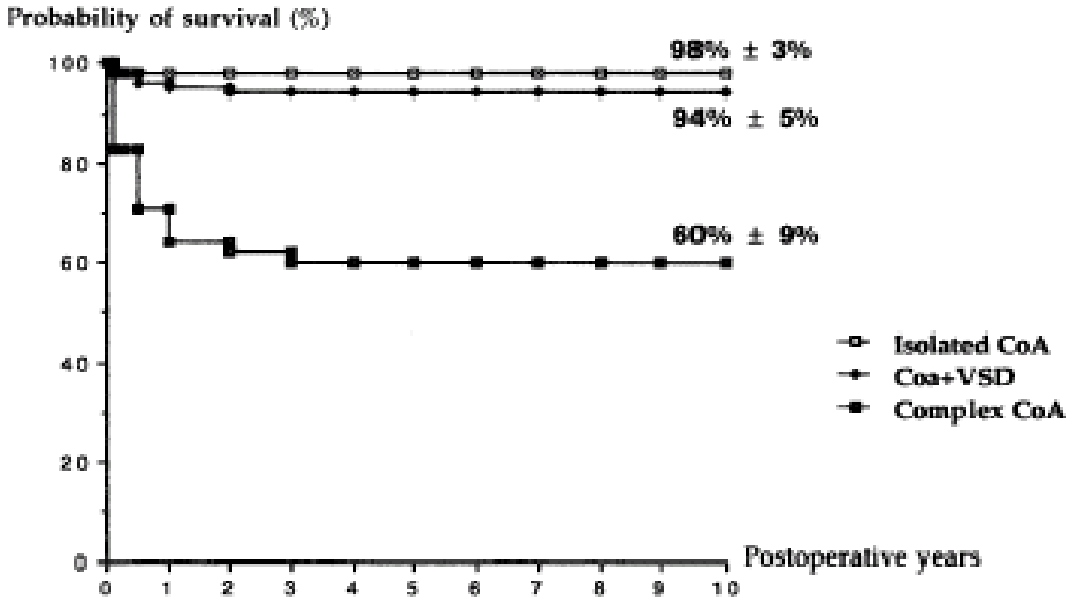

Fig. 4. Actuarial probability of survival according to associated cardiac anomalies. *CoA*, Coarctation; *VSD*, ventricular septal defect; *Complex CoA*, coarctation with associated complex heart defects.

Survie actuarielle

Høimyr. EJTCS 2006

Complications post-opératoires

- Précoces:
  - HTA paradoxale
  - troubles digestifs (syndrome post clampage)
  - pulmonaires : compression bronchique,chylothorax
  - neurologique: paraplégie, paralysie récurrent
- Tardives:
  - HTA (effort)
    - recoarctation
    - anévrysme et faux anévrysme

Re-coarctation

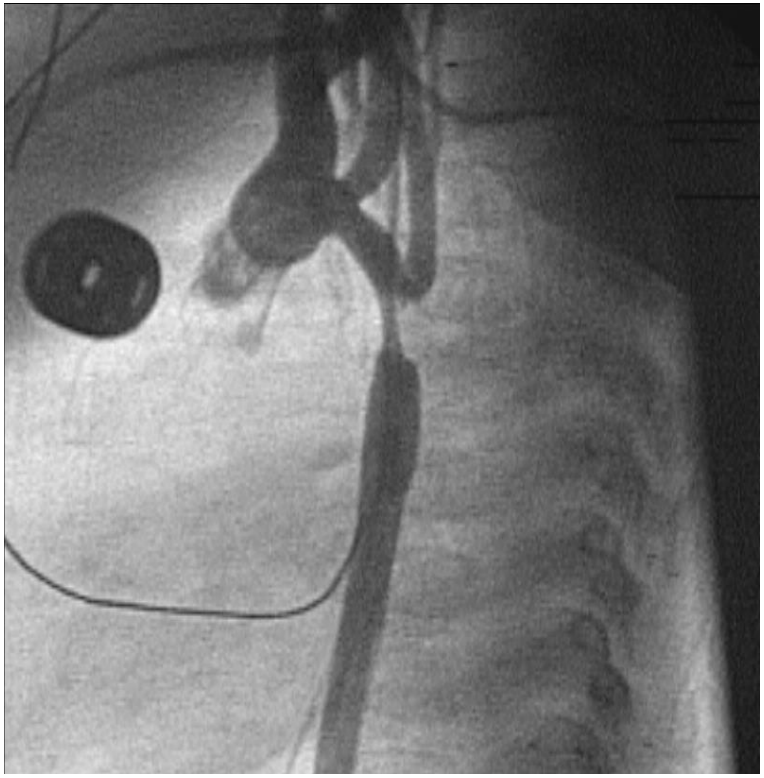

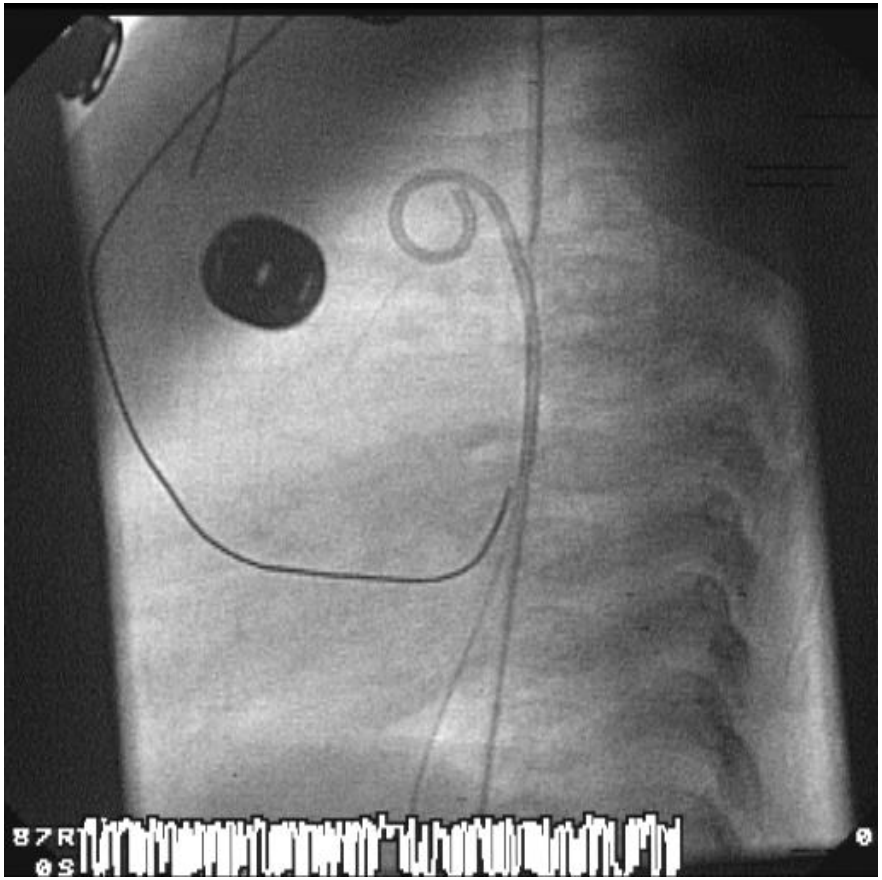

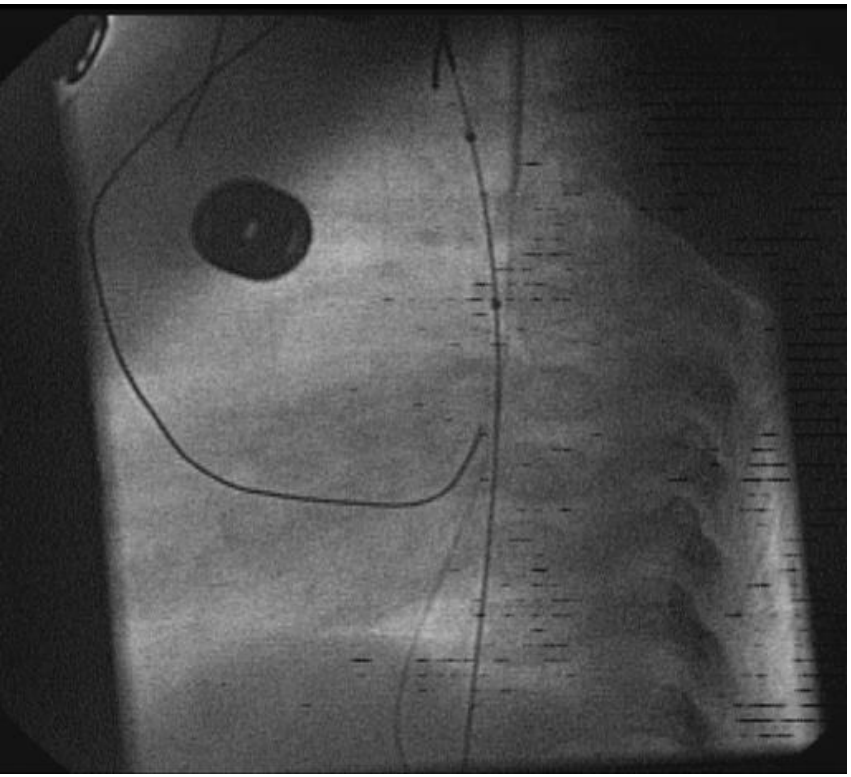

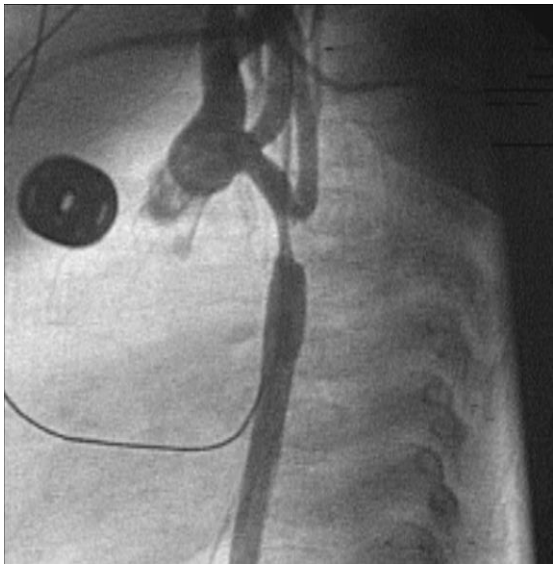

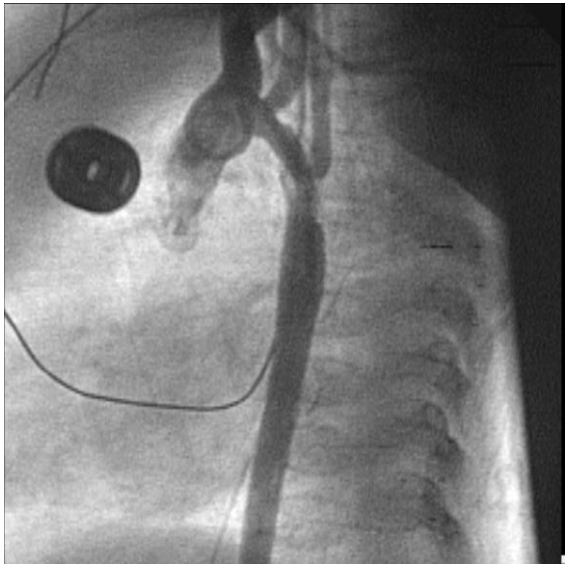

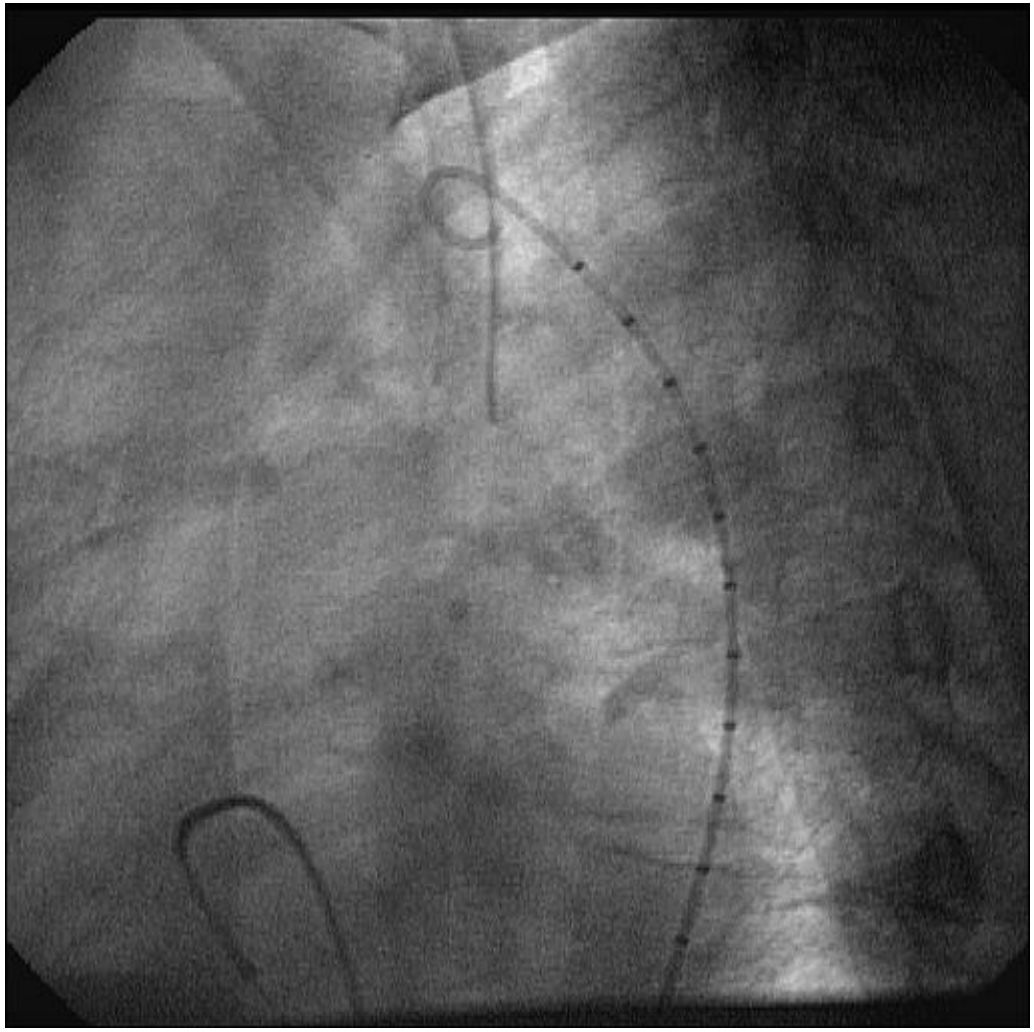

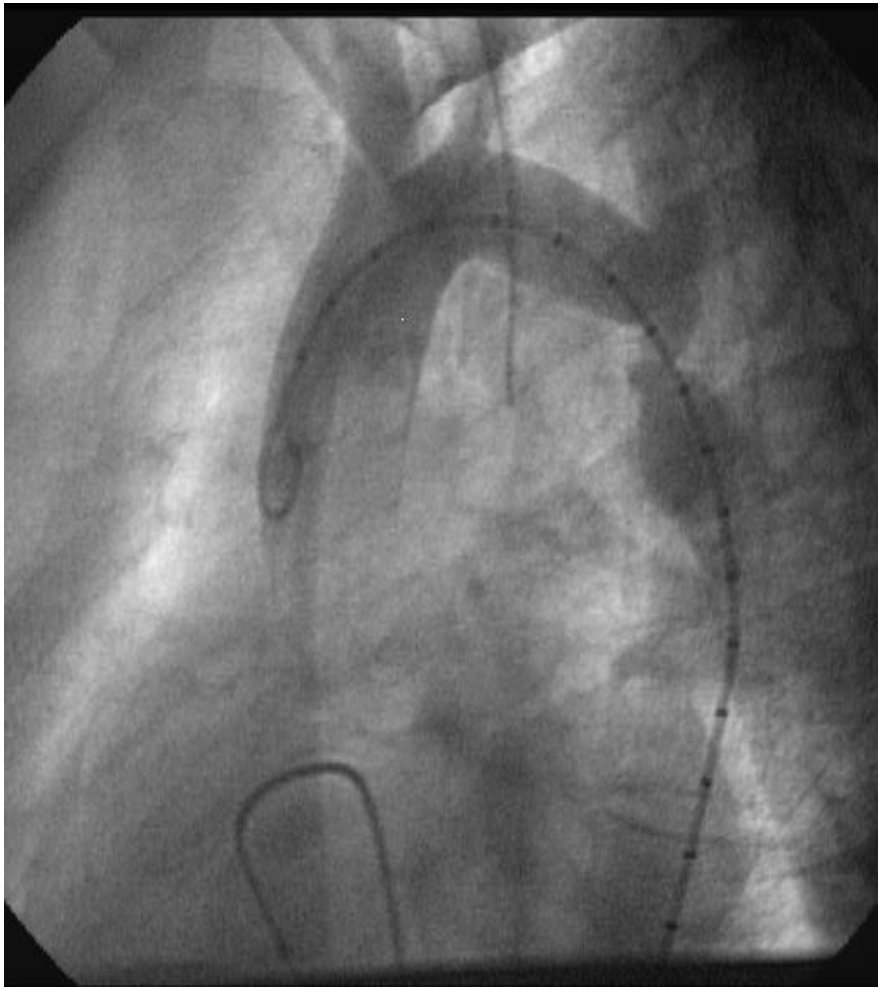

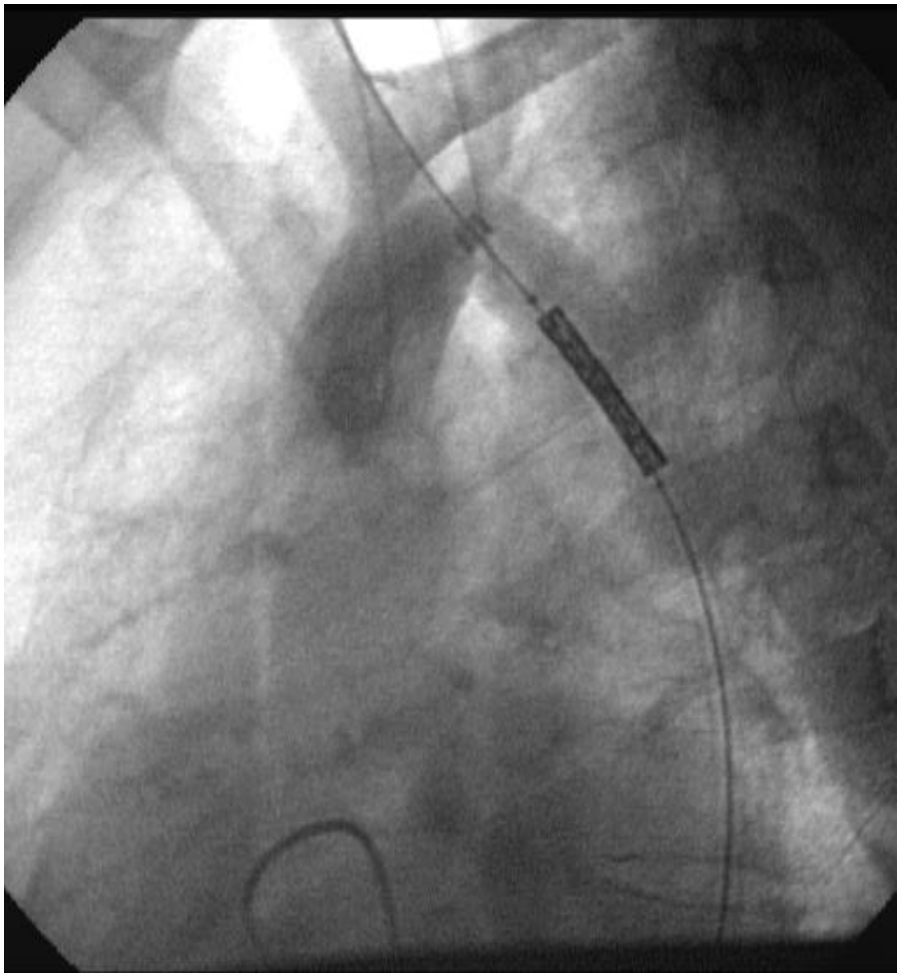

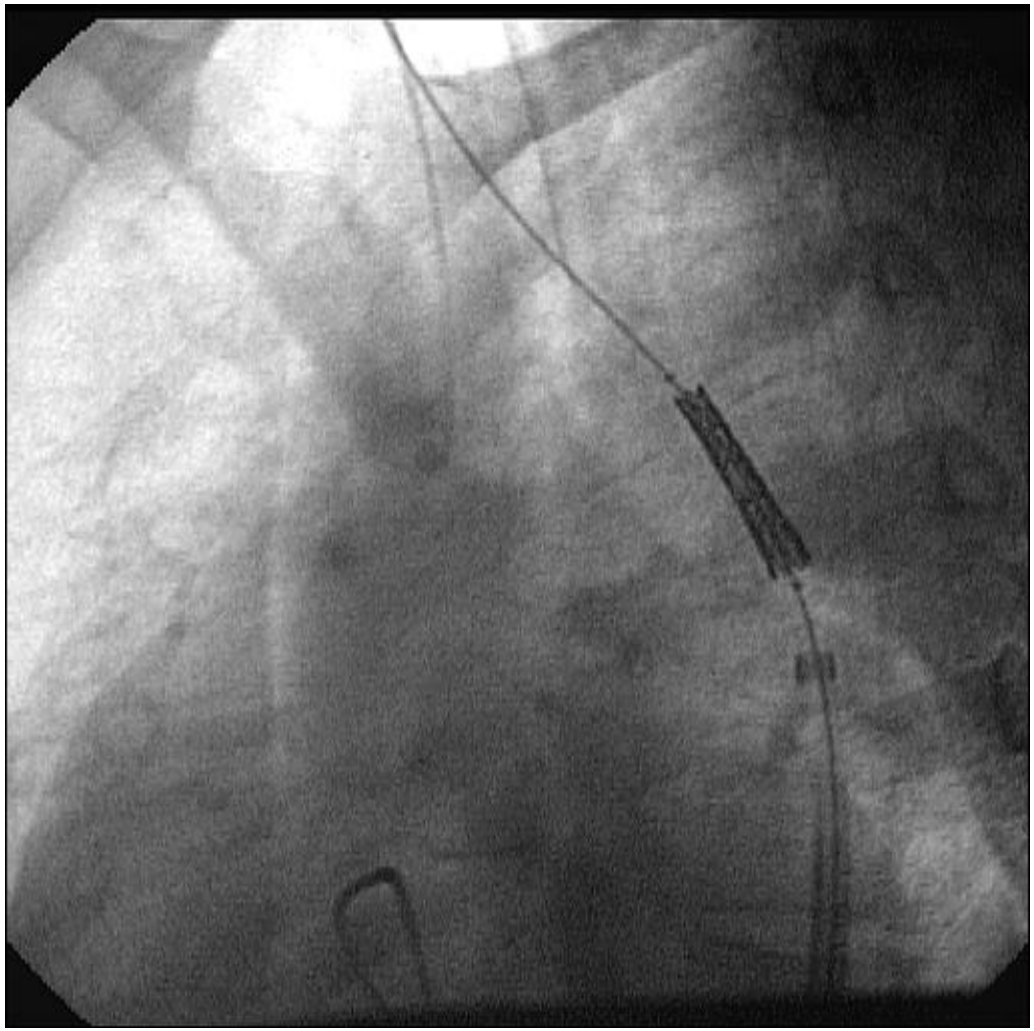

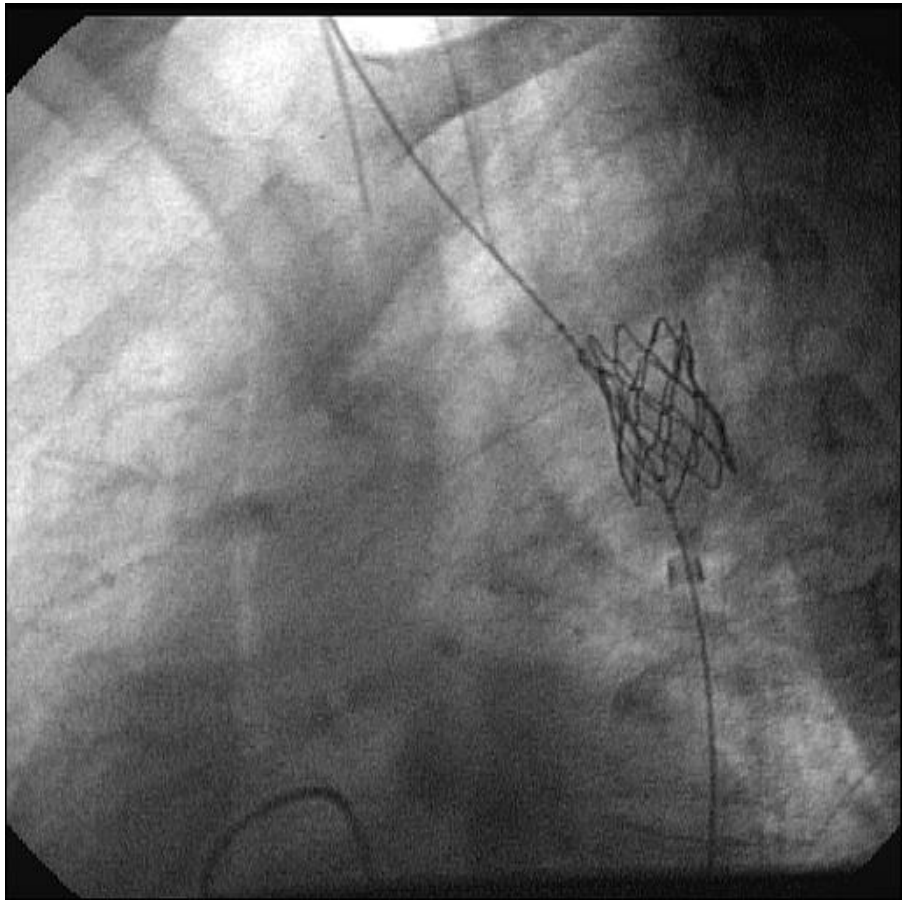

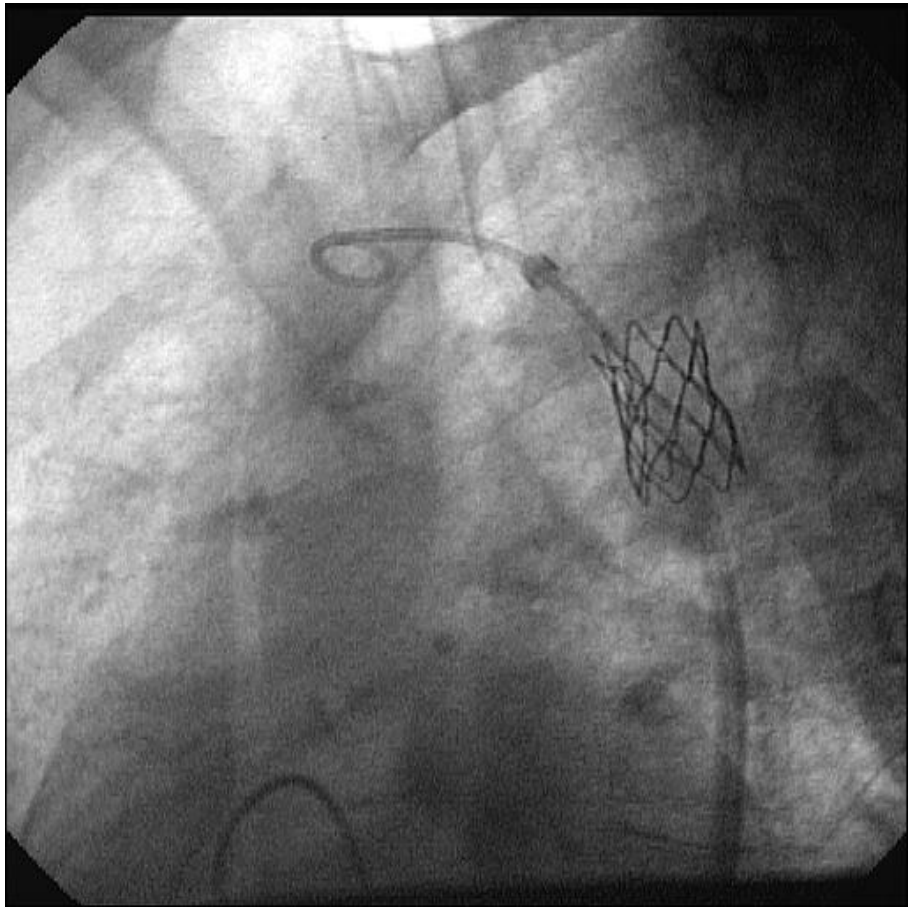

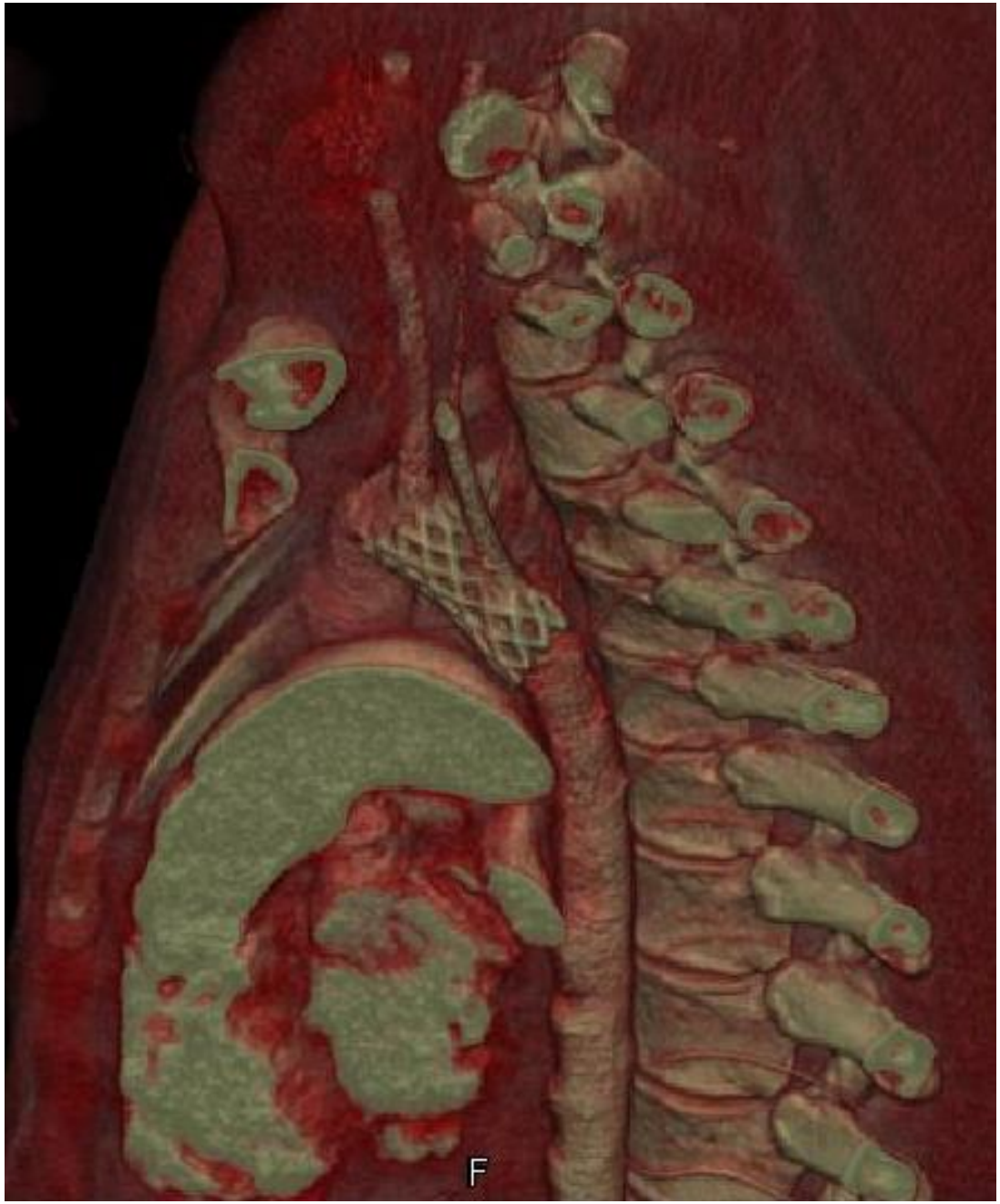
F

HTA et Coarctation de l’aorte opérée

Rôle de la géométrie de la crosse

Phalla Ou. JAAC 2007

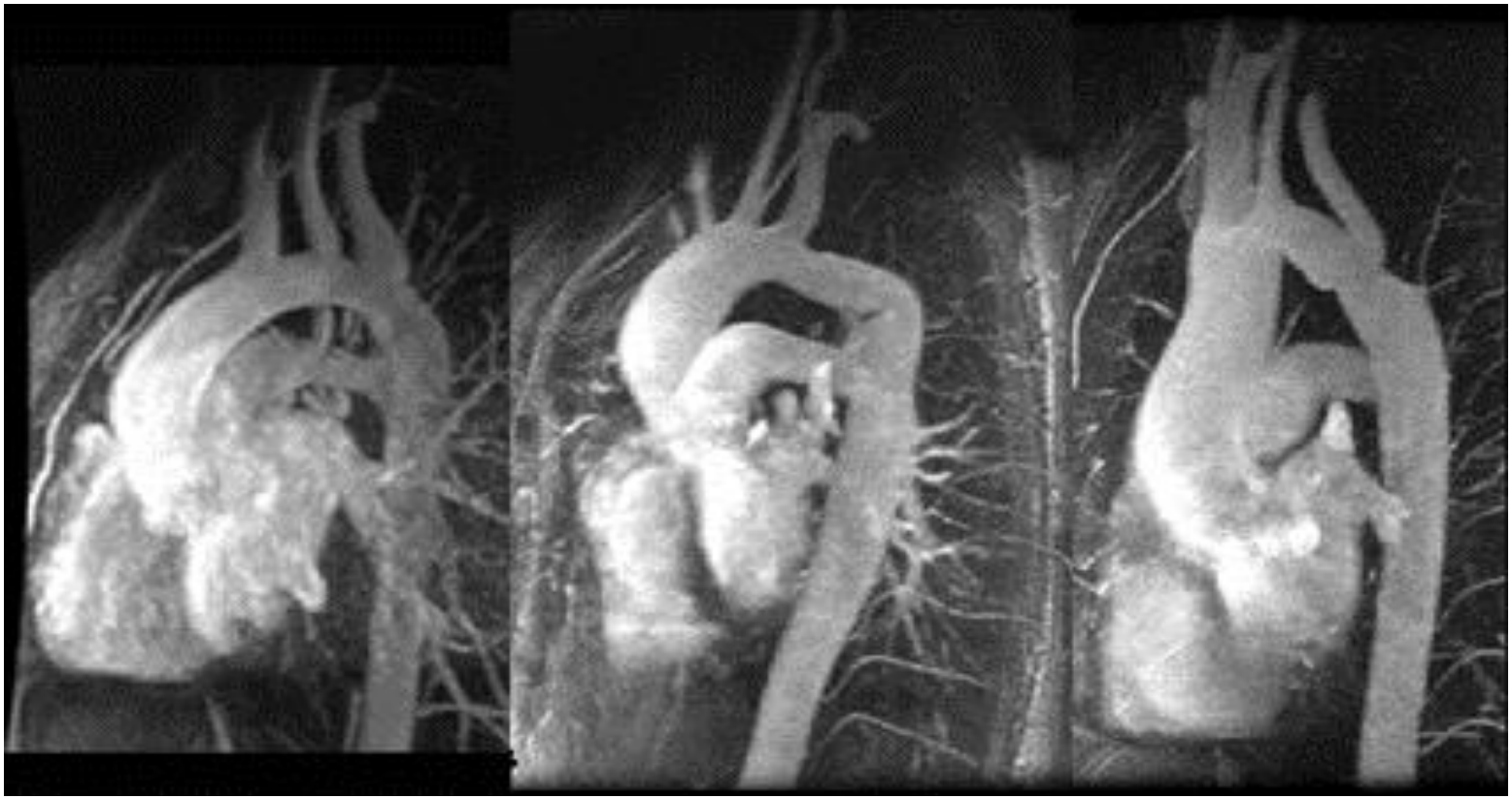

Normal Créneau Gothique

Interruption de l’arche aortique

- Rare
- Types A, B(Di George), C
- Lésions associées fréquentes: canal artériel, fenêtre aorto-pulmonaire, TGV (malpositions), truncus

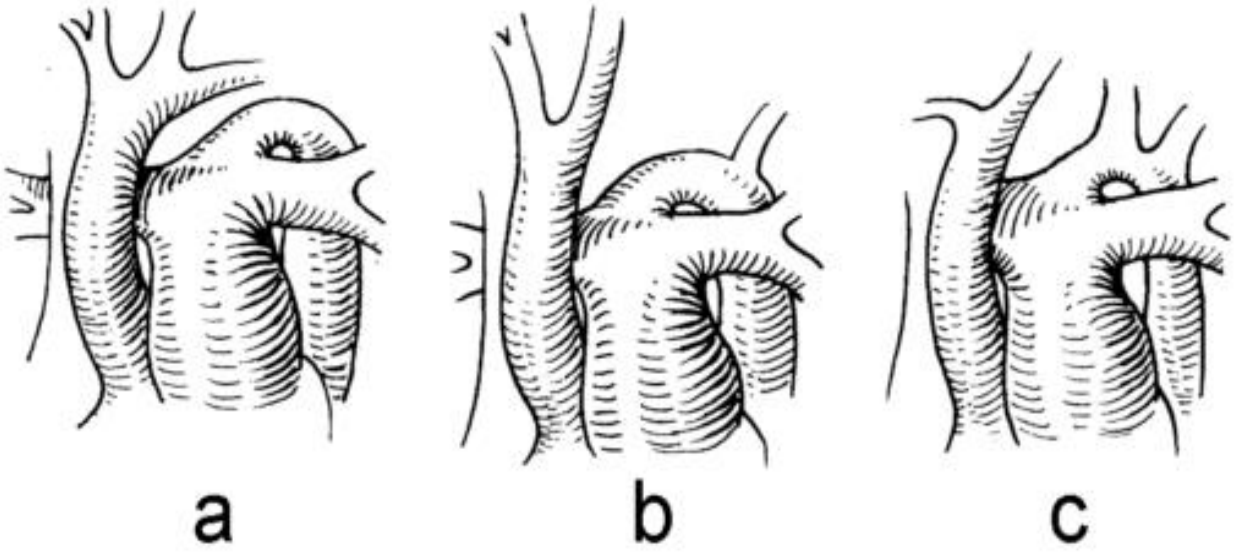

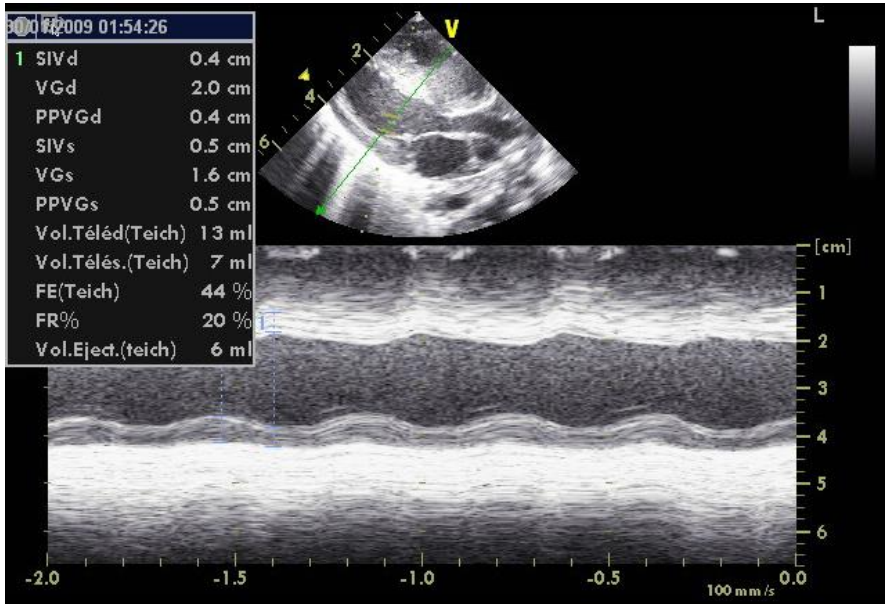

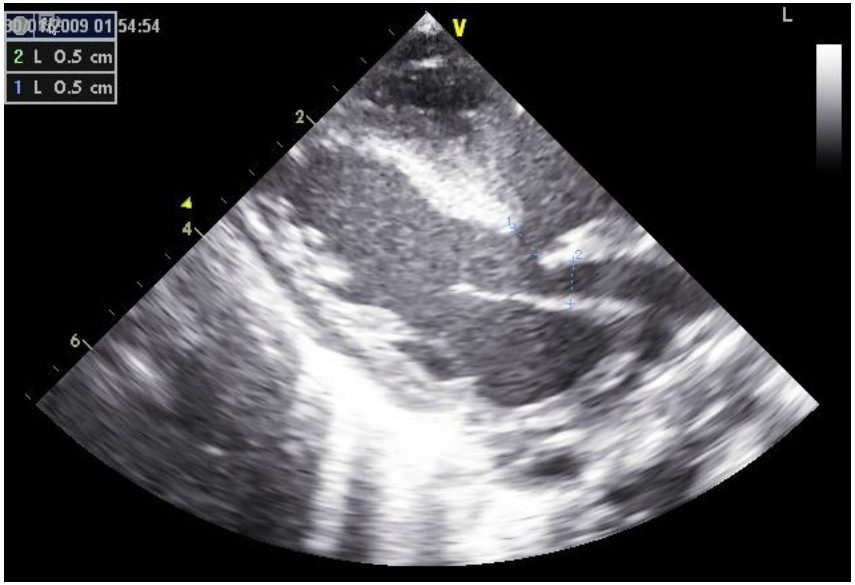

NRS J10
Pas de pouls fémoraux
Acidose métabolique
IC+++
Réapparition des pouls sous pro tine

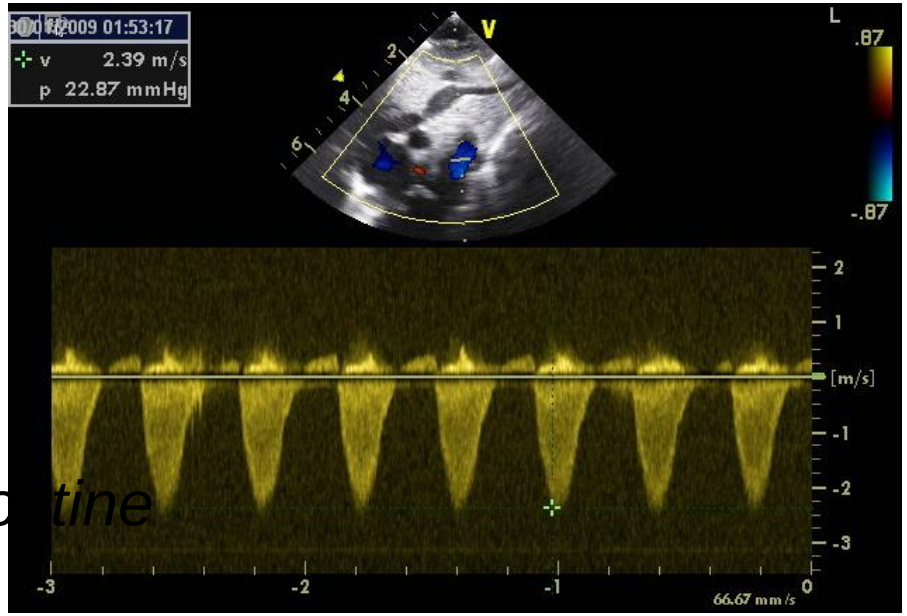

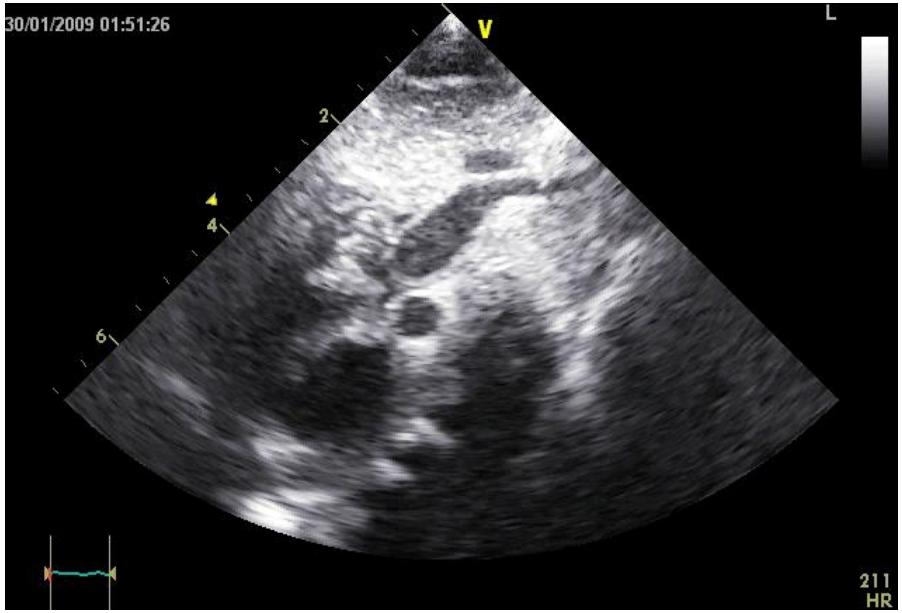
30/01/2009 01:51:26
V
L
2
4
6
211
HR

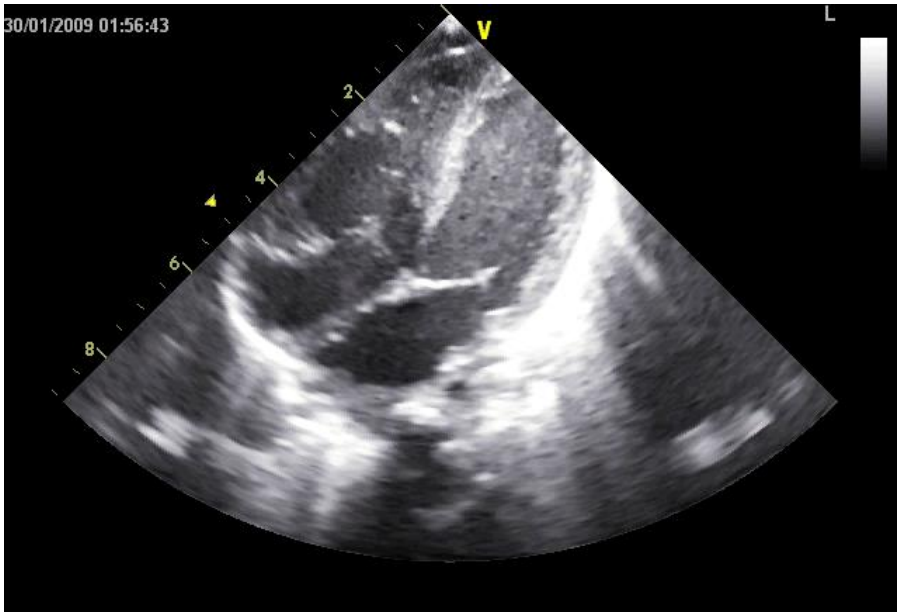
30/01/2009 01:56:43
V
L
2
4
6
8

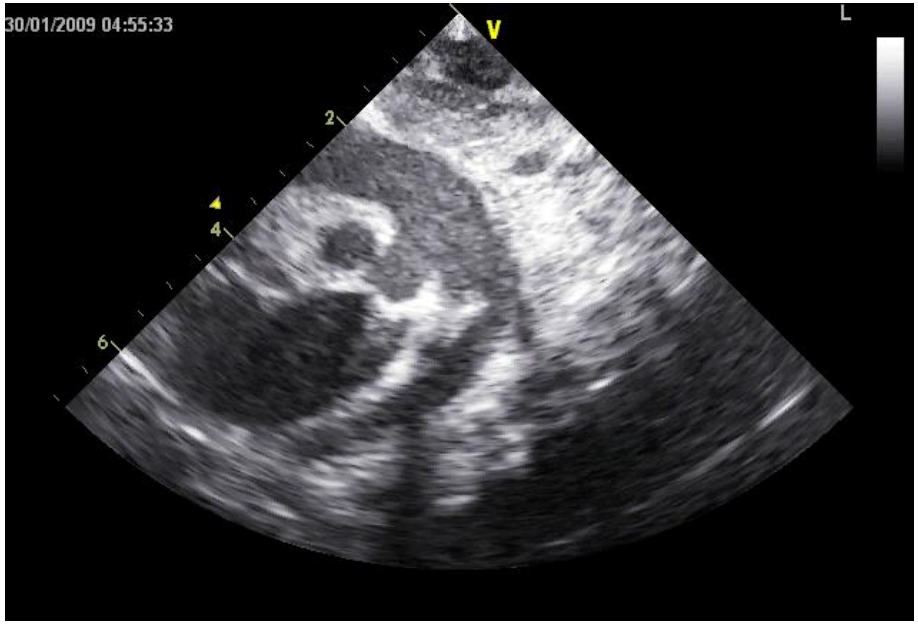
30/01/2009 04:55:33
V
L
2
4
6

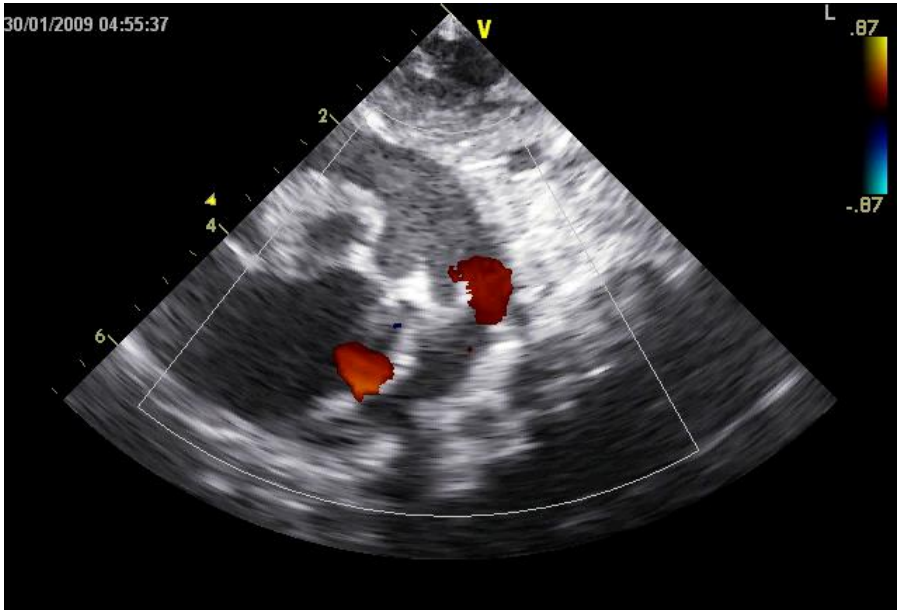
30/01/2009 04:55:37
V
L
.87
-.87
2
4
6

Interruption de l'Arche Aortique (IAA)

- Interruption complète de l'arc aortique entre Ao ascendante et descendante :
  - Ductodépendance +++
  - Prise en charge médico-chirurgicale urgente
  - Diagnostic fait 70% $\leq$ 1 semaine
    95% $\leq$ 1 mois
- Malformation rare
  - 1% des cardiopathies congénitales
  - 6 pour 100.000 naissances
- Association au syndrome de Di George (del 22q11)
  - 50 à 60% des cas (surtout IAA type B)

I.A.A.

- Association :
  - à une CIV large sous Ao +++
  - une hypoplasie ± marquée anneau Ao et Ao ascendante
  - Obstruction sous Ao ± marquée par déplacement du septum conal

- Type A : IAA après la sous-clavière gauche (44% cas)
  B : IAA après la carotide gauche (52% cas)
  C : IAA après la carotide droite (4% cas)

- Autres associations :
  - Tronc artériel commun
  - Cardiopathies complexes (VU, malposition des gros vaisseaux, CAVC…)

I.A.A

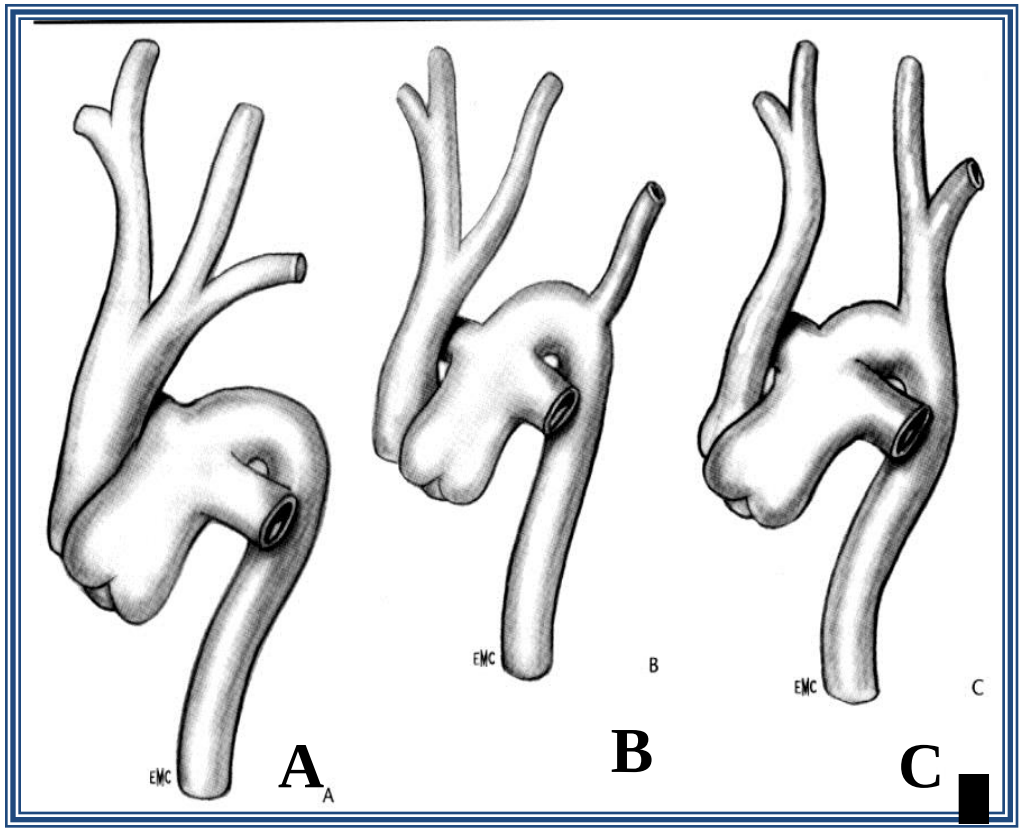

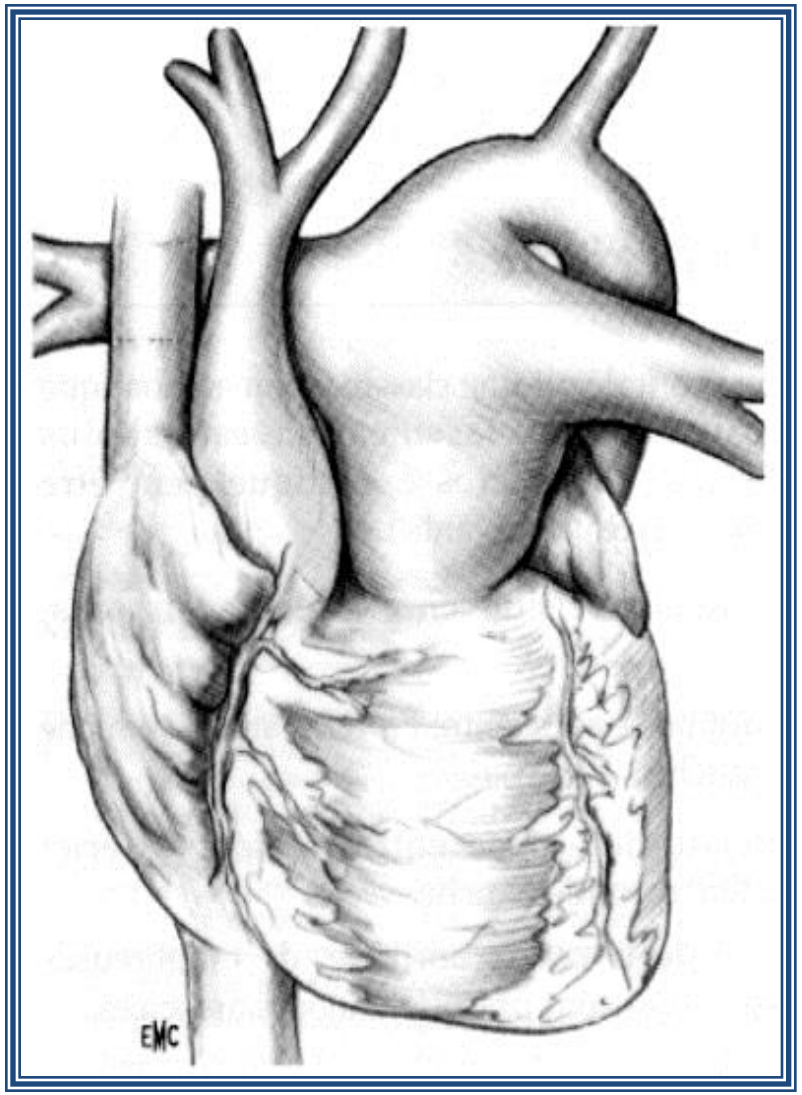

Type A: 40%
Type B: 55% (Di George)
Type C: 5 %

I.A.A. - Physiopathologie

- Perfusion par le CA de l'Ao descendante :

  - Ductodépendance +++
  - Tolérance clinique dans les 1ers jours de vie :
    - CA large assez bonne tolérance
    - CA restrictif
      → défaillance cardiaque
      → ↘ débit partie inférieure du corps

      - hypoperfusion rénale
      - ↗ rénine
      - vasoconstriction périphérique généralisée
      - acidose métabolique – insuffisance hépatique

    - CA quasi fermé
      → déchéance multiviscérale
      → prostine IV +++

I.A.A. - Physiopathologie

- Obstacle sous Ao même modéré :
  - ↗ shunt G – Dt à travers la CIV
  - ↗ de l'hypertension artérielle pulmonaire

↓

insuffisance cardiaque par ↗ débit pulmonaire

↓

Ne survient que plusieurs heures ou jours après la naissance quand les résistances vasculaires baissent et si CA reste ouvert

I.A.A. – Tableau clinique

- Examen clinique :
  - Signes d'insuffisance cardiaque
  - Asymétrie des pouls :
    - ↘ des pouls fémoraux
    - ↘ du pouls radial gauche **Type B**
    - Abolition des pouls fémoraux, ± radial gauche si CA en voie de fermeture
  - Faciès Di George
- Echo : clef du diagnostic :
  - Diagnostic ⊕ (IAA + CIV + degré d'obstacle sous aortique)
  - Types IAA
  - Anomalies associées
- Cathétérisme exceptionnel → sauf si doute
  - Après perfusion PGE_1 (Prostine)

Sténoses aortiques

Lésions simples

intéressent un seul étage de la voie d'éjection ventriculaire gauche

se divisent en :

- sténoses supra-valvulaires : +
- sténoses valvulaires : +++
- sténoses sous-valvulaires : ++

Lésions complexes

- intéressent plusieurs étages de la voie d'éjection ventriculaire gauche
- formes les plus fréquentes
  - sous-valvulaire diffuse + valvulaire
  - supra-valvulaire + valvulaire
  - sténose diffuse des 3 étages
- souvent récidives de lésions simples (réinterventions)

Plan

- **Rao critique néonatal**
- Rao du nourrisson et de l’enfant
  - Rao sous-valvulaire
  - Rao valvulaire
  - Rao supra valvulaire

Physiopathologie

- Pathologie anténatale

- Augmentation de la post charge du VG
- Hypertrophie concentrique
- Augmentation de la pression télédiastolique VG
- Diminution de la compliance du VG
- Ischémie sous endocardique
- Parfois fibrose endomyocardique

Severe aortic stenosis in the fetus and the evolution of HLHS

Valvular AS ➔ LV dysfunction / stress

↘

Myocardial damage

↓

Elevated LA and LV pressure

↙

L-R at PFO ← ↓ LV filling

↖

LV growth arrest

↑

HLHS

RAO : HVG =>ischémie sous-endocardique

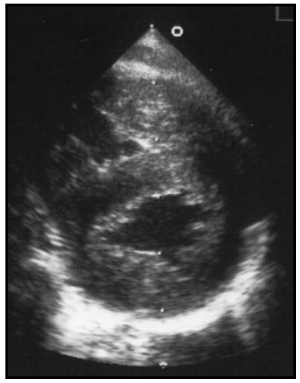

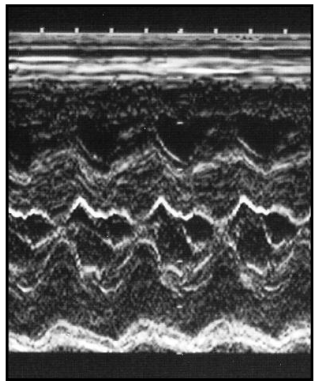

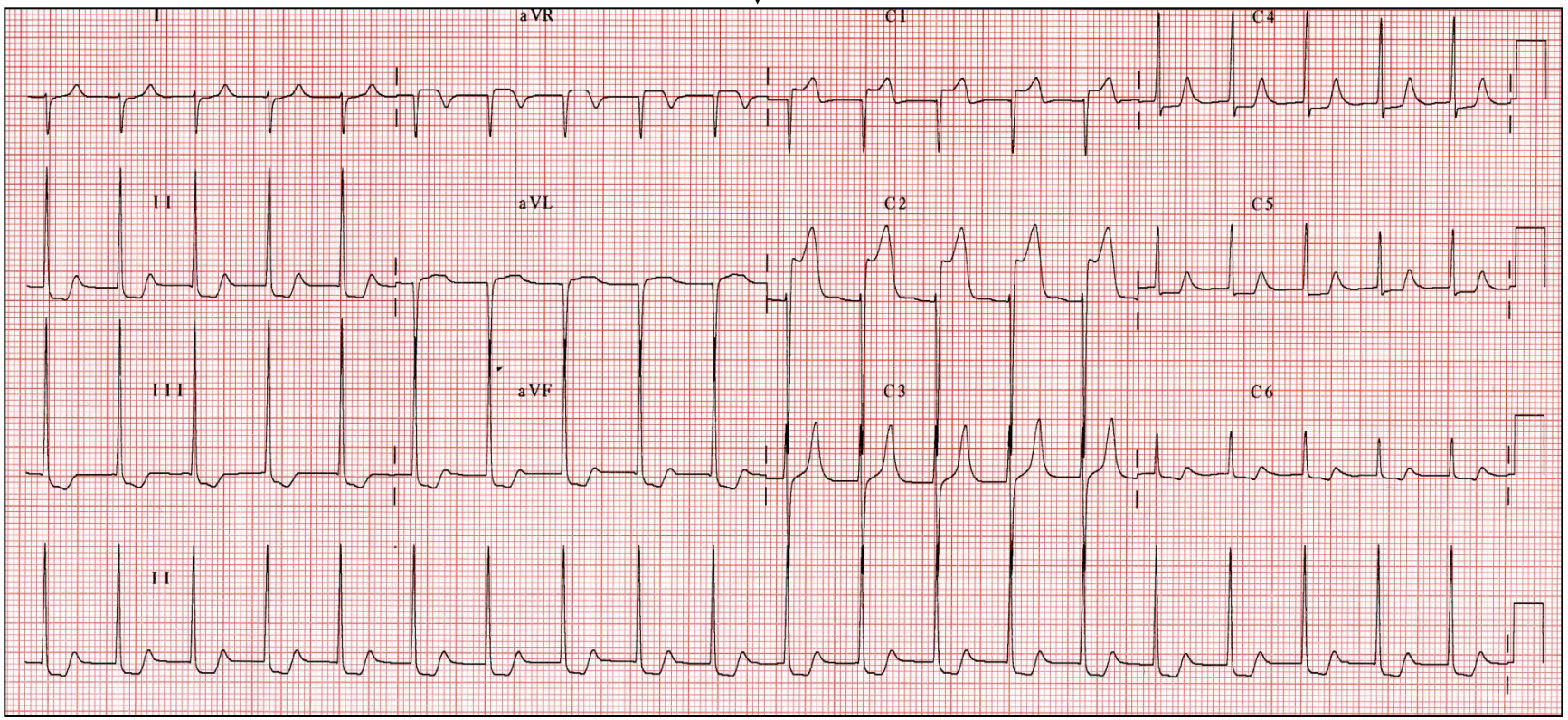

Stratégie thérapeutique et timing

- Sténose valvulaire aortique critique
  - A la naissance si la fermeture du CA est mal tolérée
  - Choix de la stratégie 2 ventricules ou 1 seul
    - En fonction de la forme (simple ou complexe)
      - HLHS,…
    - Des lésions associés

Hypoplasie du VG ou équivalent= HLHS

- Sténose aortique critique avec désadaptation anténatale du VG
  - évolution vers l'hypoplasie du cœur gauche (HLHS)
- Formes frontières avec dysfonction moyenne du VG et taille limites:
  - difficulté d'appréciation du potentiel évolutif
  - hypo VG vs circulation biventriculaire

- Critères de Rhodes+++

(circulation 1991)

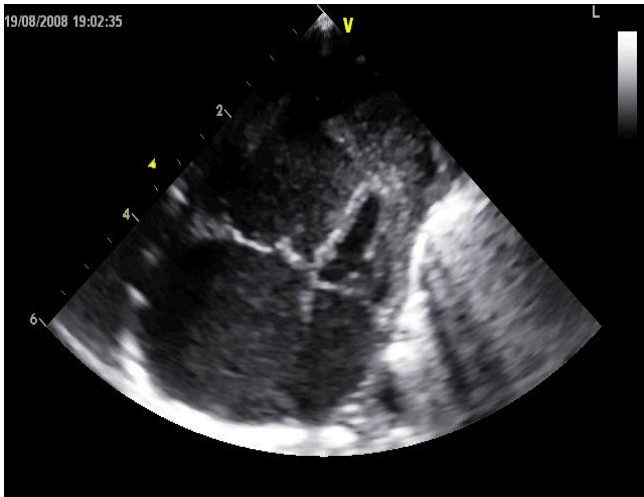

Evaluation d’une voie aortique = évaluation voie VG-AO

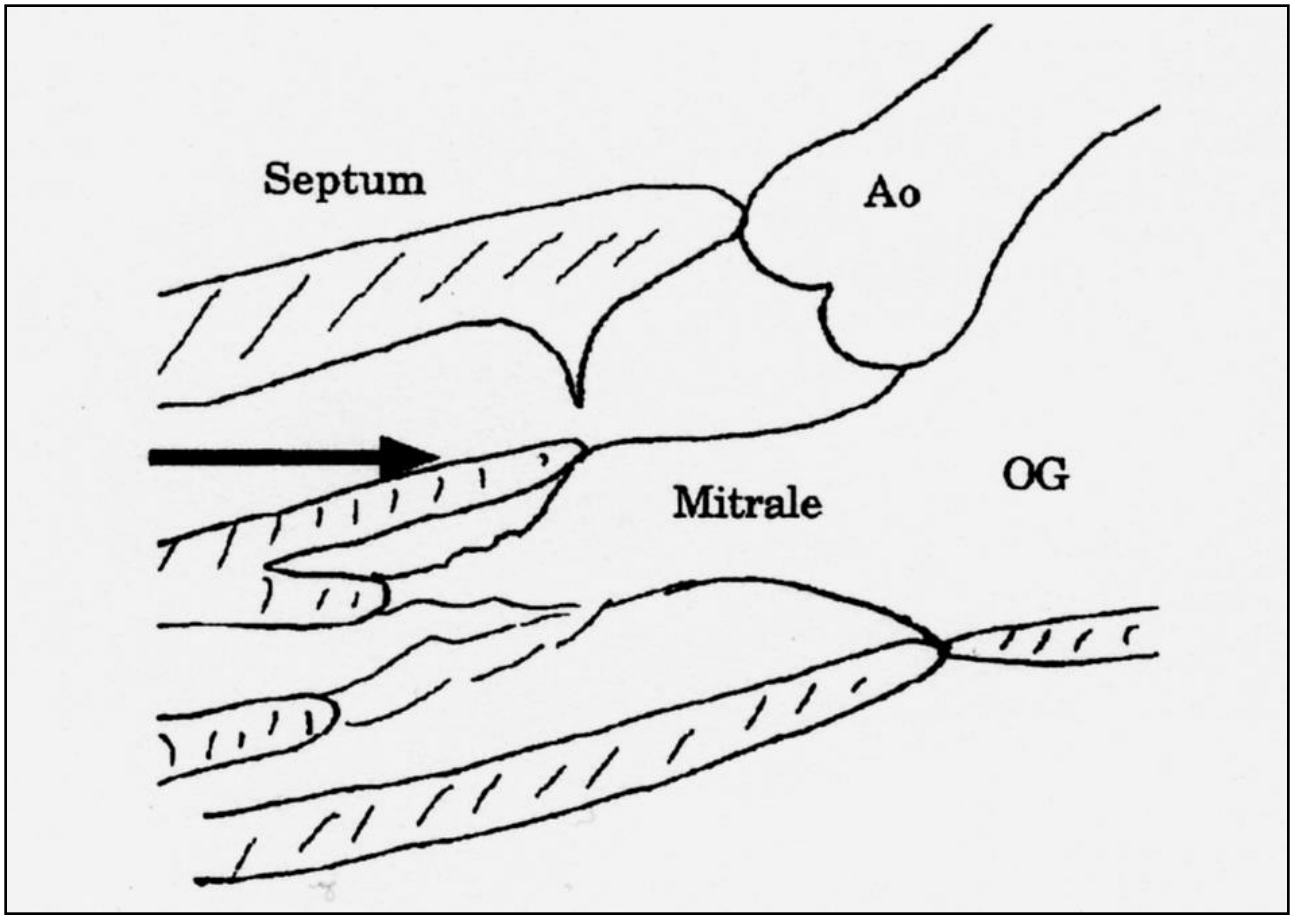

Recherche lésions associées-évaluation voie aortique

- La valve mitrale
  - Anneau
  - Membrane sous mitrale*
  - Morphologie mitrale (parachute)*
  - Tissu accessoire
- Taille du VG, hypertrophie VG
- Voie sous aortique*
- Valve (uni, bi, tricuspide)
- Anneau aortique*
- Crosse aortique*

→ ***Sd de shone**

Attitudes thérapeutiques

Sténoses valvulaires (simple)

- valvuloplastie
    - commissurotomie
    - libération commissurale
    - amincissement bord libre
    - extension péricardique

- > dilatation percutanée

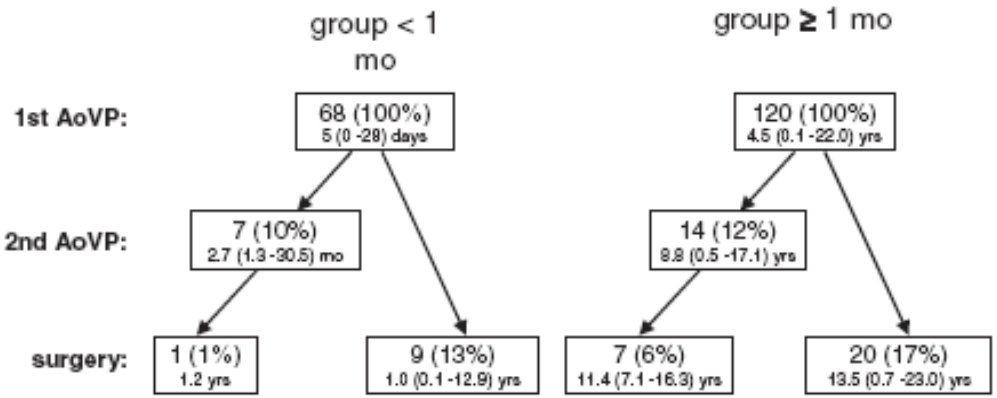

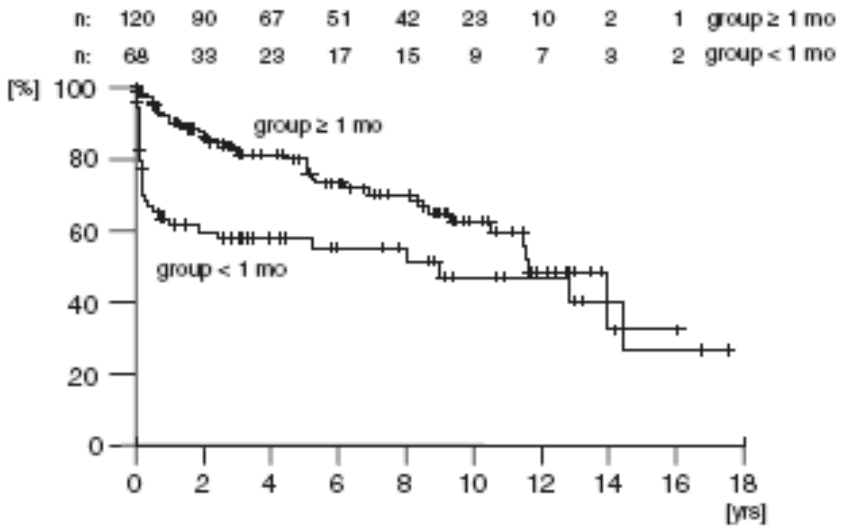

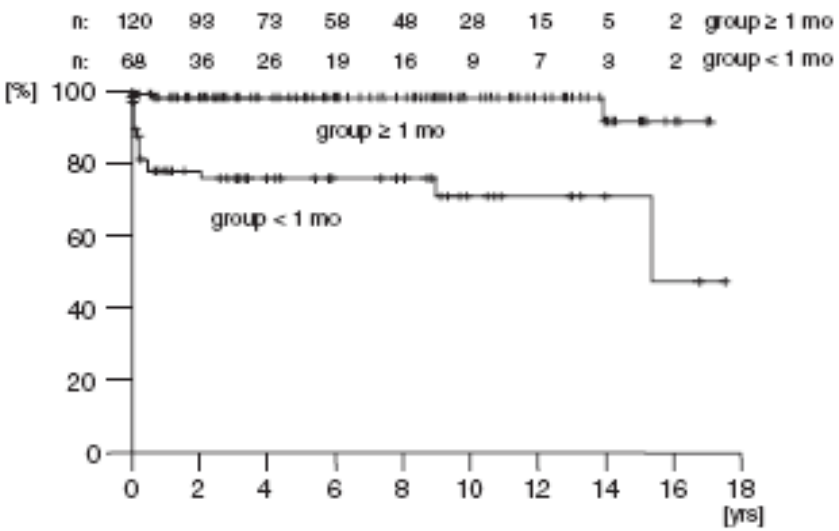

Courbe de survie sans réintervention
Mortalité groupe 1: 38% (<1998), 1% (>1998)
1998: programme Norwood

Courbe de survie globale

Fratz S. *Circulation* 2008

Aortic balloon dilatation for congenital aortic stenosis: report of 90 cases (1986–98)

A Borghi, G Agnoletti, O Valsecchi, M Carminati

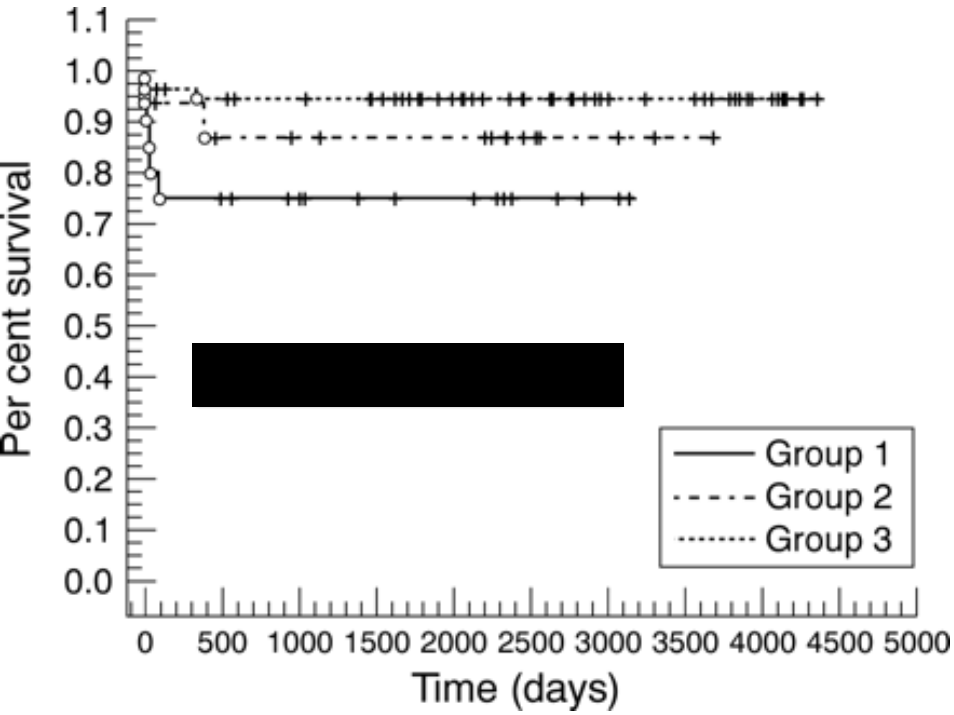

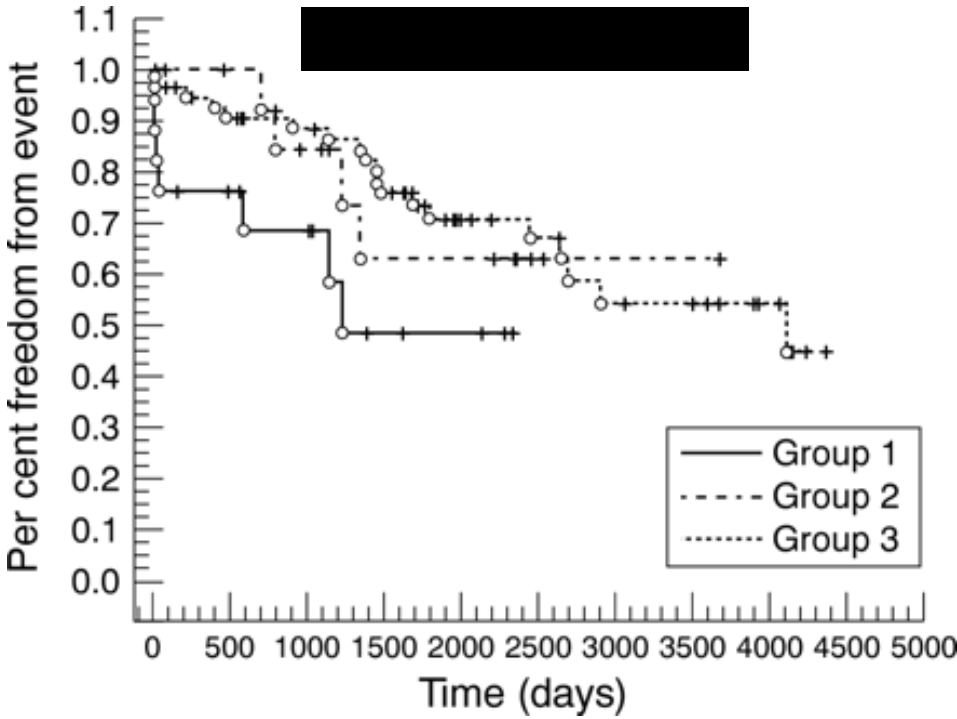

Groupe 1: < 1 mois

Groupe 2:< 1 an

Groupe 3:> 1 an

Heart 1999

Plan

- Rao critique néonatal
- Rao du nourrisson et de l'enfant
- 5% des cardiopathies congénitales
- 15% de lésions associées
  - Voie gauche+++, sténoses pulm, CIV, CAV
  - Rao supra valvulaire
  - Rao valvulaire
  - Rao sous-valvulaire

Sténoses valvulaires

- Bicuspidie (70%)
- Valve tricuspide (30%)
- Valve unicuspide
- Forme indifférenciée

- Anomalie du tissu valvulaire dans les formes infantiles
- Analyse de la filière gauche (forme limite HLHS)+++
- TTT chirurgical dépendant de l'âge

main category: number of raphes	0 raphe - Type 0		1 raphe - Type 1			2 raphes - Type 2
	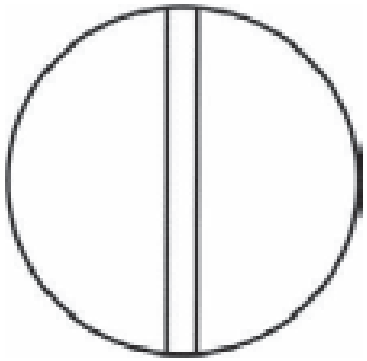		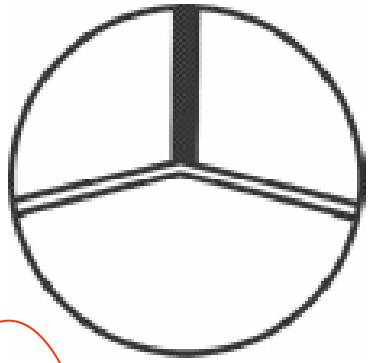			
	21 (7)		269 (88)			14 (5)
1. subcategory: spatial position of cusps in Type 0 and raphes in Types 1 and 2	lat 13 (4) 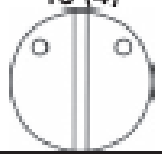	ap 7 (2) 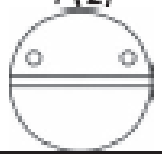	L – R 216 (71)	R – N 45 (15)	N – L 8 (3) 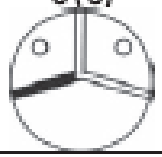	L – R / R – N 14 (5)
2. subcategory:						
VALVULAR FUNCTION: I	6 (2)	1 (0.3)	79 (26)	22 (7)	3 (1)	6 (2)
VALVULAR FUNCTION: S	7 (2)	5 (2)	119 (39)	15 (5)	3 (1)	6 (2)
VALVULAR FUNCTION: B (I + S)		1 (0.3)	15 (5)	7 (2)	2 (1)	2 (1)
VALVULAR FUNCTION: No			3 (1)	1 (0.3)		

Sievers HH et al.J Thorac Cardiovasc Surg. 2007;1226-33

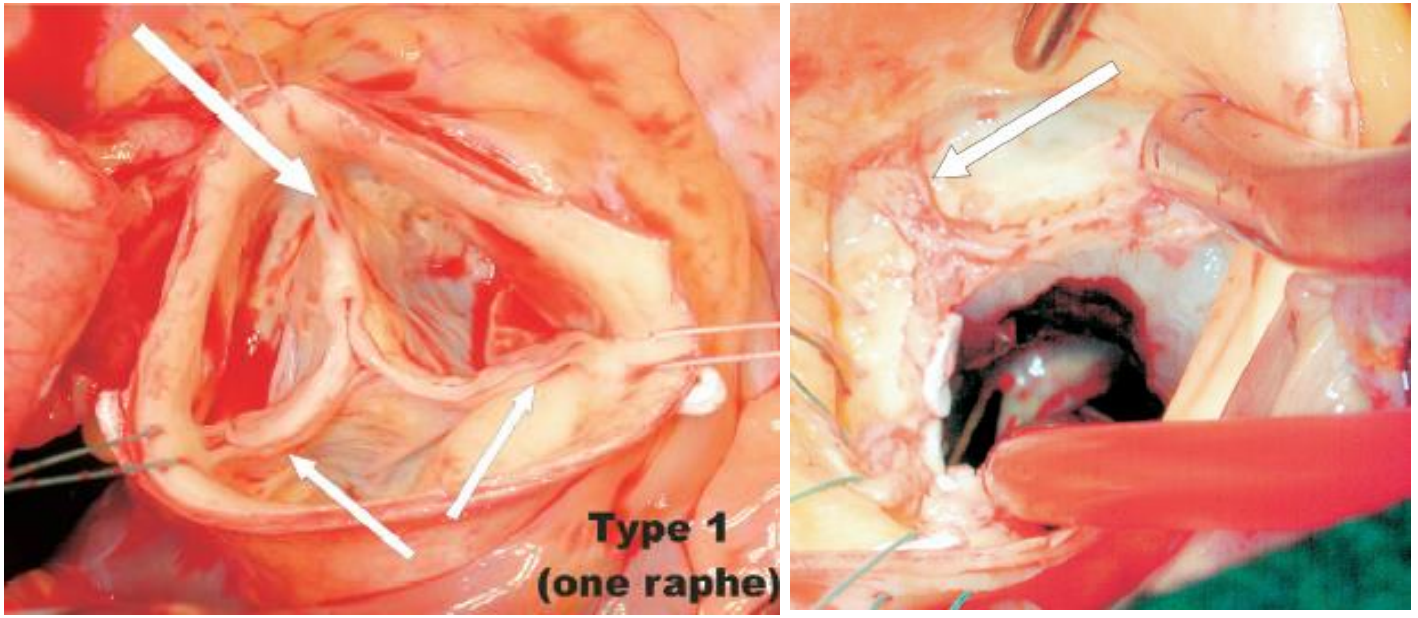
Type 1
(one raphe)

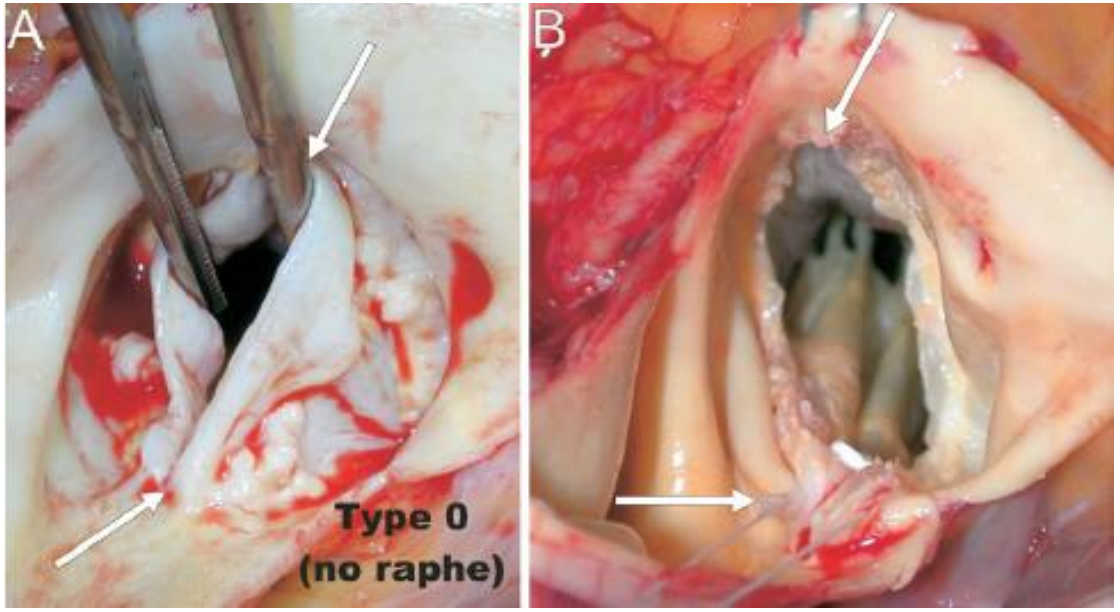
A
B
Type 0
(no raphe)

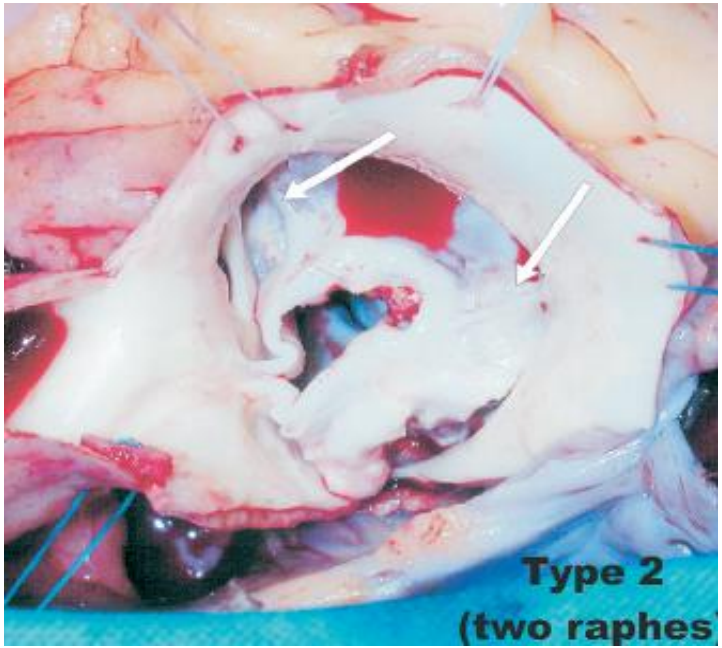
Type 2
(two raphes)

Limites anatomiques de l'artériopathie

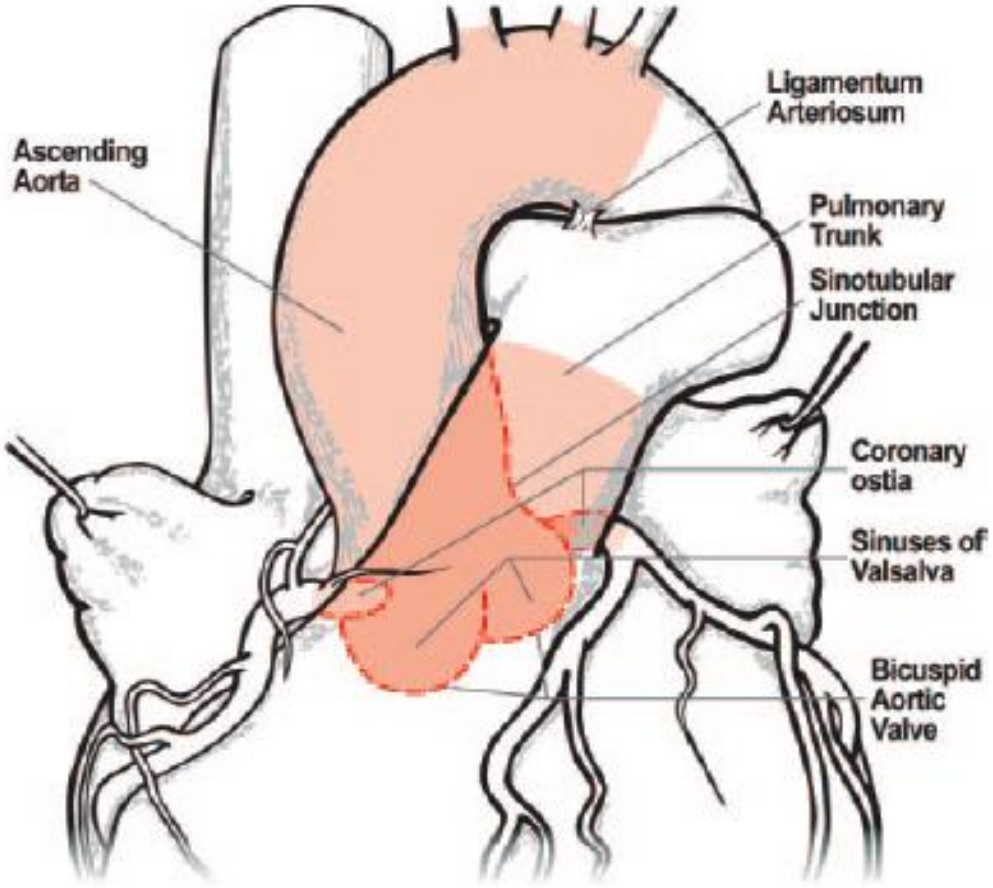

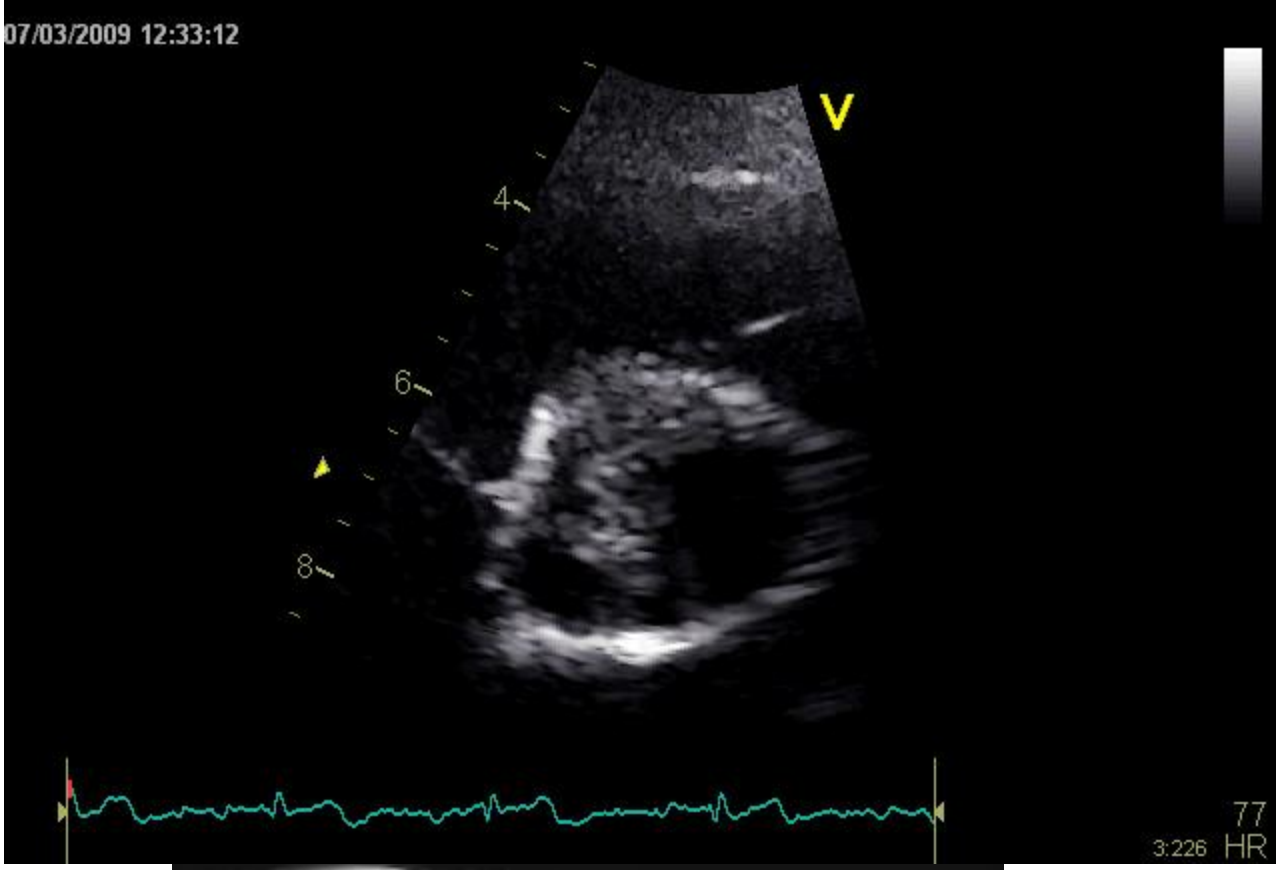
07/03/2009 12:33:12
V
4
6
8
77
3:226 HR

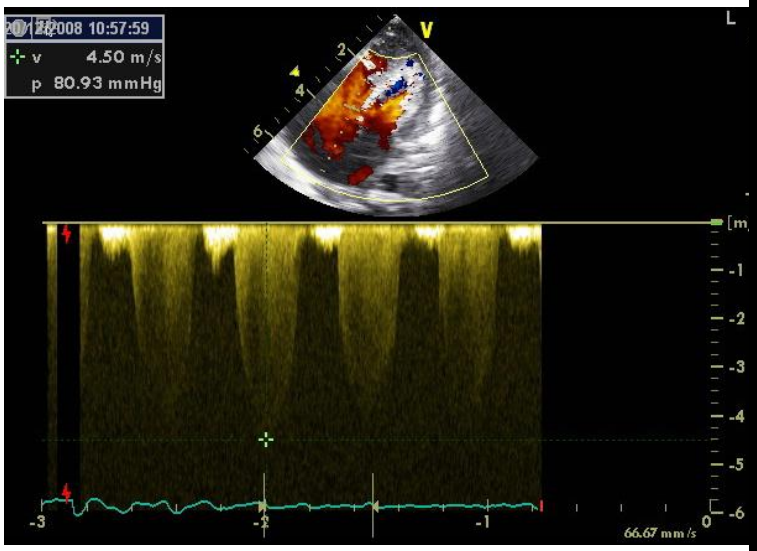
2008 10:57:59
v 4.50 m/s
p 80.93 mmHg
V
L
66.67 mm/s

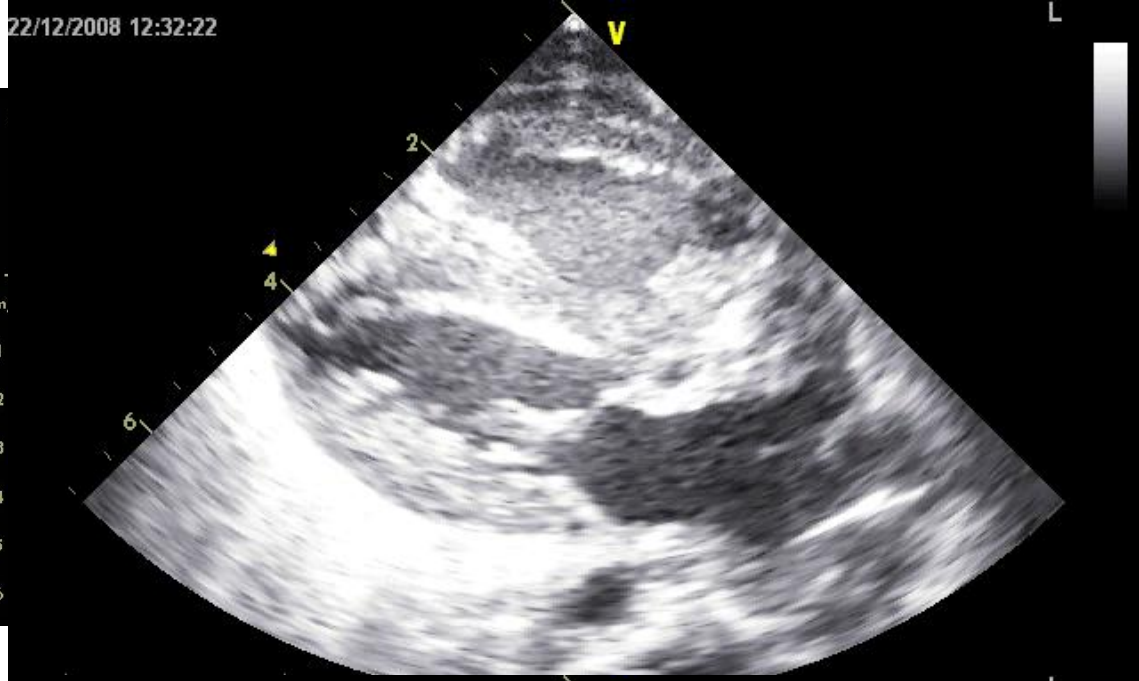
22/12/2008 12:32:22
V
L

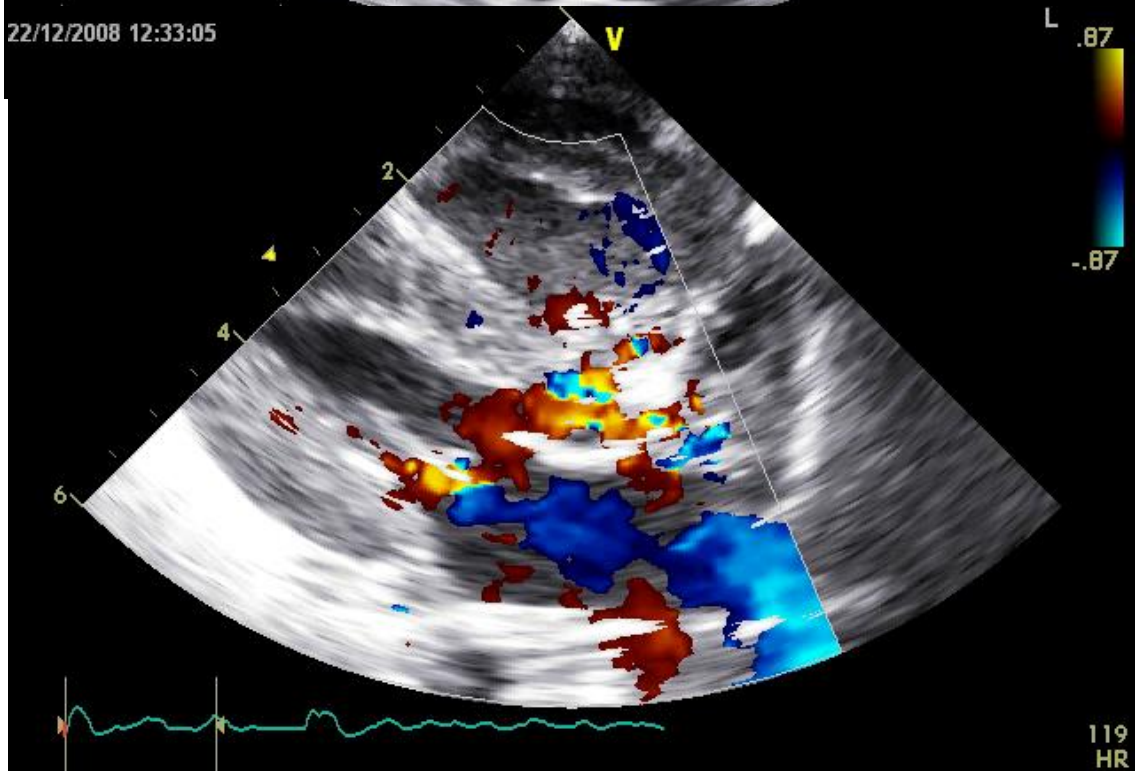
22/12/2008 12:33:05
V
L
.87
-.87
119
HR

Timing de l’intervention

- Sténose valvulaire aortique « tardive »
  - En fonction du gradient VG aorte
  - En fonction de l’épreuve d’effort
  - Eviter la mort subite & l’angor d’effort

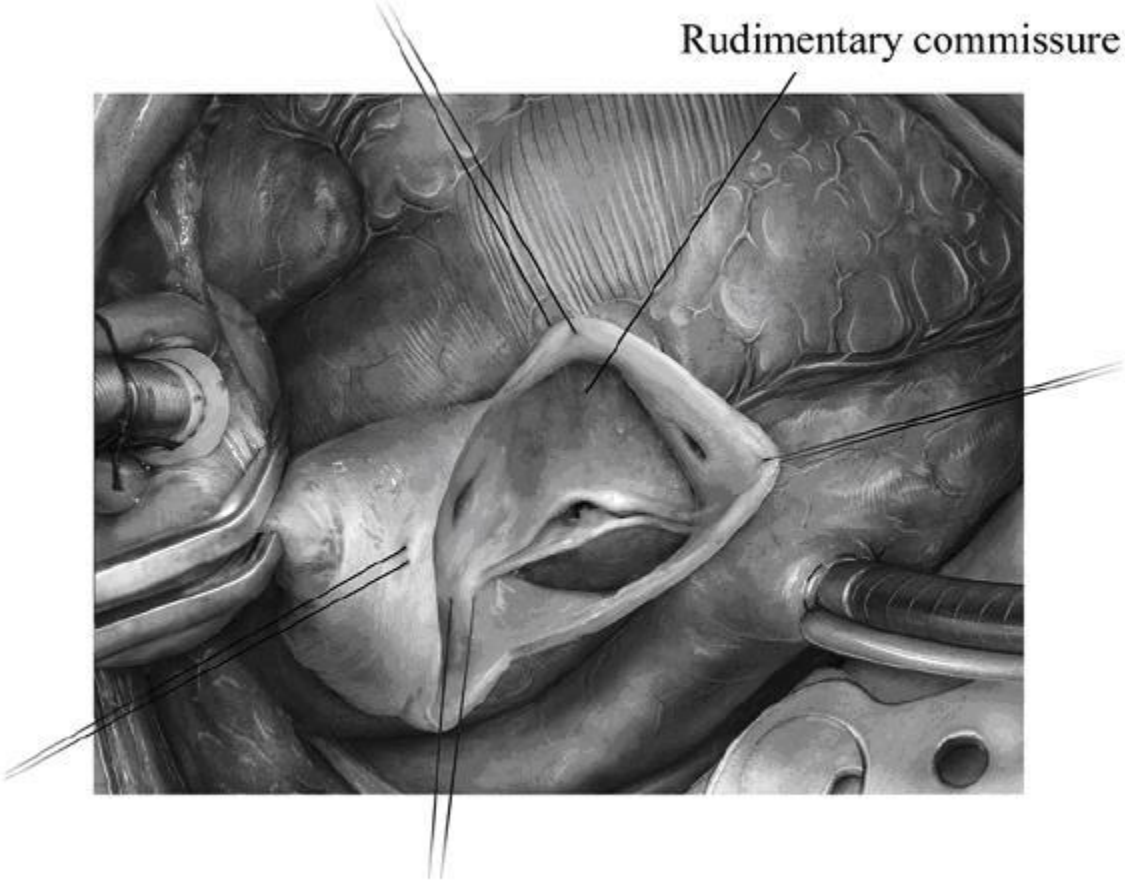
Rudimentary commissure

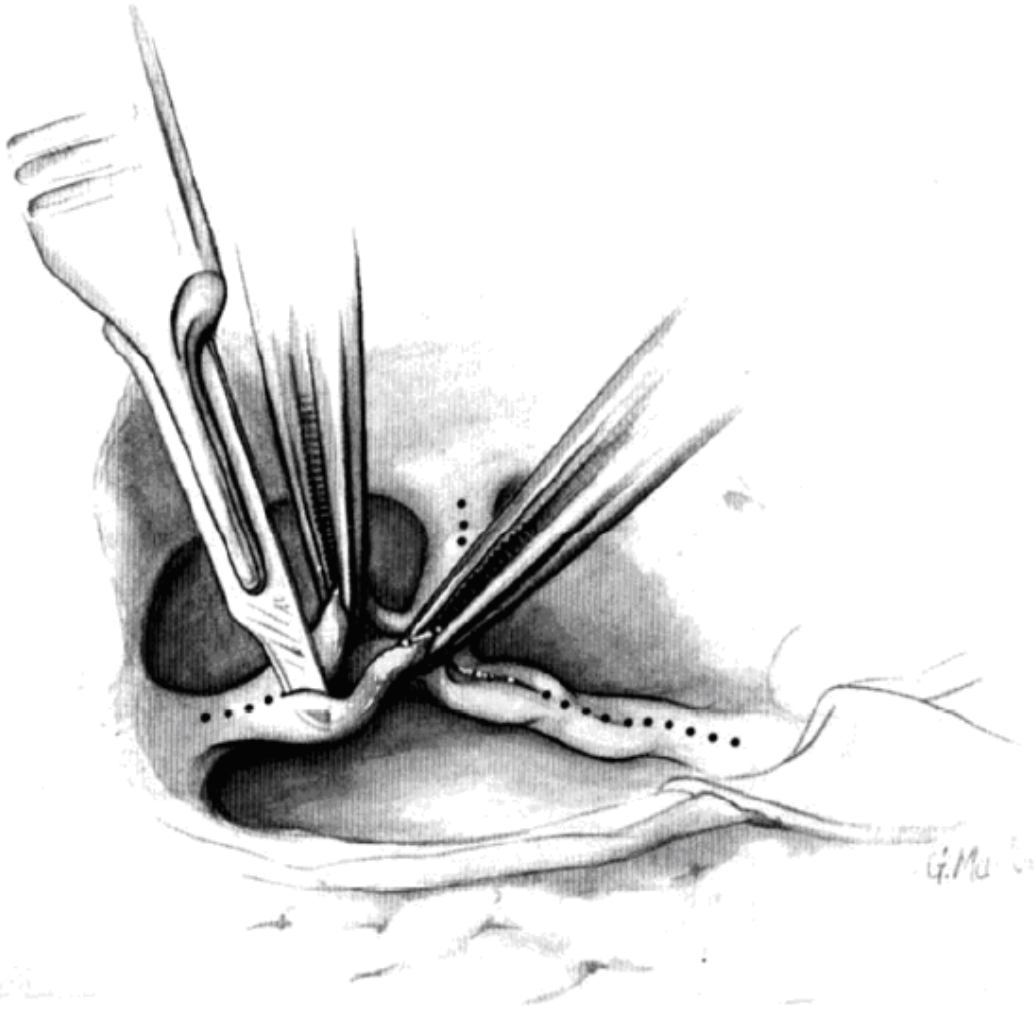

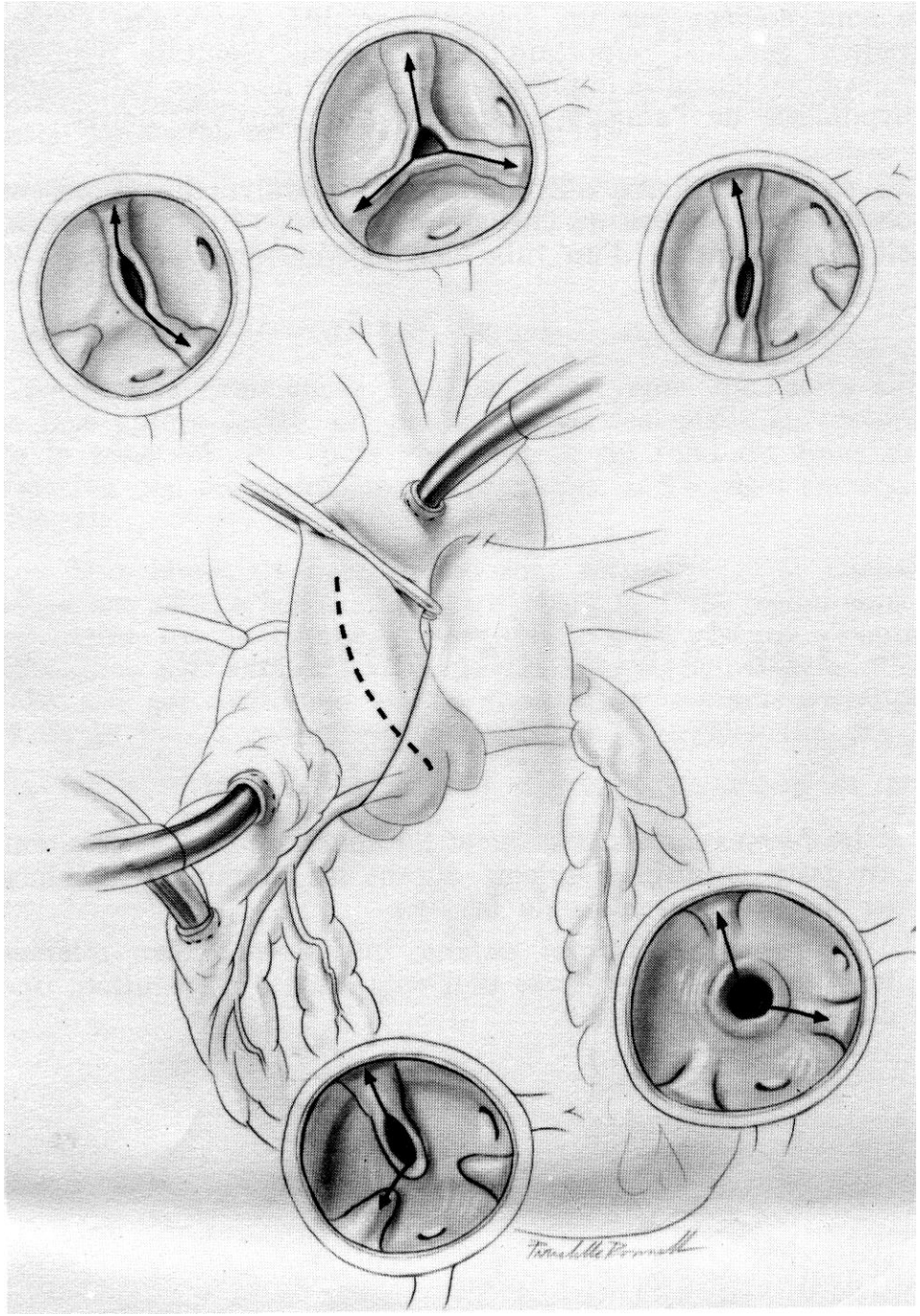

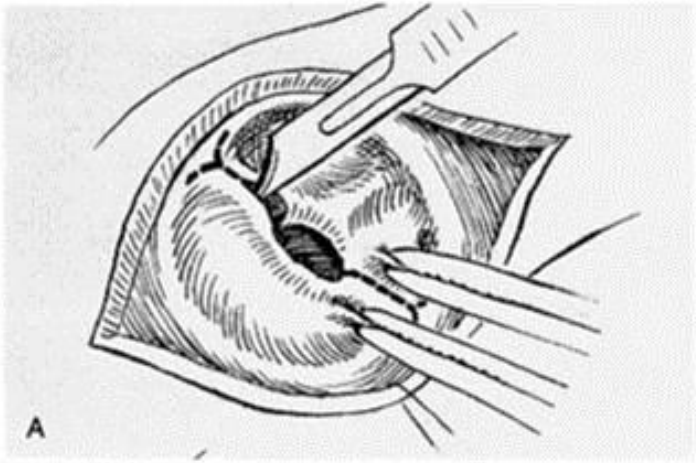
A

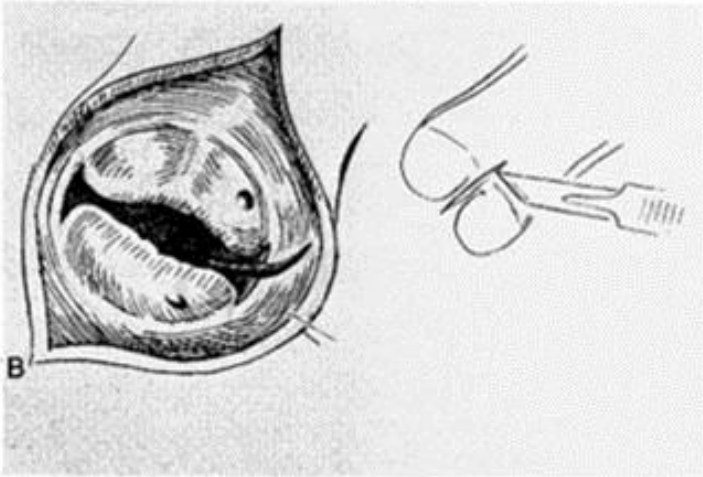
B

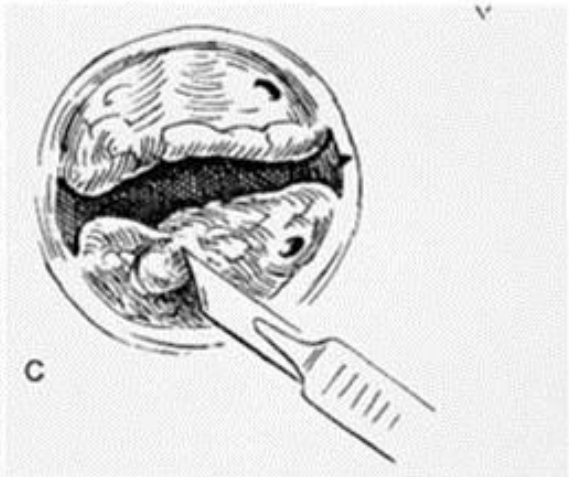
C

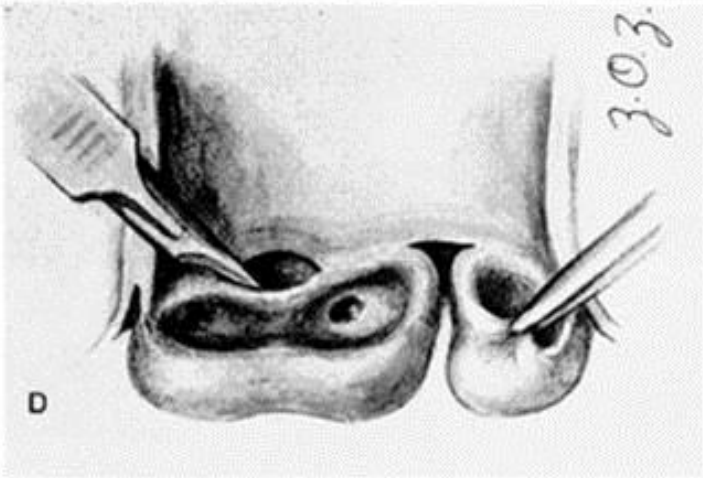
3.0.3.
D

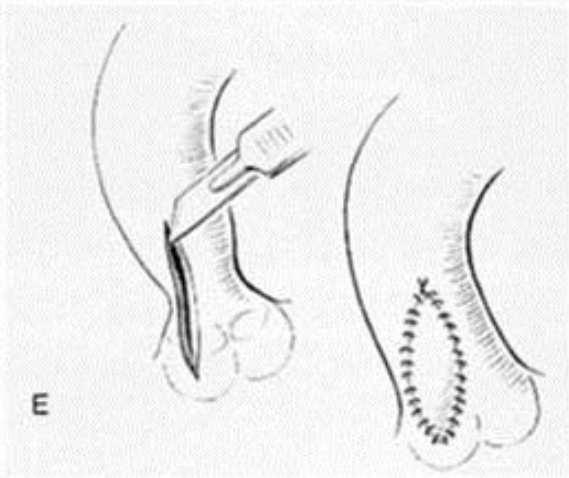
E

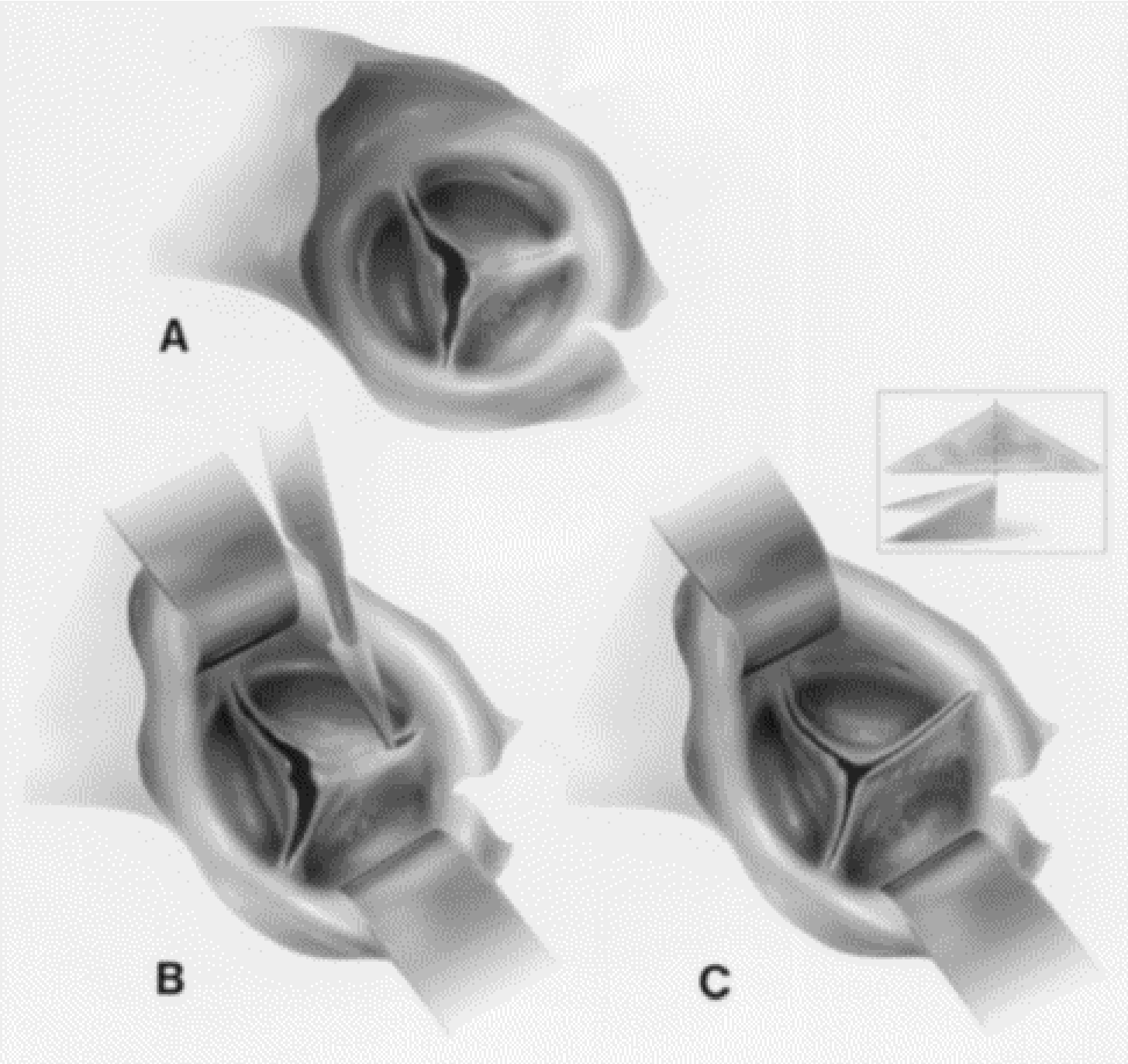
A
B
C

Sténoses sous valvulaires

- 25% des obstacles G, prédominance masculine
- Polymorphisme des lésions
- 20 à 60% de lésions associées
- Lésions « acquises » (absente chez le NN)
- Facteurs génétiques et anatomiques communs
  - Angle VG-Ao, déplacement septum conal, anomalies mitrales
- Évolutivité
  - Majoration du gradient, HVG, lésion Aortique

CAT: stratégie chirurgicale préventive?

Polymorphisme des lésions

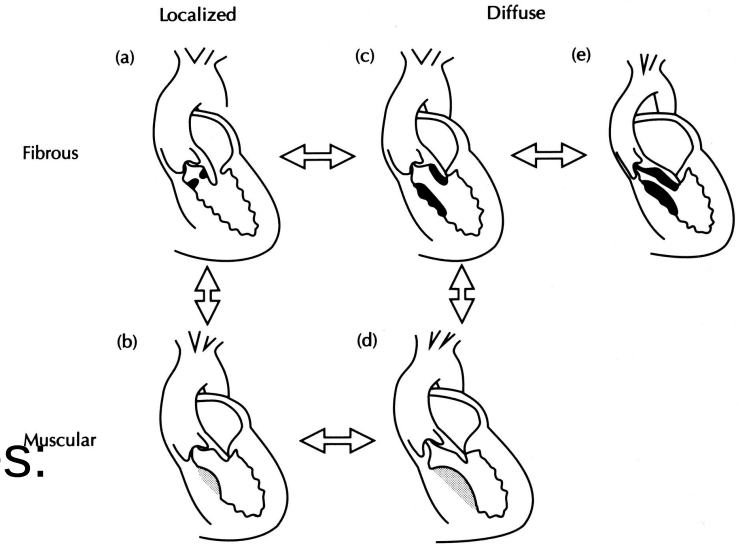

Localisées : + fréquentes (80 %):
- Membrane, Bourrelet fibreux
- Récidive++++
- Extension valvulaire Ao mitrale

Sténose diffuse : + rares et complexes:
tunnel fibro-musculaire
Anomalie associée: hypoplasie anneau Ao

Origine valvulaire mitrale : 1)insertion anormale d'un muscle papillaire sur la grande valve, 2)anomalie d'insertion du muscle papillaire ou d'un cordage sur le SIV (déviation ant: SAM), 3) muscularisation de la jonction mitro-aortique (moulaert)

Sténoses sous-valvulaires

1/ localisées

- causes diverses
  - membrane fibreuse
  - tissu mitral accessoire
  - anomalies appareil sous-valvulaire mitral

- traitement
  - résection obstacle
  - myectomie septale associée +++

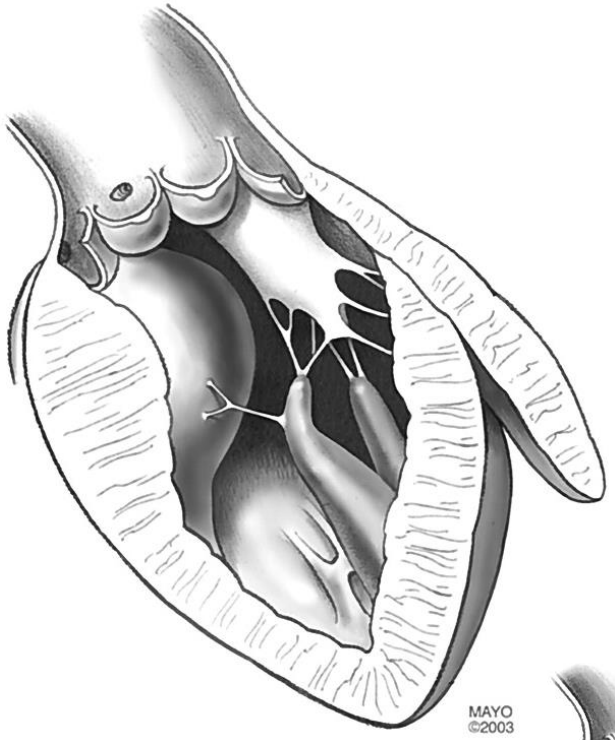
MAYO
©2003

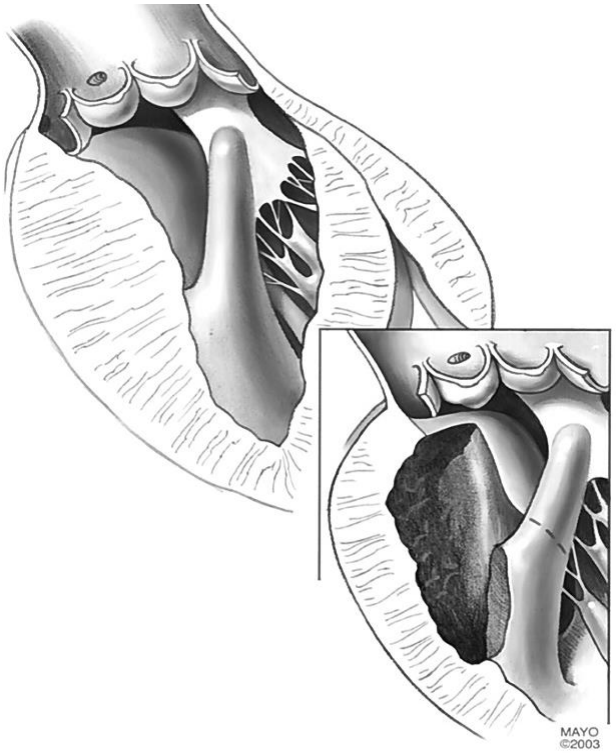
MAYO
©2003

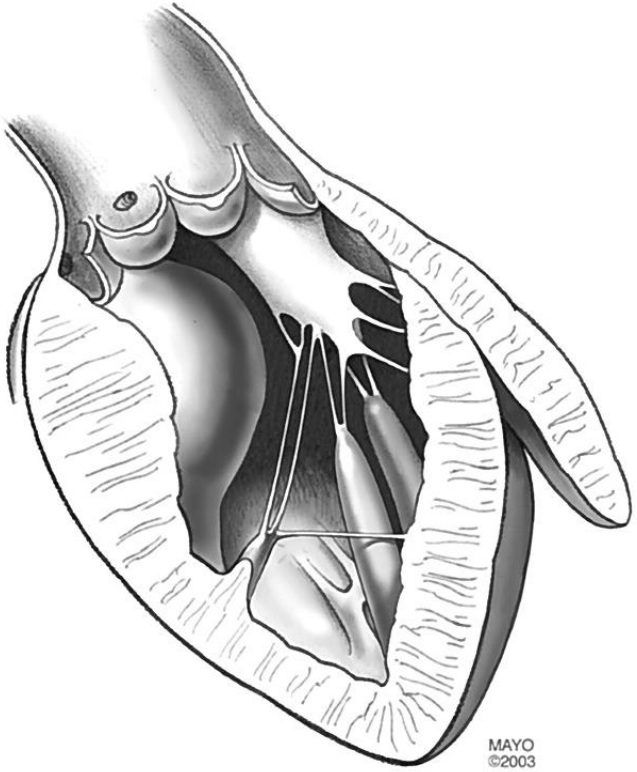
MAYO
©2003

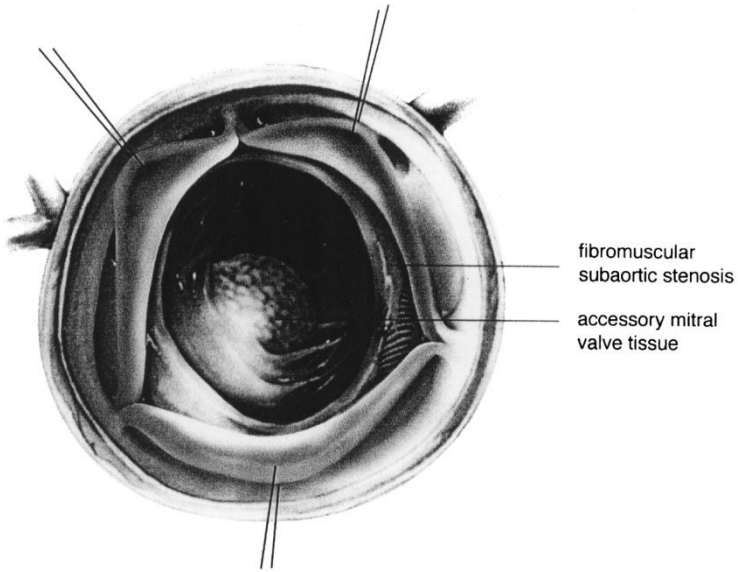
fibromuscular
subaortic stenosis
accessory mitral
valve tissue

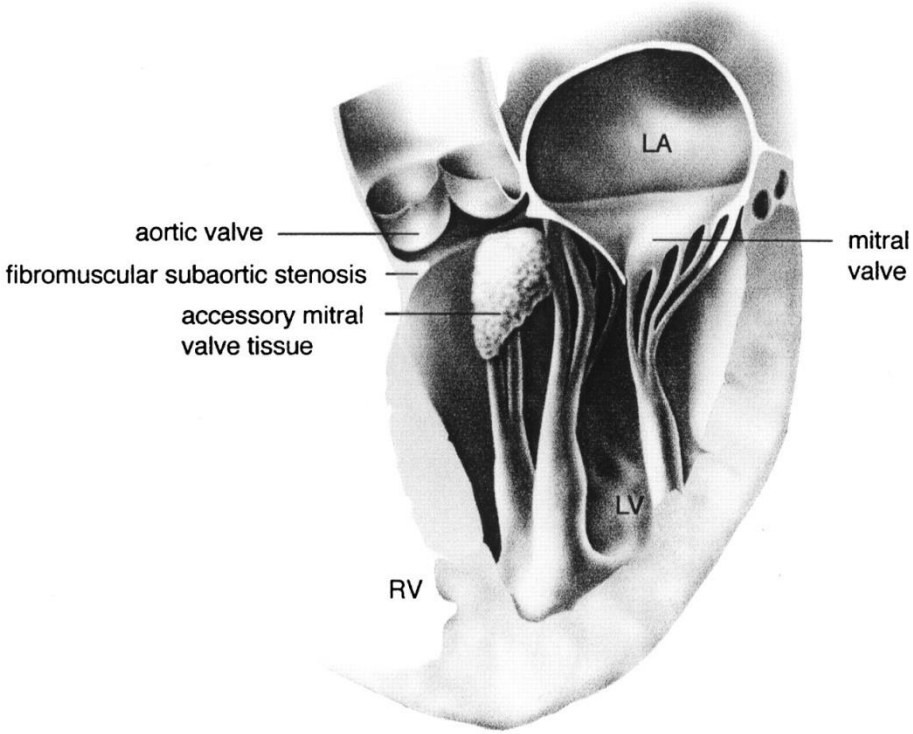
LA
aortic valve
fibromuscular subaortic stenosis
accessory mitral
valve tissue
mitral
valve
LV
RV

Sténoses sous-valvulaires

2/ diffuses

- en général, fibreuses et musculaires
  (formes de transition)

- traitement : intervention de KONNO modifiée
  (septoplastie conale)

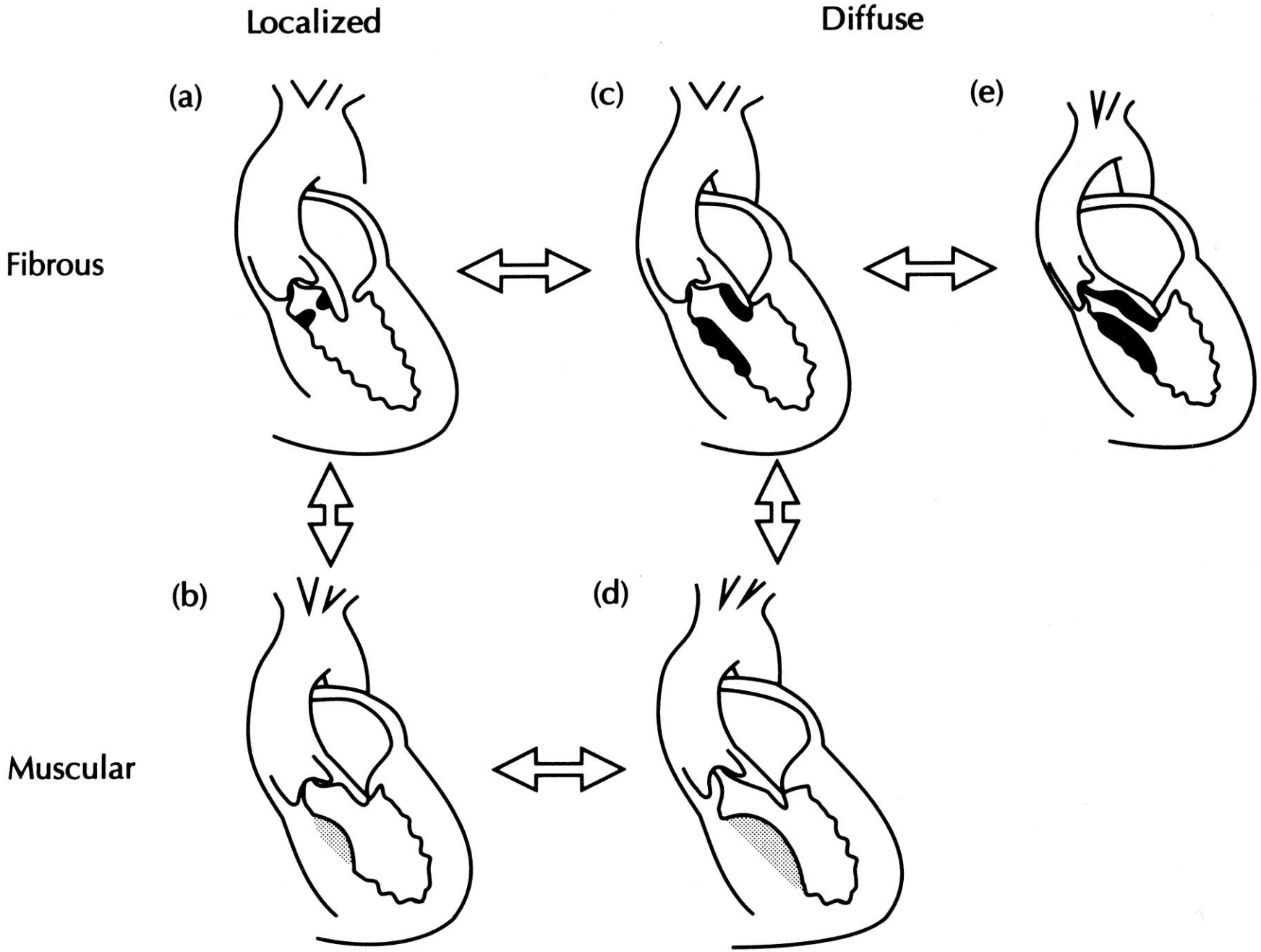
Localized
Diffuse
(a)
(c)
(e)
Fibrous
(b)
(d)
Muscular

Quand opérer?

- Apparition d'une fuite aortique
- Gradient sup à 30-40 mmHg
- Symptomatologie clinique
- En général à l'age de 5 à 10 ans

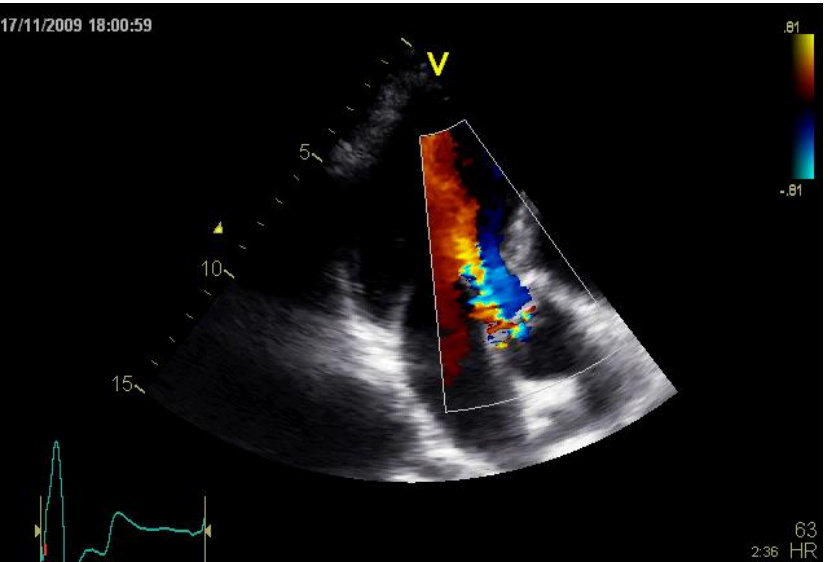

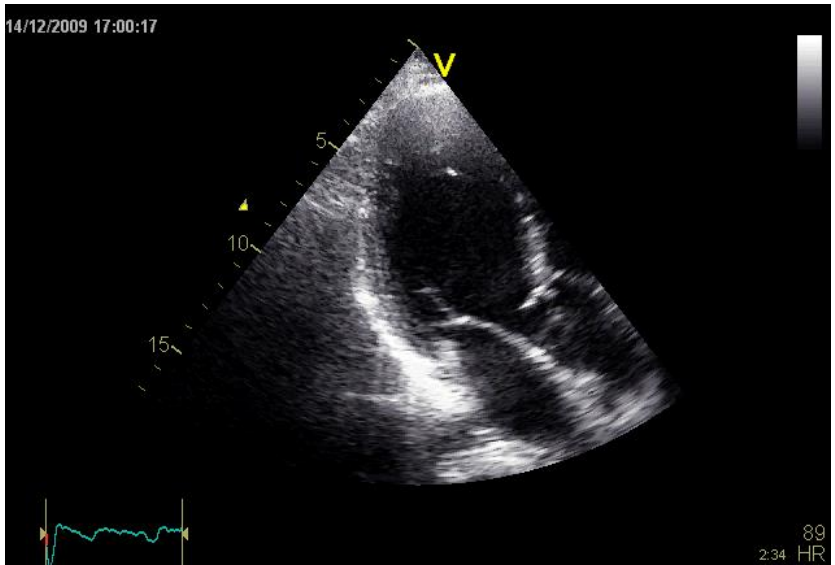

Complications

- BAV complet
- CIV
- Récidive+++
- Lésion valvulaire aortique
- Attention à la composante musculaire en PO (≠ complication. Attention aux cathécolamines)

Sténoses sous-valvulaires

Problèmes spécifiques

- BAV post-opératoire
- lésion coronaire (section 1ère septale)
- lésion valve aortique
- CIV iatrogène

Quand opérer ?

- Apparition d’une fuite aortique
- Gradient sup à 30-40 mmHg
- Symptomatologie clinique
- En général à l’age de 5 à 10 ans

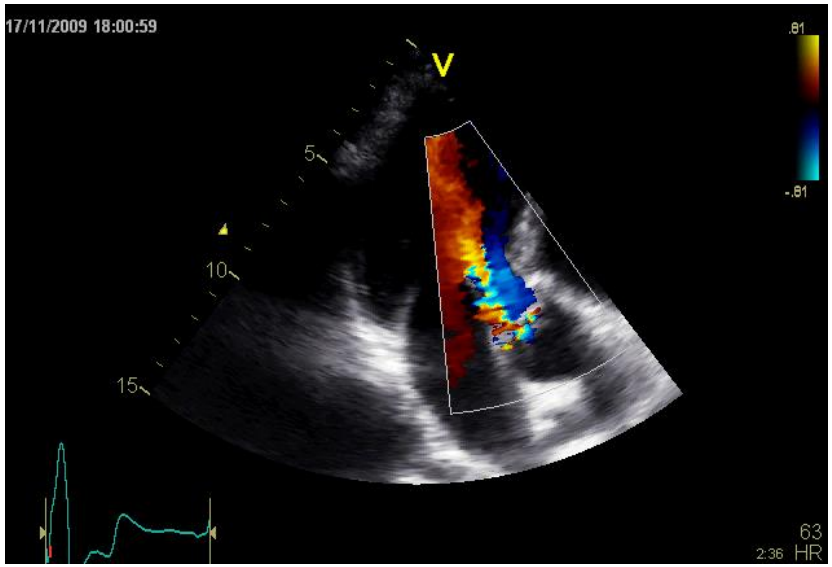

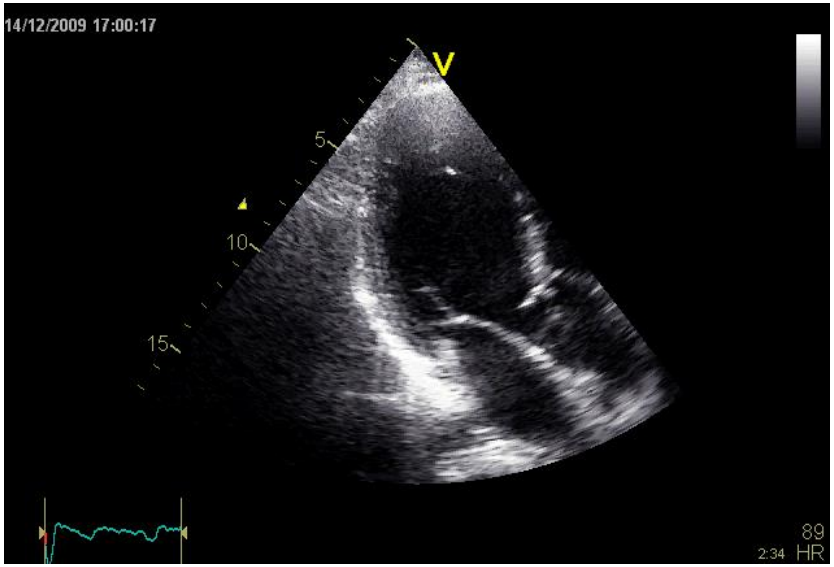

Echographie post opératoire

- Apparition d’une insuffisance aortique
- Gradient transvalvulaire résiduel
- Cinétique du VG
- Remplissage du VG & gradient musculaire sous aortique.

Sténose supra-valvulaire aortique

- Sd de williams et Buren
  - Anomalies associées CV (Aorte, pulm, coronaires) et autres. Mutation 7q11.23
- Forme familiale AD
  - Anomalies associées possible(pulm). Mutation chr 7 (gène elastine)
- Forme sporadique

sténose supra-valvulaire aortique

- ETT
- IRM/TDM
- KT

Anatomie: bourrelet fibreux, fibro musculaire +diminution calibre ext Ao (sablier)± anomalie coronaire gauche

Timing de l'intervention

- Gradient transvalvulaire de 40-50 mmHg
- Apparition de l'hypertrophie VG
- Eviter la mort subite à l'effort
- Attention à l'infiltration des ostia coronaires

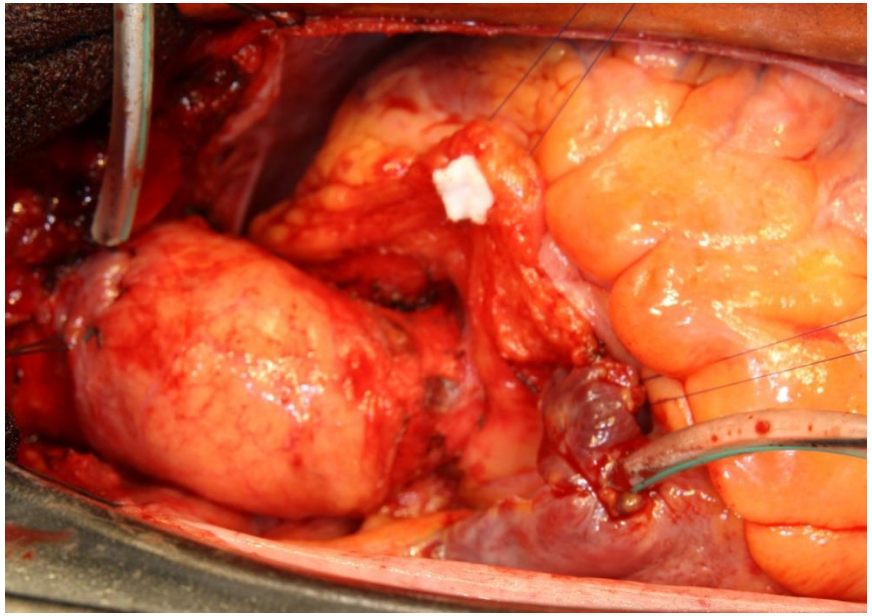

Sténoses supra-valvulaires

- reconstruction jonction sinotubulaire
- intervention de BROM

Sténoses supra-valvulaires

Problèmes spécifiques

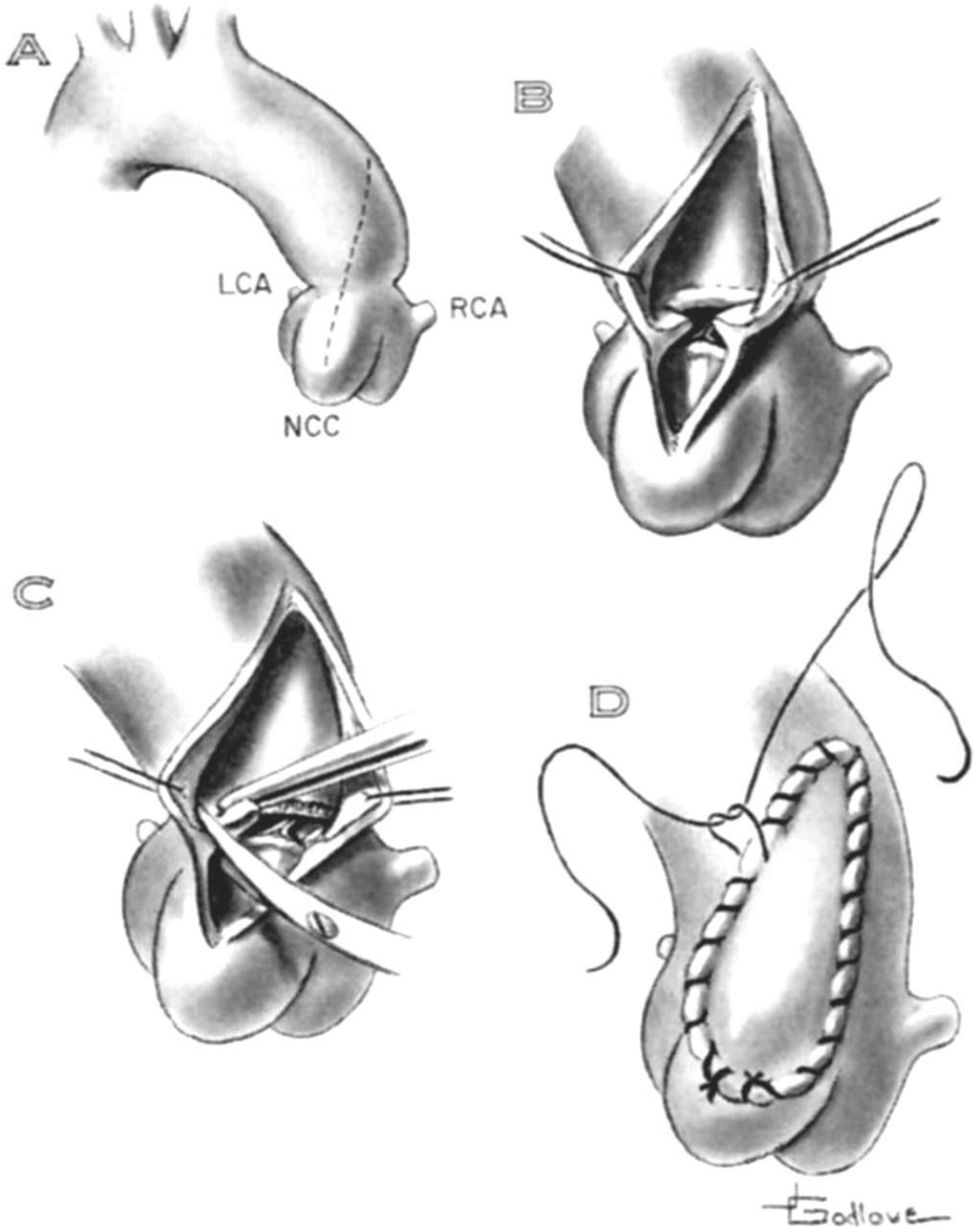
A
LCA
RCA
NCC
B
C
D
Godlove

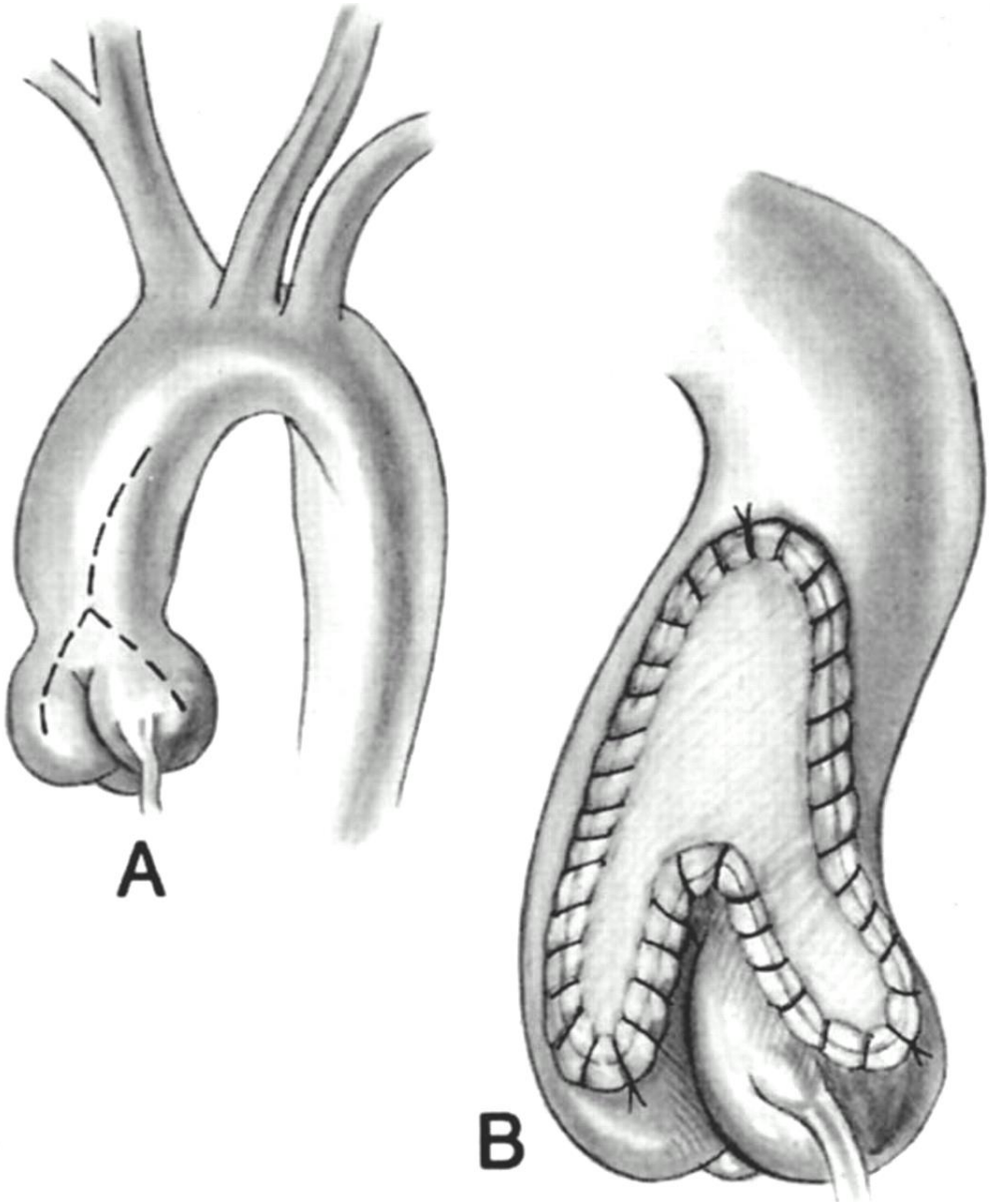
A
B

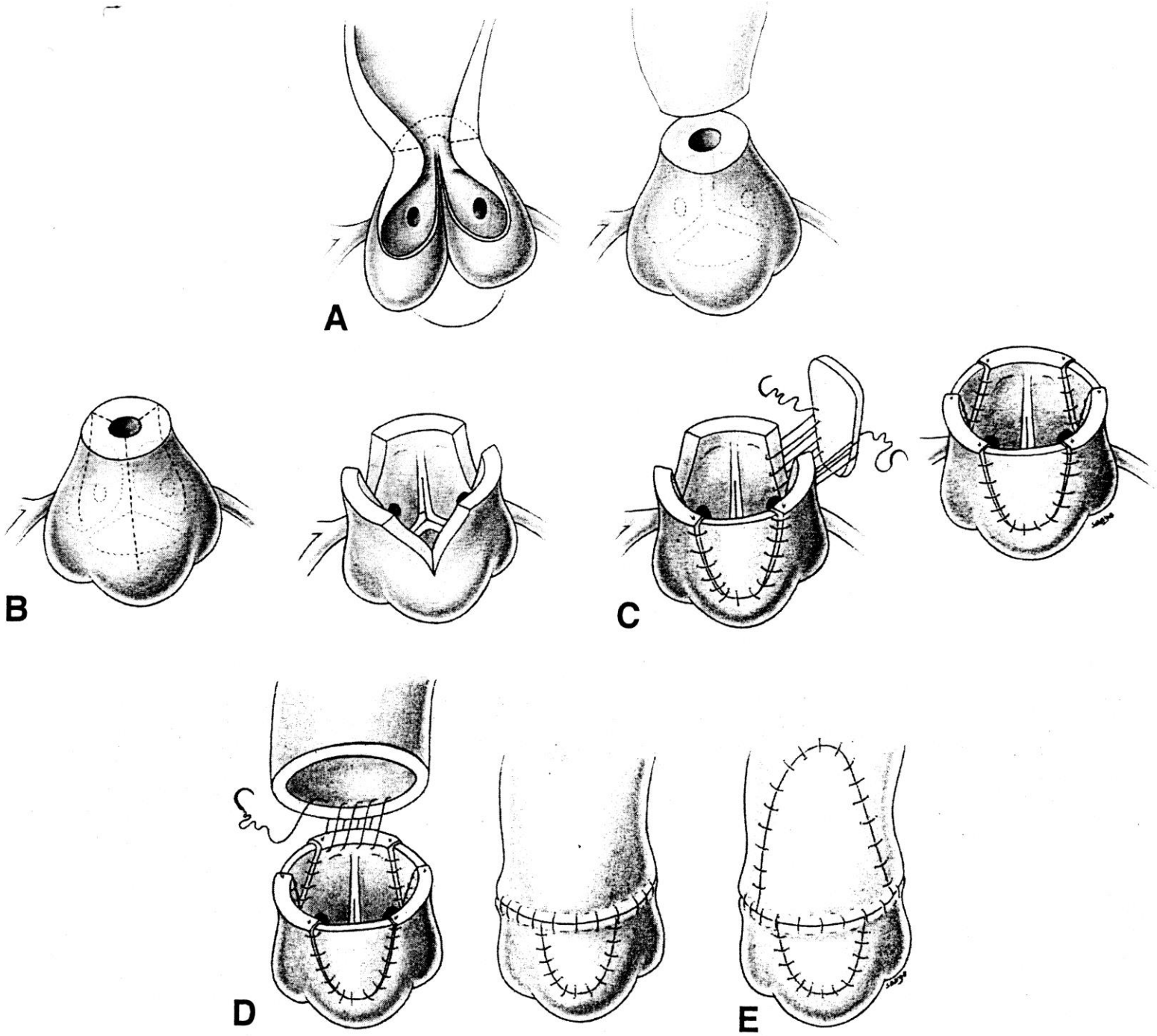
A
B
C
D
E

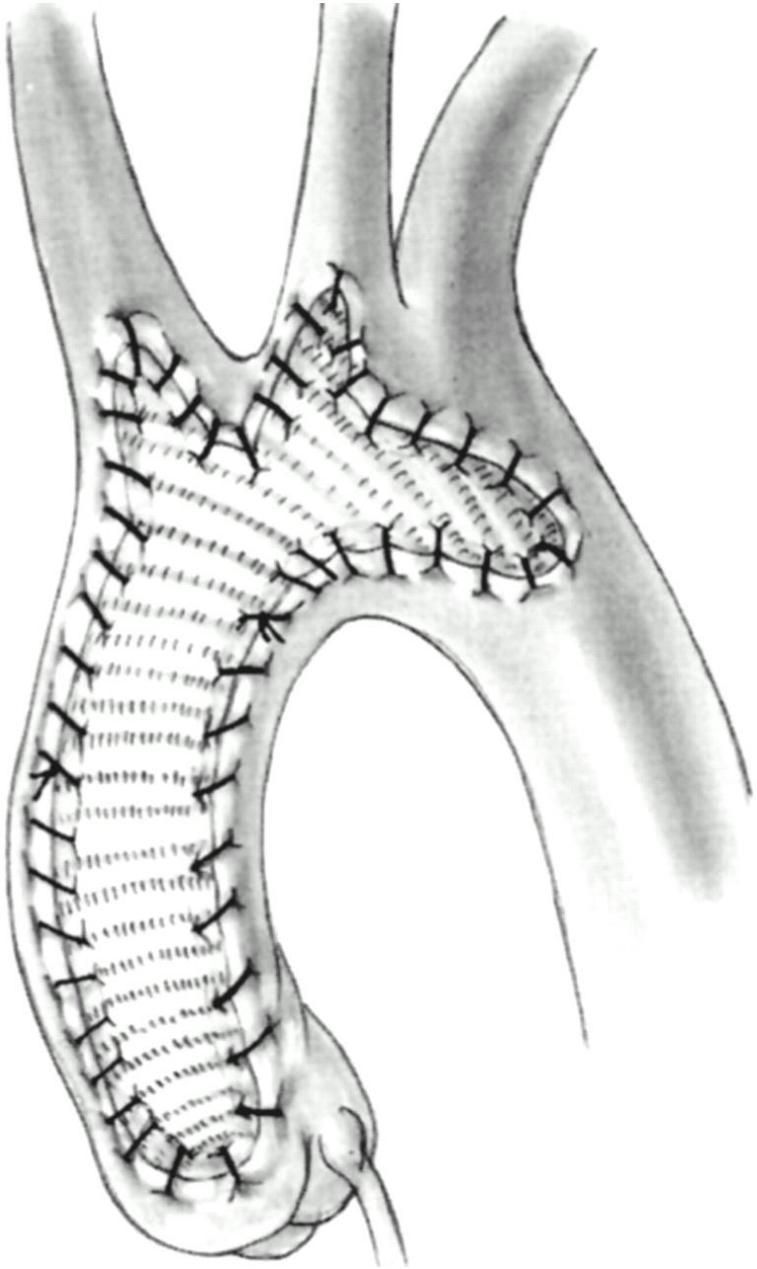

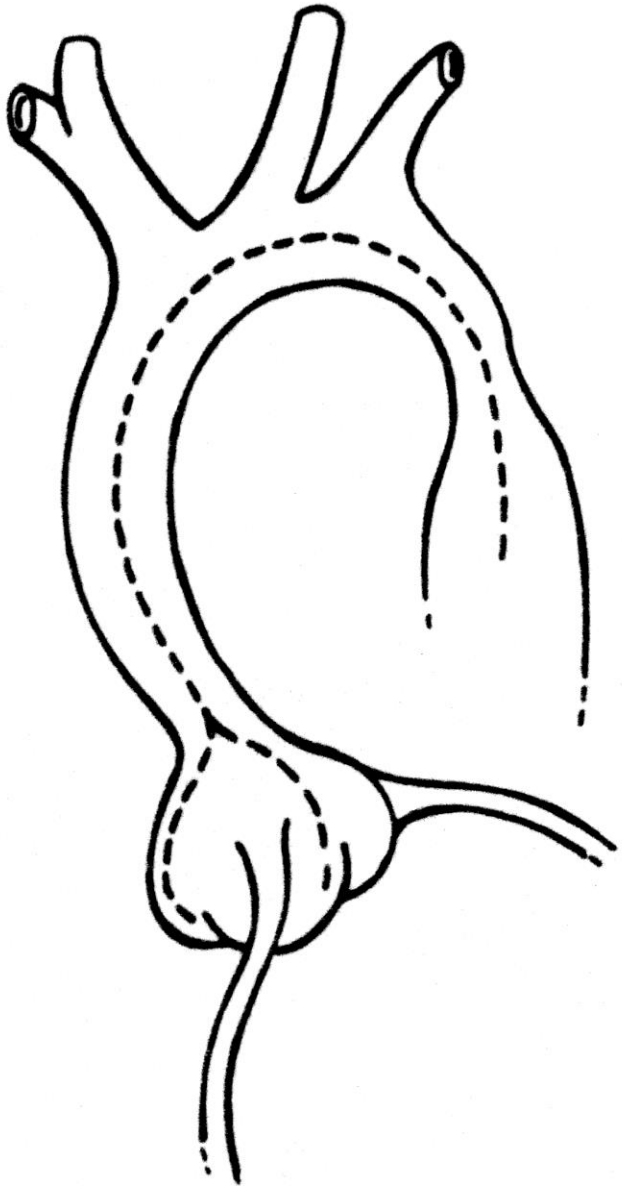



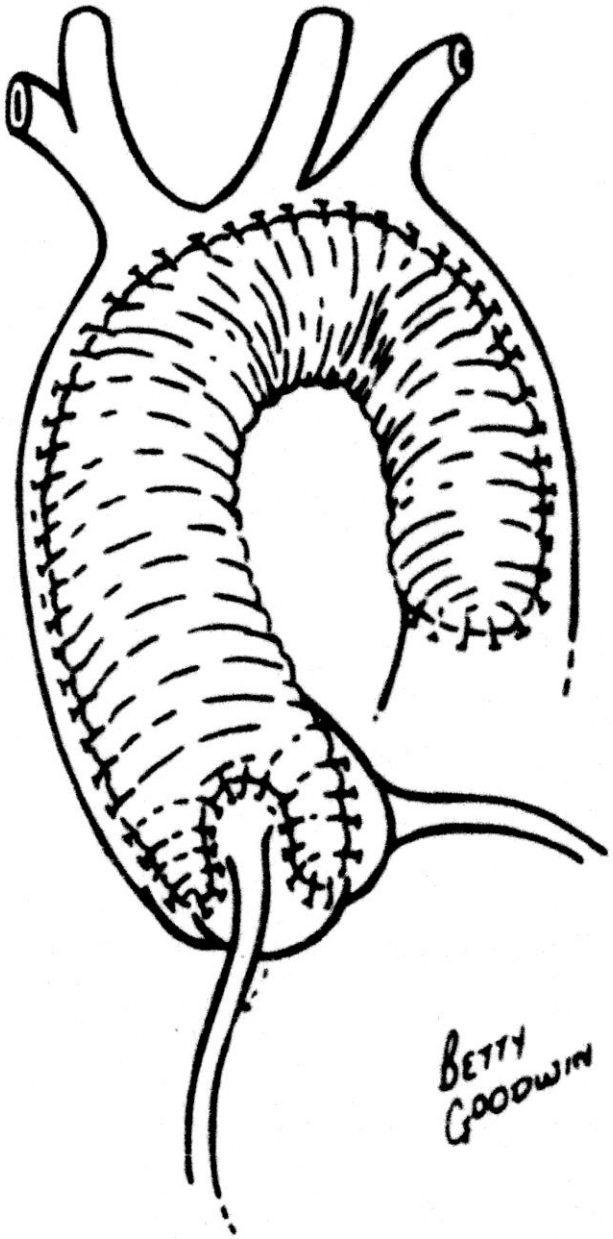
BETTY
GOODWIN



A

B

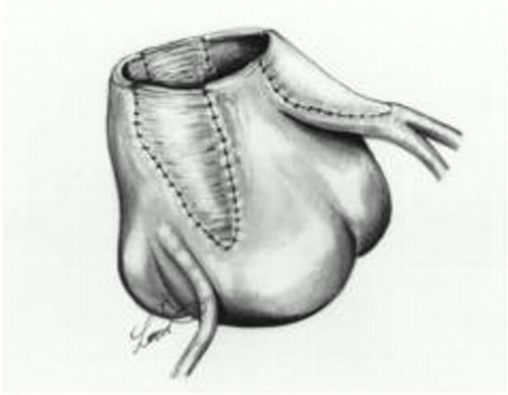

C

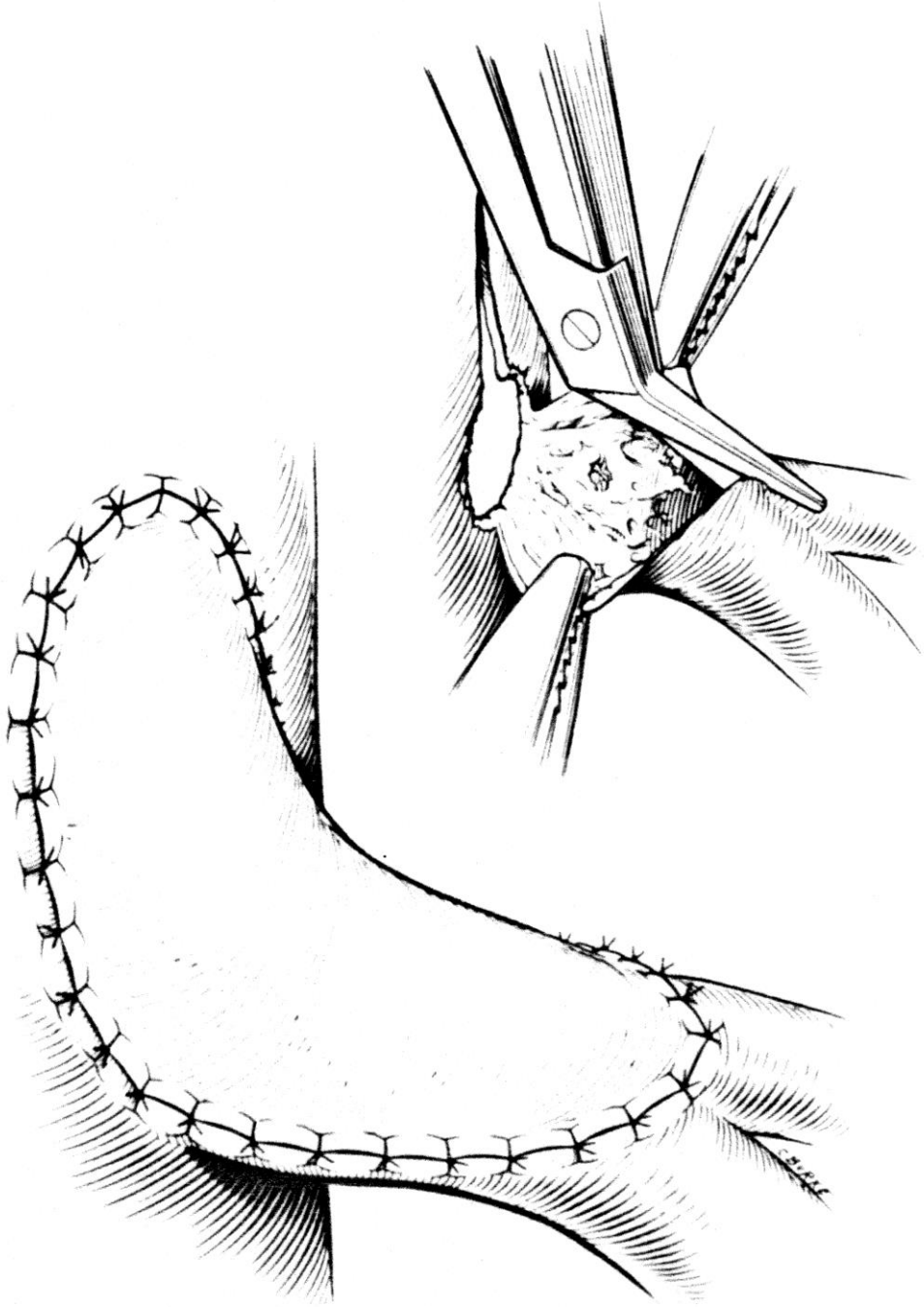

Type II



Cusp-Ridge
Fusion

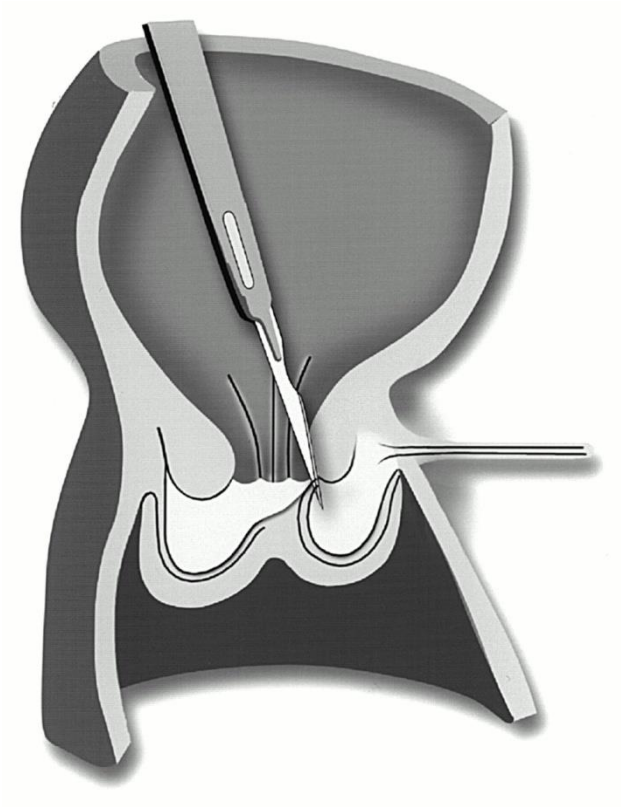

Type III

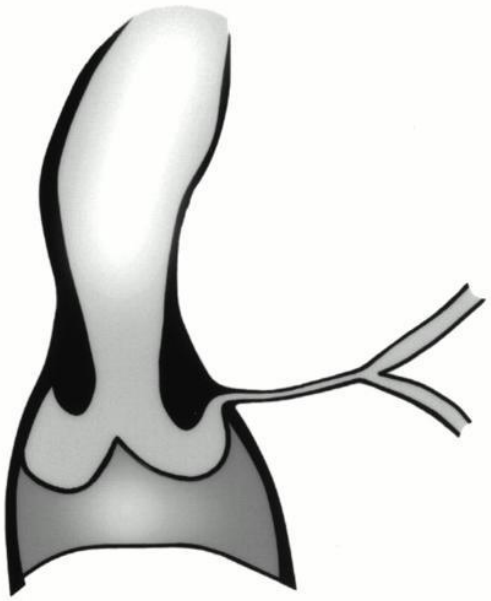

Fusiform
Narrowing