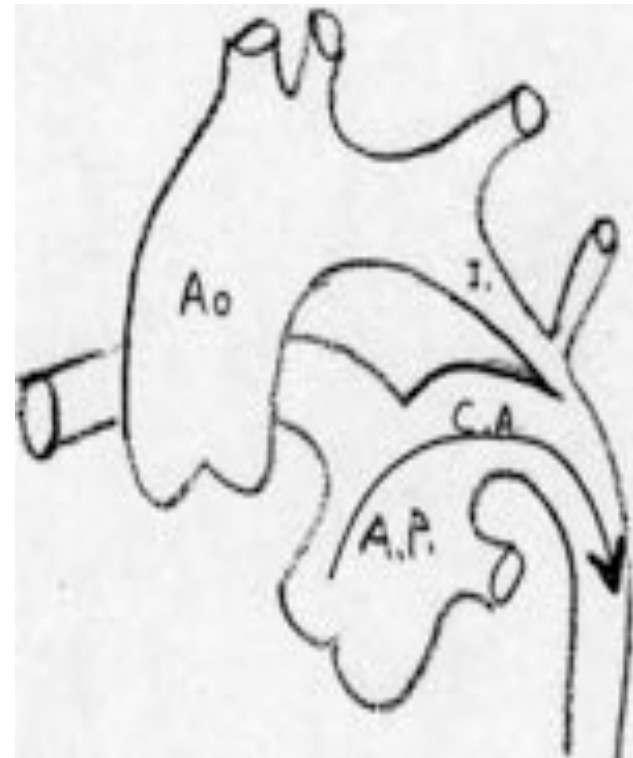


Coarctation et IAAo

- CARDIOPATHIES
DUCTODEPENDANTES
- obstacles à l'éjection du
coeur gauche (inter. de
l'arche aortique, coa., RA
serré)
- insuffisance cardiaque
sévère ou collapsus
- Prostate VR pour
hémodynamique



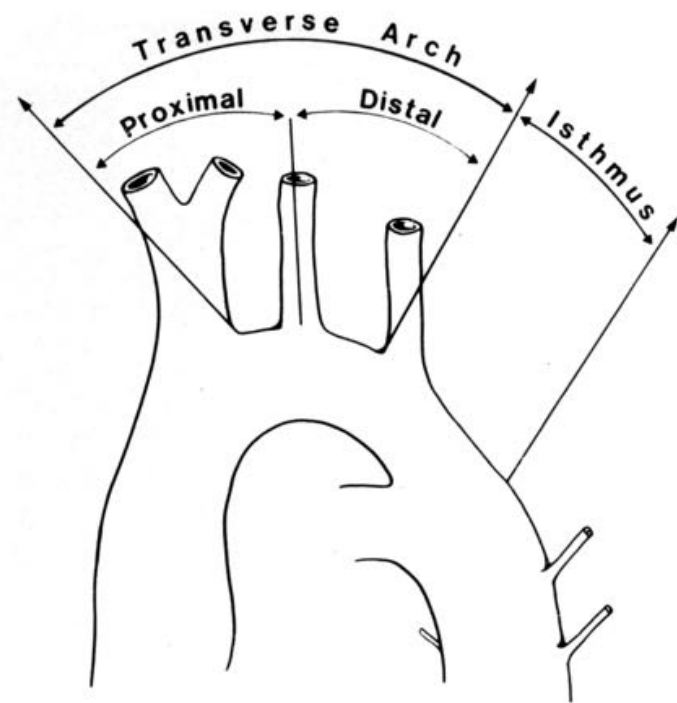
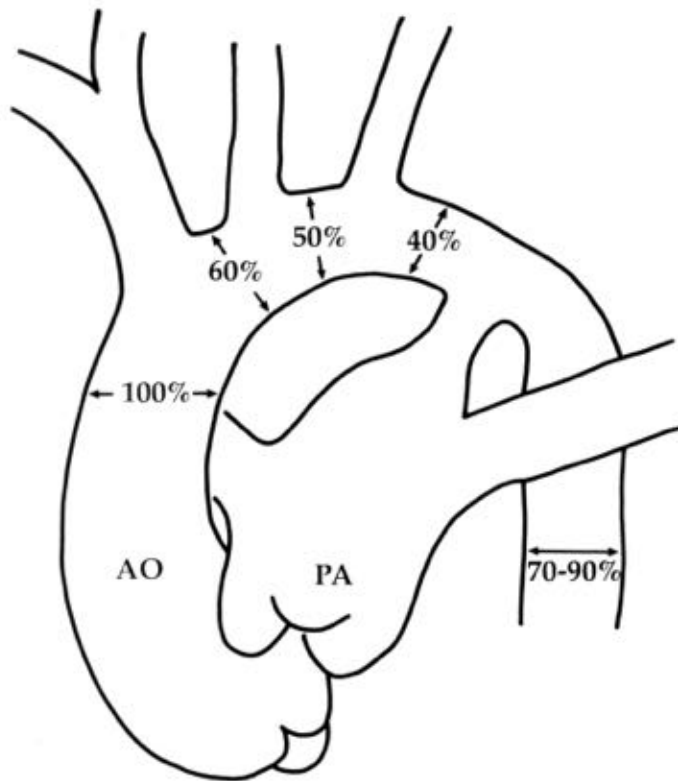


Coarctation

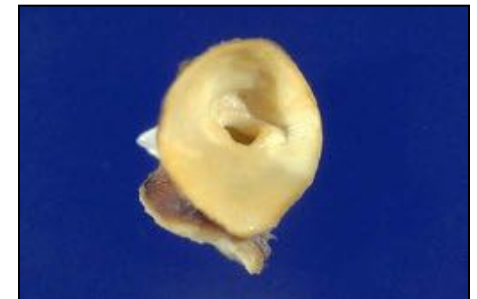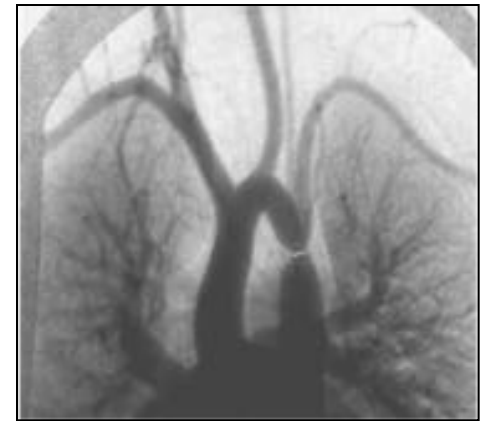
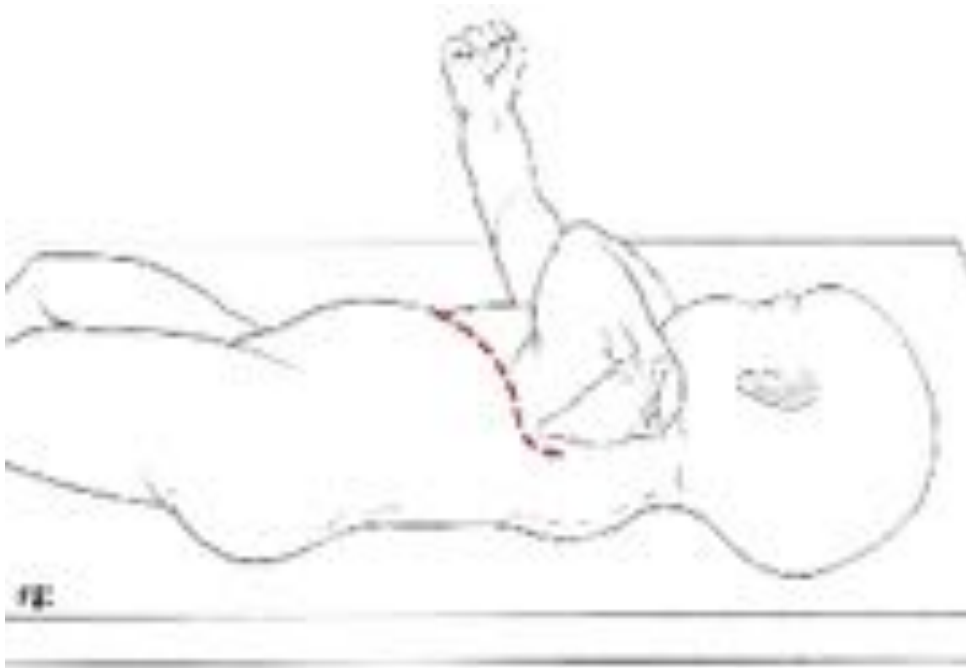
- **Forme du nouveau-né:**
 - **Isolée**
 - Hypoplasie de l' arche ?
 - **Associée**
 - Syndrome de coarctation
 - TGVx
 - Sd Shone
 - VU...
- **Forme du grand enfant...adulte**

Rappel(s) anatomique

Arche aortique = 3 segments

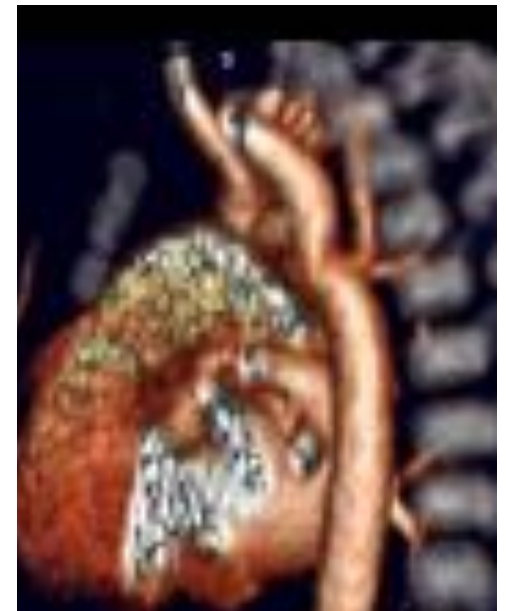
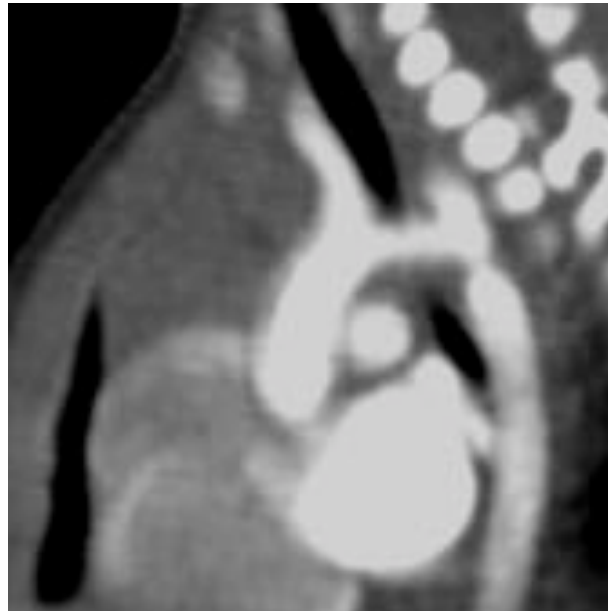
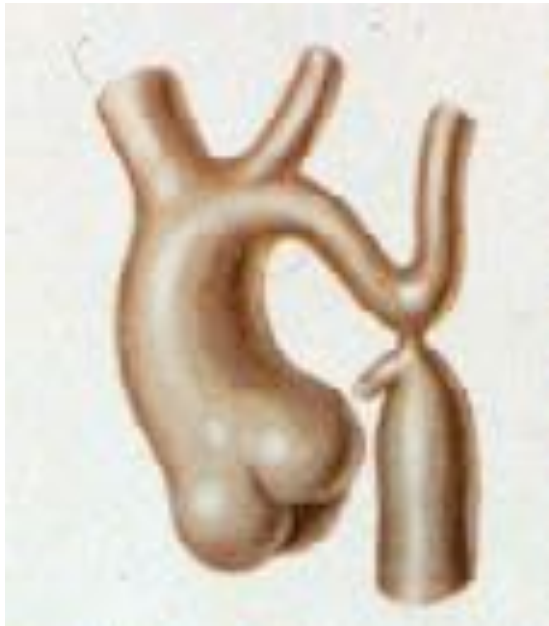Coarctation néo-natale

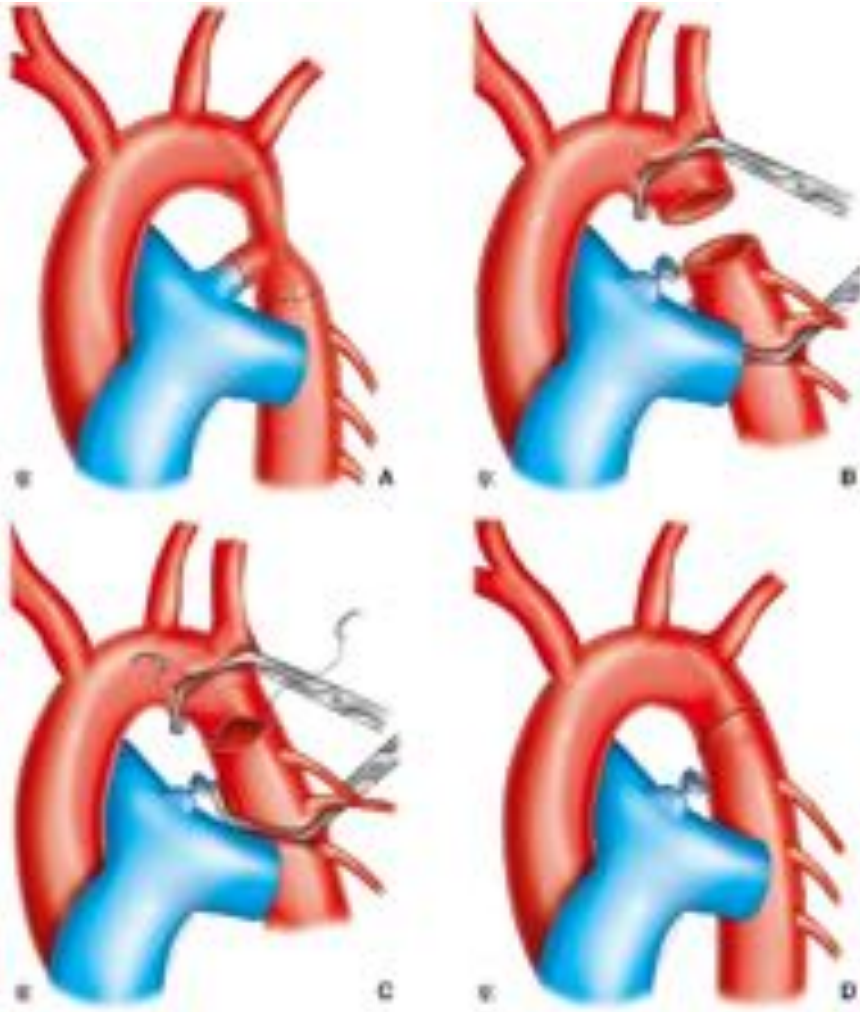


Coarctation néo-natale

- Coarctation +/- hypoplasie sus-jacente ?
- Pression radiale droite (anomalie arc aortique ?)
- NIRS



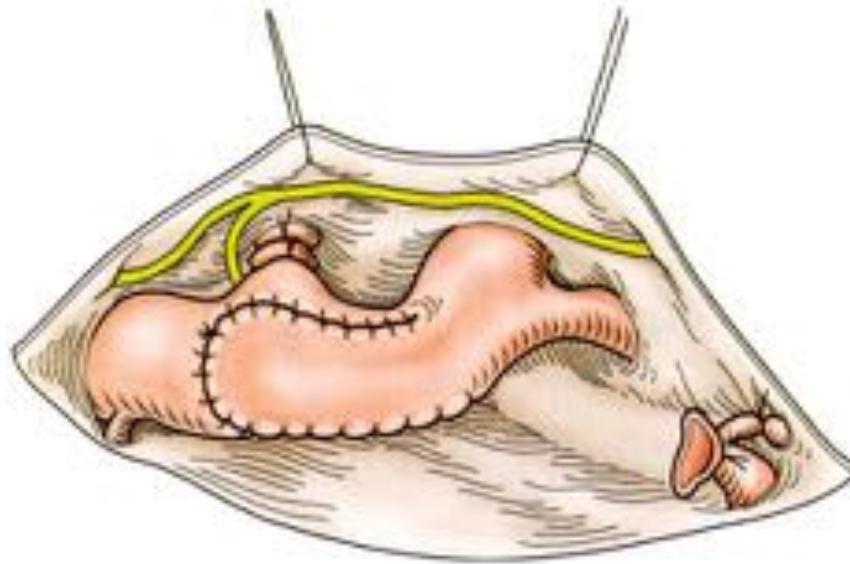
Coarctation Nné + crosse "normale"



- **Technique de Crafoord**

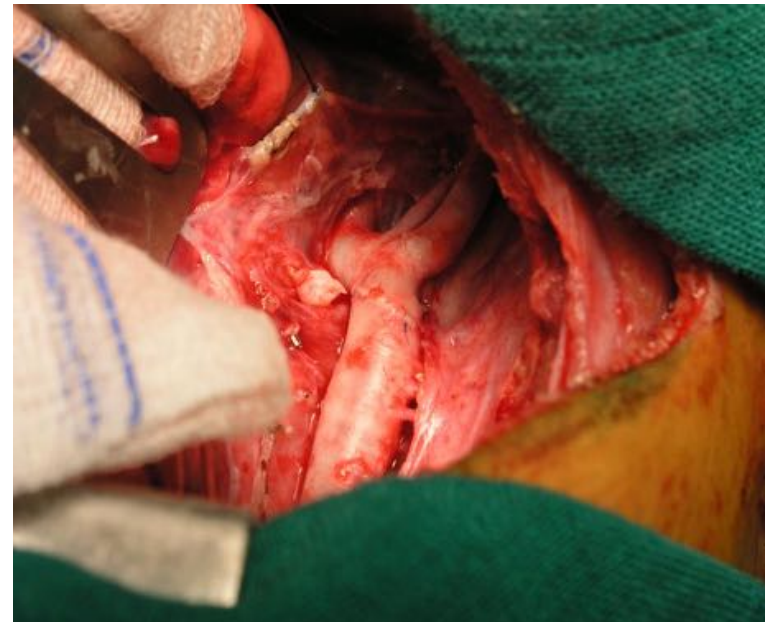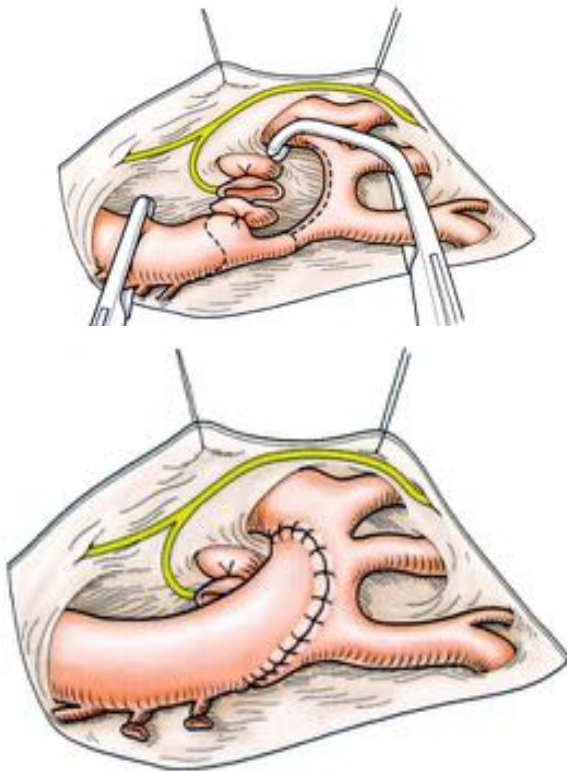
Coarctation Nné + crosse "normale"

- **Plastie d'élargissement avec SCG**



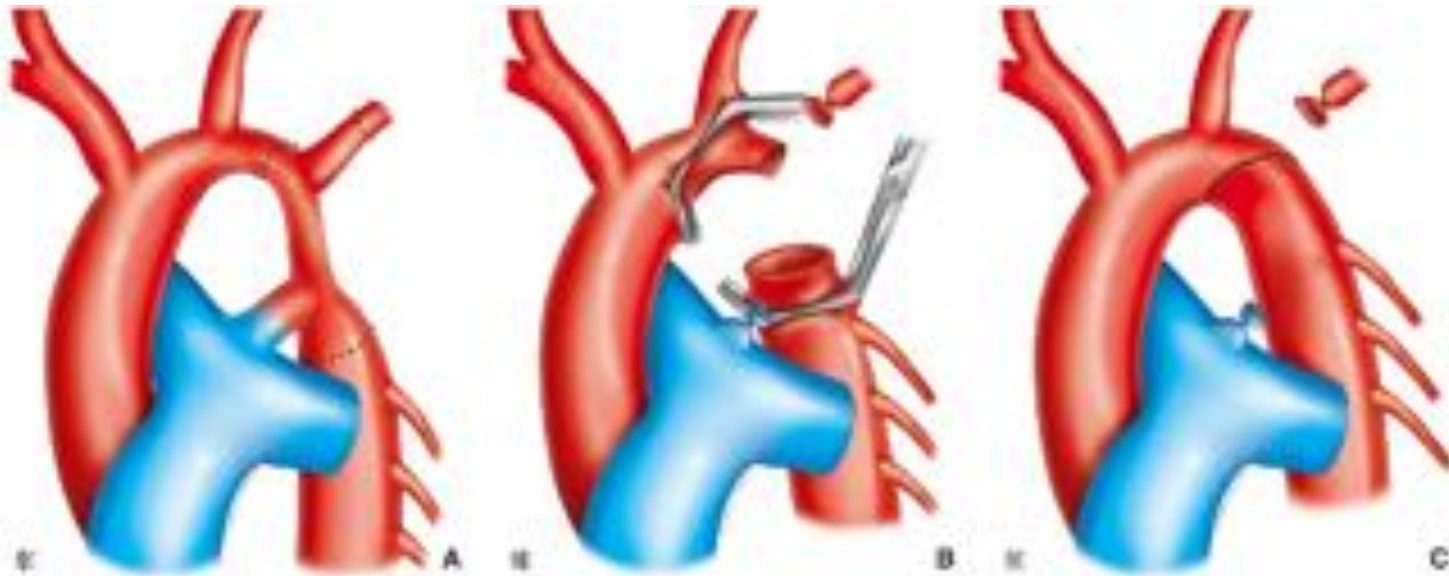
Coarctation Nné + hypoplasie segment II

- Résection anastomose étendue +/- sacrifice SCG



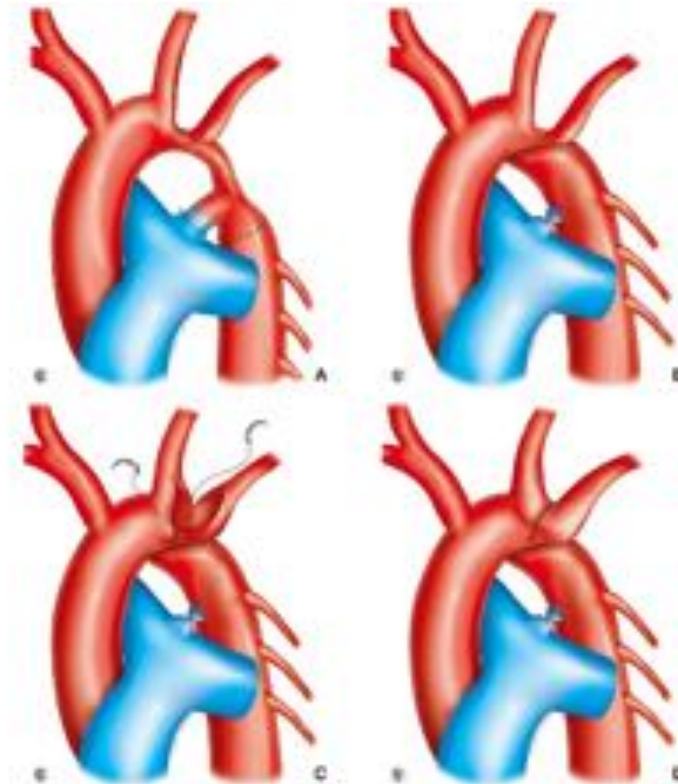
Coarctation Nné + hypoplasie segment II

- Résection anastomose étendue +/- sacrifice SCG

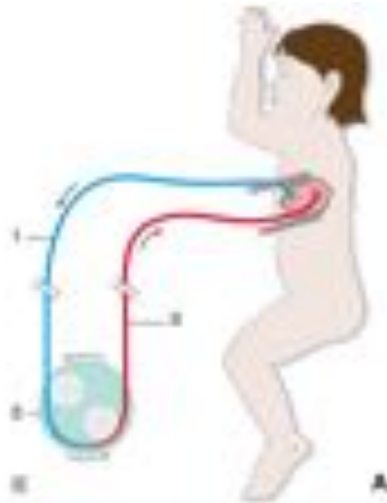


Coarctation Nné + hypoplasie segment II

- Amato

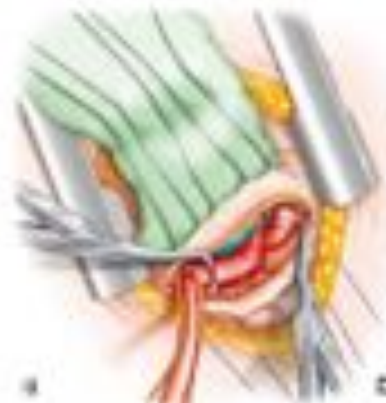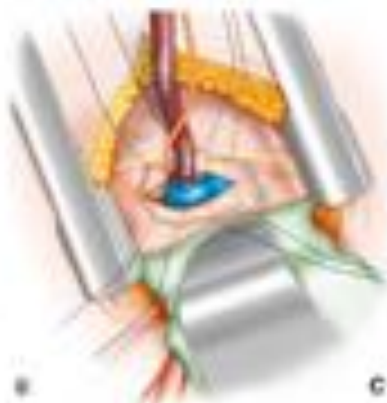

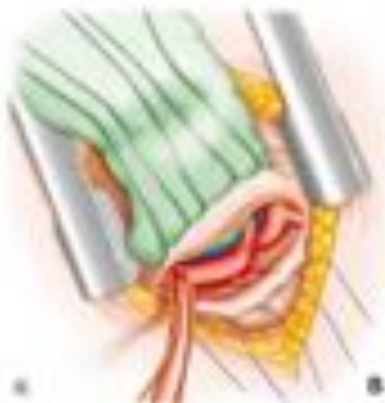
Coarctation grand enfant

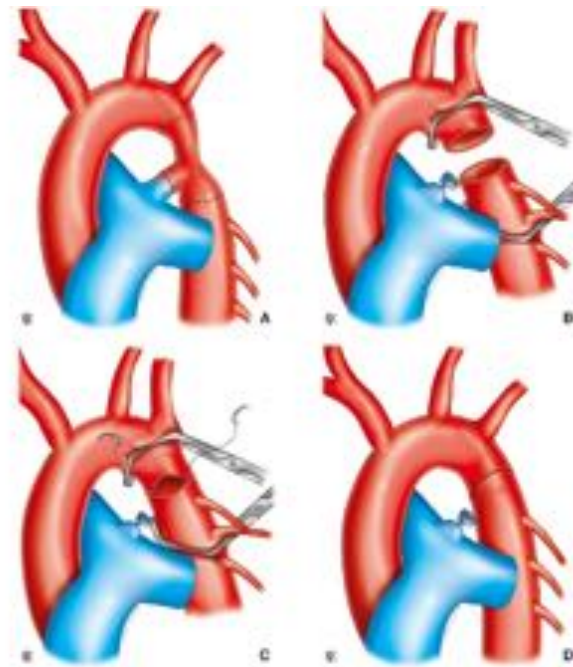
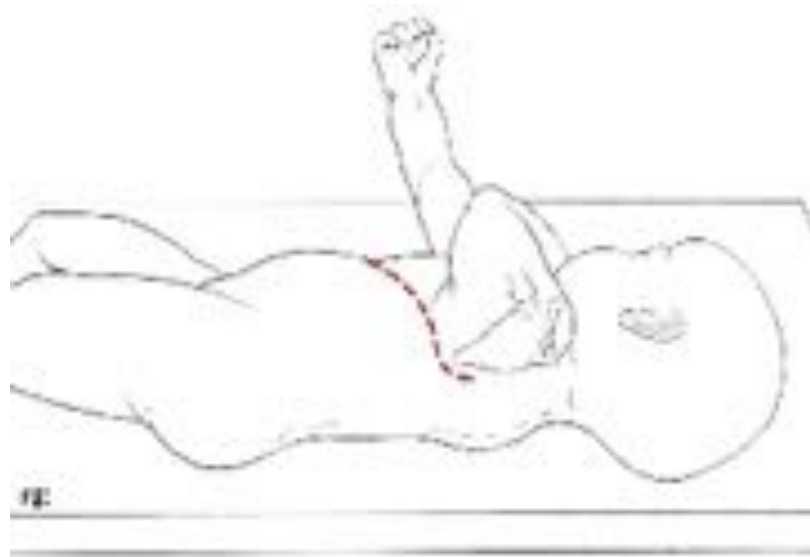


CEC ? :

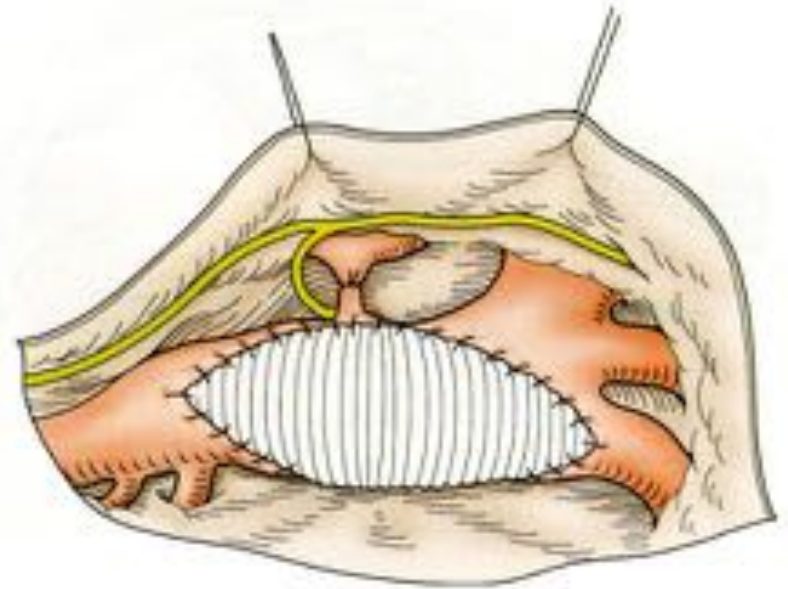
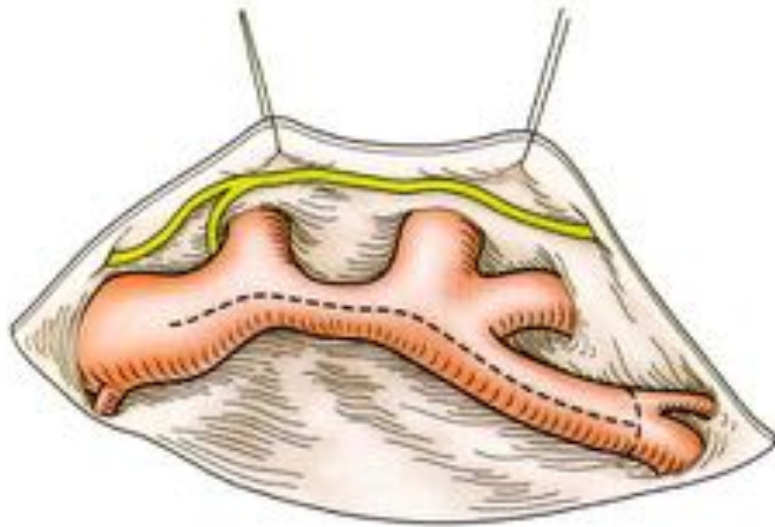
- **Importance des collatérales**
- **Pression aorte thoracique descendante**



Coarctation grand enfant

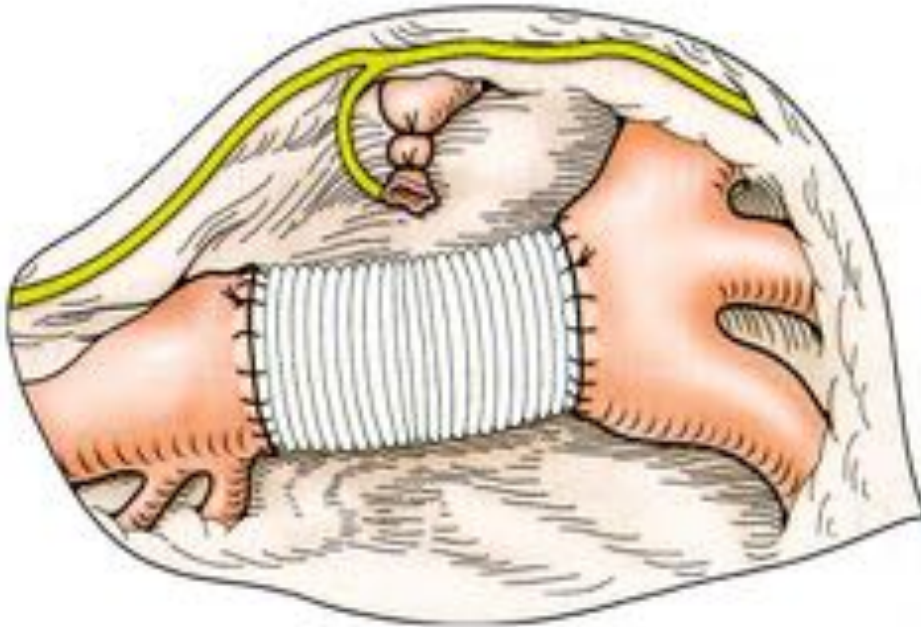


Coarctation +/- grand enfant +++ adulte





Coarctation +++ adulte

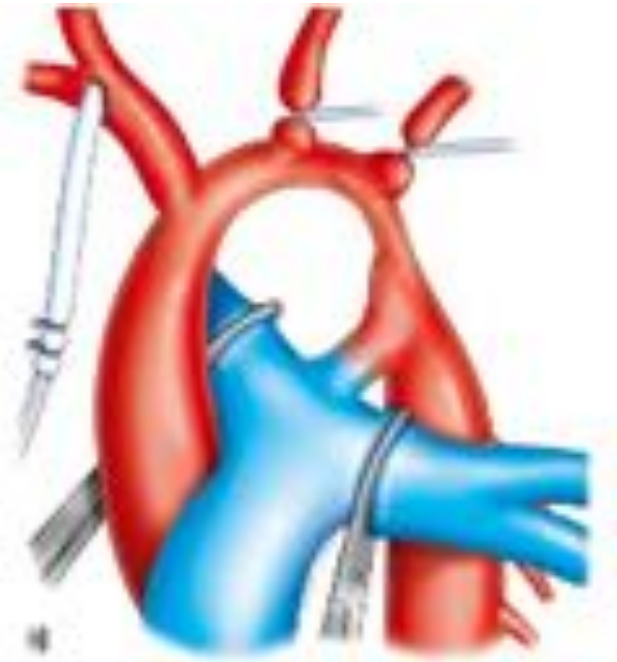

TTT endovasculaire +++

- **POIDS > 30 kg**
- **Expérience**

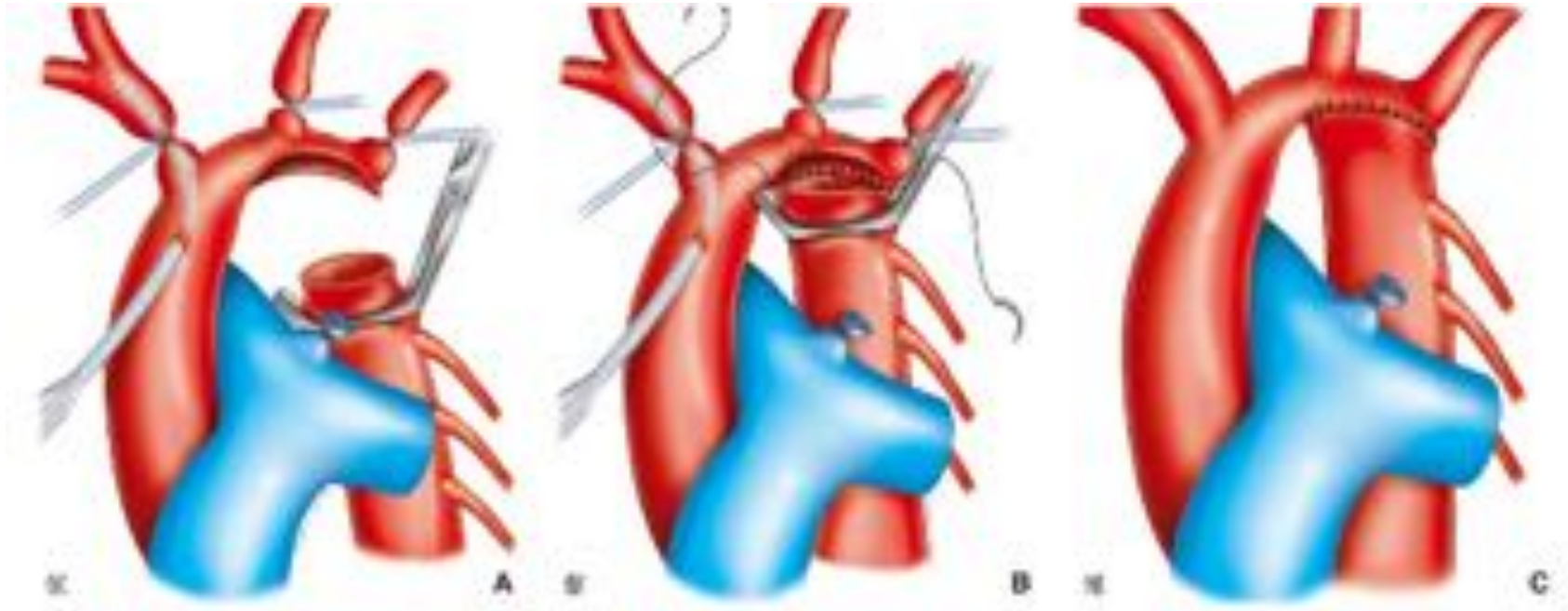
Coarctation Nné : Sternotomie + CEC

- Rares hypoplasie segment I
- Naissance commune TABC et CPG
- Lésions associées: syndrome de coarctation...
- Re-coarctation complexe



- Perfusion cérébrale
- Protection médullaire
- Hypothermie
- Protection myocardique

Coarctation Nné : Sternotomie + CEC



- +/- patch d'élargissement



Coarctation : complications précoces

- Saignement
- HTA paroxystique
- **Paraplégie (risque ++ ado/adulte)**
- Iléus réflexe
- Chylothorax
- Paralysie récurrentielle

Coarctation : complication tardive

- **Re-coarctation ++++ : traitement endo-vasculaire**

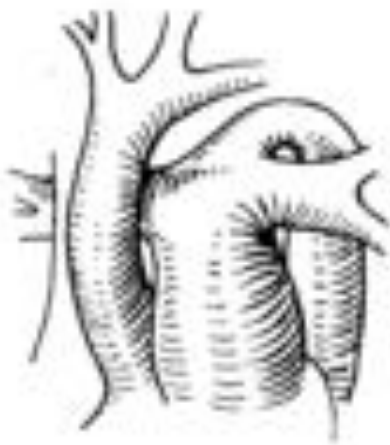Interruption de l'arche

Types A B C

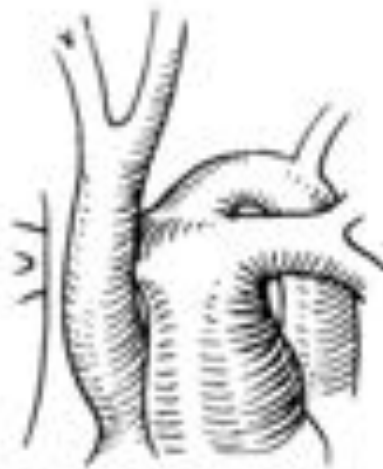Lésions associées fréquentes:

CIV +++ (fermeture par OD +++)

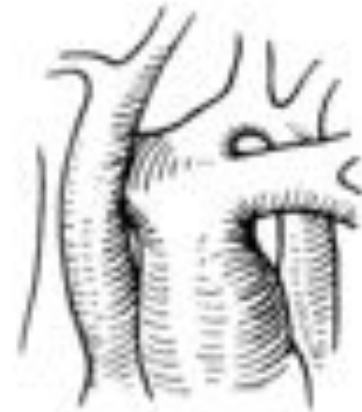FAP, TGVx (malpositions), truncus arteriosus



a



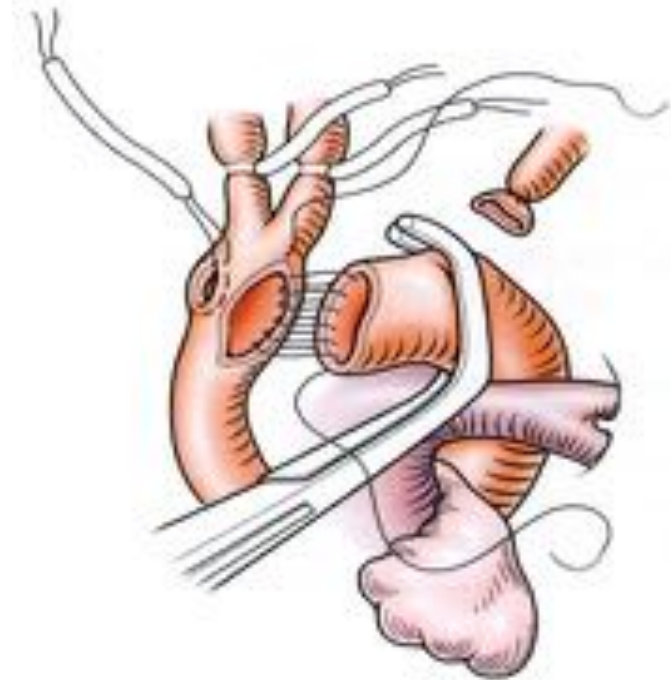
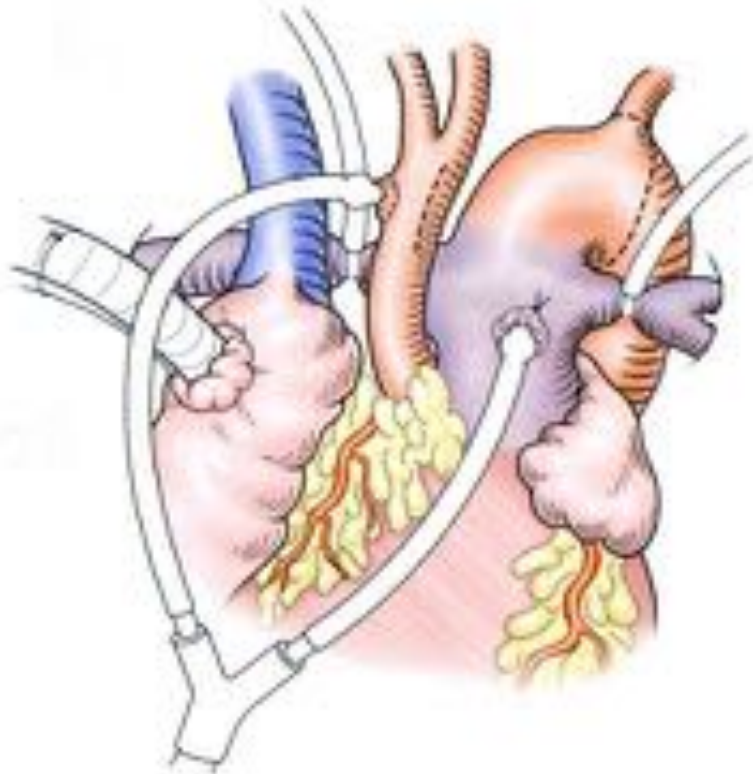
b



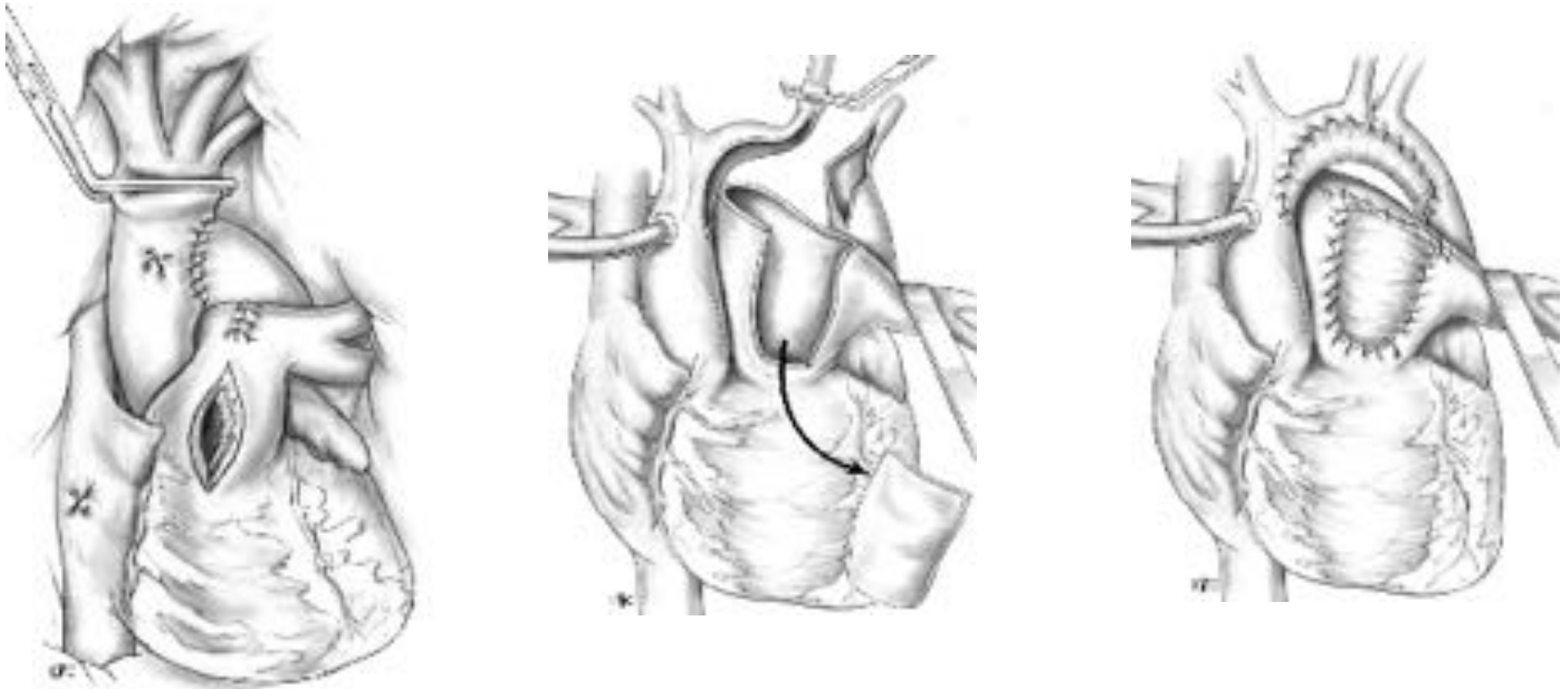
c

Interruption de l'arche

- **CEC systématique sauf cas exceptionnel...**



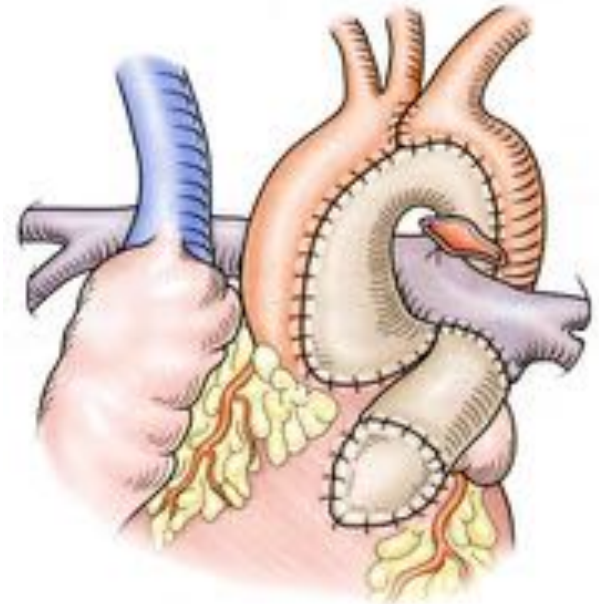
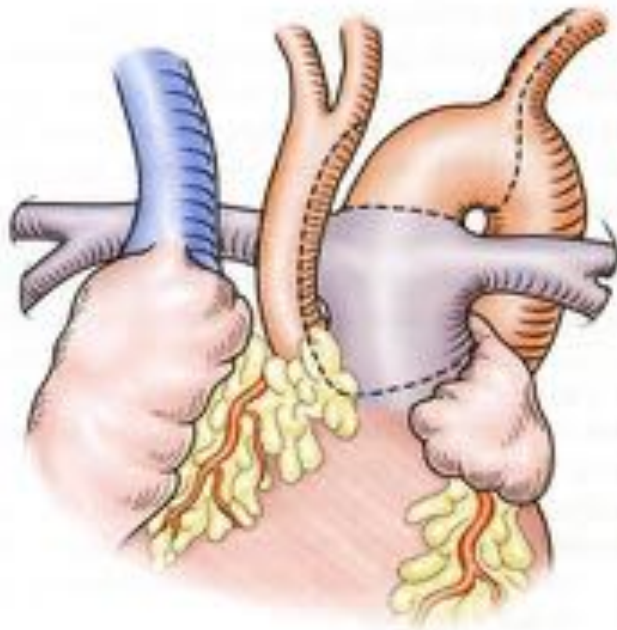
Interruption de l'arche



- Utilisation fréquente de patch d'élargissement divers...

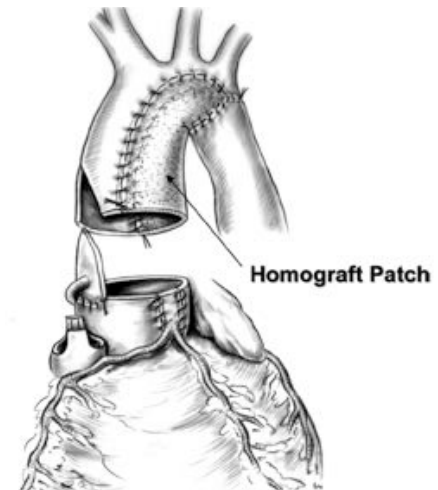
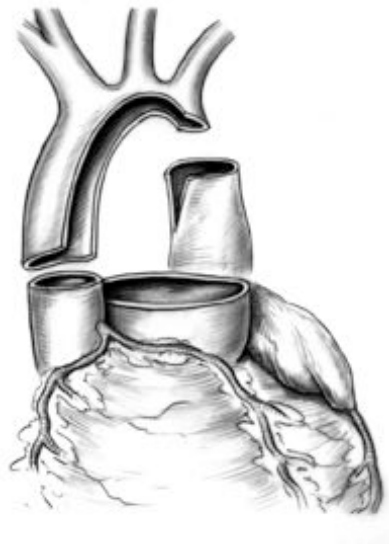
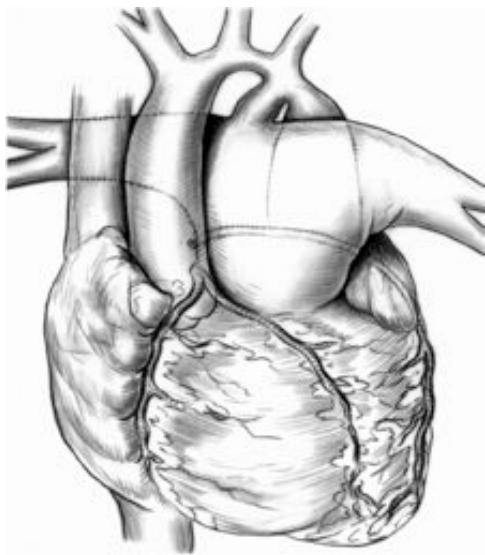


Interruption de l'arche



Forme complexe : Truncus arteriosus

Interruption de l'arche



Forme complexe : TGVx (malpositions...)



IAAo : complications précoces

- Saignement
- HTA paroxystique
- Paraplégie
- Iléus réflexe
- Chylothorax
- Paralysie récurrentielle
- **Compression bronchique gauche**
- **Bloc auriculo-ventriculaire**

IAAO : complication tardive

- **Re-coarctation ++++ : traitement endo-vasculaire**
- **Obstacle sous aortique**