# Communication

# Inter

# Ventriculaire

# CIV

**Anatomie**
**Traitement chirurgical**
**Formes associées**
**Les problèmes techniques**

# ANATOMIE DU SEPTUM INTERVENTRICULAIRE

- Septum conal
  = infundibulaire
  = outlet septum
- Septum d ’admission = inlet septum
- Septum trabéculé
- Septum membraneux

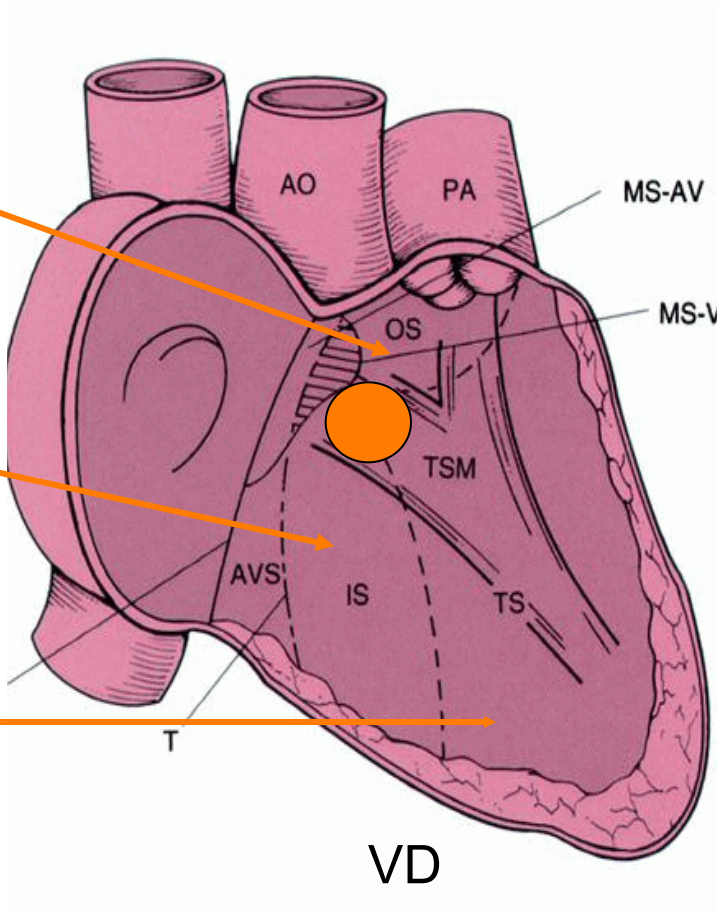

# Anatomie chirurgicale

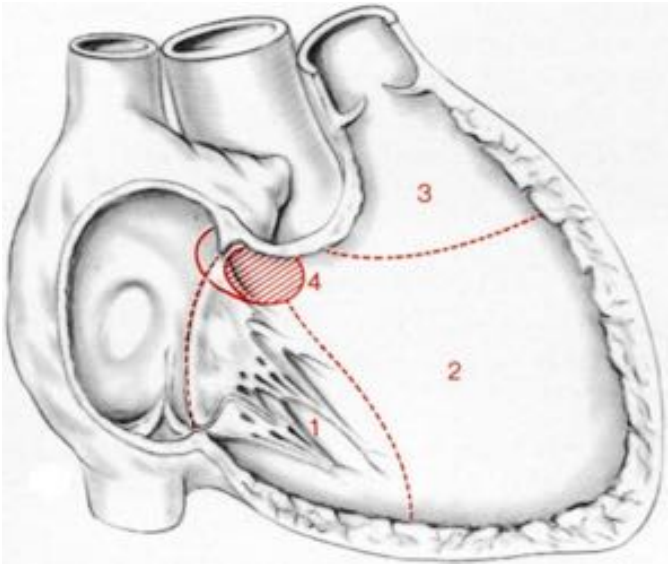


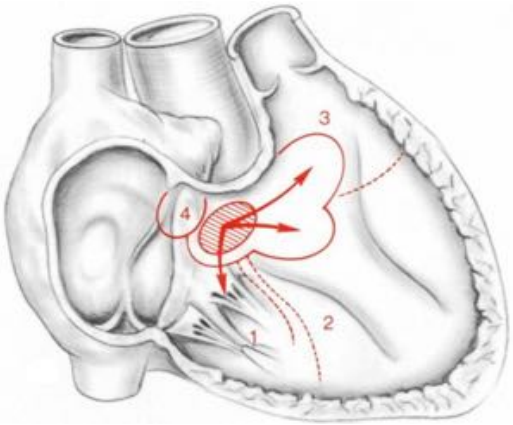


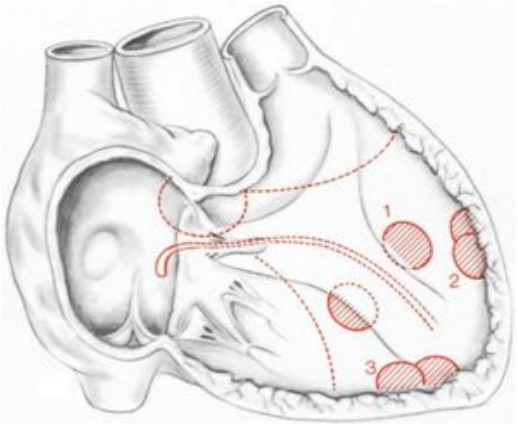


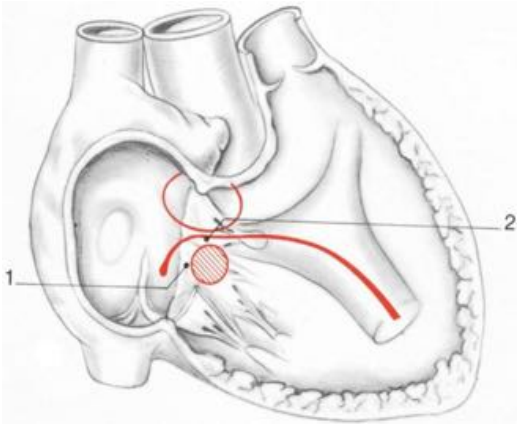


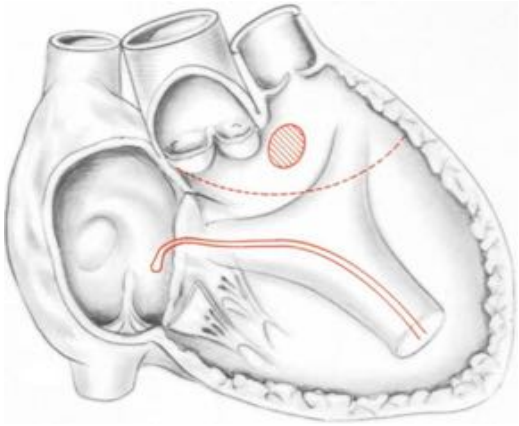

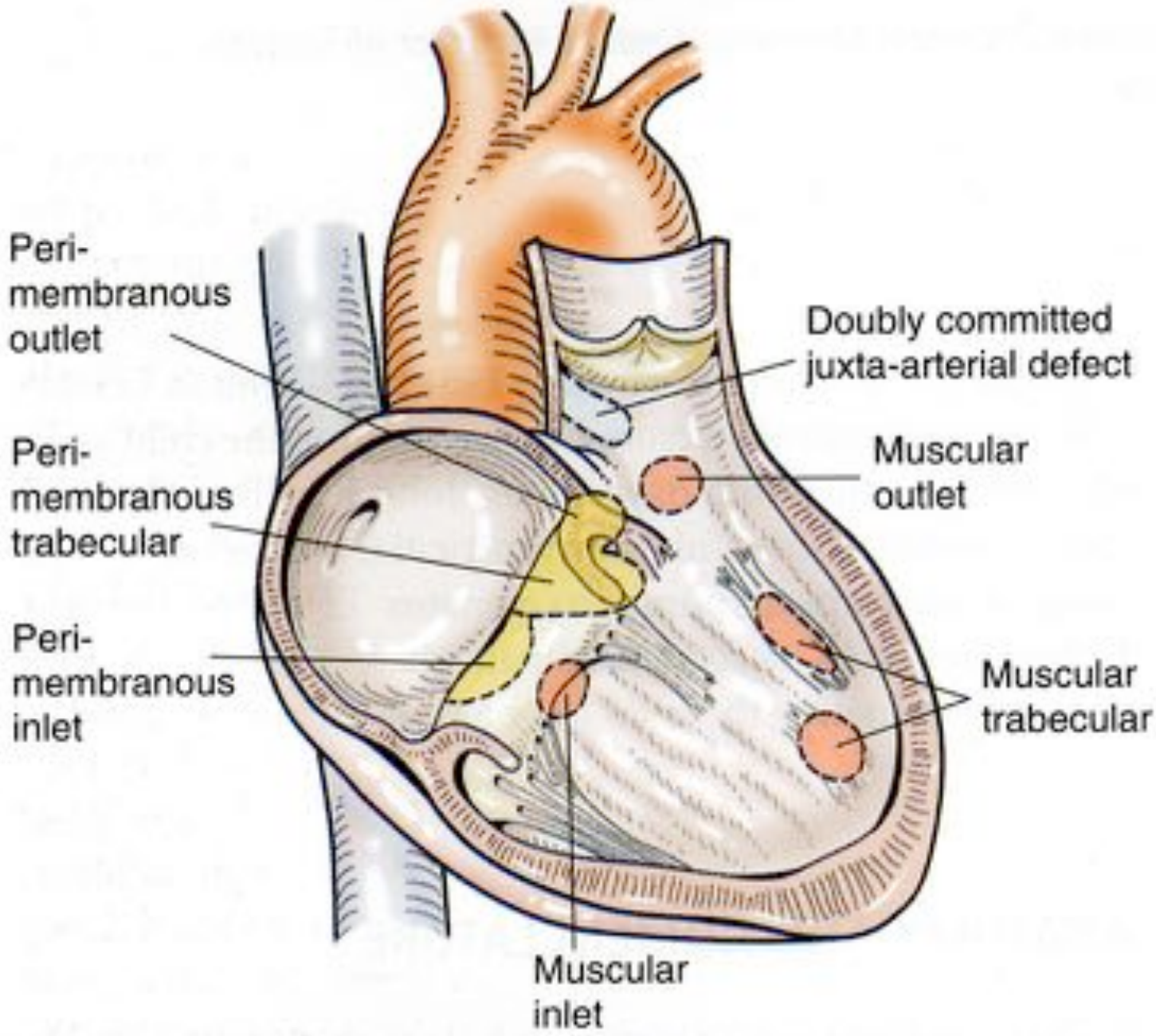
Peri-
membranous
outlet
Peri-
membranous
trabecular
Peri-
membranous
inlet
Doubly committed
juxta-arterial defect
Muscular
outlet
Muscular
trabecular
Muscular
inlet

# VENTRICULE DROIT

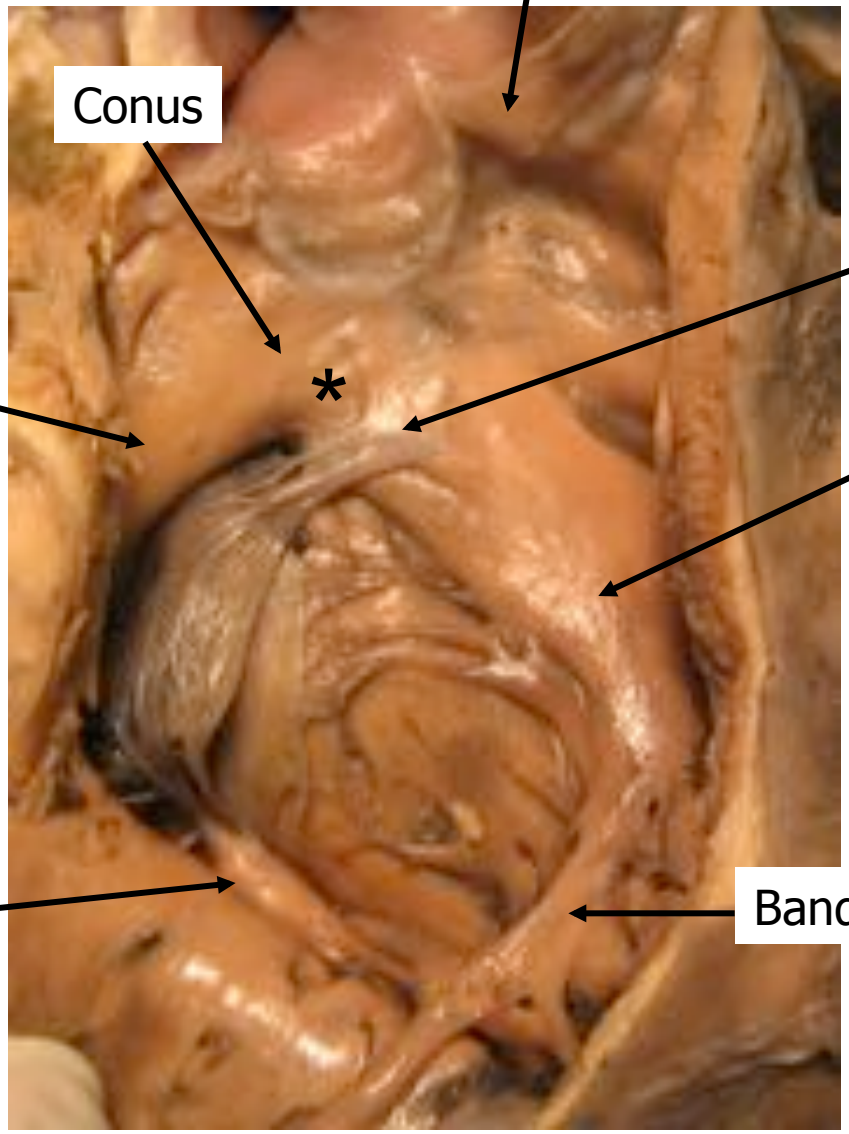

# Ventricule gauche

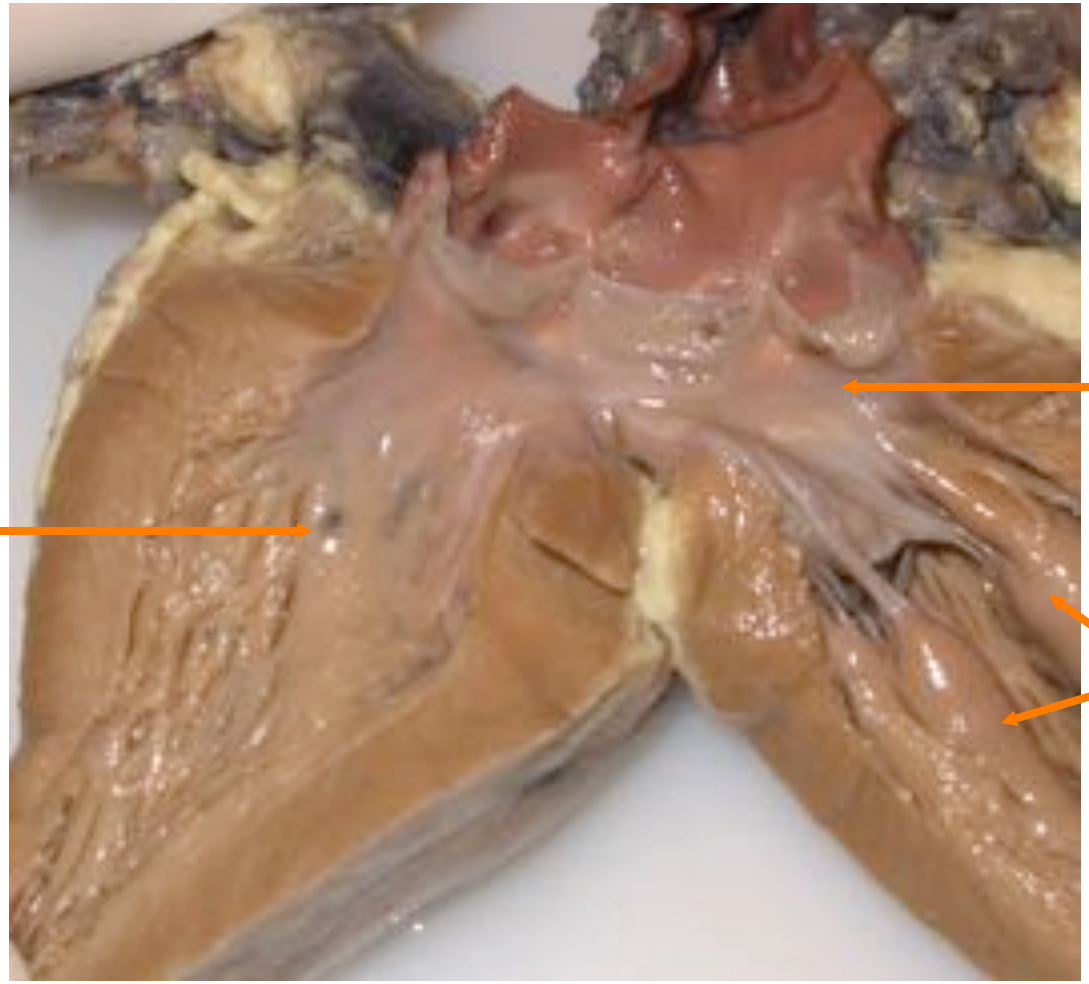

# Septum membraneux

- ultime zone de fusion entre les différents composants

Muscle papillaire du conus

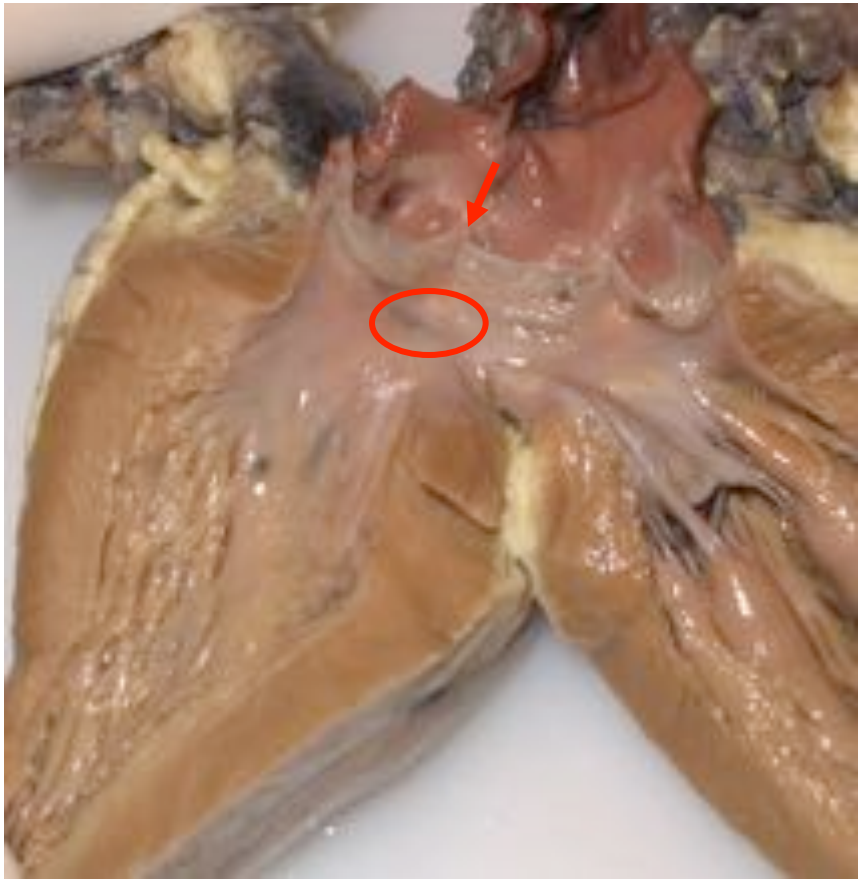

Commissure cusp CD - cusp non coro

# CIV d'admission (inlet)

- bourgeons endocardiques auriculoventriculaires

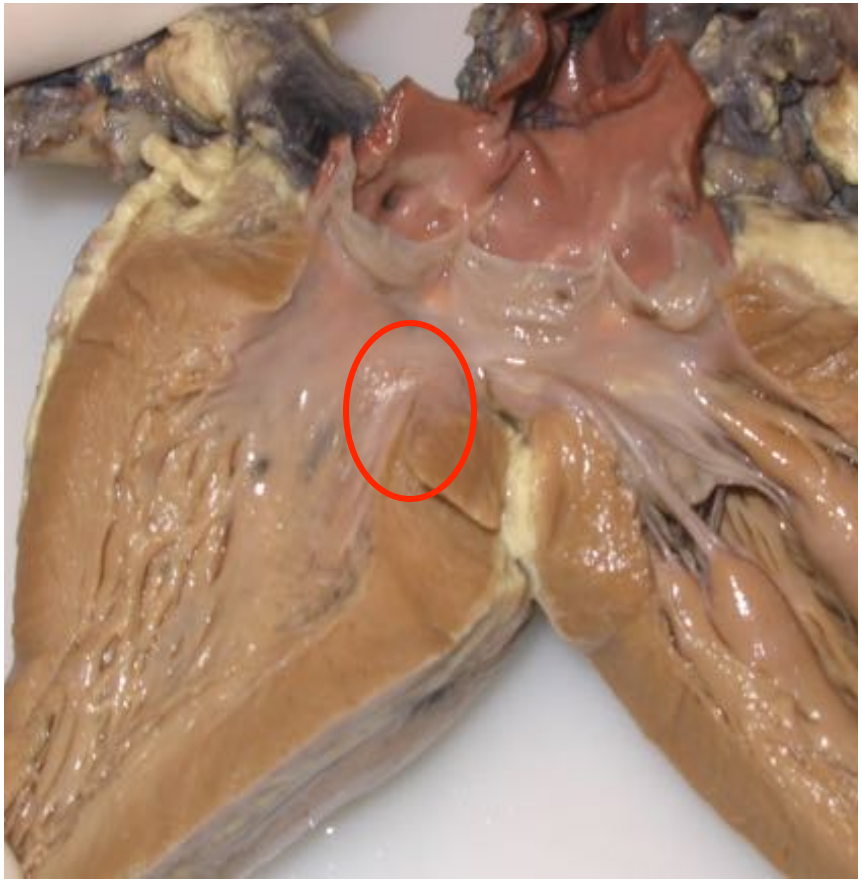

Canal atrioventriculaire

# CIV conoventriculaire =infundibulaire=conales=juxtaartérielles

- bourgeons endocardiques du conus

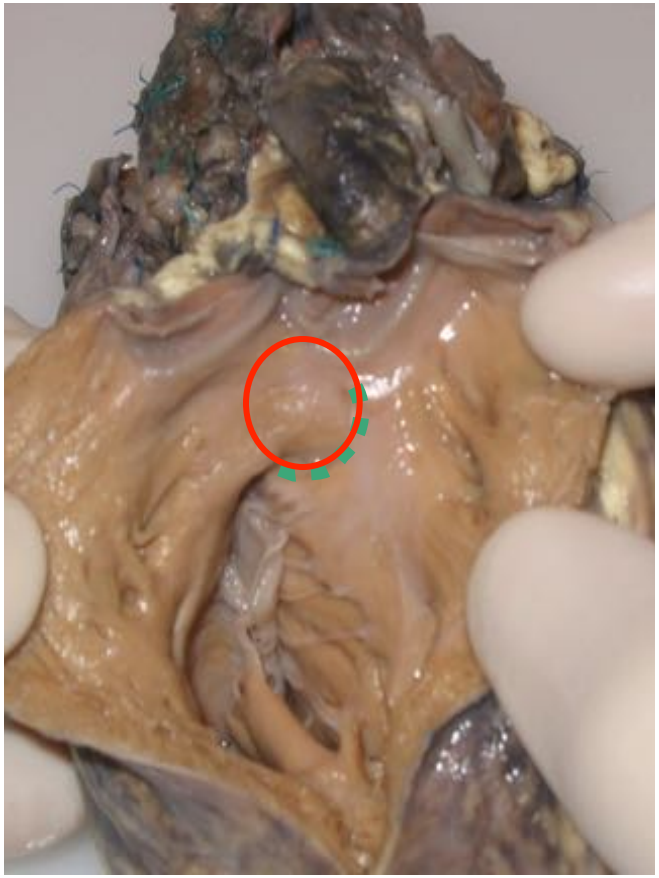

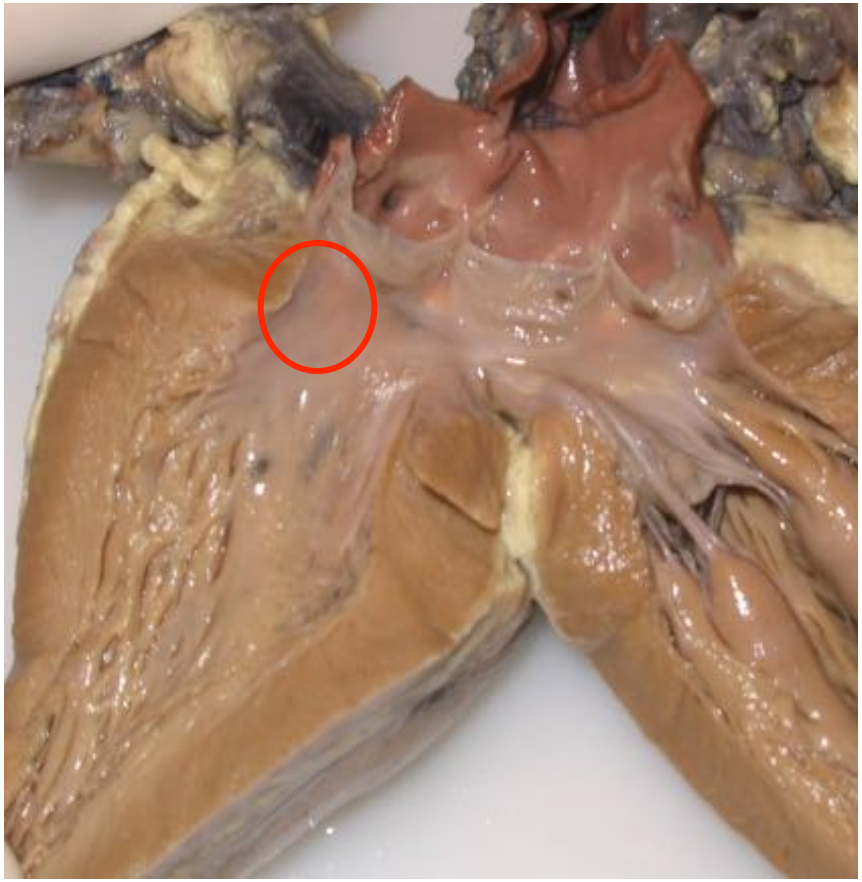

+/- mal alignement du septum conal

# CIV musculaires

- septum interventriculaire primitif

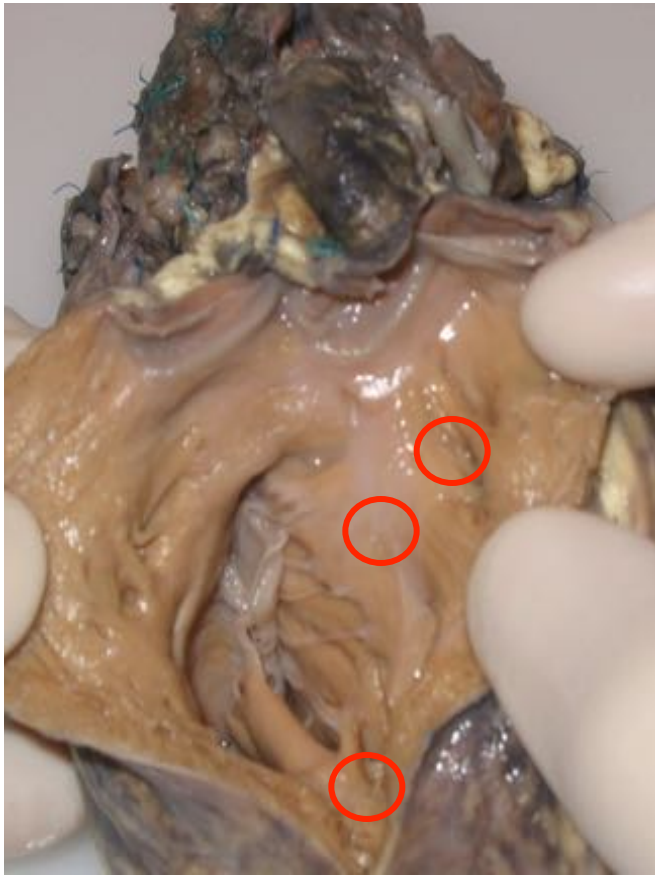

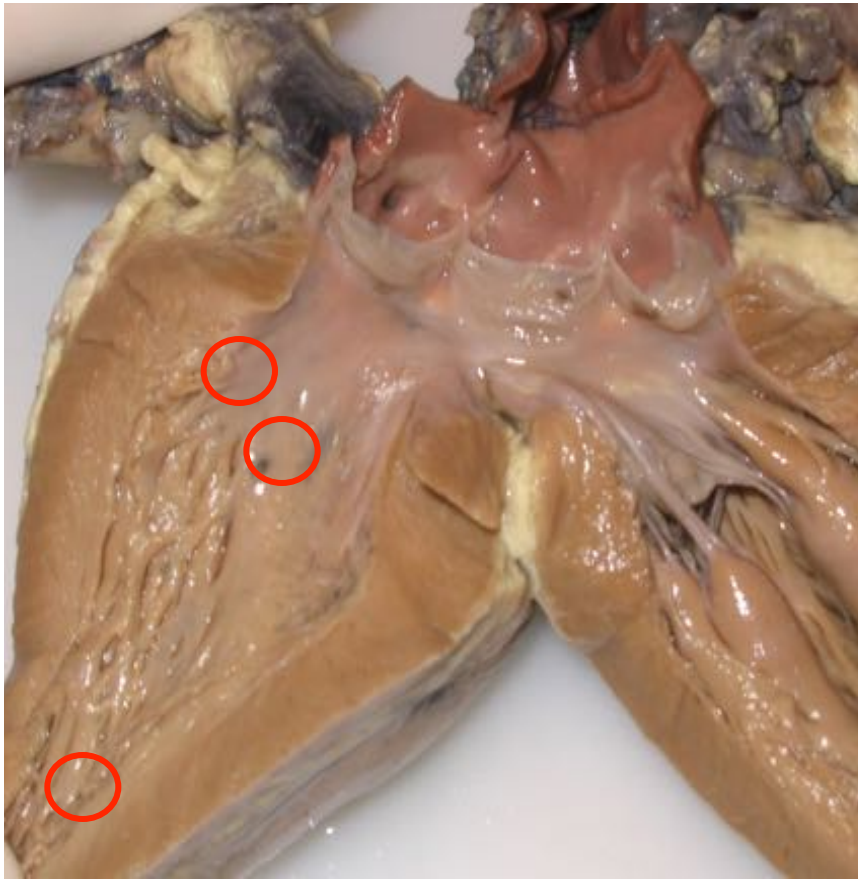

# CIV multiples

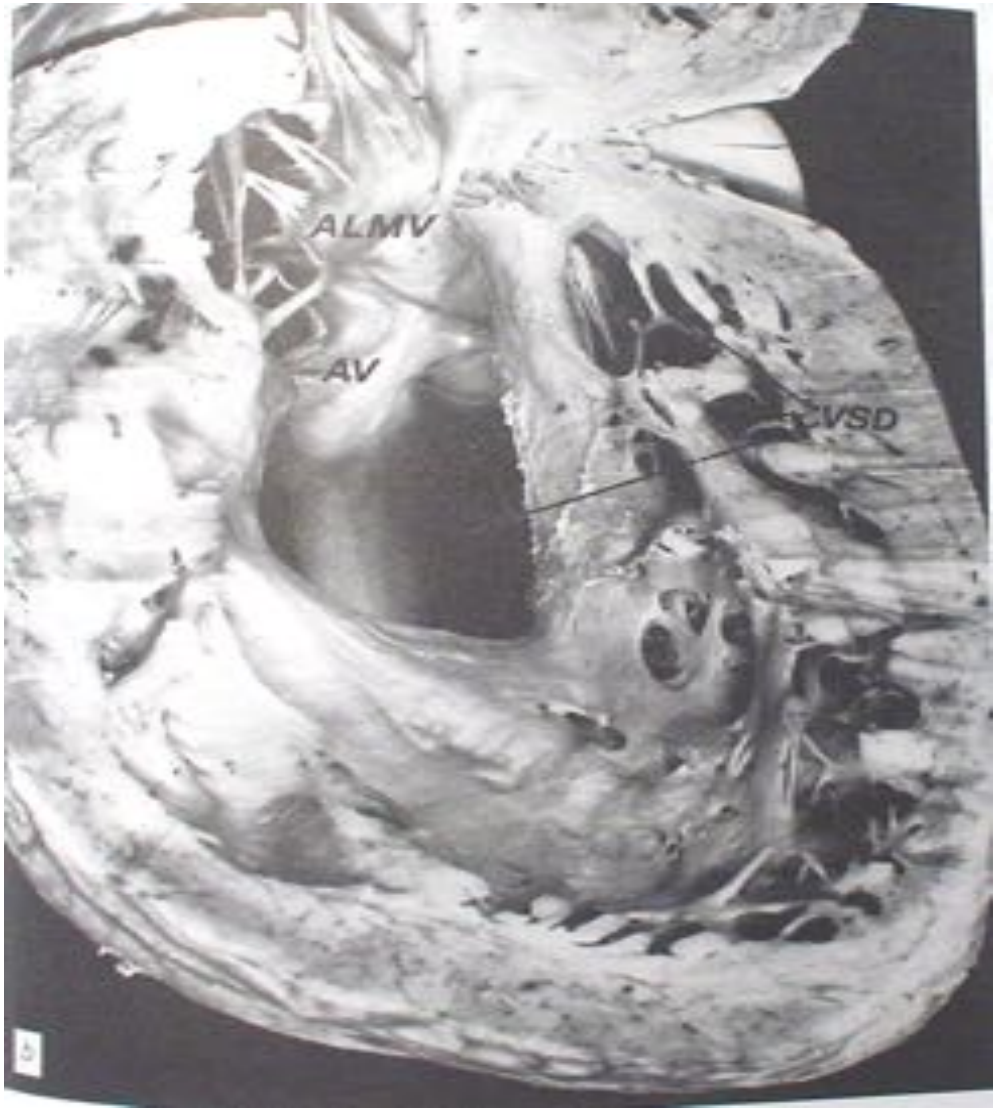

# INDICATIONS

- CIV large ,deux situations:

1. CIV avec HTAP ( non restrictive) :Chirurgie
2. CIV sans HTAP (restrictive) avec hyperdébit:Patienter si bonne prise staturo-pondérale

- CIV petite:pas de chirurgie sauf:

1. Insuffisance aortique qui se developpe (périmembraneuse)
2. Endocardite infectieuse

# INDICATIONS

- fermeture sous CEC
- cerclage pulmonaire
  - CIV multiples
  - contre-indication CEC (CIV unique)

# Fermeture chirurgicale des CIV périmembraneuses par voie transatriale

- Contrôle premier du canal artériel dès le départ en CEC

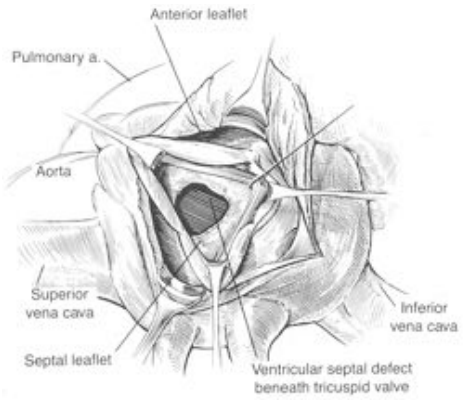


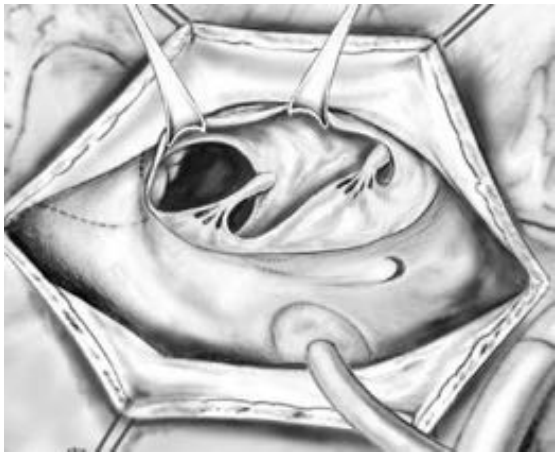

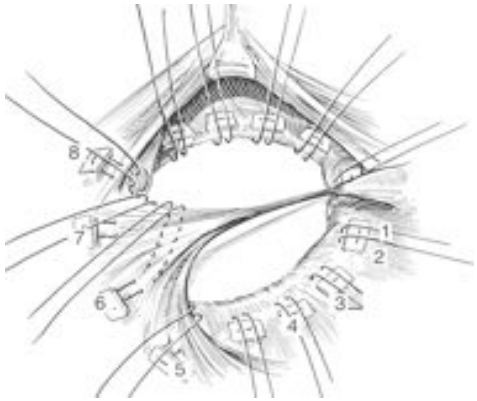


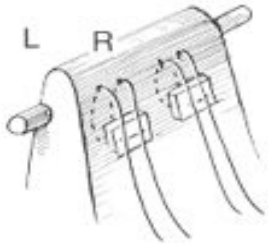

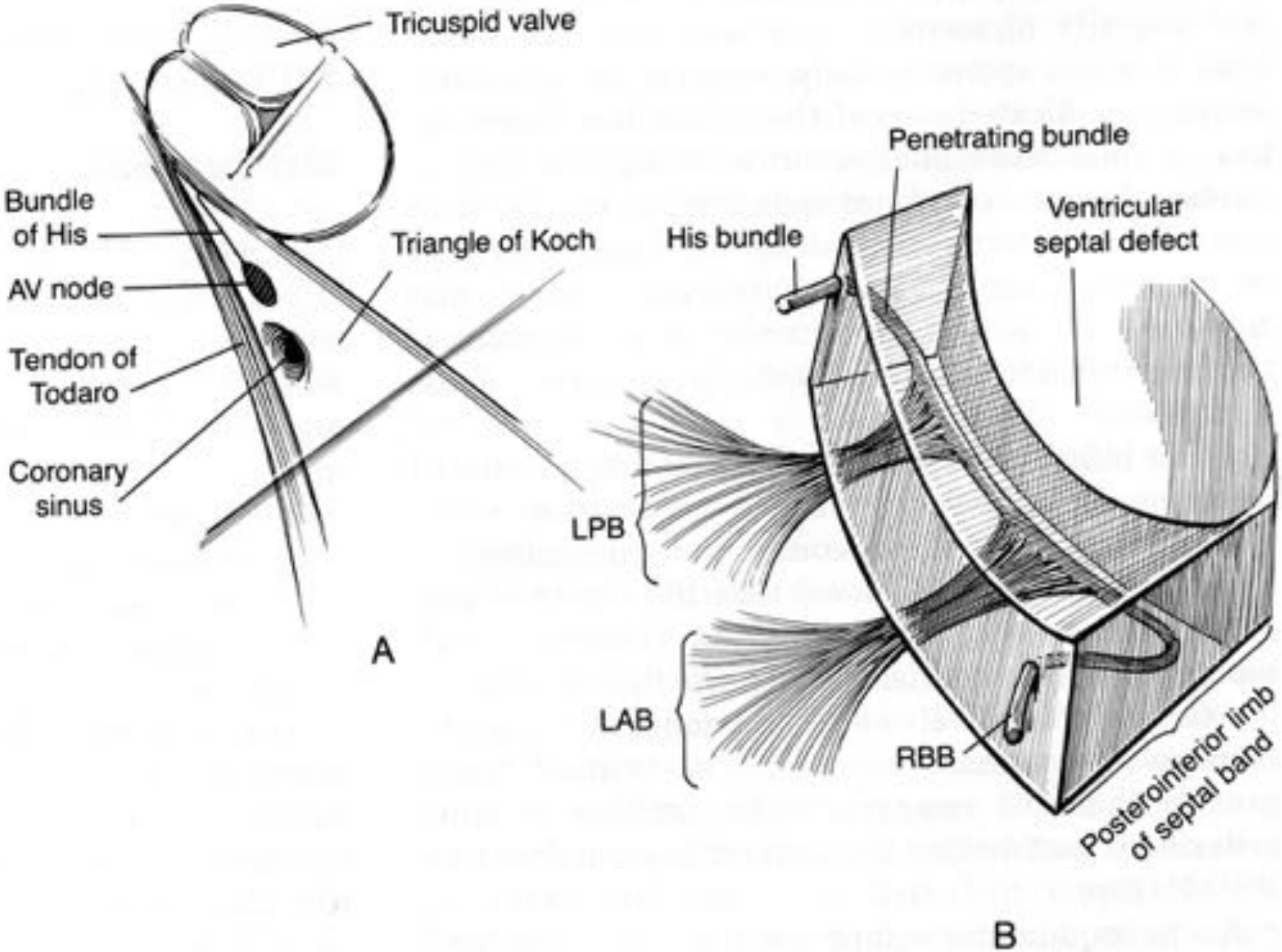
Tricuspid valve
Bundle of His
AV node
Tendon of Todaro
Coronary sinus
Triangle of Koch
A
Penetrating bundle
His bundle
Ventricular septal defect
LPB
LAB
RBB
Posteroinferior limb of septal band
B

# Fermeture chirurgicale des CIV d'admission par voie transatriale

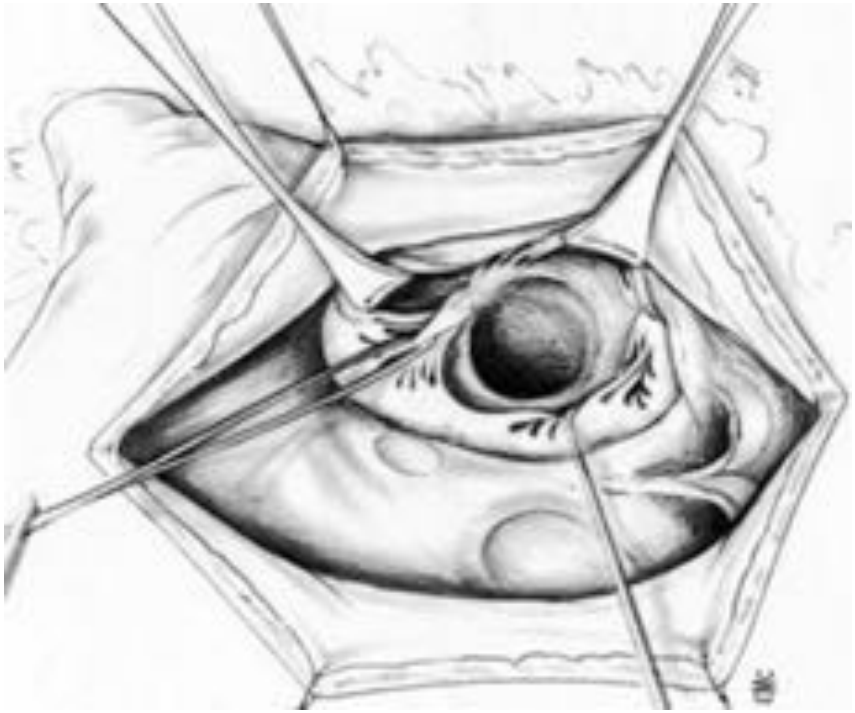

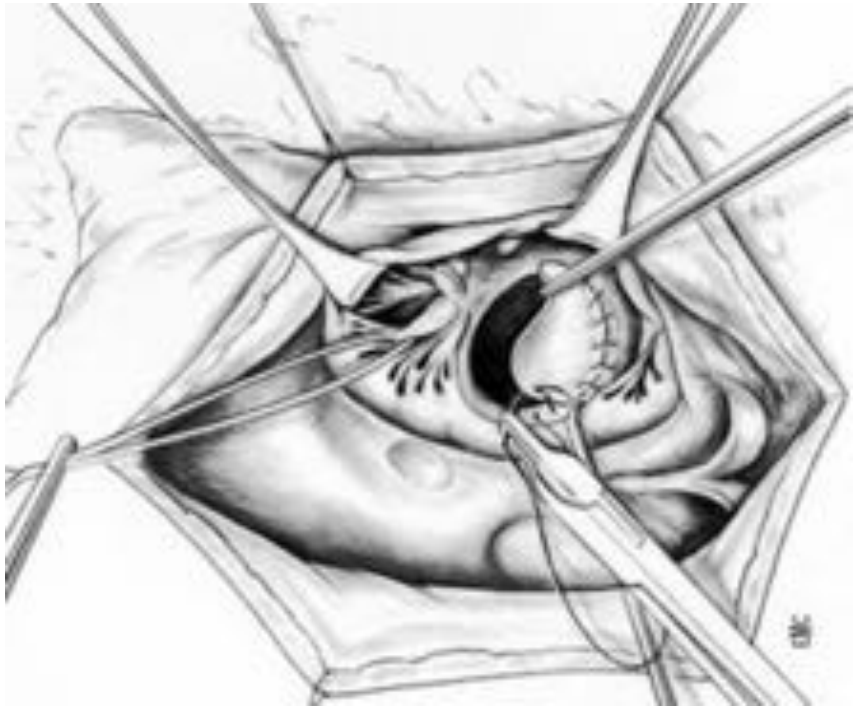

# Fermeture chirurgicale des CIV infundibulaires

## Voie Transpulmonaire

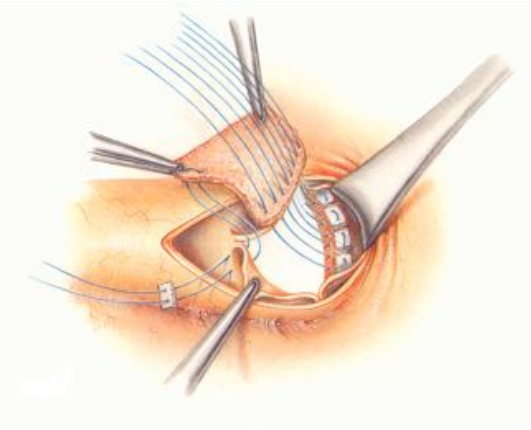

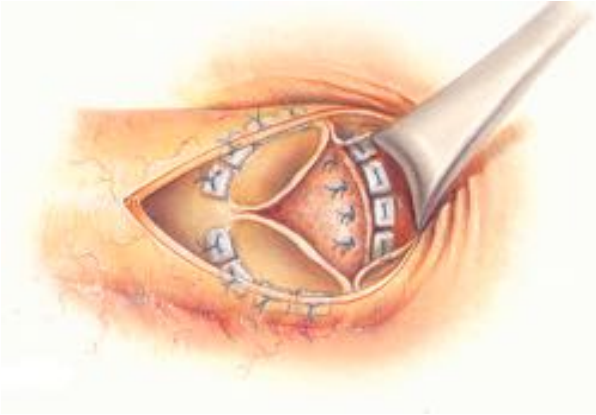

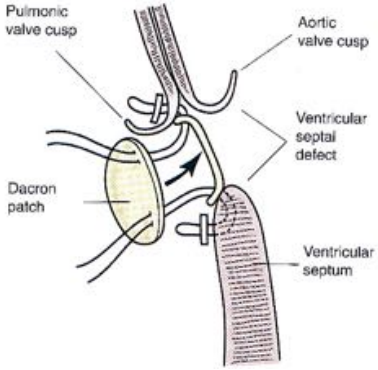


## Voie Transinfundibulaire

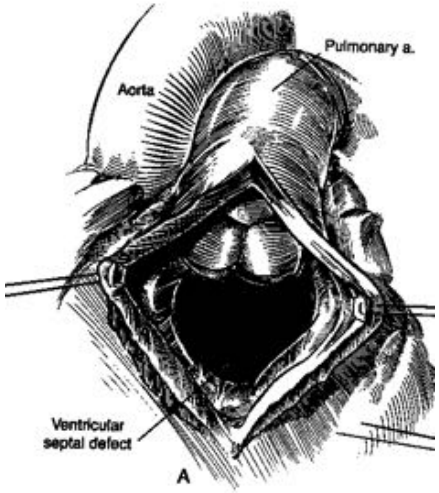


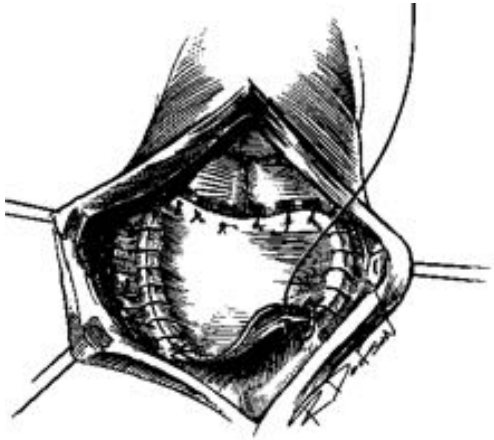

# Fermeture chirurgicale des CIV trabéculée

Voie transatriale pour CIV trabéculées haute ou moyenne

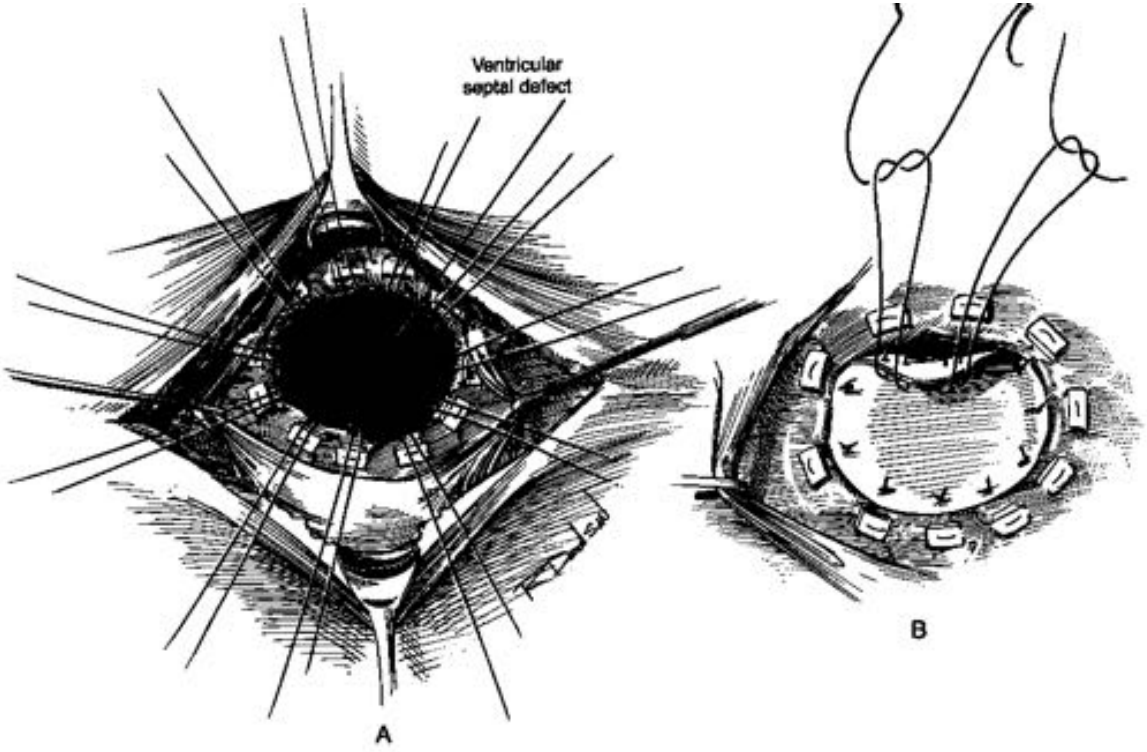

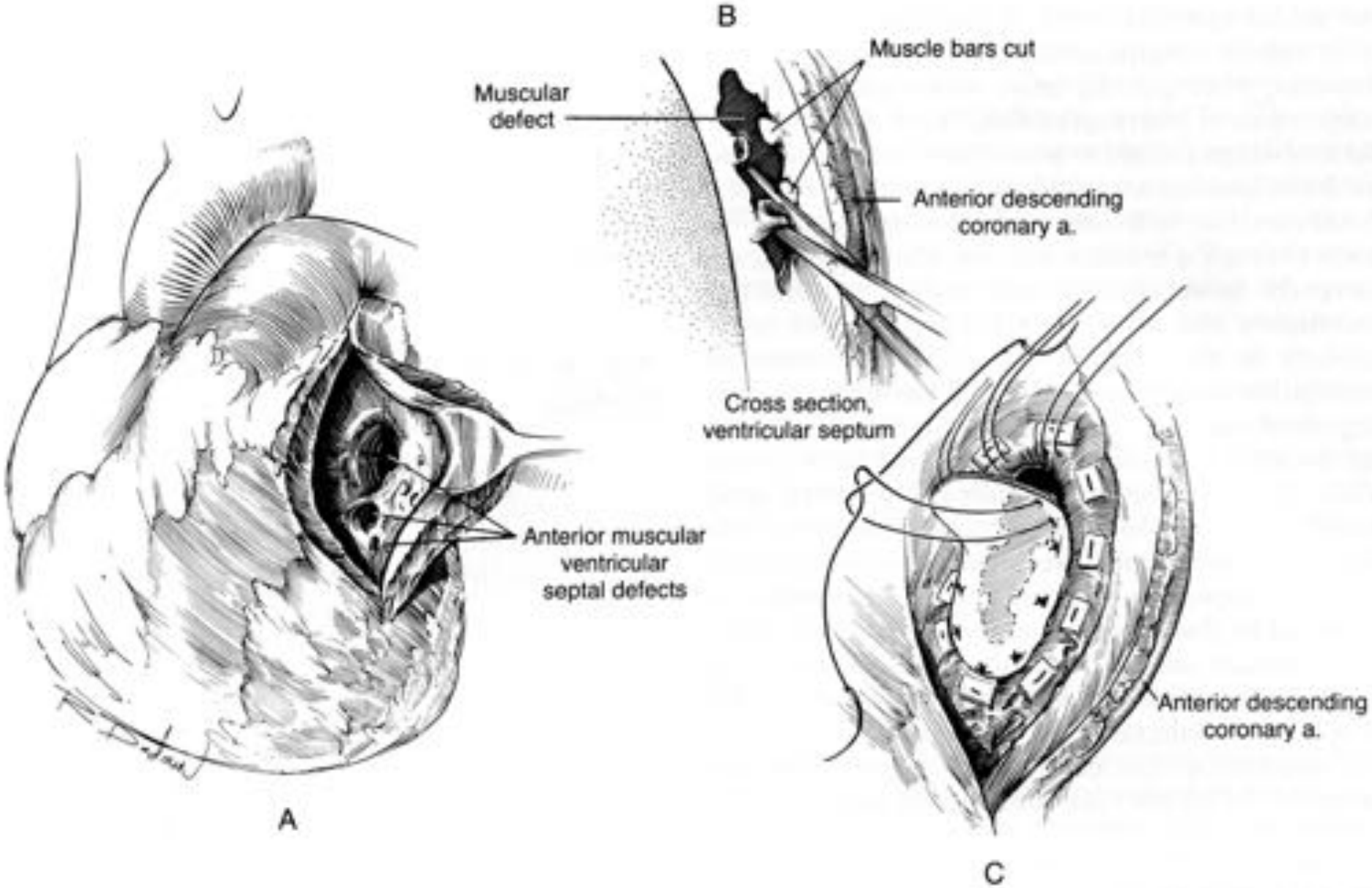
B
Muscle bars cut
Muscular defect
Anterior descending coronary a.
Cross section, ventricular septum
Anterior muscular ventricular septal defects
Anterior descending coronary a.
A
C

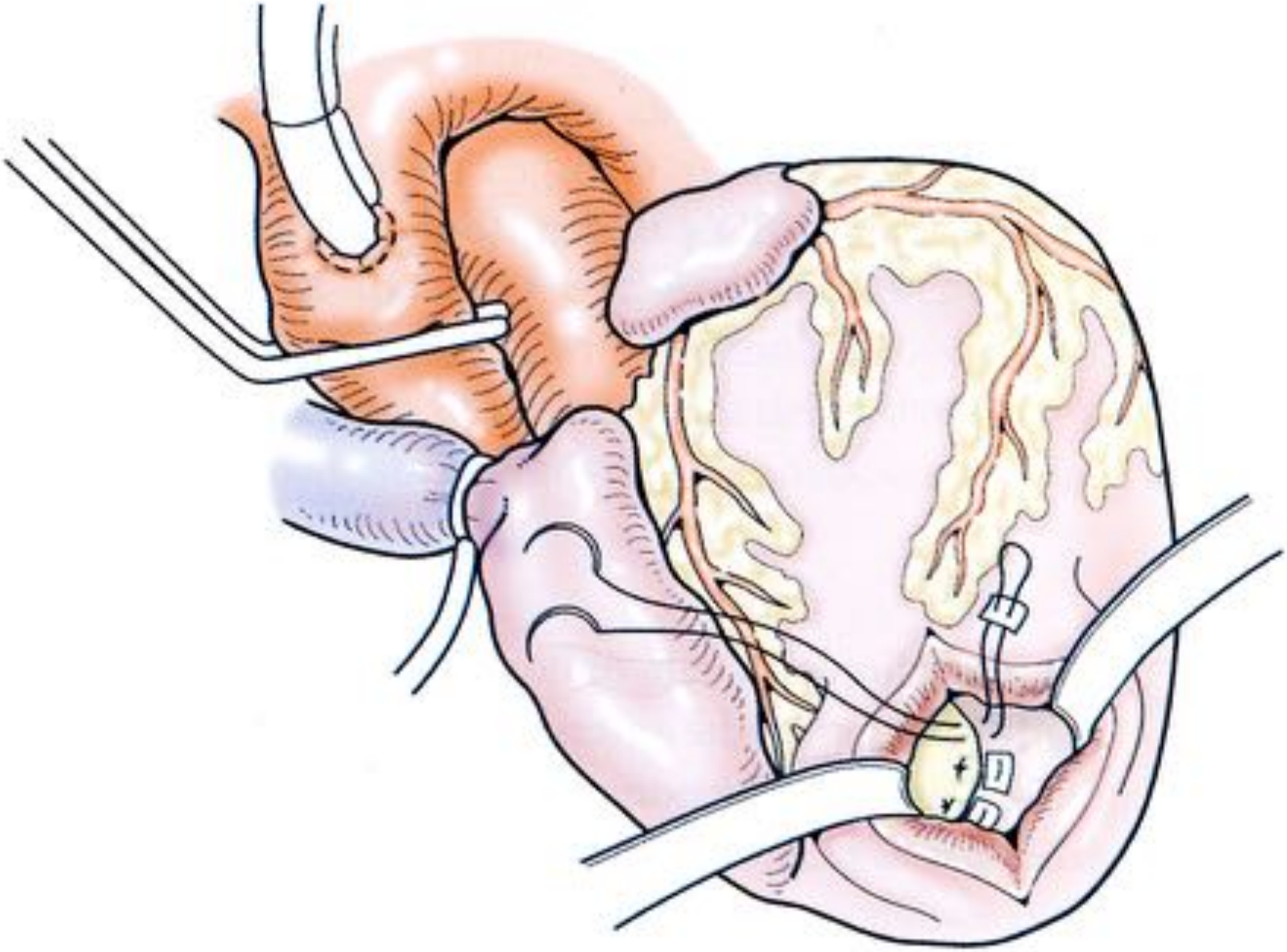

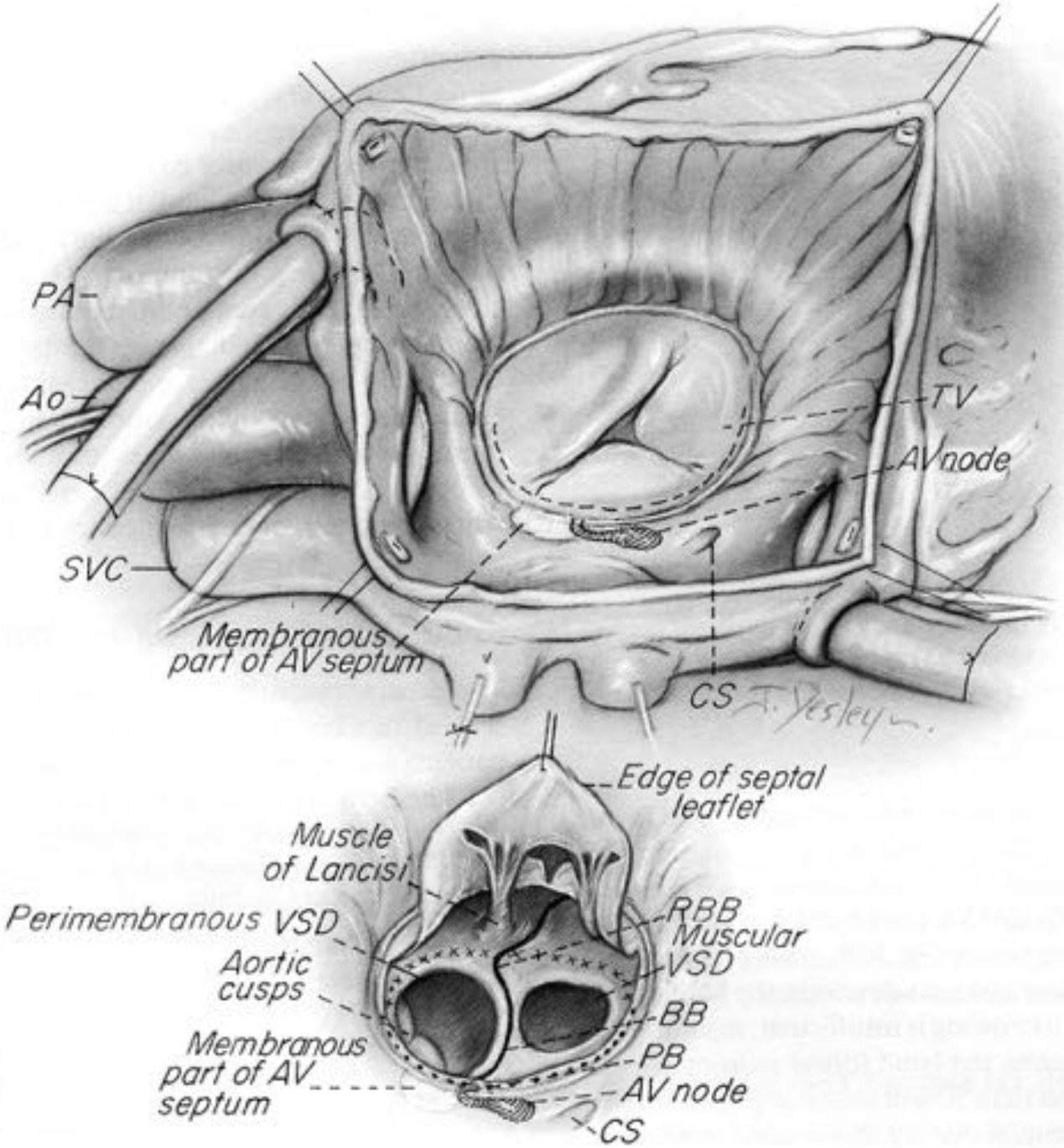
PA
Ao
SVC
TV
AV node
Membranous part of AV septum
CS
Edge of septal leaflet
Muscle of Lancisi
Perimembranous VSD
Aortic cusps
Membranous part of AV septum
RBB
Muscular VSD
BB
PB
AV node
CS

- cono-troncale : OD (±VD)
- infundibulaire : AP (± VD)
- inlet : OD
- trabéculées (souvent multiples)
  - moyennes : OD
  - antérieures : VD
  - apicales : VD (VG)

# Management per-opératoire

- CIA résiduelle restrictive
  - G/D : défaillance VG
  - D/G : HTAP

- détection CIV résiduelle (CIV multiples)
  - saturations étagées
  - échocardiographie per-opératoire

# Lésions associées

- canal artériel perméable
  (ligature systématique)
- insuffisance aortique
- sténose infundibulaire
- coarctation aortique

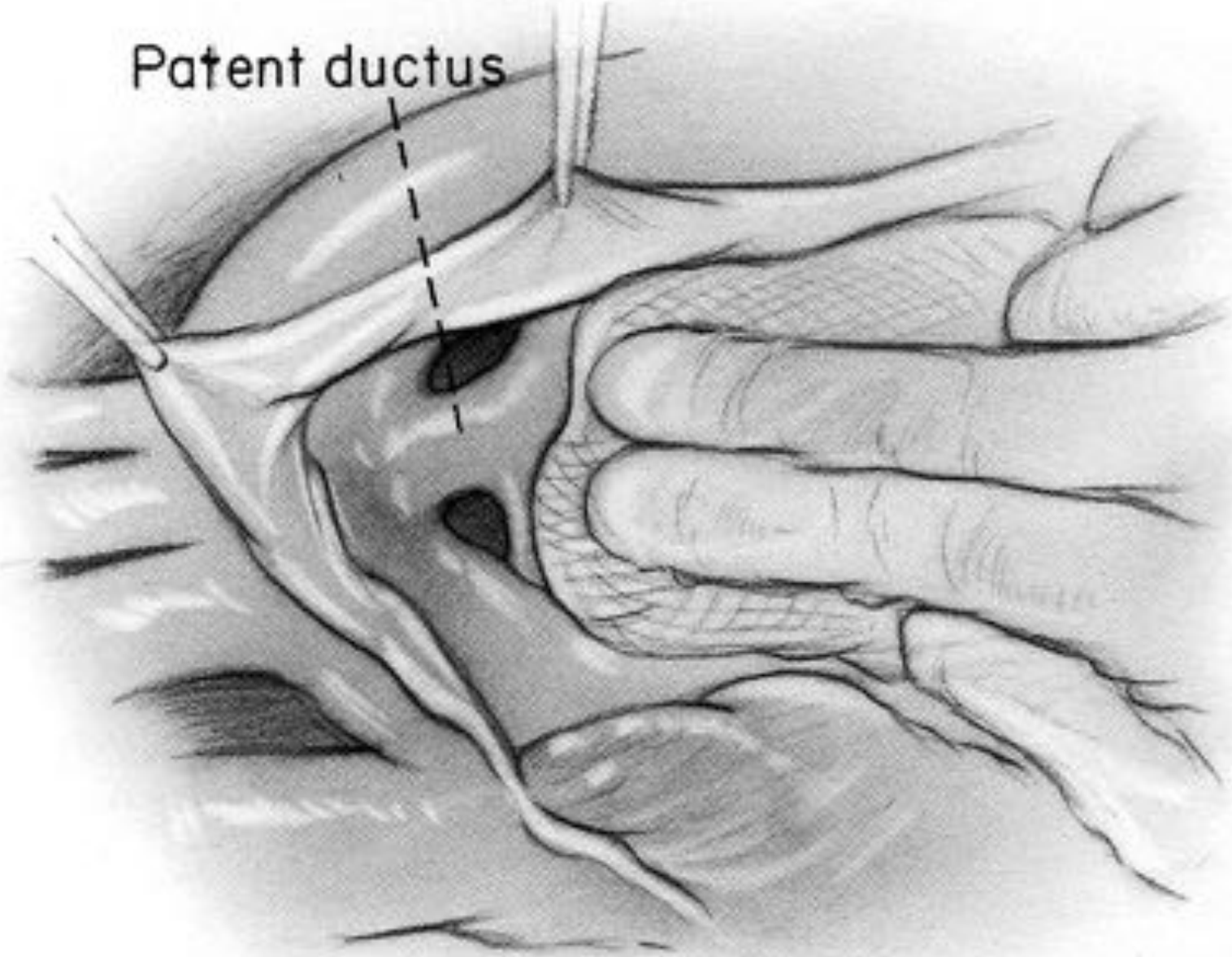
Patent ductus

# CIV + IAo

- IAo minime
  - indication formelle fermeture CIV
  - pas de geste sur valve aortique

- IAo significative
  - plastie valvulaire aortique
  - résultats aléatoires

# Lésion associées

- Fuite aortique (PM ou OUTLET)

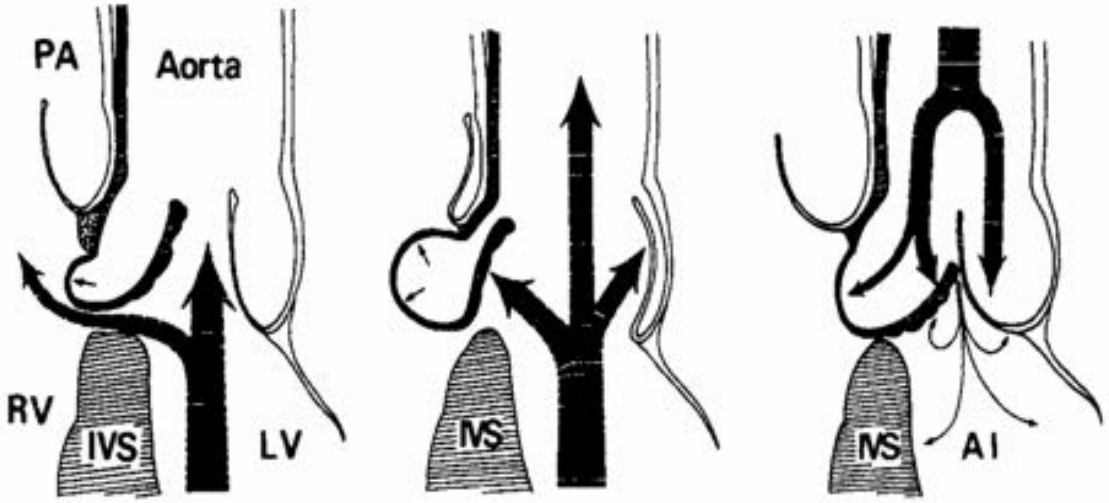

# CIV + coarctation

- coarctation + CIV petite
  - cure de coarctation
  - surveillance
- coarctation + CIV large
  - cure complète en 1 temps
  - coarctation + cerclage = contre-indication cure complète
- coarctation + CIV moyenne
  - coarctation + cerclage résorbable
  - surveillance

# Complications spécifiques après fermeture chirurgicale des CIV

Risques communs :
- HTAP (Résistances Pulmonaires élevées +/- CIVr)
- Rythme jonctionnel

Risques spécifiques

CIV PM
- *CIVr*
- *BAV*
- *Valves aortique et tricuspide*

CIV Inlet
- *CIVr*
- *BAV ++*

CIV Outlet
- *CIVr*
- *Valve aortique et pulmonaire*

CIV Trabéculée
- *CIVr ++ (souvent CIVm)*

- ✓ CIV résiduelle
  - fermeture incomplète
  - autre CIV méconnue
  - réintervention ? (taille, shunt)
- ✓ CIV résiduelle
  - CIV résiduelle (attention Osler)
- ✓ BAV post-opératoire
- ✓ insuffisance aortique
- ✓ insuffisance tricuspidienne
- ✓ HTAP

- ✓ Désinsertion patch (taille du patch!!! Pas trop petit)
- ✓ Problème coronaire
  - civ infundibulaire
  - Alcapa
- ✓ défaillance ventriculaire gauche