Pathologies Cardiaques Congénitales

Hôpitaux de Bordeaux

C·H·U

Hôpitaux de Bordeaux

Sténose pulmonaire APSI

Pierre-Emmanuel Séguéla

DIU RCC 2017

VALVE PULMONAIRE

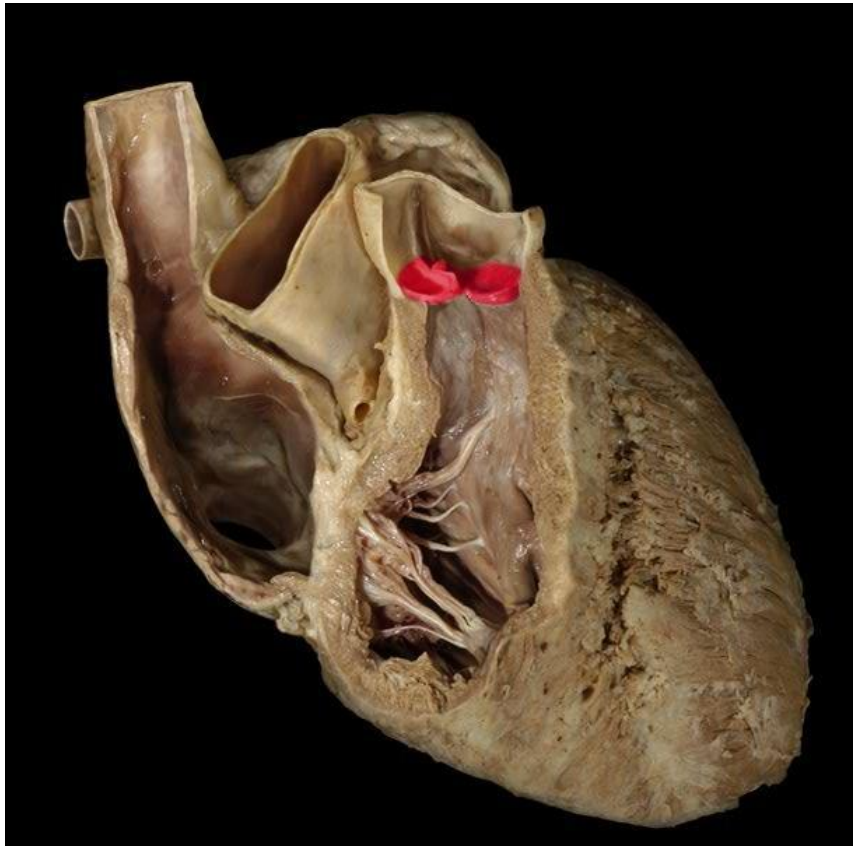

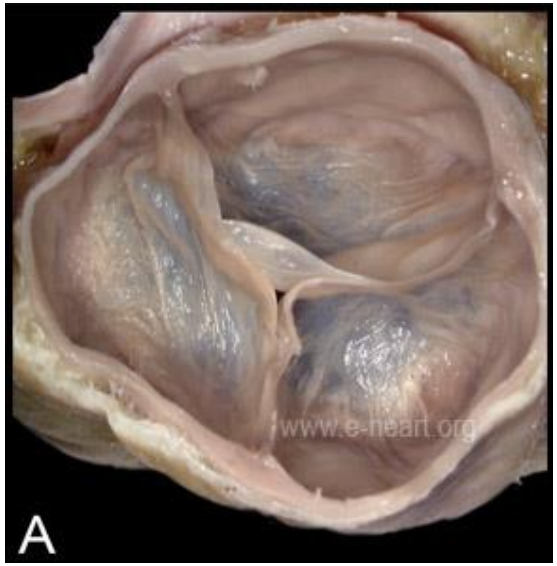

- Anneau fibreux circulaire
- 3 valves semi-lunaires

OBSTACLE DROIT SANS SHUNT VENTRICULAIRE

- Cyanose réfractaire (shunt atrial)
- Souffle systolique
- RP: hypoperfusion pulmonaire (± marquée)

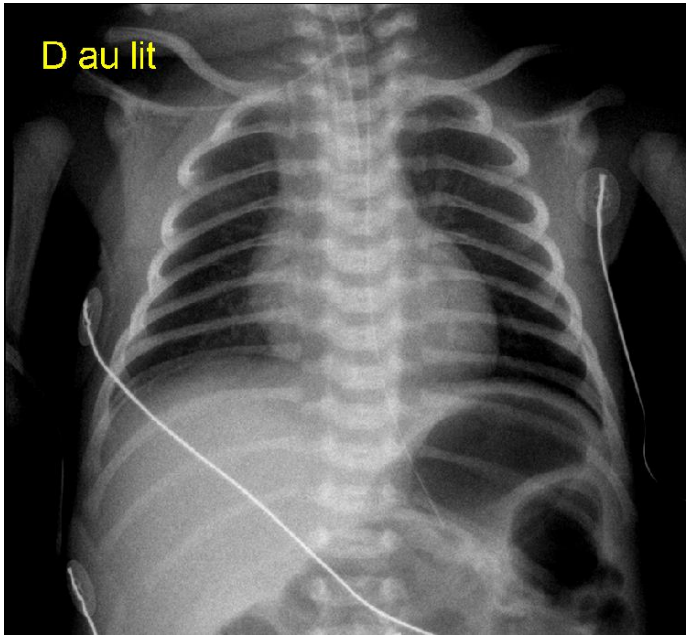

STENOSE PULMONAIRE

7-12 % des CC

- Supra-valvulaire

- Valvulaire

- Sous-valvulaire

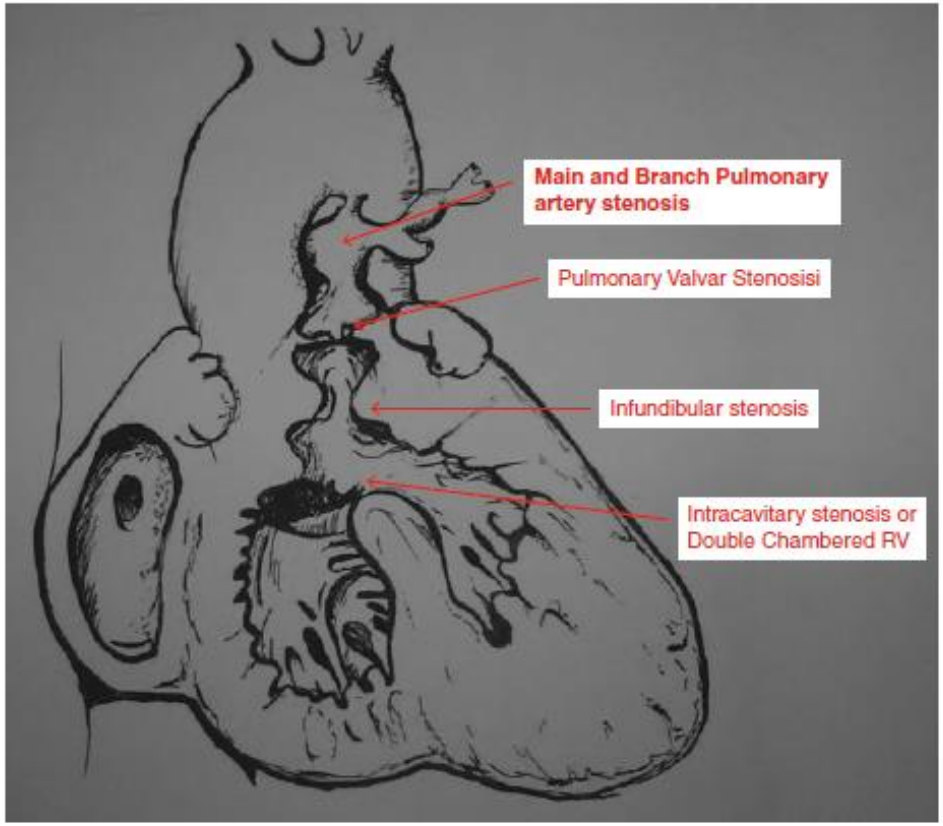

STENOSE VALVULAIRE

- Bicuspidie et/ou dysplasie

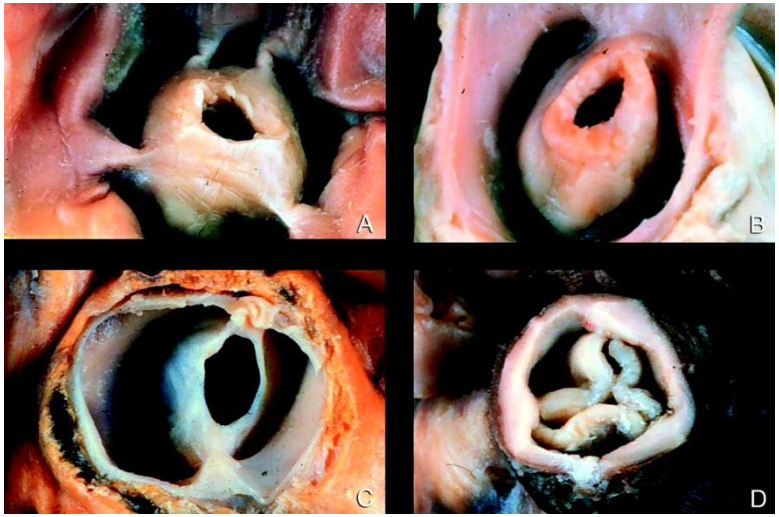

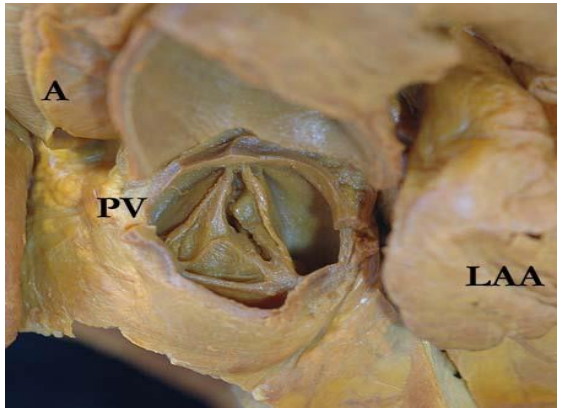

Bruce et al. Circulation 2009.

- Ouverture en dôme

- Jet lesion = dilatation post-sténotique

- Syndrome de Noonan ++

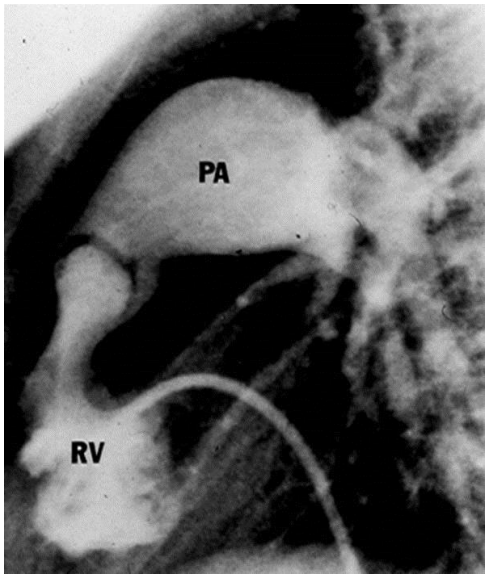

PHYSIOPATHOLOGIE

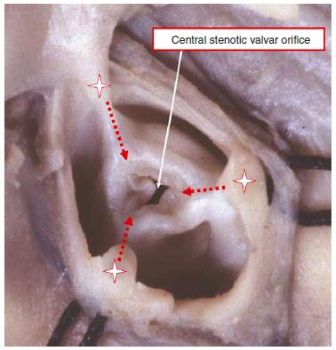

- ↗ PVDs
- HVD (si sévère: ischémie myocardique/fibrose)
- ↘ compliance VD
- ↗ POD
- Si FOP/CIA: shunt D-G atrial et cyanose

EVALUATION ETT

- Taille de l'anneau

- Bicuspidie/dysplasie

- Gradient VD-AP et PVDs

- Fuite associée

- Taille AP

- Taille et fonction du VD

- Valve tricuspide

Table 11 Grading of pulmonary stenosis

	Mild	Moderate	Severe
Peak velocity (m/s)	<3	3–4	>4
Peak gradient (mmHg)	<36	36–64	>64

EAE/ASE Recommendations. Eur Heart J 2009.

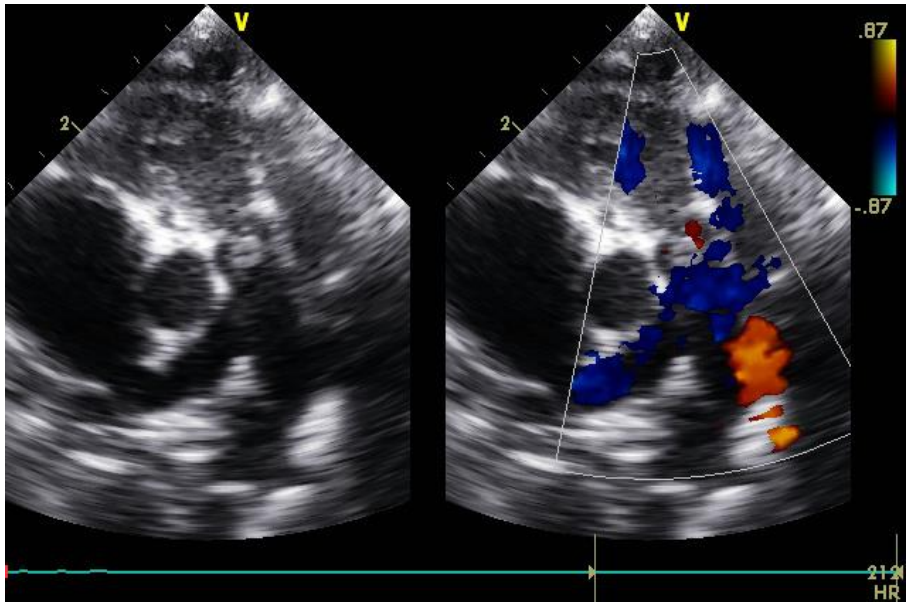
V
2
V
2
.87
-.87
212
HR

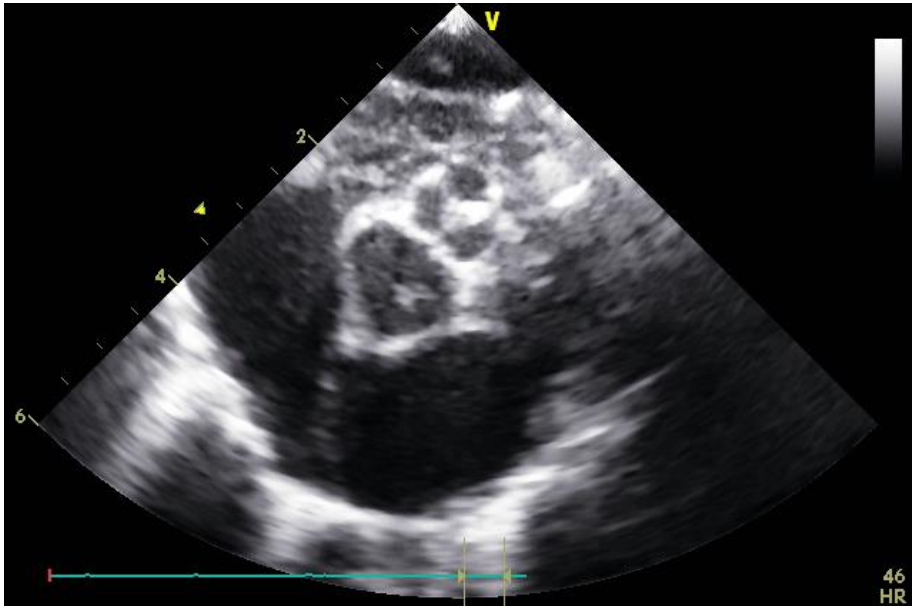
V
2
4
6
46
HR

STENOSE CRITIQUE NEONATALE

- ↗ rapide du gradient VD-AP (baisse des RVP)

- PVDs iso/suprasystémique

- HVD: risque de défaillance VD

- FOP D-G

⇨ Cardiopathie ducto-dépendante

GRADIENT: QUEL CUT-OFF ?

Recommendations for Pulmonary Valvuloplasty

Class I

1. Pulmonary valvuloplasty is indicated for a patient with critical valvar pulmonary stenosis (defined as pulmonary stenosis present at birth with cyanosis and evidence of patent ductus arteriosus dependency), valvar pulmonic stenosis, and a peak-to-peak catheter gradient or echocardiographic peak instantaneous gradient of ≥40 mm Hg or clinically significant pulmonary valvar obstruction in the presence of RV dysfunction *(Level of Evidence: A)*.

Class IIa

1. It is reasonable to perform pulmonary valvuloplasty on a patient with valvar pulmonic stenosis who meets the above criteria in the setting of a dysplastic pulmonary valve *(Level of Evidence: C)*.
2. It is reasonable to perform pulmonary valvuloplasty in newborns with pulmonary valve atresia and intact ventricular septum who have favorable anatomy that includes the exclusion of RV-dependent coronary circulation *(Level of Evidence: C)*.

Class IIb

1. Pulmonary valvuloplasty may be considered as a palliative procedure in a patient with complex cyanotic CHD, including some rare cases of tetralogy of Fallot *(Level of Evidence: C)*.

Class III

1. Pulmonary valvuloplasty should not be performed in patients with pulmonary atresia and RV-dependent coronary circulation *(Level of Evidence: B)*.

Majoration rapide au cours du 1er mois de vie

AHA indications. Circulation 2011.

TRAITEMENT

- Prostine

- Dilatation percutanée (sizing: 120% anneau)

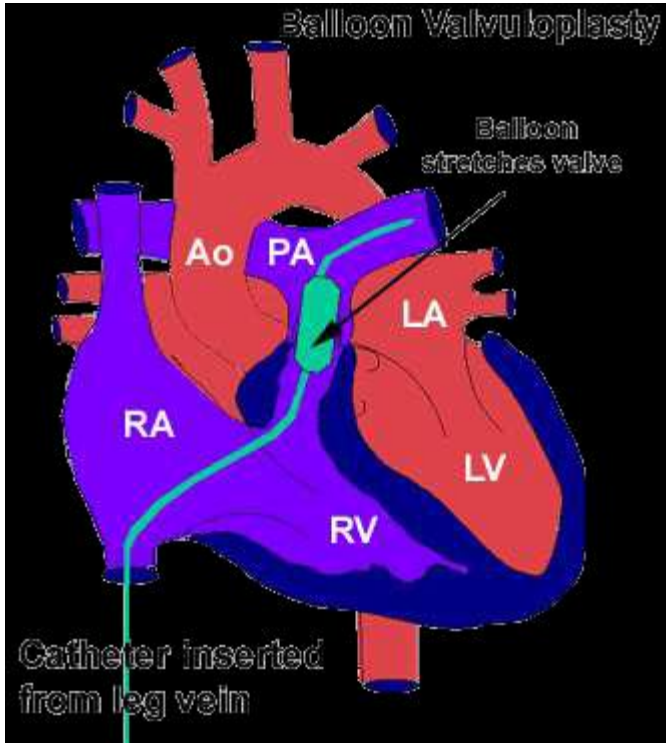

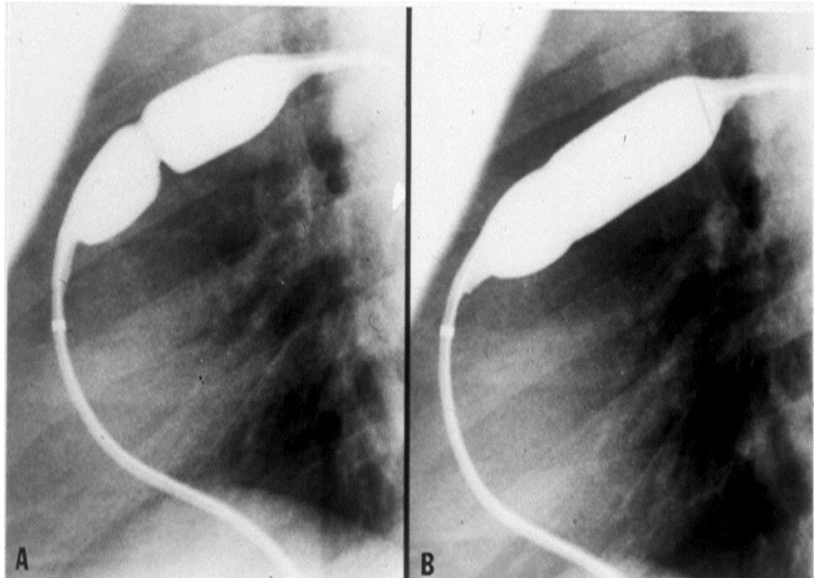

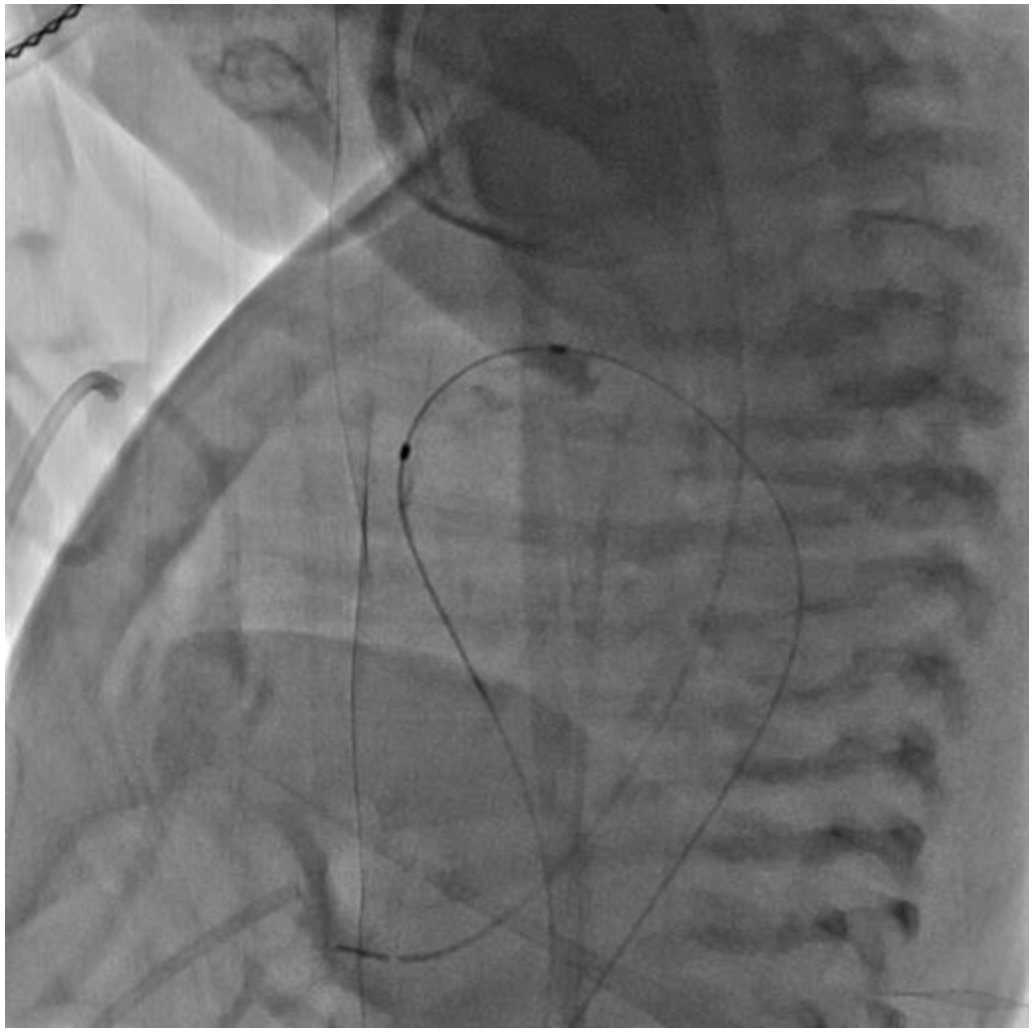

COMPLICATIONS

- Accès vasculaires
- Arythmie
- Emboles
- IP +++
- IT par rupture de pilier
- Perforation tricuspide
- Sténose infundibulaire réactionnelle
- Shunt circulaire
- Récidive

EFFICACITE

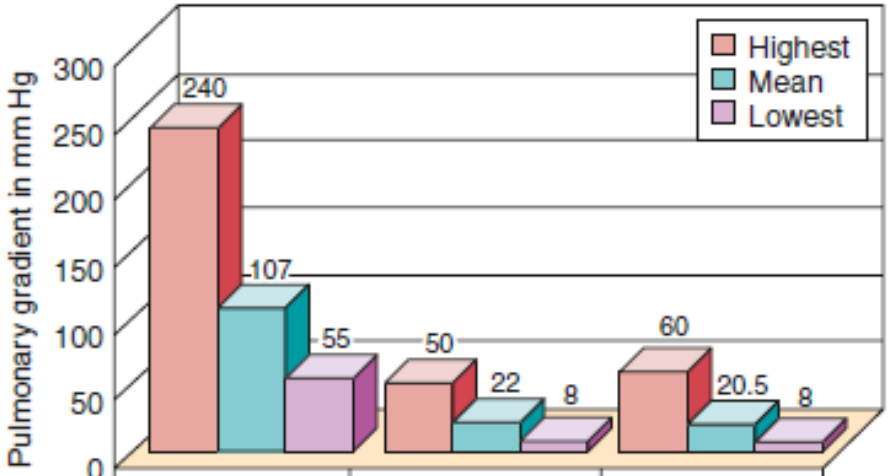

	Pre balloon	Immediately after	Late
Highest	240	50	60
Mean	107	22	20.5
Lowest	55	8	8

Figure 43-31 Pulmonary valvar gradients before, immediately after, and late after balloon pulmonary valvoplasty. (Reproduced with permission from Sadr-Ameli MA, Sheikholeslami F, Firoozi I, Azarnik H: Late results of balloon pulmonary valvuloplasty in adults. Am J Cardiol 1998;82:398–400.)

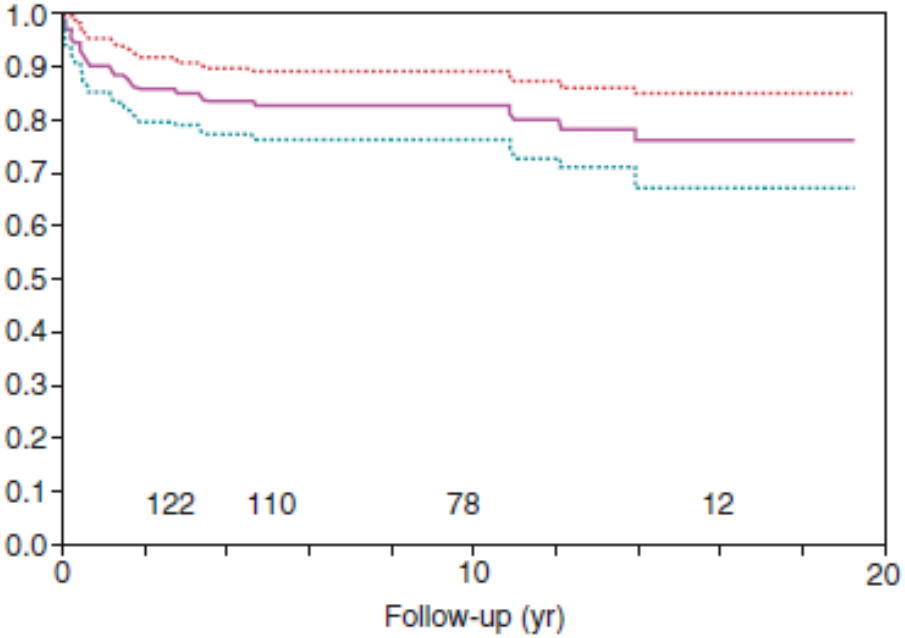

COMMISSUROTOMIE CHIRURGICALE

- Si échec de la dilatation
- Si anneau trop petit

SHUNT CIRCULAIRE

- Arrêt rapide de la prostine +++

Canal large

IP

IT

Shunt atrial

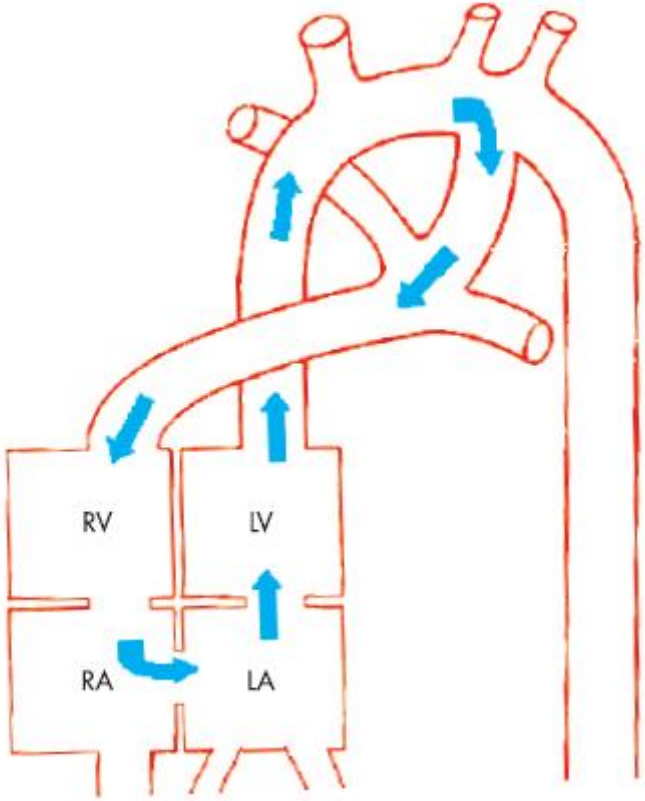

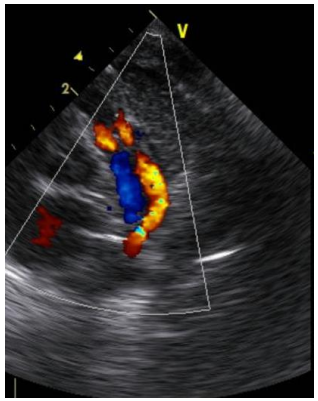

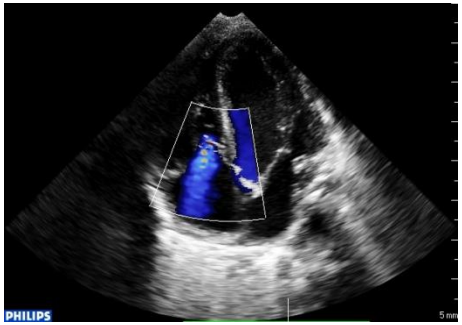

« SUICIDAL RIGHT VENTRICLE »

- Sténose infundibulaire réactionnelle

- Tachycardie

⇨ ↘ compliance VD
⇨ ↗ cyanose
⇨ ↘ perfusion coronaire (ischémie)

SVP DE L'ENFANT

- Souvent bien tolérée

- Majoration de l'obstacle: 1ère année et adolescence

- Indications:
  - symptomatique
  - PVDs > 2/3 Psyst
  - Gradient max

QUEL GRADIENT ?

Table 13 Indications for intervention in right ventricular outflow tract obstruction

Indications	Class[a]	Level[b]
RVOTO at any level should be repaired regardless of symptoms when Doppler peak gradient is >64 mmHg (peak velocity >4m/s), provided that RV function is normal and no valve substitute is required	I	C
In valvular PS, balloon valvotomy should be the intervention of choice	I	C
In asymptomatic patients in whom balloon valvotomy is ineffective and surgical valve replacement is the only option, surgery should be performed in the presence of a systolic RVP >80 mmHg (TR velocity >4.3 m/s)	I	C
Intervention in patients with gradient <64 mmHg should be considered in the presence of: • symptoms related to PS or, • decreased RV function or, • double-chambered RV (which is usually progressive) or, • important arrhythmias or, • right-to-left shunting via an ASD or VSD.	IIa	C
Peripheral PS, regardless of symptoms, should be considered for repair if >50% diameter narrowing and RV systolic pressure >50 mmHg and/or lung perfusion abnormalities are present	IIa	C

[a]Class of recommendation.
[b]Level of evidence.
ASD = atrial septal defect; PS = pulmonary stenosis; RV = right ventricle; RVOTO = right ventricular outflow tract obstruction; RVP = right ventricular pressure; TR = tricuspid regurgitation; VSD = ventricular septal defect.

Guidelines ESC. Eur Heart J 2010.

EFFICACITE

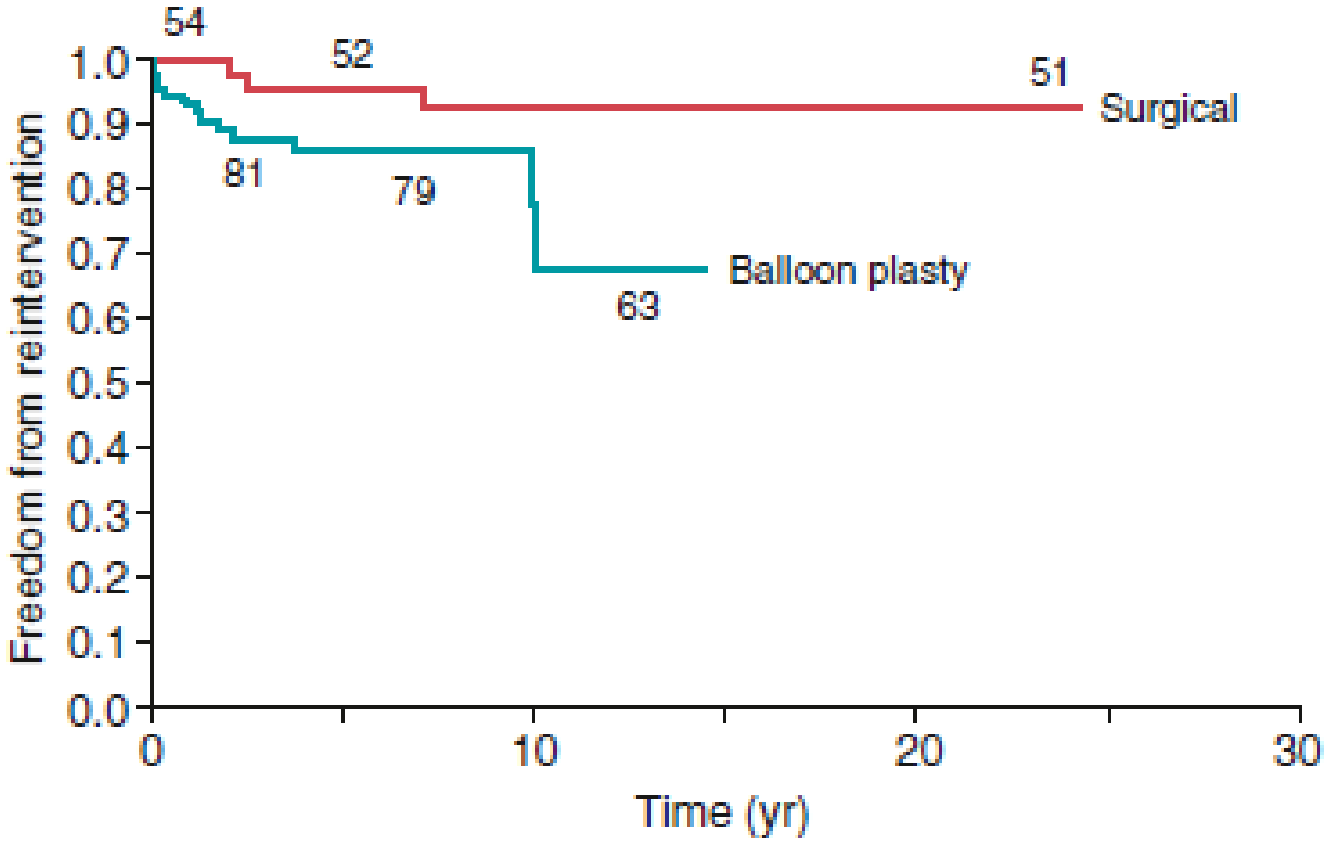

Chez l’adulte

STENOSE SOUS-VALVULAIRE

- 2 formes:

  - VDDC (bande musculaire)

  - Sténose infundibulaire

⇨ Chirurgie

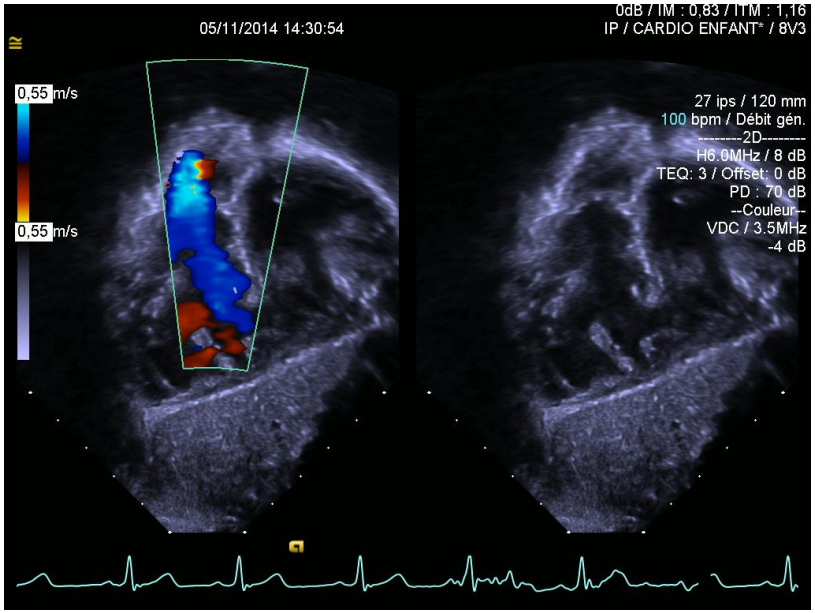
05/11/2014 14:30:54
0dB / IM : 0,83 / ITM : 1,16
IP / CARDIO ENFANT* / 8V3
0,55 m/s
0,55 m/s
27 ips / 120 mm
100 bpm / Débit gén.
--------2D--------
H6.0MHz / 8 dB
TEQ: 3 / Offset: 0 dB
PD : 70 dB
--Couleur--
VDC / 3.5MHz
-4 dB

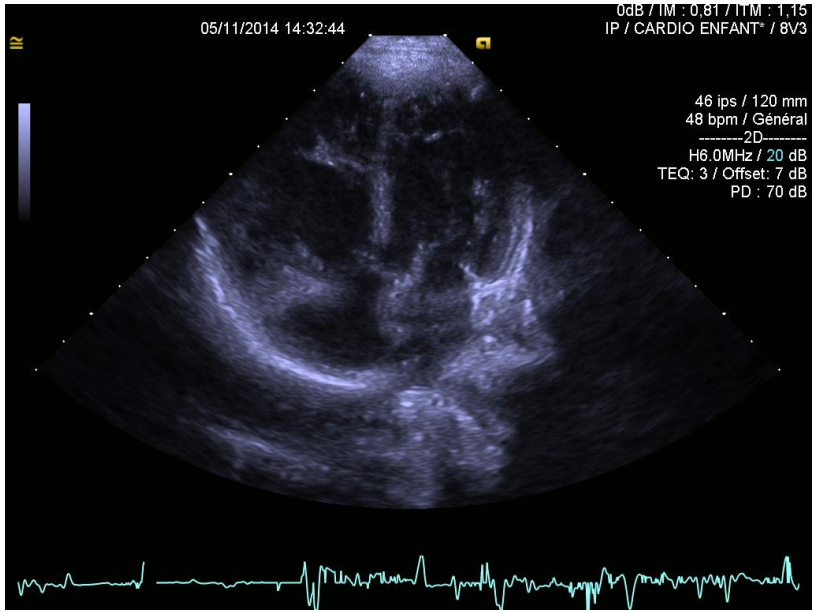
05/11/2014 14:32:44
0dB / IM : 0,81 / ITM : 1,15
IP / CARDIO ENFANT* / 8V3
46 ips / 120 mm
48 bpm / Général
--------2D--------
H6.0MHz / 20 dB
TEQ: 3 / Offset: 7 dB
PD : 70 dB

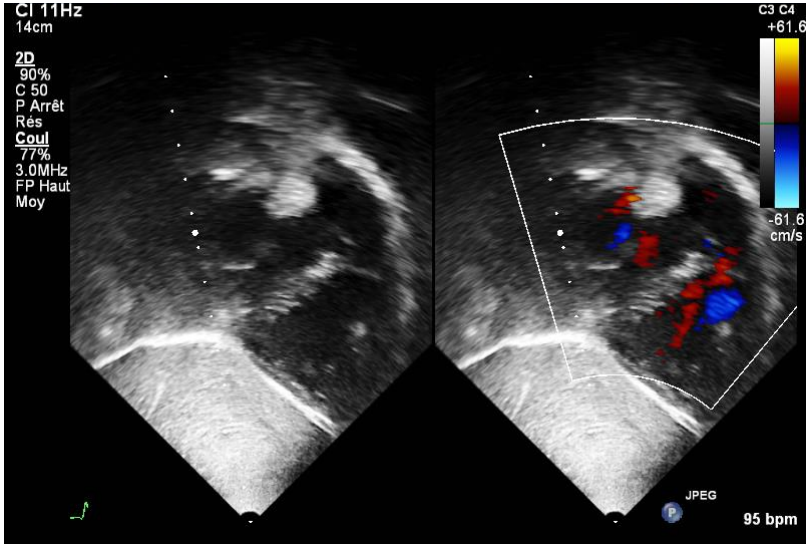
CI 11Hz
14cm
2D
90%
C 50
P Arrêt
Rés
Coul
77%
3.0MHz
FP Haut
Moy
C3 C4
+61.6
-61.6
cm/s
JPEG
95 bpm

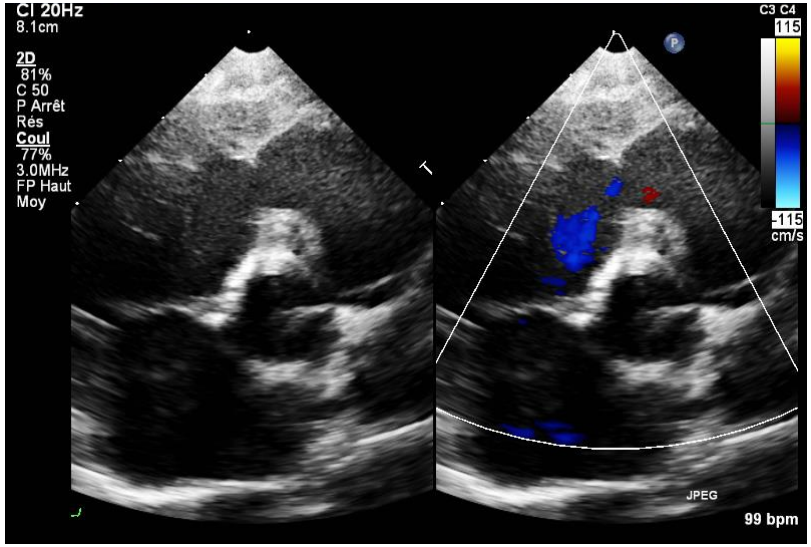
CI 20Hz
8.1cm
2D
81%
C 50
P Arrêt
Rés
Coul
77%
3.0MHz
FP Haut
Moy
C3 C4
115
-115
cm/s
JPEG
99 bpm

STENOSE SUPRA-VALVULAIRE

- Etiologies: - isolée

syndromique
- rubéole congénitale
- cutis laxa
- syndrome d'Alagille
- syndrome de Noonan
- Ehlers-Danlos
- syndrome de Williams-Beuren

- acquise après réparation

TRAITEMENT PERCUTANE

- Sténose bilatérale: PVDs > 75% Psyst

- Sténose unilatérale: hypoperfusion pulmonaire
  (scinti/valeur?)

- Williams Beuren: savoir attendre (si possible)

APSI

- Défaut de développement de la valve pulmonaire ⇨ plancher valvulaire
- Défaut de développement du VD
- Atrésie ± étendue (membrane/muscle)

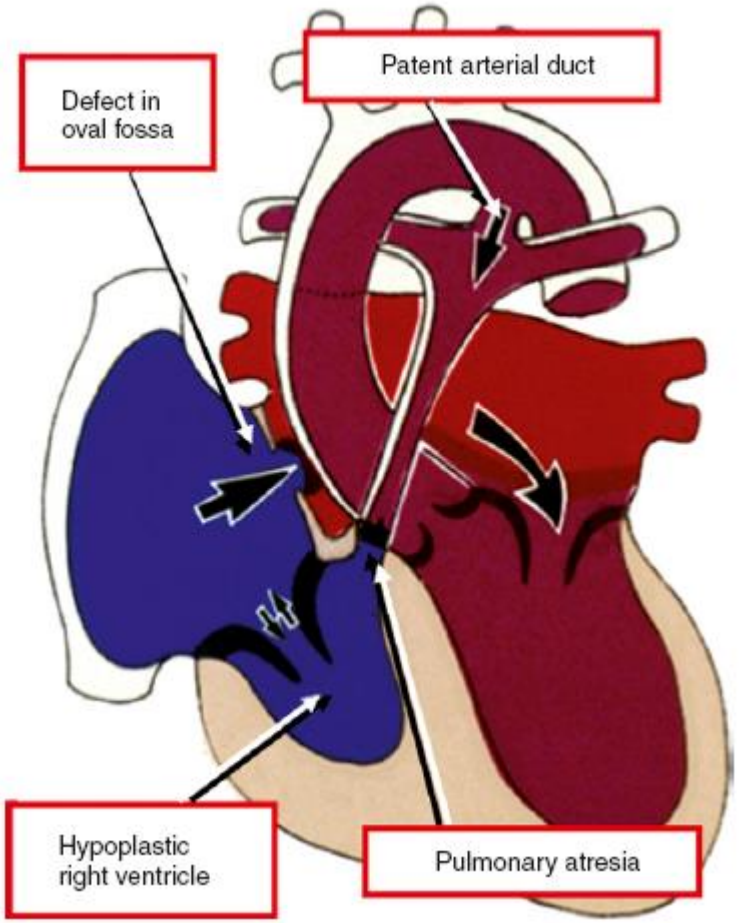

⇨ Cardiopathie ducto-dépendante

VD: RAPPEL

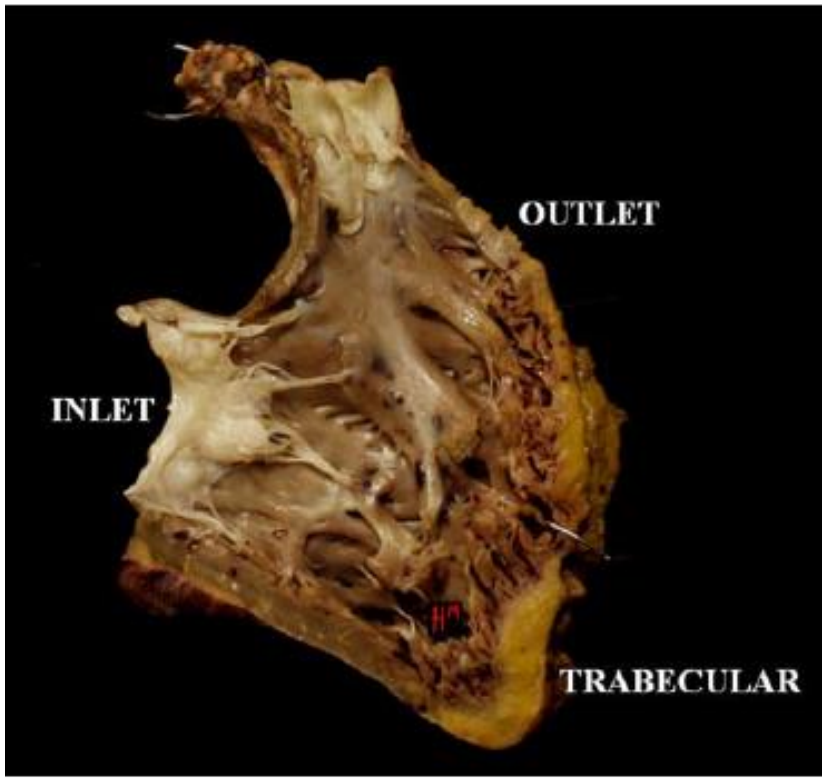

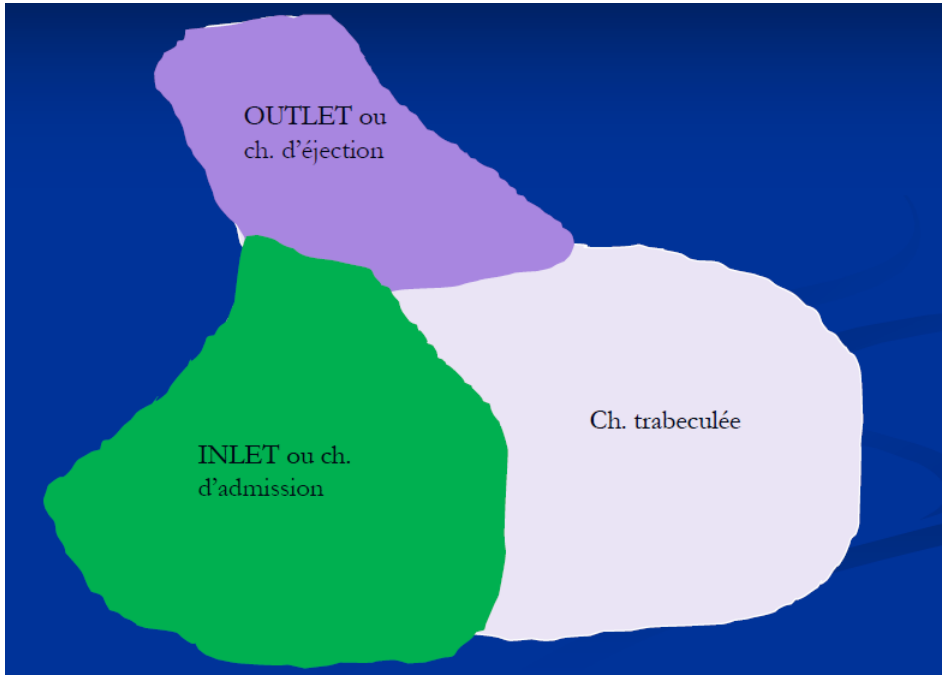

Muresian. Clin Anat 2014.

VD

- Normalement tripartite

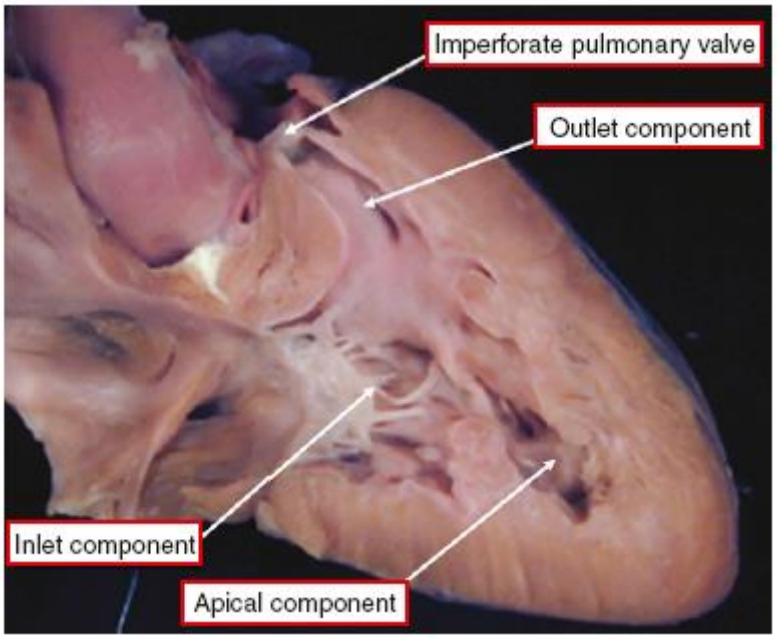

- Bipartite: chambre d’admission + infundibulum
- Unipartite (croupion): chambre d’admission

VALVE TRICUSPIDE

- ± dysplasique
- Anneau ± petit
- IT variable (corrélée à la PVDs)

FISTULES CORONAIRES (SINUSOIDES)

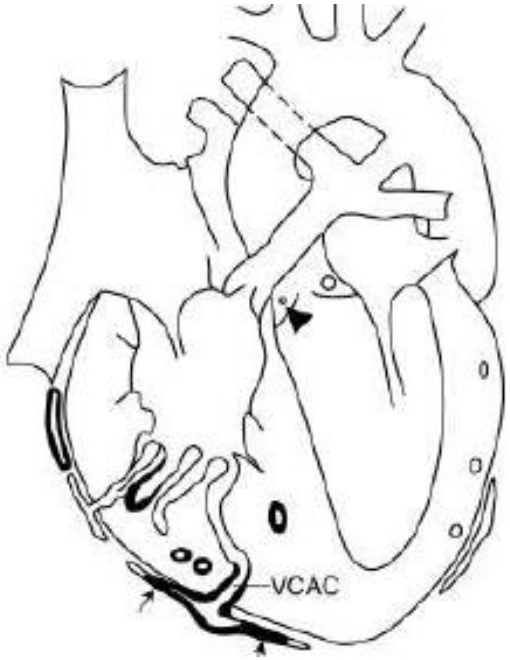

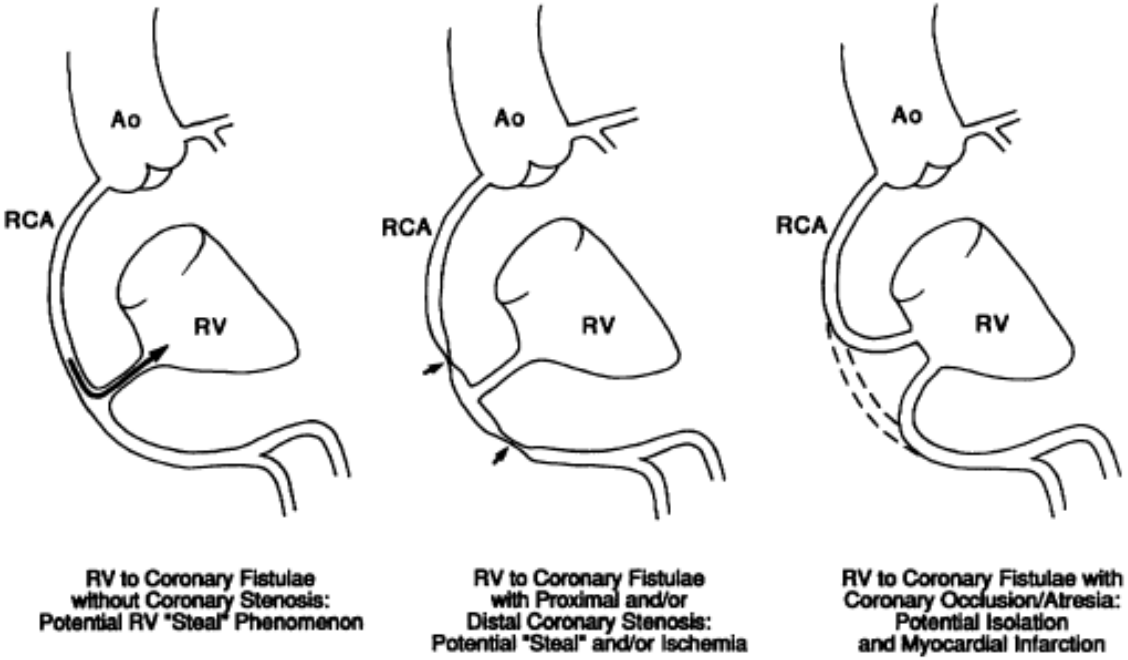

Notion de circulation coronaire VD-dépendante

a right ventricle-dependent coronary circulation is classically defined as a right ventricle to coronary artery fistula associated with obstruction of more than one main coronary artery

EVALUATION ETT

- Extension de l’atrésie
- Diamètre anneau pulmonaire
- Branches pulmonaires
- Diamètre anneau tricuspide
- Taille VD
- IT
- CA
- Sinusoïdes

1. VD de bonne taille, pas de fistule, plancher valvulaire

- Ouverture percutanée

- Bêta-bloquant si besoin

- Blalock si sevrage PGE1 impossible

2. VD bipartite, pas de fistule, plancher valvulaire

- Décompression VD
- + Blalock ou stenting canal
- Attendre la croissance du VD

→ fermeture blalock/canal ou DCPP

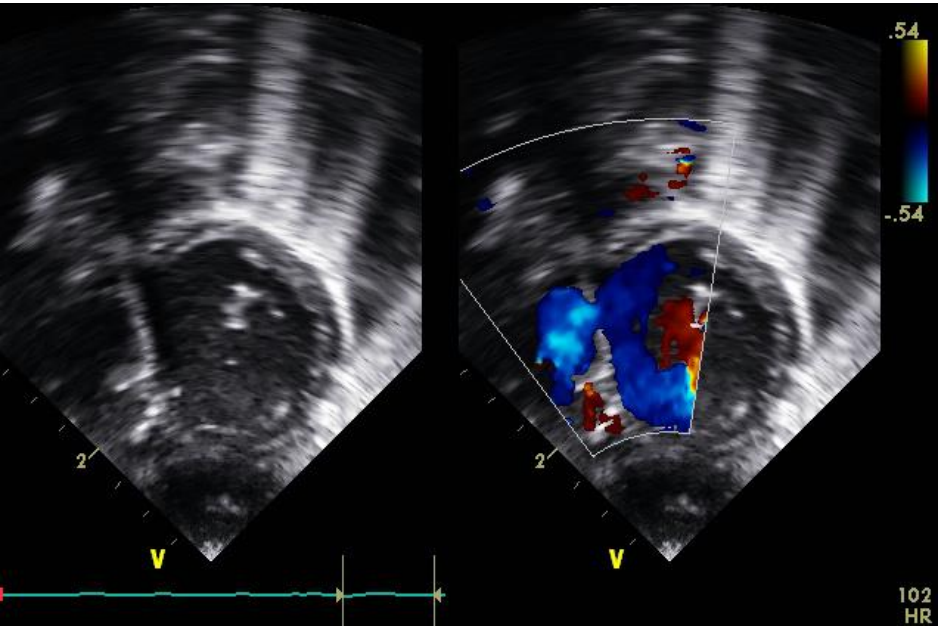
.54
-.54
2
V
2
V
102
HR

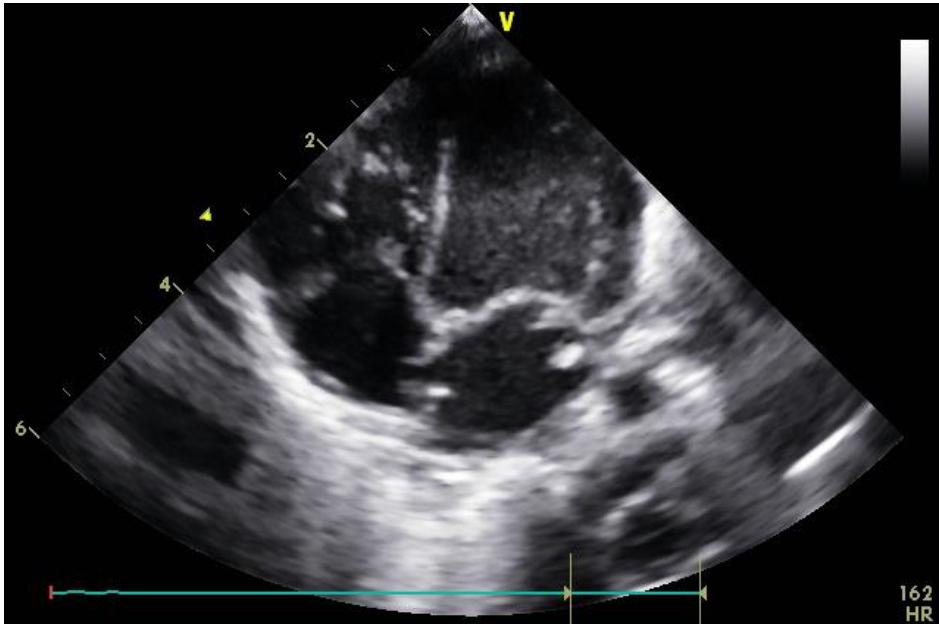
V
2
4
6
162
HR

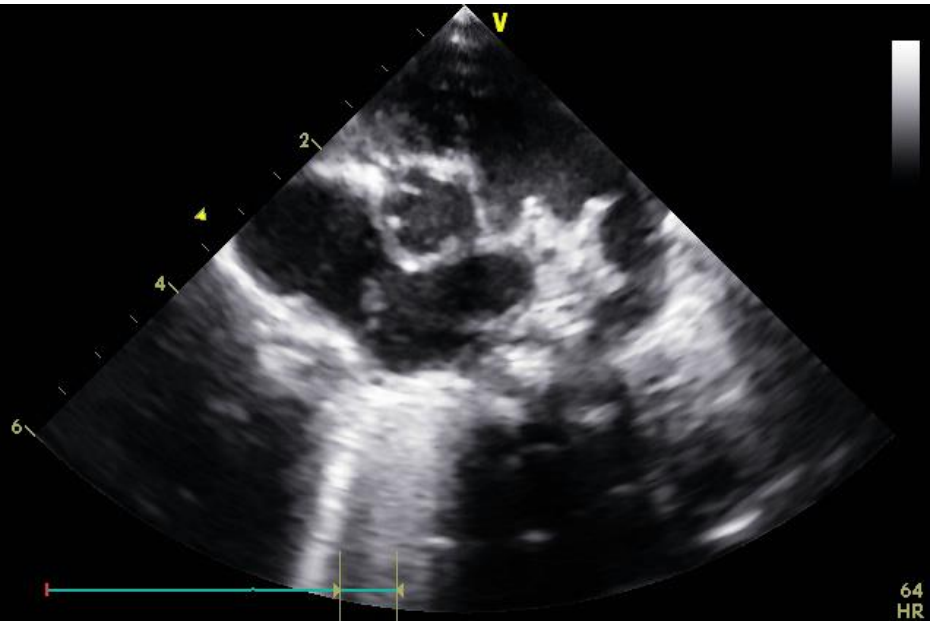
V
2
4
6
64
HR

FERMETURE DE LA CIA?

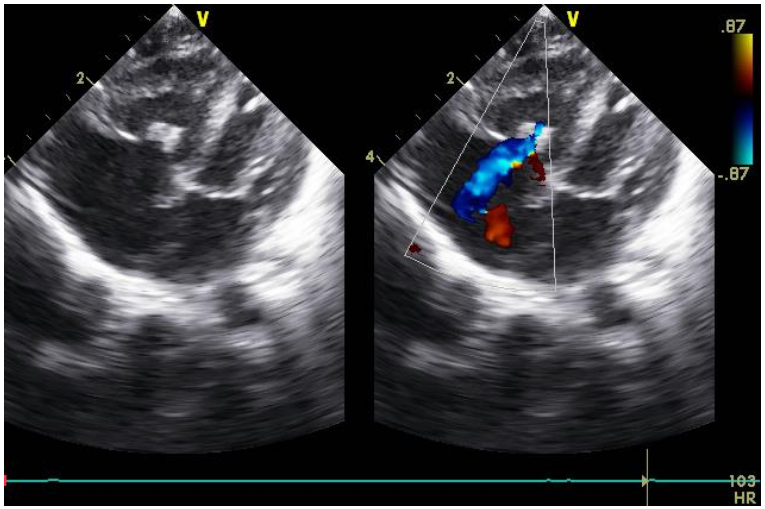

Naissance:

Dilatation

+

blalock

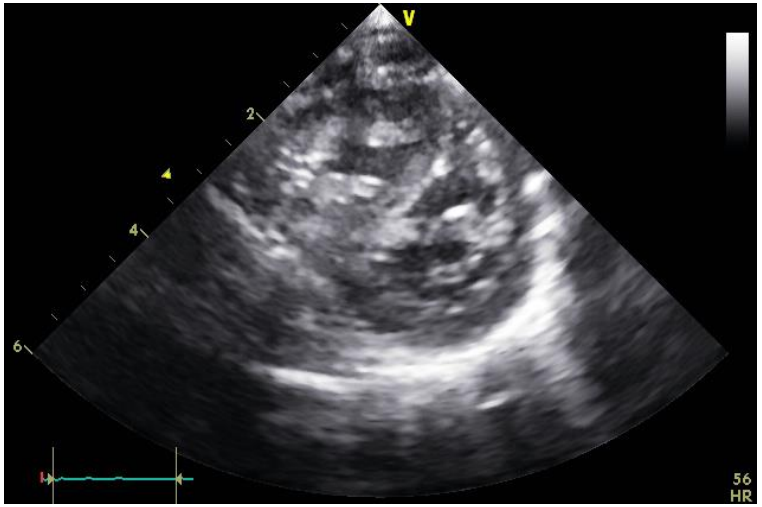

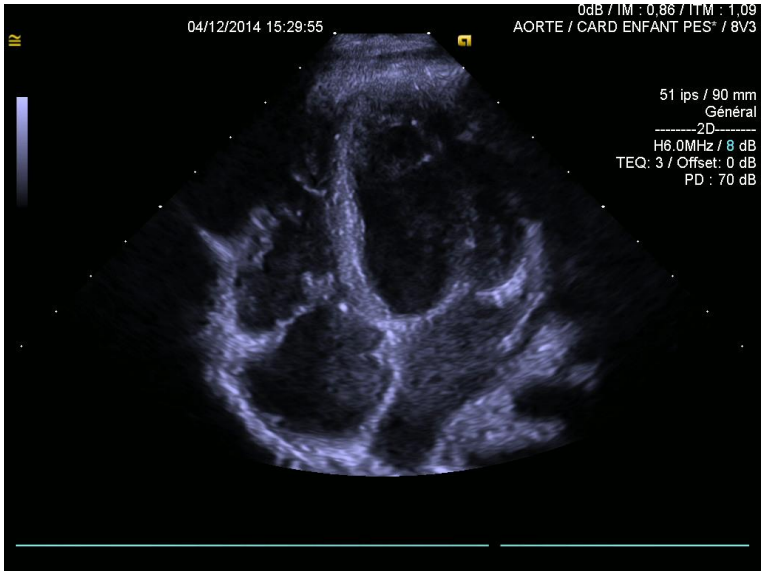

1 an ½

SpO2 99%

FOP G-D

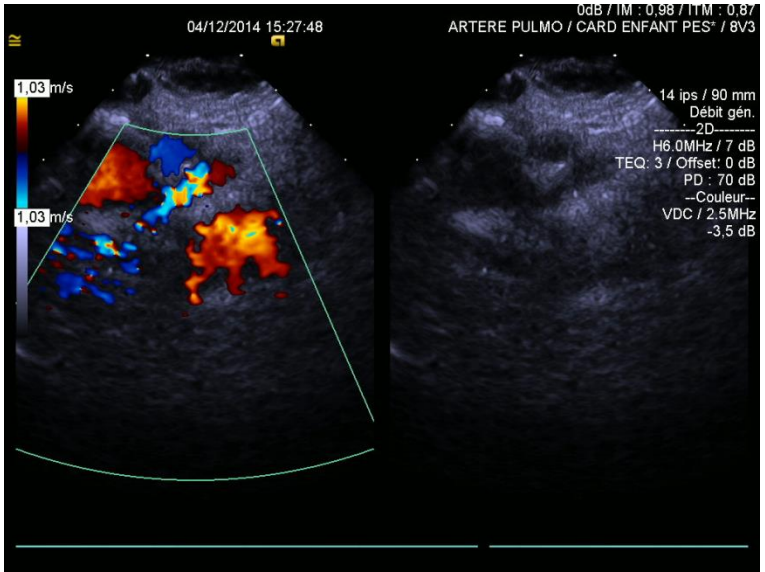

3. VD unipartite

- Blalock ou stenting canal
- Si CIA restrictive: Rashkind
- DCPP puis DCPT

Circulation VD-dépendante

- Contre-indication à la décompression du VD

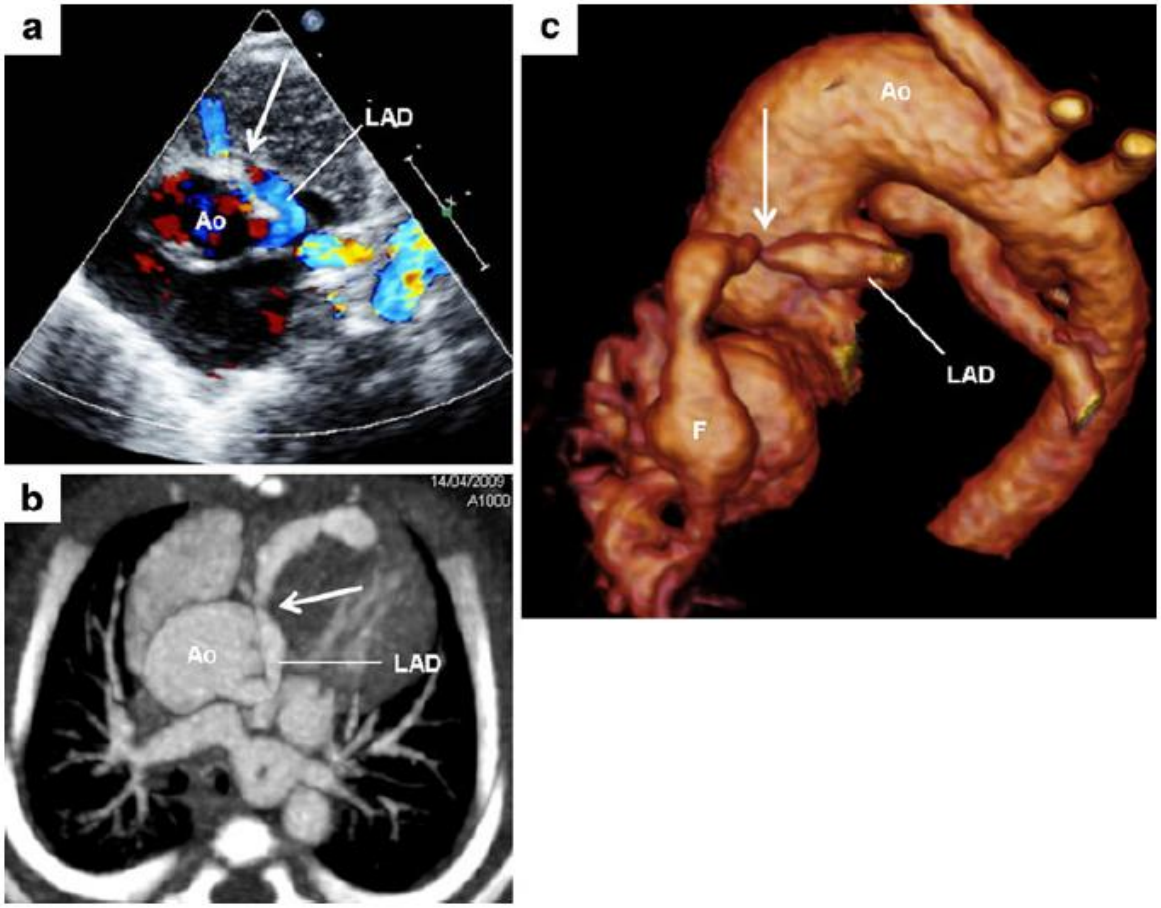

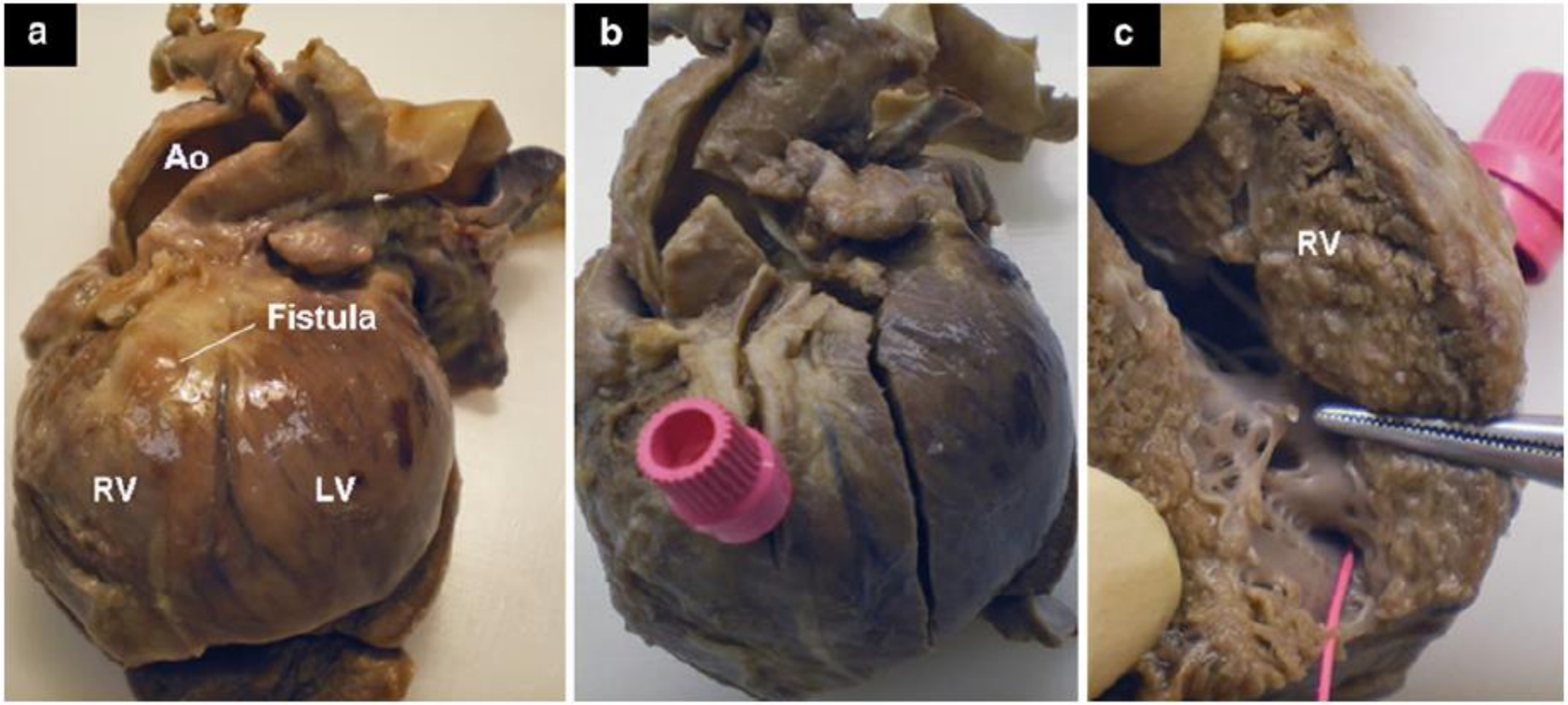
a
Ao
Fistula
RV
LV
b
c
RV

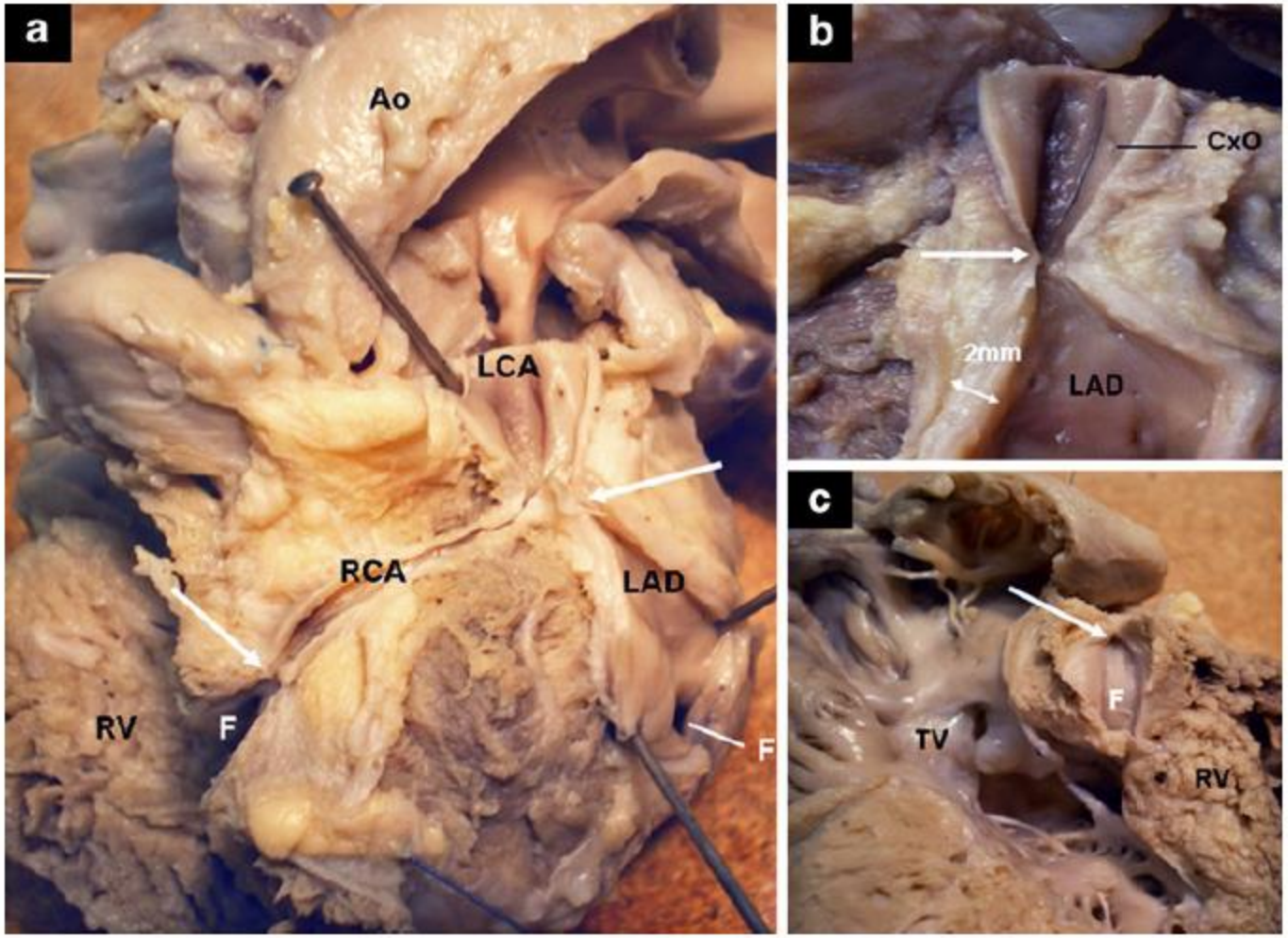
a
Ao
LCA
RCA
LAD
RV
F
F
b
CxO
2mm
LAD
c
F
TV
RV

APSI: Conclusion

- Evaluation ETT primordiale (TDM si nécessaire)
- Choix uni/bi-ventriculaire = VD
- Pronostic = sinusoïdes