Troubles du rythme et de conduction en réanimation pédiatrique

Pierre Bordachar, Jean-Benoit Thambo

Rémi Chauvel

Pessac, France

Anatomie voies de conduction

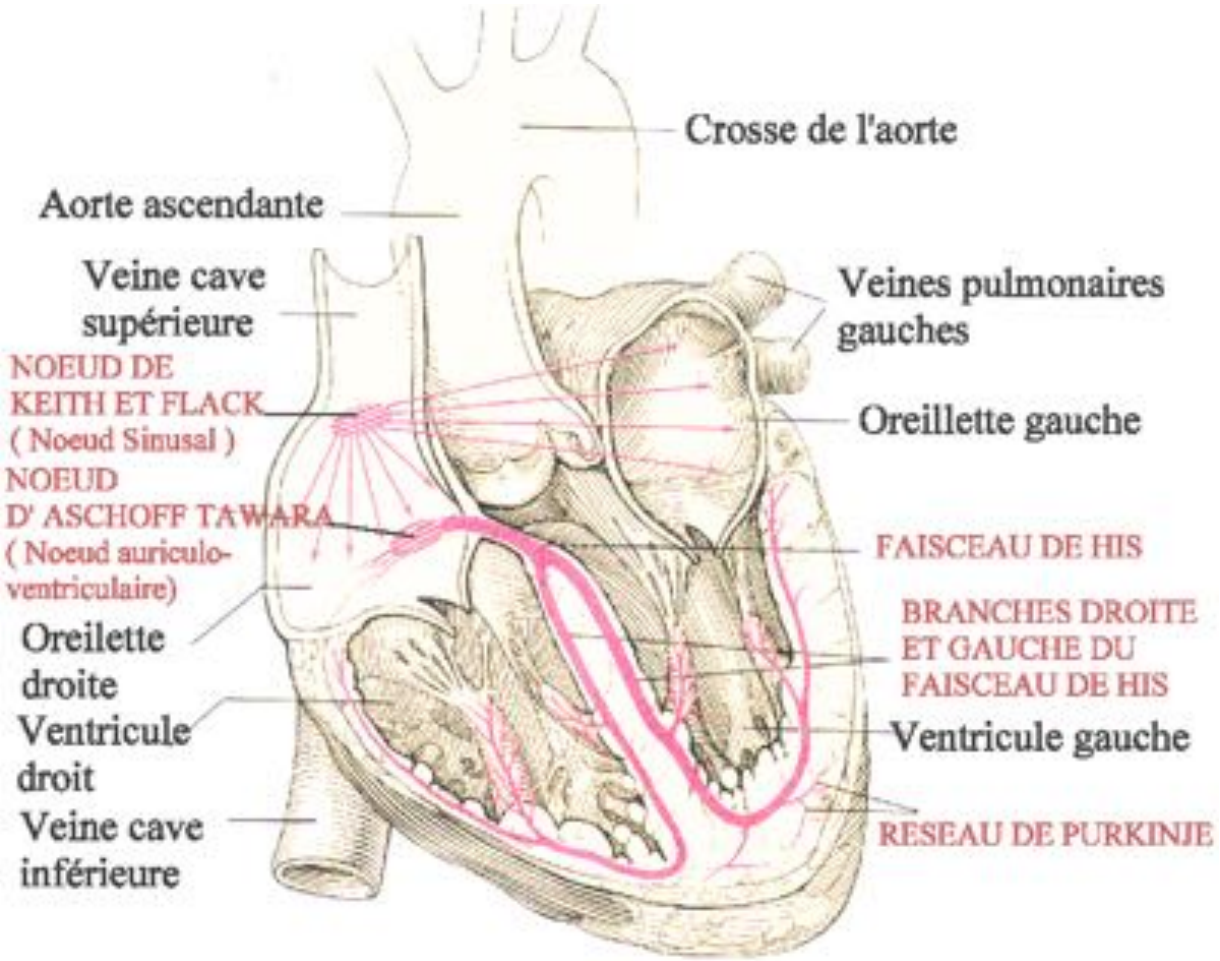

Anatomie voies de conduction

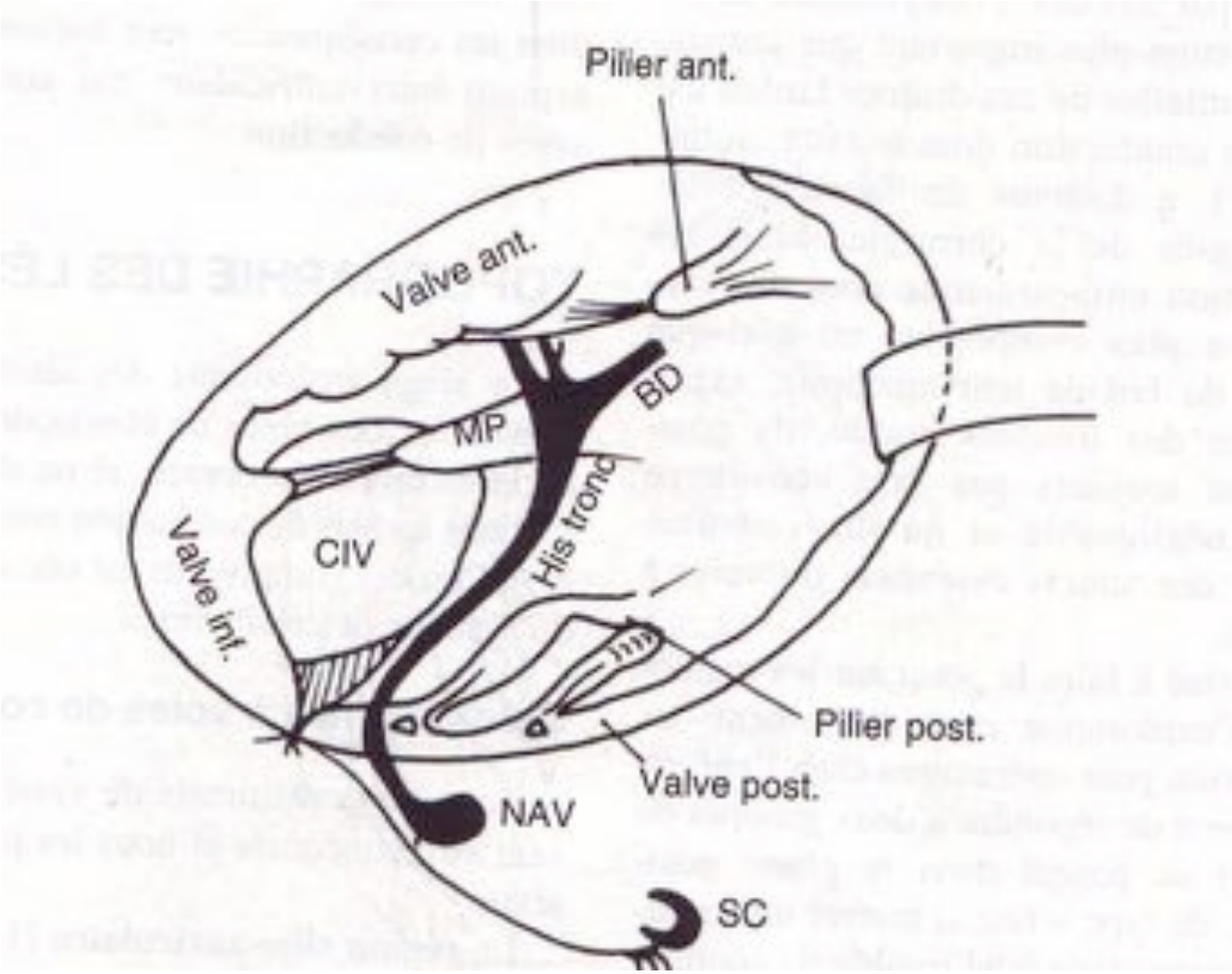

Jonction atrio-ventriculaire dans les doubles discordances

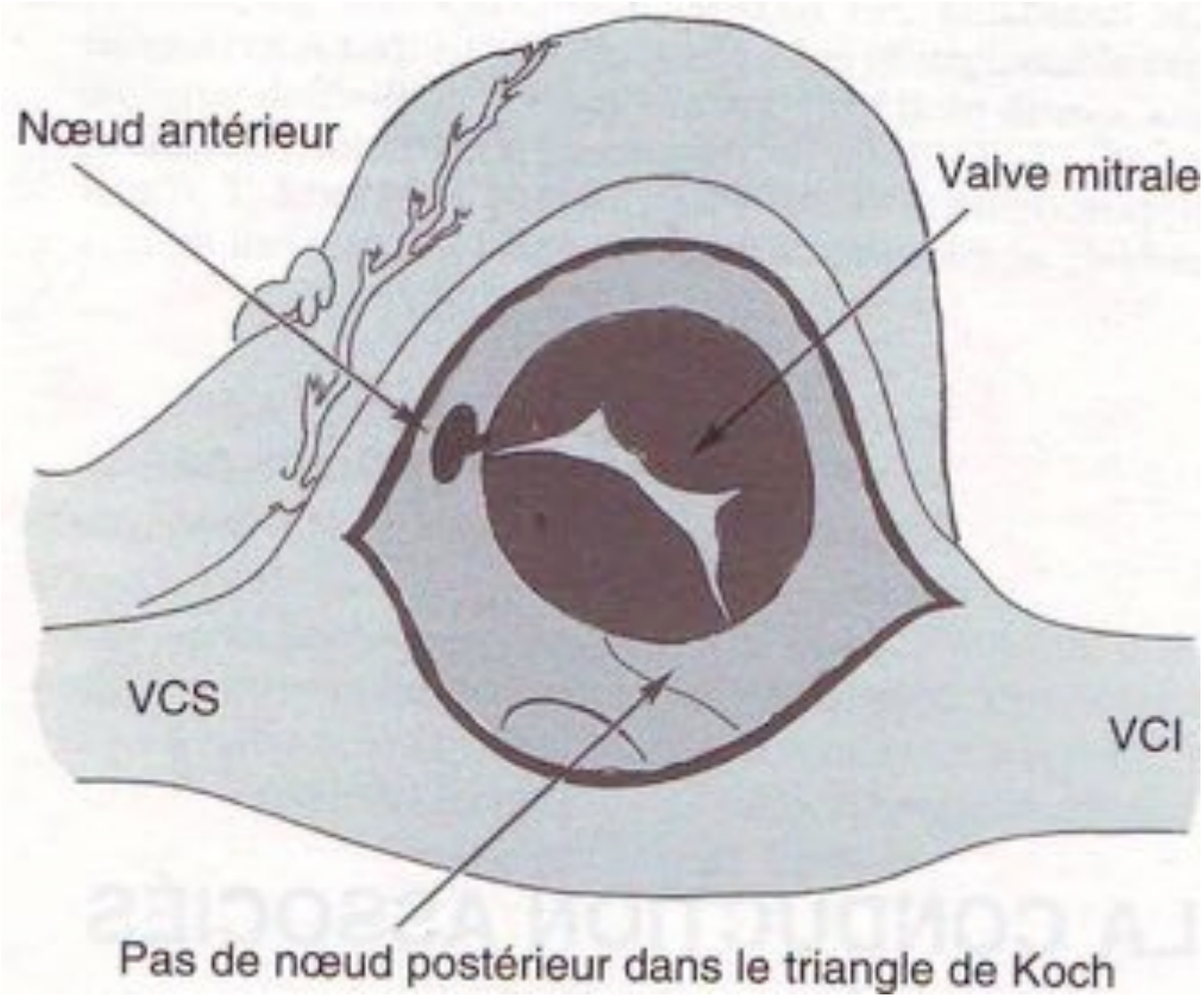

Lésion région sino-auriculaire

- Cible privilégiée des interventions portant directement sur l'oreillette
- Lésion directe du nœud sinusal
- Lésion artère du nœud sinusal
- Contexte chirurgical (hypoxie, hypothermie…)

Lésion région sino-auriculaire
Aspect ECG

Dysfonction sinusale, échappement jonctionnel

Pause sinusale: absence d’onde P

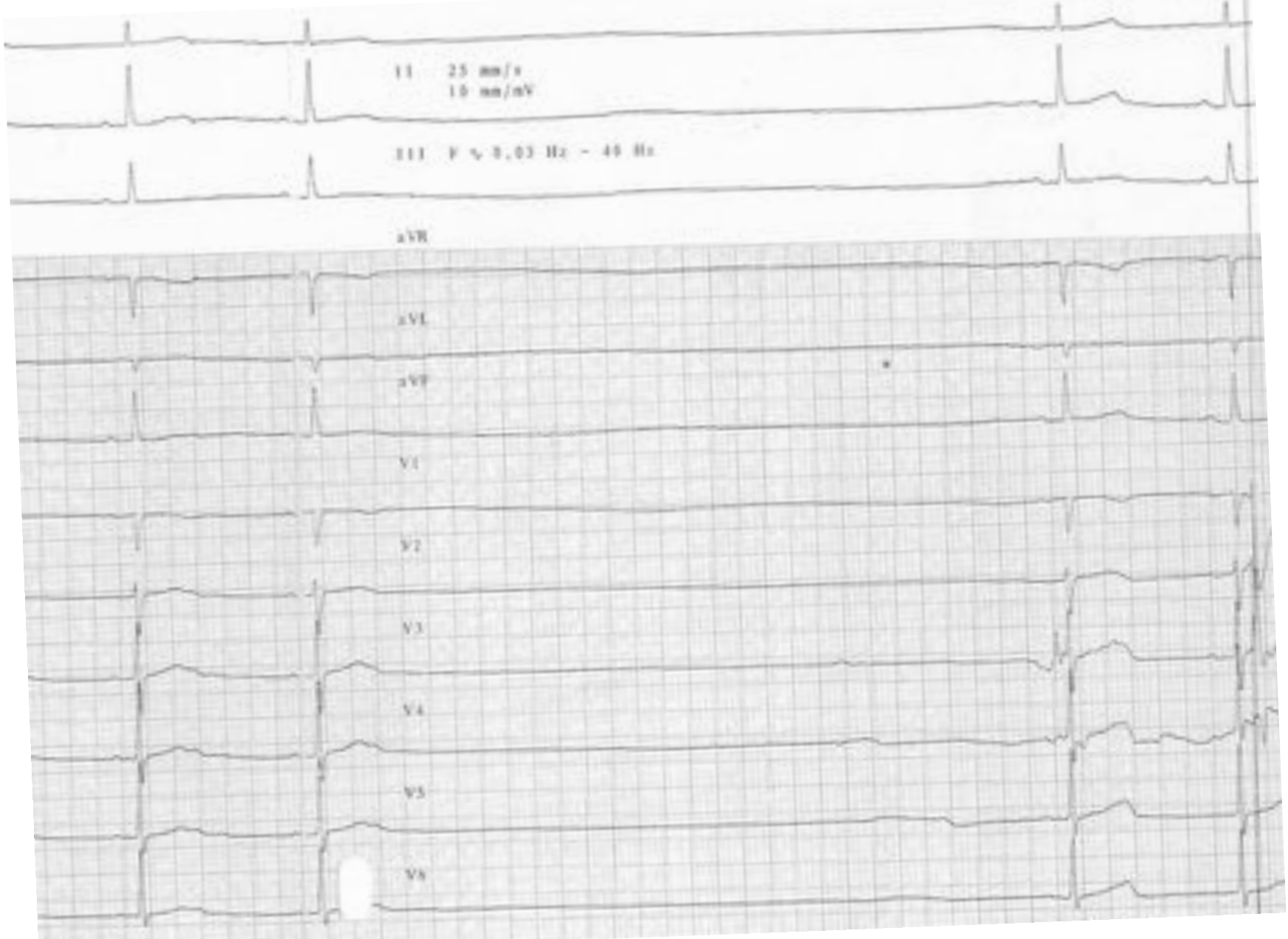

Lésion région sino-auriculaire
Evolution et traitement

Evolution le plus souvent favorable

Indications rarissimes implantation définitive

Lésion du nœud auriculo-ventriculaire

- Fréquent
- Le plus souvent transitoire
- Sensible à l'attrition locorégionale et à l'étirement
- Amélioration sous Atropine

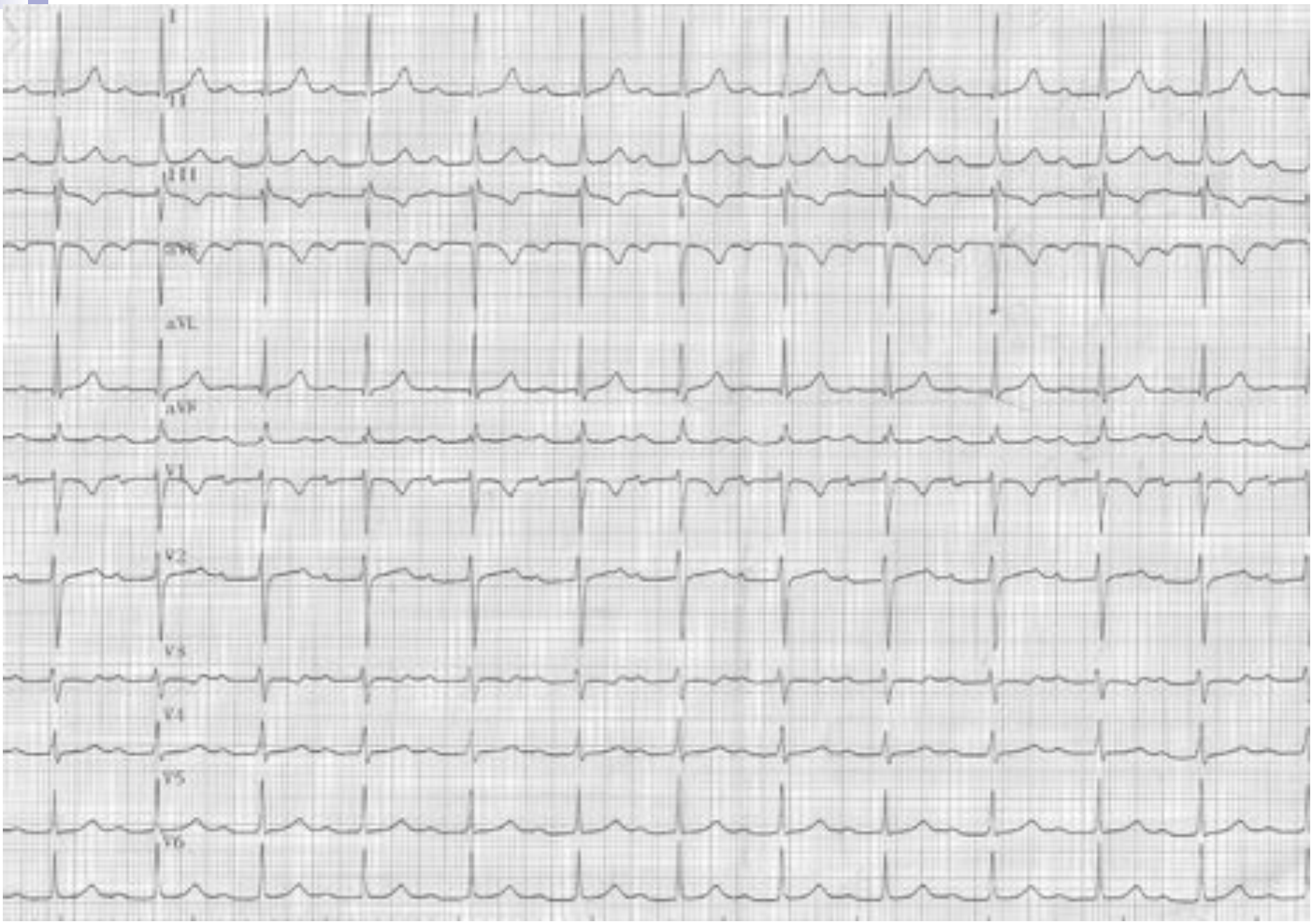
I
II
III
aVR
aVL
aVF
V1
V2
V3
V4
V5
V6

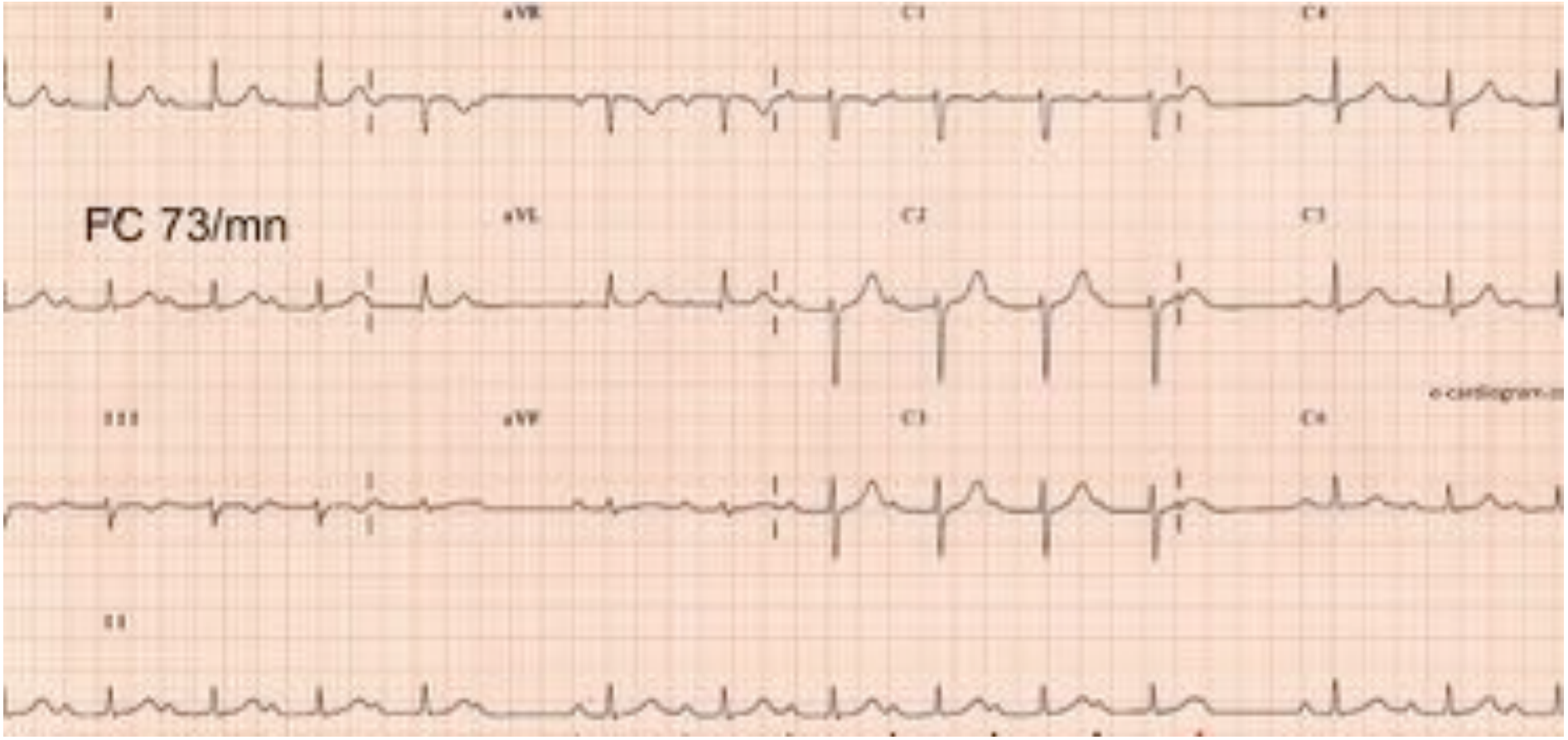
FC 73/mn

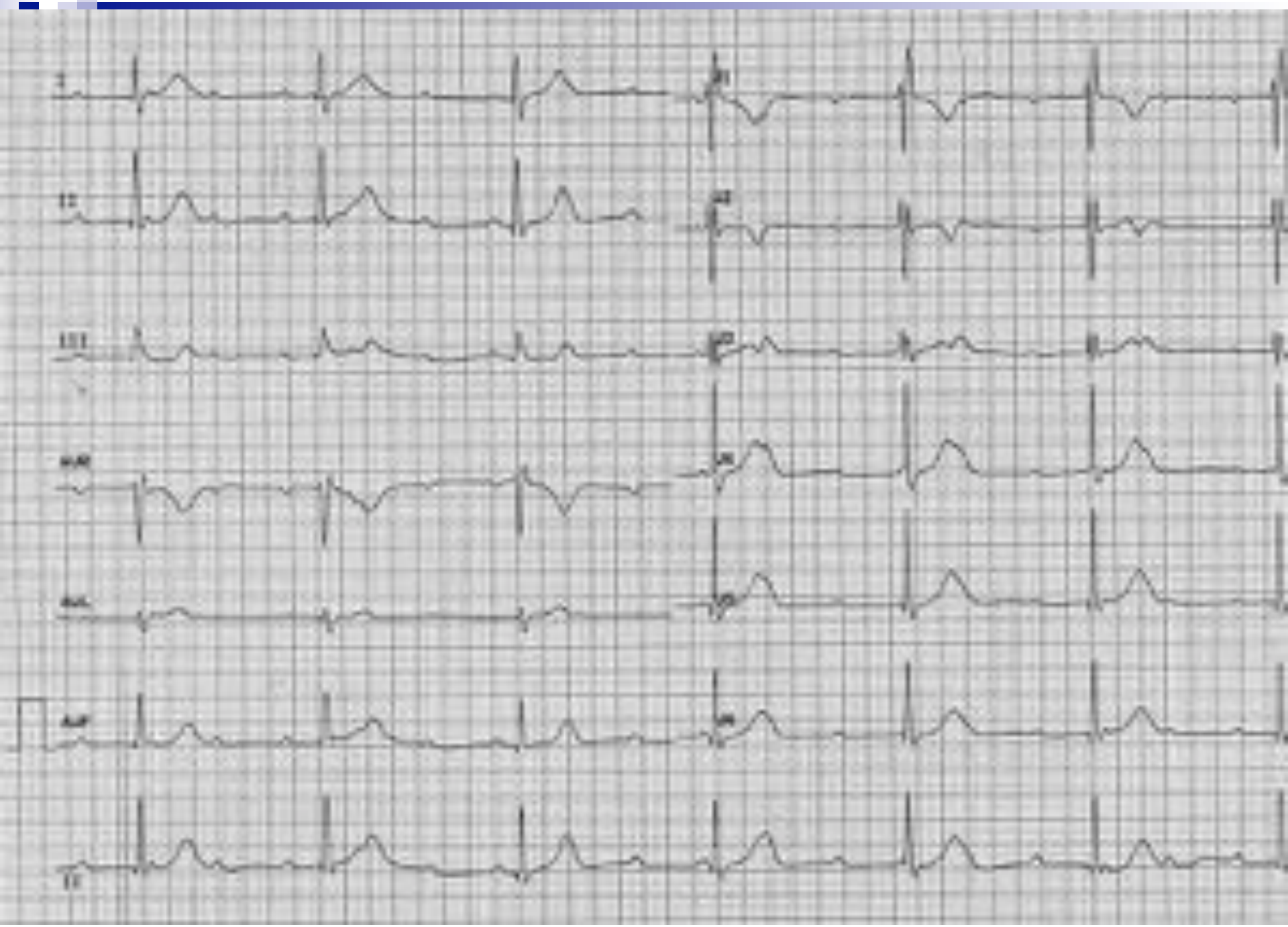

Lésion du nœud auriculo-ventriculaire
Evolution et traitement

Evolution le plus souvent favorable

Indications rarissimes implantation définitive
Attendre au minimum 10 jours
Intérêt exploration

Lésions du tronc et des branches du His

- Les plus graves
- His le plus souvent au bord inférieur CIV péri-membraneuses ou musculaires
- Localisation ectopique dans double discordance, cœurs univentriculaires, CAV

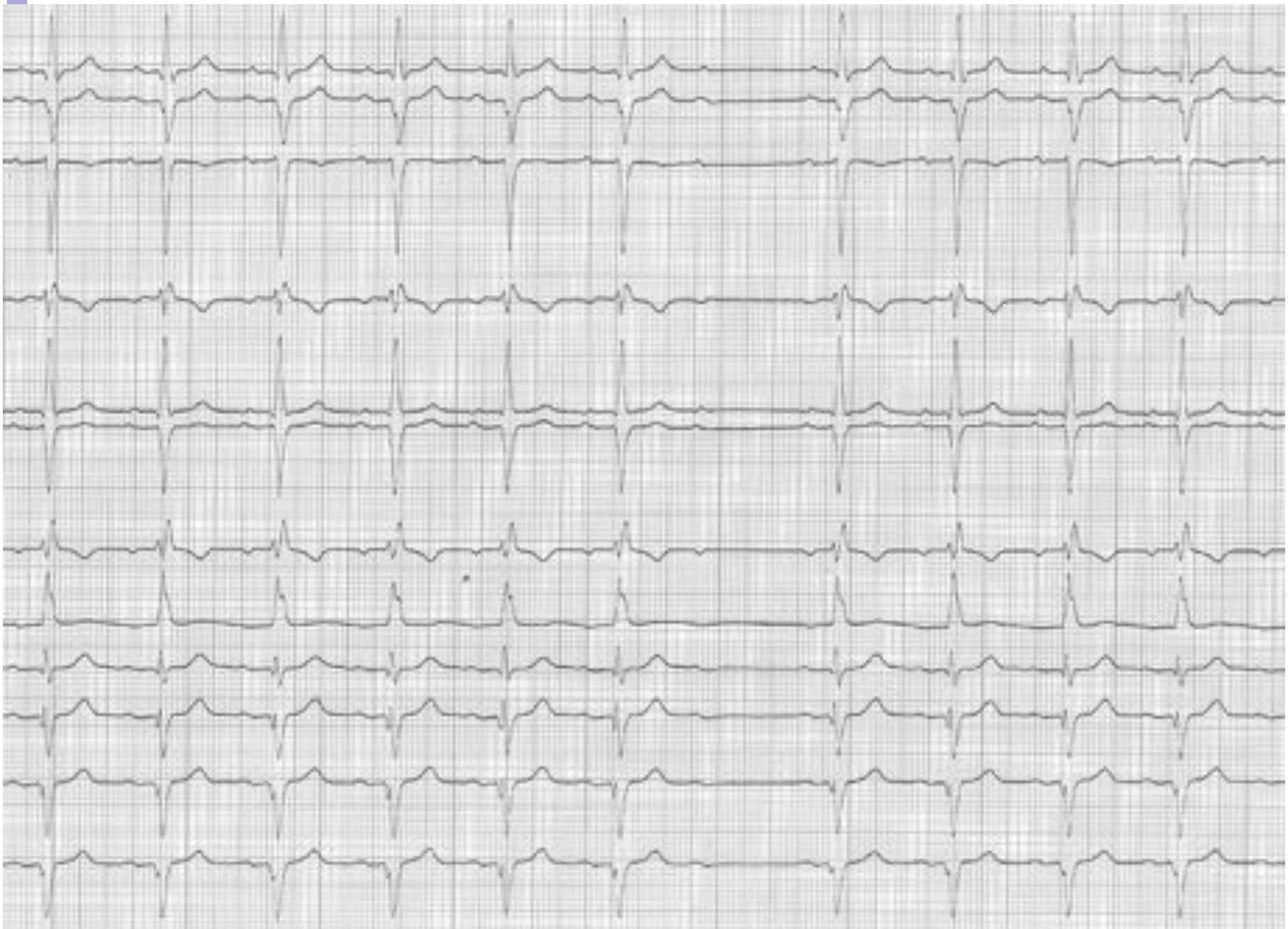

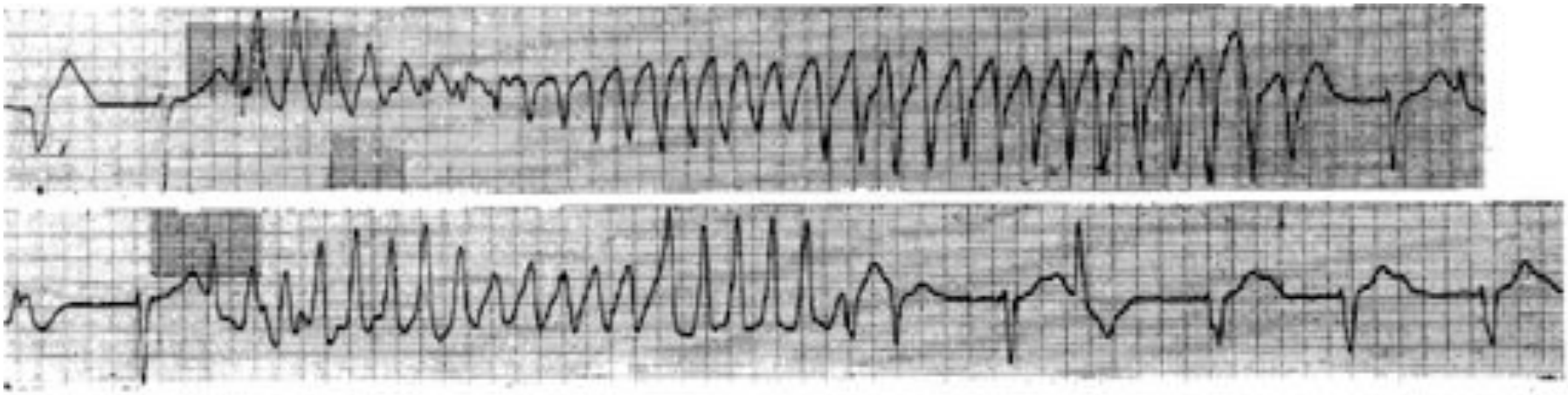

Lésions du tronc et des branches du His
Evolution et traitement

Evolution variable suivant l'origine

Attendre 10 jours avant implantation définitive
Facteurs péjoratifs:

- Rythme ventriculaire lent
- QRS larges
- Pauses prolongées avec symptômes

Troubles de conduction intraventriculaire

- Bloc de branche gauche complet: chirurgie de la voie d'éjection VG
- Habituellement non régressifs

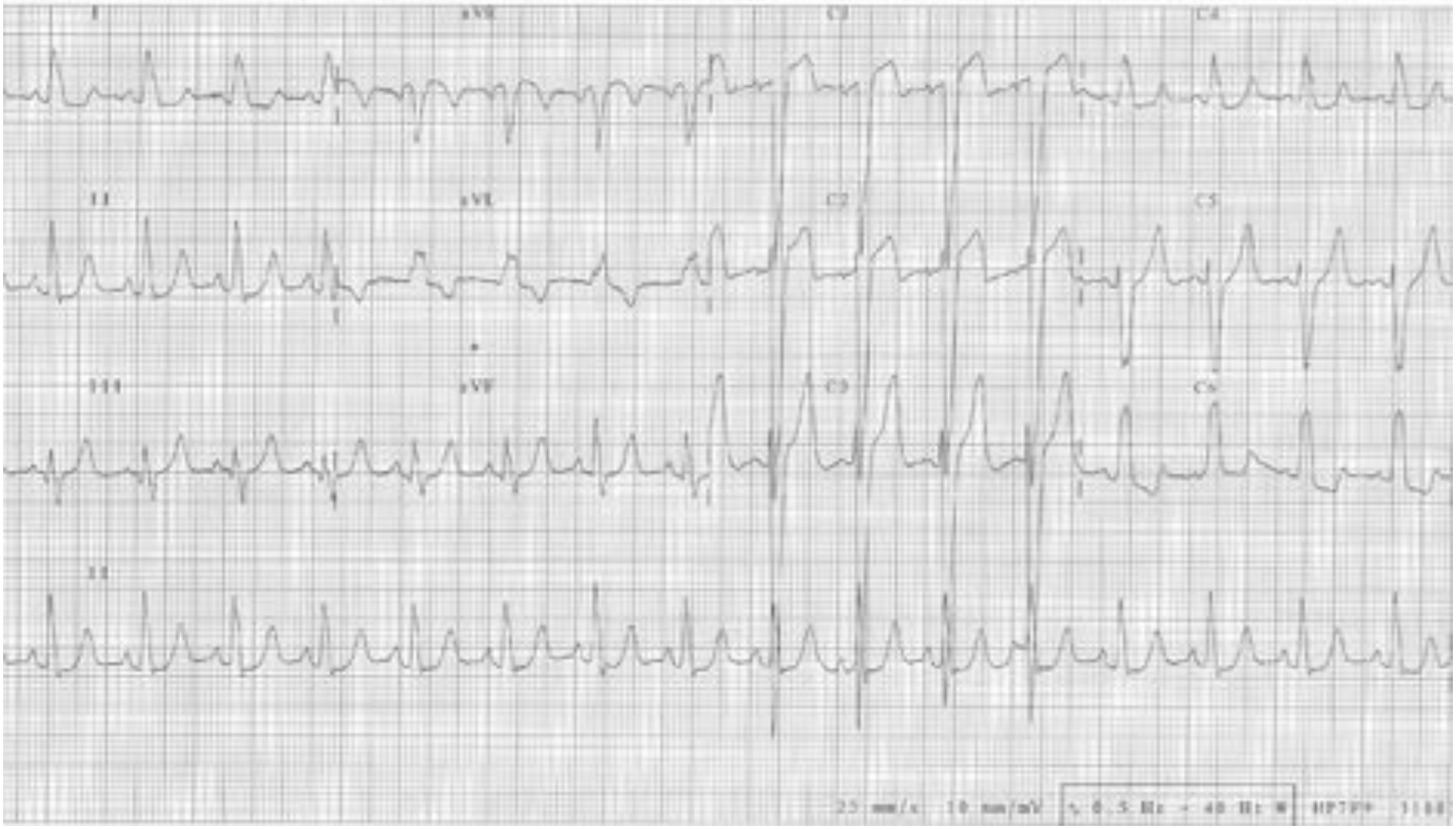
I
aVR
C1
C4
II
aVL
C2
C5
III
aVF
C3
C6
II
25 mm/s 10 mm/mV
0.5 Hz - 40 Hz W
HP7P9

Troubles de conduction intraventriculaire

- Peut être lié à une surcharge VD, fermeture d’une CIV,résection VD…

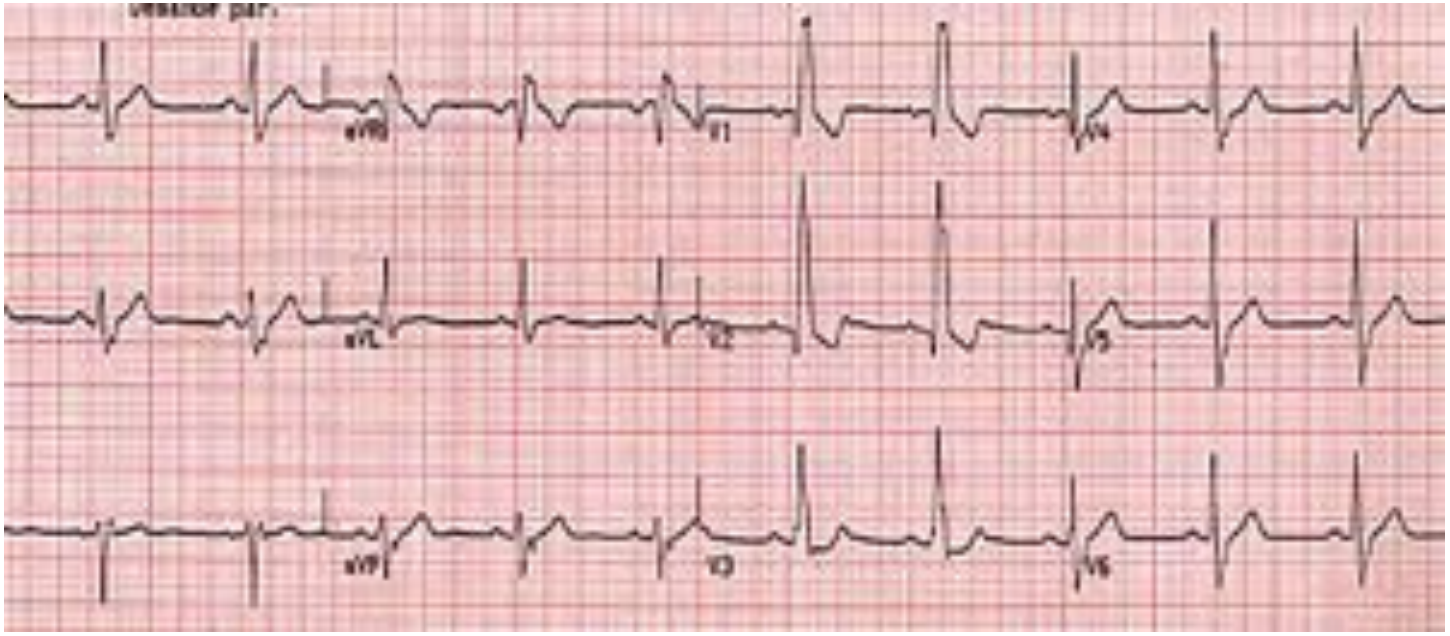

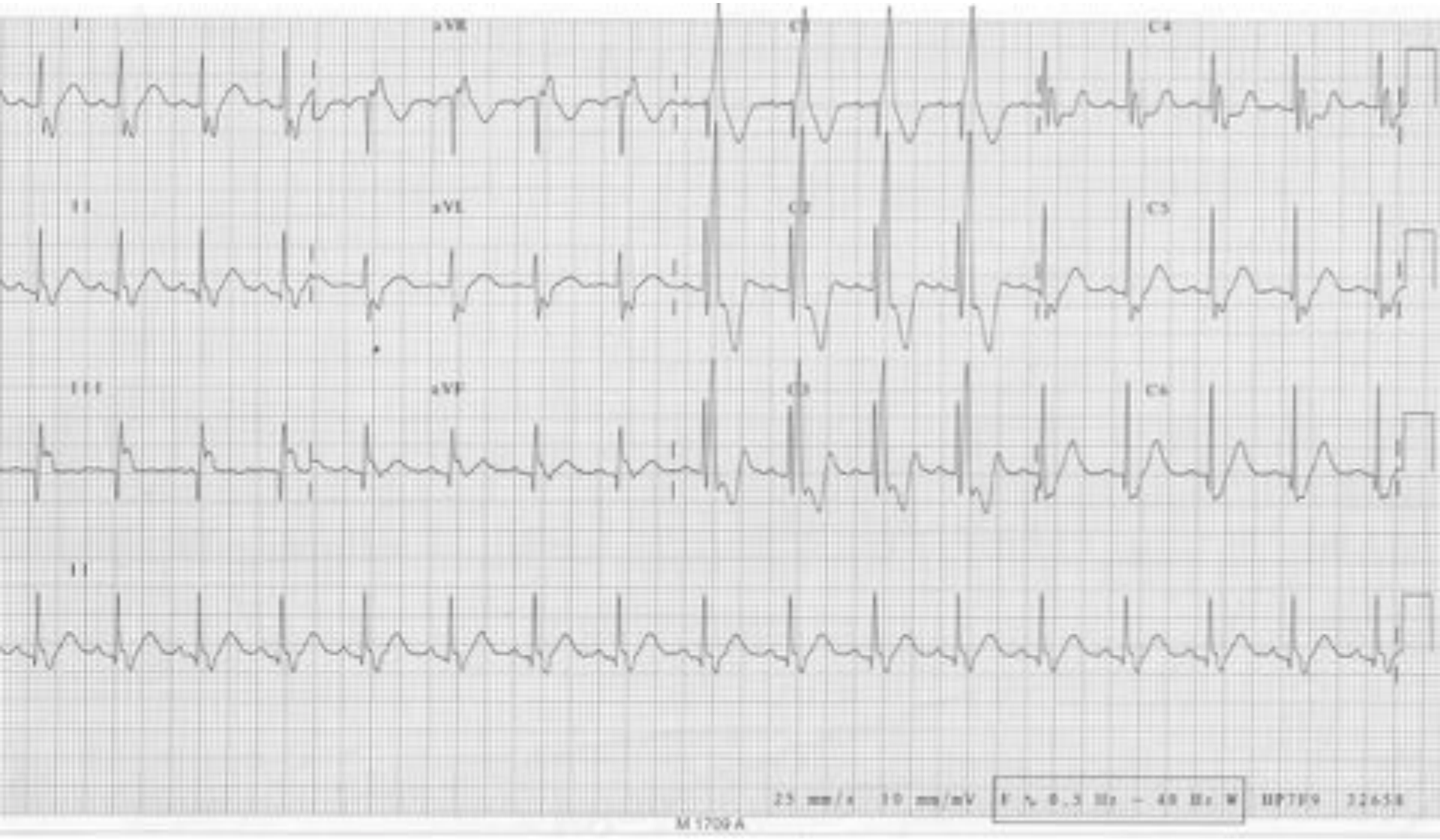
I
aVR
C1
C4
II
aVL
C2
C5
III
aVF
C3
C6
II
25 mm/s 10 mm/mV
F ∿ 0.5 Hz – 40 Hz M
M 1700 A

Indication pacemaker

- BAV complets persistant plus de 10 jours
- BAV complets intermittents avec symptomatologie type syncope après 10 jours
- BAV intermittent avec persistance Bloc de branche droit + hémibloc antérieur gauche

Pas d’indication pacemaker

- BAV transitoires de moins de 48 heures
- BAV transitoires < 10 jours avec QRS fins

Indication exploration électrophysiologique

- **Bloc dit trifasciculaire: bloc droit + hémibloc antérieur gauche + PR long**

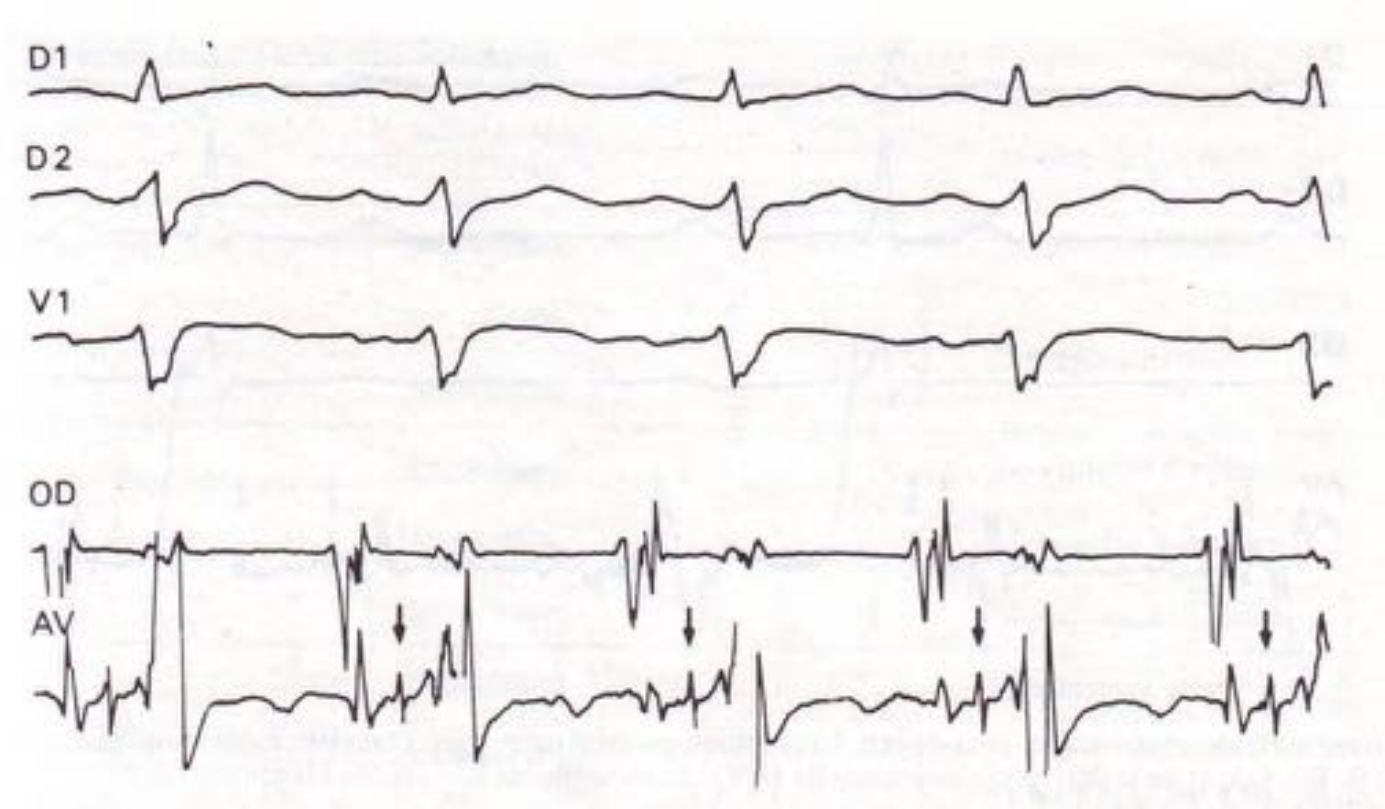

Le pacemaker externe

- S: stimulation: A, V, D, O
- D: détection: A, V, D, O
- F: fonction: I, T, D

Stimulation cardiaque définitive endocavitaire

Poids > 10 kg

Conditions anatomiques adéquates

Stimulation cardiaque définitive épicardique

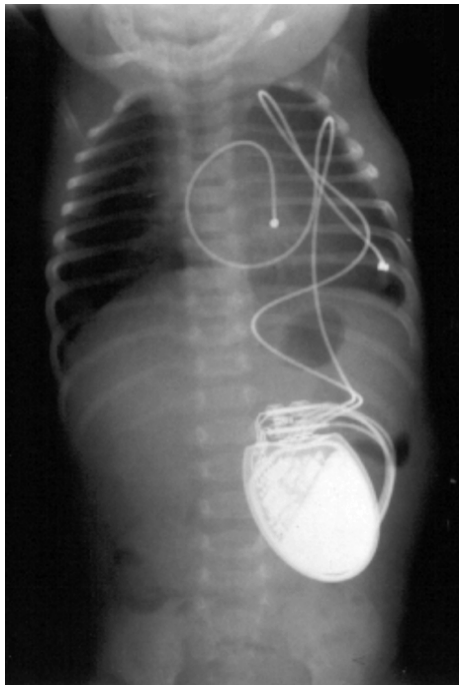

Poids < 10 kg

VU; cavo-pulmonaire totale;

Importance du site de stimulation

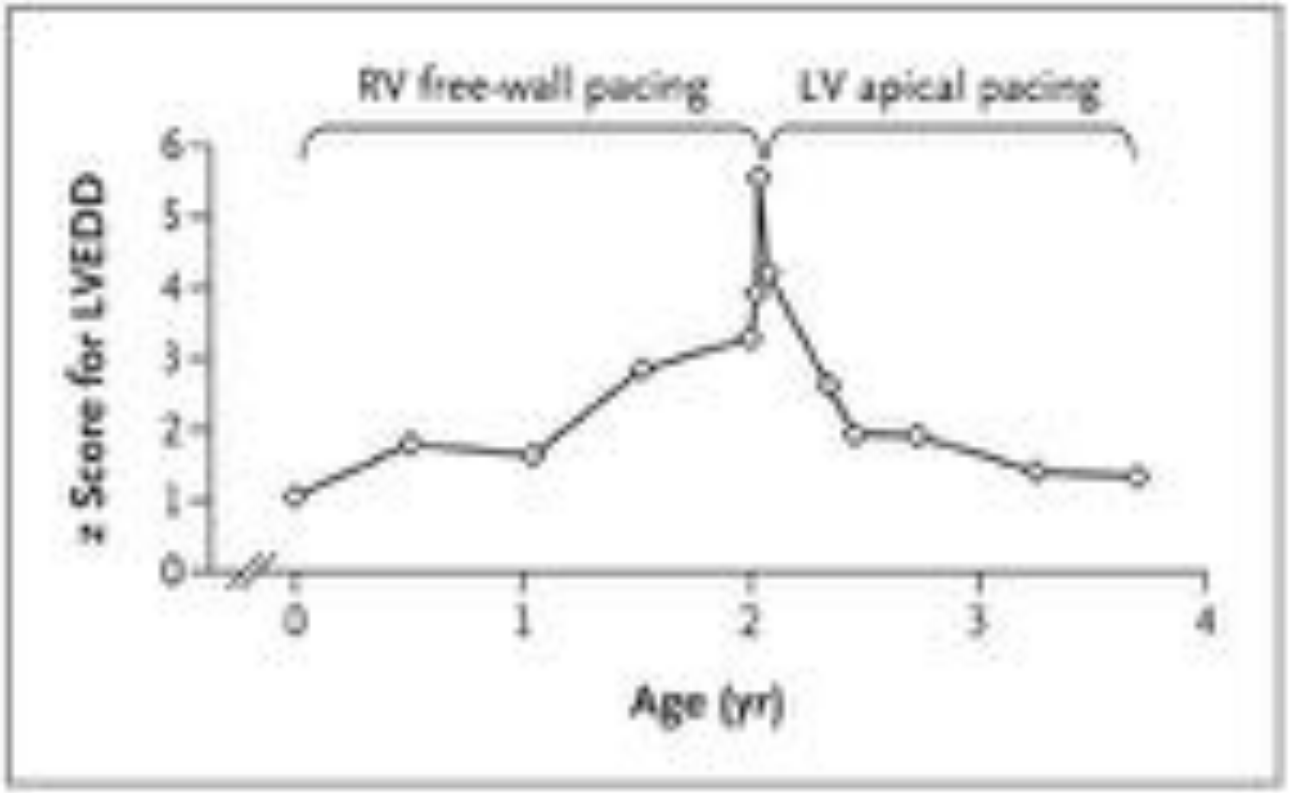

Prinzen F, New England J Med, 2008

Monsieur V. 16 ans

- Tétralogie de Fallot opérée à l'âge de 3 ans
- Symptomatique avec dyspnée stade III
- Bilan de contrôle

IRM pré-opératoire

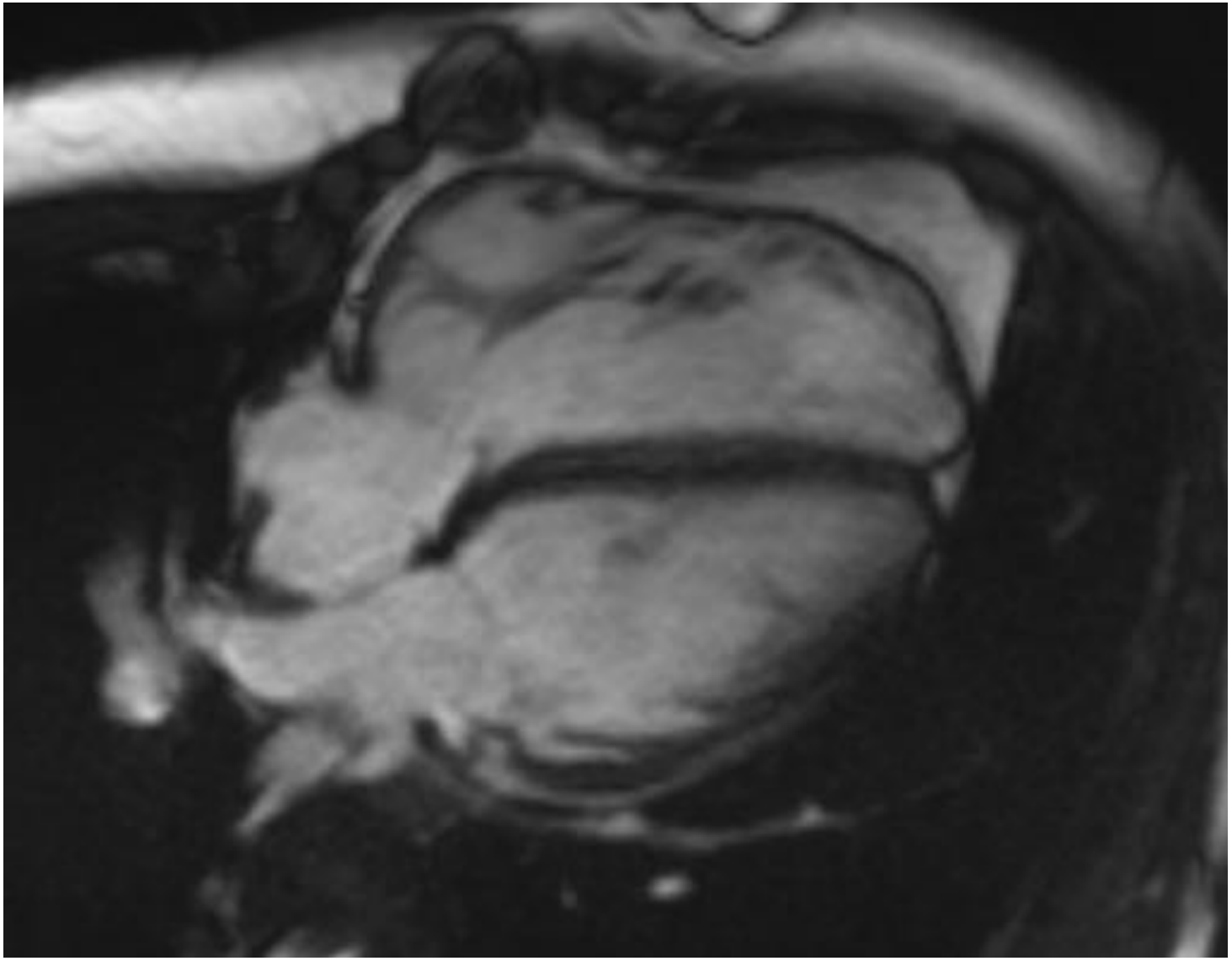

ECG pré-opératoire

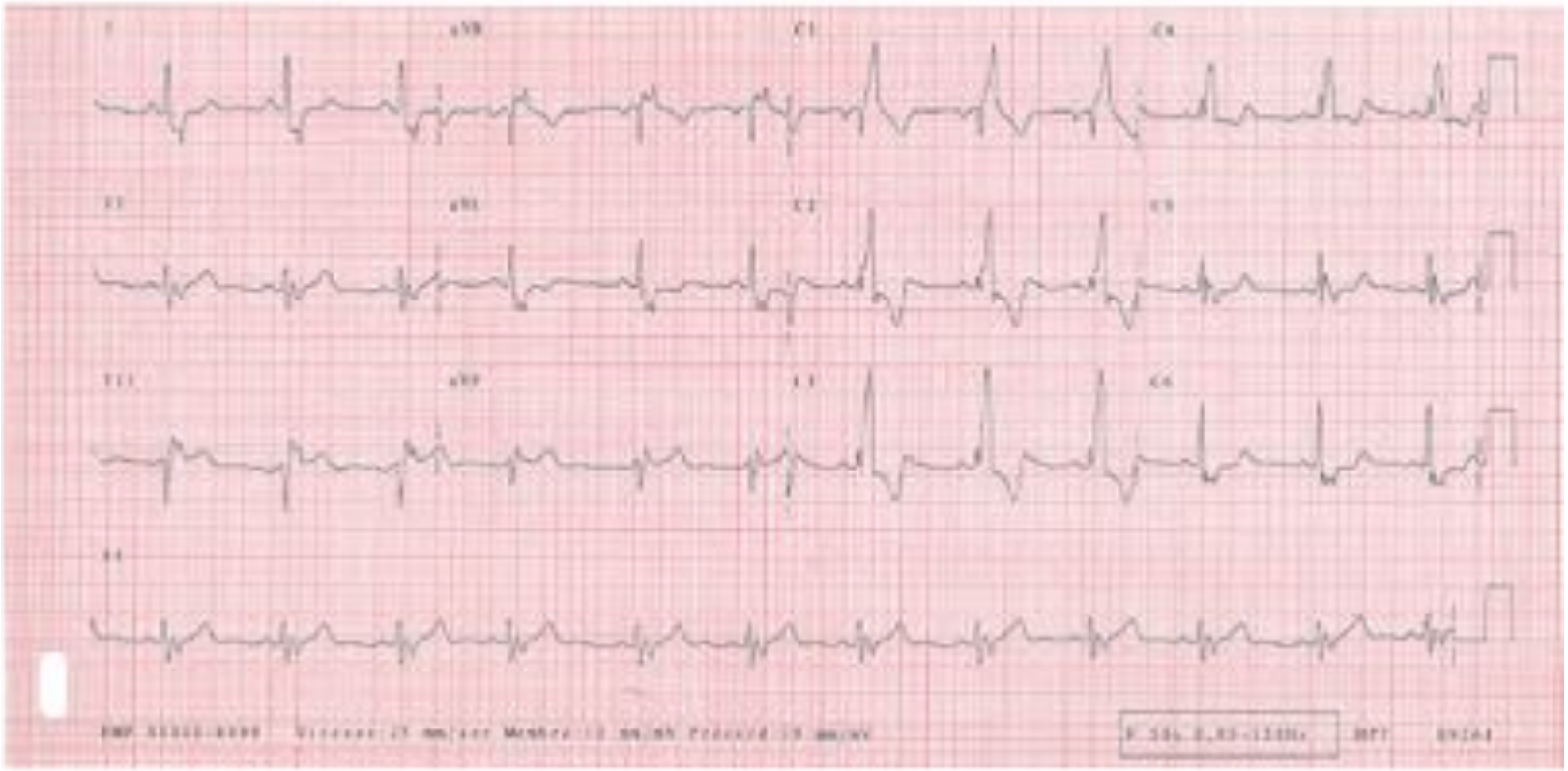

Cartographie non invasive

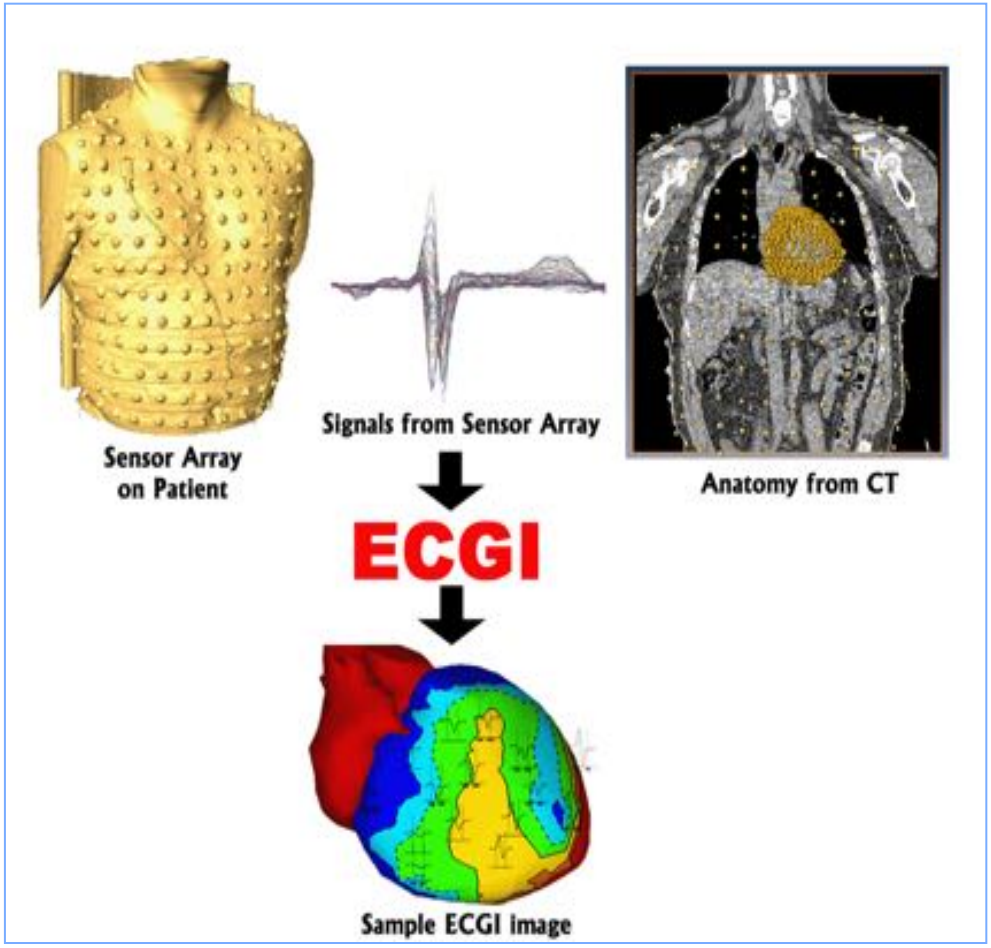

Cartographie non invasive

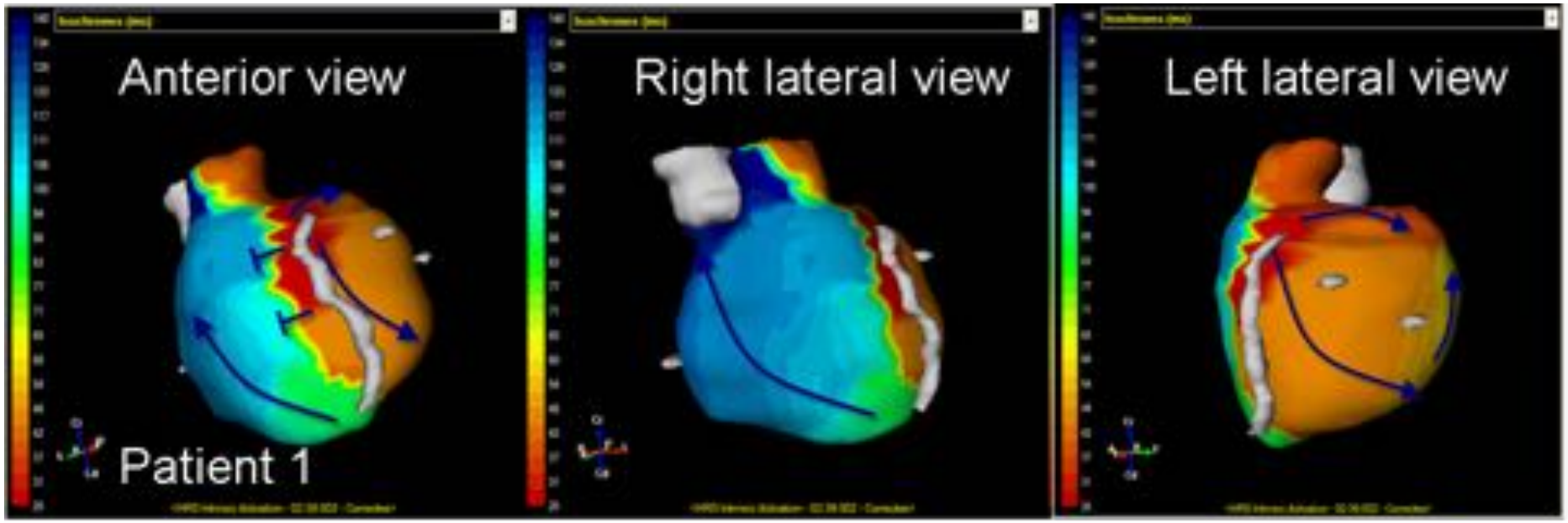

Chirurgie mars 2009

- Valvulation pulmonaire
- Pose d’un stimulateur triple chambre

Radio post-opératoire

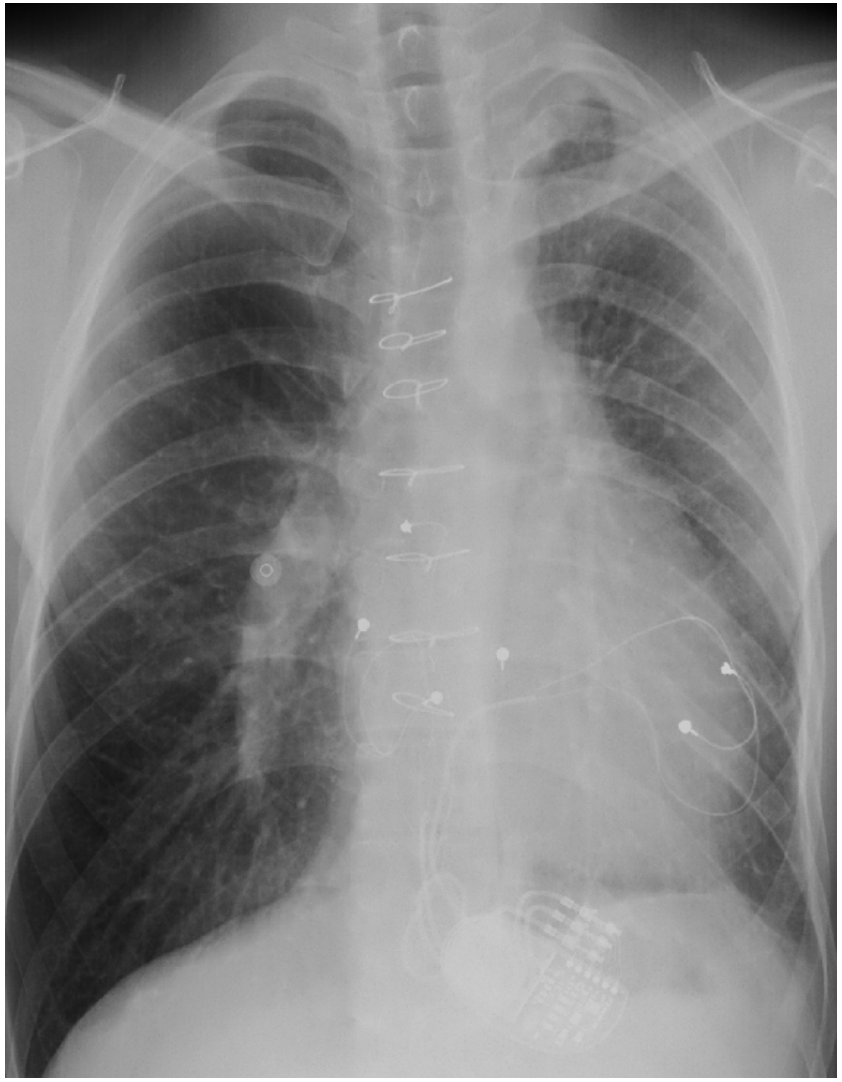

Echo post-opératoire

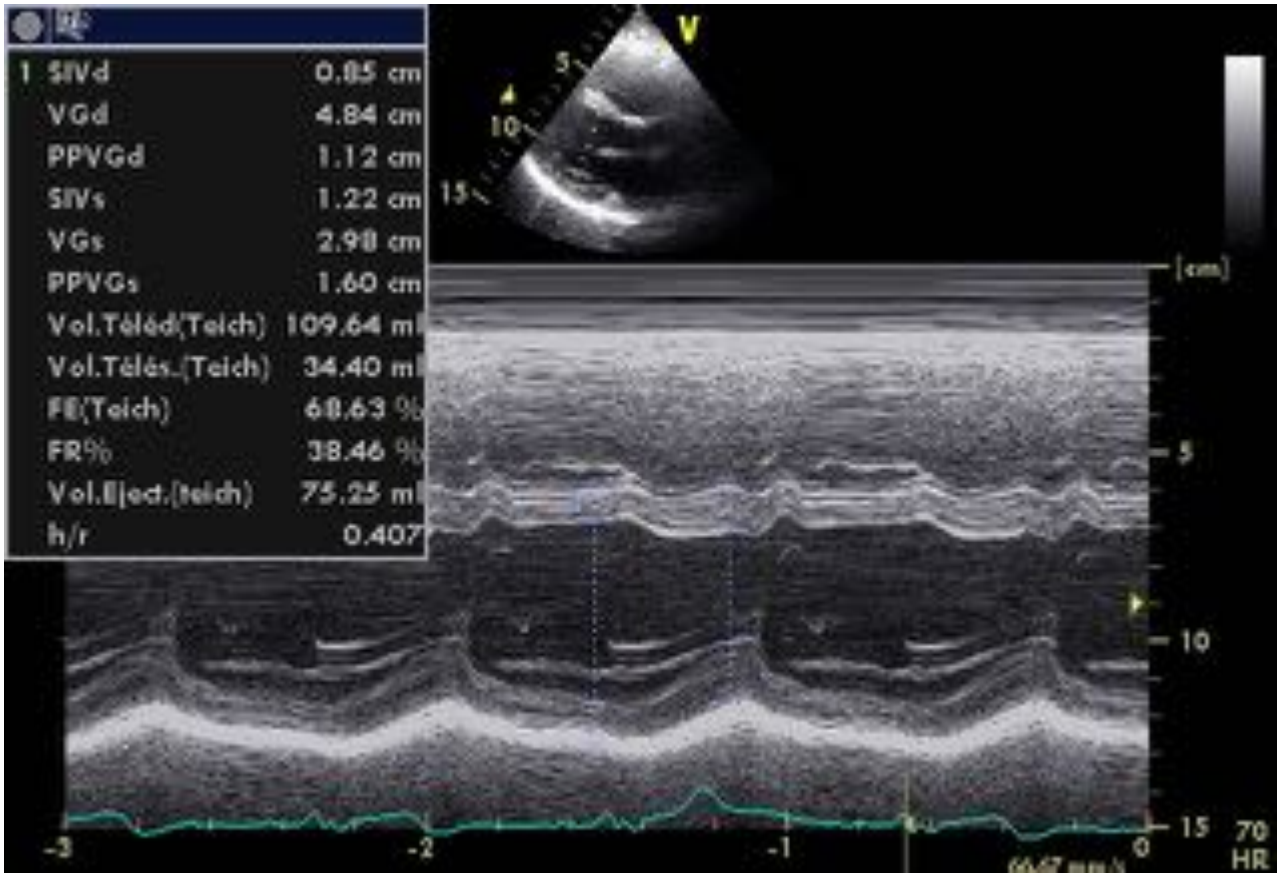

Cartographie non invasive

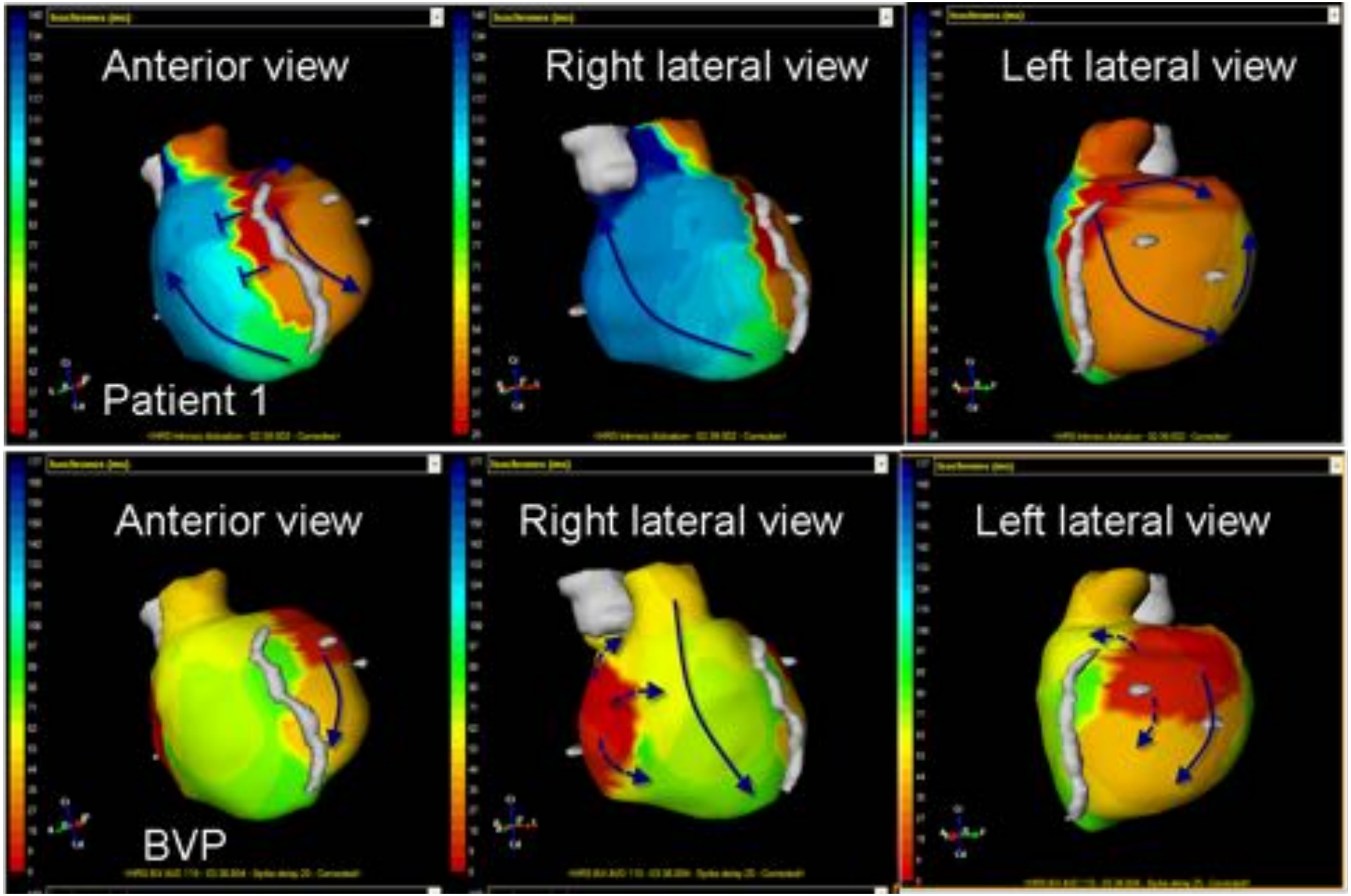

Troubles du rythme post-chirurgie

Prévalence élevée: 40% des cardiopathies congénitales opérées sous CEC

La réanimation est un univers arythmogène:

- Catécholamines
- Variations ioniques
- Hypovolémie

Troubles du rythme post-chirurgie

Sévérité condition hémodynamique pré-chirurgie

Lésions liées à l'acte opératoire

Séquelles hémodynamiques post-opératoires

Pour interpréter un trouble du rythme

- Il faut connaître :
  - La cardiopathie
  - L'état du myocarde
  - L'équilibre ionique : K, Ca ionisé, Mg
  - La balance acide base : pH
  - Troponine

Cardiopathies à risque de TSV

- Ebstein
- DCPT et Fontan
- Senning et Mustard
- RVPA
- Globalement la grosse chirurgie de l'oreillette

Troubles du rythme post-chirurgie
Tachycardies supra-ventriculaires

- Tachycardies sinusales

- Flutter auriculaire

- Tachycardies atriales

- Tachycardies jonctionnelles

- Tachycardies hissiennes

Tachycardie sinusale

Très fréquent en post-opératoire

Parfois diagnostic difficile

QRS fins

Début et fin progressifs

Hypovolémie, fièvre…

Tachycardie sinusale

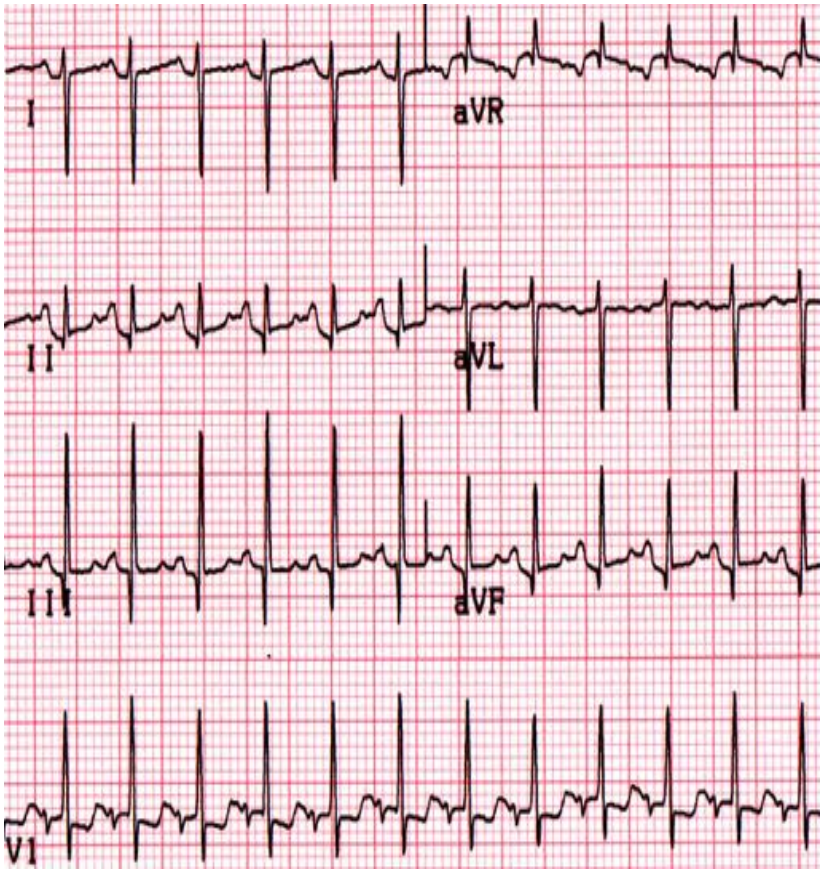

Traitement de la tachycardie sinusale

- Traiter la cause
- Si bien tolérée s’abstenir

Troubles du rythme post-chirurgie
Tachycardies supra-ventriculaires

Troubles du rythme post-chirurgie
Tachycardies supra-ventriculaires

Manœuvres vagales

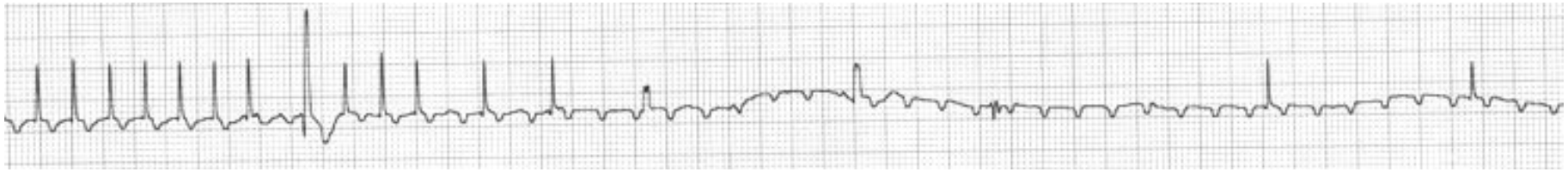

Tachycardie atriale

Flutter auriculaire

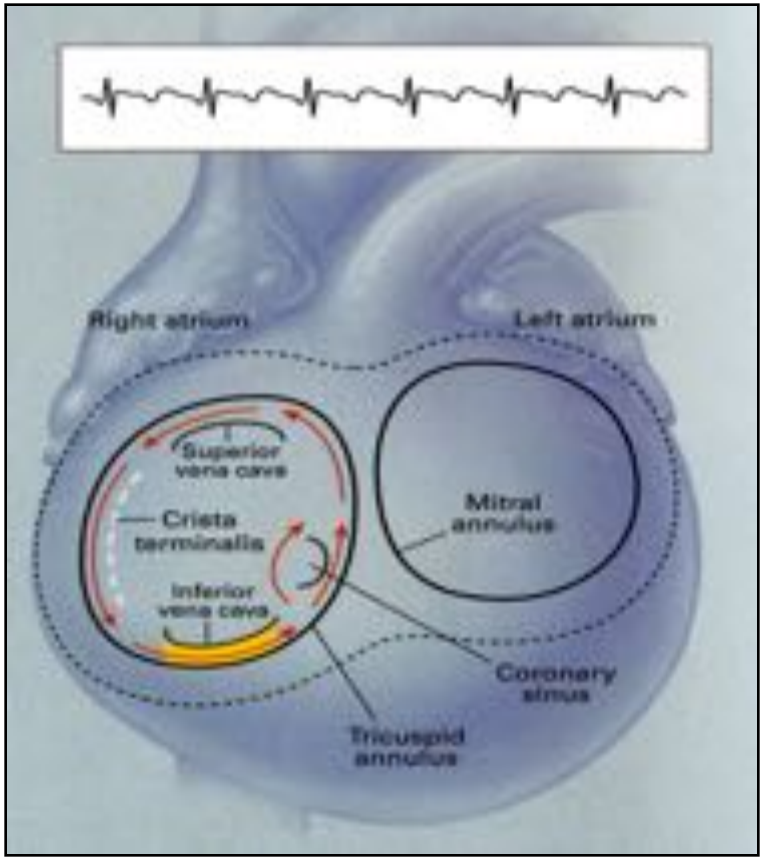

Flutter auriculaire

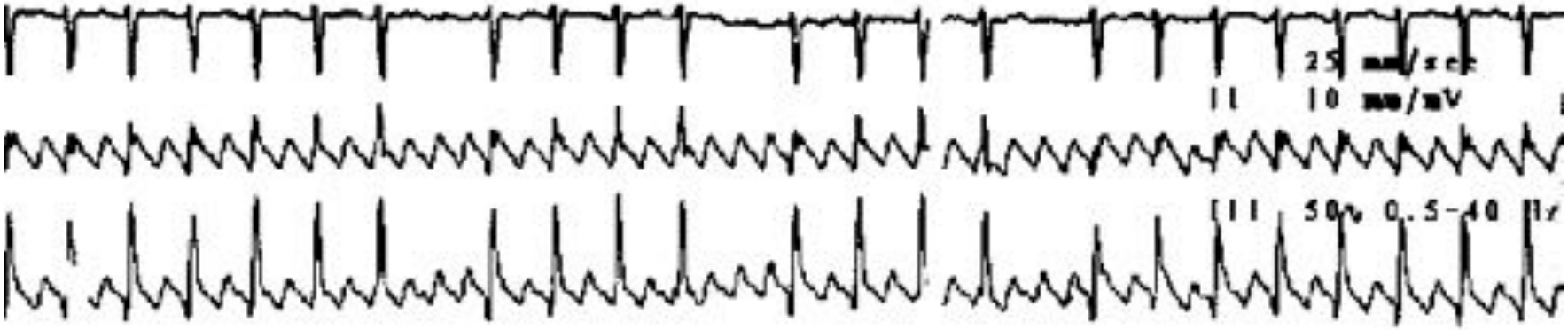

Stimulation rapide de l’OD

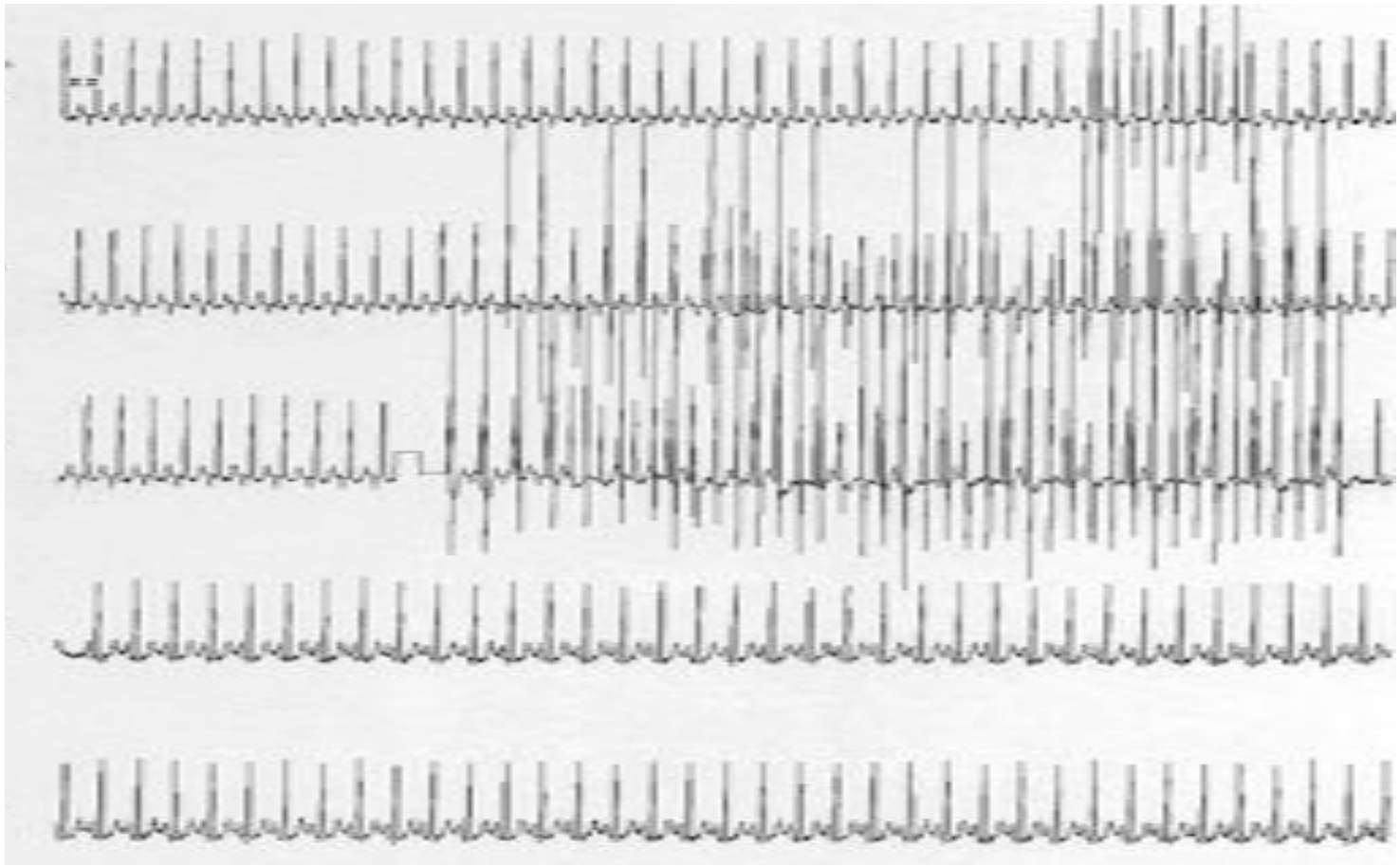

Stimulation œsophagienne

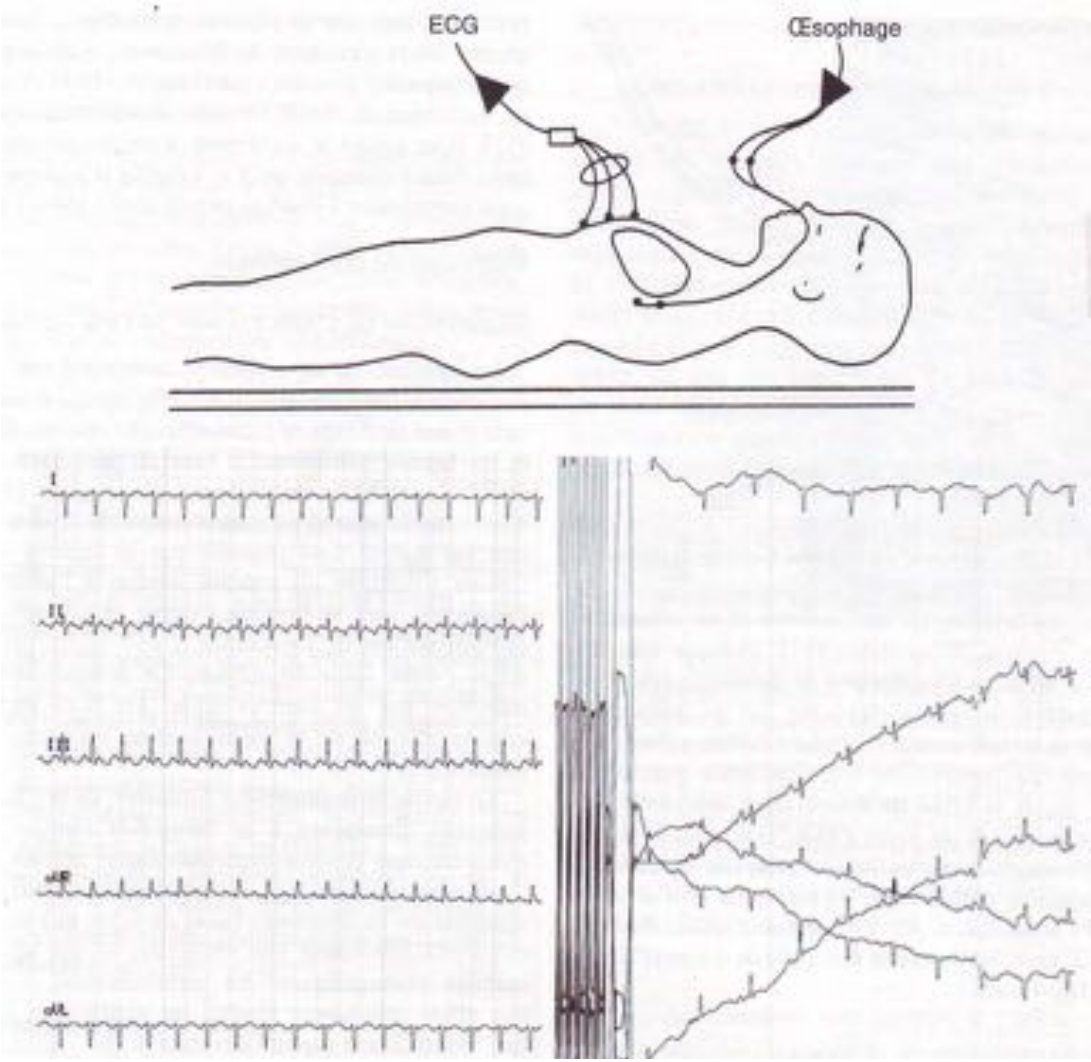

Tachycardie atriale

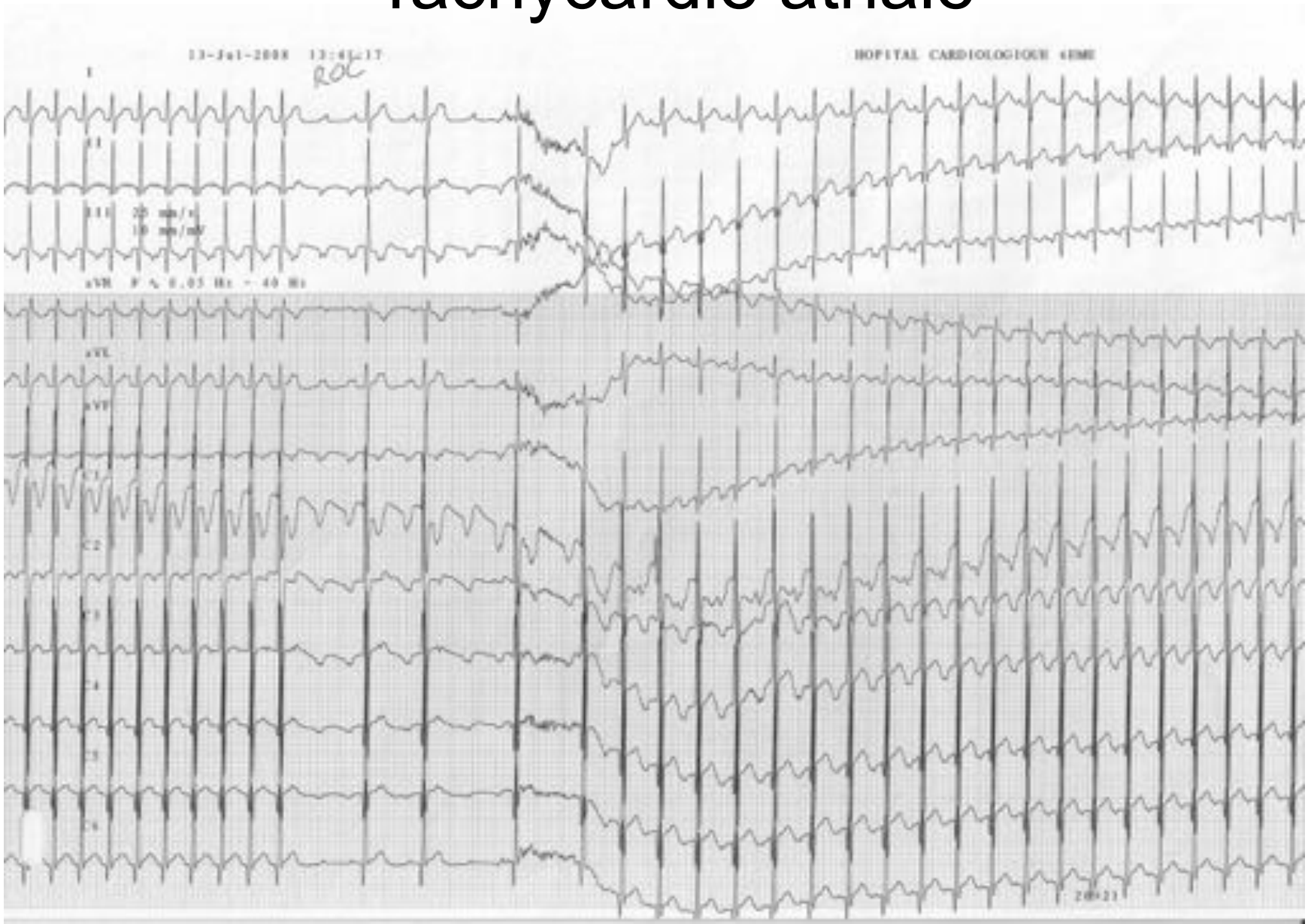

Tachycardie atriale

Tachy 2 cl260 ms: Postero septal area. Entrainment stopped tachy

P > QRS : tachycardie atriale

<u>Flutter</u> :
-rythme régulier
-fréquence A : 400/min
-fréquence V :220-230/min
-P' en dent de scie

<u>Tachy atriale ectopique</u> :
-rythme régulier
-fréquence A : 250/min
-fréquence V :150-200/min
-P' d'aspect non sinusal

<u>Tachy atriale chaotique</u>:
-rythme irrégulier
-fréquence A : 180-500/min
-fréquence V :50-250/min
-P' ≥3 morphologies

Traitement

En cas de mauvaise tolérance : cardioversion 1-2 joules / kg

Cordarone dose de charge ou overdriving atrial ectopique :
Entretien : cordarone ou rien

Digoxine ± sotalex ± flécaine. Cordarone si échec
Entretien=TTT efficace pour la réduction

-Digoxine+sotalex ± flécaine.
-Cordarone ± digoxine si échec
Entretien=TTT efficace pour la réduction

Tachycardie jonctionnelle sur voie accessoire

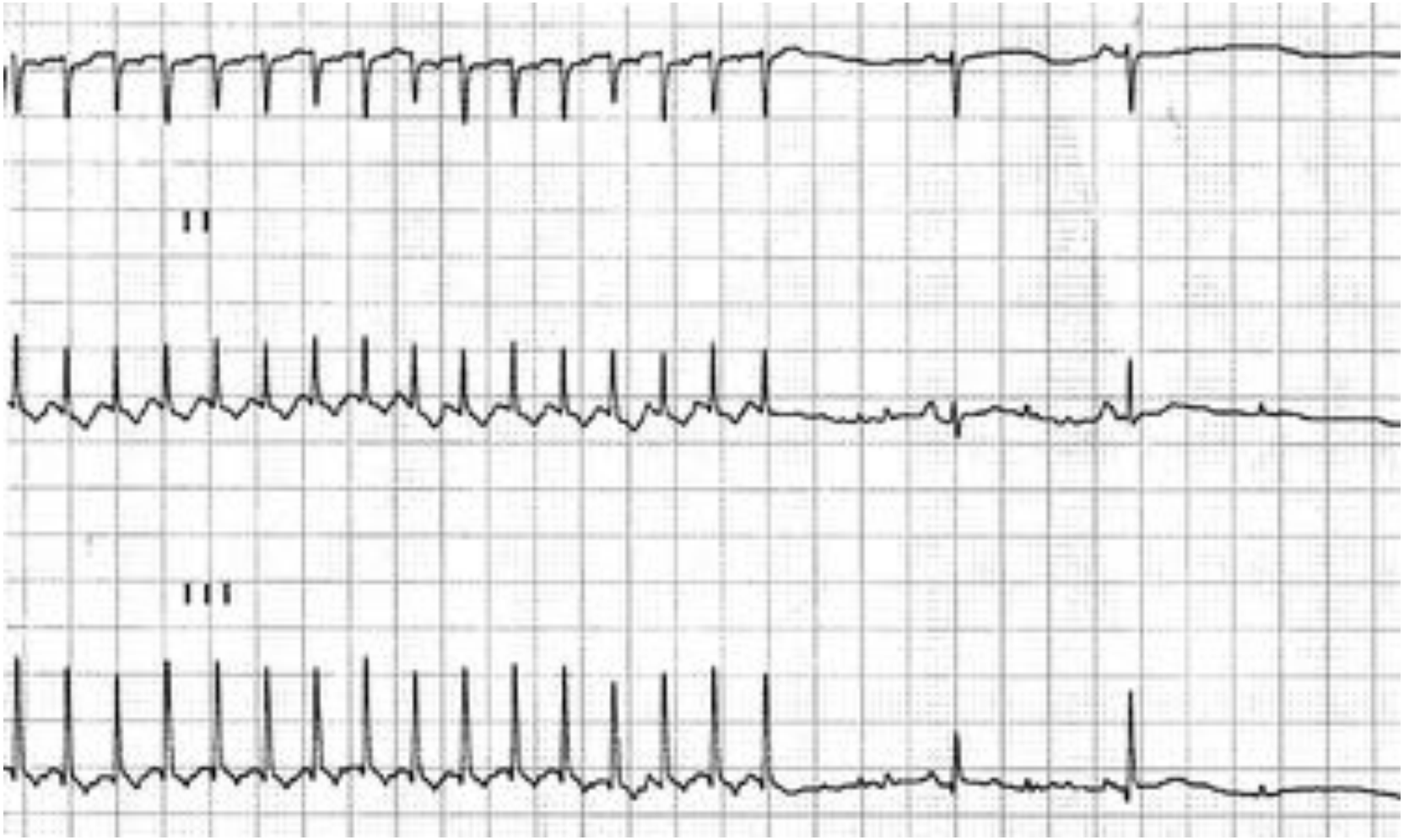

Tachycardie Hissienne

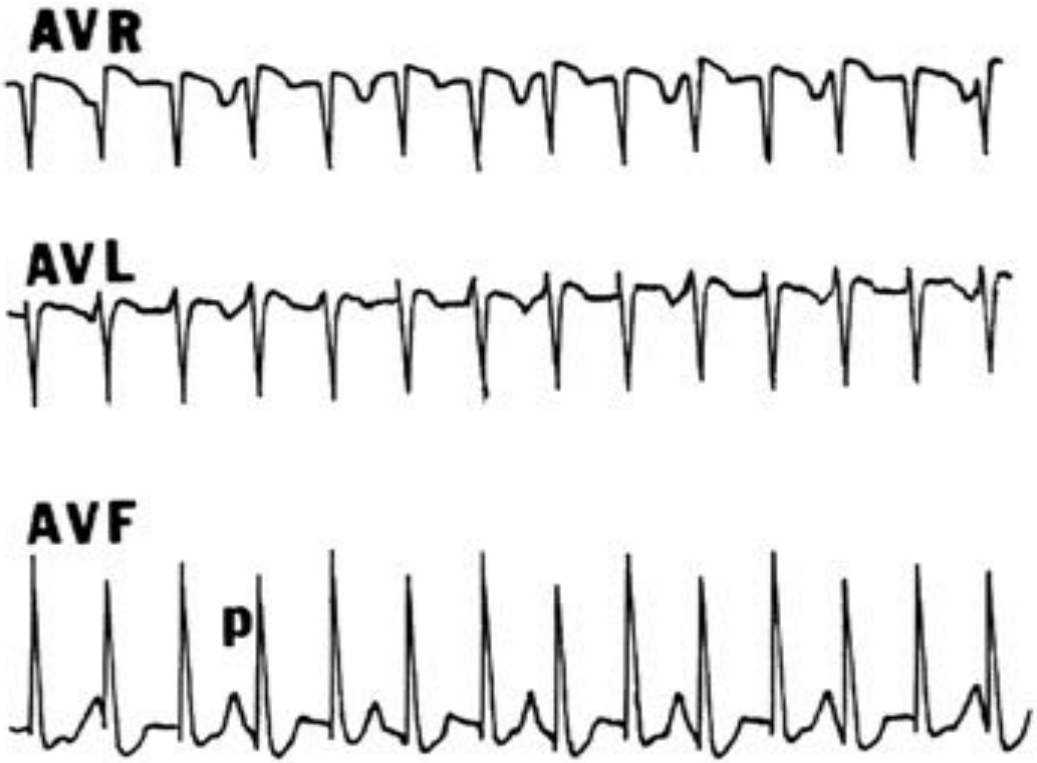

P< QRS : tachycardie hissienne

↓

<u>Tachy jonctionnelle ectopique</u>

-Rythme régulier ou non

-Fréquence 240±60

-Bloc AV rétrograde

-dissociation A-V+capture ou fusion

Traitement

↓

Cordarone seule per os ± sotalex ou flécaine si échec. Corgard en 3° intention en association si échec

Troubles du rythme ventriculaire

- Complexes QRS larges
- Dissociation AV

Patient avec tétralogie de Fallot opérée

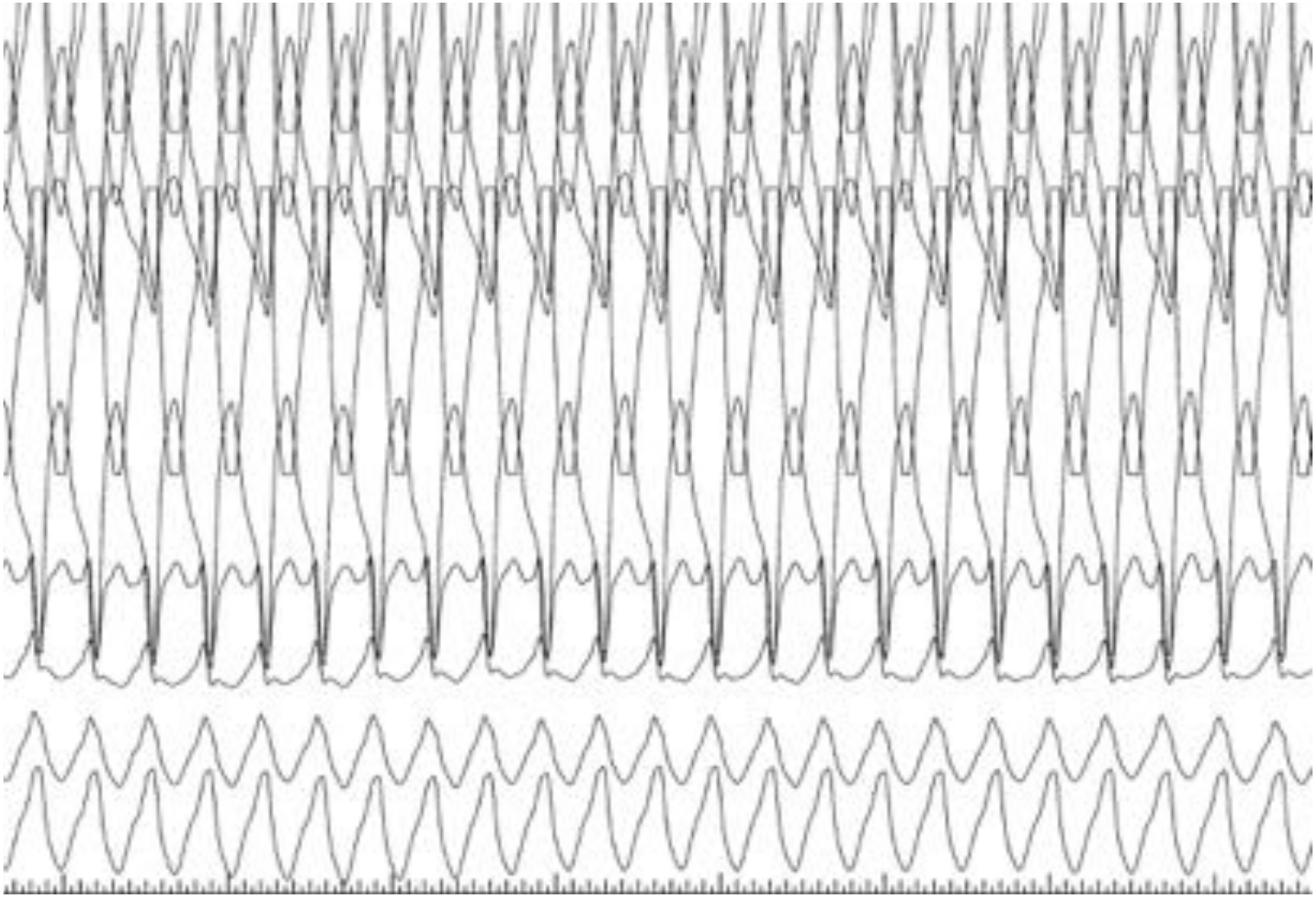

IRM

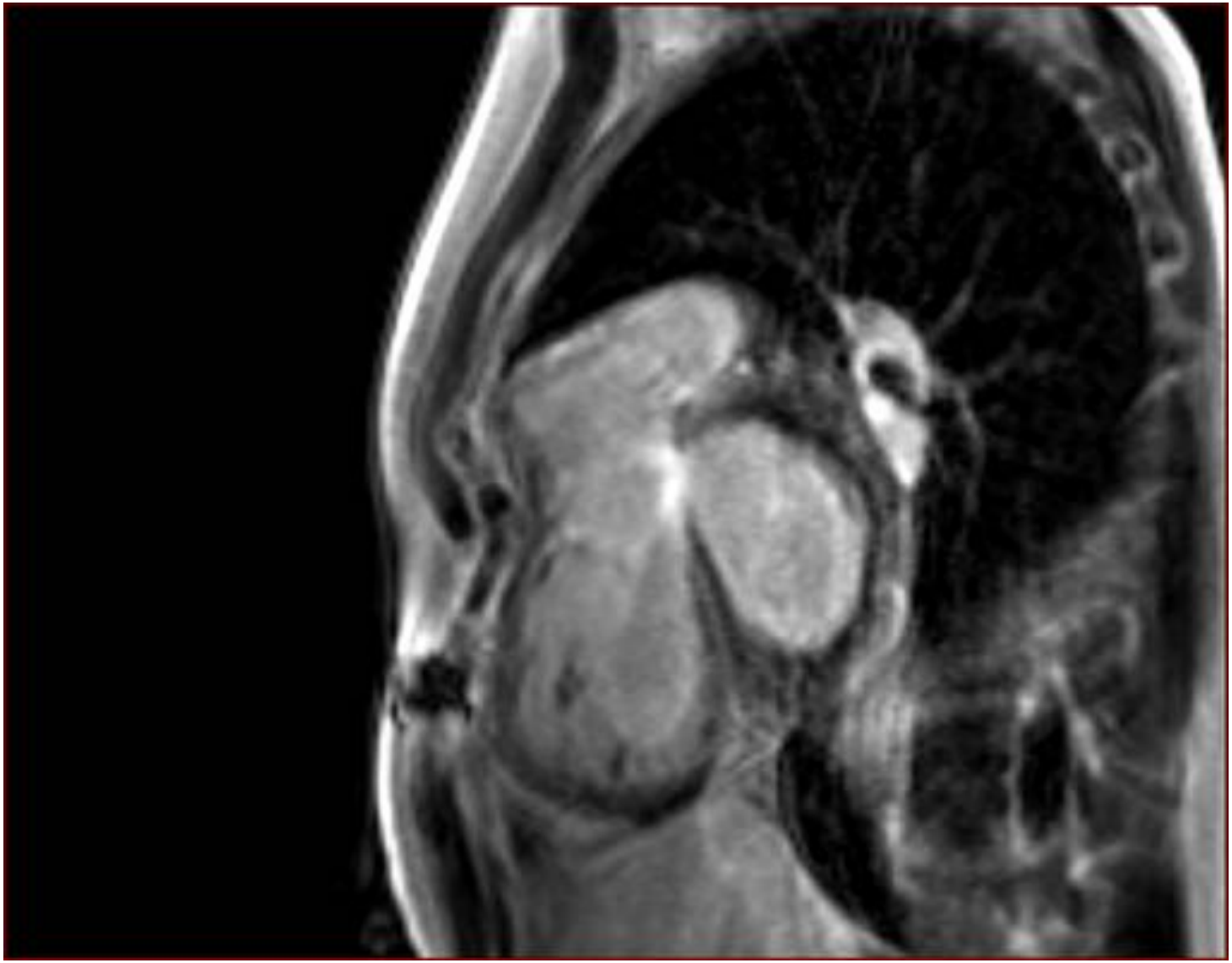

IRM

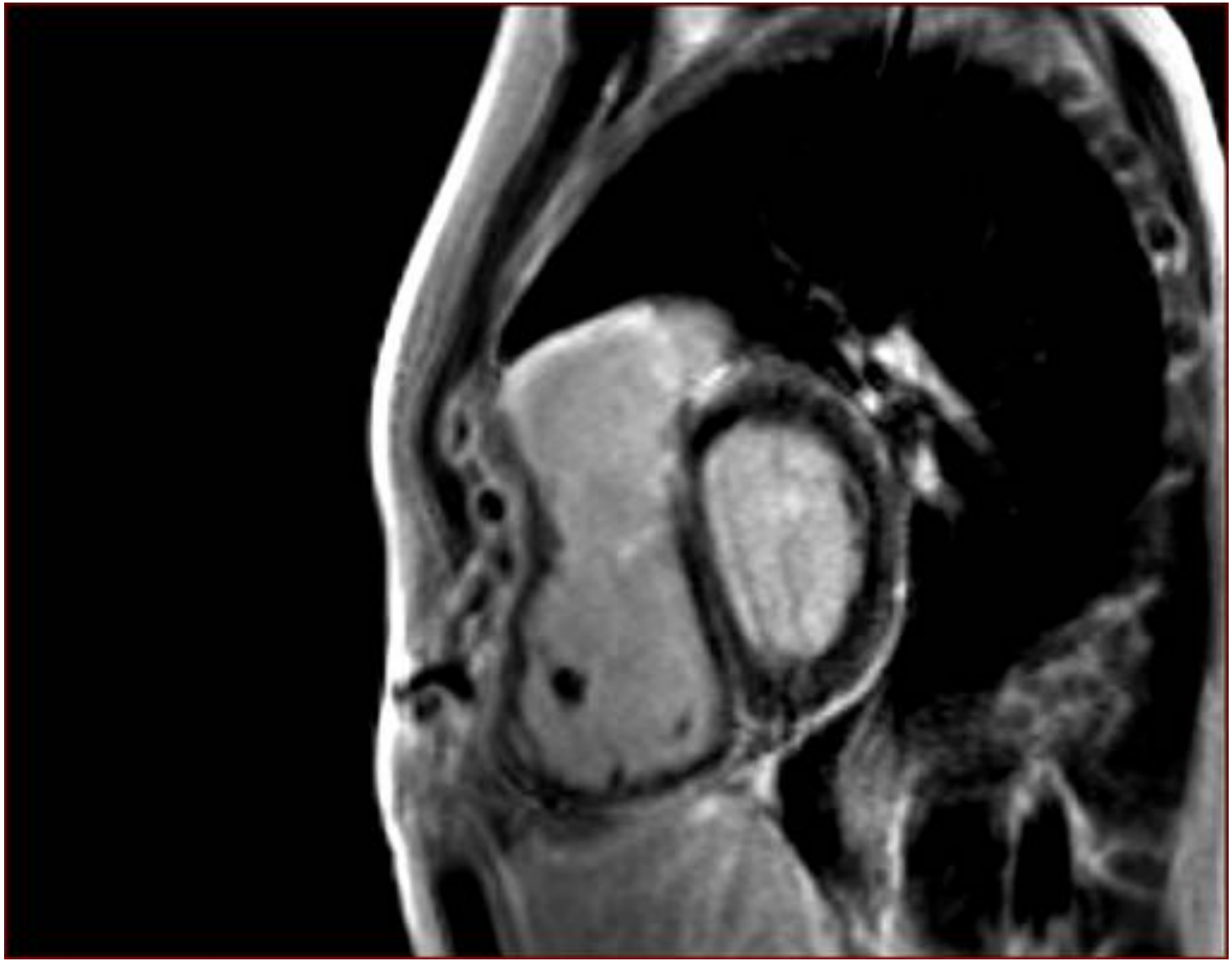

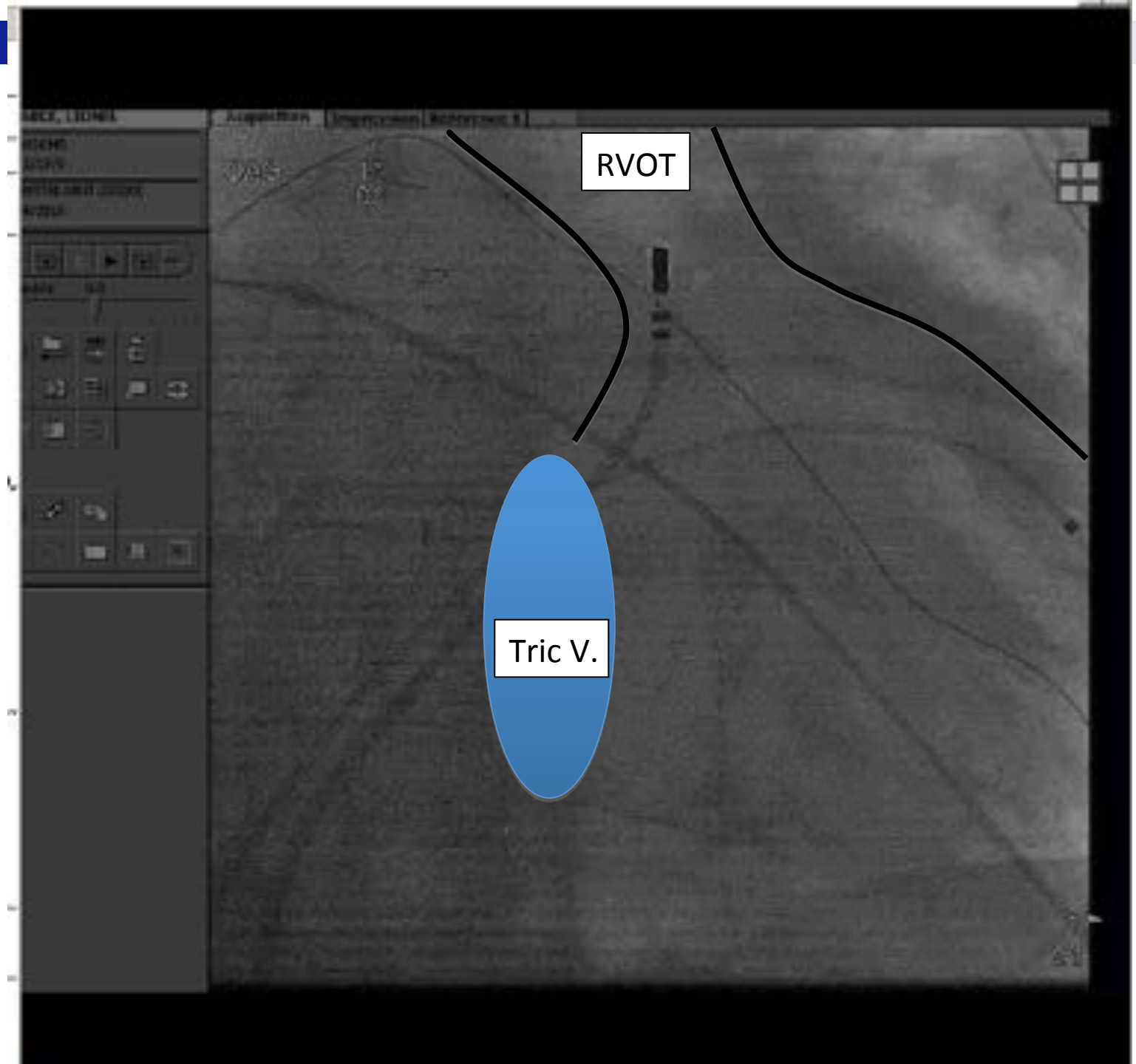
RVOT
Tric V.

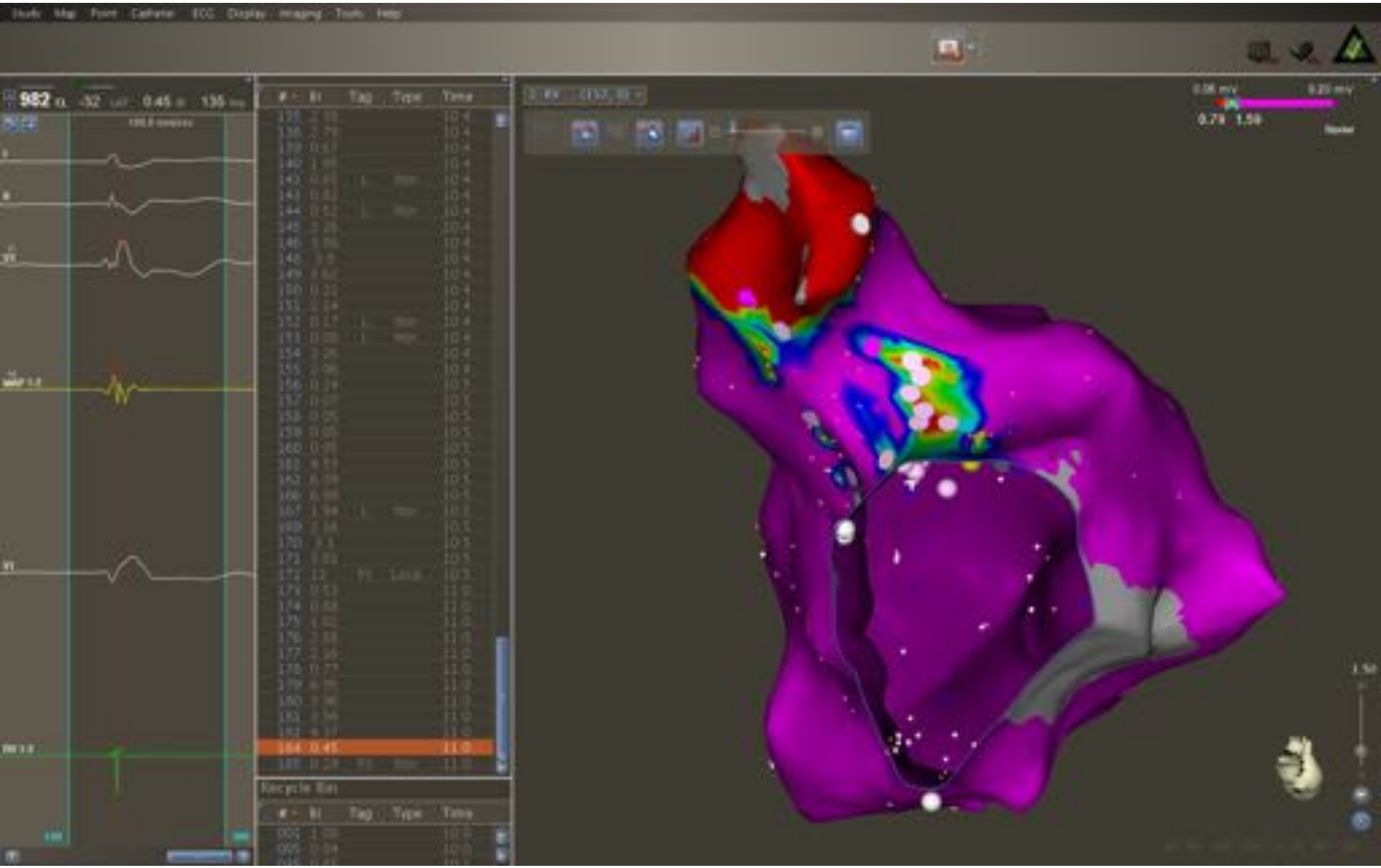
Study Map Point Catheter ECG Display Imaging Tools Help
Tag Type Time
Recycle Bin

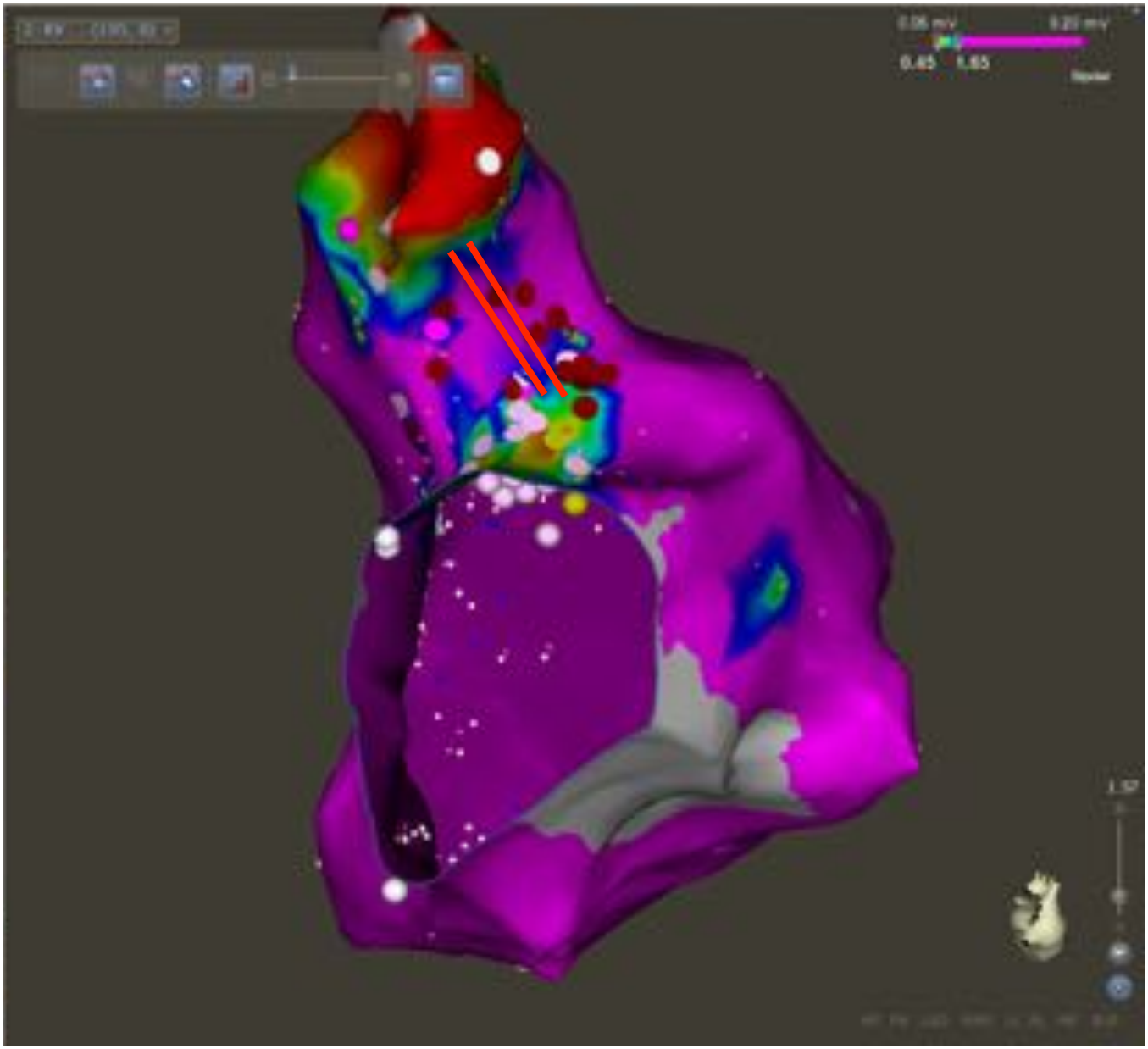
0.05 mV
0.20 mV
0.45
1.65

Troubles du rythme post-chirurgie
Torsade de pointe

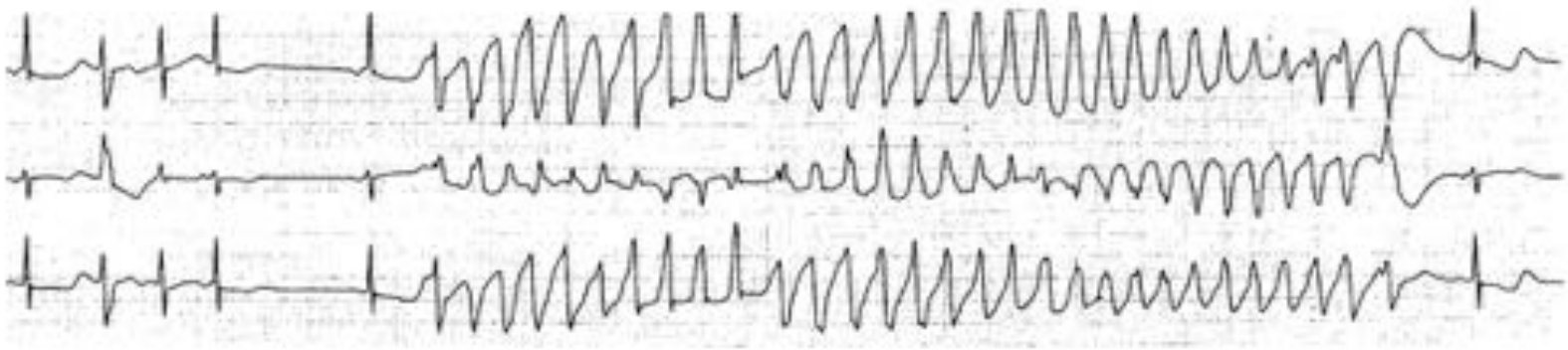

Torsade de pointe

- CEE uniquement si l'épisode dure longtemps
- Mg. 0.5 mEq /kg sur 5 minutes
- Isuprel ou stimulation cardiaque

Troubles du rythme post-chirurgie
Traitements

- Electrique : choc, stimulation rapide de l'oreillette
- Métabolique : K, Mg
- Facteurs déclenchants
- Pharmacologique

Le choc électrique externe

- En cas de TSV:
  - 1-2 J/kg en mode synchrone
- En cas de FV:
  - 2-4 J/kg en mode asynchrone

MERCI

Un mot sur les guidelines

- « there are no ranodomized clinical trials of cardiac pacing in pediatric or congenial heart disease patients »
- AHA : 2012
- ESC : 2013

Post-operative atrioventricular block

In patients with congenital heart disease, post-operative AV conduction block complicates 1% to 3% of cardiac operations.[w216] The risk is greatest for the surgical repair of ventricular septal defects. Spontaneous resolution of complete AV block in the early post-operative period can occur, usually within 10 days after the operation.[137–141] The prognosis for patients whose AV conduction returns to normal is favourable. In contrast, the prognosis for non-paced patients is very poor. In a large meta-analysis, residual bifascicular block that persisted after the disappearance of transient post-surgical complete heart block was associated with a high incidence of late recurrence of AV block or sudden death (29%).[138] Post-operative HV interval determination may help to assess the risk of late-onset AV block in patients with residual conduction disorder (long PR interval, bifascicular block).[w217]

Sinus node disease and bradycardia-tachycardia syndrome

In children, sinus node dysfunction might precede or follow reparative cardiac surgery involving the atria, though it is also observed in patients treated with anti-arrhythmic drugs and in patients with an otherwise normal heart.[w218,w219] Contrary to AV block, sinus node dysfunction is not associated with increased mortality.

Indications for cardiac pacing (Recommendations 5 and 6)

The occurrence of symptomatic sinus node disease justifies the implantation of a PM if competing causes have been ruled-out after extensive examination.[w220,w221] Chronotropic incompetence has been correlated with the late development of post-operative atrial flutter.[w222] Pacing to restore chronotropic competence may prevent late post-operative atrial flutter and reduce exercise intolerance, especially late after Mustard, Senning or Fontan procedures. Pacing can also be used to treat congestive HF or fatigue and to prevent the development of supraventricular arrhythmias.[w223,w224] The evidence of benefit is lacking for young, asymptomatic patients, with a heart rate <40 bpm or >3 sec pauses.[w218–w221]

Cardiac resynchronization in congenital heart disease

Evidence of benefit from CRT is limited to case reports, retrospective analyses of heterogeneous populations, small crossover trials conducted in the immediate post-operative period and expert opinions.[w204,w225–w228] In particular, a subset of patients paced in RV for isolated congenital AV block develops a dilated cardiomyopathy. In these patients, single-site LV pacing is particularly attractive for children and young adults. A recent European multicentre study showed that, during a mean follow-up of 5.4 years, pacing from the RV outflow tract/lateral RV caused a significant decrease in LV function, whereas LV apex/LV mid-lateral wall pacing was associated with preserved LV function.[w229] For the purpose of single-site LV pacing, either epicardial implantation or implantation via the coronary sinus may be used (*Web Figure 12*). However, the evidence is not great enough and this Task Force cannot make any specific recommendation.