CIV

Xavier Iriart

Bordeaux

ANATOMIE du septum interventriculaire

Vue du ventricule droit

Vue du ventricule gauche

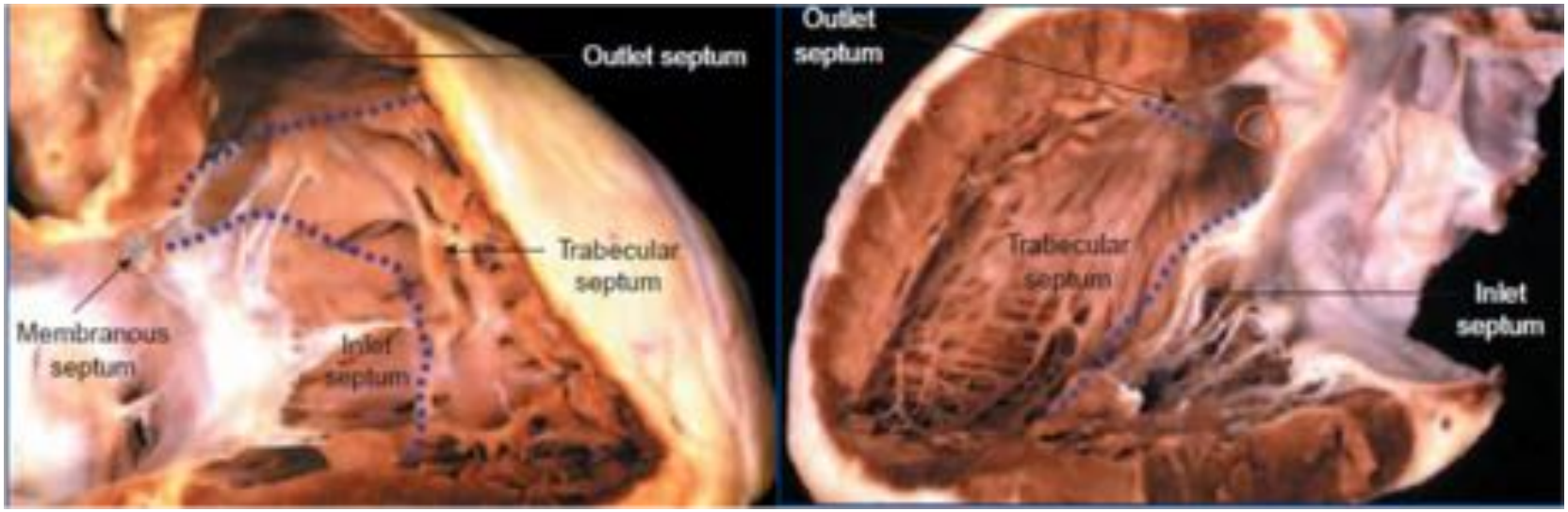

Définition

- Ouverture dans le septum interventriculaire
- Localisation:
  - Perimembraneuse (extension vers l'inlet/l'outlet/SIV musculaire)
  - Doubly committed/juxta arterielle
  - Musculaire (inlet/outlet/apical)
- Nombre: isolée ou multiples
- Taille: forme et taille variable
- Lésions associées: nécessité une analyse segmentaire complète

classification

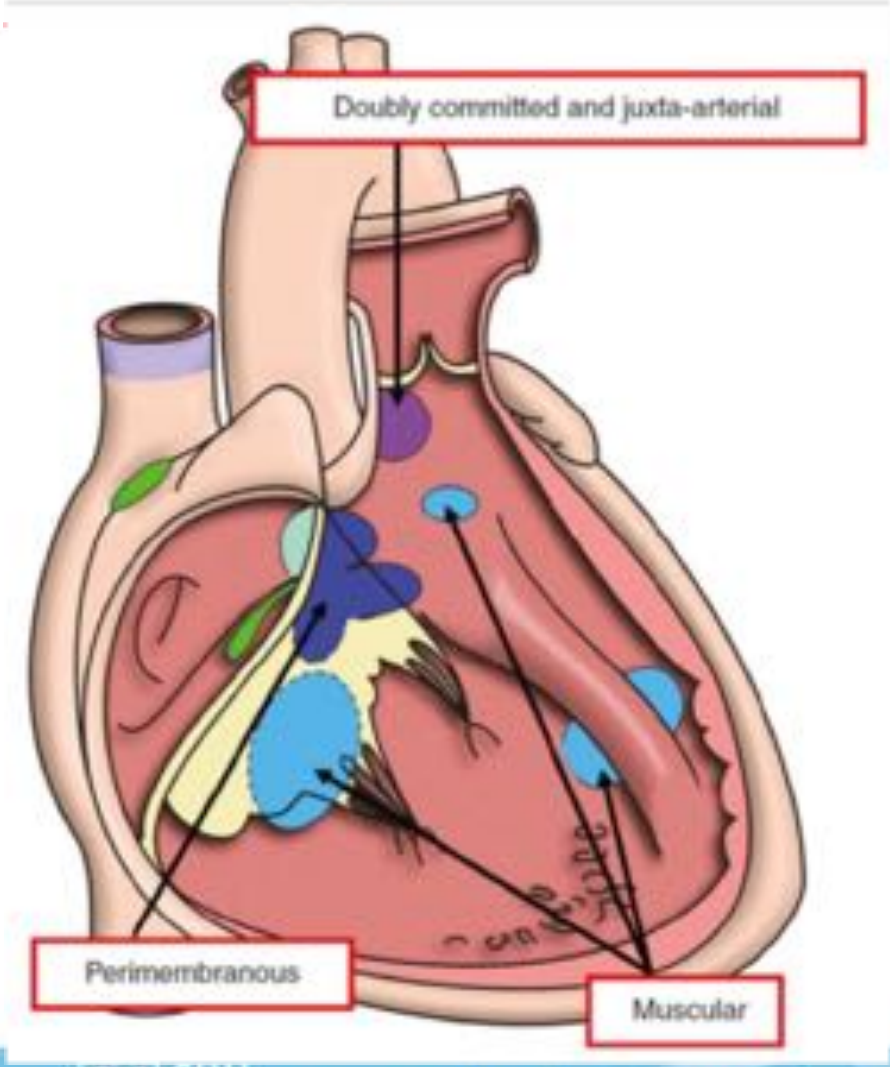

Les résistances vasculaires au cours des premières semaines de vie

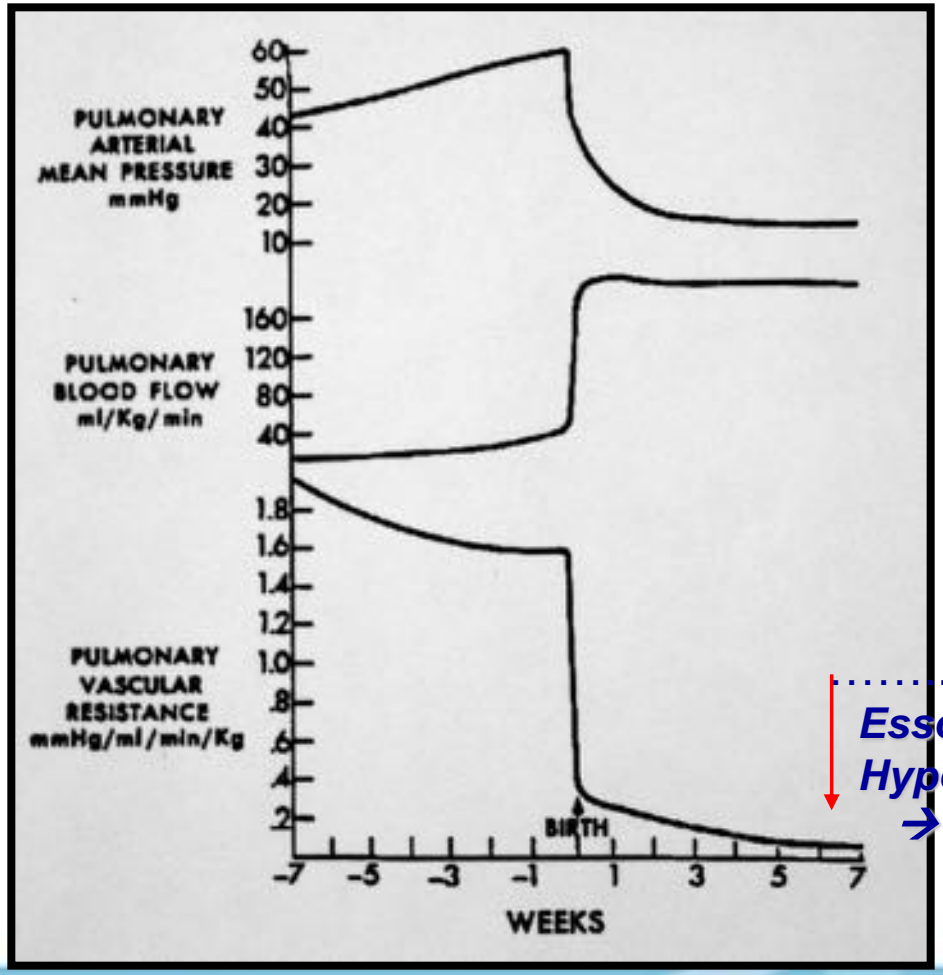

CIV large

……. ***Apparition du souffle***
Essoufflement
Hypotrophie
→ Bas débit

Physiopathologie

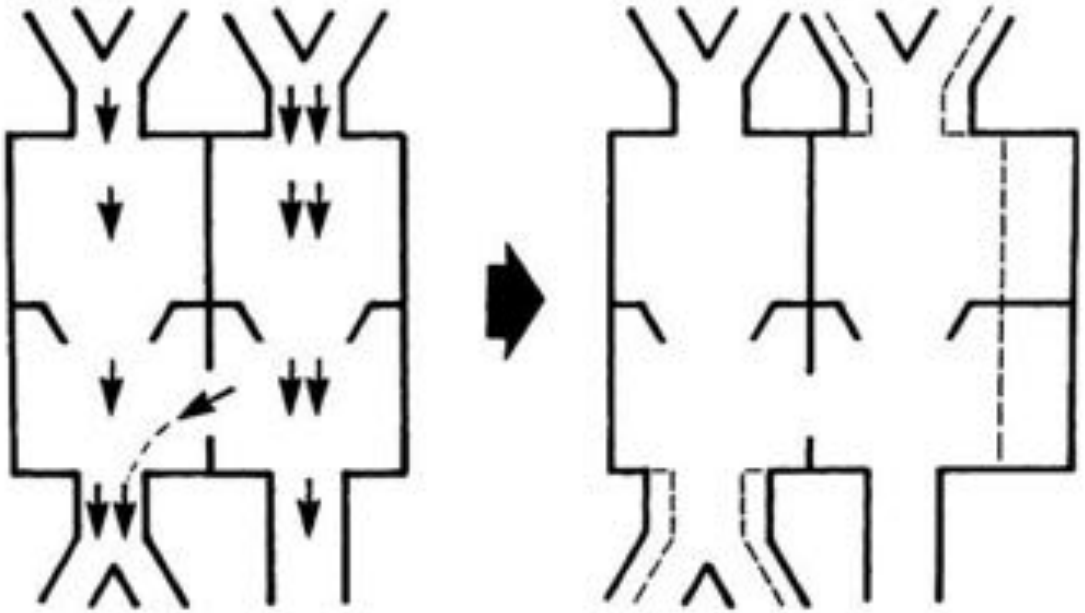

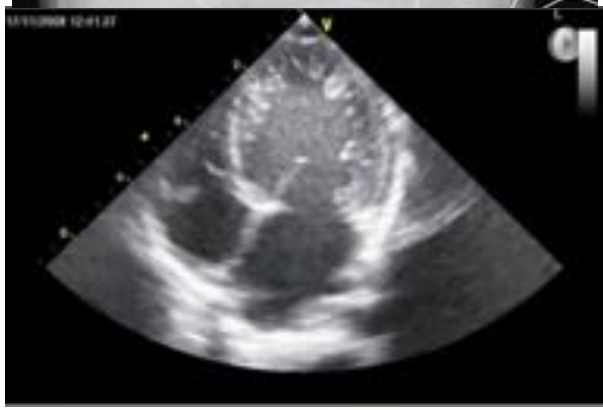

classification physiopathologique

CIV I: maladie de ROGER (CIV petite)

* CIV restrictive: PAPS/PS<0,3 QP/QS = 1-1,5

CIV II: CIV à gros débit (CIV moyenne et large)

*CIV IIa large/restrictive: PAPS/PS 0,3-O,7 QP/QS >2

*CIV IIb large/non restrictive: PAPS/PS 0,7-1 QP/QS >2

CIV III: sydrome d' EISENMENGER

* CIV large: PAPS/PS>1 QP/QS<1

CIV IV:CIV à poumons protégés

* CIV + SP: grVD-AP > 25 mmHg PAPS/PS<0,7 QP/QS>2

Évolution CIV type 1 (maladie de Roger)
CIV de petite taille, siège d'un shunt restrictif

naissance

Resistances vasc pulm hautes, petit défect
=> **Hyperdébit pulmonaire faible**

Bébé eupnéïque,
pas de gênes aux tétées,
pas de signes d'IC,
souffle 3-4/6

3 sem après

Baisse prog des resist vasc pulm
=> **↑de l'hyperdébit pulmonaire mais reste faible**

ETT
shunt VG-VD systolique à vitesses élevées++
pas de Dilatation des cavités gauches

Eupnéïque,
Pas de gêne aux tétées
Souffle 4/6 voire thrill
Pas de signes d'IC

RP quasi normale

Risques à long terme

IA, endocardite

Évolution CIV avec hyperdébit pulm modéré = 2a (taille moyenne, shunt restrictif)

naissance

Resistances vasc pulm hautes
Défect taille moyenne
= **Hyperdébit pulmonaire faible**

Bébé eupnéïque,
pas de gênes aux tétées,
pas de signes d'IC,
souffle 2/6 voire absent

≈ 3 sem après

Baisse prog des resist vasc pulm
=> ↑**hyperdébit pulmonaire progressif**

Polypnée légère
Gêne aux tétées modérée ou absente
Souffle 3 ou 4/6
Peu ou pas de signes d'IC
Stagnation pondérale modérée ou ascension insuffisante

ETT
shunt VG-VD systolique à vitesses élevée
Dilatation des cavités gauches
+/- obstacle pulmonaire
RP= cardiomégalie, surcharge vasculaire modérée

Risques à long terme

Possible Maladie Vasc Pulm à long terme si Qp/Qs reste élevé (dilatation cavités gauche) mais rare
IA, endocardite

Évolution CIV 2b (hyperdébit pulm sévère)
CIV de taille large siège d'un shunt non restrictif

naissance

Resistances vasc pulm hautes
Défect large
= **Hyperdébit pulmonaire faible**

Bébé eupnéïque,
pas de gênes aux tétées,
pas de signes d'IC,
souffle 2/6 voire absent

≈ 3 sem après

Baisse prog des resist vasc pulm
=> ↑**hyperdébit pulmonaire progressif**

ETT
shunt VG-VD systolique à vitesses basses (HTP de débit)
Dilatation des cavités gauches

Polypnée marquée
Gêne aux tétées importante
Souffle 2 à 3/6
HMG
Stagnation pondérale
voire cassure

Risques

Maladie Vasc Pulm dans les 6 à 12 mois (fixation des résistances pulm)
Eisenmenger à long terme (Rpulm>Rsystémiques)

Développement de la maladie vasculaire pulmonaire chez les patients avec shunts GD

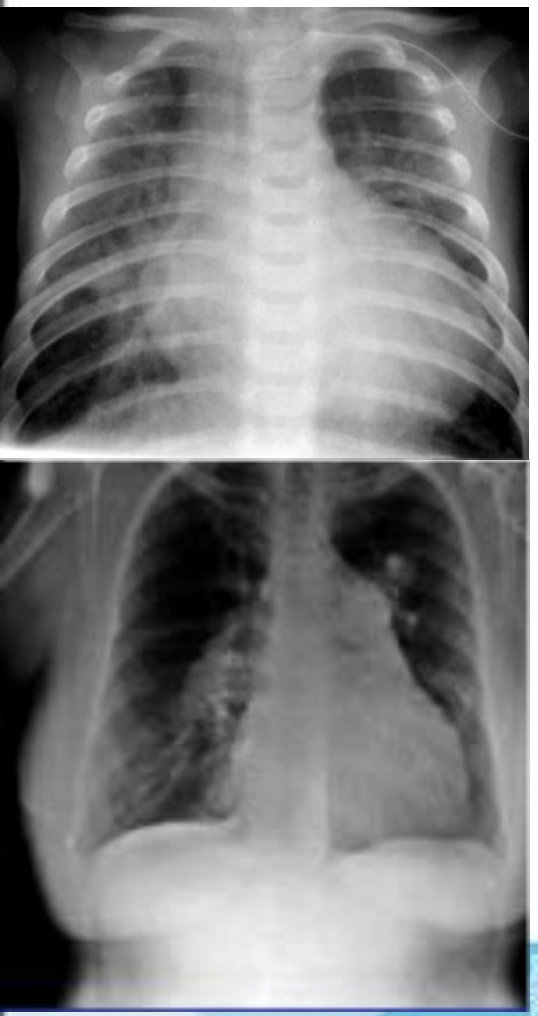

Shunt gauche-droite

↓

Augmentation du flux sanguin pulmonaire

↓

Augmentation des résistances vasculaires pulmonaires (RVP)

↓

En l'absence de correction chirurgicale,
la maladie vasculaire pulmonaire peut se développer
de type histologique similaire à celui de l'HTAP idiopathique (HTAPi)

↓

Dommages irréversibles du système vasculaire pulmonaire
et augmentation des RVP

L'HTAP peut se développer après chirurgie correctrice ou palliative de la CC [18]

Galié N et al. Drugs 2008
Beghetti M et al. J Am Coll Cardiol 2009

Évolution des Pressions / Résistances Pulmonaires

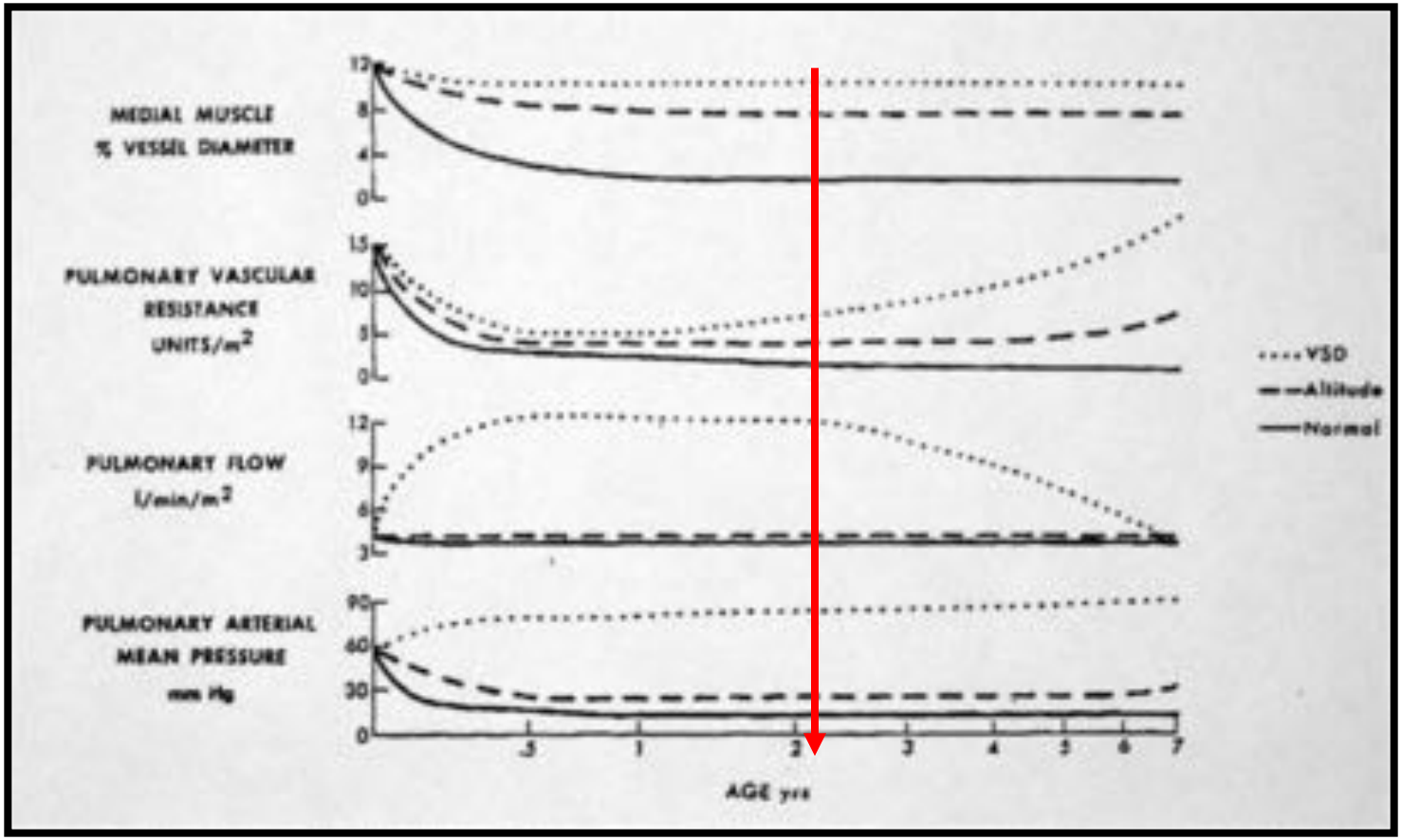

EISENMENGER … INOP !!!!

syndrome d'Eisenmenger

Shunt gauche-droite — **Shunt bidirectionnel** — **Shunt droite-gauche**

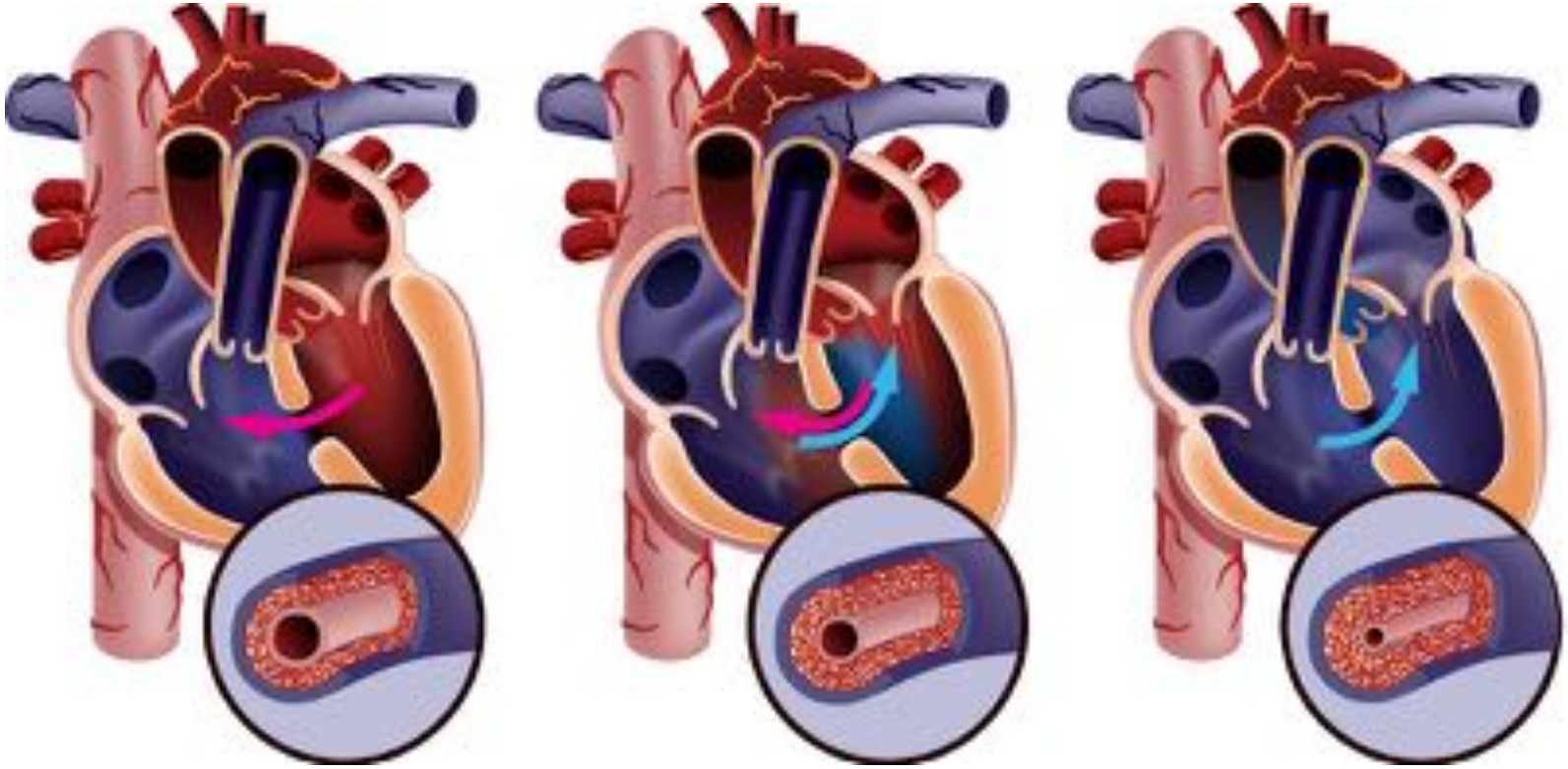

Progression de la maladie →

Qp et/ou PAP — RVP — RVP-cyanose

Galié N et al. Drugs 2008

Echographie des CIV

- Diagnostic anatomique
  - Localisation
  - Nombre
  - Rapports anatomiques
  - Taille (π x D1 X D2 /4) forme ellipsoide
- Diagnostic hémodynamique
- Recherche de lésions associées
- Bilan post-opératoire
- Cardiologie interventionnelle

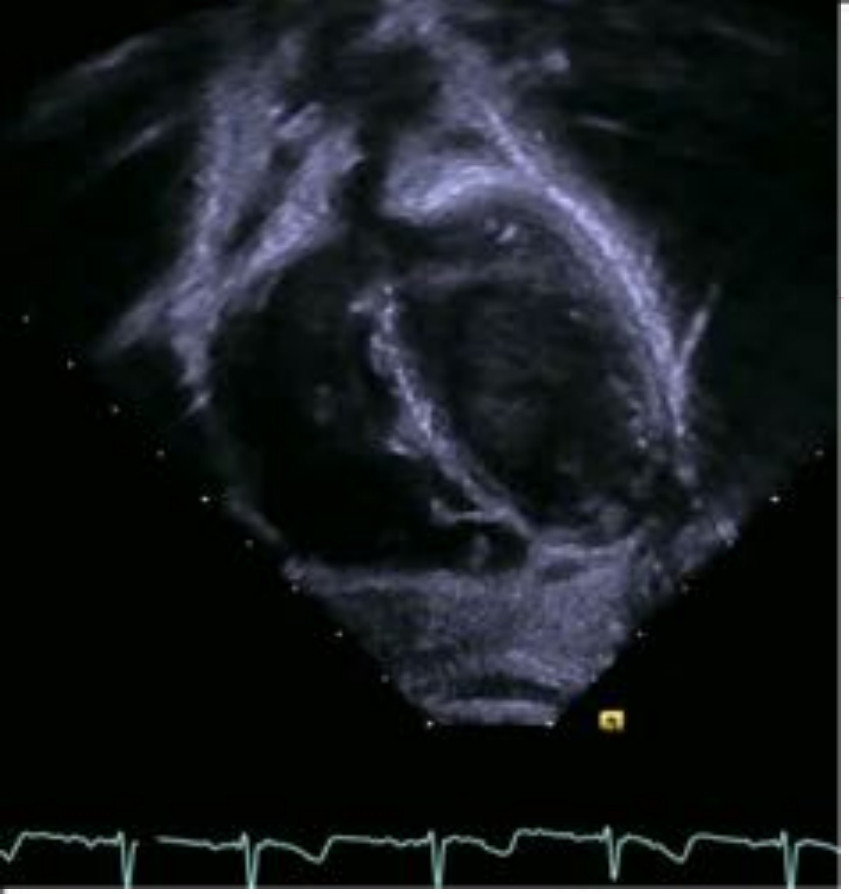

Balayage antéro-postérieur

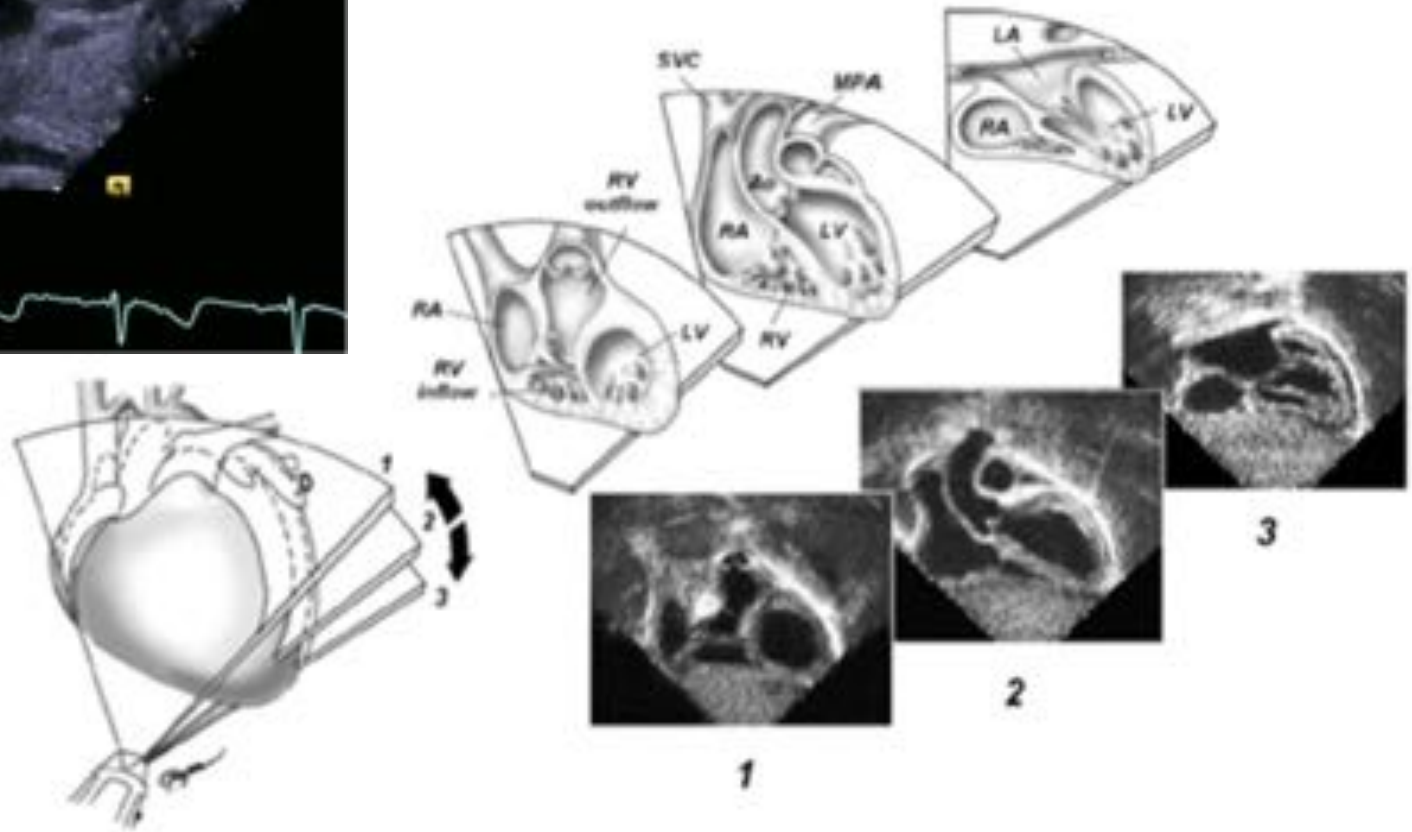

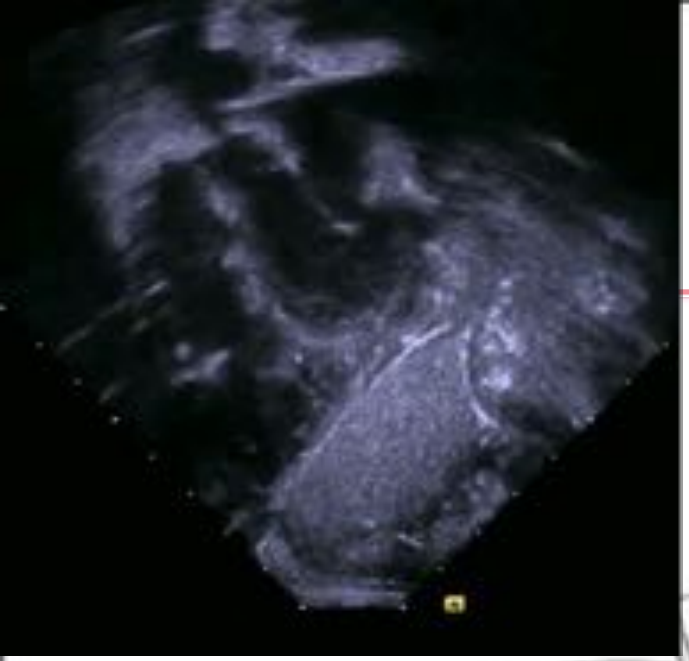

Balayage apex-base

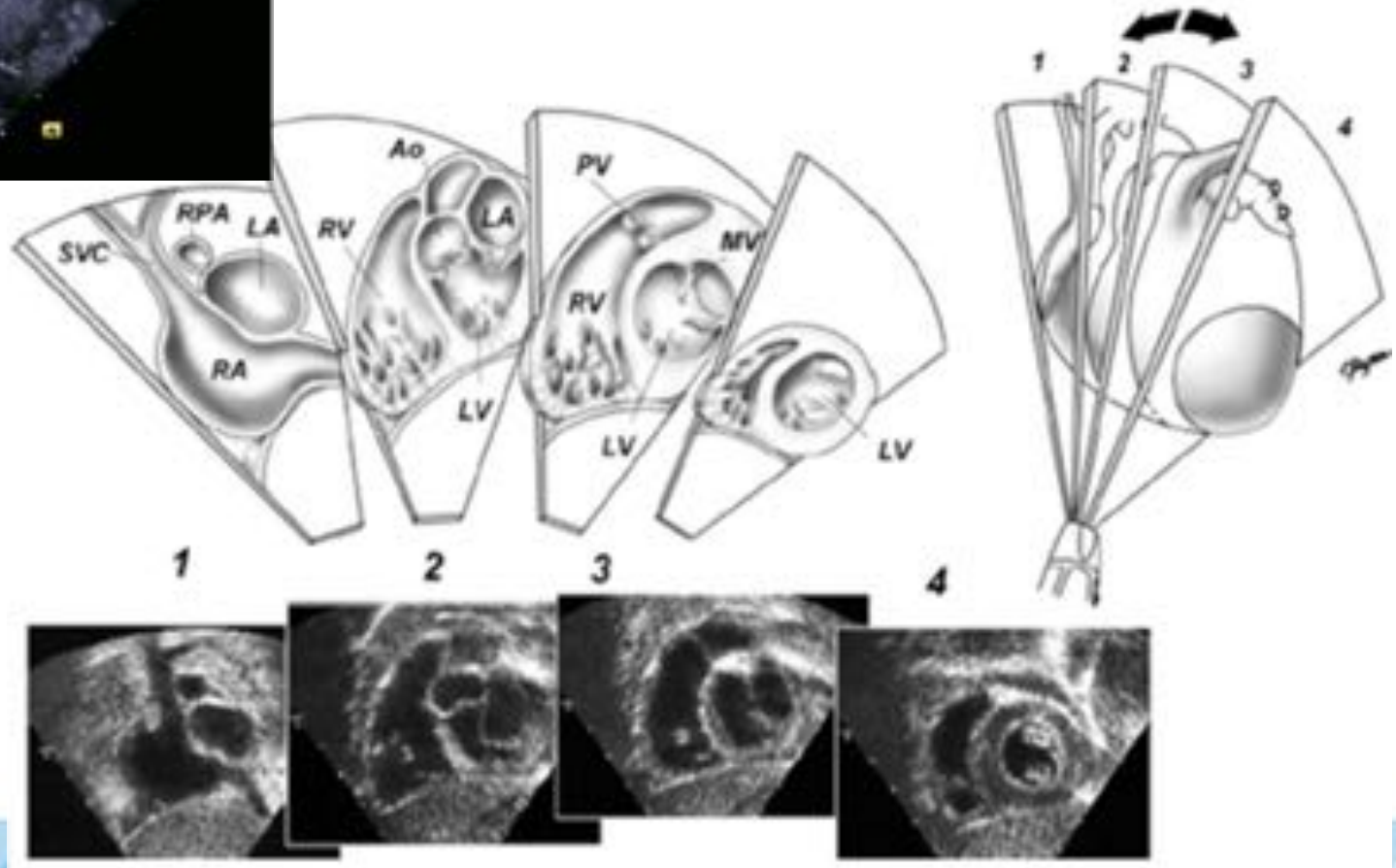

Balayage antéro-postérieur

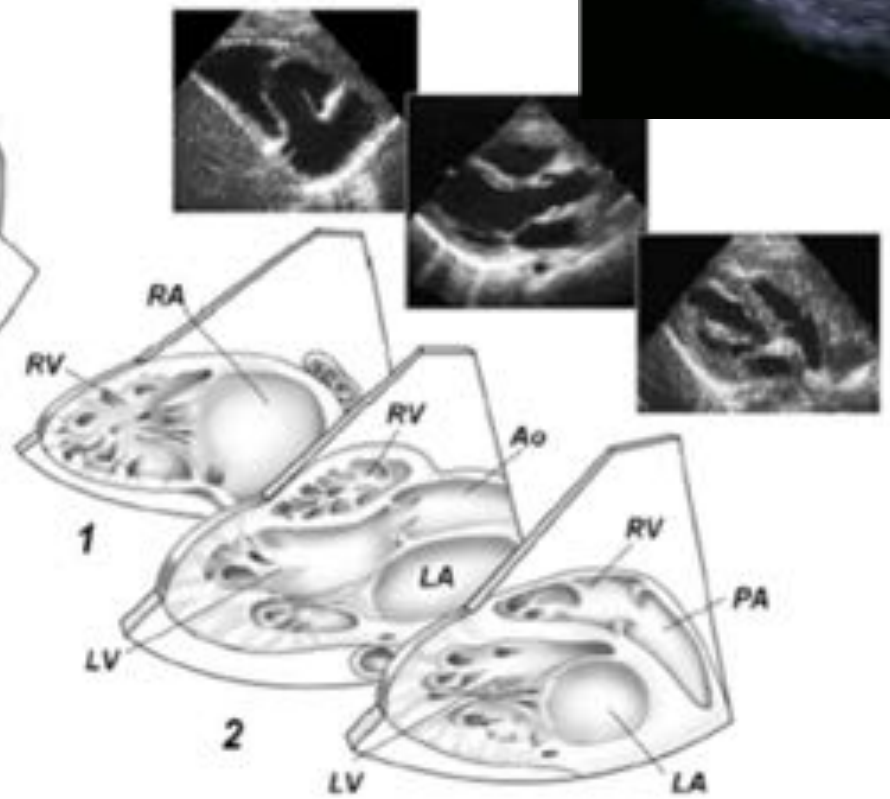

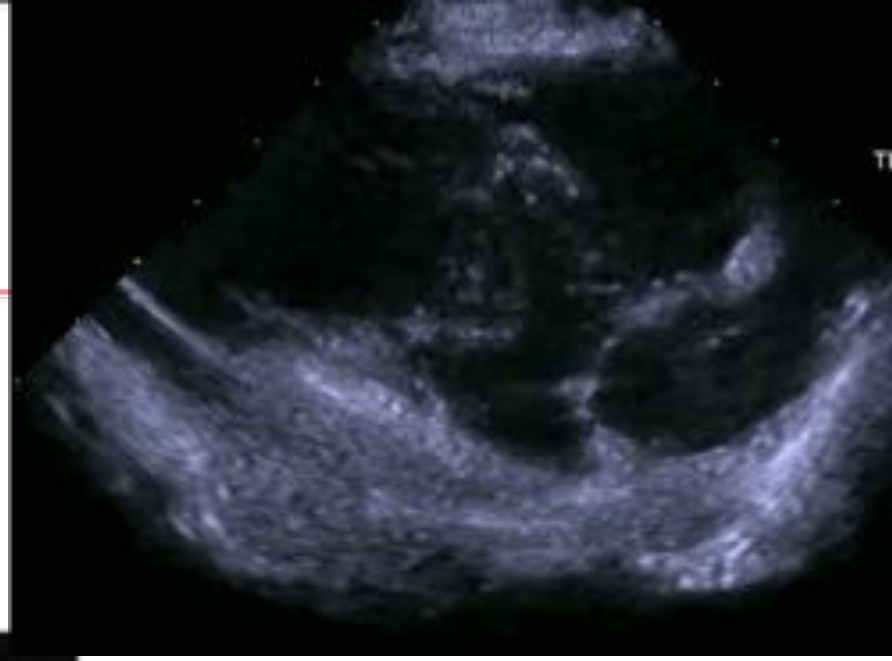

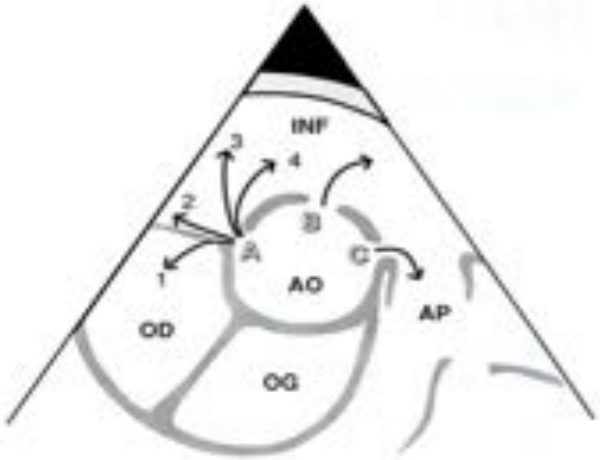

A CIV périmembraneuse
- 1- avec shunt VG ⟶ OD
- 2- avec extension dans l'inlet
- 3- avec extension dans le septum musculaire trabéculé
- 4- avec extension dans l'outlet

B CIV musculaire de l'outlet (infundibulaire)

C CIV sous-artérielle

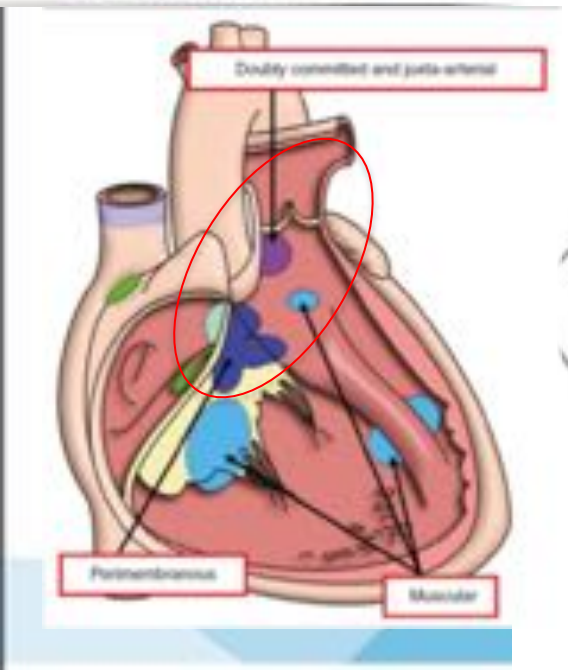

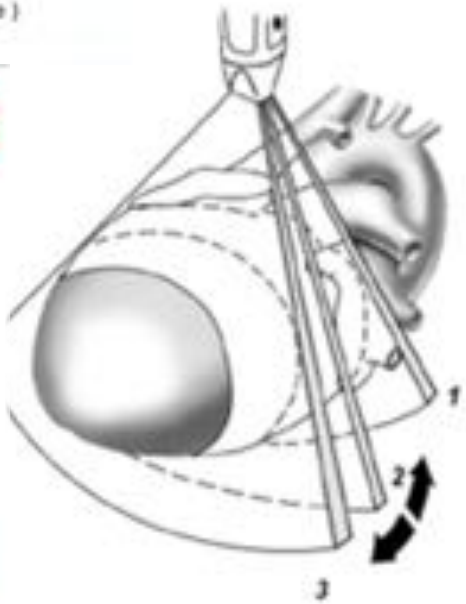

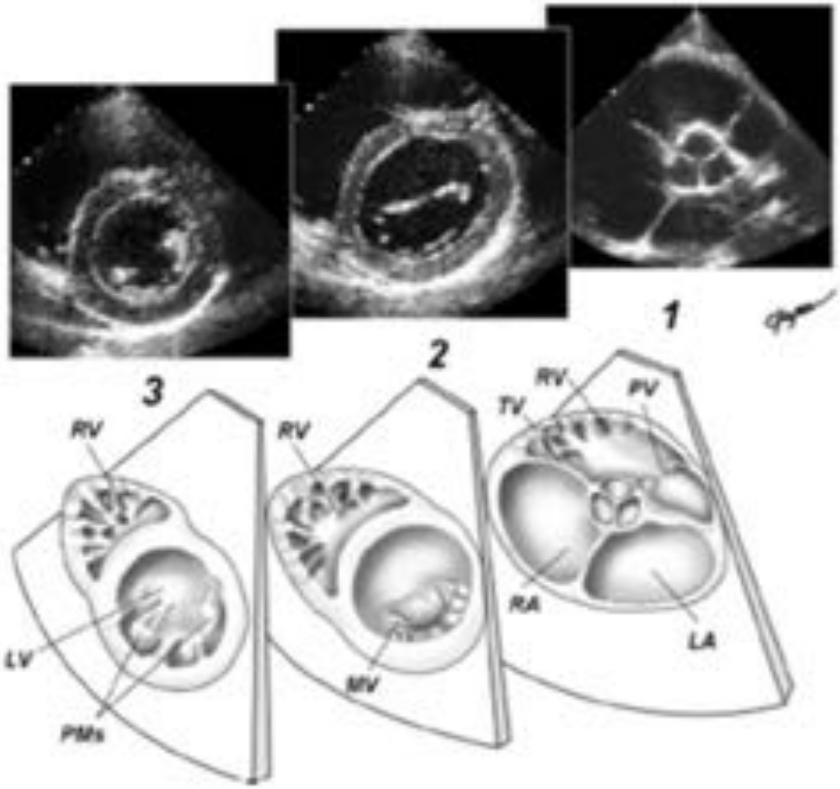

Balayage antéro-postérieur

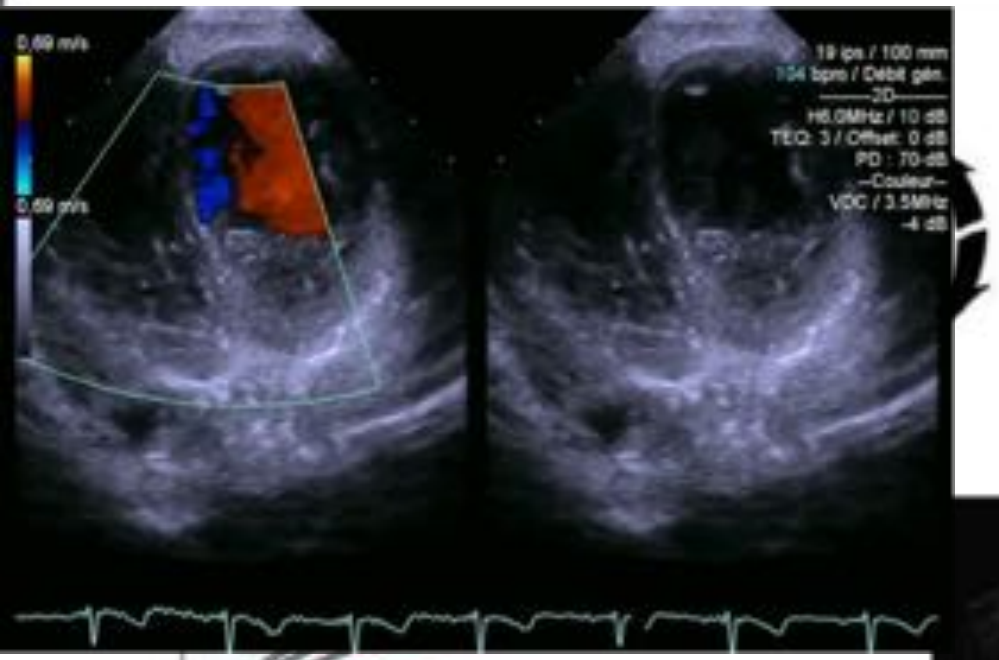

(1)

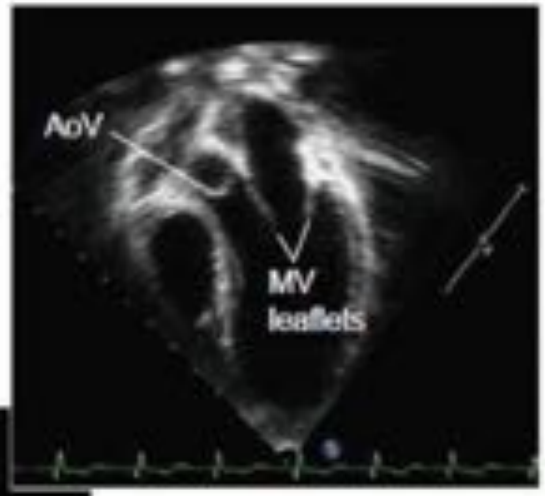

(2)

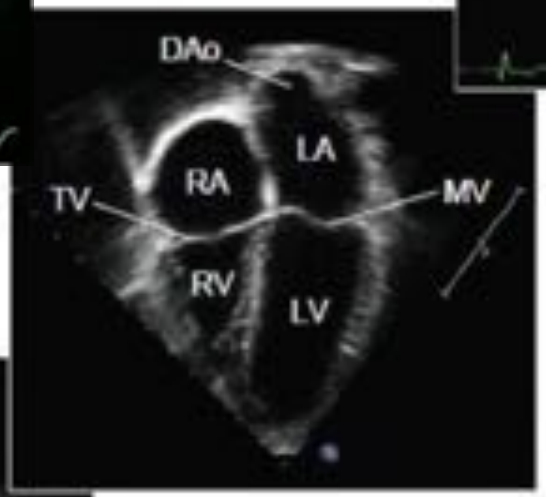

(3)

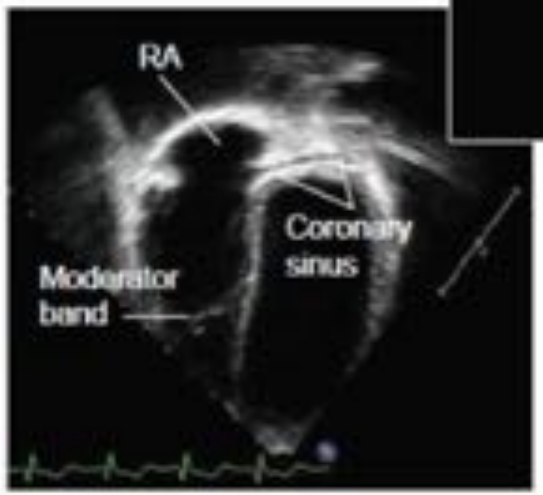

Etude échographique du septum

Coupes parasternales

Coupes apicales

Coupes sous-costales

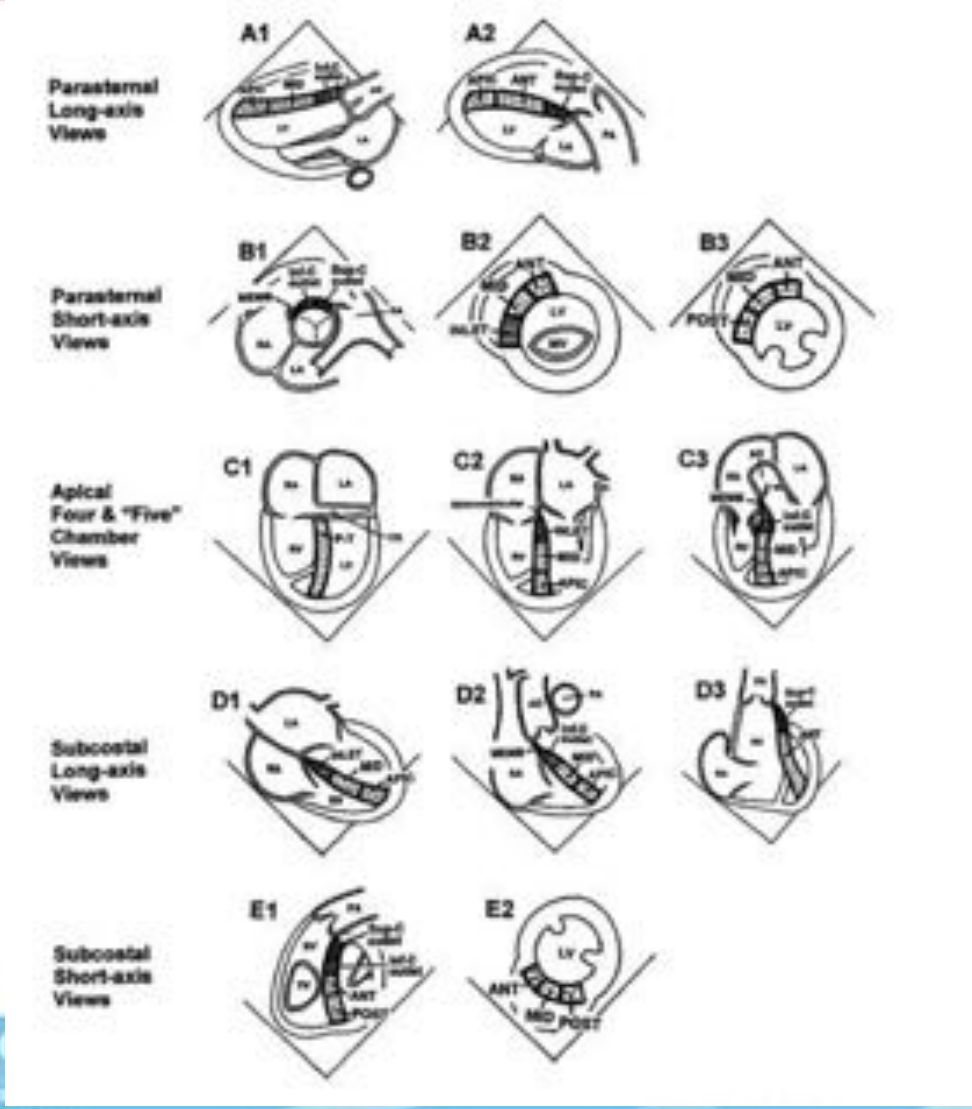

Critères simplifiés pour fermeture

TABLE 1 Perimembranous Ventricular Septal Defect and Aortic Size in Both Groups

Surgery	≤5 mm	5–6.5 mm	≥6.5 mm	Size (mm)	Aortic Annulus
+ (n = 20)	4	2	14	7.0 ± 1.7	10.1 ± 1.8
0 (n = 37)	30	5	2	4.4 ± 1.2*	8.8 ± 1.6†

*p <0.001; †p <0.01.

- Nourisson < 3 mois
  - CIV PM <5mm: fermeture spontanée ou HD non significative
  - CIV PM >6.5mm: nécessité de fermeture chirurgicale

Puchalski M et al. Am J Cardiol 2002; 90:569-71

Evaluation hémodynamique

- Gradient trans ventriculaire: $4V^2$

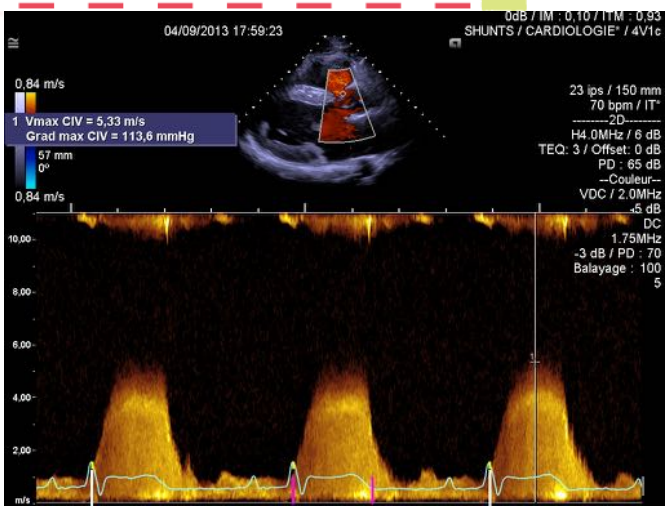

- Evaluation du QP/QS
  - Qp= ITVpulm x π ½ D^2 / Qs=ITVAo x π ½ D^2

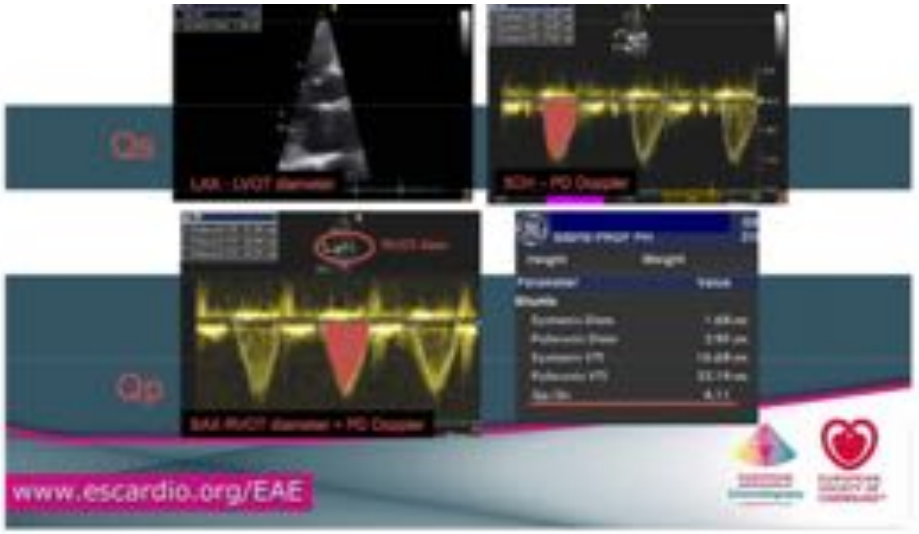

Evaluation hémodynamique

- Evaluation des pressions pulmonaires
  - Par la CIV: PAPS= PAS – gdt CIV
    - Pré-op
  - Par l'IT
  - Par l'IP
    - PO





- Evaluation des résistances vasculaires
  - Evaluation post-opératoire

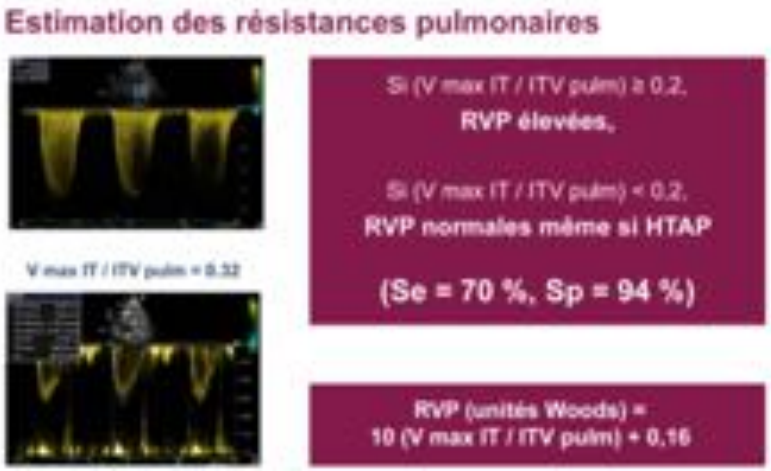

Evaluation hémodynamique

- Post-fermeture
- Post cerclage

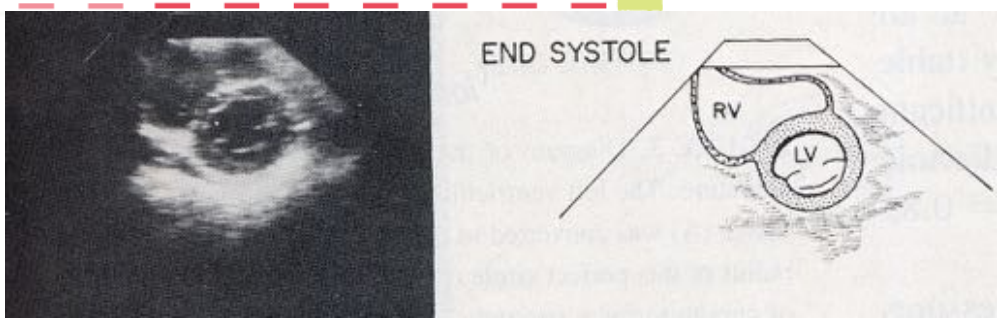



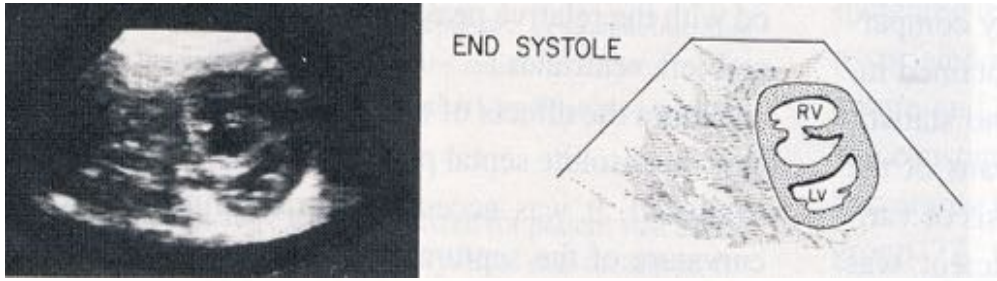

Intérêt de l'échographie dans le syndrome d'Eisenmenger

- Association dysfonction VD et mortalité
  - Fonction longitudinale VD conservée (TASE 15-20mm: 65%)
  - Corrélation TAPSE <15mm et mortalité à 3ans > 30%

- Echocardiographic composite score:

TAPSE<15 mm, RV effective systolic to diastolic duration ratio 1.5, RA area 25 cm2, RA/LA area ratio 1.5

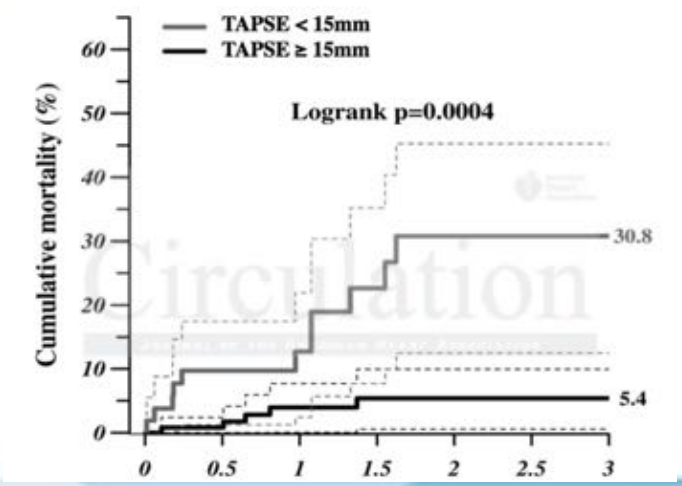

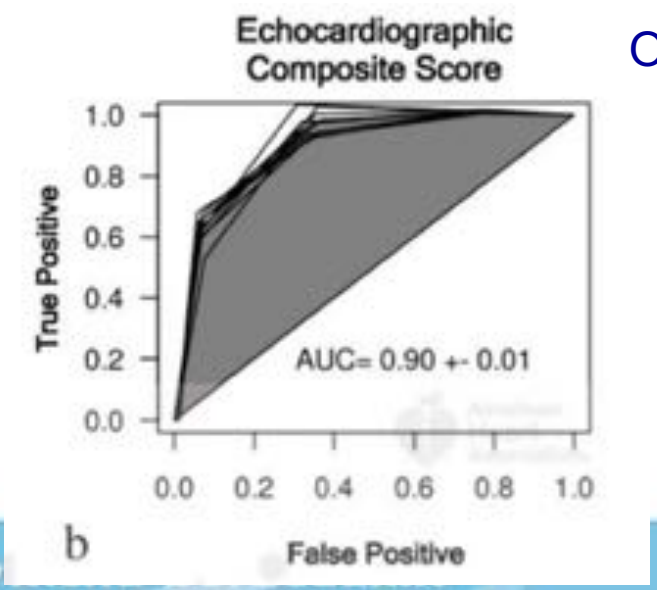

OR: 3.69

Mocéri P et al. Circulation 2012

Différence entre HTAPi et Eisenmenger

Paramètres Moyenne & IC95%	Populations		
	NORMAUX	EISNENMGER	HTAP
BNP (pg/l)	-	109,7	221,3
	-	[23,9 - 195,5]	[56,9 - 385,6]
Test de Marche de 6' (m)	-	384,5	380,5
	-	[320,6 - 448,3]	[272 - 489,1]
TAPSE (mm)	26,3	16,7	14,8
	[24,8 - 27,7]	[15 - 18,4]	[10,9 - 18,8]
SVD (cm/s)	17,5	10,9	11,1
	[16,6 - 18,3]	[9,3 - 12,6]	[8,6 - 13,5]
FRS (%)	0,3	0,4	0,3
	[0,23 - 0,30]	[0,31 - 0,42]	[0,27 - 0,38]
Indice de TEI	0,5	0,5	0,6
	[0,49 - 0,54]	[0,4 - 0,7]	[0,49 - 0,64]
Ratio SOD/SOG	0,8	1,9	1,9
	[0,73 - 0,86]	[1,4 - 2,3]	[1,4 - 2,3]
Indice Excentricité	1,0	1,4	1,5
	[0,92 - 1,04]	[1,2 - 1,7]	[1,2 - 1,7]
Strain Longitudinal (%)	-32,4	-19,1	-13,8
	[(-)33,6 - (-)31,2]	[(-)21,4 - (-)16,8]	[(-)17,8 - (-)9,82]

P=0.02

P<0.001

Iriart X, Hachemaoui I. JESFC 2014

CIV péri membraneuses

- Définition anatomique: continuité fibreuse entre la valve aortique (sup), la valve tricuspide (post)
- Fréquentes: 75%
- Fermeture spontanée: 8-35%
- Variantes anatomiques
  - Fermeture partielle par du tissu fibreux
  - CIV type Gerbode
  - Extension vers l'oulet (IAo associée)

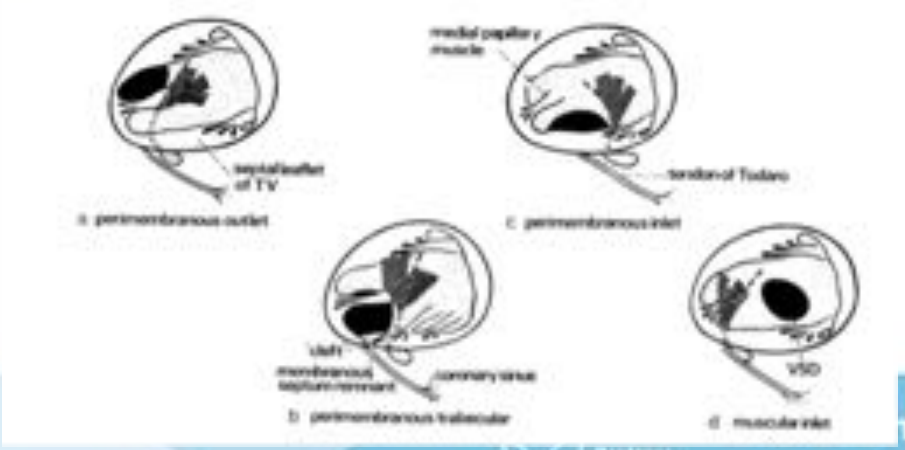

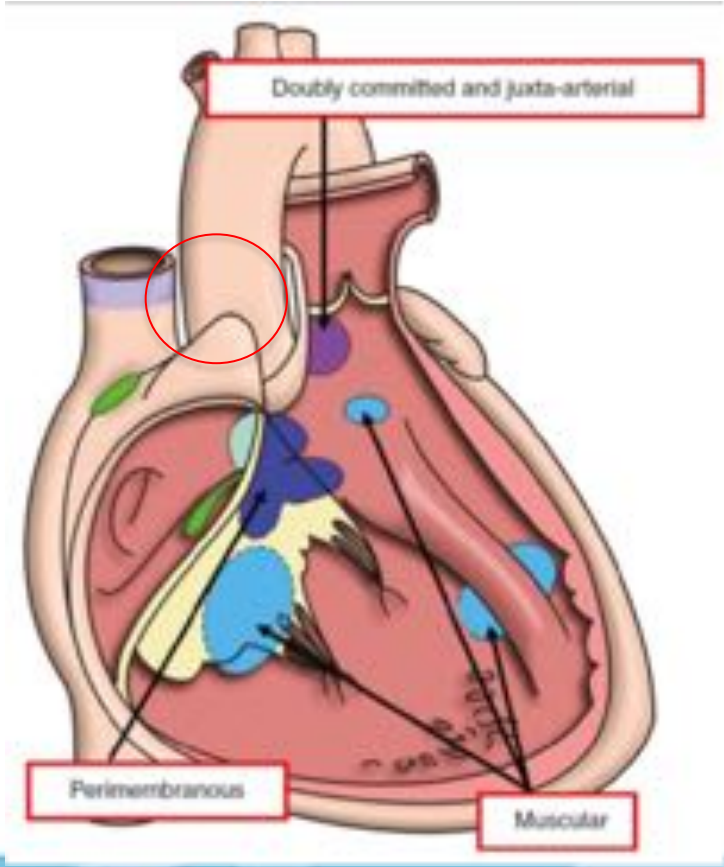

Echograhie

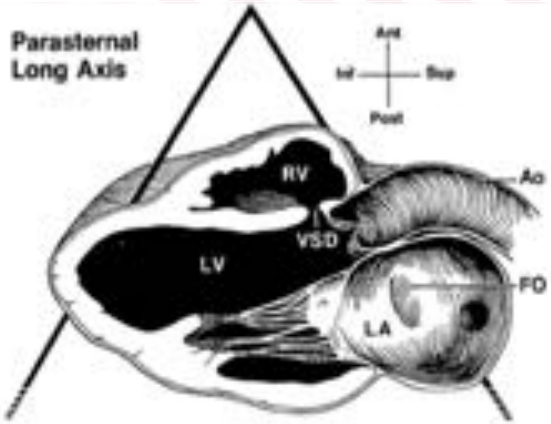
Parasternal
Long Axis
Ant
Inf
Sup
Post
RV
Ao
VSD
LV
FO
LA

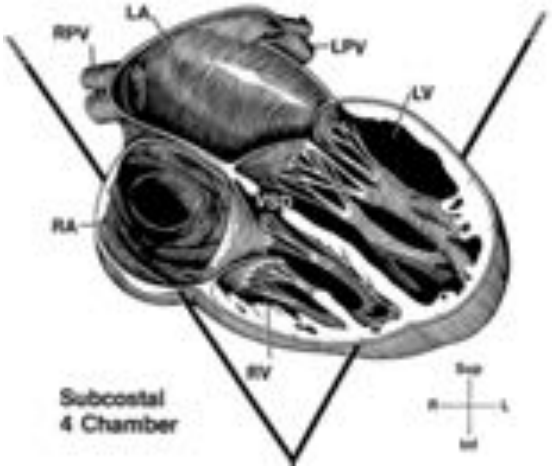
LA
RPV
LPV
LV
RA
VSD
RV
Subcostal
4 Chamber
Sup
R
L
Inf

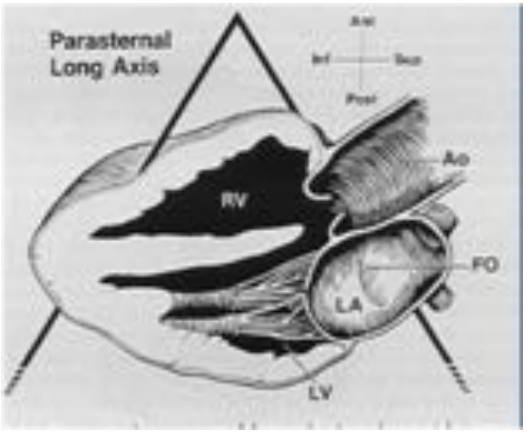
Parasternal
Long Axis
Ao
RV
FO
LA
LV

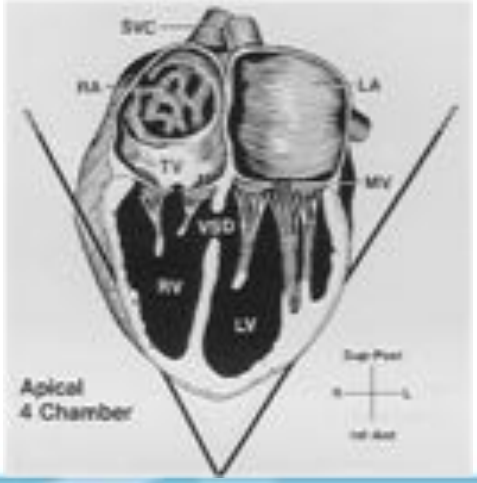
SVC
RA
LA
TV
MV
VSD
RV
LV
Apical
4 Chamber

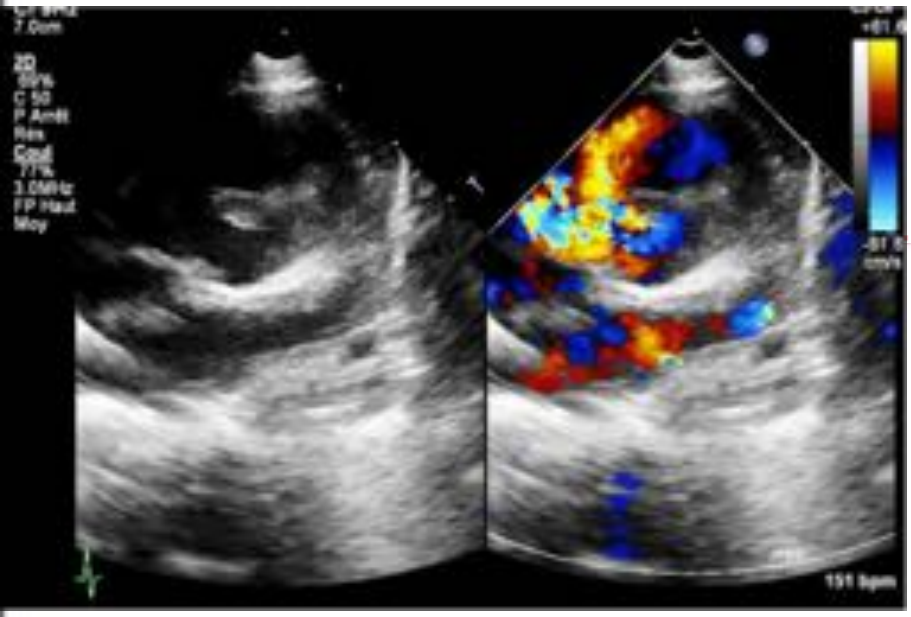
151 bpm

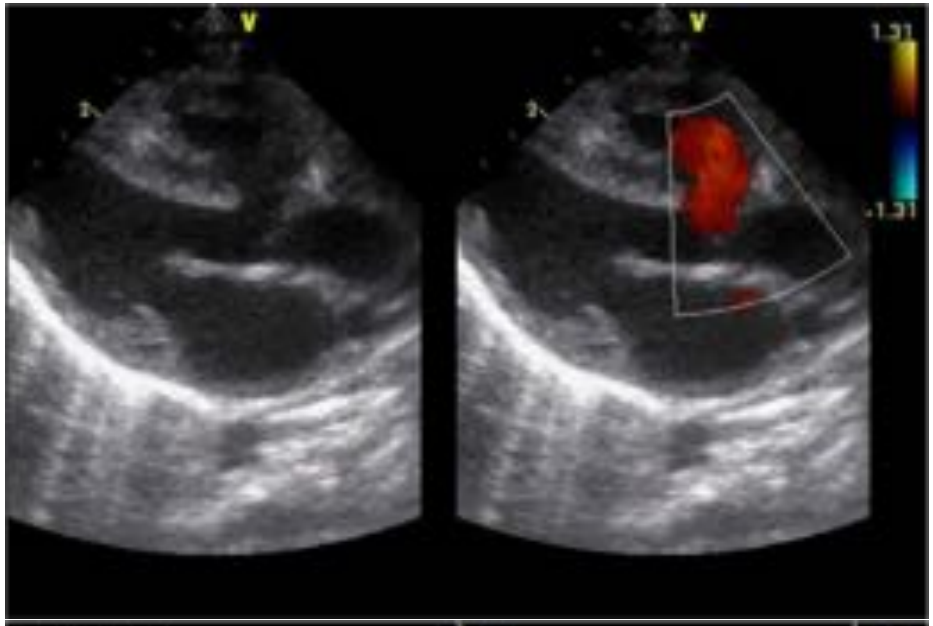

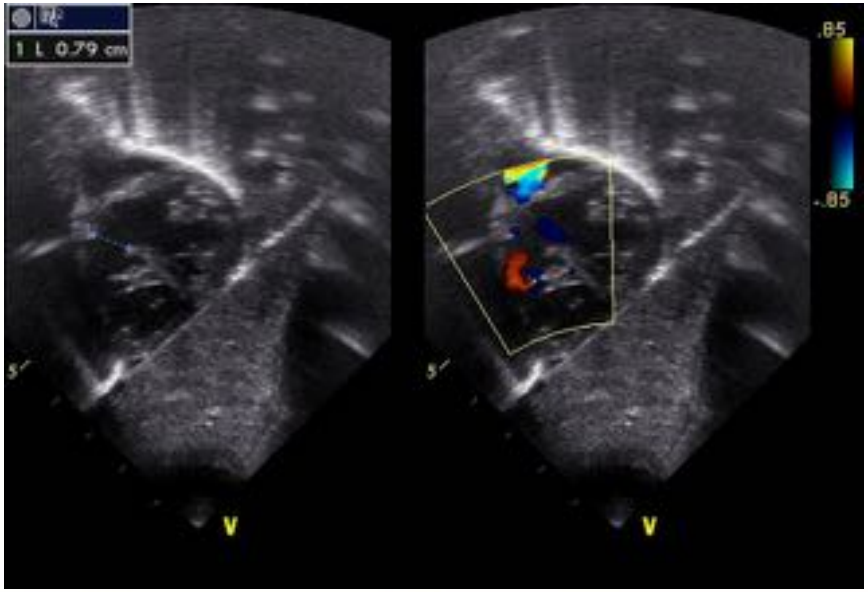
1 L 0.79 cm

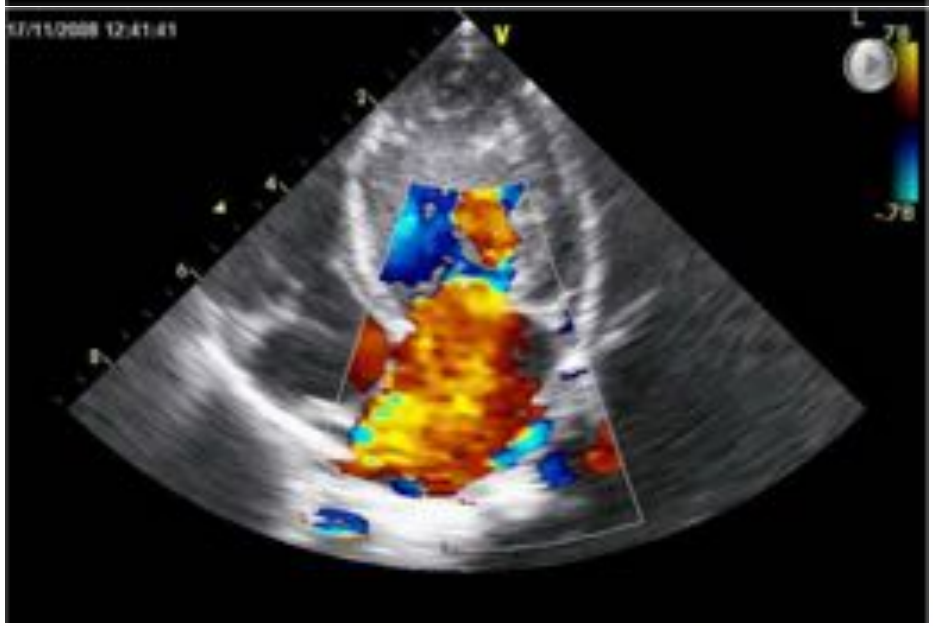

CIV 2A Adulte

Qp= ITVpulm x π ½ D^2 / Qs=ITVAo x π ½ D^2

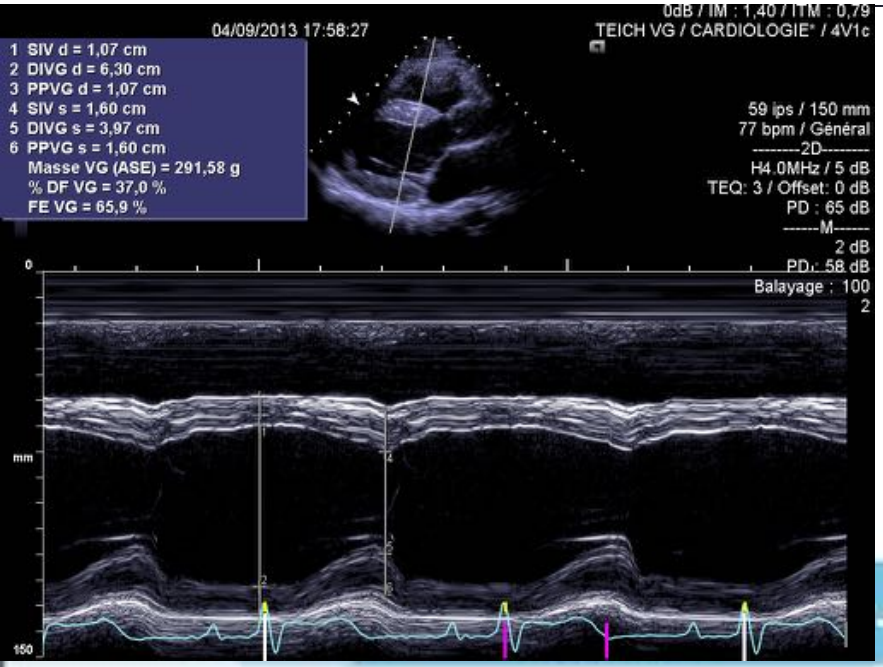

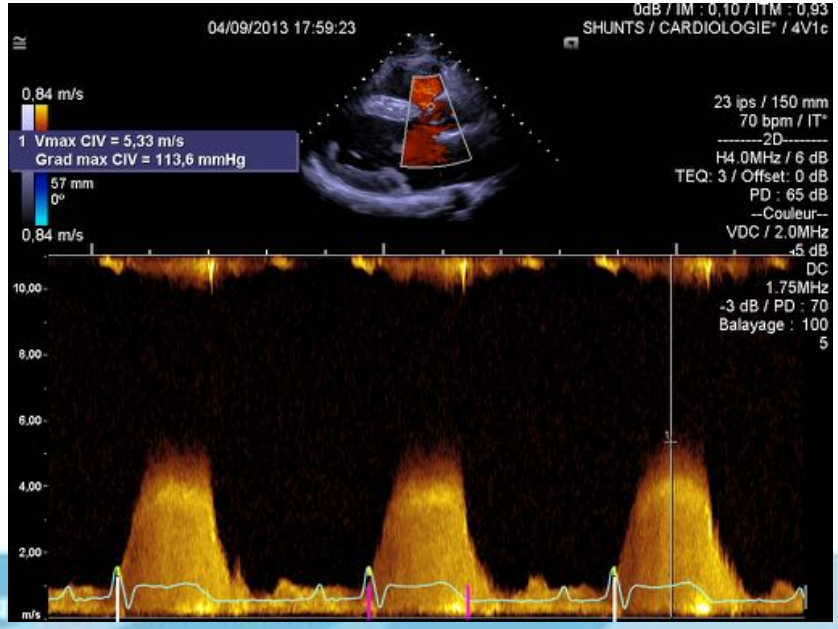

Fermeture par du tissu accessoire

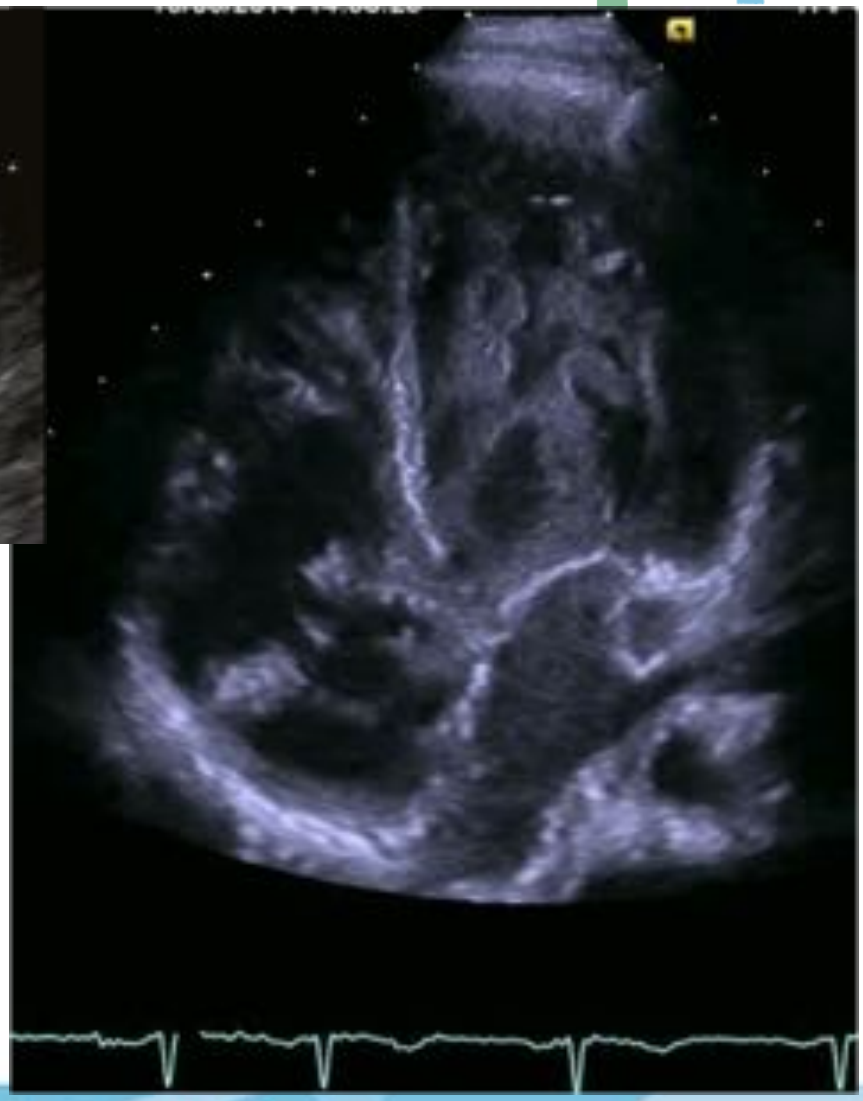

Fermeture par du tissu accessoire

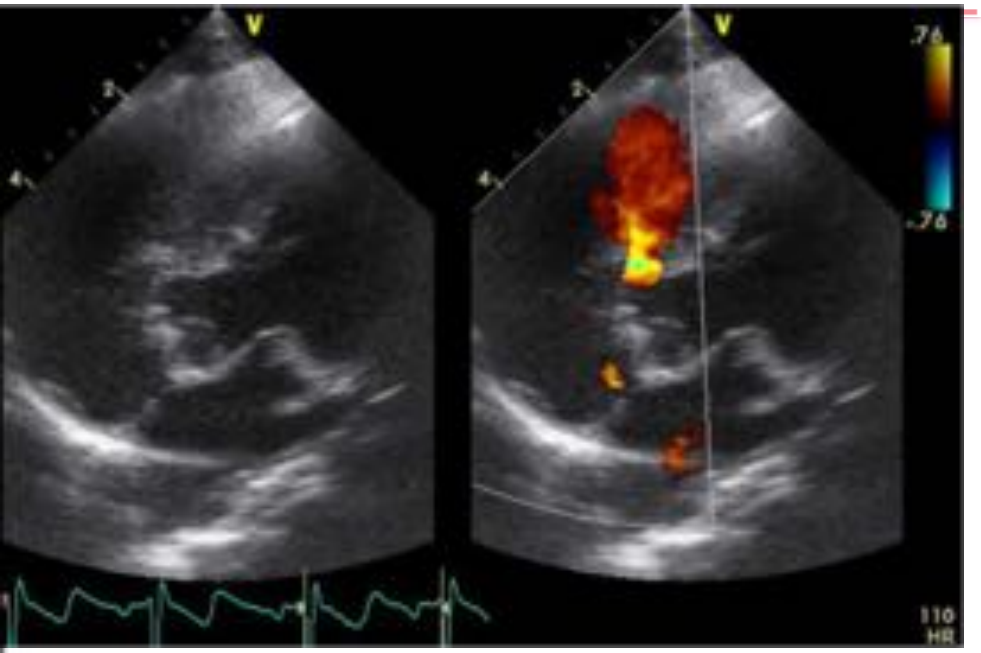

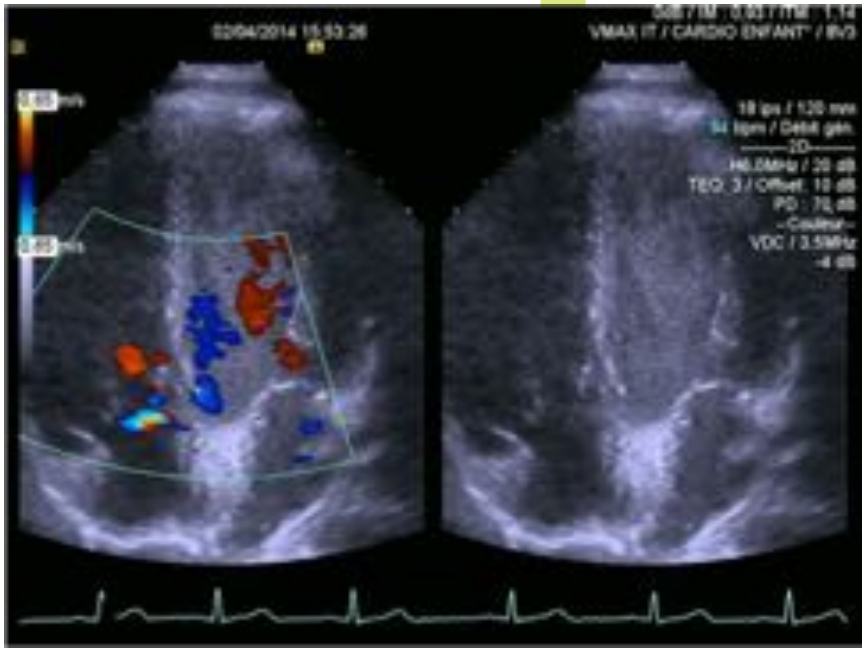

CIV par malalignement

- Déviation sur septum conal
- ± associé à un overriding de l'aorte

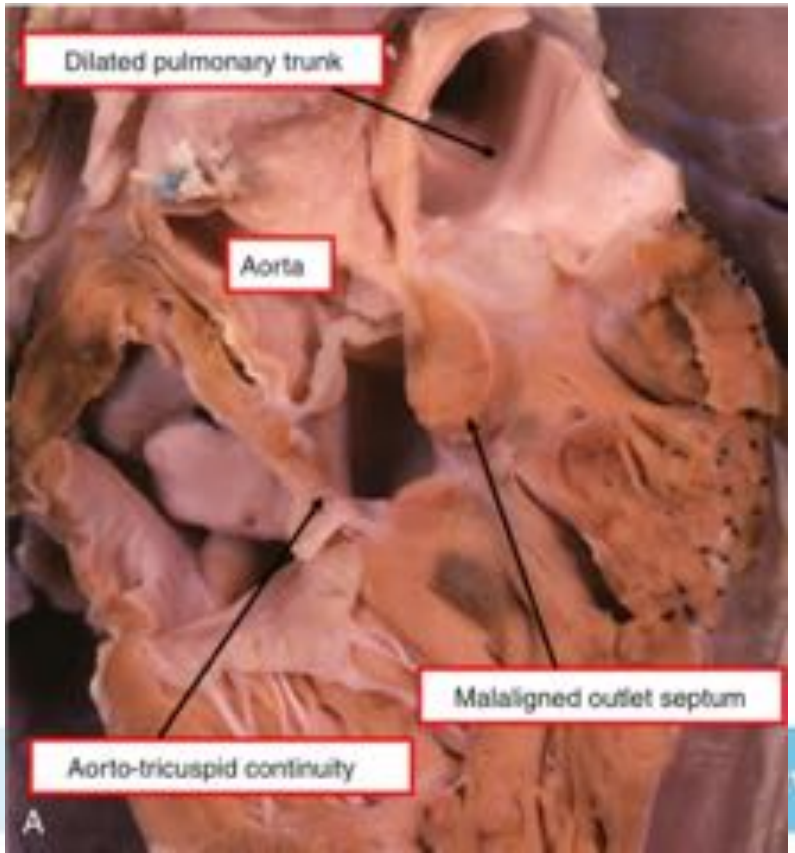

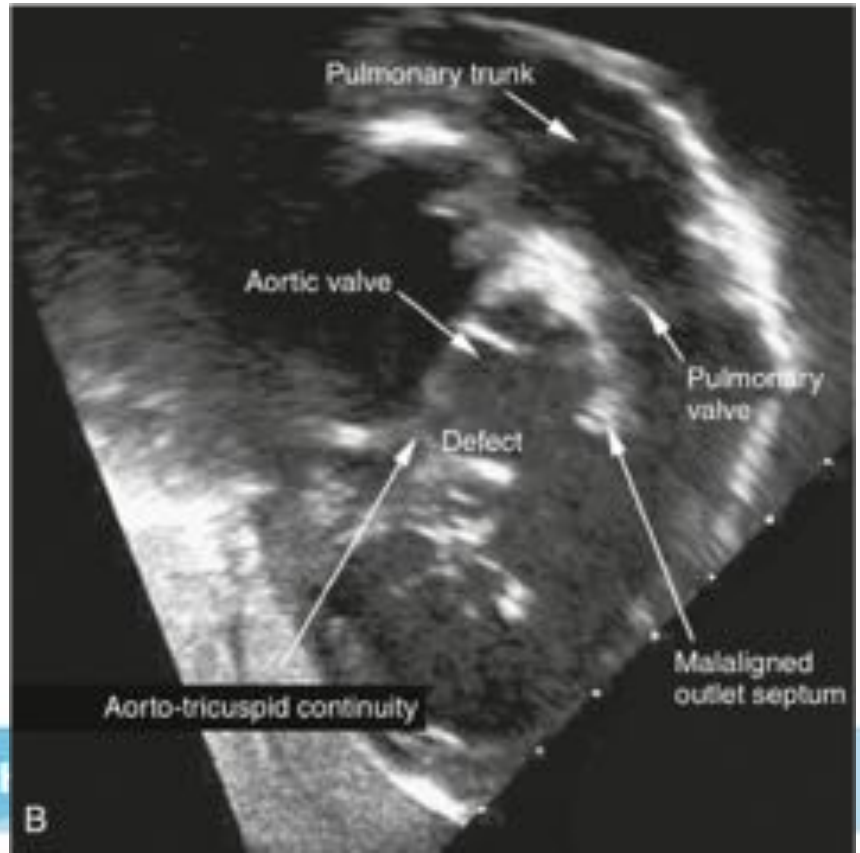

CIV par malalignement

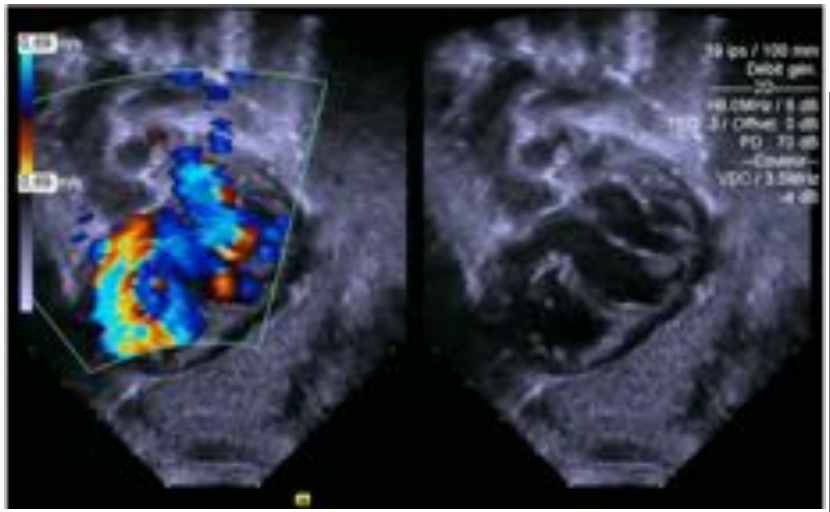

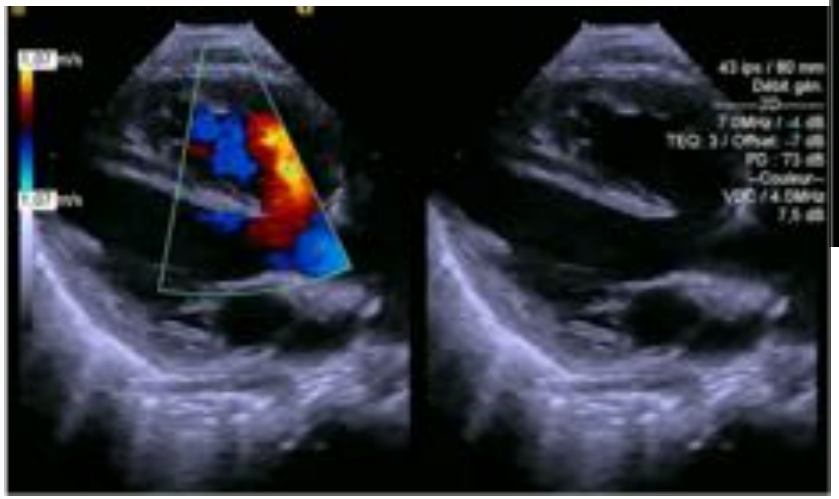

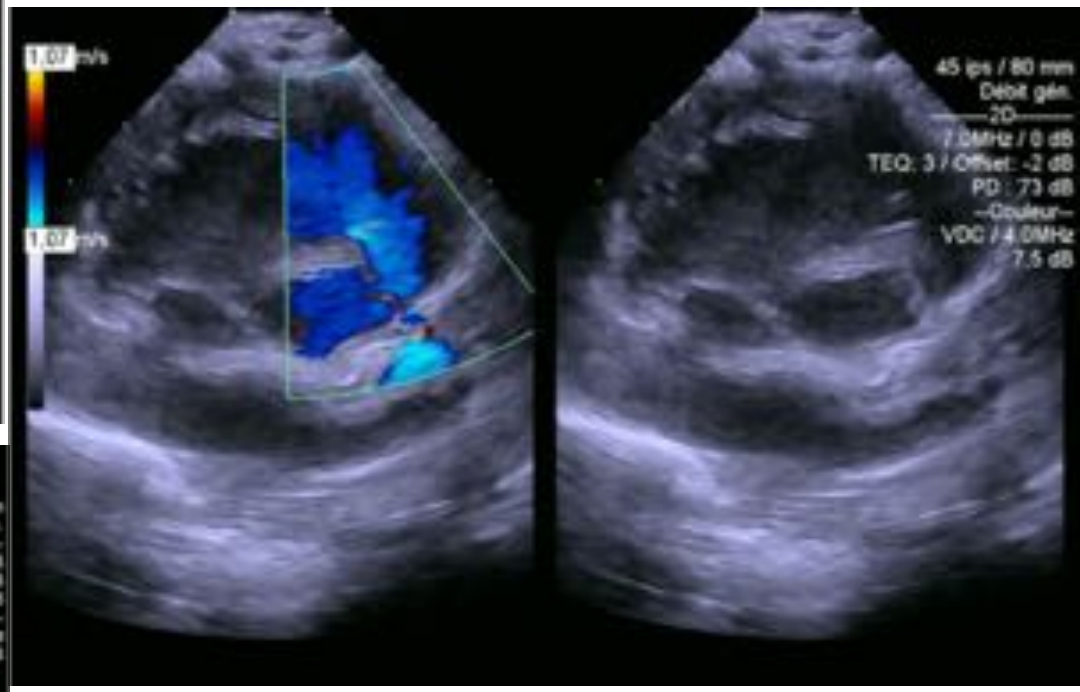

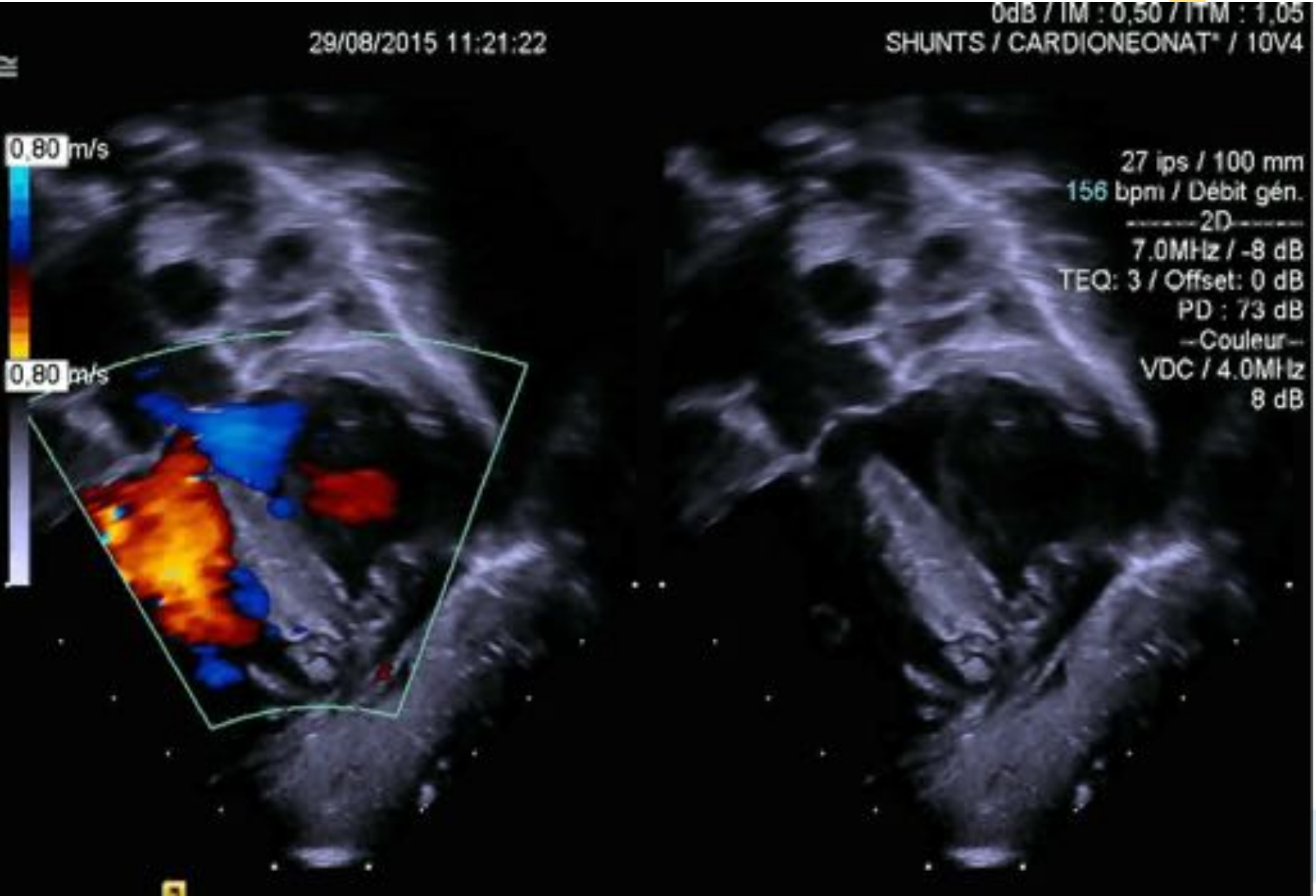
29/08/2015 11:21:22
0dB / IM : 0,50 / ITM : 1,05
SHUNTS / CARDIONEONAT® / 10V4
0,80 m/s
0,80 m/s
27 ips / 100 mm
156 bpm / Débit gén.
2D
7.0MHz / -8 dB
TEQ: 3 / Offset: 0 dB
PD : 73 dB
Couleur
VDC / 4.0MHz
8 dB

29/08/2015 11:28:44
CROSSE AO / CARDIONEONAT° / 10V4
73 ips / 100 mm
185 bpm / Général
2D
7.0MHz / 8 dB
TEQ: 3 / Offset: 0 dB
PD : 73 dB

29/08/2015 11:31:11
TAPSE / CARDIONEONAT° / 10V
73 ips / 100 m
162 bpm / Génér
2D
7.0MHz / 6
TEQ: 3 / Offset: 0
PD : 73

CIV et membrane sous aortique

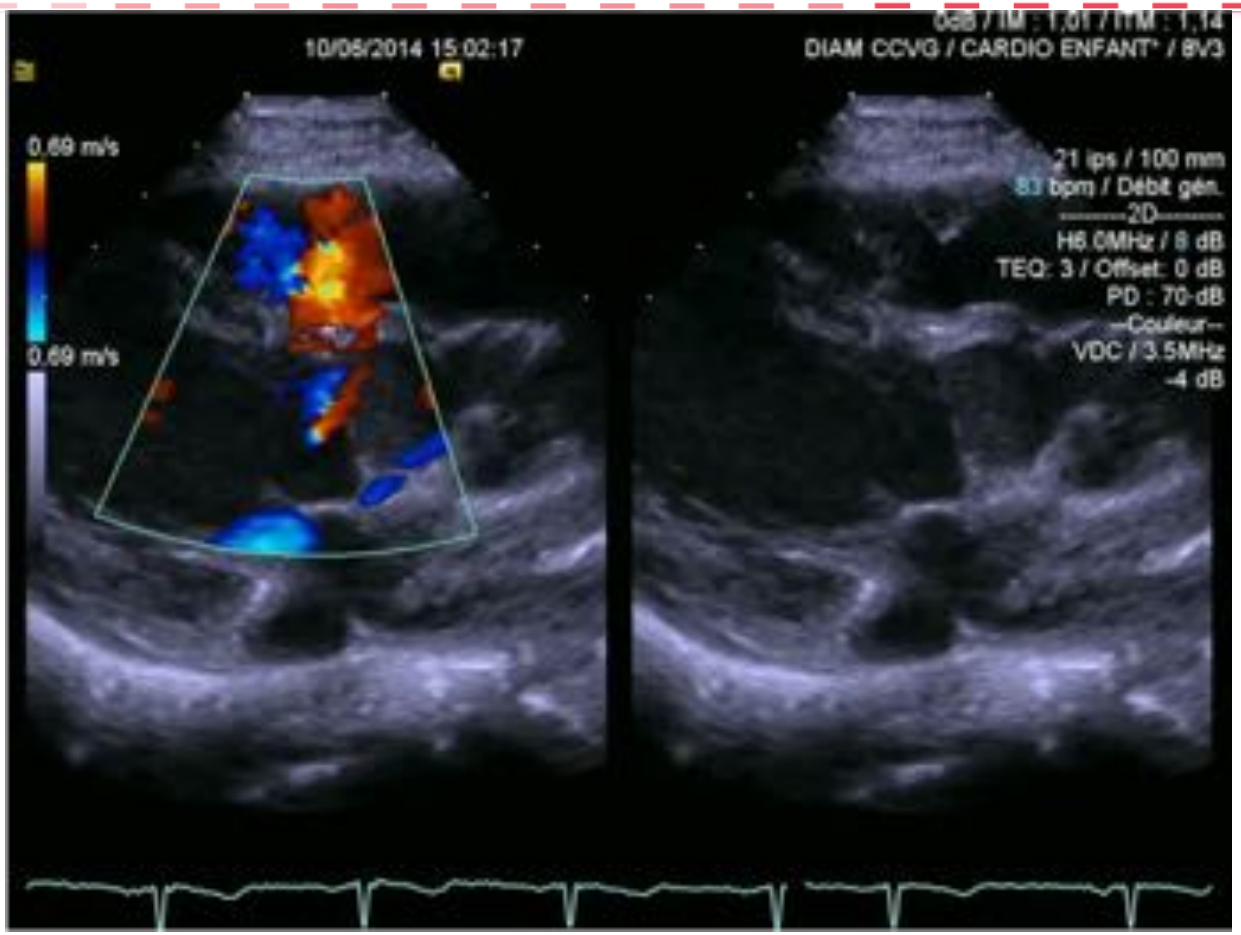

CIV et obstacle intra VD

- Epaississement des bandes musculaires
- Lésions fibreuses

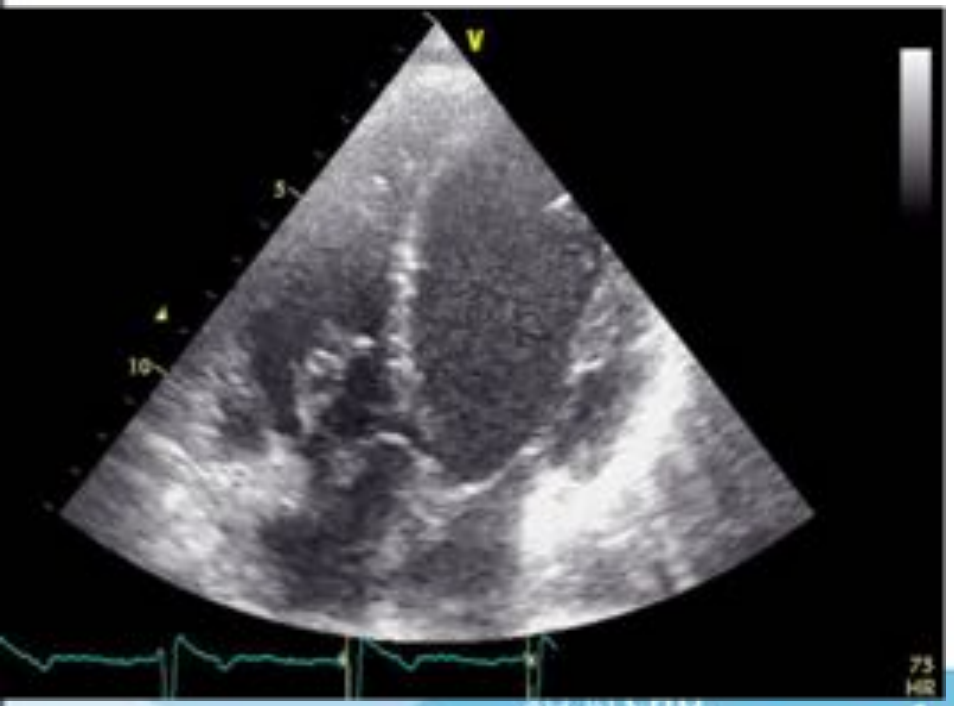

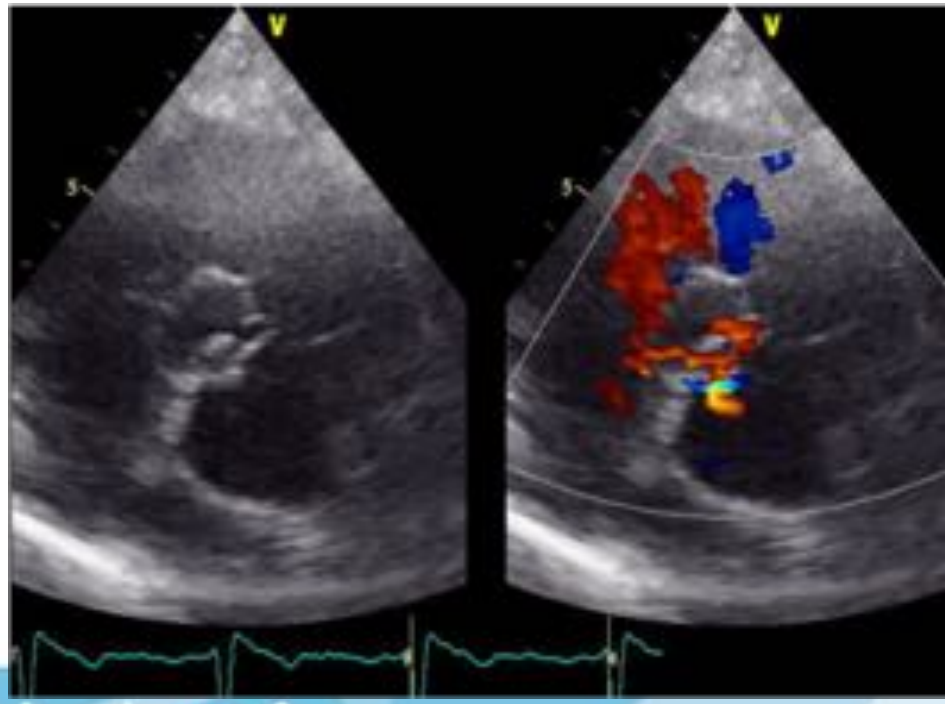

v 4.47 m/s
p 79.78 mmHg
[m/s]
78
HR
1 IT Vmax 4.44 m/s
IT GDmax 78.9 mmHg
[m/s]
78
HR

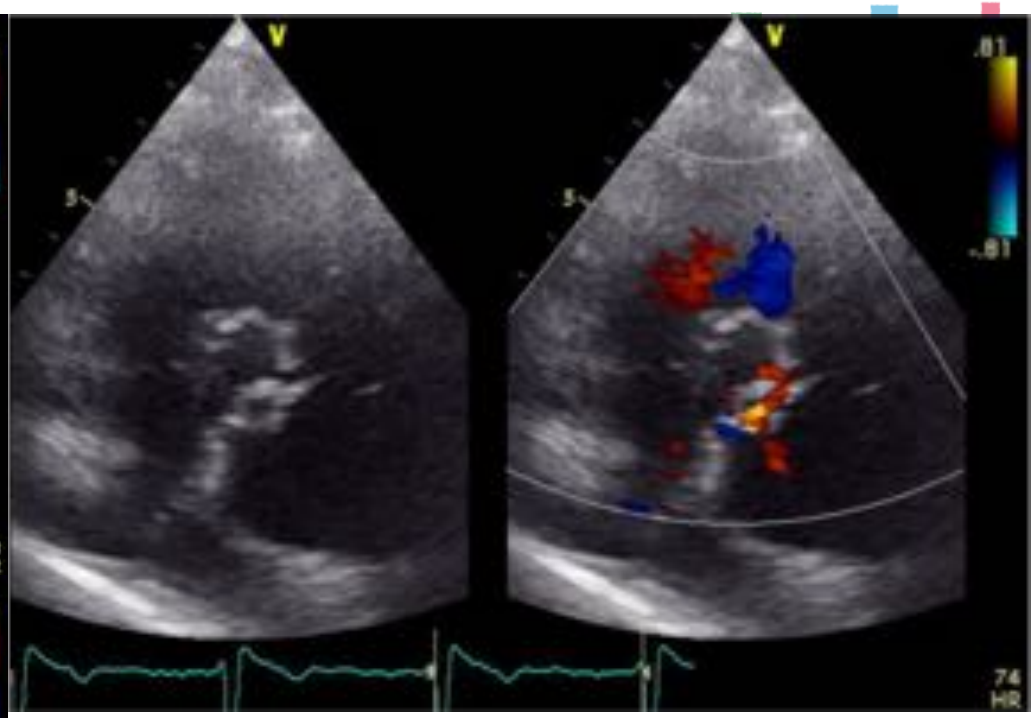
74
HR

.87
-.87
131

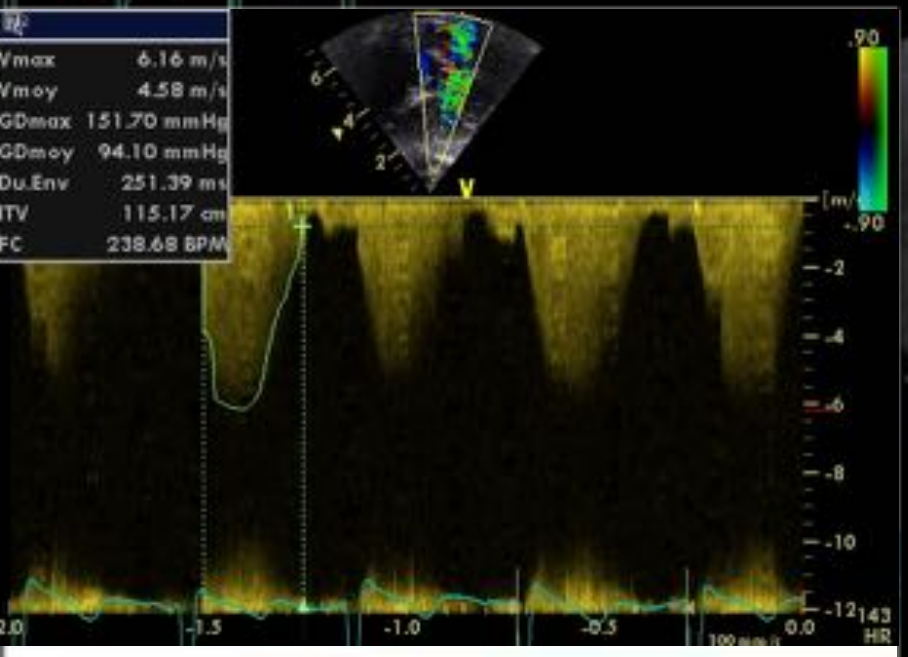
Vmax 6.16 m/s
Vmoy 4.58 m/s
GDmax 151.70 mmHg
GDmoy 94.10 mmHg
Du.Env 251.39 ms
ITV 115.17 cm
FC 238.68 BPM
.90
-.90
-2
-4
-6
-8
-10
-12
143
HR
-1.5
-1.0
-0.5
0.0

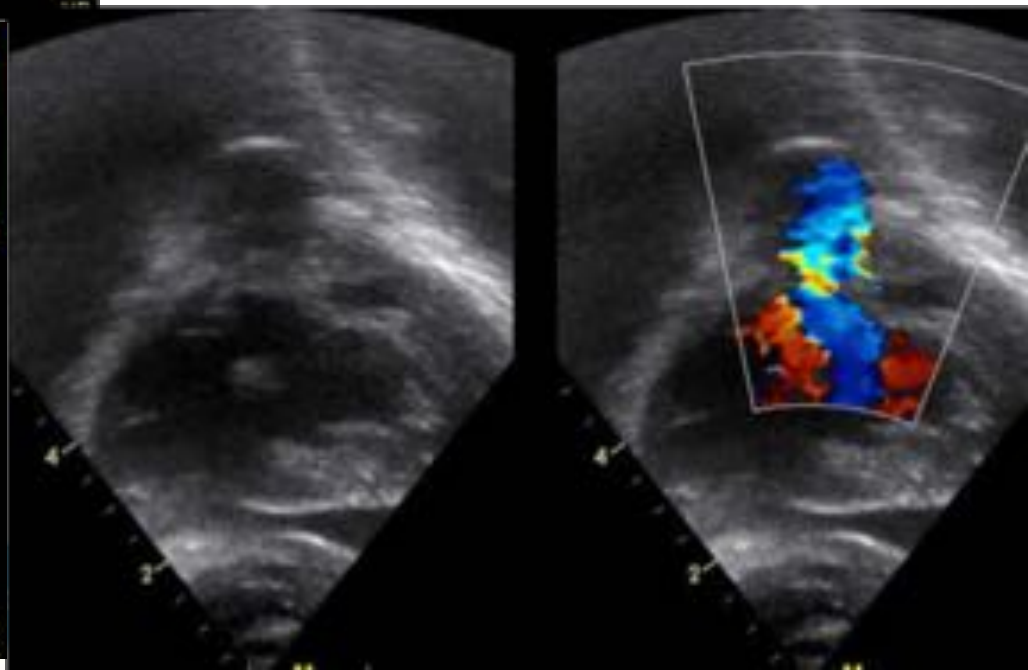

Syndrome d'Eisenmenger

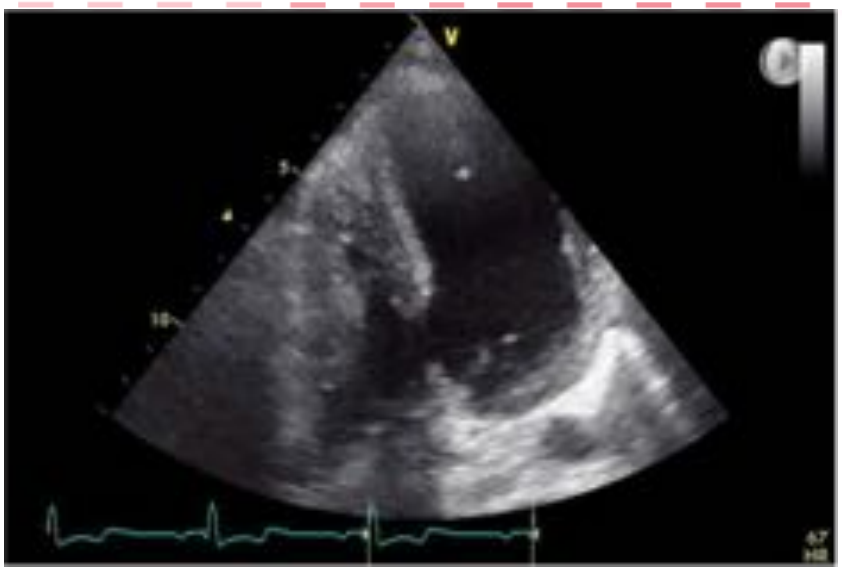

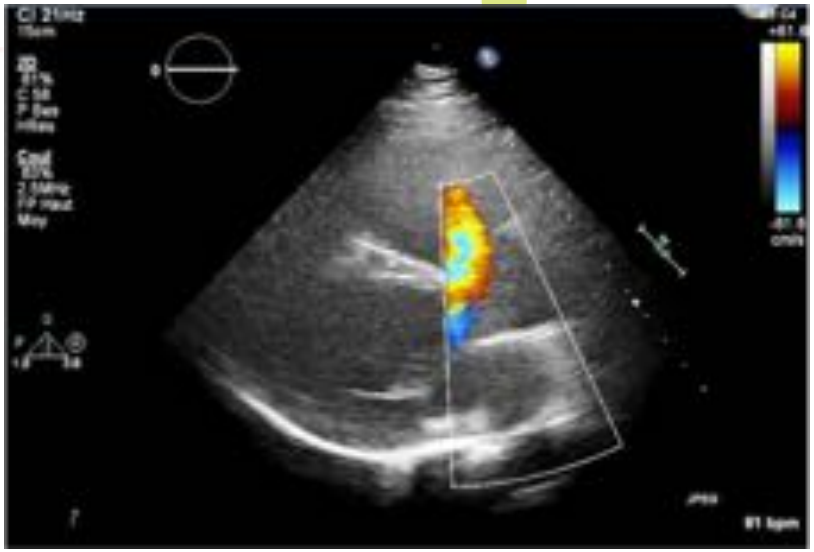

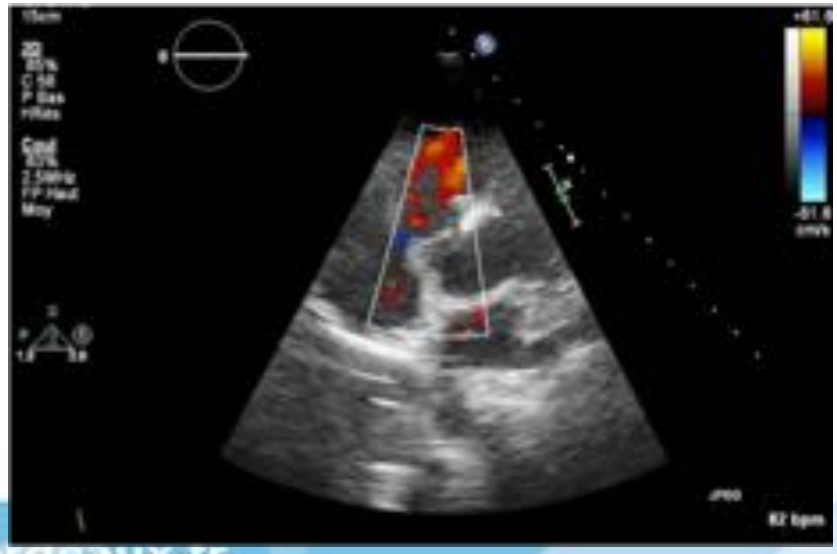

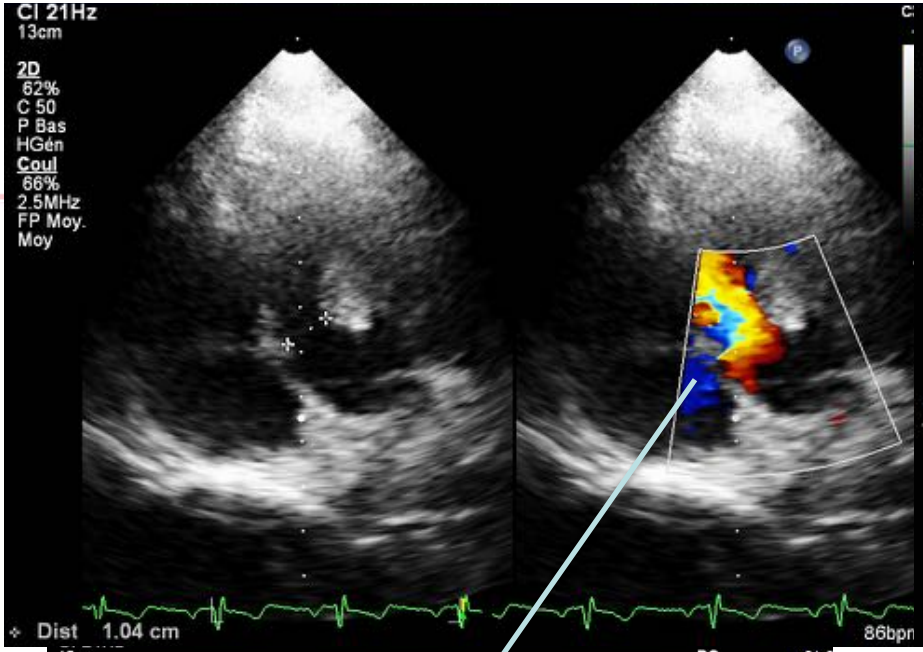
CI 21Hz
13cm
2D
62%
C 50
P Bas
HGén
Coul
66%
2.5MHz
FP Moy.
Moy
Dist 1.04 cm
86bpm

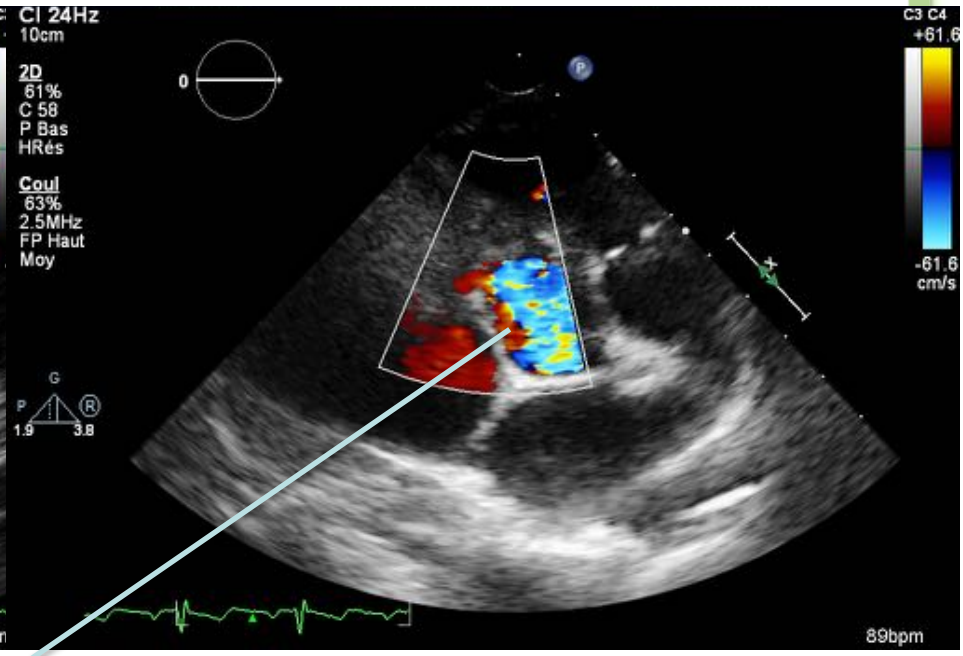
CI 24Hz
10cm
2D
61%
C 58
P Bas
HRés
Coul
63%
2.5MHz
FP Haut
Moy
C3 C4
+61.6
-61.6
cm/s
1.9
3.8
89bpm

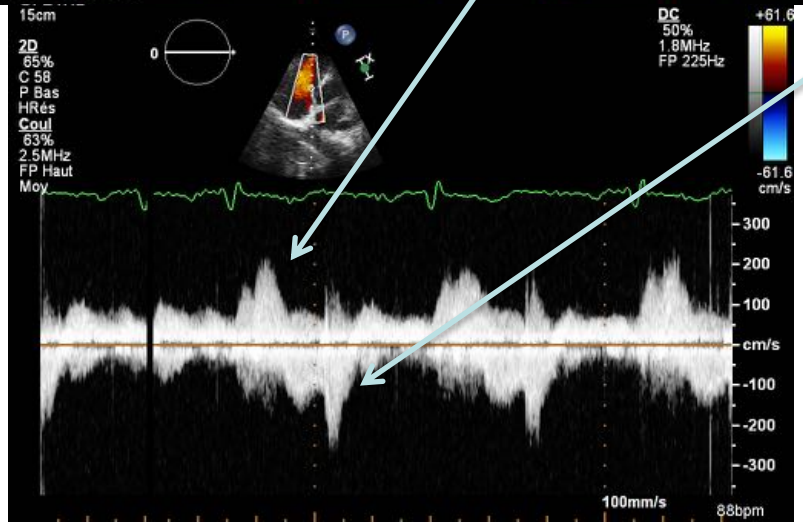
15cm
2D
65%
C 58
P Bas
HRés
Coul
63%
2.5MHz
FP Haut
Moy
DC
50%
1.8MHz
FP 225Hz
+61.6
-61.6
cm/s
300
200
100
cm/s
-100
-200
-300
100mm/s
88bpm

CIV type Gerbode

- 2 types anatomiques

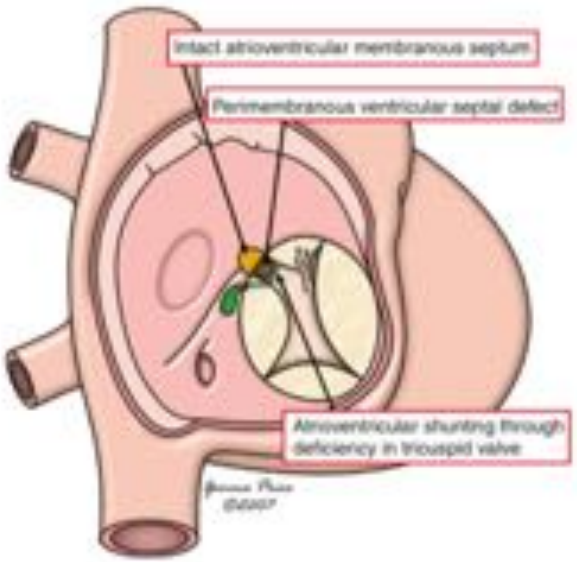

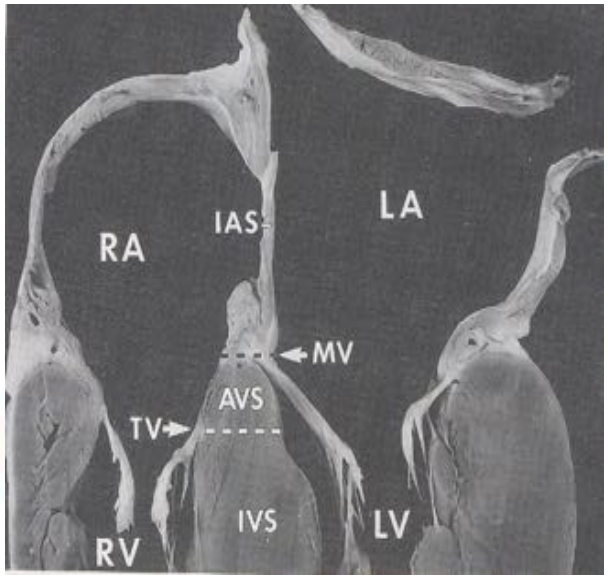

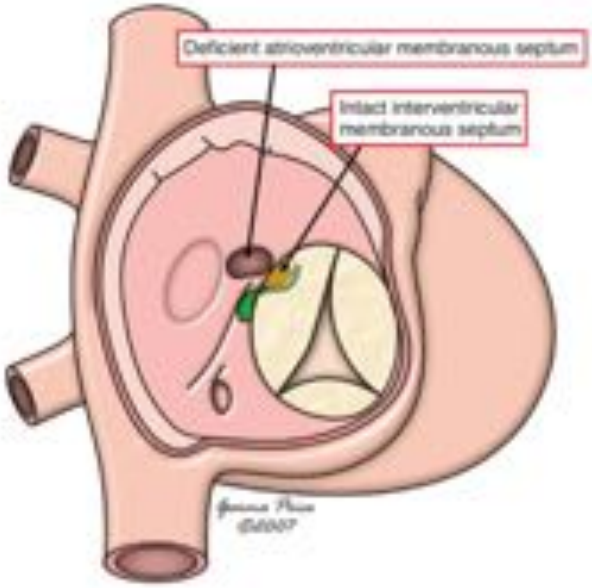

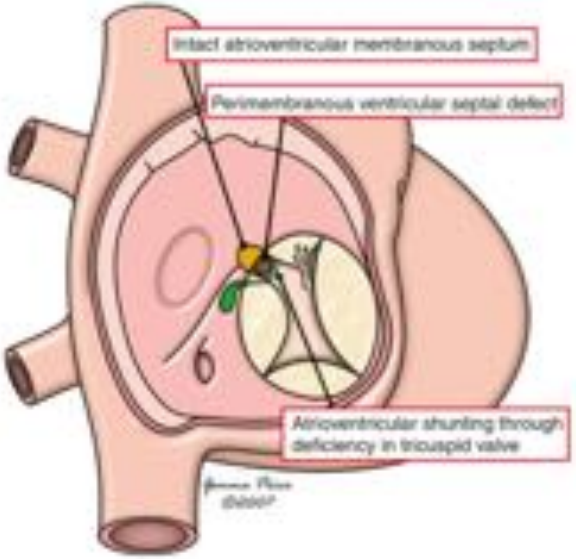

- Fente/perforation de la valve septale
- Adhérence de la valve sur la CIV
- Élargissement de la commissure AS

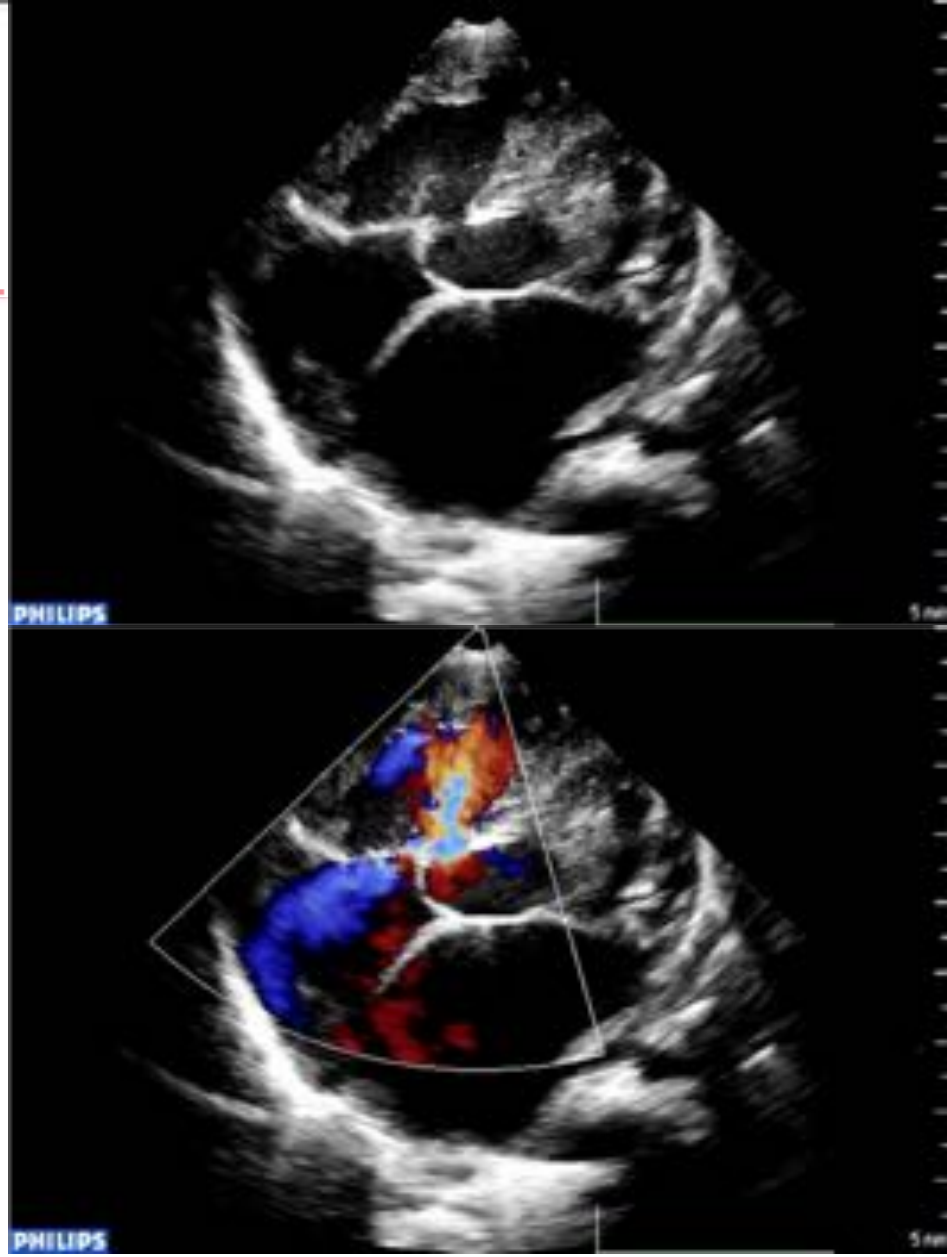

Courtesy PE Séguéla

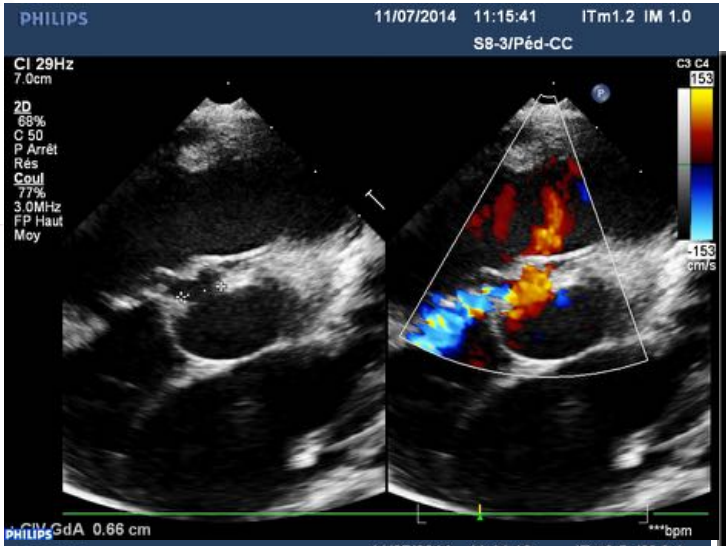

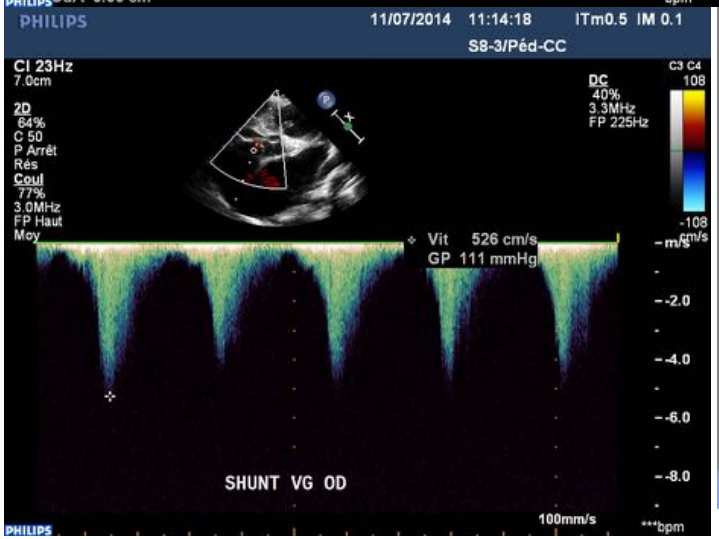

Courtesy PE Séguéla

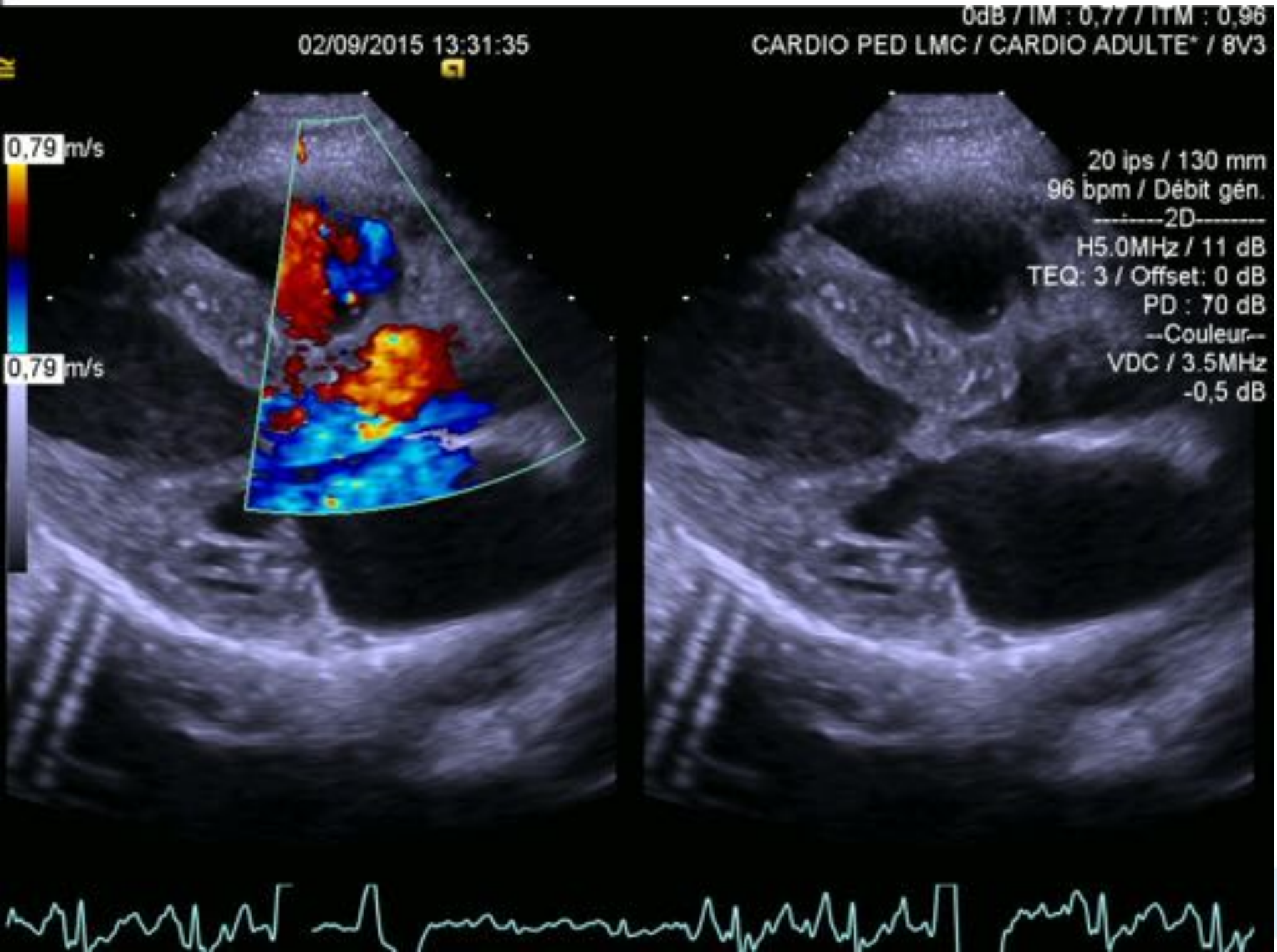
0dB / IM : 0,77 / TIM : 0,96
02/09/2015 13:31:35
CARDIO PED LMC / CARDIO ADULTE* / 8V3
0,79 m/s
0,79 m/s
20 ips / 130 mm
96 bpm / Débit gén.
--------2D--------
H5.0MHz / 11 dB
TEQ: 3 / Offset: 0 dB
PD : 70 dB
--Couleur--
VDC / 3.5MHz
-0,5 dB

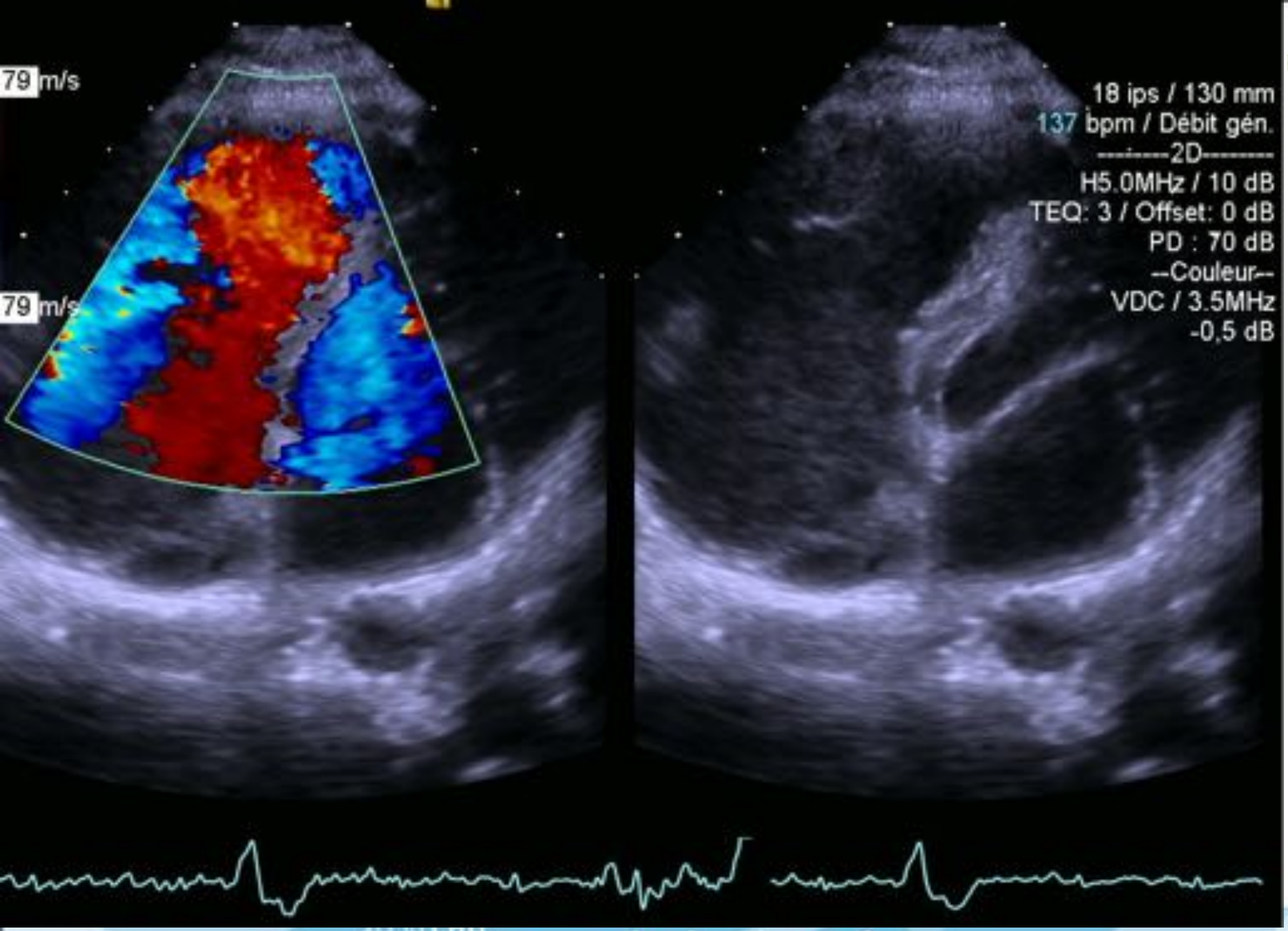
79 m/s
79 m/s
18 ips / 130 mm
137 bpm / Débit gén.
----------2D----------
H5.0MHz / 10 dB
TEQ: 3 / Offset: 0 dB
PD : 70 dB
--Couleur--
VDC / 3.5MHz
-0,5 dB

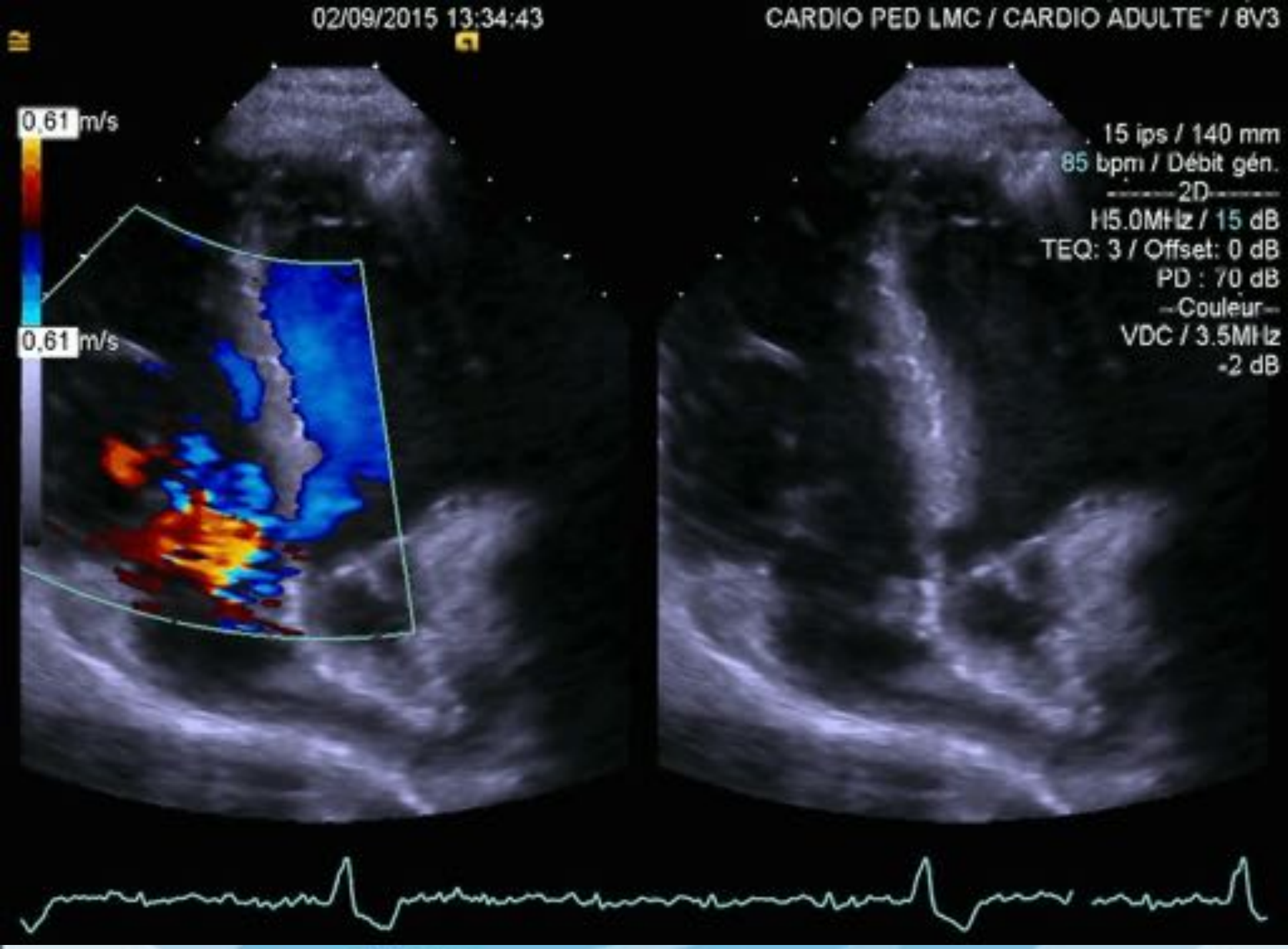
02/09/2015 13:34:43
CARDIO PED LMC / CARDIO ADULTE* / 8V3
0,61 m/s
0,61 m/s
15 ips / 140 mm
85 bpm / Débit gén.
2D
H5.0MHz / 15 dB
TEQ: 3 / Offset: 0 dB
PD : 70 dB
Couleur
VDC / 3.5MHz
-2 dB

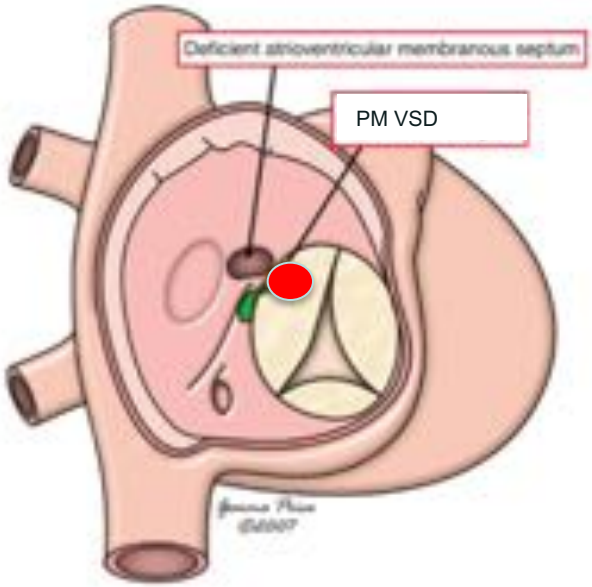

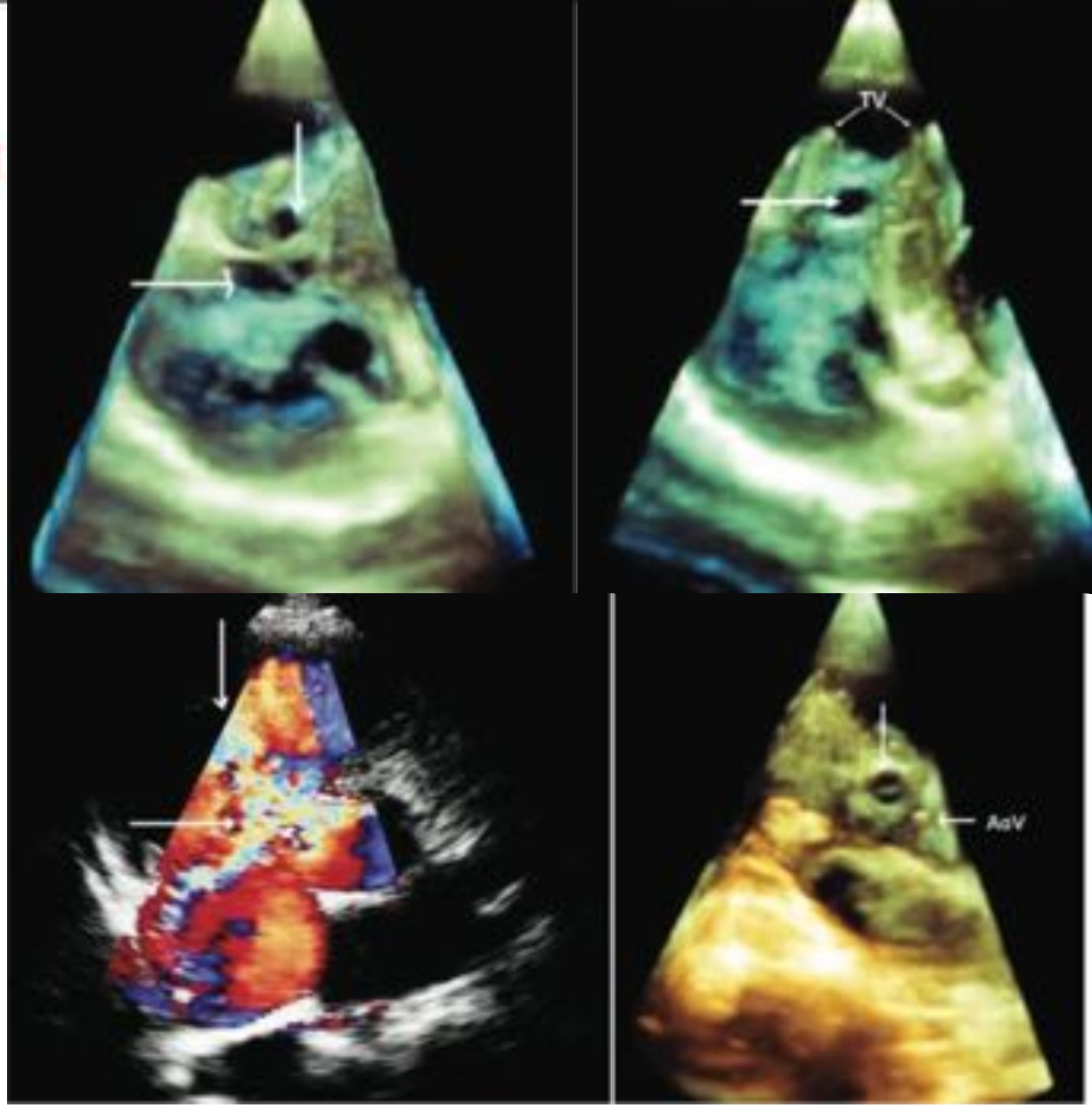

Acar P, Seguela PE, Hascoet S. Echography 2011

CIV post-opératoires

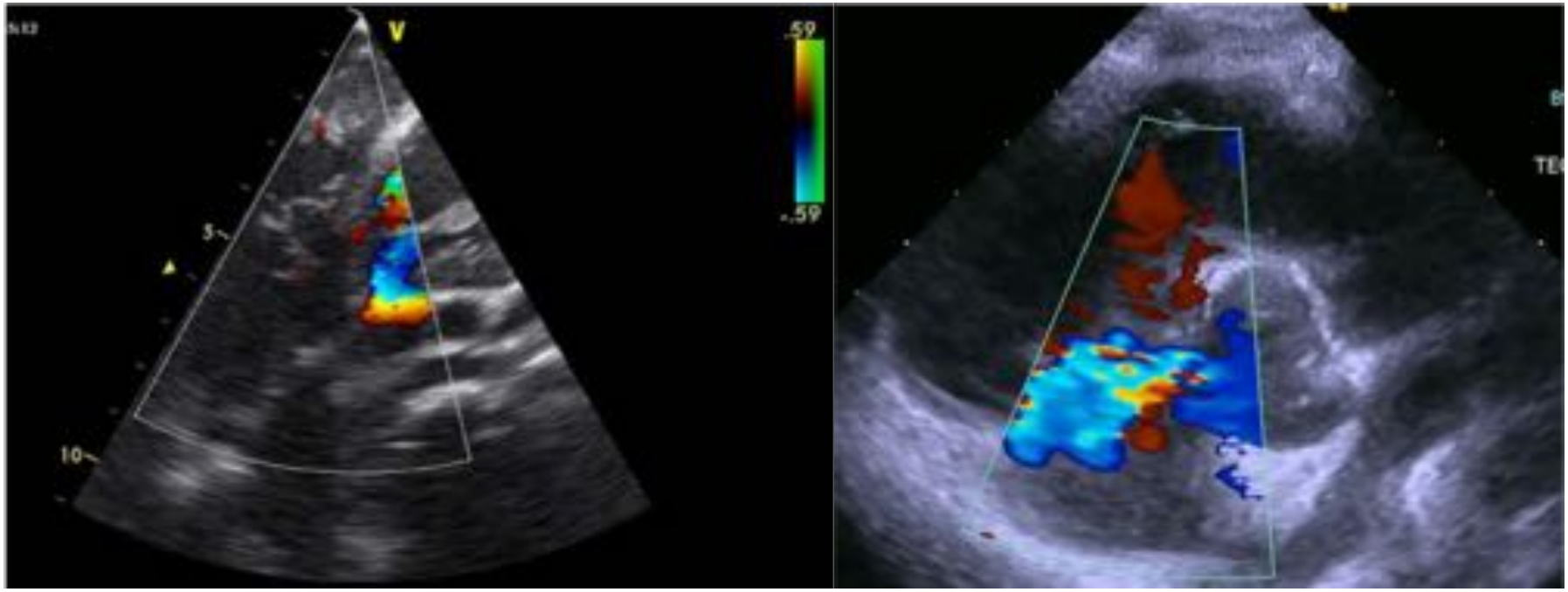

Complication exceptionnelle

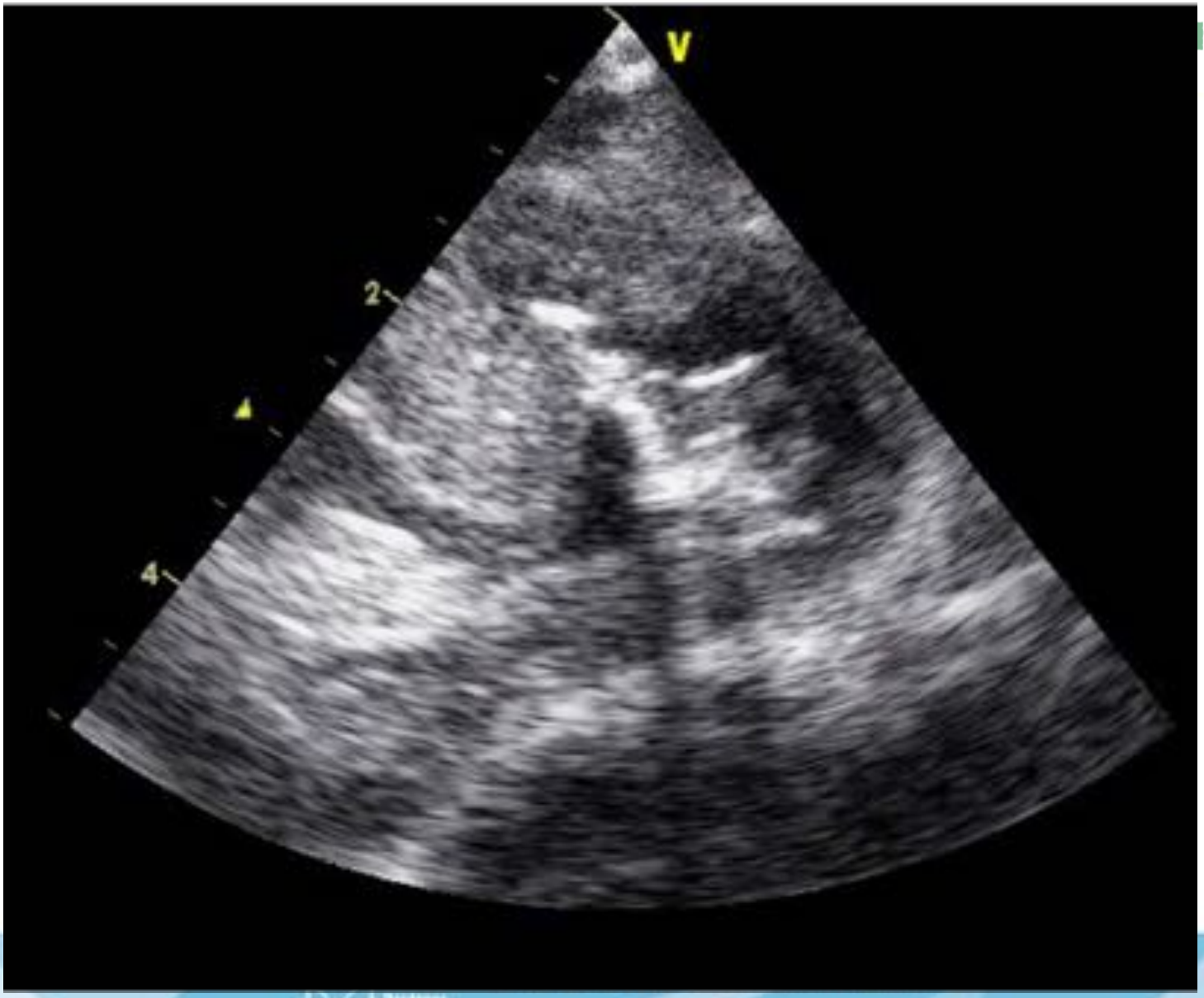

CIV atypique

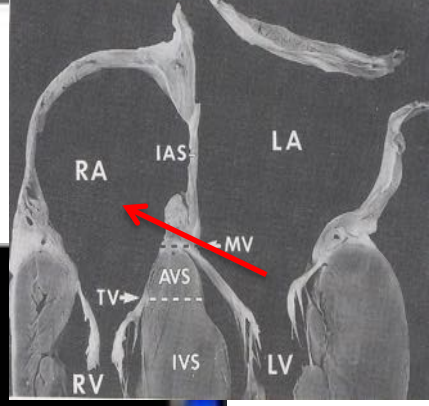

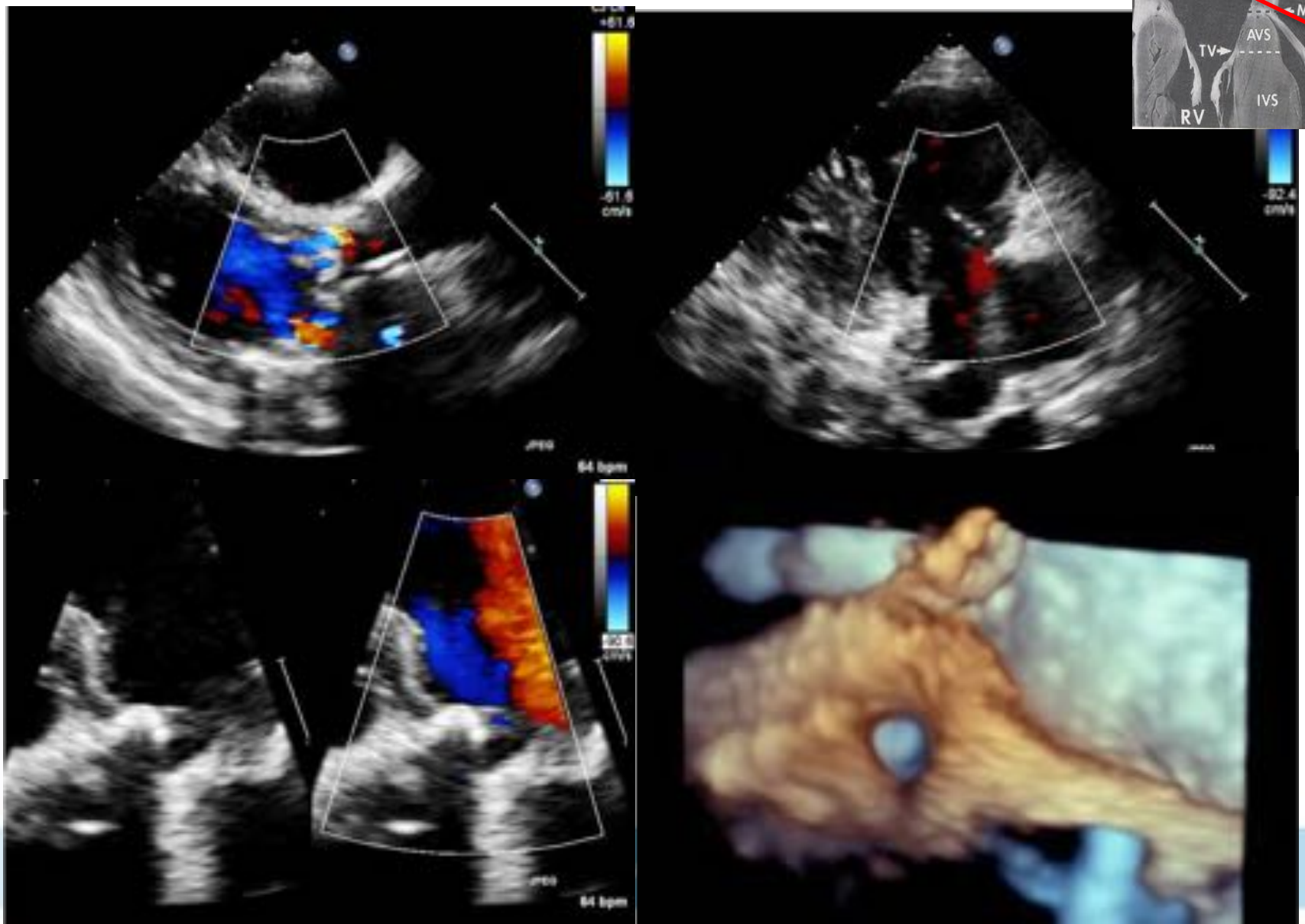

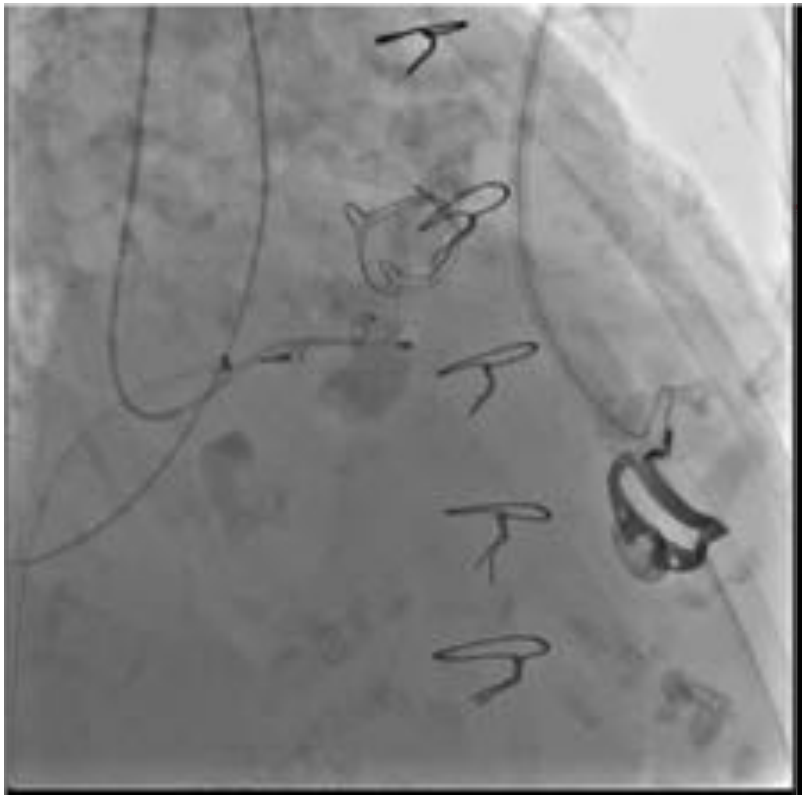

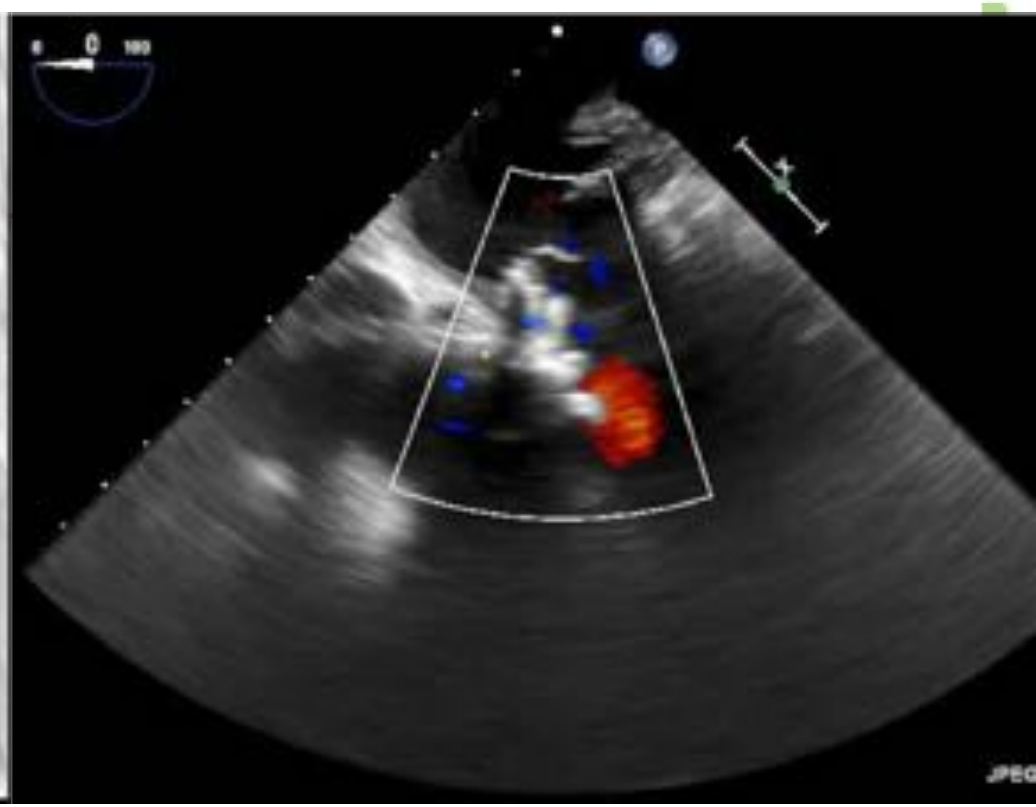

CIV musculaires

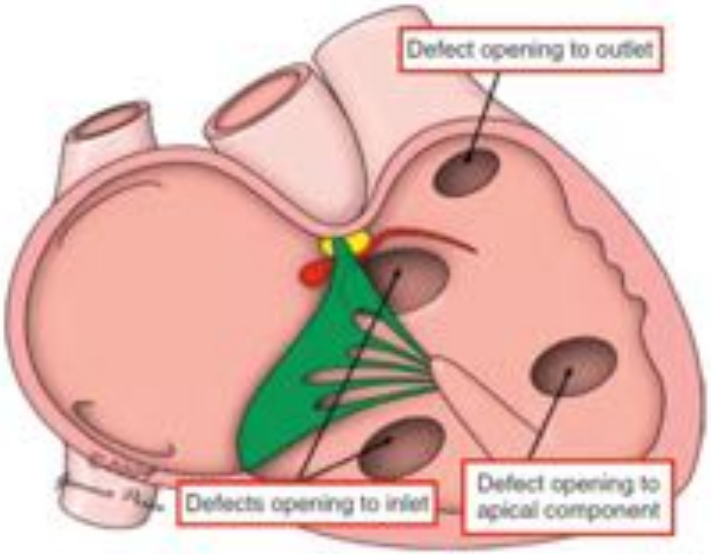

- 10% des CIV
- Berges uniquement musculaires
- Unique ou multiples (souvent)
- Tendance à la fermeture spontanée (76-89%)
- Localisation variable
  - Inlet
  - Oulet
  - Trabeculées (unique/swiss cheese)

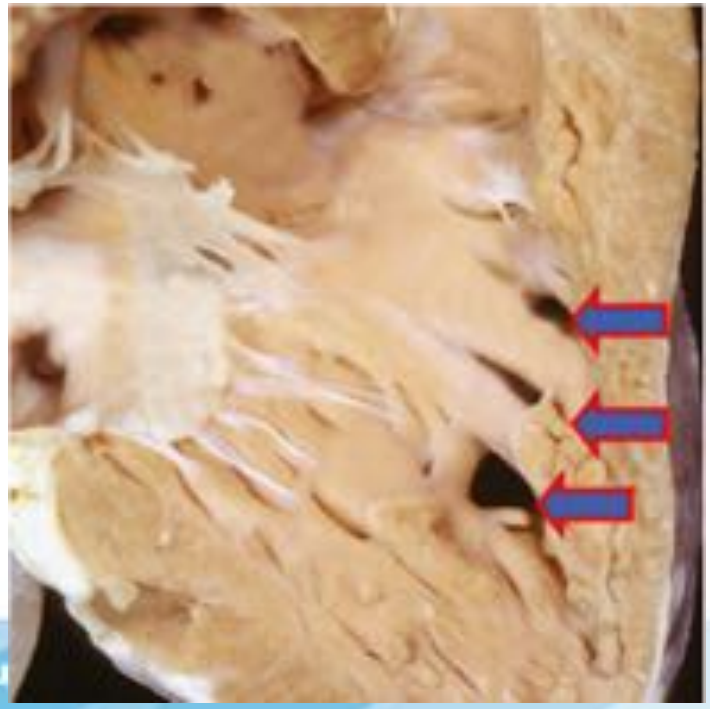

Echographie

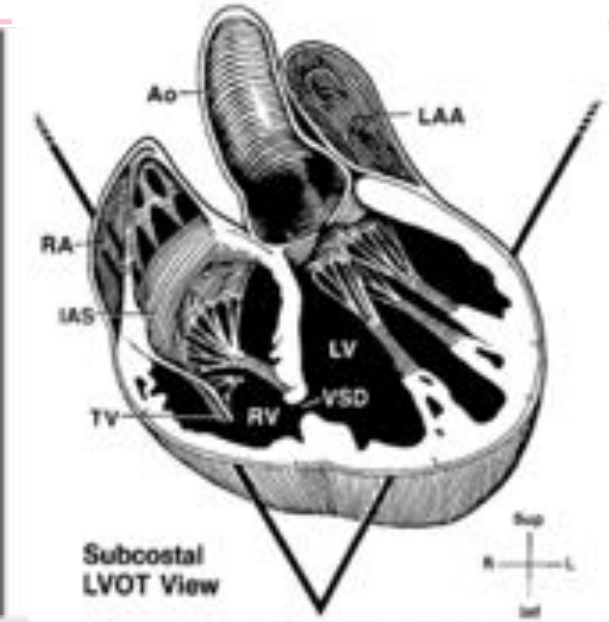

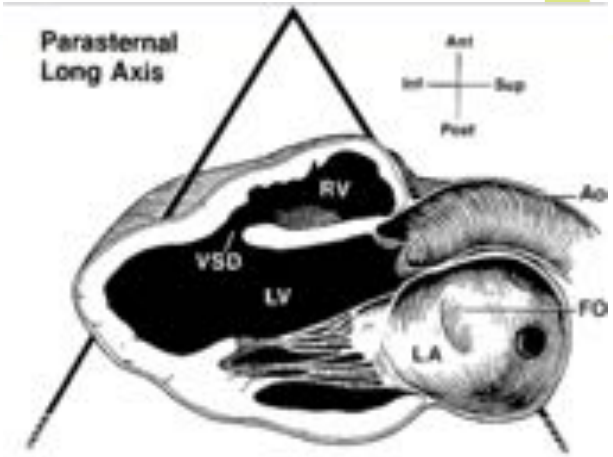

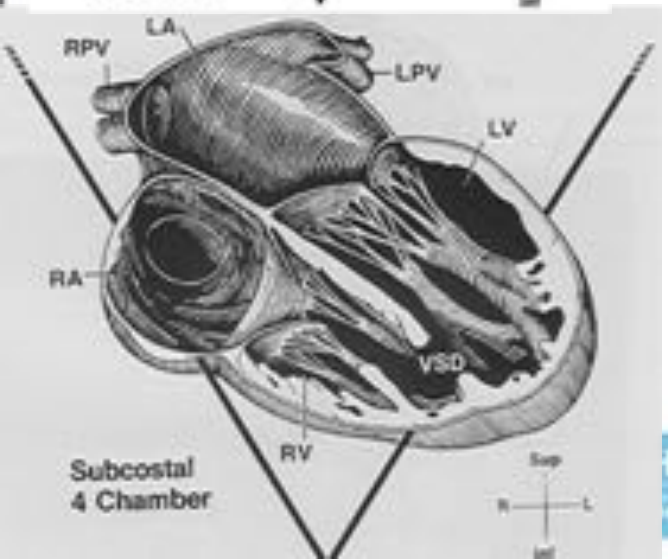

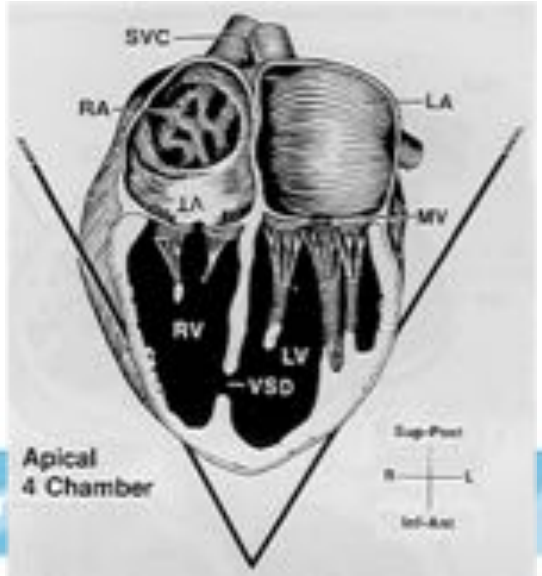

CIV musculaires

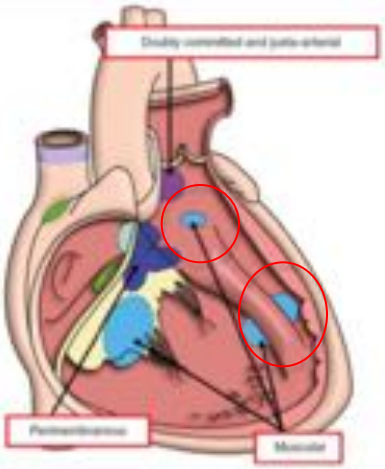

CIV musculaire de l'outlet

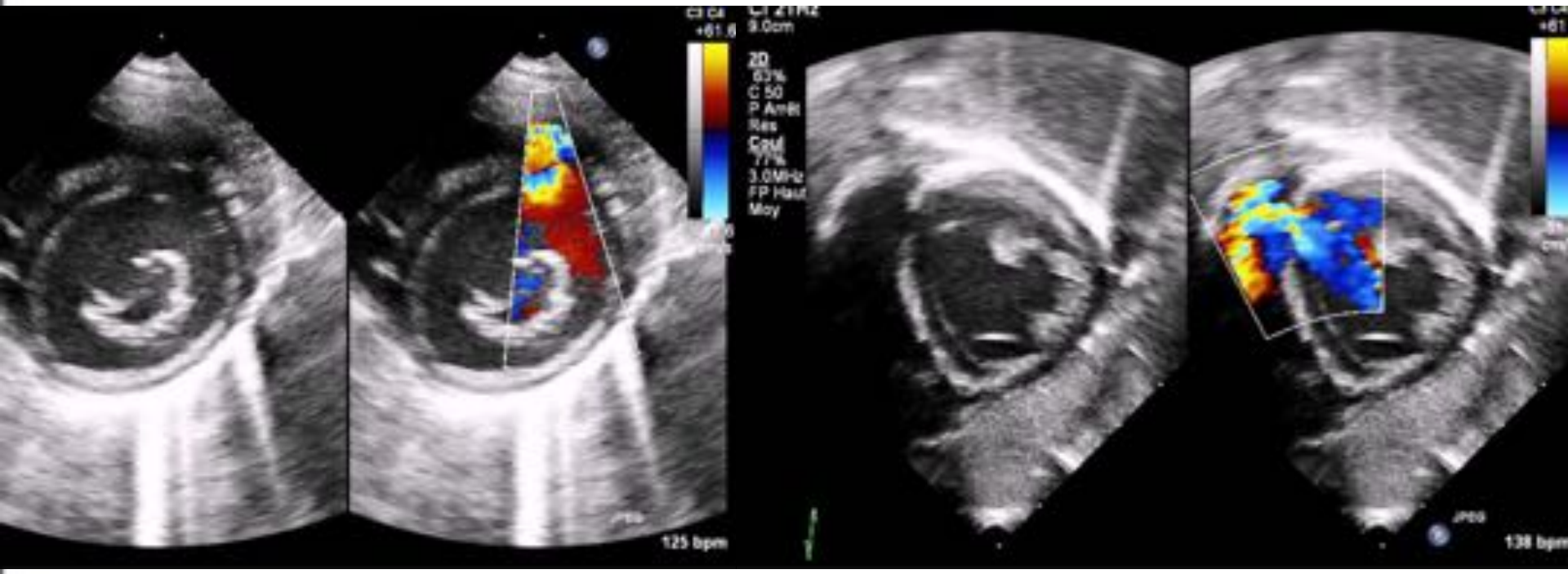

CIV post cerclage

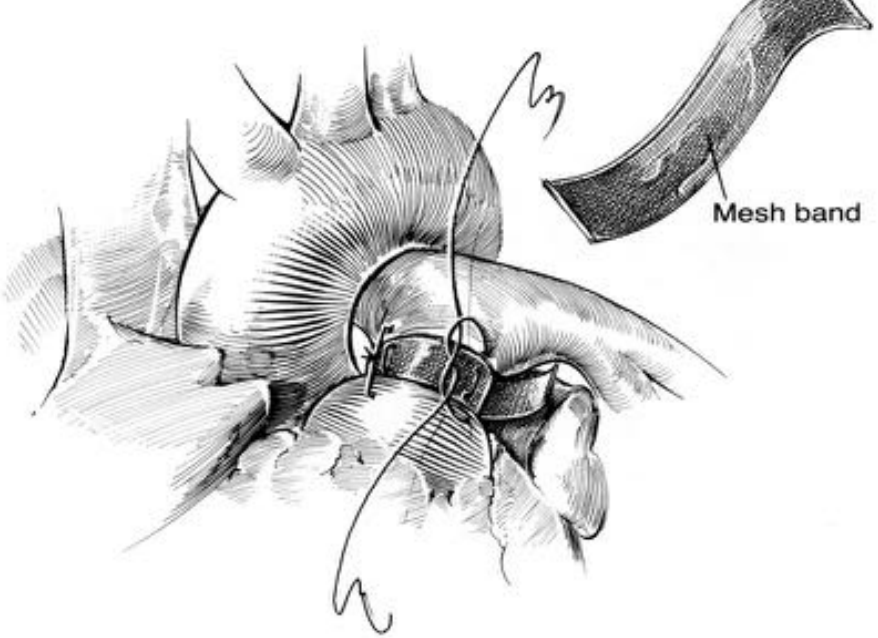

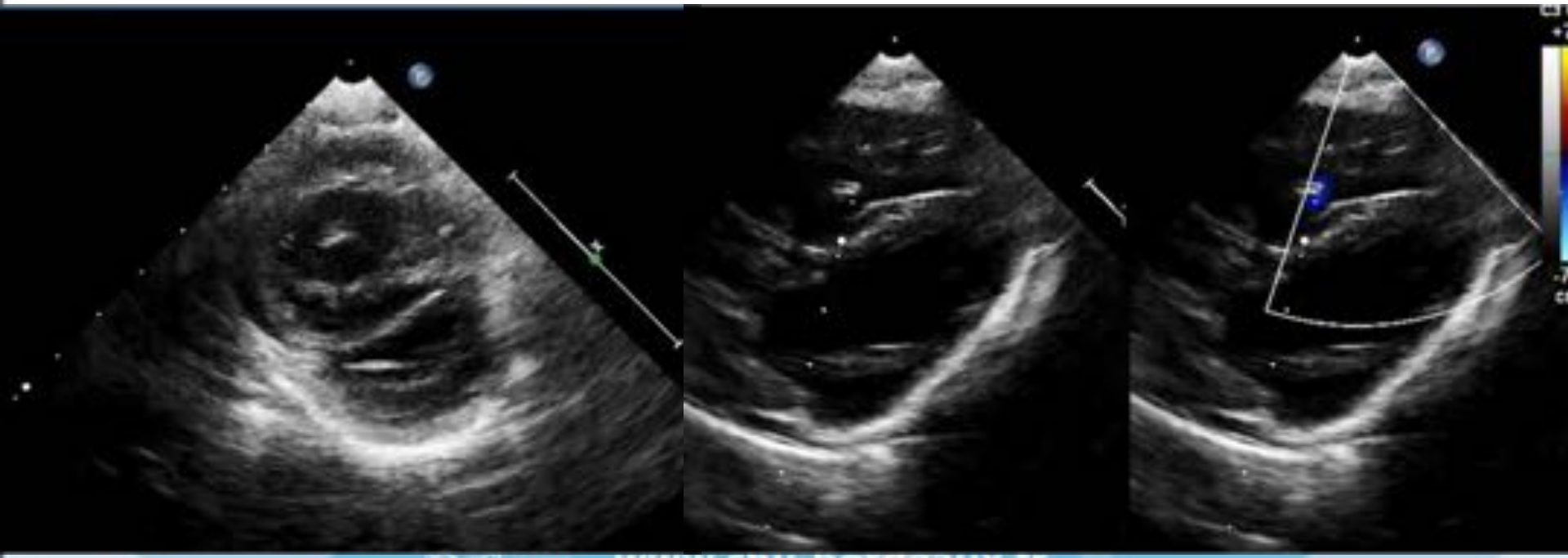

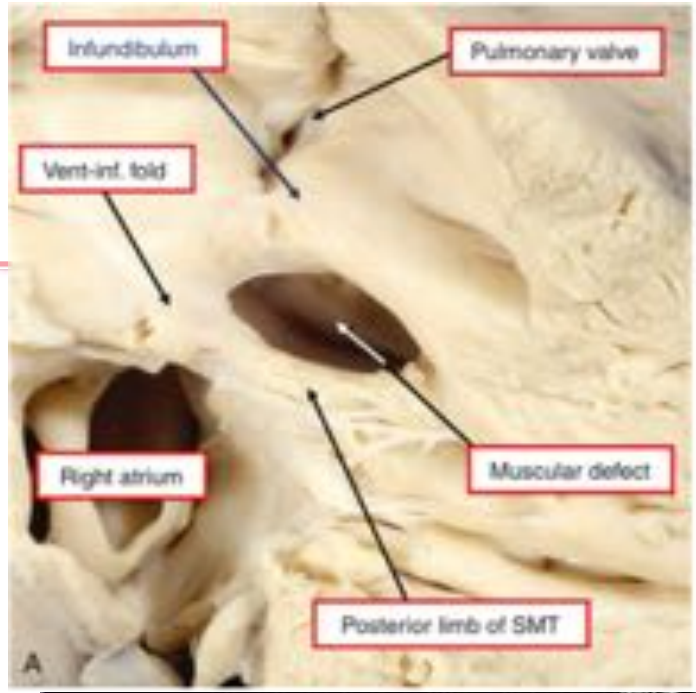
Infundibulum
Pulmonary valve
Vent-inf. fold
Right atrium
Muscular defect
Posterior limb of SMT
A

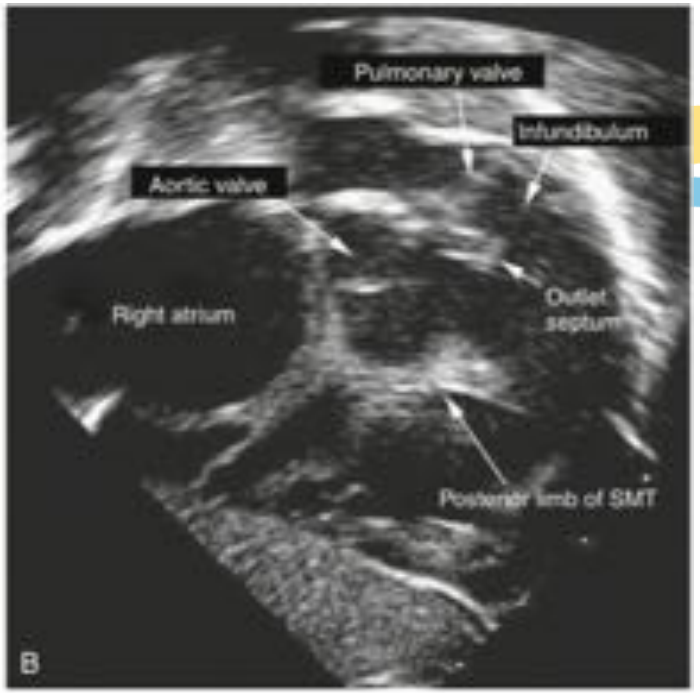
Pulmonary valve
Infundibulum
Aortic valve
Right atrium
Outlet septum
Posterior limb of SMT
B

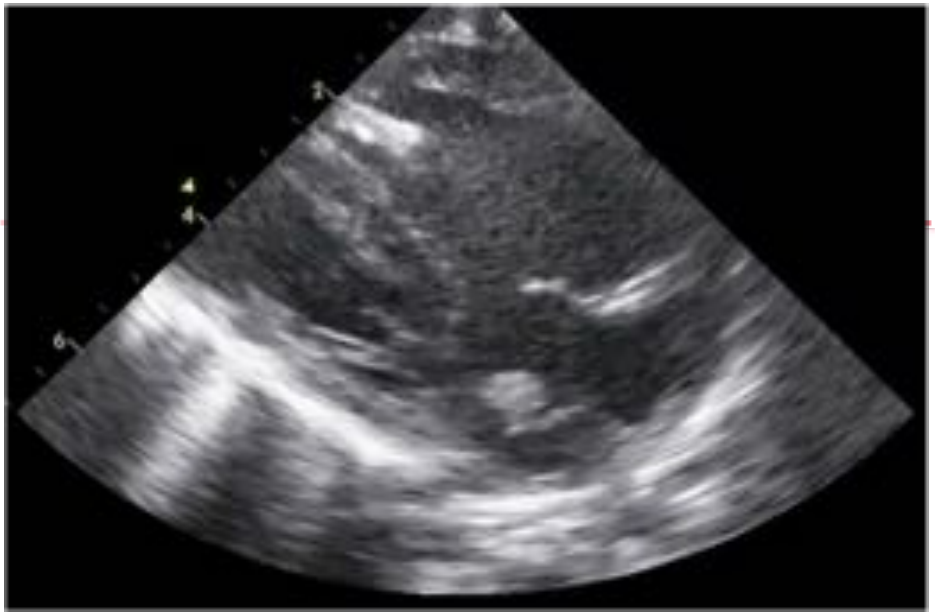

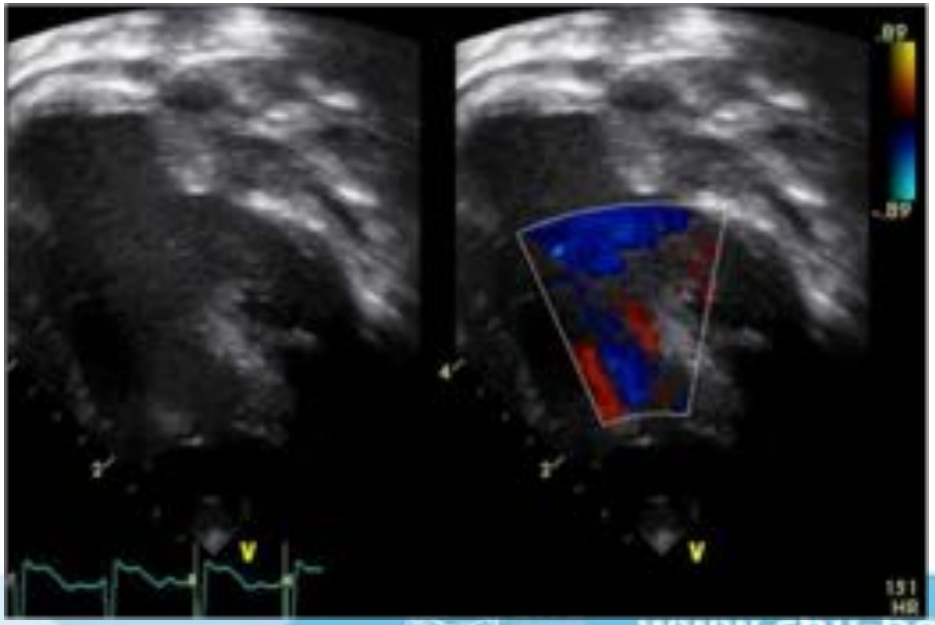

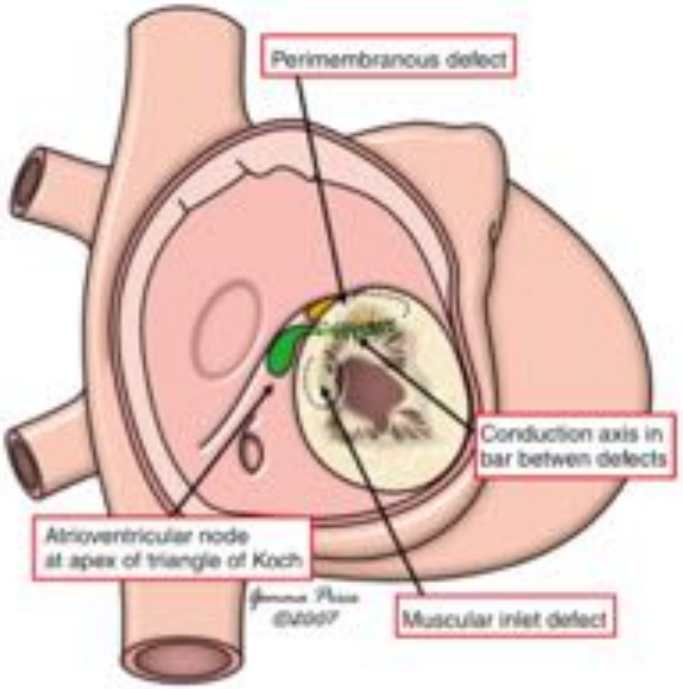
Perimembranous defect
Conduction axis in bar betwen defects
Atrioventricular node at apex of triangle of Koch
Muscular inlet defect

Endocardite sur CIV

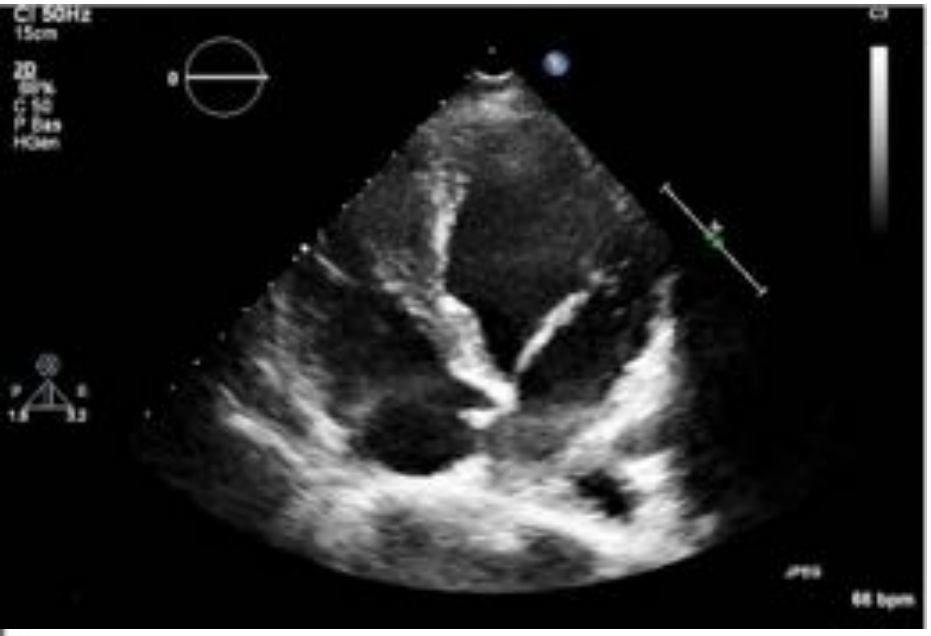

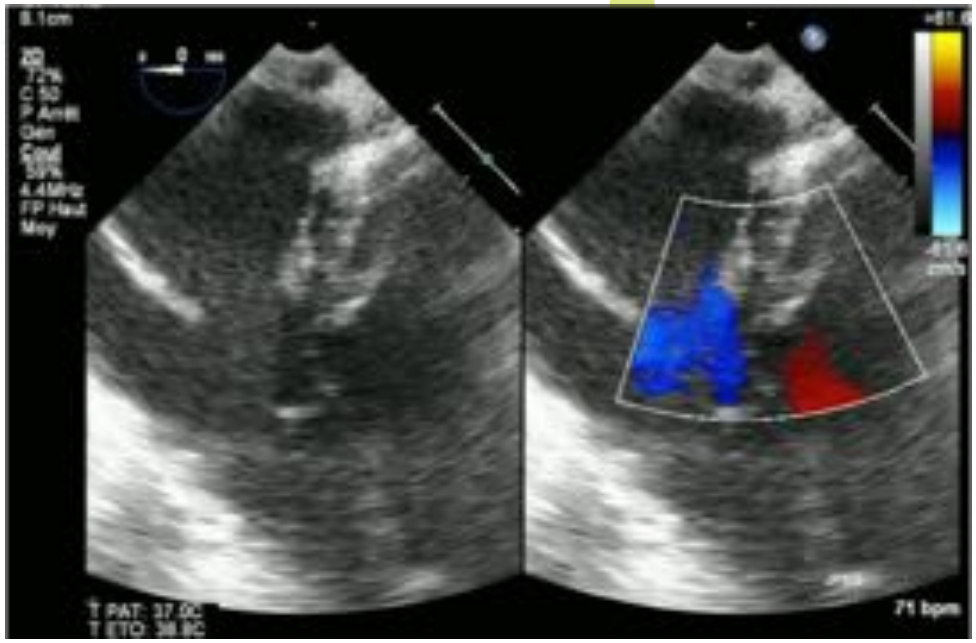

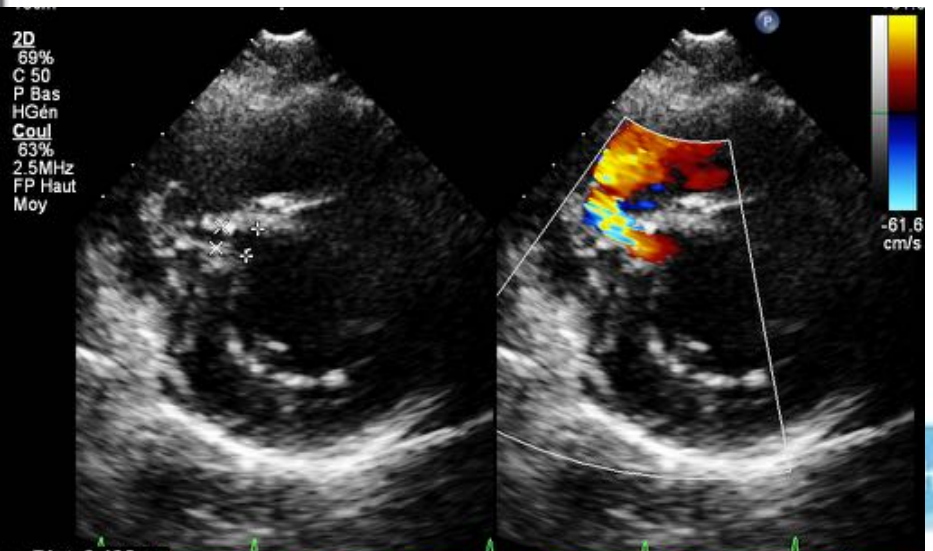

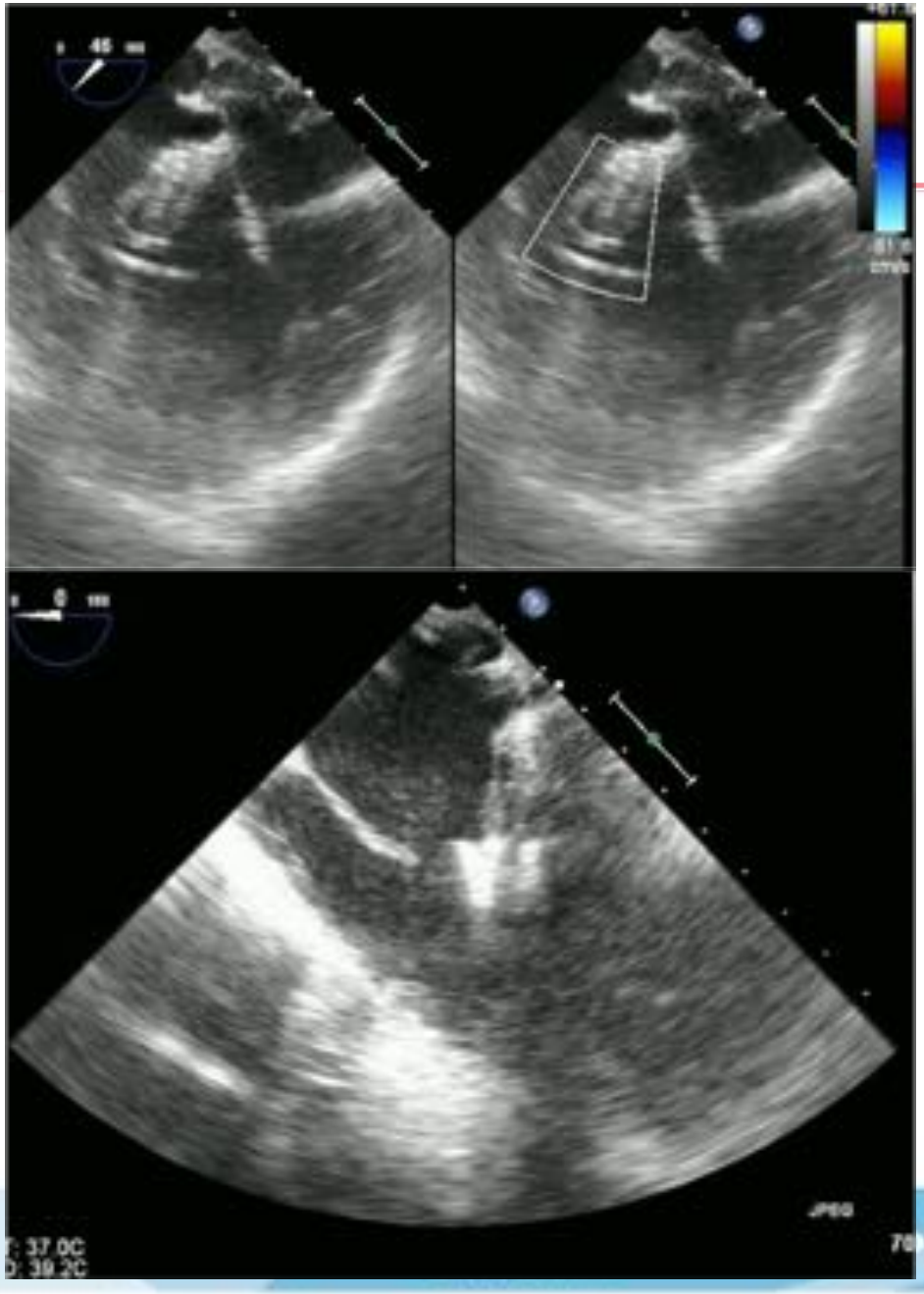
JPEG

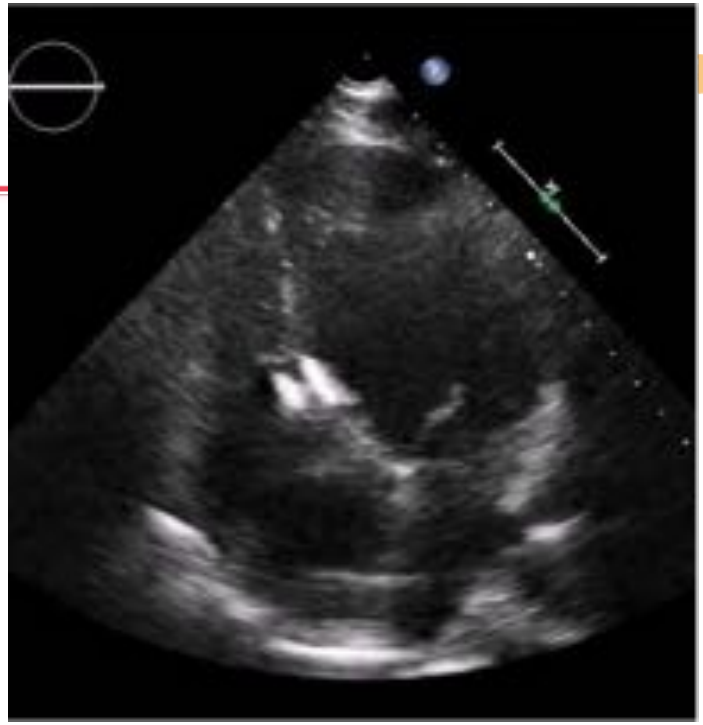

CIV atypique

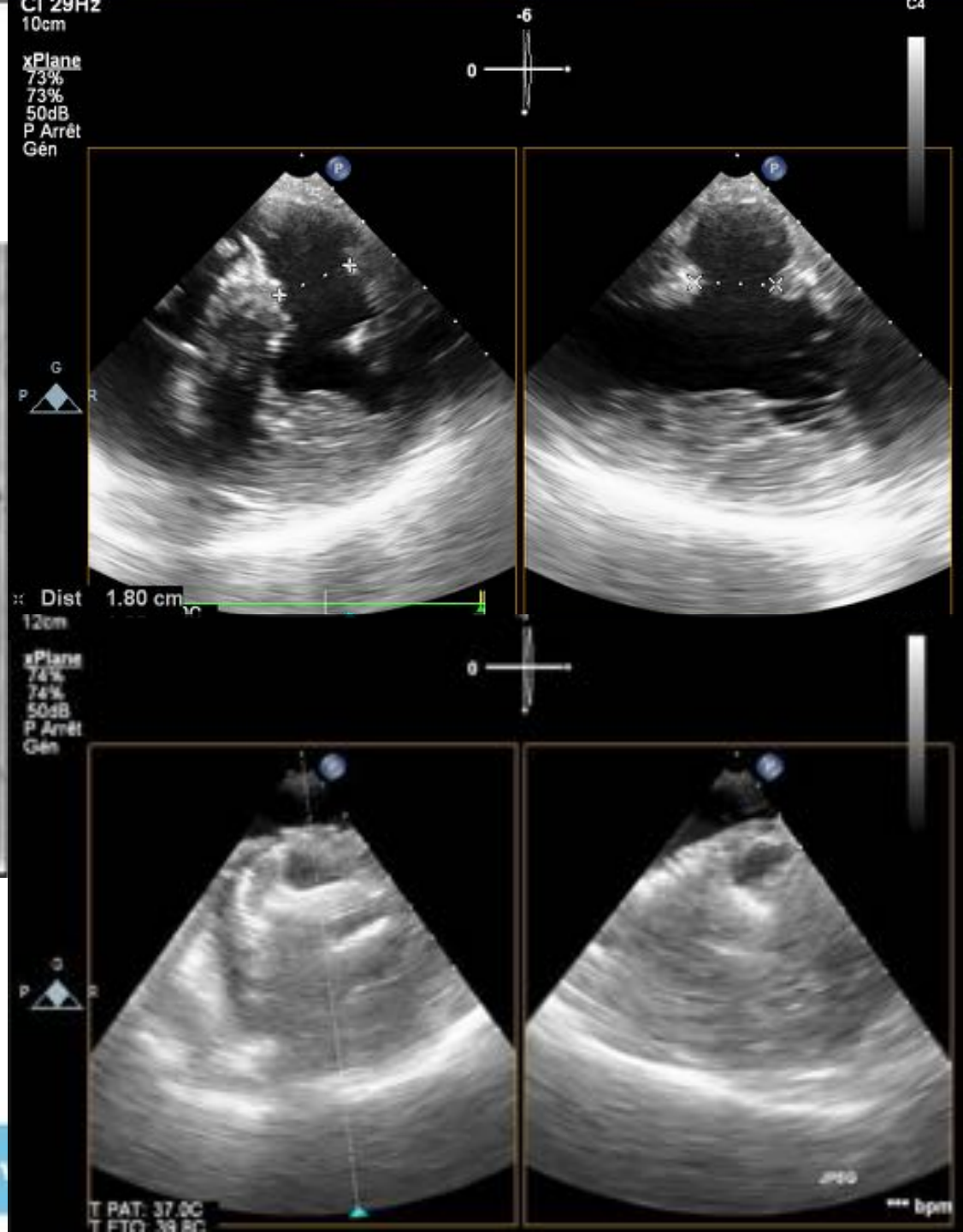

CIV sous pulmonaires

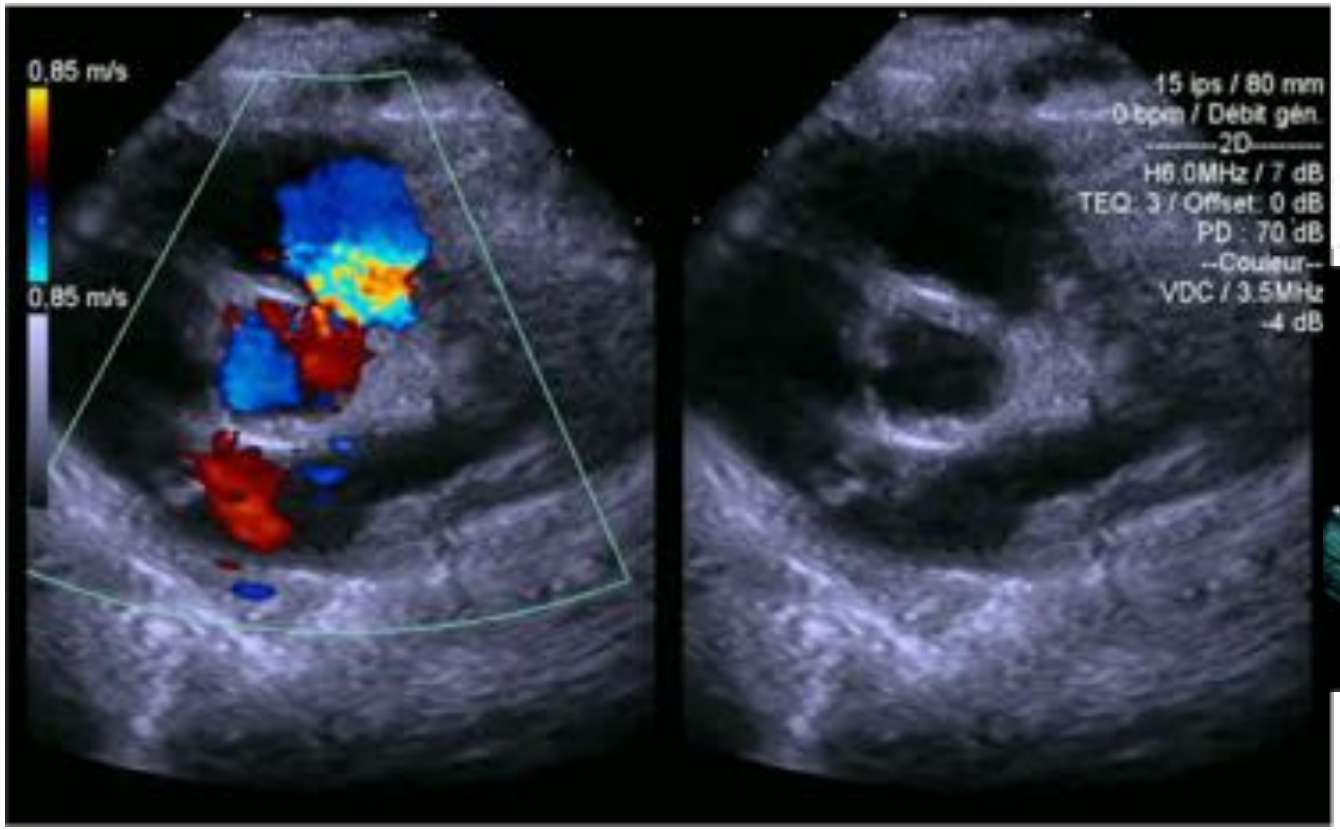

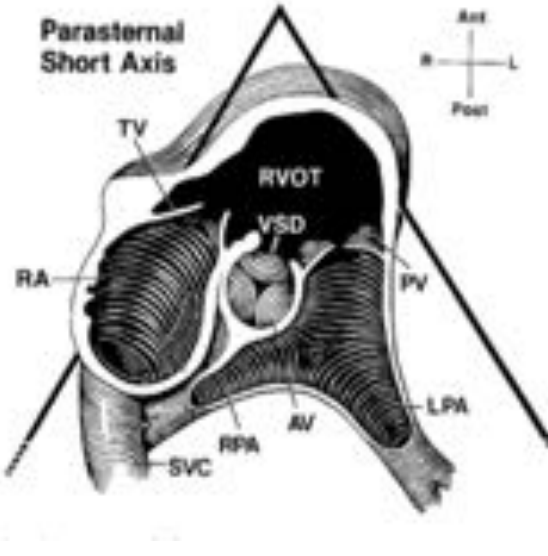

CIV sous pulmonaires

- 3% des CIV (beaucoup plus fréquentes en Asie)
- Absence de fermeture spontanée
- Continuité fibreuse au niveau du toit avec les sigmoides Ao/pulm
- Bord musculaire postero-inferieur
  - Anomalie de développement du septum musc sous pulm
- Cas particulier:extension postero inf avec bord fibreux entre les feuillets Ao / tricuspide
  - CIV périmembraneuse

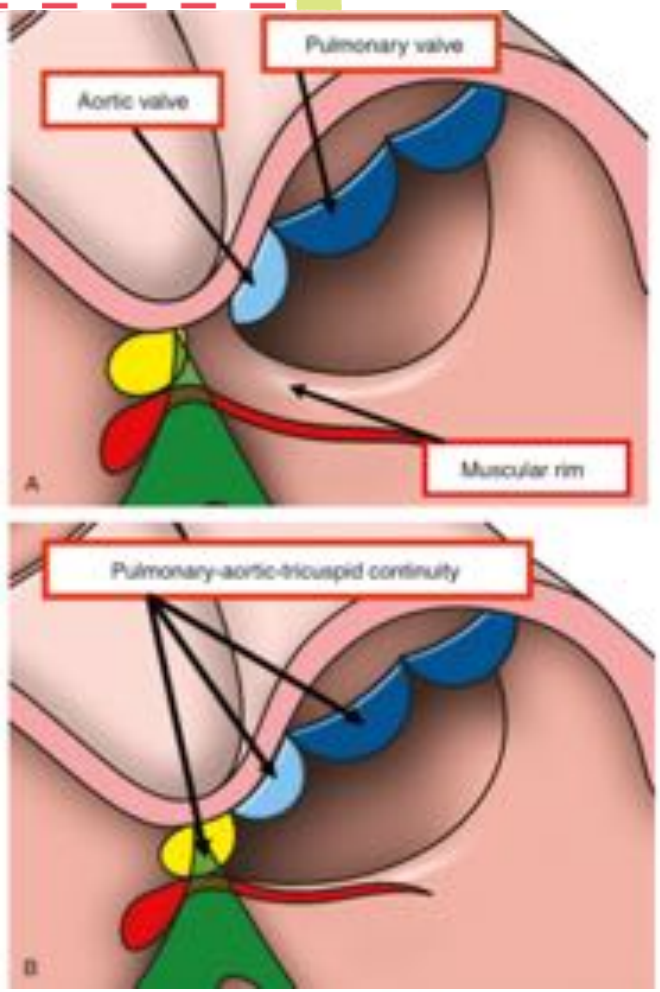

Prolapsus de la valve aortique et CIV

Prolapsus de la valve aortique et CIV

- CIV moyennement large
  - Ovale/musculaire outlet (inclut svt septum PM)
- Dilatation du sinus droit
  - Sigmoide AD/ rarement NC (2/46 série Yacoub)
  - Perte de continuité entre la media et l'aorte
    - Zone de faiblesse secondaire (→)

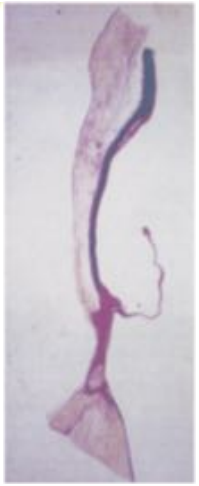

- Déplacement de l'anneau
  - Élongation de la cusp droite
  - Aggravation par effet venturi

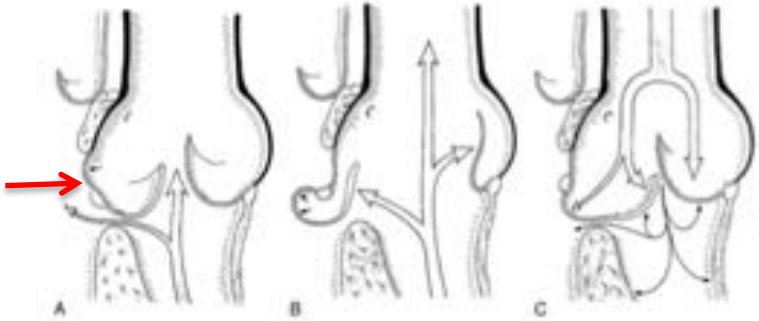

- Degré variable d'obstruction droite
  - Mineur à modéré

Yacoub M et al JTCS 2007
Eapen R et al JASE 2003

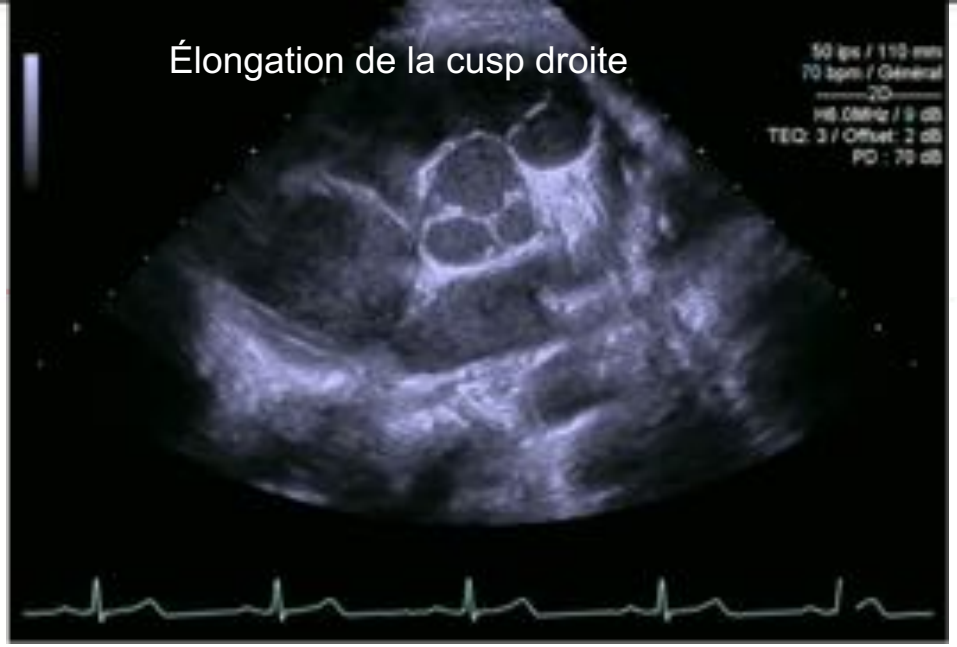
Élongation de la cusp droite

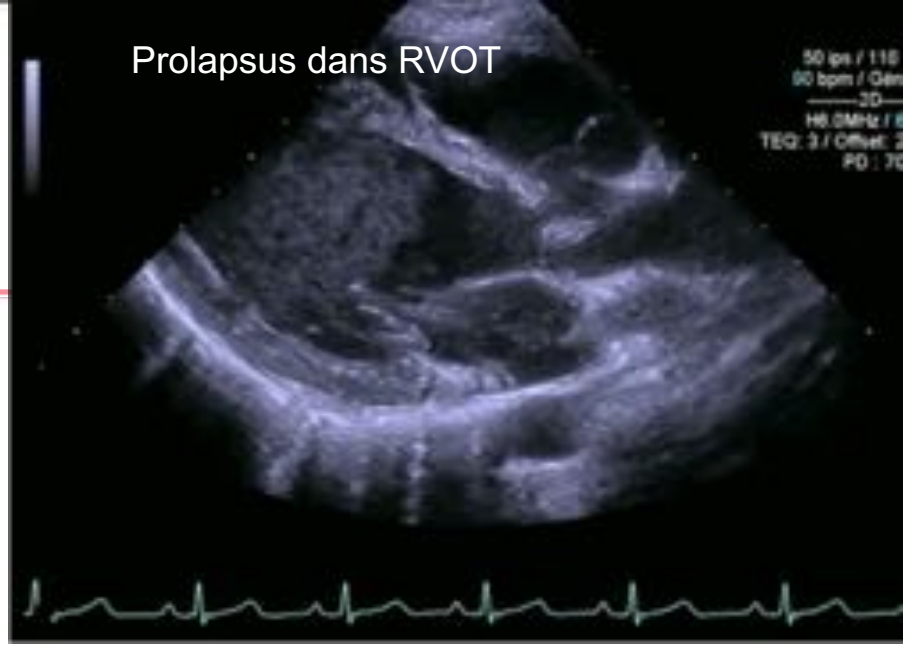
Prolapsus dans RVOT

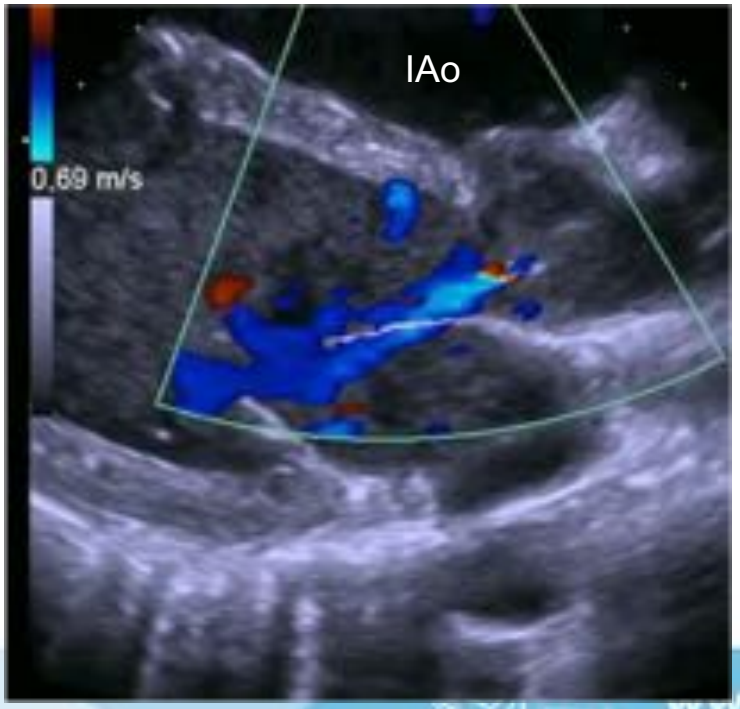
IAo
0,69 m/s

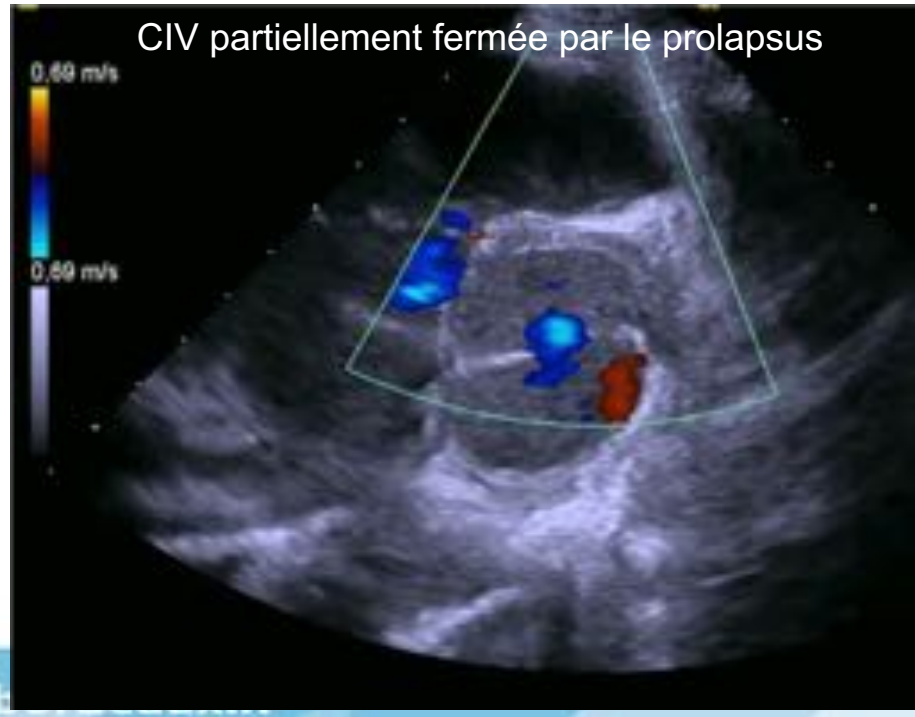
CIV partiellement fermée par le prolapsus
0,69 m/s
0,69 m/s

26/08/2013 10:31:47
CARDIO PED XI / CARDIONEONAT° / 10V4
90 ips / 80 mm
120 bpm / Général
2D
7.0MHz / -1 dB
TEQ: 3 / Offset: 0 dB
PD : 65 dB

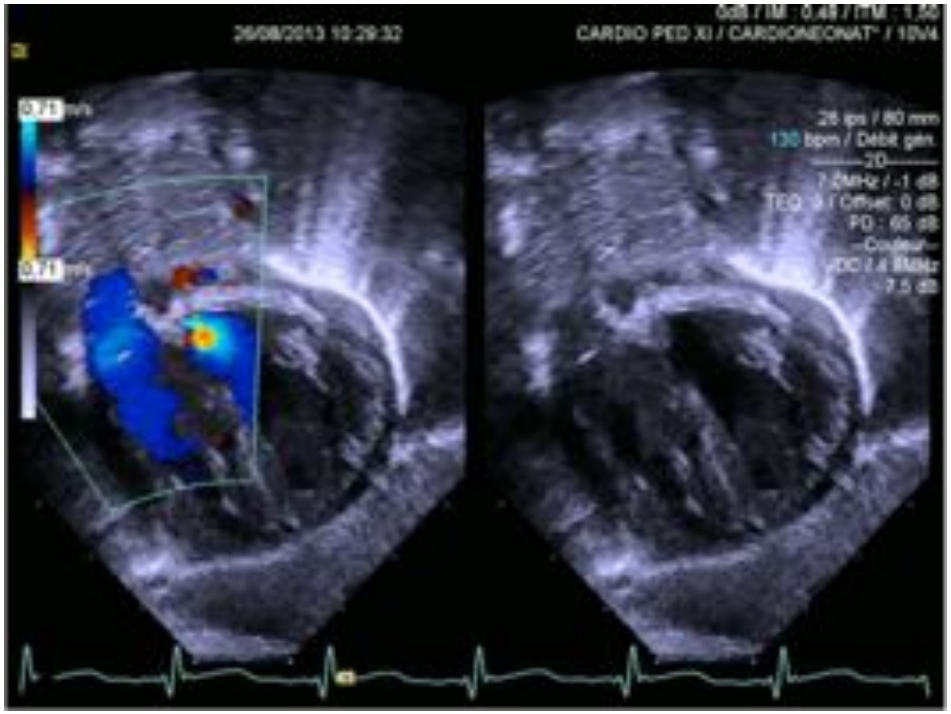
26/08/2013 10:29:32
CARDIO PED XI / CARDIONEONAT° / 10V4
0.71 m/s
0.71 m/s
26 ips / 80 mm
130 bpm / Debit gén
2D
7.5MHz / -1 dB
TEQ: 3 / Offset: 0 dB
PD : 65 dB
Couleur
DC / 4 MHz
7.5 dB

Anomlalies associées

- Straddling, overriding

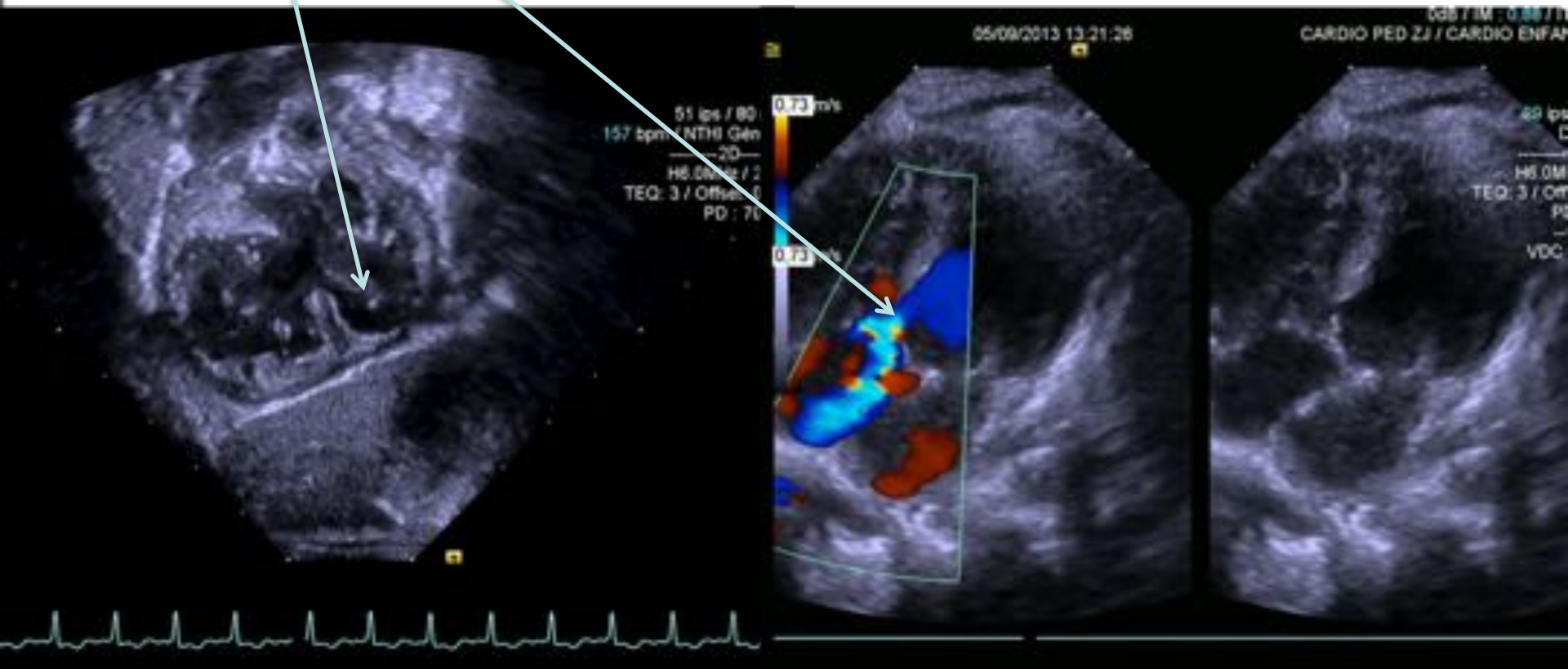

Conclusion: échographie des CIV

- Place prépondérante dans le diagnostic
  - Anatomique
  - Hémodynamique
- Recherche de lésions associées
- Évaluation pré-per-post opératoire