Prise en charge des APSI

Dr Fanny Bajolle
M3C-Necker

Obstacles du cœur droit

Sténose supra valvulaire pulmonaire

Sténose pulmonaire

APSI

Cœur triatrial droit

Ebstein

HypoVD

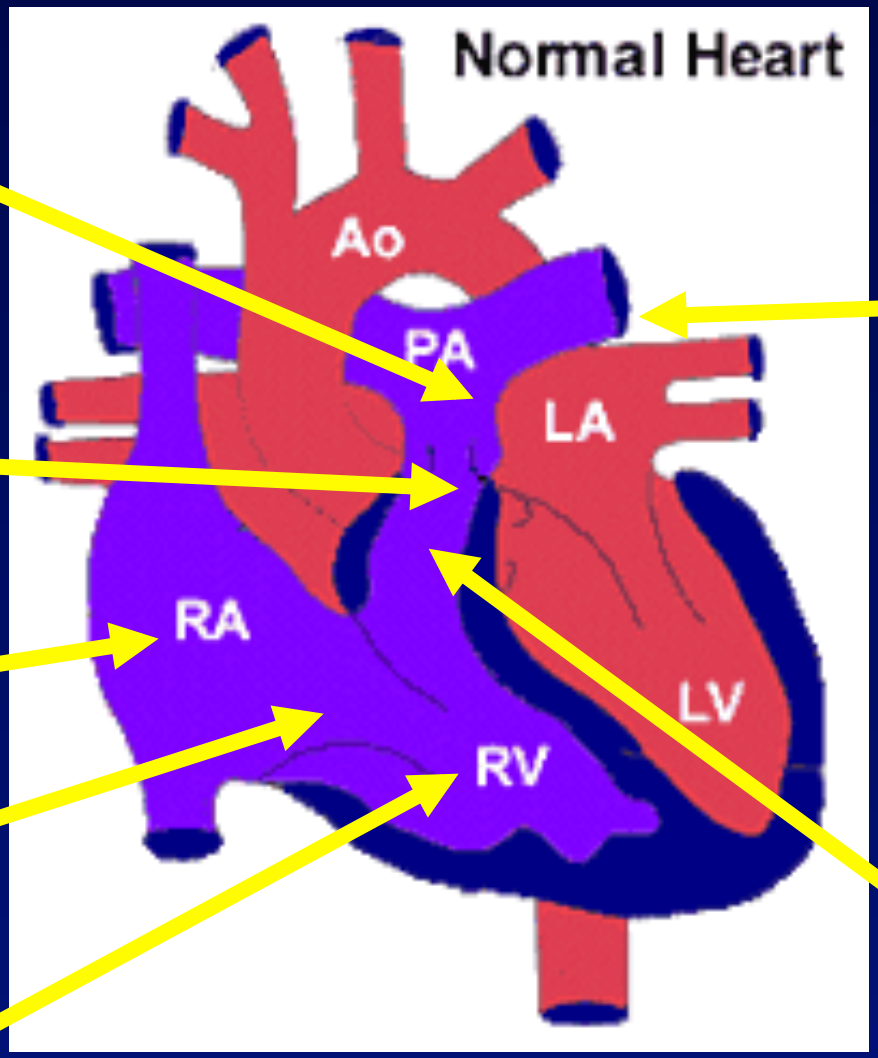

Sténose des branches pulmonaires

Sténose sous pulmonaire

Atrésie pulmonaire à septum intact

APSI

Cyanose et souffle au foyer tricuspide

Atrésie pulmonaire à septum intact, Diagnostic prénatal

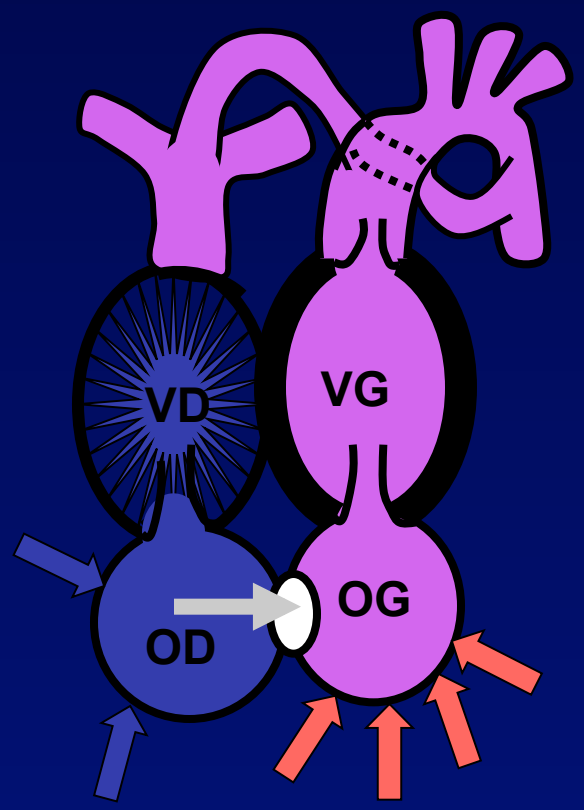

- Cardiopathie cyanogène à sang mélangé
- Ductodépendance de la circulation pulmonaire
- Maladie du muscle du cœur droit avec hypertrophie VD
- Shunt D-G atrial due à la dysfonction diast VD

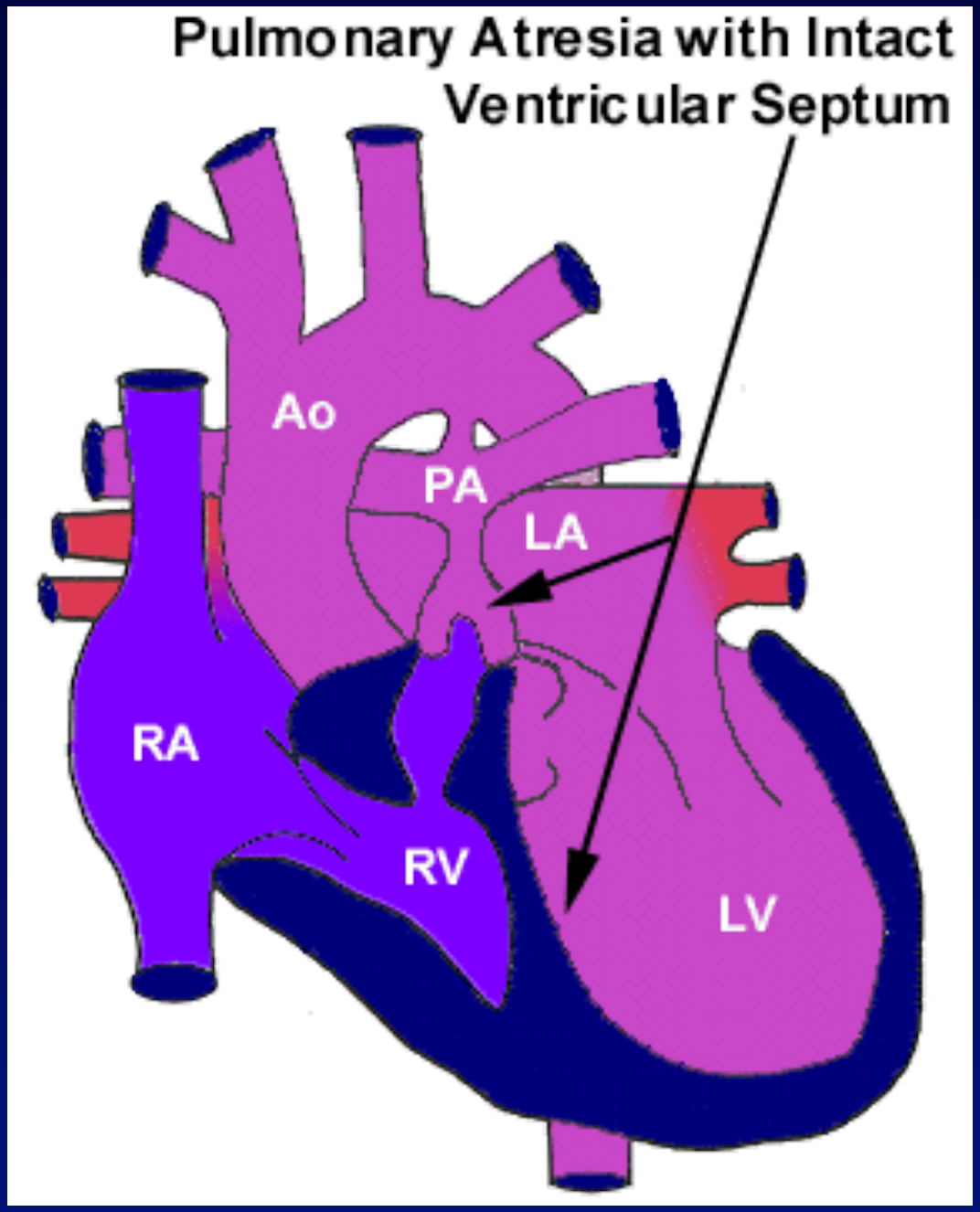
Pulmonary Atresia with Intact Ventricular Septum
Ao
PA
LA
RA
RV
LV

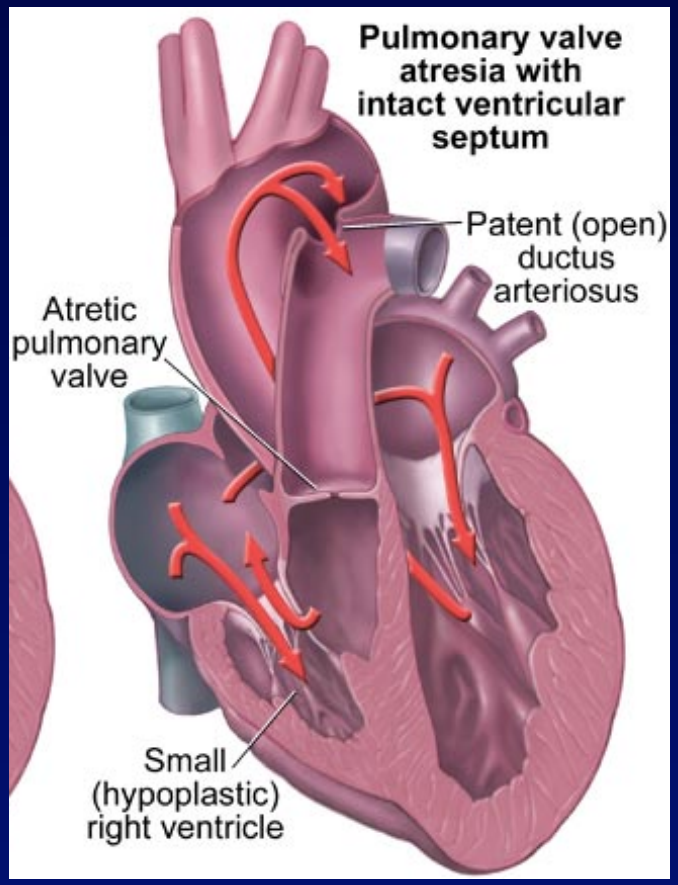
Pulmonary valve atresia with intact ventricular septum
Patent (open) ductus arteriosus
Atretic pulmonary valve
Small (hypoplastic) right ventricle

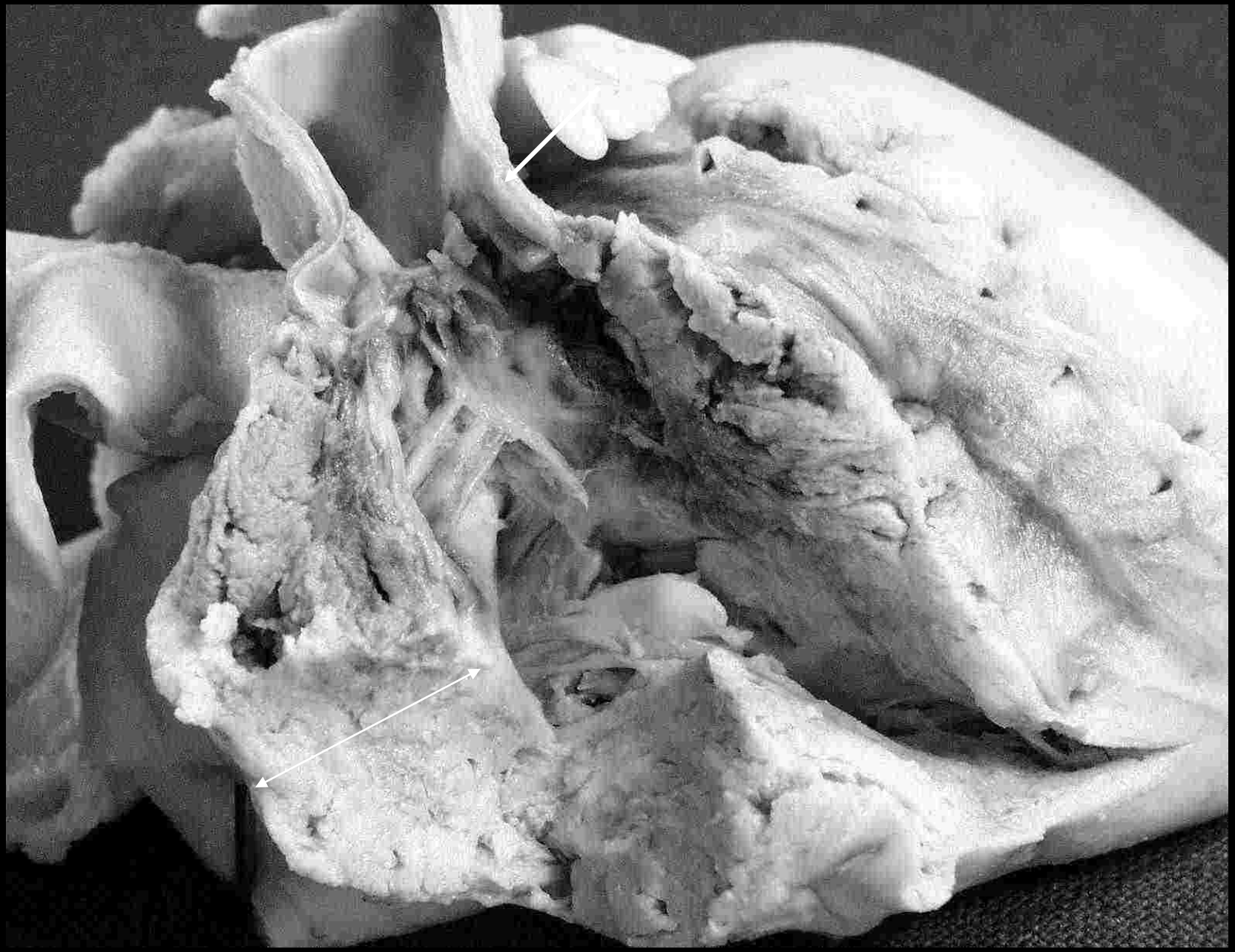

Atrésie pulmonaire à septum intact

- Shunt D-G auriculaire
- Cyanose isolée
- SS d'IT
- Cardiopathie ducto-dépendante

Atrésie pulmonaire à septum intact

- Evolutivité pendant la vie foetale
- Anatomie du VD
  - Nombre de chambres
  - Taille de la tricuspide
  - Anneau pulmonaire
- Perfusion coronaire (angiographie)
  - Fistules/sinusoïdes
  - VD dépendance

VD normal tripartite

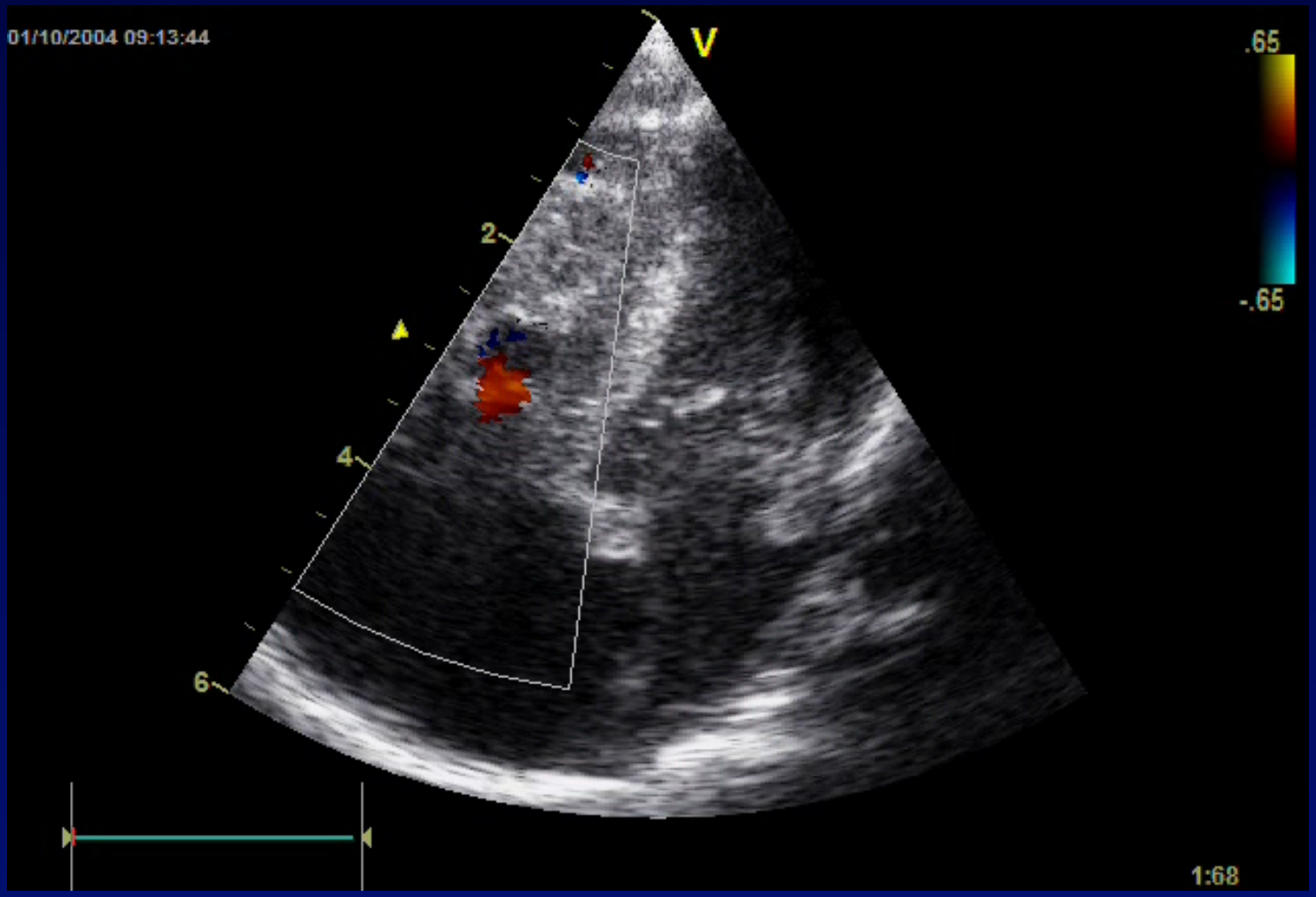
01/10/2004 09:13:44
V
.65
-.65
2
4
6
1:68

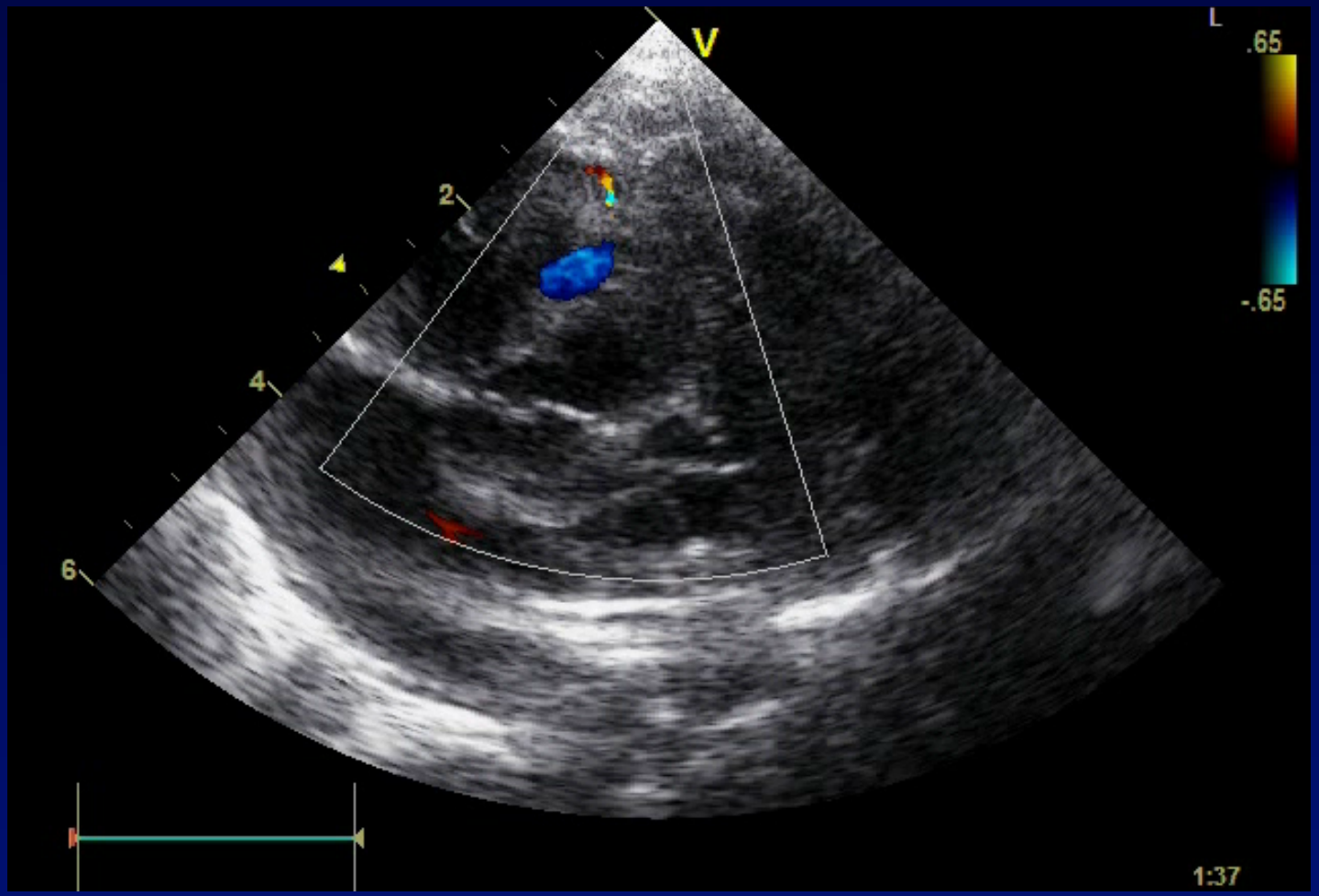
V
L
.65
-.65
2
4
4
6
1:37

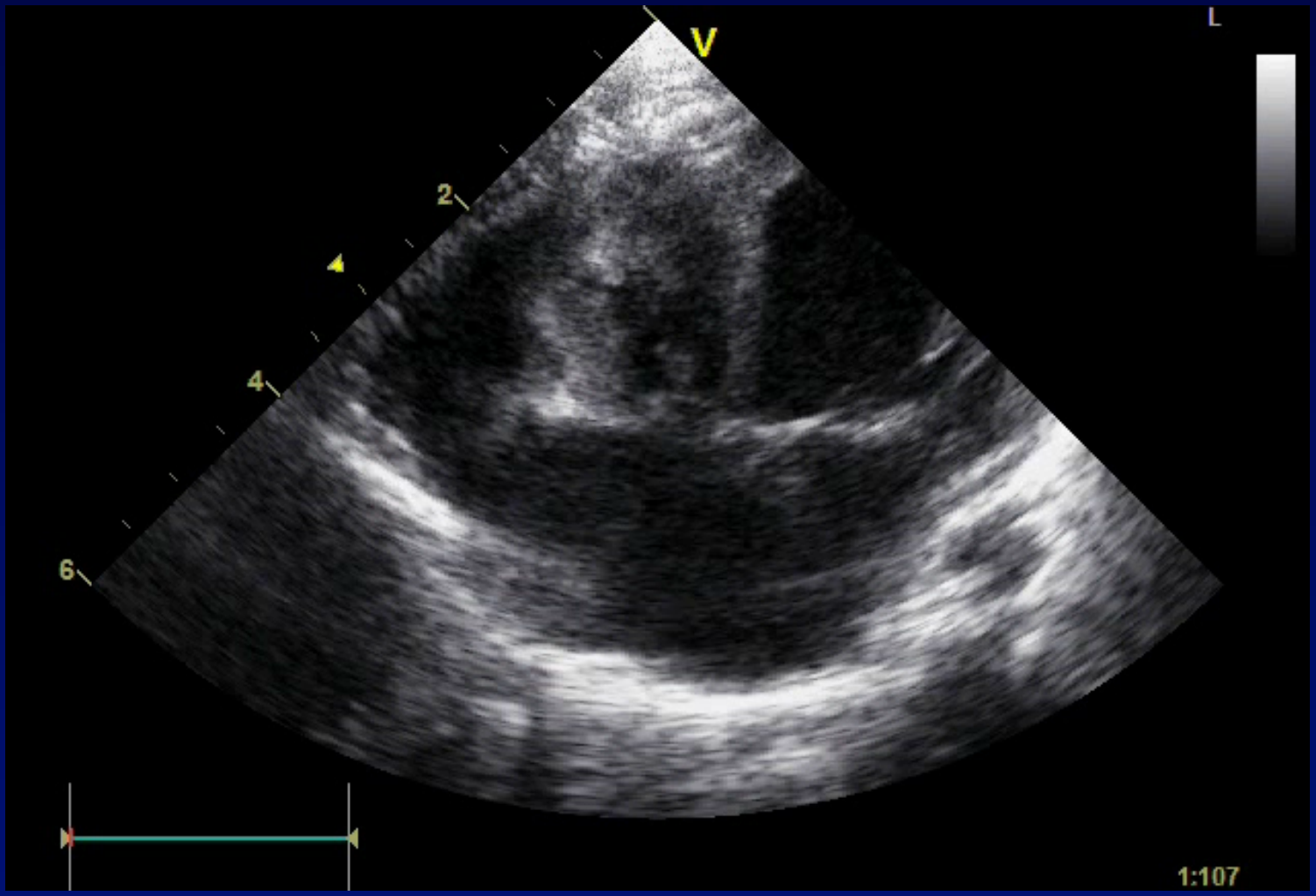
V
L
2
4
6
1:107

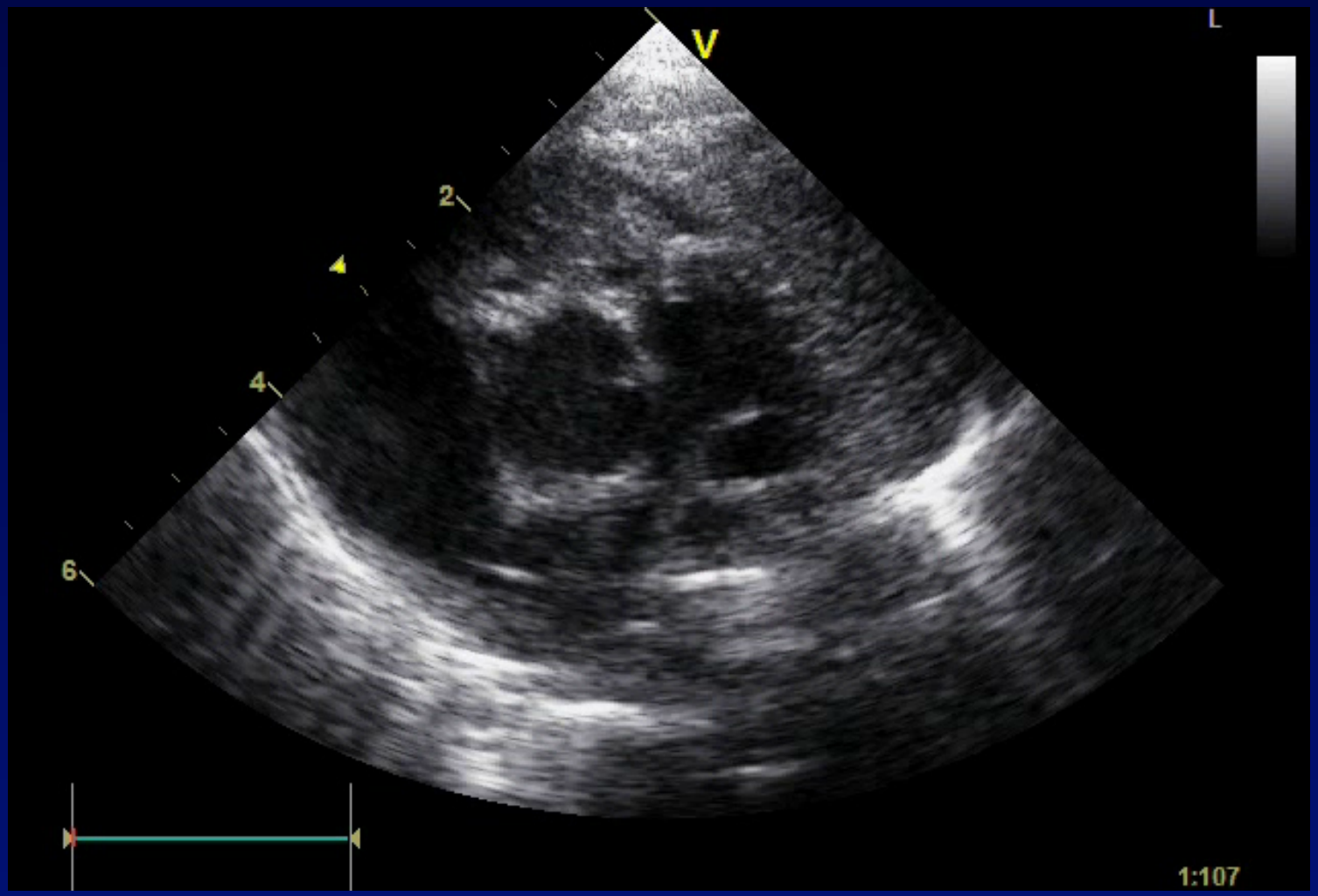
V
L
2
4
4
6
1:107

Atrésie pulmonaire à septum intact: VD tripartite

- Perforation par sonde de radio-fréquence
- Puis dilatation percutanée
- Procédure plus risquée qu'une dilatation simple

APSI: perforation-dilatation percutanée

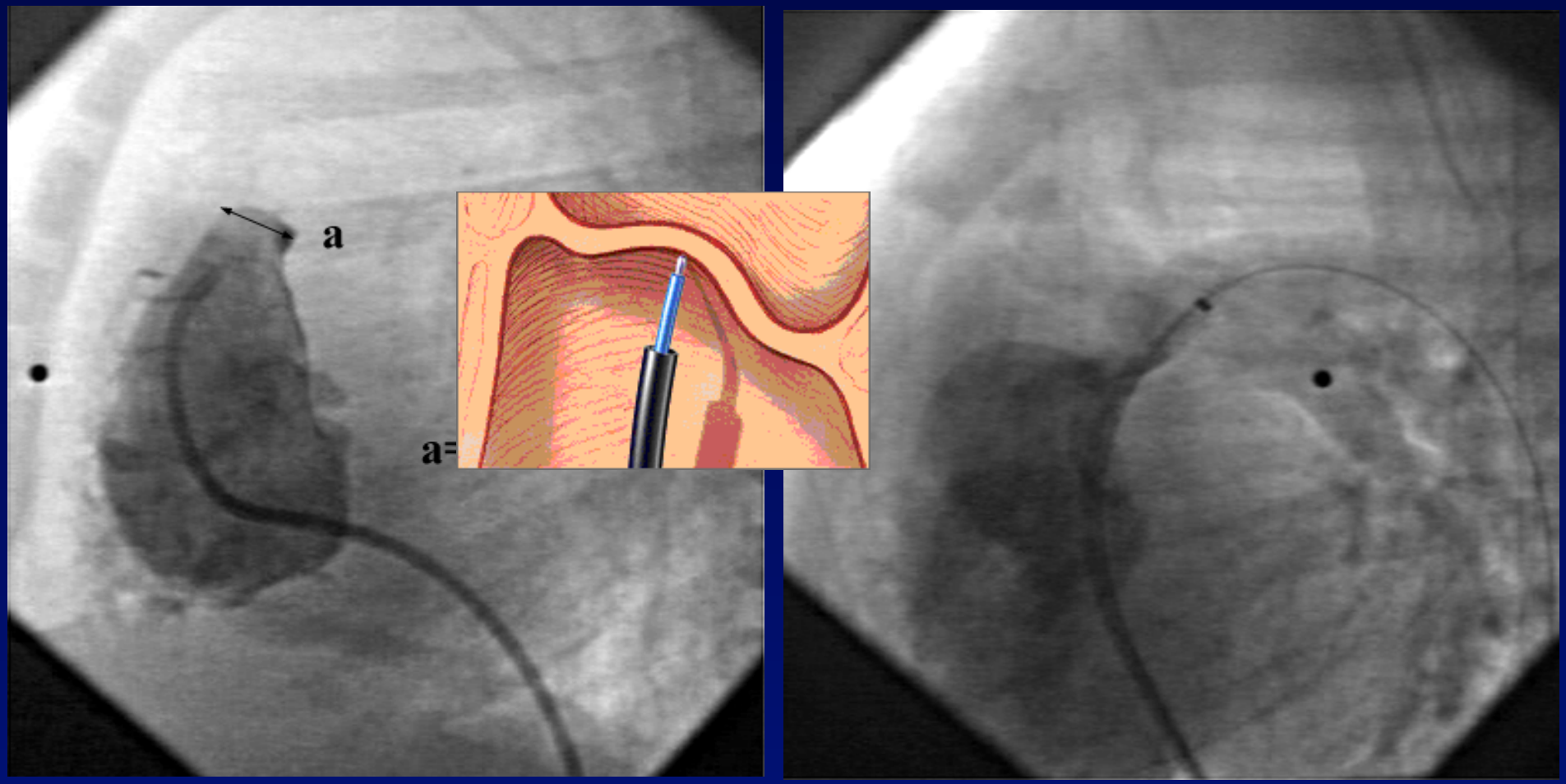

Traitement par cathétérisme cardiaque

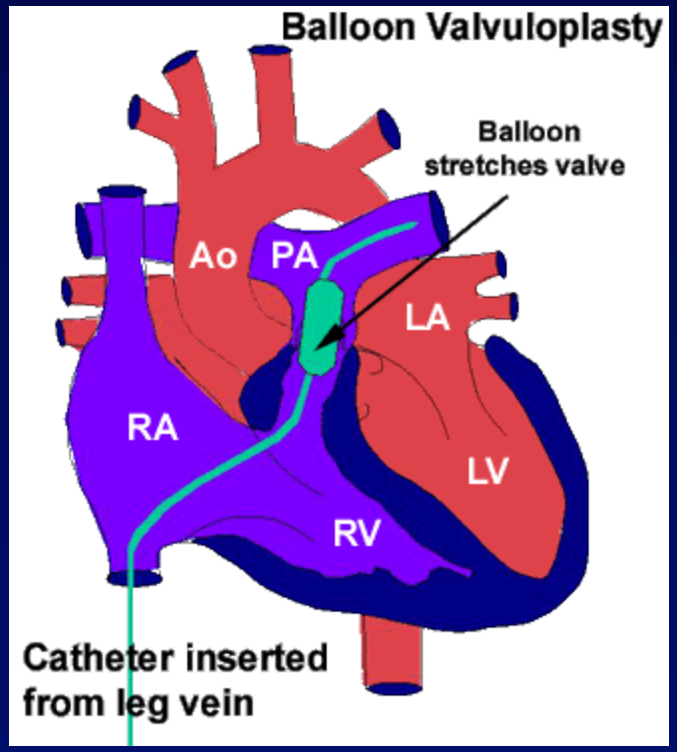

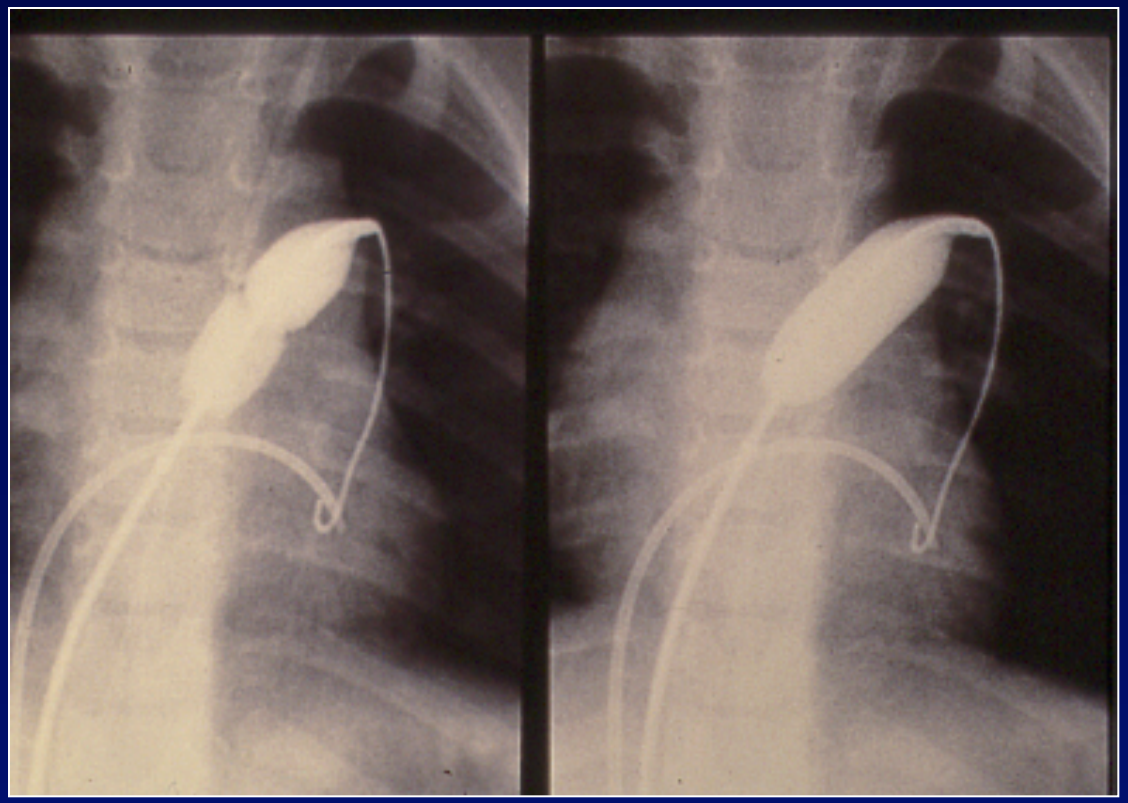

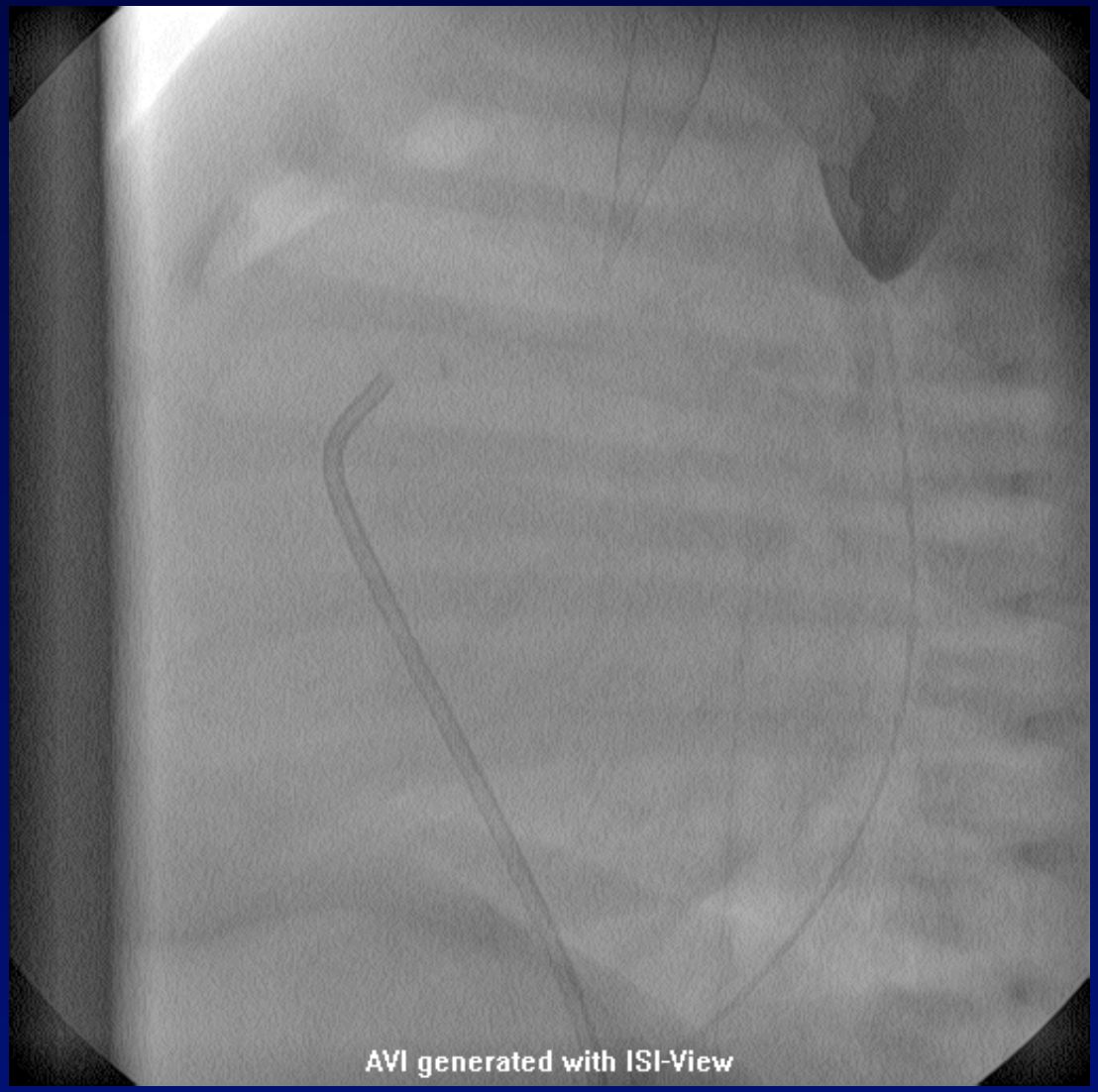
AVI generated with ISI-View

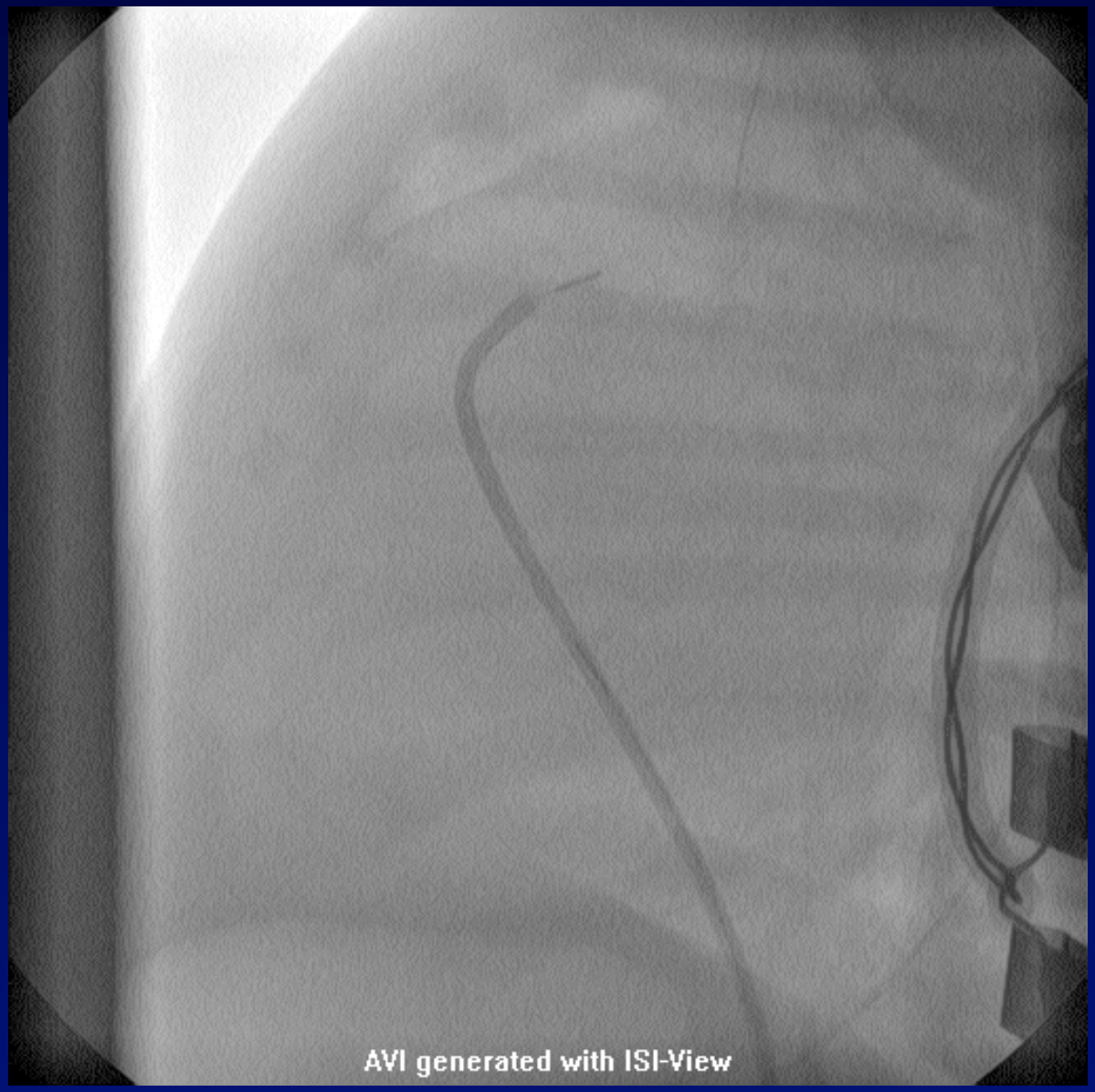
AVI generated with ISI-View

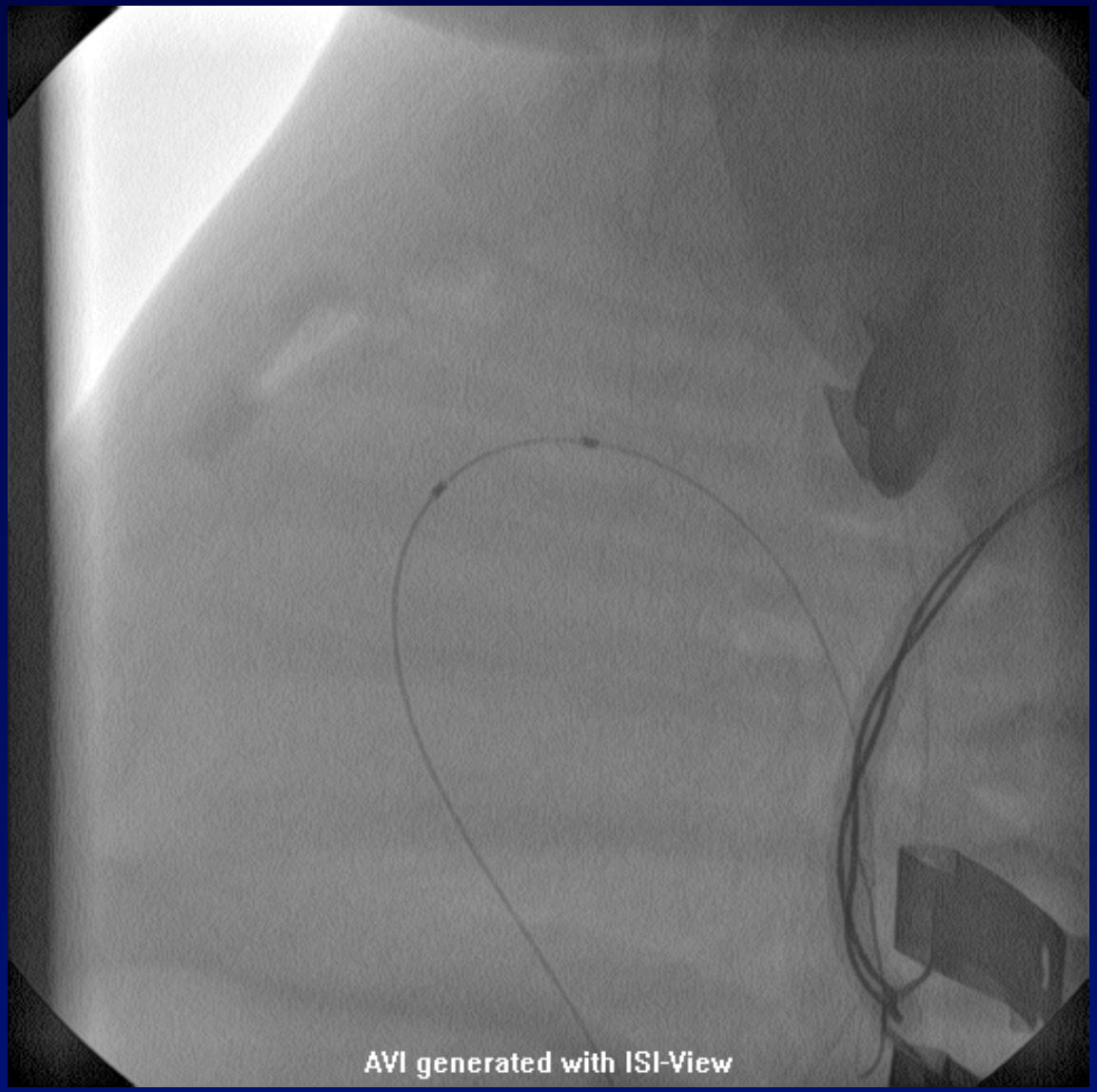
AVI generated with ISI-View

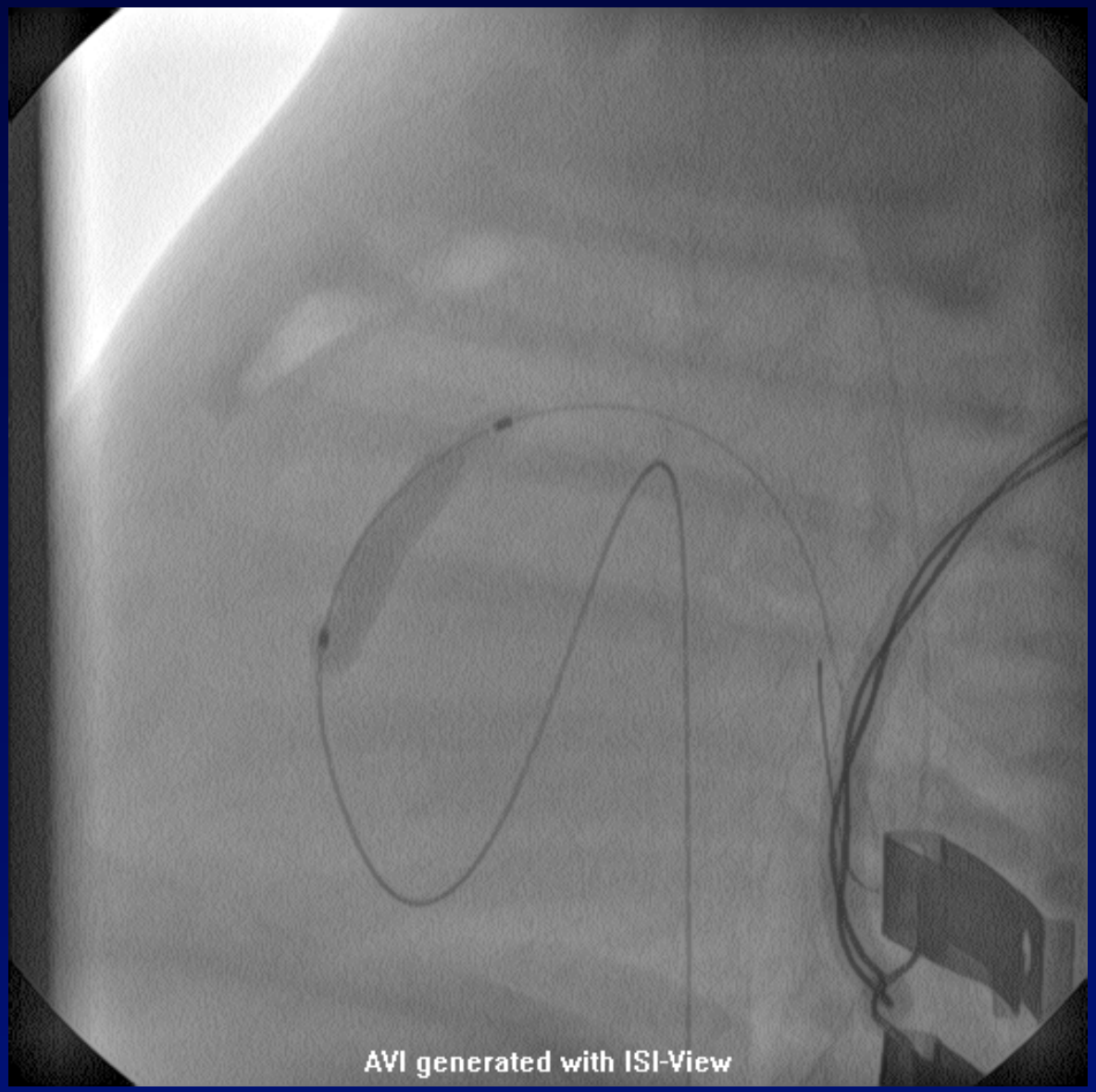
AVI generated with ISI-View

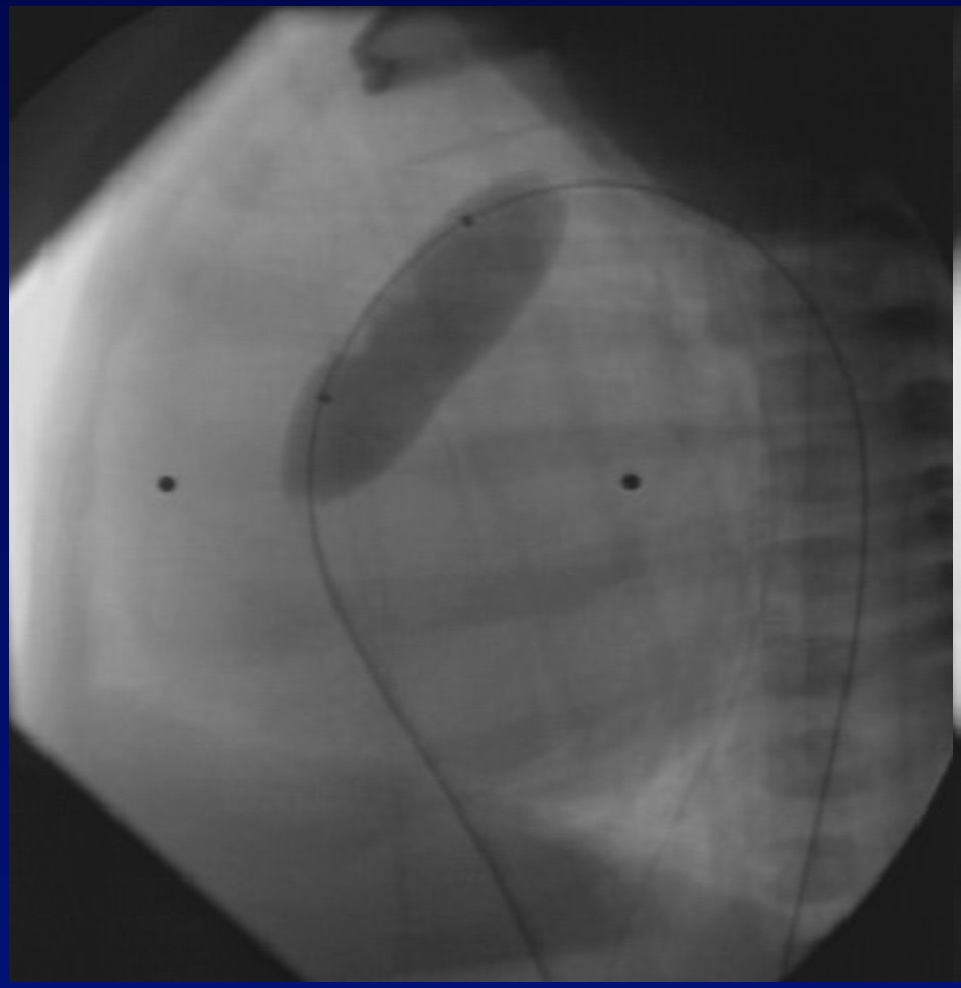

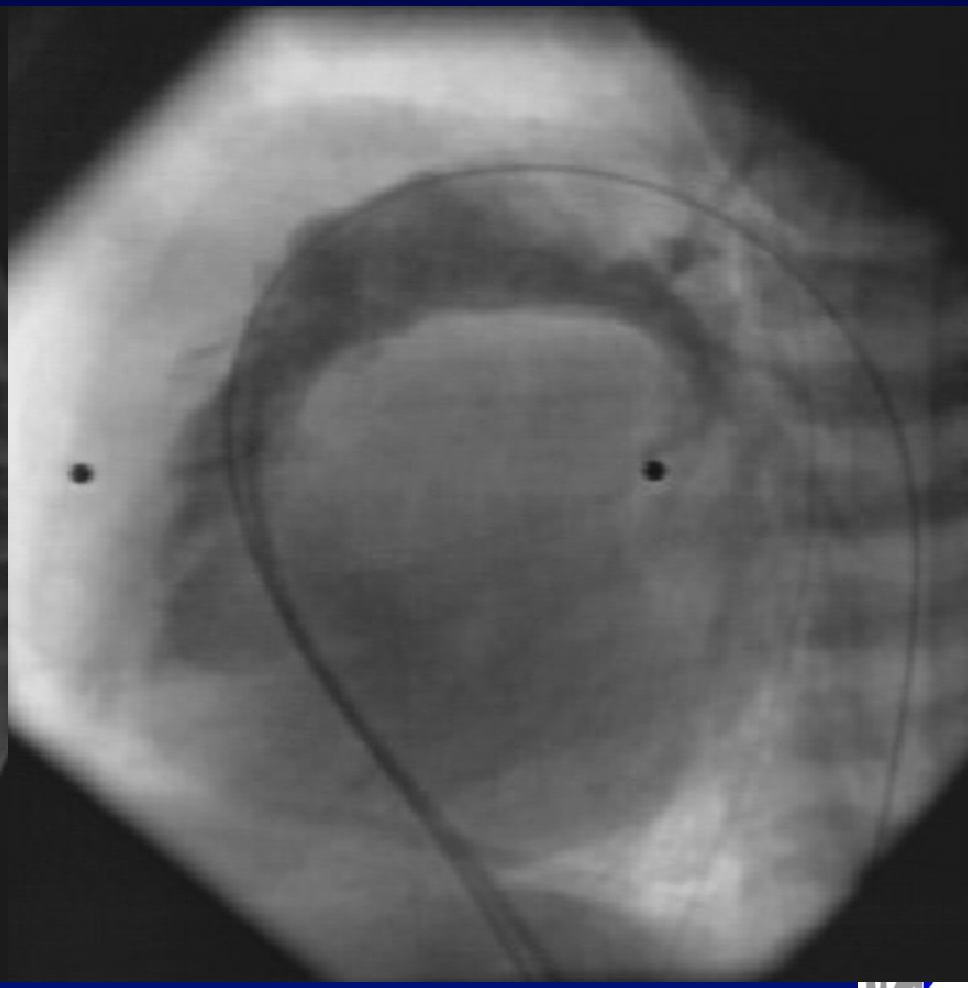

Results of three to 10 year follow up of balloon dilatation of the pulmonary valve

P S Rao, O Galal, M Patnana, S H Buck, A D Wilson

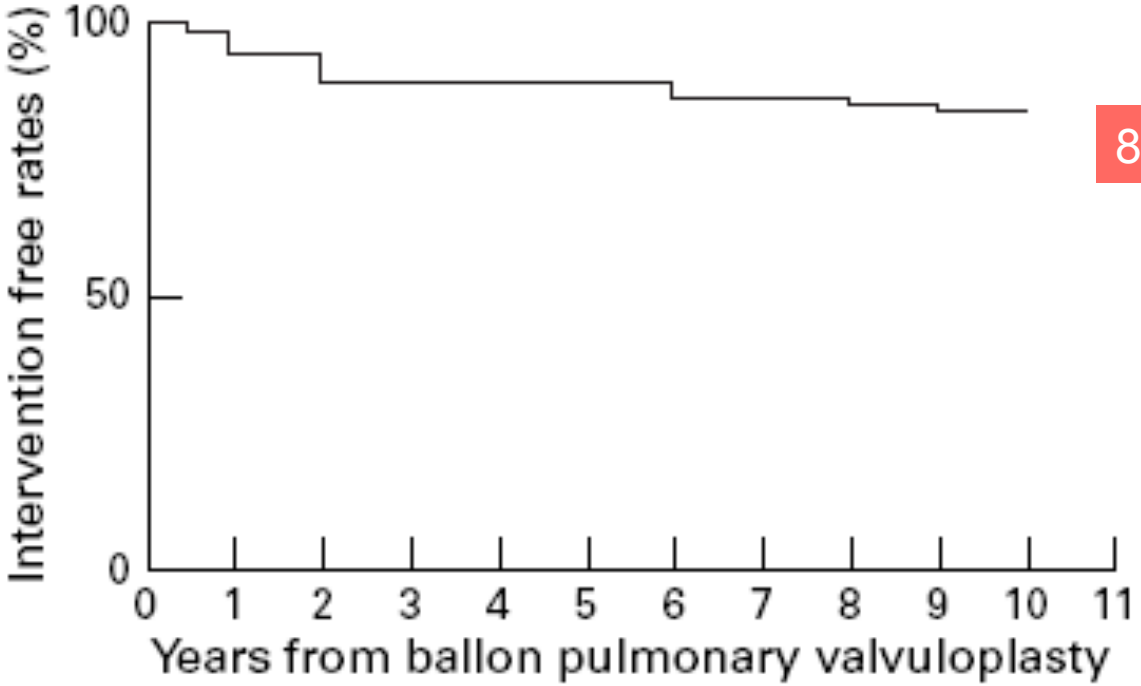

84% at 10 years

Figure 3 Actuarial event free rates after balloon dilatation of the pulmonary valve. Reintervention free rates at one, two, five, and 10 years are 94%, 89%, 88%, and 84%, respectively.

Heart 1998;**80**:591–595

Pas de mortalité de cette procédure dans cette série

APSI post perforation

- Cyanose persistante (VD ratatiné par défaut de compliance)
  - Maintenir les PGE1
  - Béta-bloquants
  - Anastomose de Blalock
  - Stent du canal artériel
- Insuffisance tricuspide post-dilatation
  - Ne pas remettre de PGE1
  - Fermer le canal au plus vite
  - Accélerer le coeur, pas de BB
- Suivi de la croissance du VD et de la tricuspide

APSI: VD croupion

- Pas de perforation-dilatation
- Coronaires sténosées et perfusées par le VD : risque de dysfonction du VU si défaut de perfusion coronaire en levant l'obstacle
- Blalock ou stenting du canal artériel
- Puis programme coeur univentriculaire
- Importance du cathétérisme néonatal
- Pronostic plus mauvais que l'hypoVG
- Discuter accompagnement

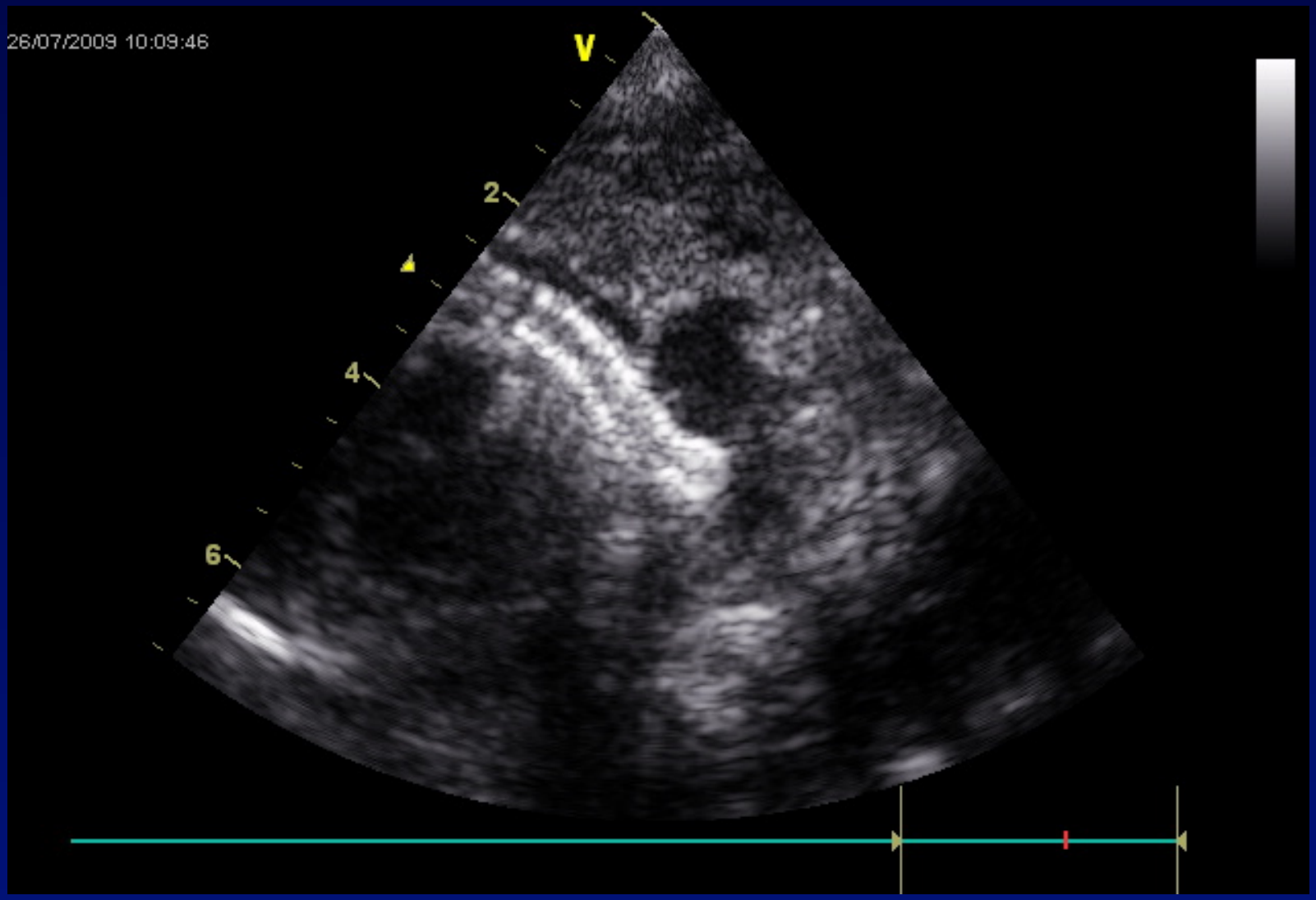
26/07/2009 10:09:46
V
2
4
6

Mag = 1.00
FL:
ROT:
P
R
S
0cm
39.38 0.984:1 AVERAGE
WW: 815WL: 107
IRP

APSI: VD bipartite

- Perforation-dilatation à discuter
- si très bleu à moins de 6 mois
  - Blalock ou stenting du canal artériel
- si reste bleu après 6 mois
  - DCPP

APSI : Projet thérapeutique

- Tripartite : admission + trabéculée + infundibulum
  - 2 ventricules
- Bipartite : admission + infundibulum
  - 1,8 ventricule (DCPP)
- Unipartite : croupion
  - 1 ventricule (DCPP puis DCPT)
  - Accompagnent si anomalie coronaire

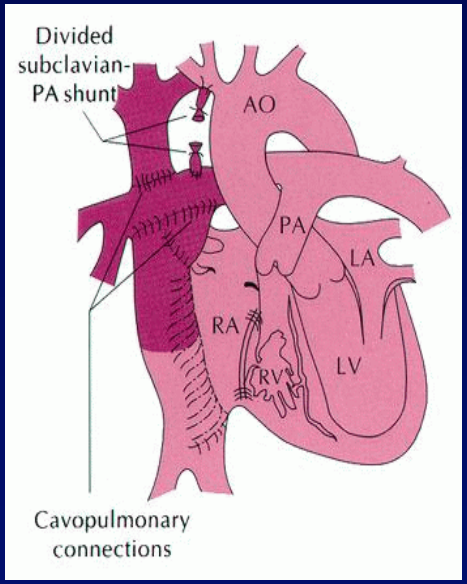

Management Algorithm in Pulmonary Atresia With Intact Ventricular Septum

Mazeni Alwi,* MBBS, MRCP

Morphologic classification and treatment strategies

Group A	Group B	Group C
Good RV anatomy TV z score >-2.5 Usually tripartite RV Membranous atresia (good infundibulum) Usually no major sinusoids Variable tricuspid regurgitation	**Intermediate anatomy** Borderline RV size (TV z score -2.5 to -4.5) Usually bipartite RV – absent or markedly attenuated trabecular component Patent infundibulum Major sinusoids may be present Minor sinusoids common ± Small PV annulus ± Subvalvar stenosis Variable tricuspid regurgitation	**Severe RV hypoplasia** TV z score <-5.0 Unipartite – absent trabecular component and diminutive/absent infundibulum (muscular atresia) Hypoplastic TV Usually competent TV Major sinusoids more common ± Stenoses or interruption
Dilatation perforation	Dilatation perforation + stenting CA DCPP	Shunt aorto-pulmonaire DCPP DCPT

Catheterization and Cardiovascular Interventions 67:679–686 (2006)