Hypoplasie du coeur gauche

Sophie Malekzadeh Milani
Cardiologie pédiatrique
Hôpital Necker Enfants malades
Centre de Référence des Malformations Cardiaques Congénitales Complexes M3C

Plan

- Principe de base
- Anatomie
- Diagnostic anténatal
- Thérapeutique anténatale
- Prise en charge néonatale - physiologie
- Chirurgie: le premier temps opératoire et réanimation
- Suivi post opératoire
- Second temps opératoire

Principes de base

Le bon candidat au Fontan

Age >4 years

Sinus rhythm

Normal systemic venous return

Normal right atrial volume

Mean pulmonary artery pressure <15 mm Hg

Pulmonary arteriolar resistance <4 Wood units/m^2

Pulmonary artery–aorta ratio >0.75

Left-ventricular ejection fraction >0.60

Competent mitral valve

Absence of pulmonary artery distortion

Choussat et al 1977

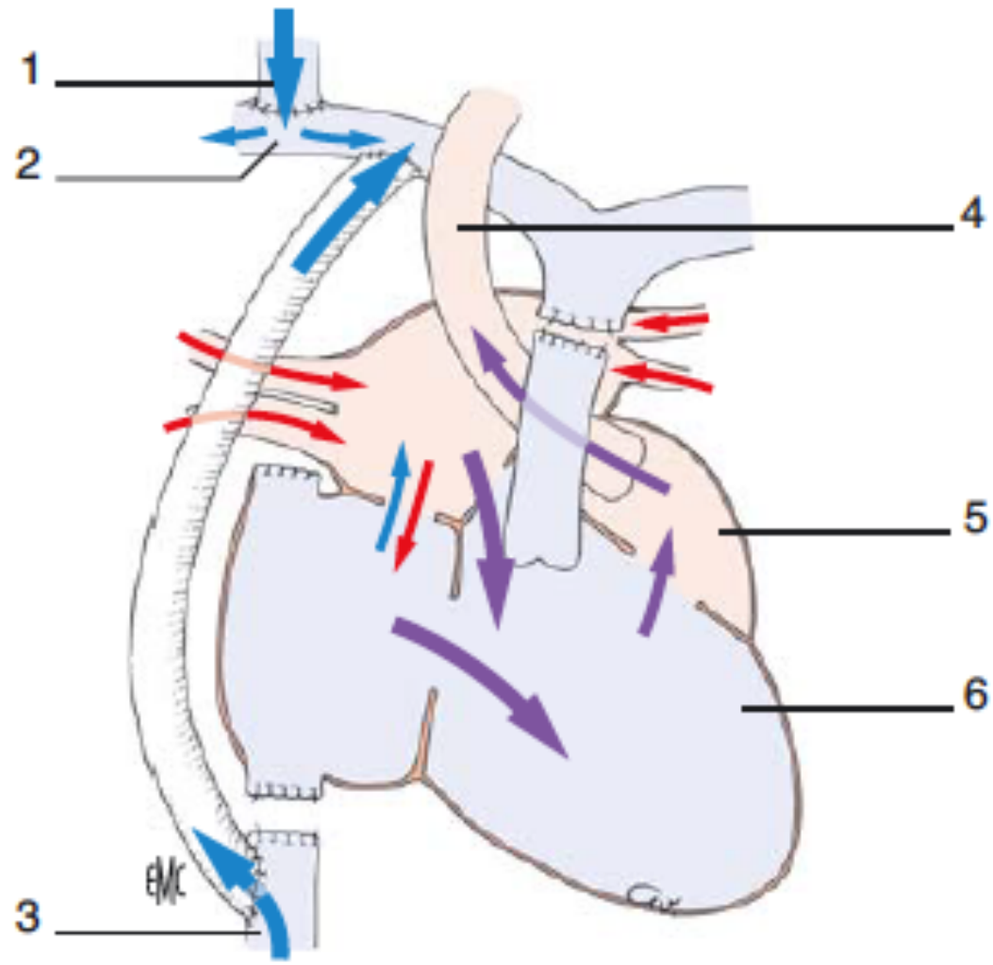

Figure 9. Dérivation cavopulmonaire totale. 1. Veine cave supérieure ; 2. artère pulmonaire ; 3. veine cave inférieure ; 4. aorte ; 5. cavité accessoire ; 6. ventricule principal.

Anatomie

Hypoplasie du coeur gauche

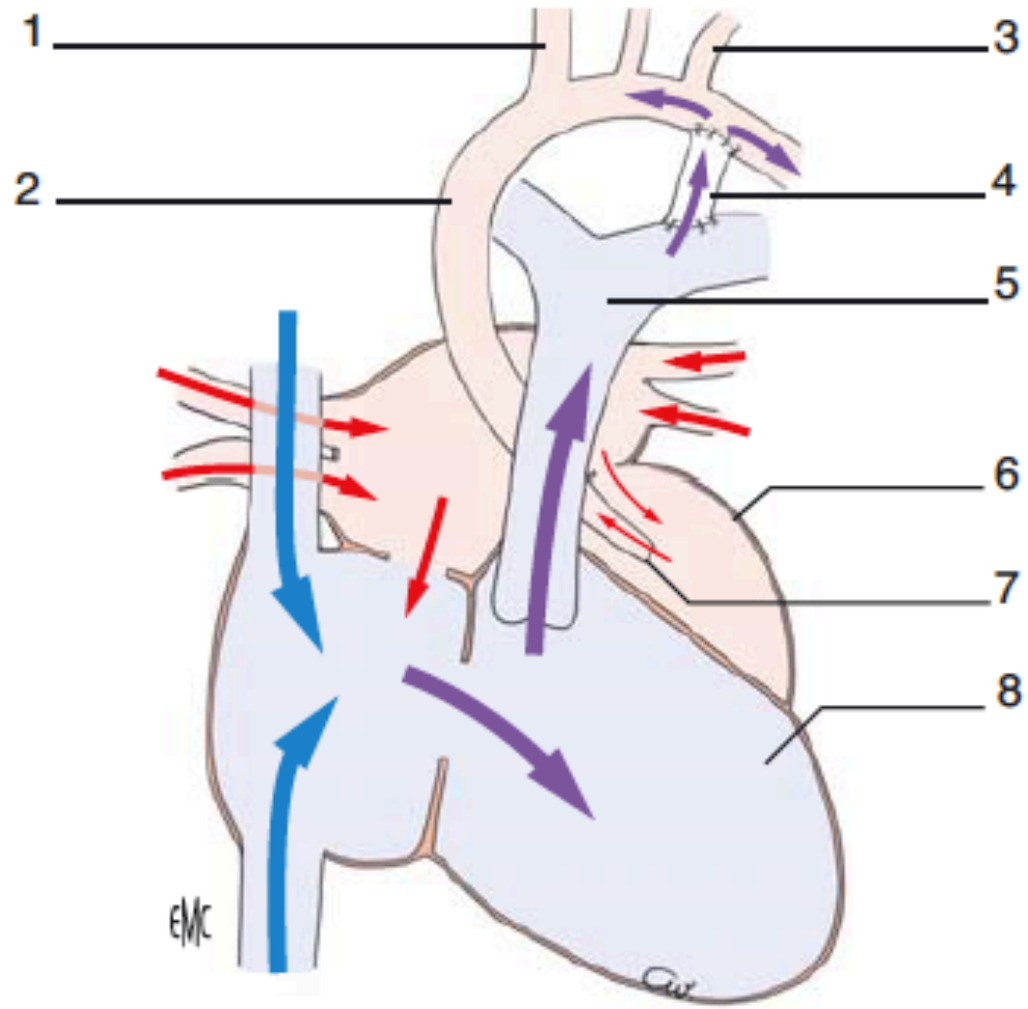

Figure 2. Hypoplasie du coeur gauche. 1. Tronc brachiocéphalique ; 2. aorte ; 3. artère sous-clavière gauche ; 4. canal artériel ; 5. artère pulmonaire ; 6. ventricule gauche hypoplasique ; 7. aorte hypoplasique ; 8. ventricule droit.

Hypoplasie du cœur gauche
Atrésie mitrale et atrésie aortique

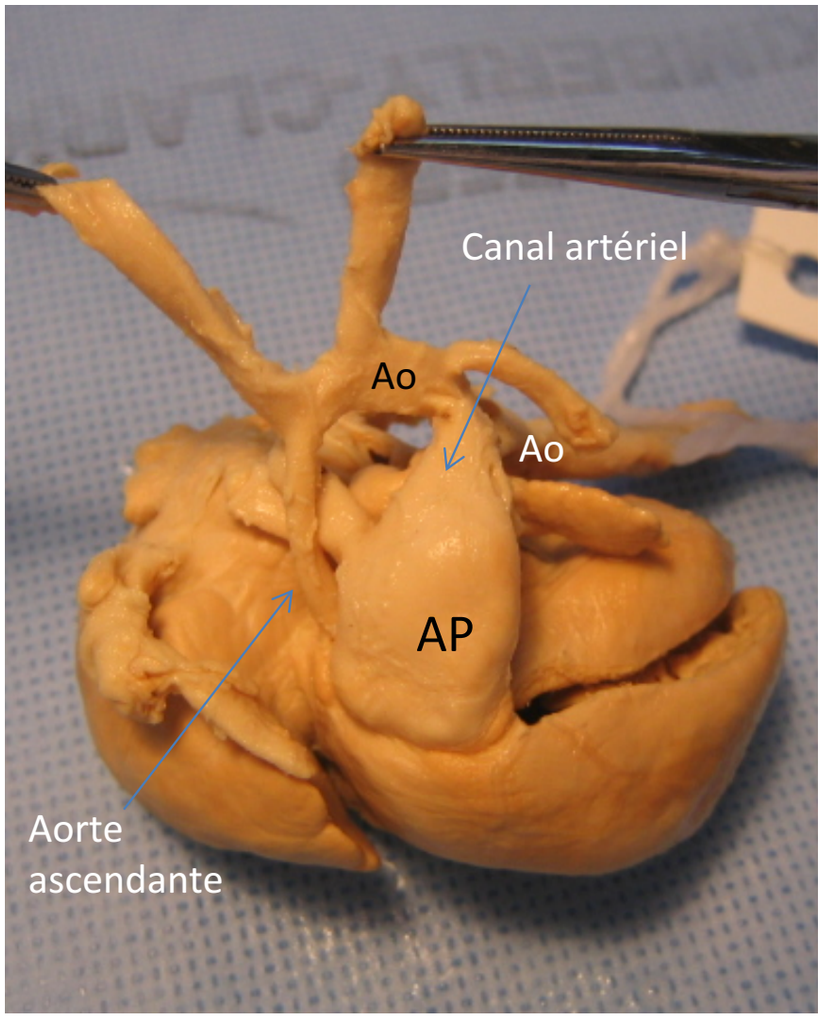

Vue antérieure du cœur, gros vaisseaux

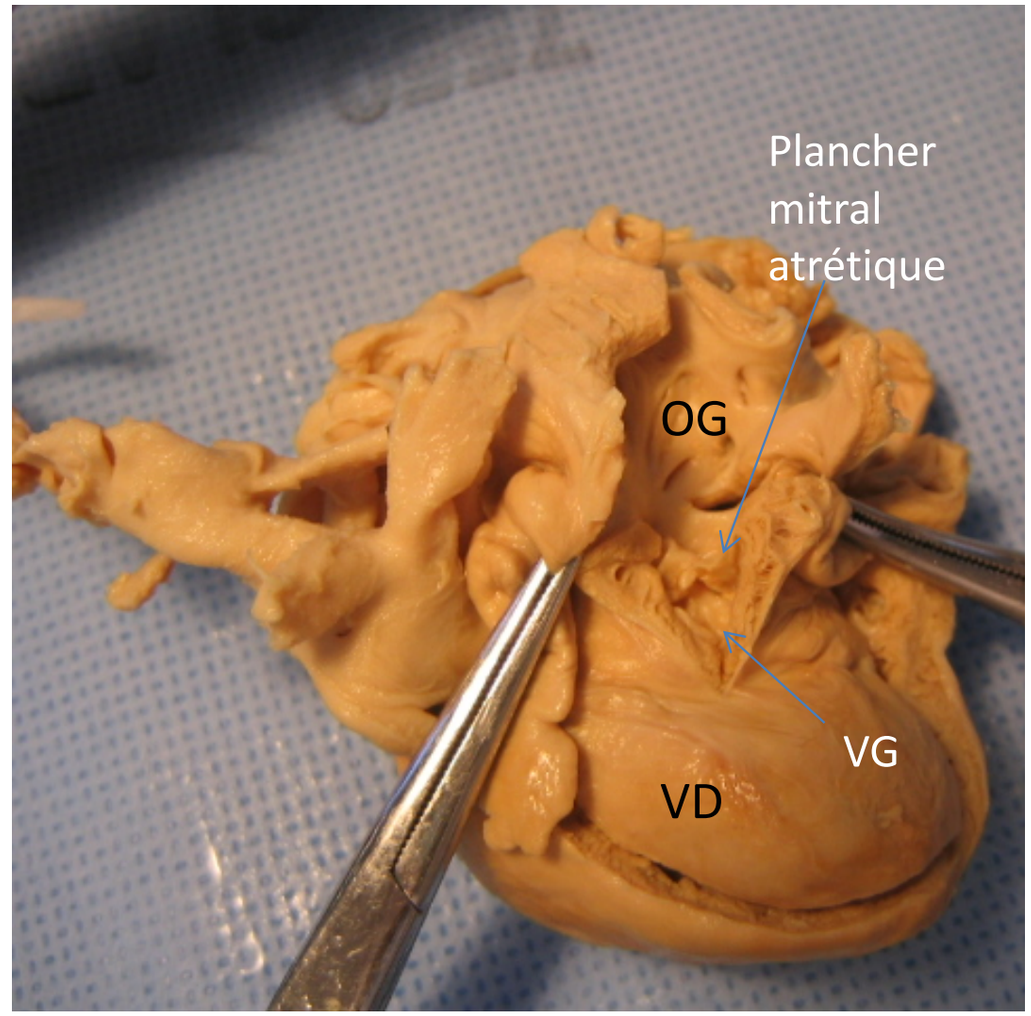

Face postérieure du coeur

Hypoplasie du cœur gauche
« forme poupée »

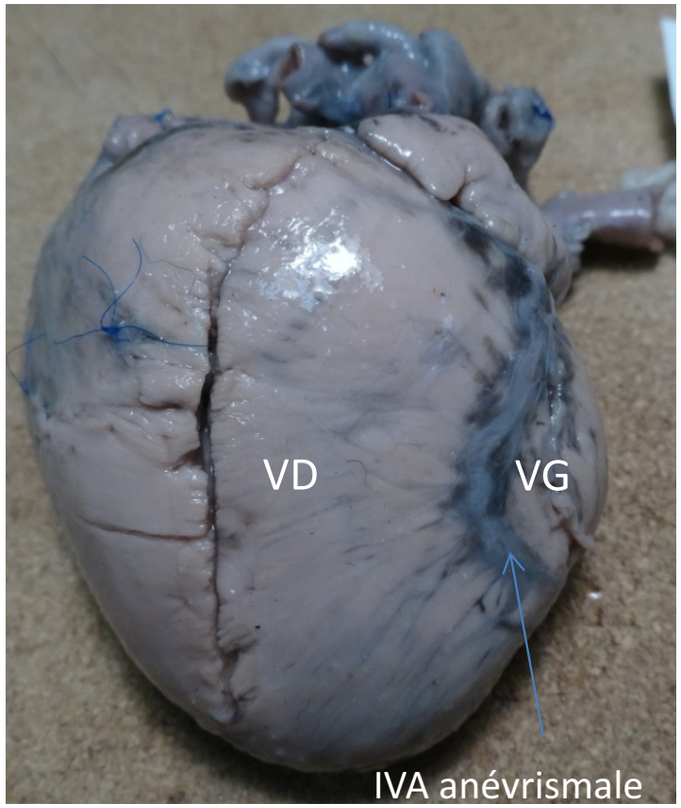

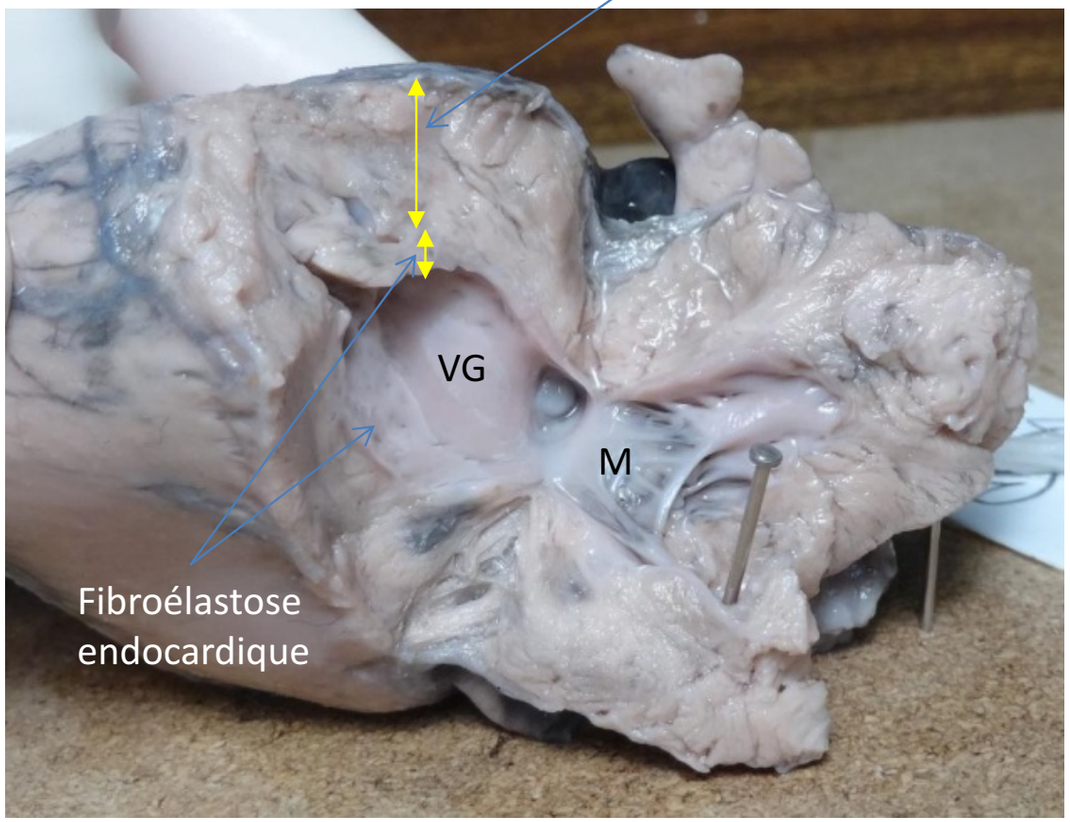

Hypoplasie valve aortique (bicuspide)
et mitrale (arcade)

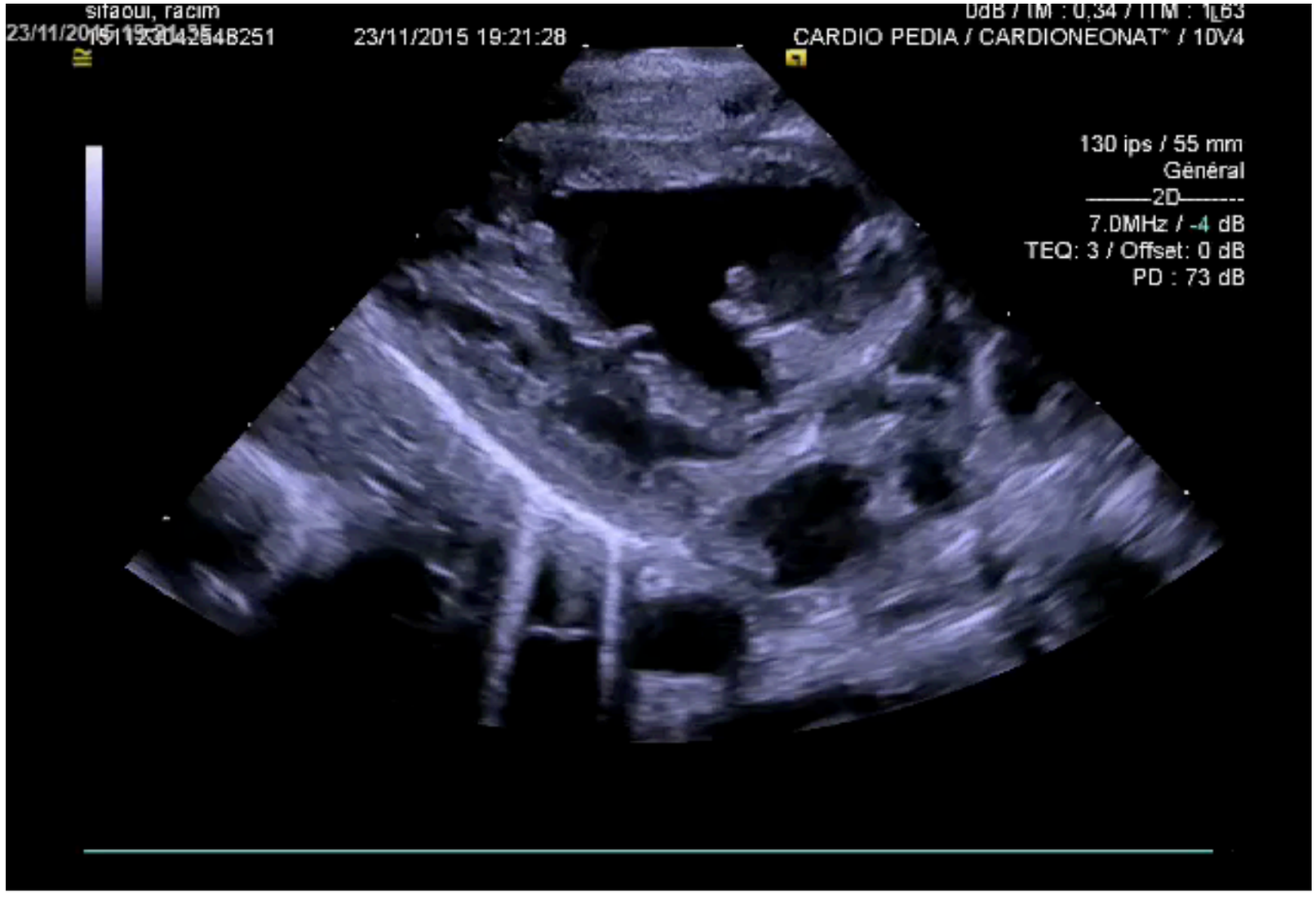
sifaoui, racim
23/11/2015 19:21:28
23/11/2015 19:21:28
CARDIO PEDIA / CARDIONEONAT* / 10V4
130 ips / 55 mm
Général
2D
7.0MHz / -4 dB
TEQ: 3 / Offset: 0 dB
PD : 73 dB

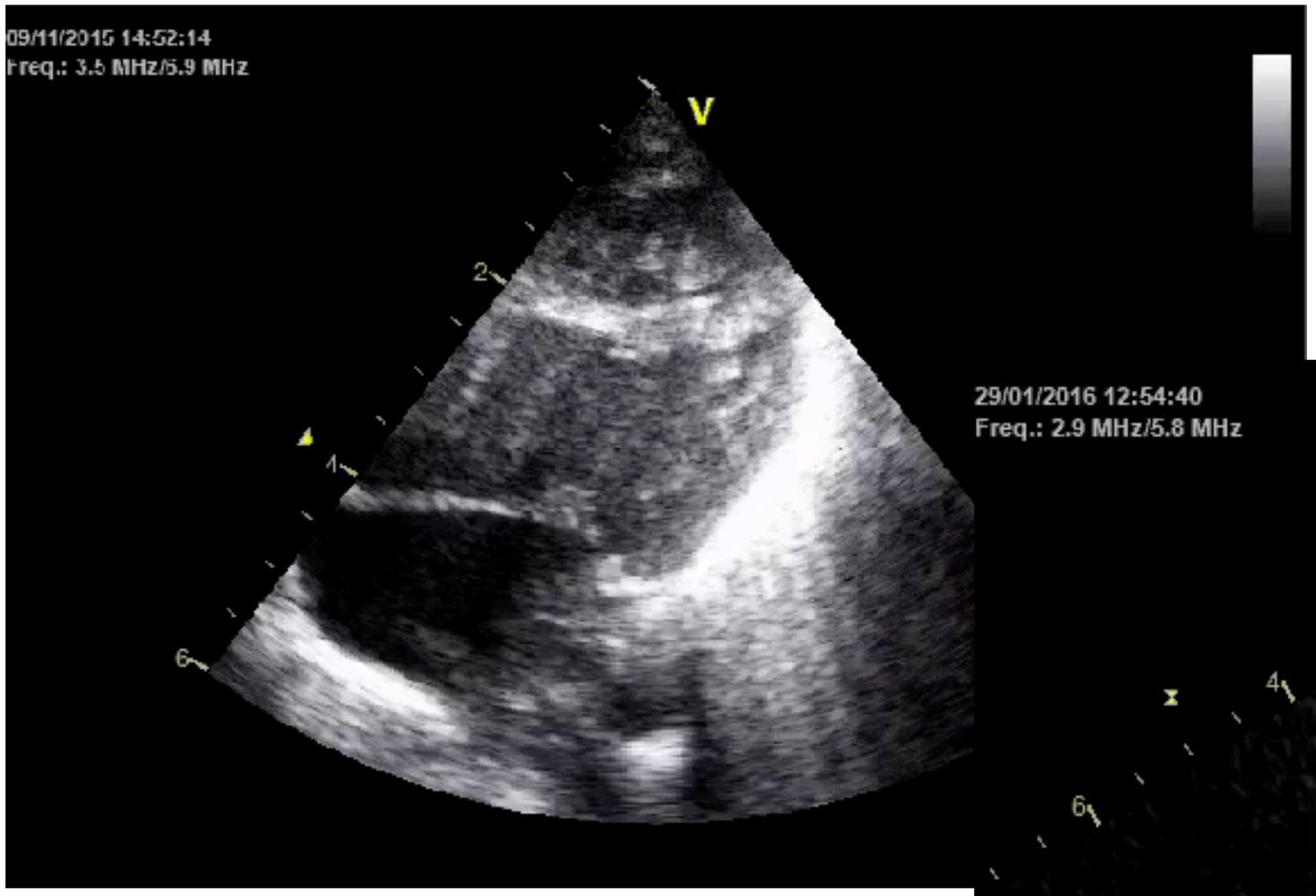
09/11/2015 14:52:14
Freq.: 3.5 MHz/5.9 MHz
V
2
4
6

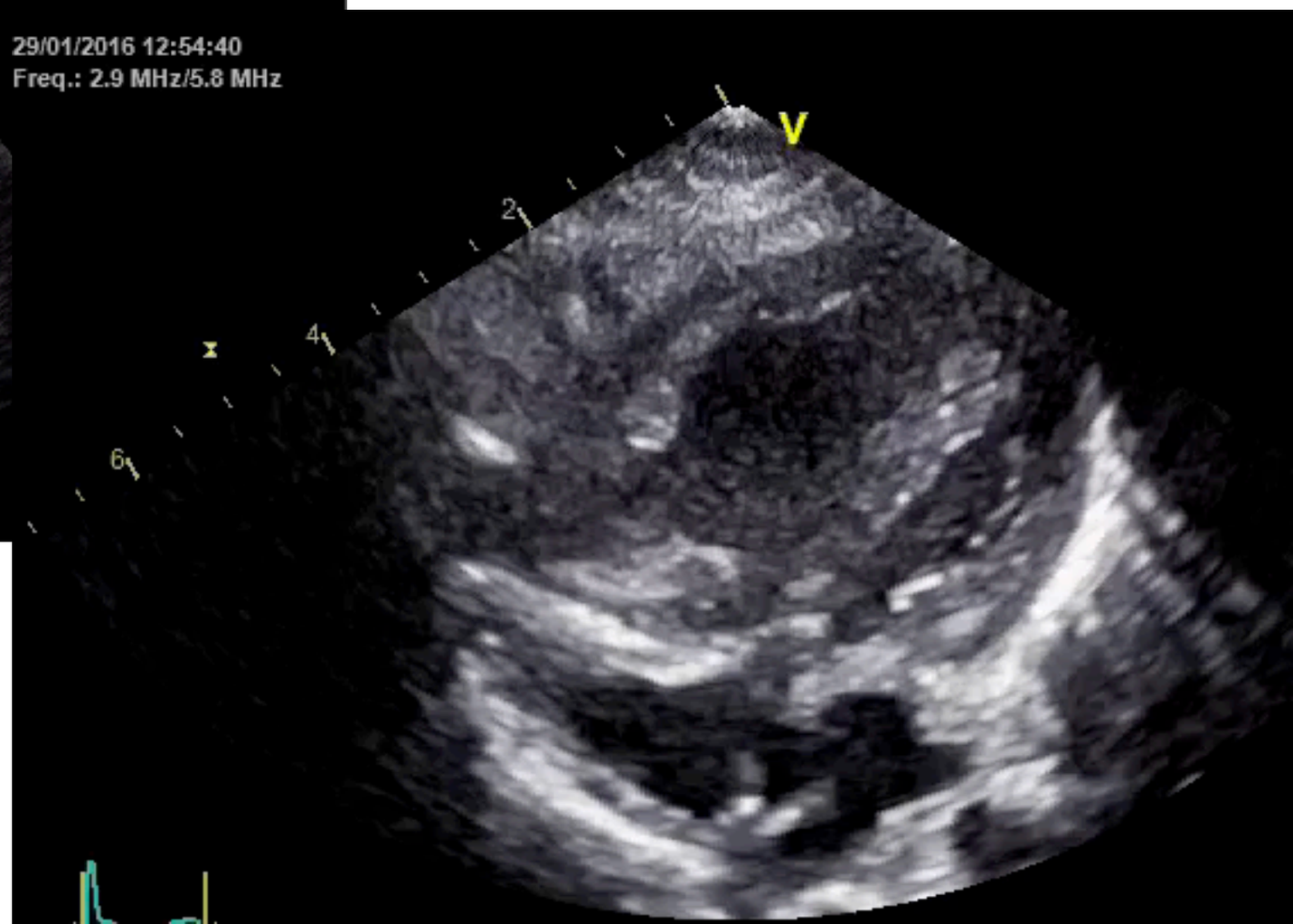
29/01/2016 12:54:40
Freq.: 2.9 MHz/5.8 MHz
V
2
4
6

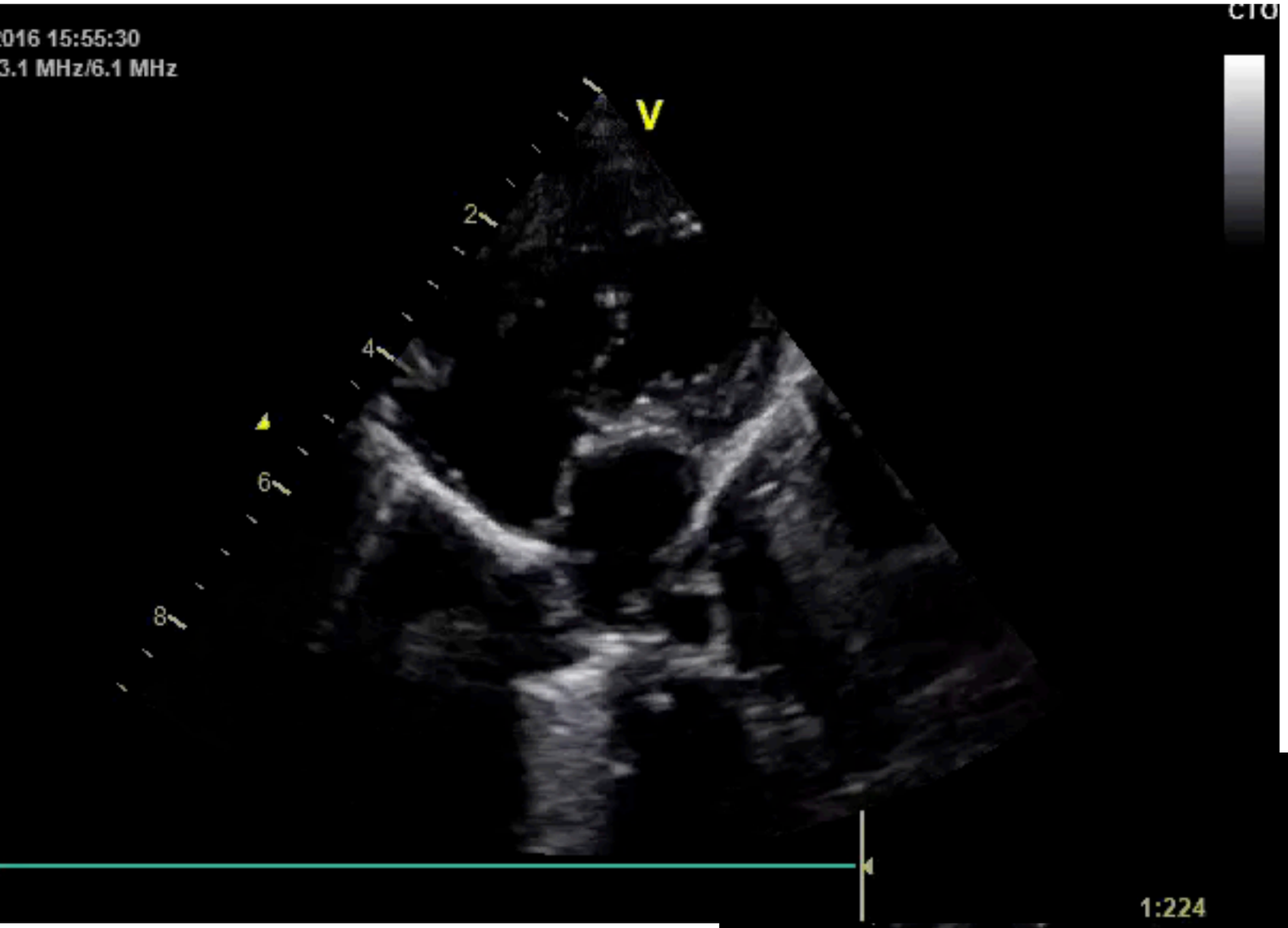
2016 15:55:30
3.1 MHz/6.1 MHz
V
2
4
6
8

1:224
4

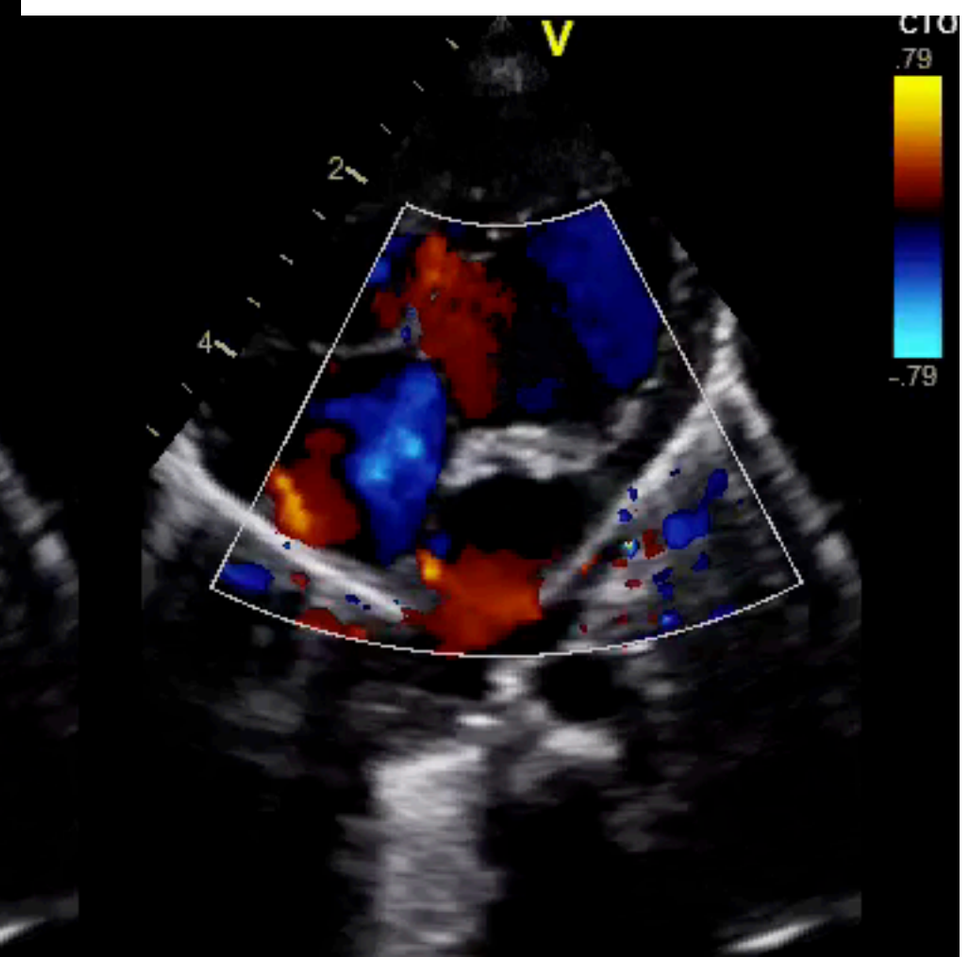
V
2
4
.79
-.79

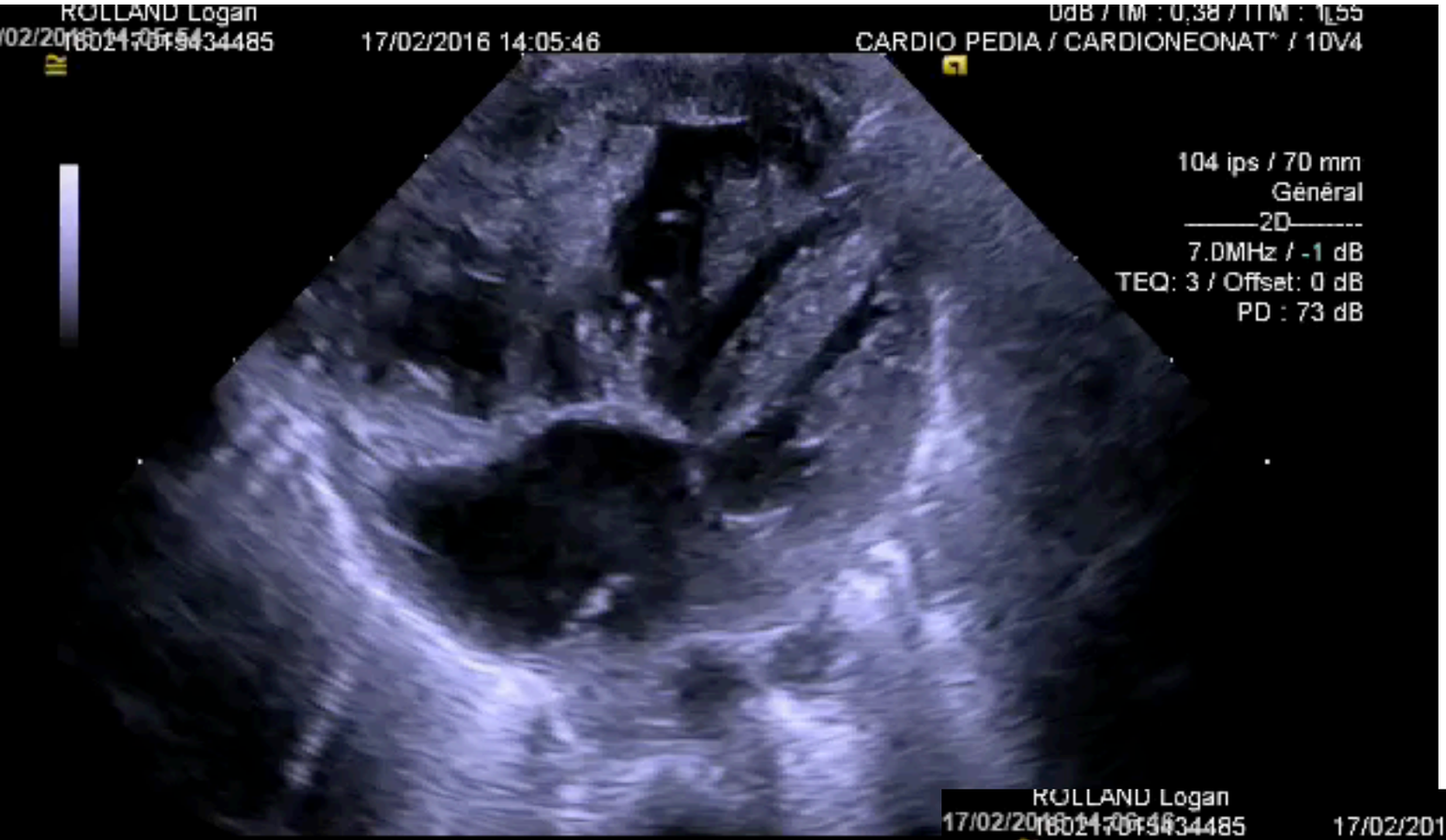
ROLLAND Logan
17/02/2016 14:05:46
CARDIO PEDIA / CARDIONEONAT* / 10V4
104 ips / 70 mm
Général
2D
7.0MHz / -1 dB
TEQ: 3 / Offset: 0 dB
PD : 73 dB

ROLLAND Logan
17/02/2016 14:06:04
CARDIO PEDIA / CARDIONEONAT* / 10V4
104 ips / 70 mm
Général
2D
7.0MHz / -3 dB
TEQ: 3 / Offset: 0 dB
PD : 73 dB

Diagnostic anténatal

Traitements anténataux

3 types de sténose aortique foetale

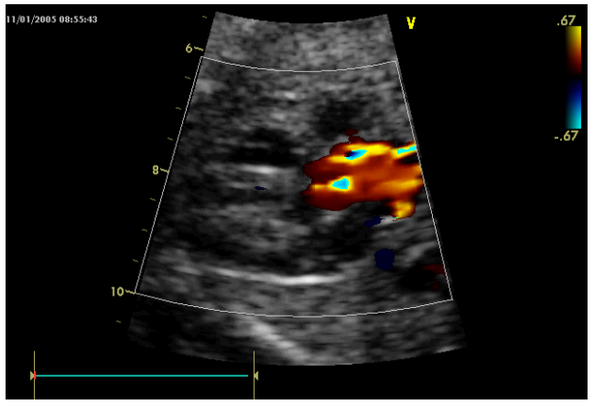

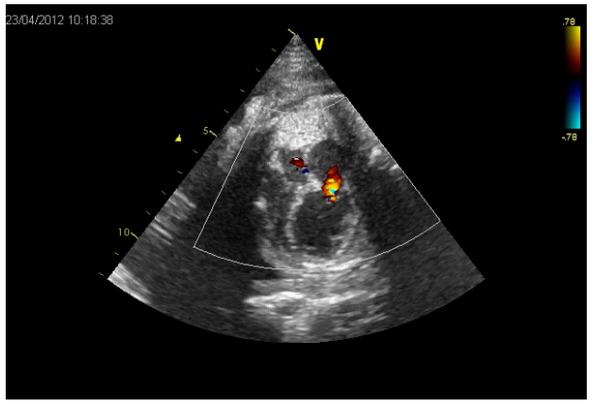

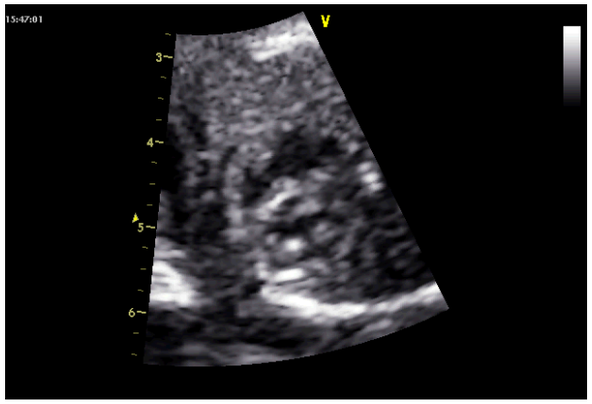

Necker
ENFANTS MALADES
HÔPITAL UNIVERSITAIRE

Sténose aortique foetale

Différents phénotypes

✓Sténose aortique avec VG adapté, hypertrophié: suivi rapproché de la fonction ventriculaire gauche, évolutivité possible

✓Sténose aortique avec VG non adapté, dilaté
Risque de MFIU
T3: suivi très rapproché, traitement néonatal
T2: proposition de traitement in utéro chez certains Patients

✓Sténose aortique avec VG petit, fibreux
Stratégie univentriculaire à la naissance

Evolution of the disease

[Allan, Int. J. Cardiology 1989]

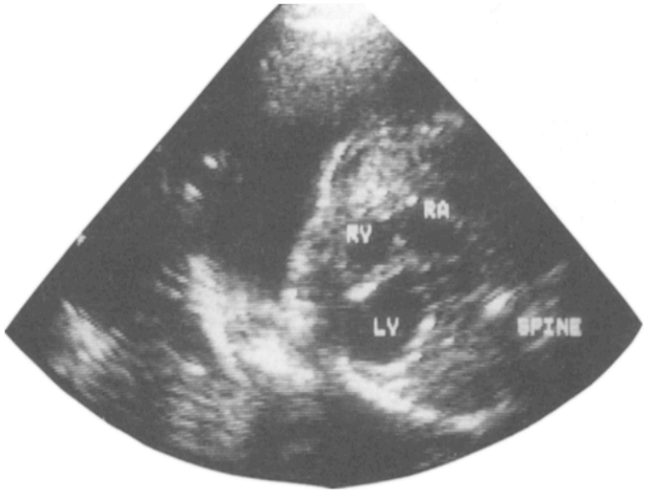

22 weeks gestation

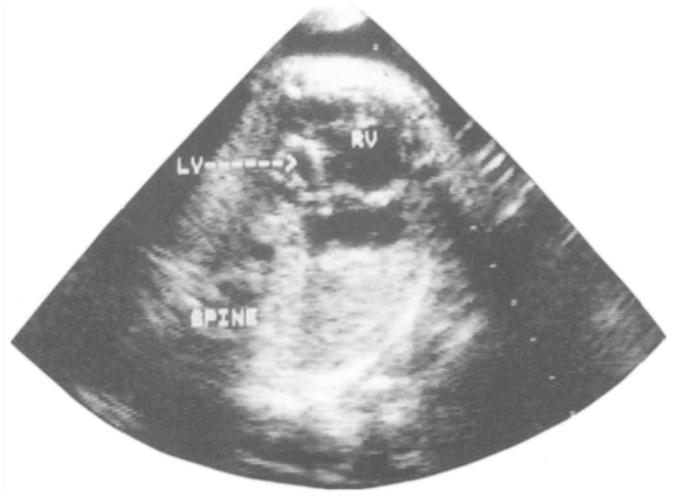

32 weeks gestation

Necker
ENFANTS MALADES
HÔPITAL UNIVERSITAIRE

Histoire de la dilatation foetale 1989-2000

Br Heart J 1991;65:256–8

Balloon dilatation of the aortic valve in the fetus: a report of two cases

Darryl Maxwell, Lindsey Allan, Michael J Tynan

Ultrasound Obstet. Gynecol. 5 (1995) 90–91

Survival after fetal aortic balloon valvoplasty

L. D. Allan, D. J. Maxwell, M. Carminati and M. J. Tynan*

Departments of Fetal Cardiology, Fetal Medicine and Paediatric Cardiology, Guy's Hospital, London; and *Division of Cardiology, Bergamo, Italy

World Experience of Percutaneous Ultrasound-Guided Balloon Valvuloplasty in Human Fetuses With Severe Aortic Valve Obstruction

Thomas Kohl, MD, Gurleen Sharland, MD, Lindsey D. Allan, MD, Ulrich Gembruch, MD, Rabih Chaoui, MD, Lilian M. Lopes, MD, Paulo Zielinsky, MD, James Huhta, MD, and Norman H. Silverman, MD

Prenatal alleviation of severe fetal aortic valve obstructions by percutaneous ultrasound-guided balloon valvuloplasty has been performed to improve the fate of affected fetuses. The purpose of this study was to analyze the current world experience of these procedures in human fetuses. Data from 12 human fetuses were available for analysis. The mean gestational age at intervention was 29.2 weeks (range 27 to 33). The mean time period between initial presentation and intervention was 3.3 weeks (range 3 days to 9 weeks). Technically successful balloon valvuloplasties were achieved in 7 fetuses, none of whom had an atretic valve. Only 1 of these fetuses remains alive today. Of the 5 remaining technical failures, 1 patient with severe aortic stenosis underwent successful postnatal intervention and remains alive. Six patients who survived prenatal intervention died from cardiac dysfunction or at surgery in the first days or weeks after delivery. Four fetuses died early within 24 hours after the procedure, 1 from a bleeding complication, 2 from persistent bradycardias, and 1 at valvotomy after emergency delivery. Thus, the early clinical experience of percutaneous ultrasound-guided fetal balloon valvuloplasty in human fetuses with severe aortic valve obstruction has been poor due to selection of severe cases, technical problems during the procedure, and high postnatal operative mortality in fetuses who survived gestation. Improved patient selection and technical modifications in interventional methods may hold promise to improve outcome in future cases. ©2000 by Excerpta Medica, Inc.

(Am J Cardiol 2000;85:1230–1233)

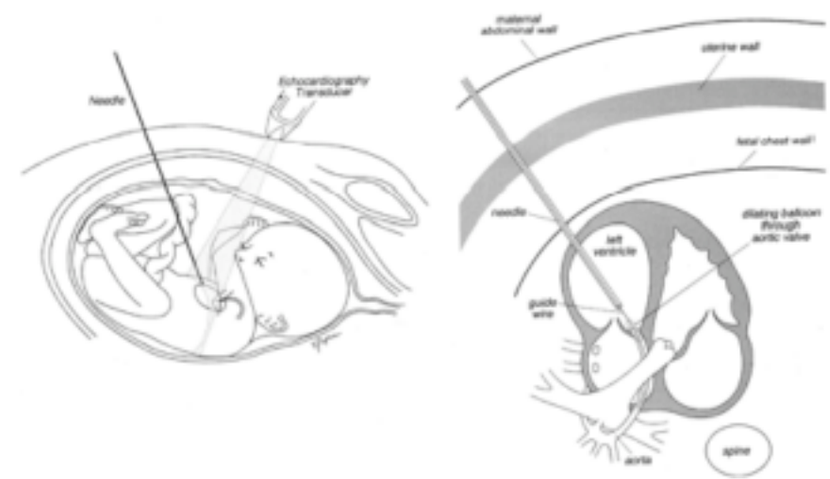

Necker
ENFANTS MALADES
HÔPITAL UNIVERSITAIRE

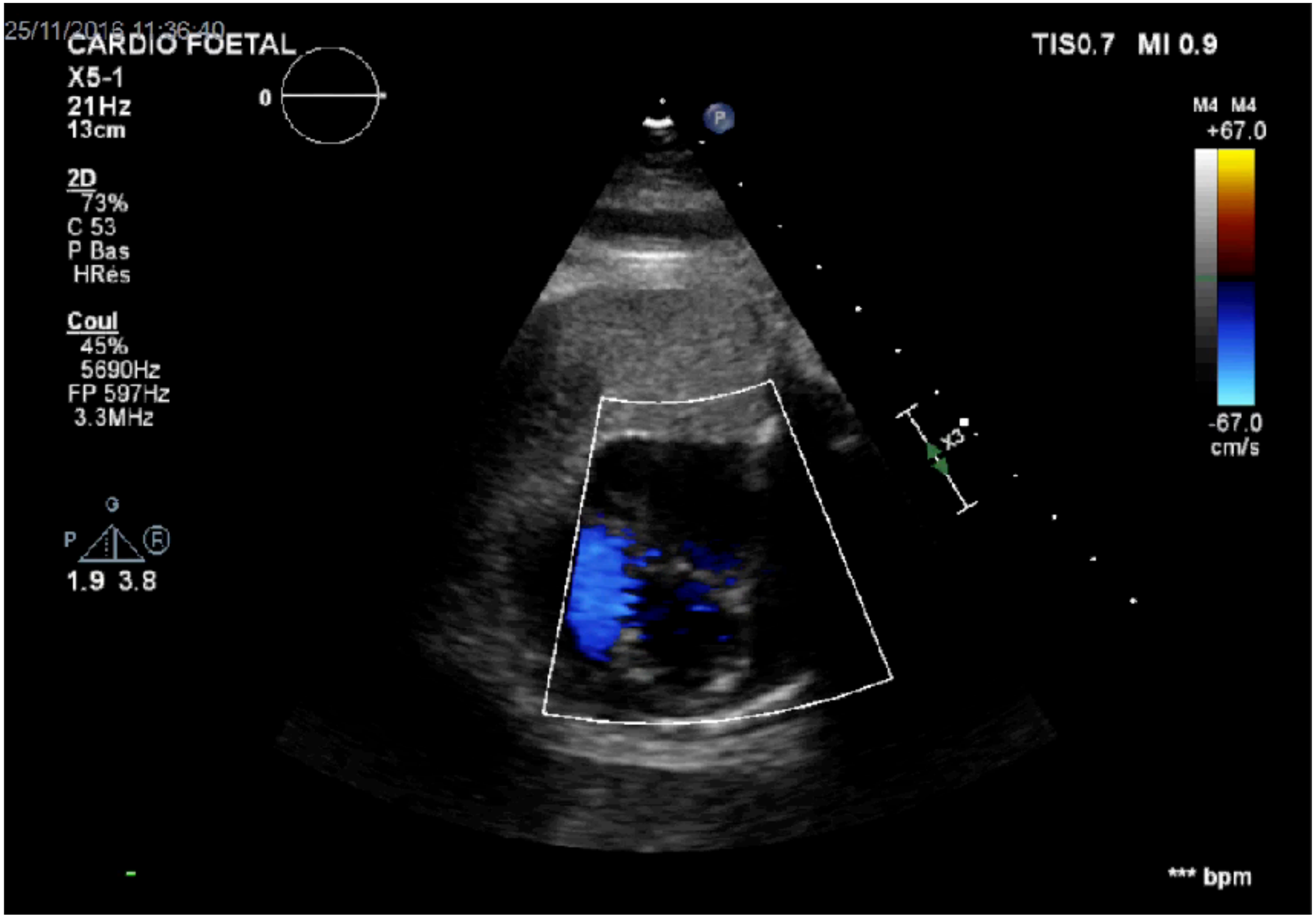
25/11/2016 11:36:40
CARDIO FOETAL
X5-1
21Hz
13cm
0
2D
73%
C 53
P Bas
HRés
Coul
45%
5690Hz
FP 597Hz
3.3MHz
P
F
1.9 3.8
TIS0.7 MI 0.9
M4 M4
+67.0
-67.0
cm/s
x3
*** bpm

- Stenting ou ouverture de la CIA restrictive

Bref rappel de physiologie

Physiologie du cœur univentriculaire

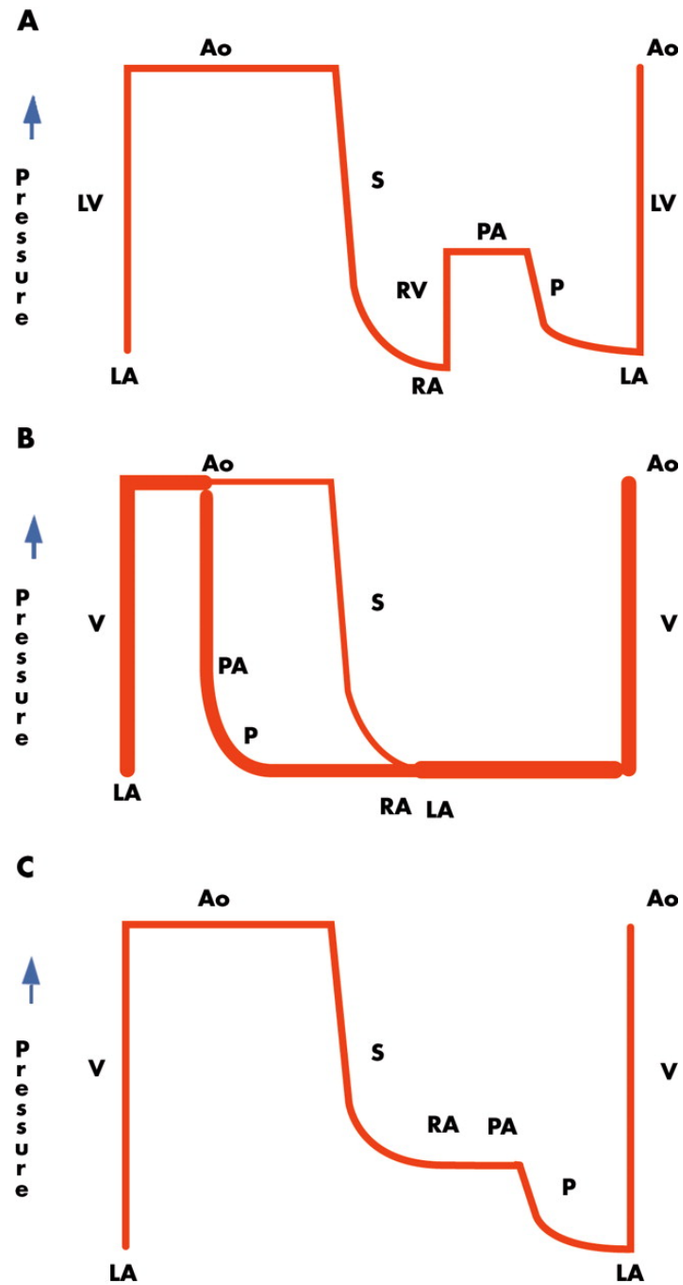

Période néonatale

Doit on proposer systématiquement une prise en charge palliative?

- Les questions posées?
- Décision éthique

1. Respect de l'autonomie
2. Information éclairée
3. Principe de non malfaisance (primum non nocere)
4. Principe de bienfaisance
5. Intégrer le critère du coût économique

Rappel physiologie néonatale

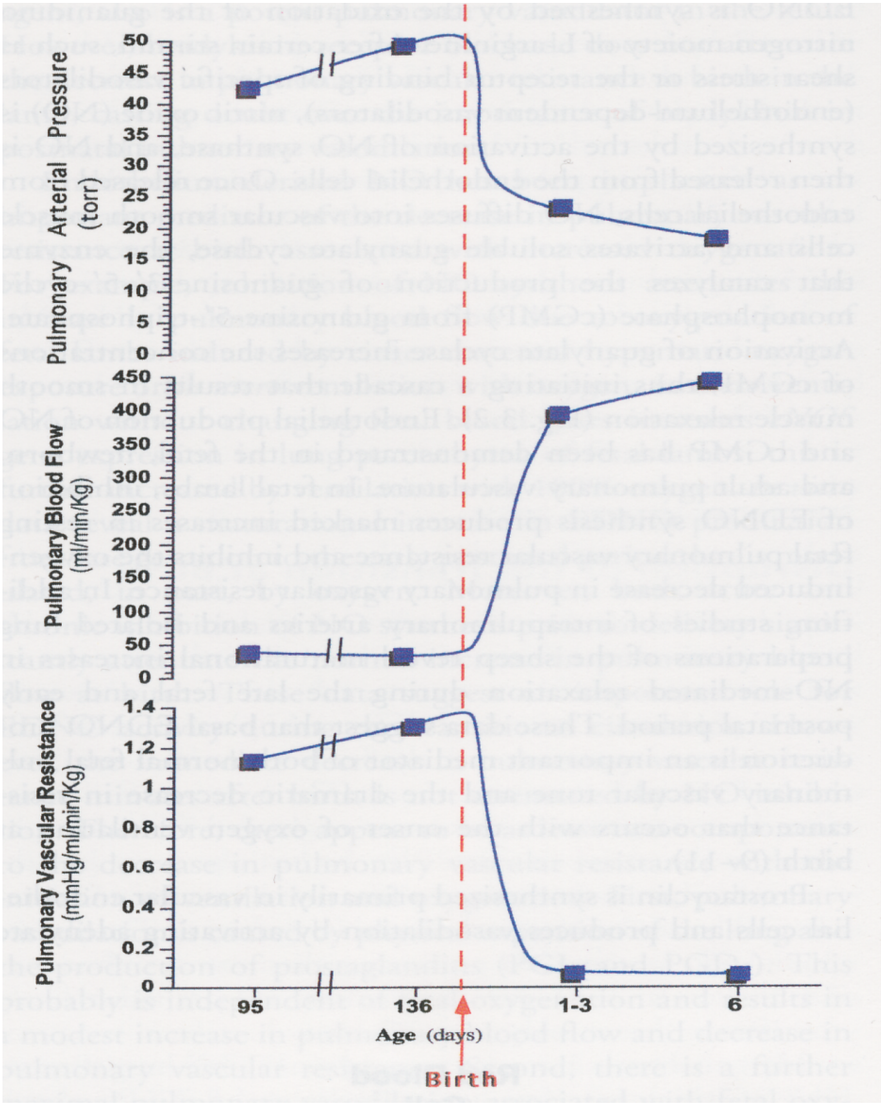

Objectifs de prise en charge d'un VU

- **Protéger la circulation pulmonaire**
  - Cerclage
  - Lever les obstacles au retour veineux: CIA – RVPA bloqués
- **Calibrer le débit pulmonaire**
  - Blalock, conduit VU-AP
- **Préserver la fonction du ventricule et des VAV**
  - Réduire la post-charge
    - Coarctation, sténose sous aortique
  - Limiter la surcharge diastolique
    - Calibrer le débit pulmonaire
  - Essayer de limiter la durée de clampage aortique pendant la chirurgie
- **Préserver les artères pulmonaires et les veines systémiques**
- **Limiter les cicatrices atriales et ventriculaires**

En période néonatale

- ✓ Equilibre des 2 circulations
- ✓ Voie d'éjection gauche libre, sans obstacle
- ✓ Voie droite avec débit pulmonaire calibré
- ✓ Lever les obstacles au retour veineux pulmonaire (RVPA, CIA restrictive)

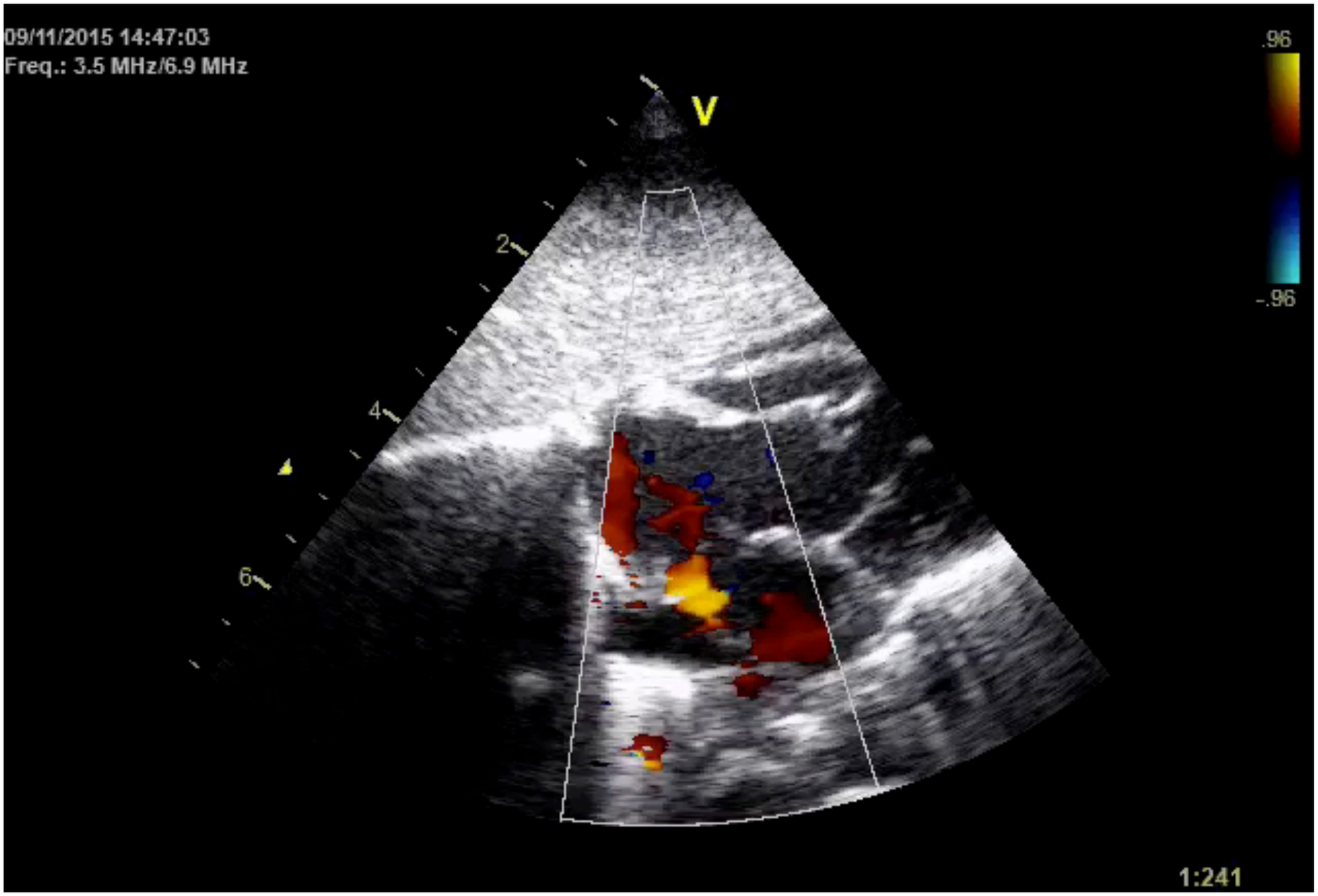
09/11/2015 14:47:03
Freq.: 3.5 MHz/6.9 MHz
V
2
4
6
.96
-.96
1:241

Particularités de l’HypoVG

- Circulation coronaire à risque
- Ventricule droit systémique
- Chirurgie plus longue et complexe que dans les autres cardiopathies univentriculaires

Pourquoi ne peut-on pas séparer les 2 circulations en période néonatale?

Elevation des RVP les premières semaines de vie
Vaisseaux trop petits (VCS, AP, VCI)

Même après la chute des résistances, une approche séquentielle est préférée pour la connection de la VCS puis de la VCI. Cela permet au corps et au cœur de s'adapter à des physiologies très différentes, diminue la mortalité et la morbidité globale

Prise en charge chirurgicale ou hybride

Norwood hybride

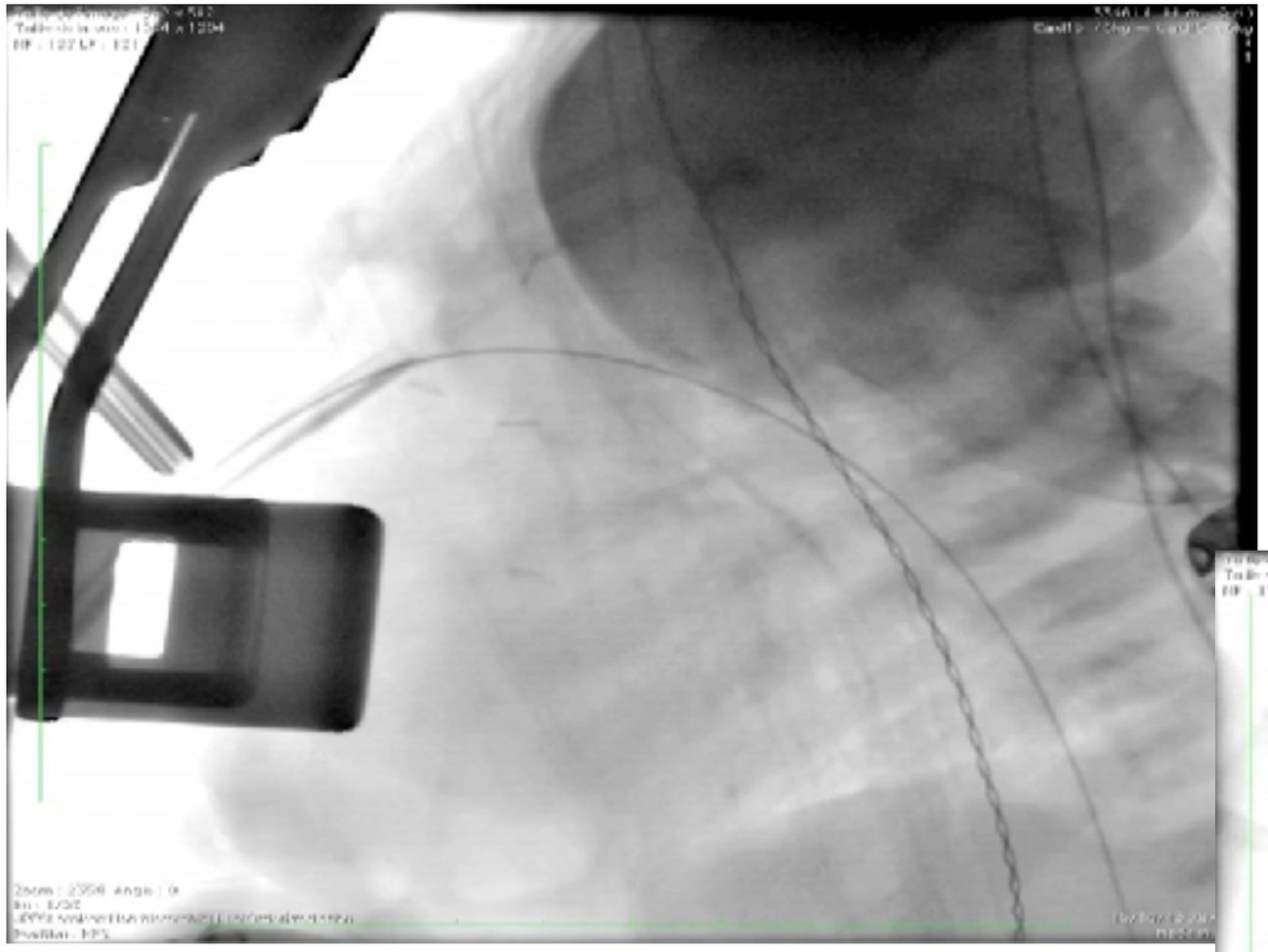

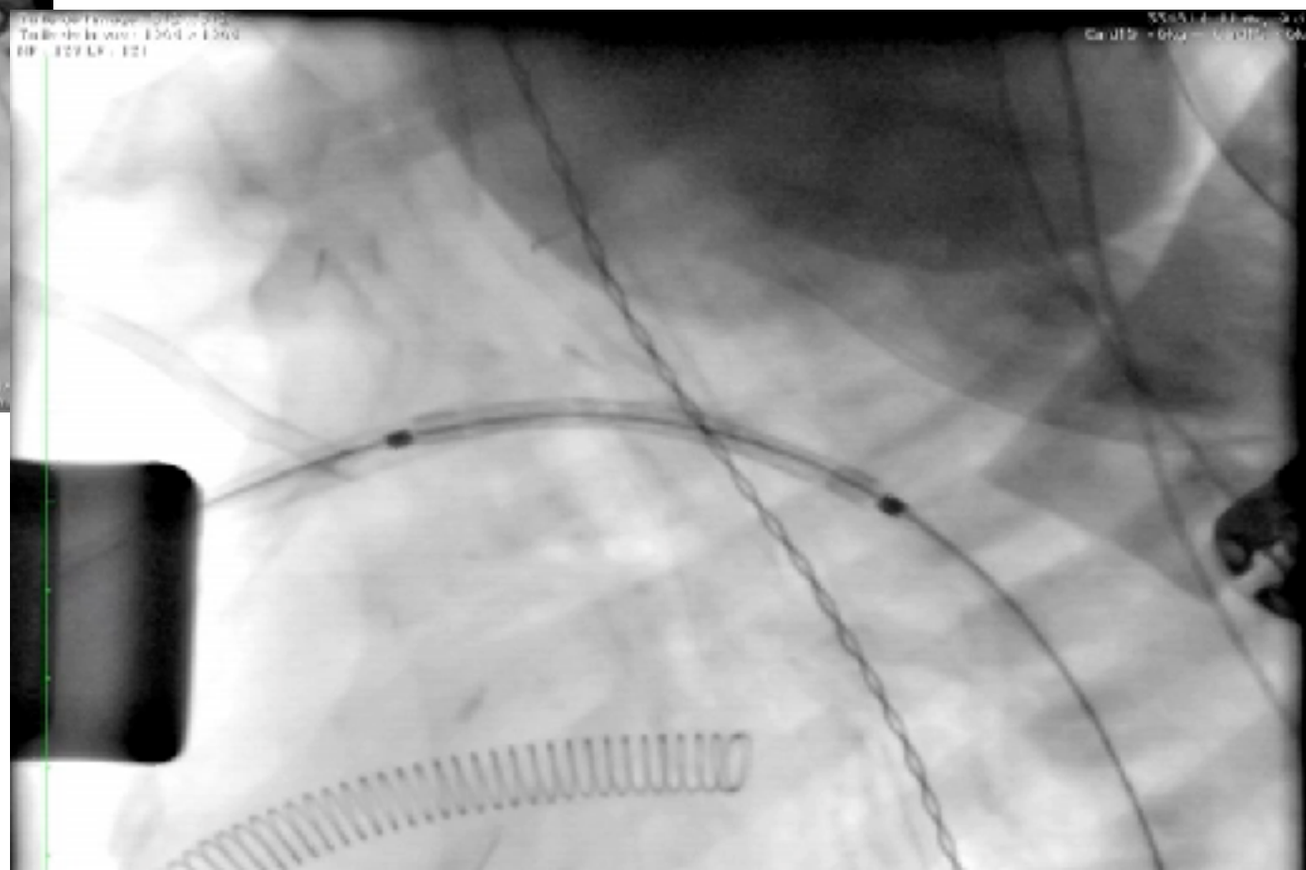

Norwood hybride

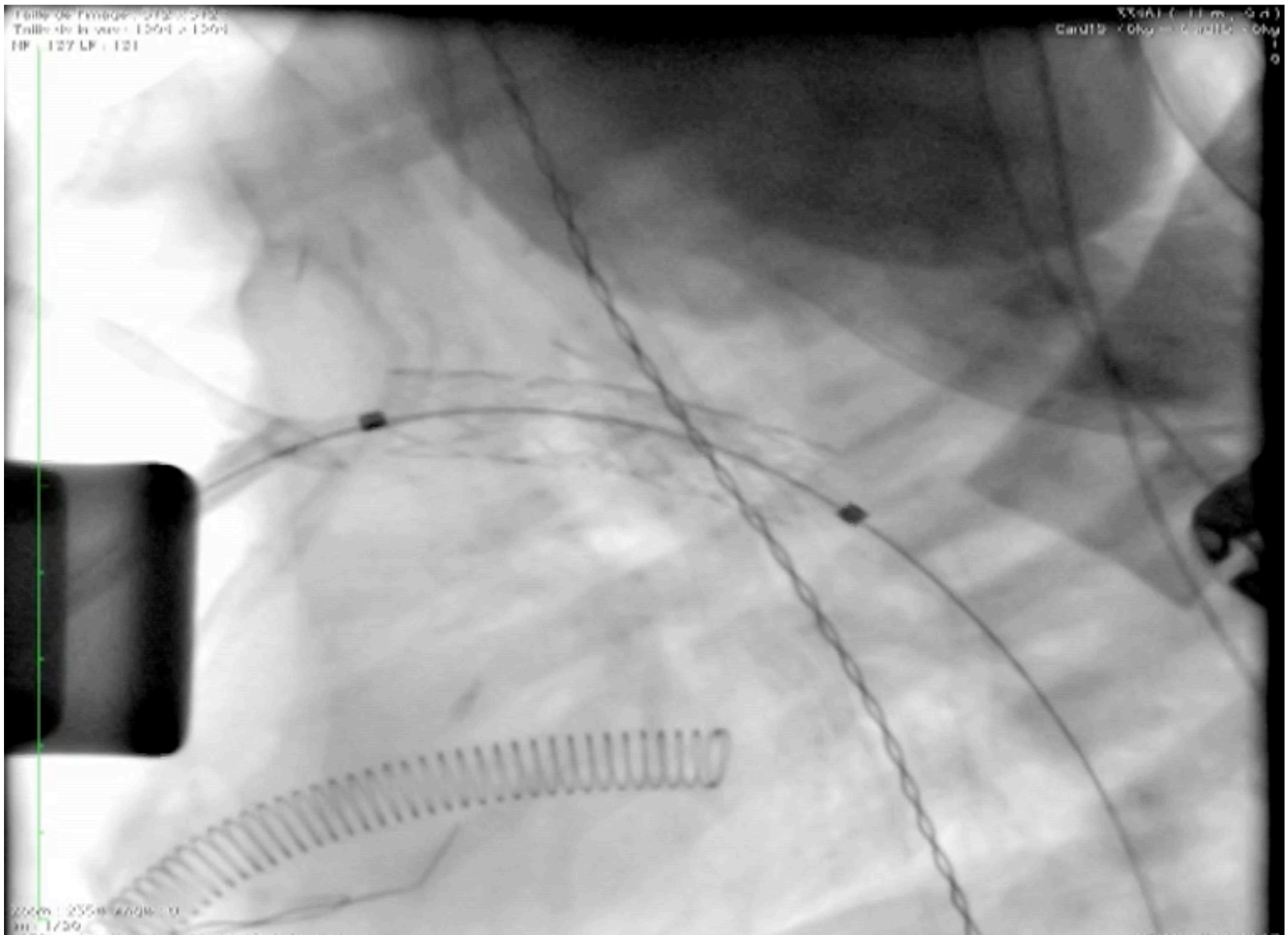

Suivi post premier temps de Norwood

- Suivi clinique très rapproché
- Prise pondérale
- Saturation
- Pouls fémoraux
- Echographie

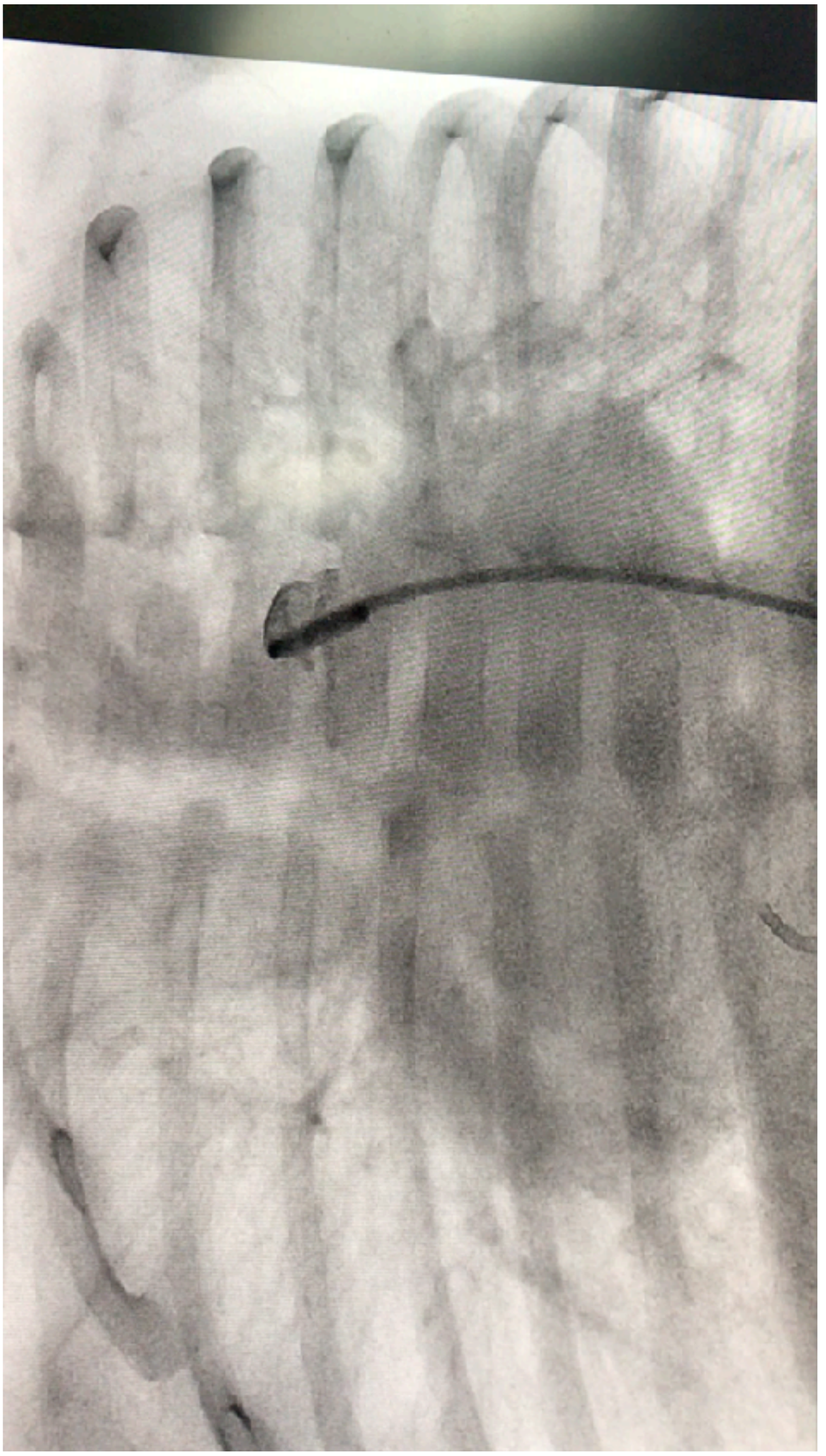

Second temps opératoire

- Bilan par cathétérisme
- Prise des pressions
- Anatomie
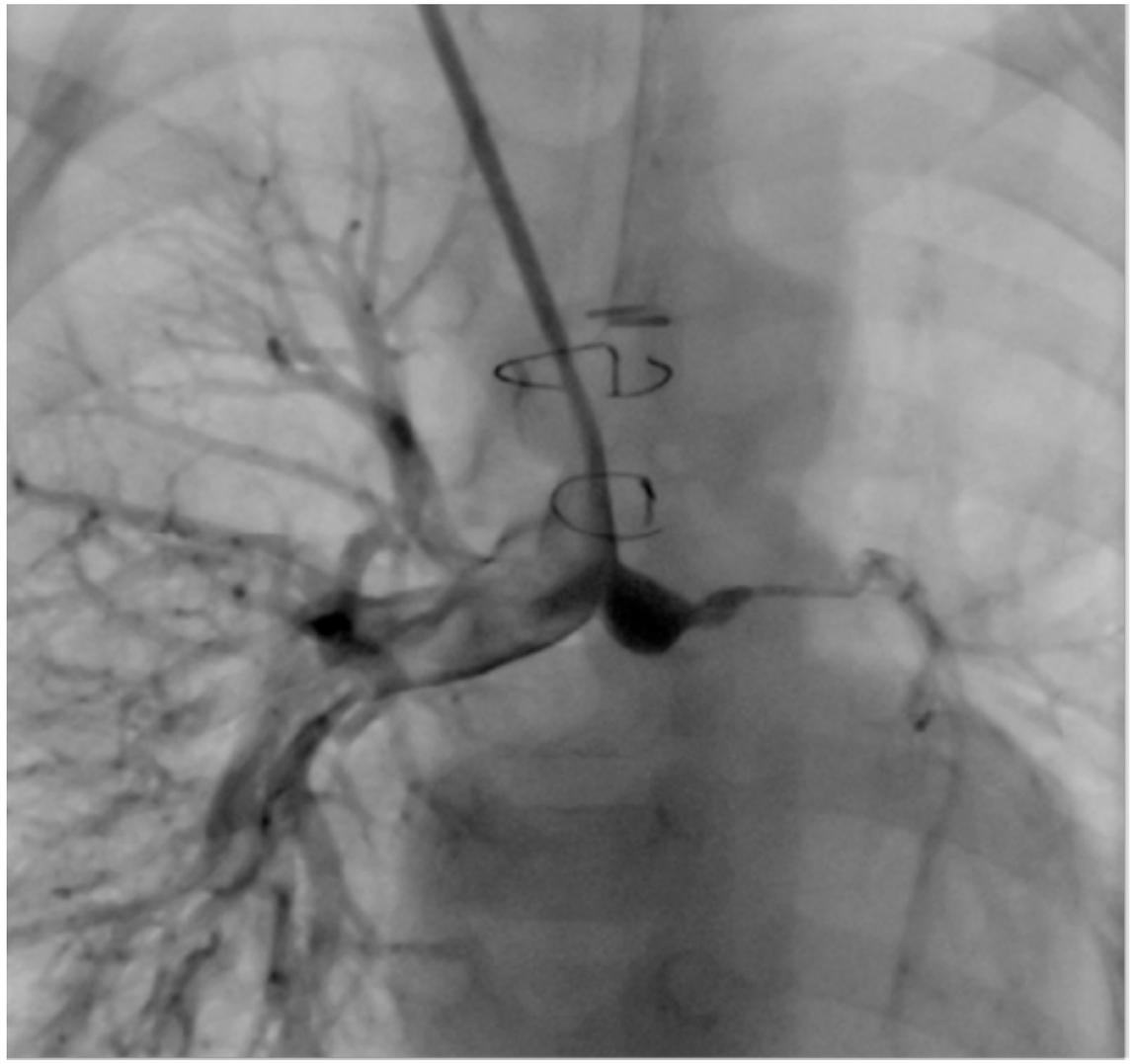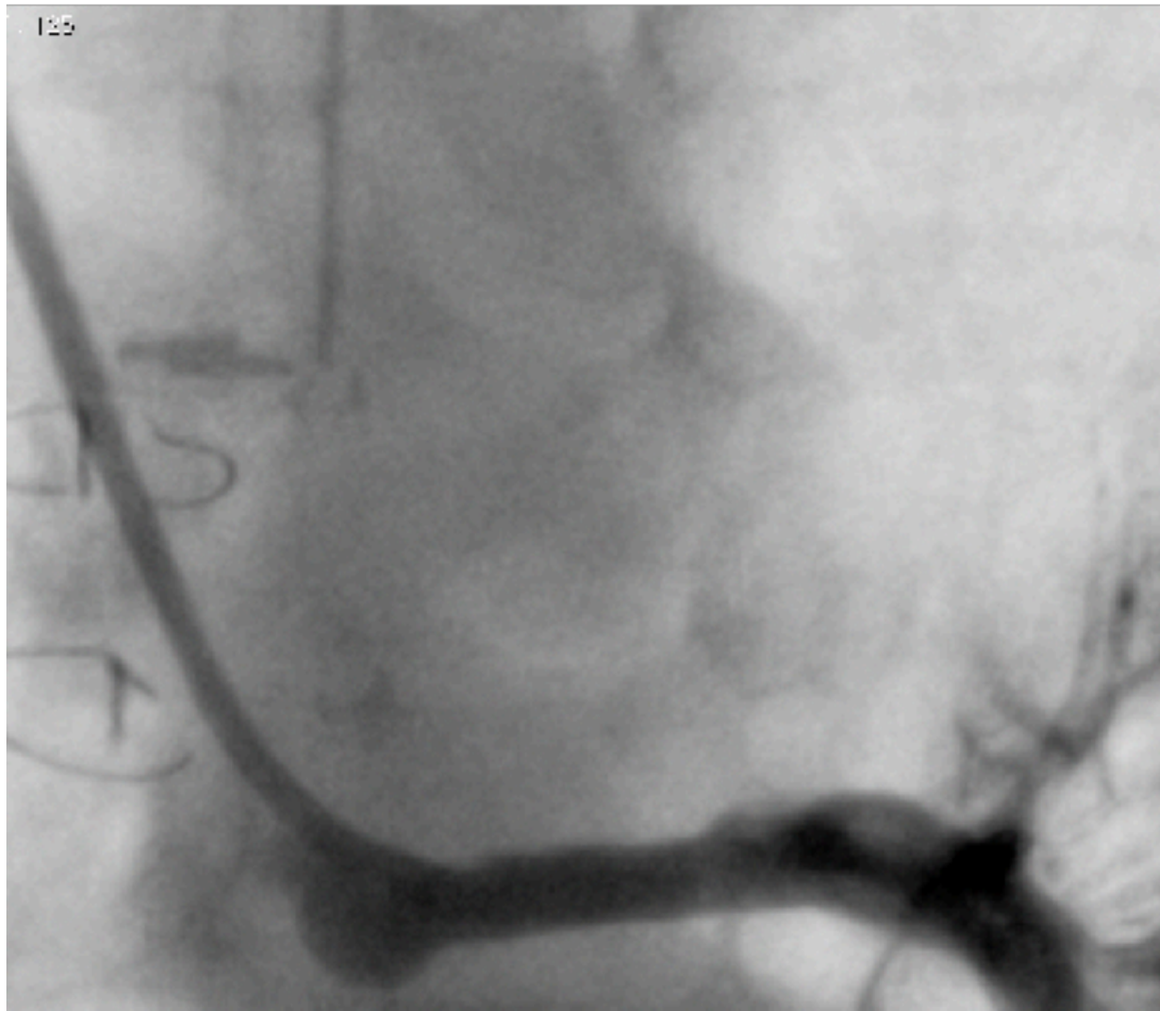
Complications après le second temps opératoire