PERSISTANCE DU CANAL ARTERIEL

Anatomie chirurgicale

Traitement chirurgical

Problèmes chirurgicaux

CANAL ARTERIEL : RAPPELS

- Seconde cardiopathie congénitale :
  - 1,5/3000
- Nnés :
  - Fermeture en 72 H
  - Fermeture rare > 3 mois
- Prématurés (< 1 kg) :
  - 80 % à une semaine de vie

Anatomie chirurgicale

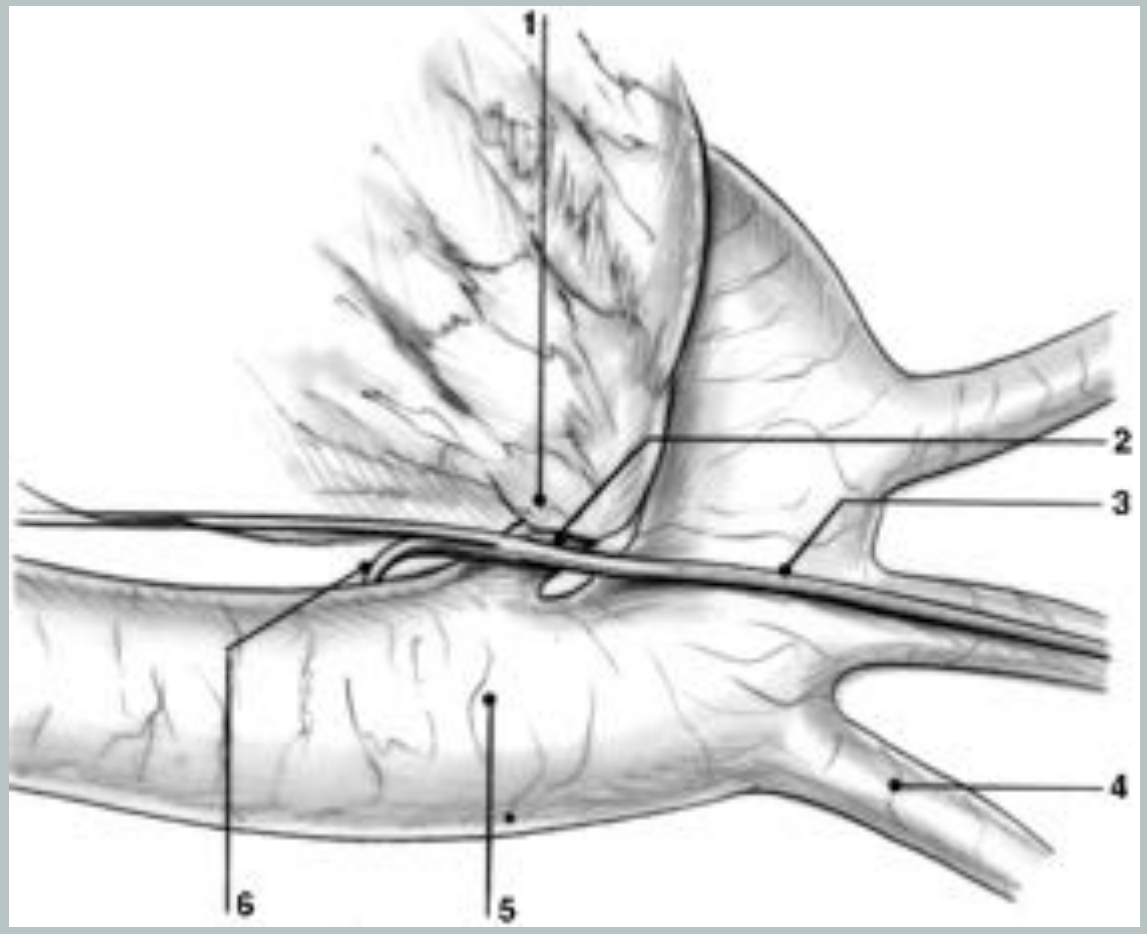

Technique chirurgicale

Particularité du nouveau-né

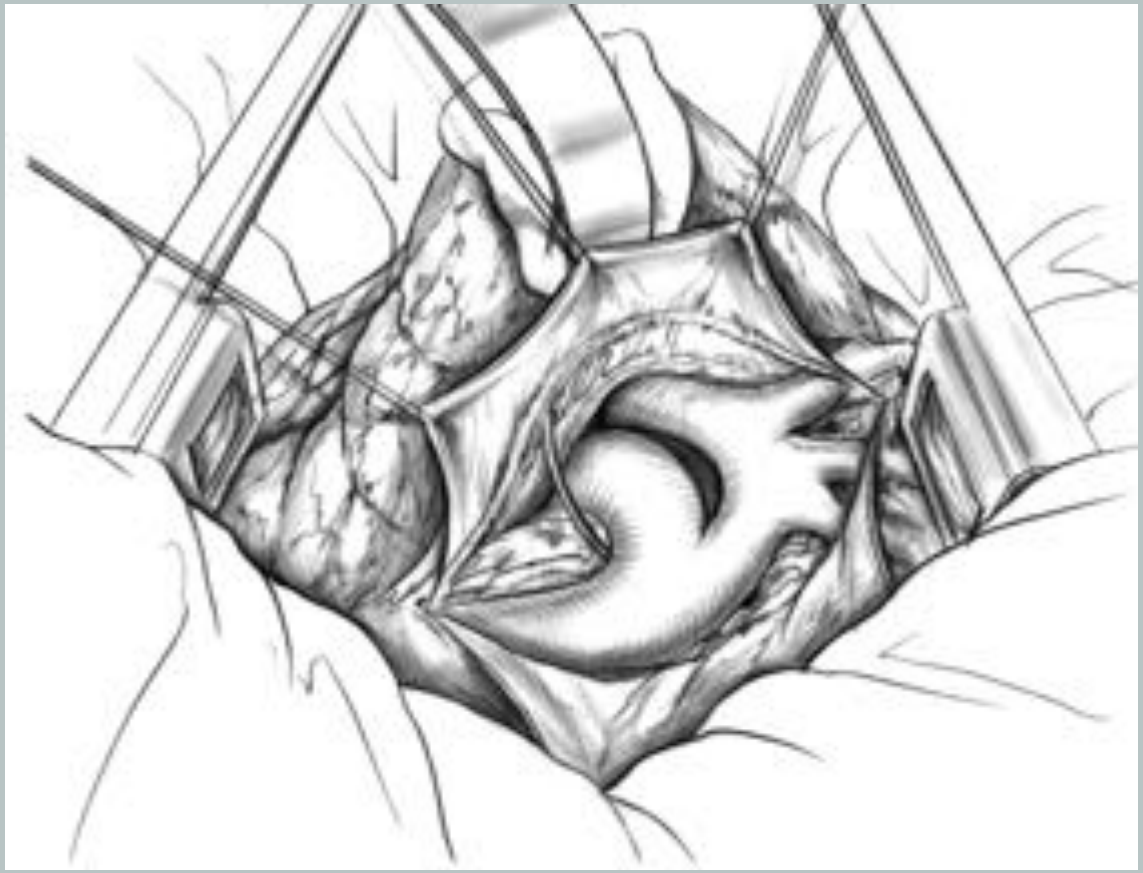

Technique chirurgicale NNé

Canal artériel

Thoracotomie postéro-latérale , 4°EICG

ligature simple

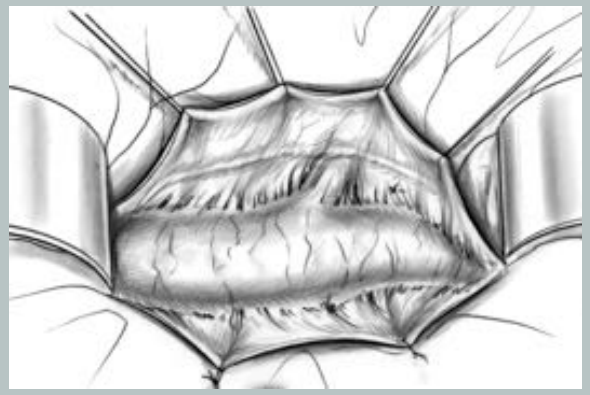

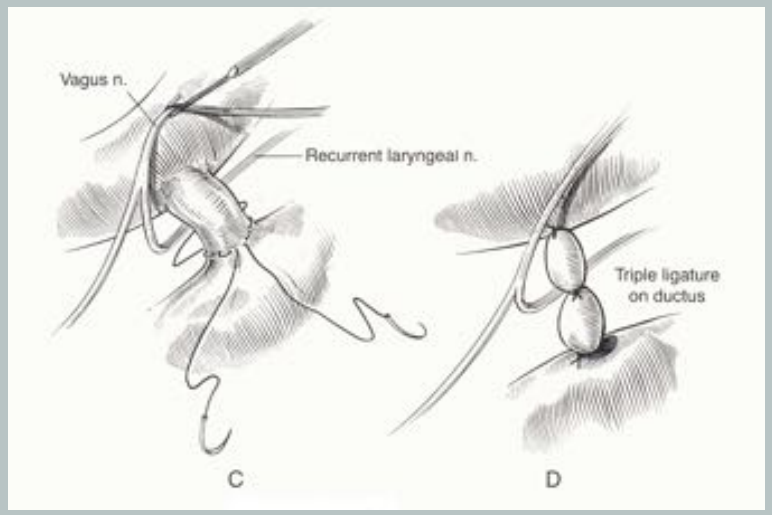

Technique chirurgicale après période néo natale

Thoracotomie postéro-latérale , 4°EICG

<u>section suture :</u> CA court et large !

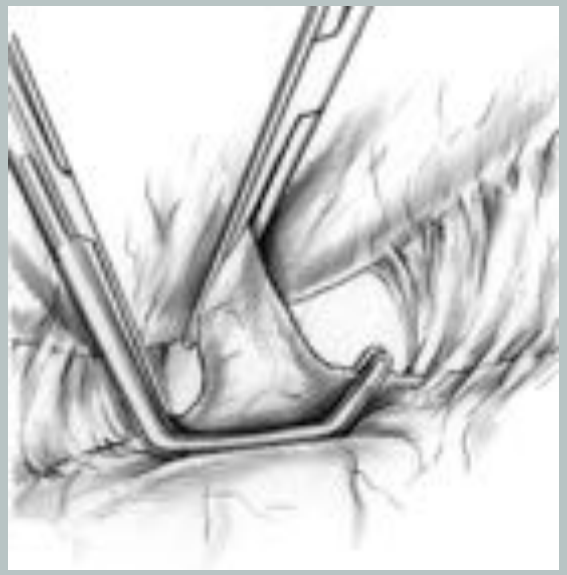

Technique chirurgicale (CA associé)

Sternotomie

section suture

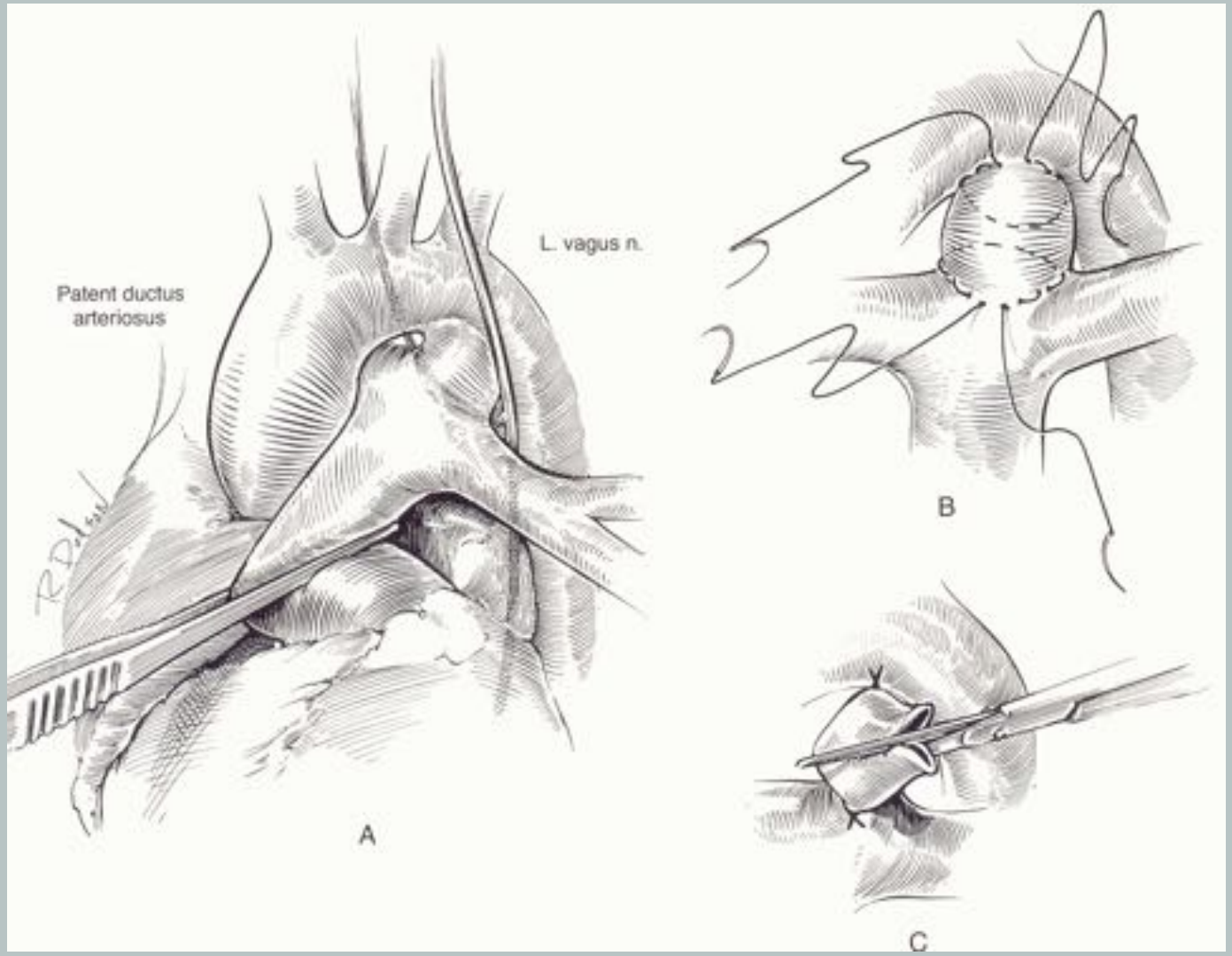

Technique chirurgicale

Vidéo-thoracoscopie

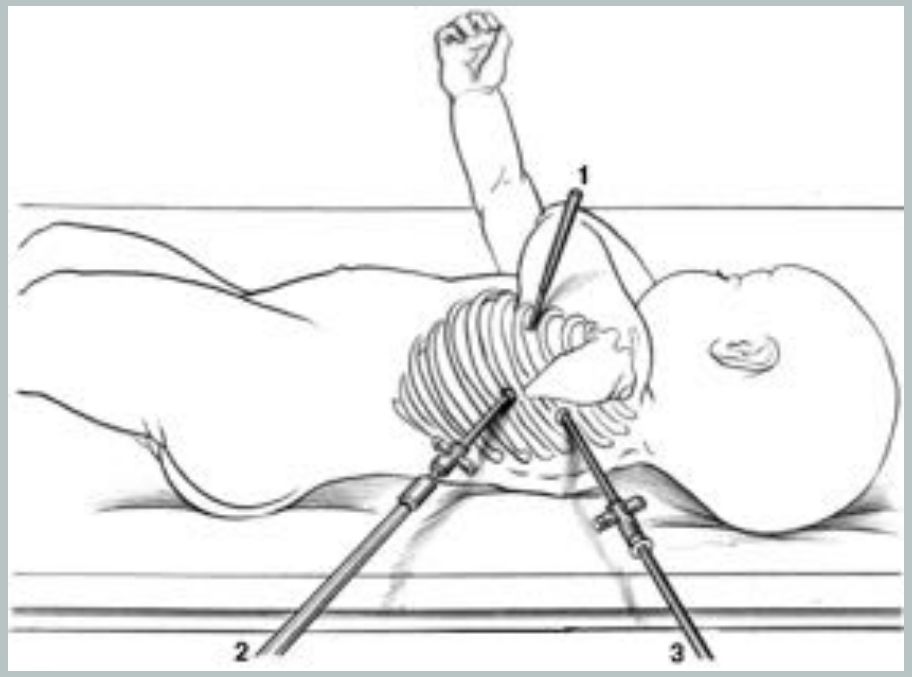

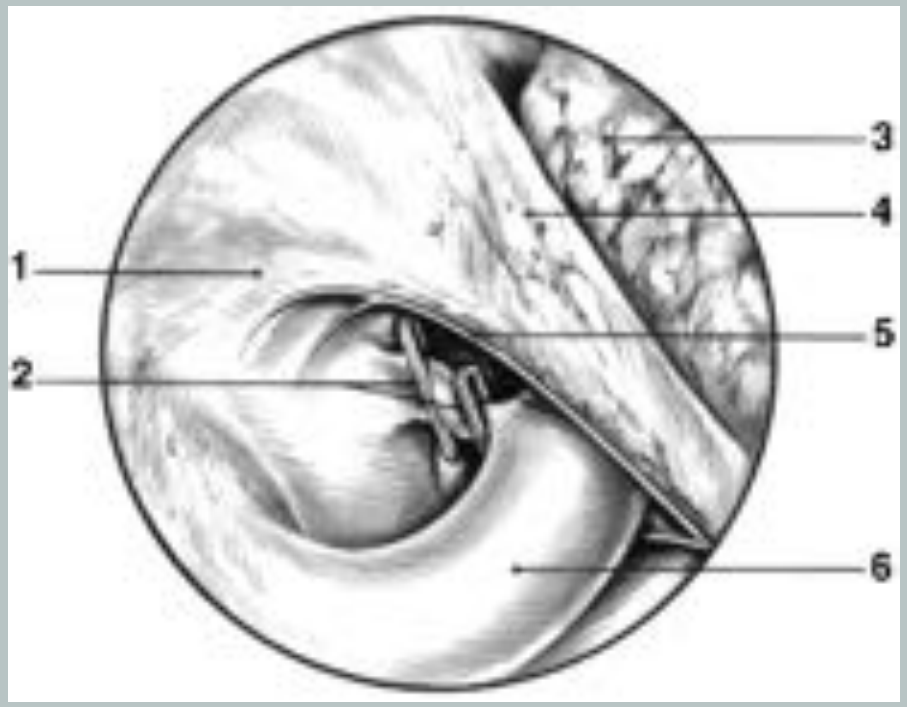

Cas particuliers

- Prématuré : +++ chirurgie
  - -Insuffisance cardiaque
- Enfant : +++ KT (> 5 kg)
  - - Endocardite
  - - Anévrisme
- Adulte
  - -HTAP fixée ?

cathétérisme interventionnel

fermeture sous CEC ±calcifié!

Canal artériel

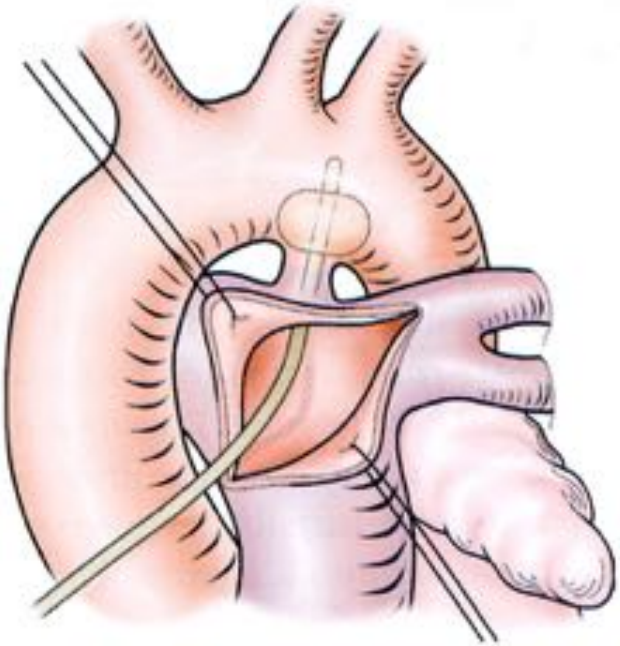

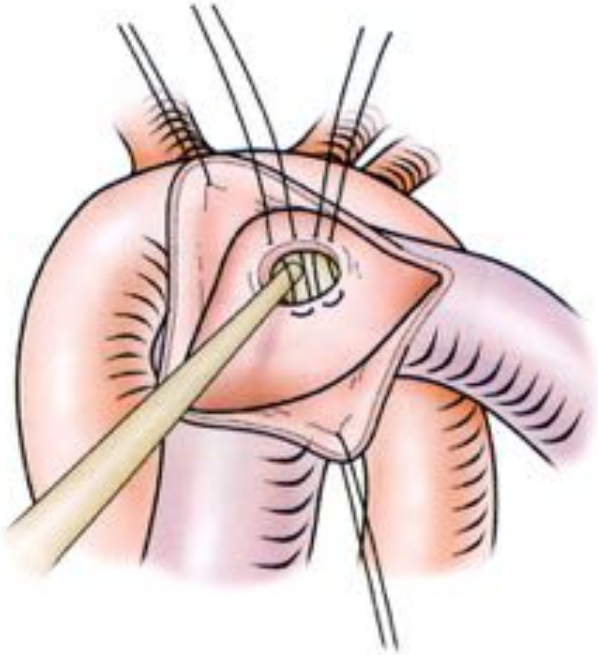

Malfaçons chirurgicales

- hémorragie +++
- ligature de l'aorte ou de l'APG
- coarctation aortique
- sténose APD
- shunt résiduel
- lésion récurrent gauche
- pneumothorax
- lésion collecteur lymphatique

FENETRE AORTO-PULMONAIRE

Anatomie chirurgicale

Traitement chirurgical

Problèmes chirurgicaux

FENETRE AORTO-PULMONAIRE

- Rare : < 0,2 % des CC
- Isolée
- Associée :
  - CA
  - IAAO
  - TOF
  - VSD
- Parfois restrictive

Fenêtre AP

Anatomie chirurgicale

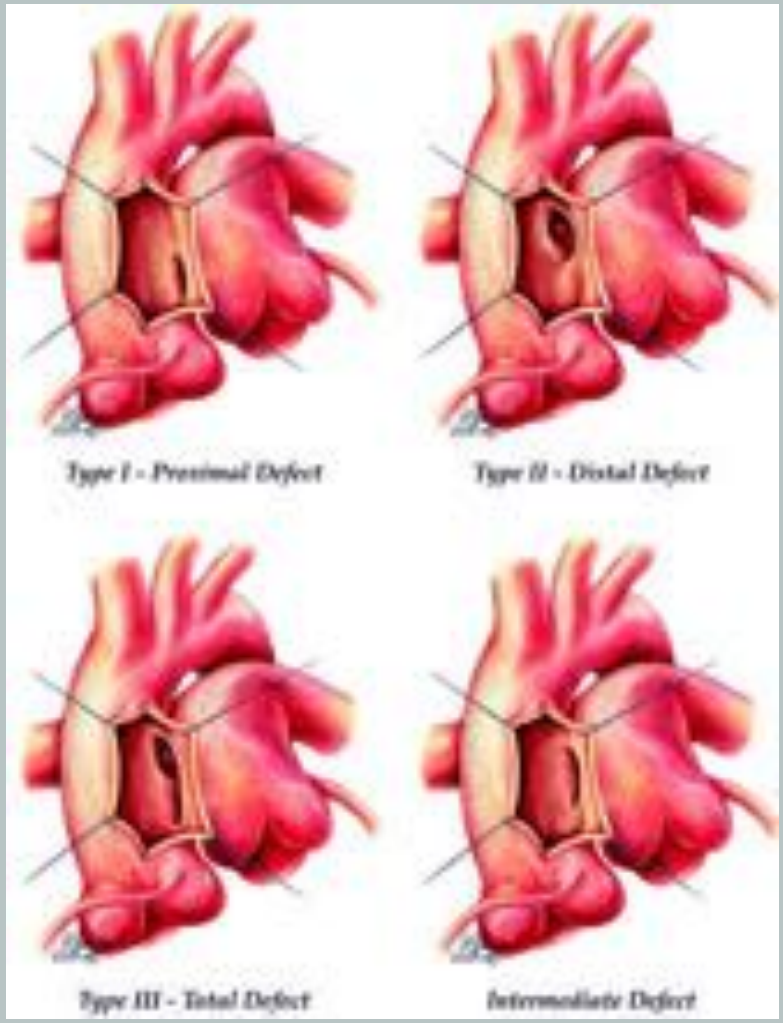

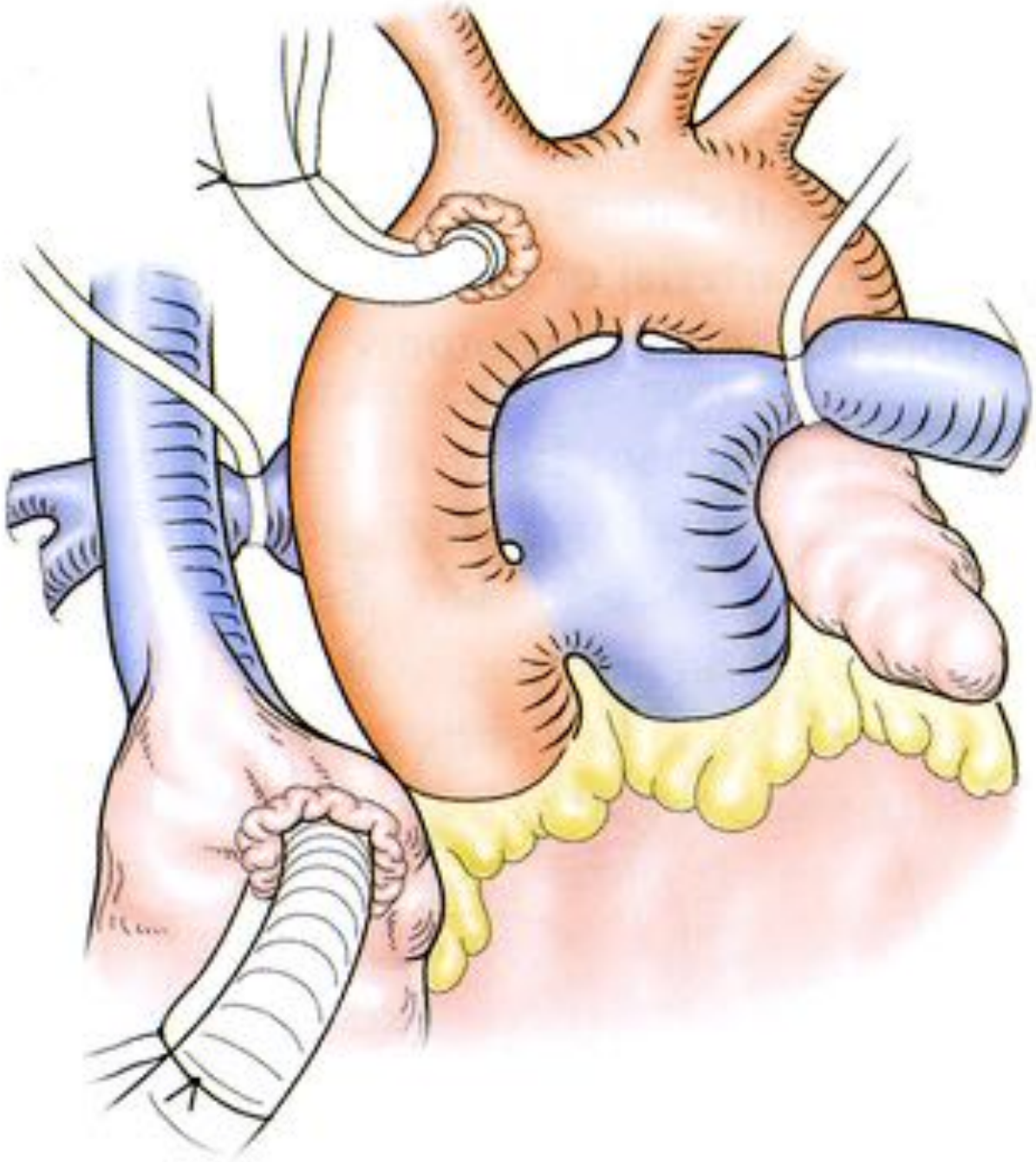

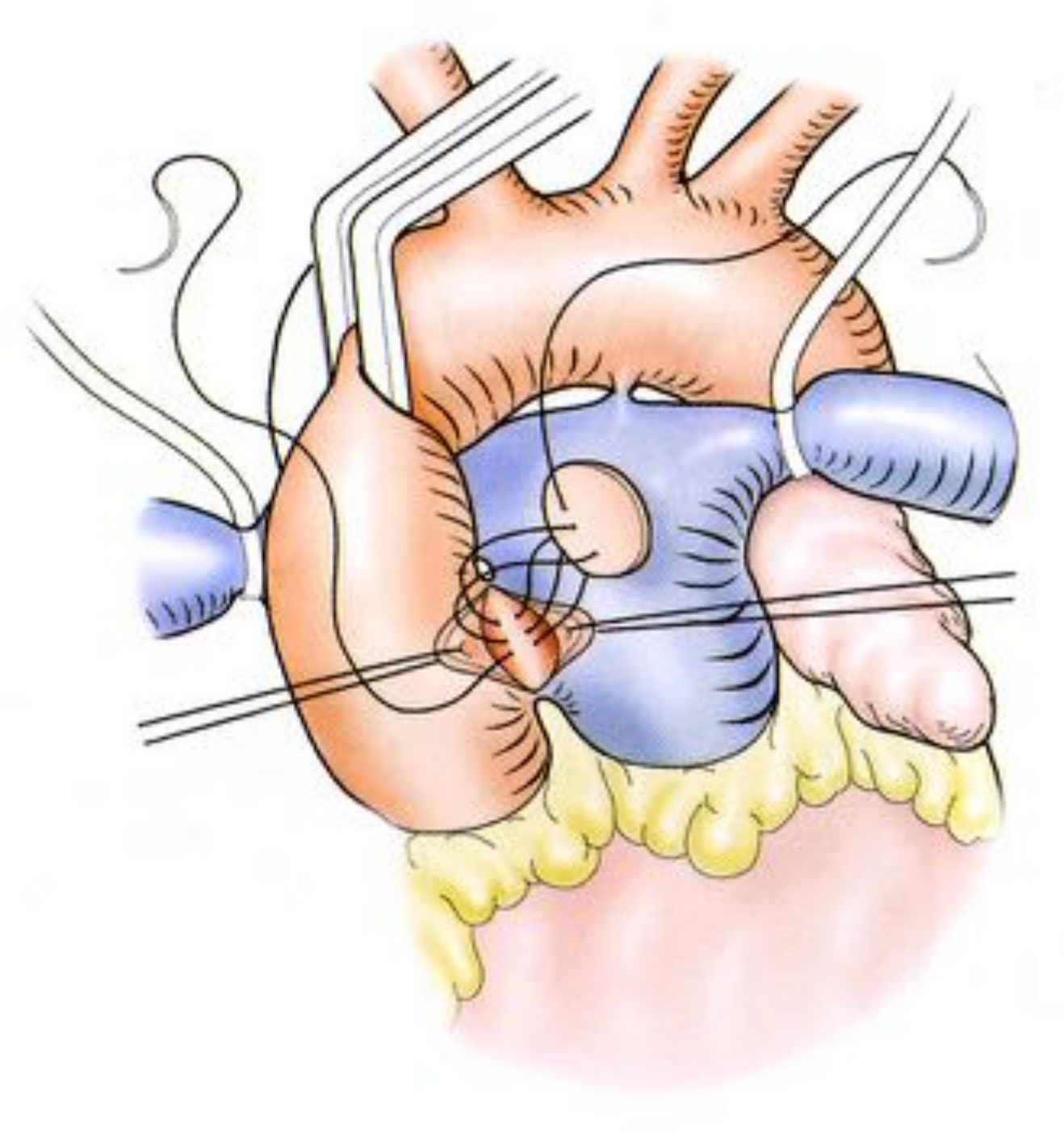

Technique chirurgicale

Ouverture de l'aorte

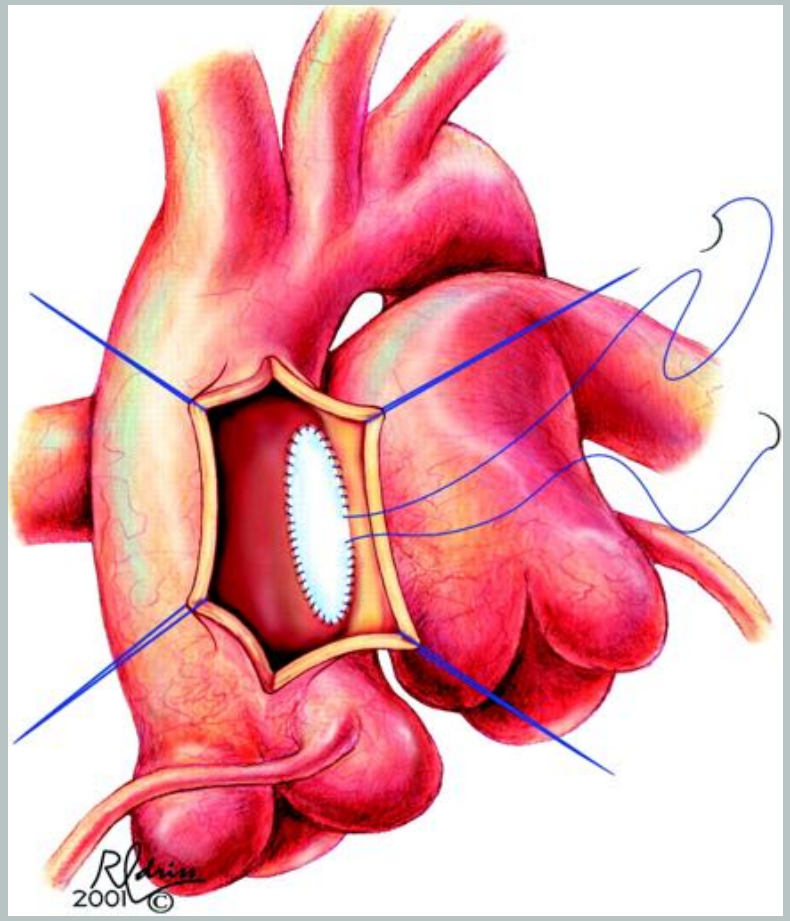

Problèmes per-opératoires

- contrôle des AP dès le départ en CEC

- protection myocardique (orifices coronaires)

- anomalies coronaires associées
    . *coronaire naissant proche de la fenêtre*
    . *coronaire naissant de l'AP*
    . *intérêt de la voie trans-aortique*

Problèmes post-opératoires

- shunt résiduel
- sténose APD
- sténose aorte ascendante
- sténose artère coronaire

FAP et IAA

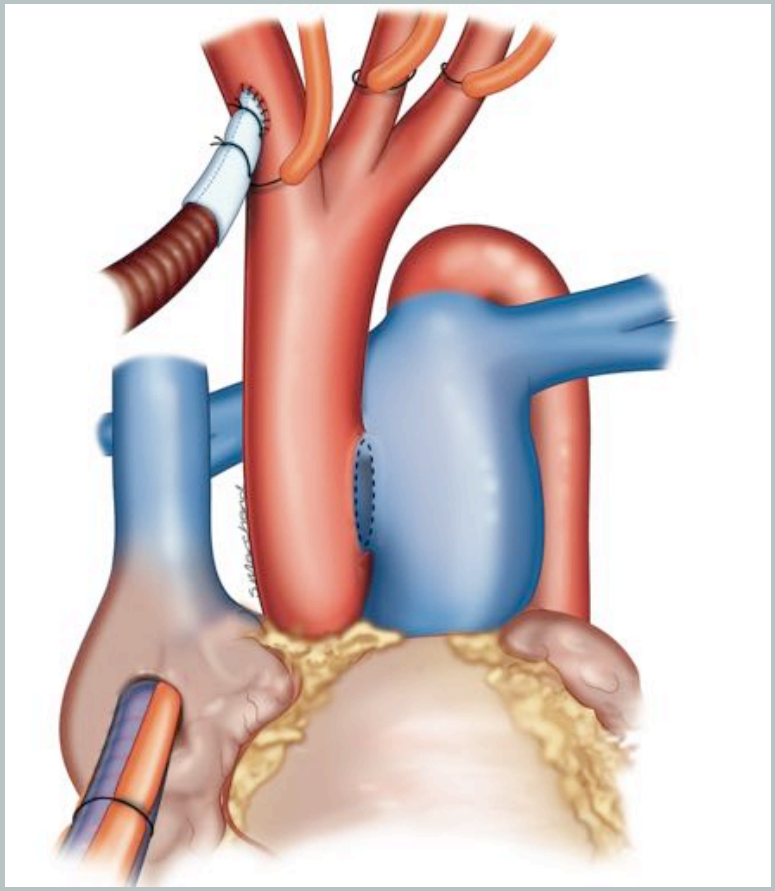

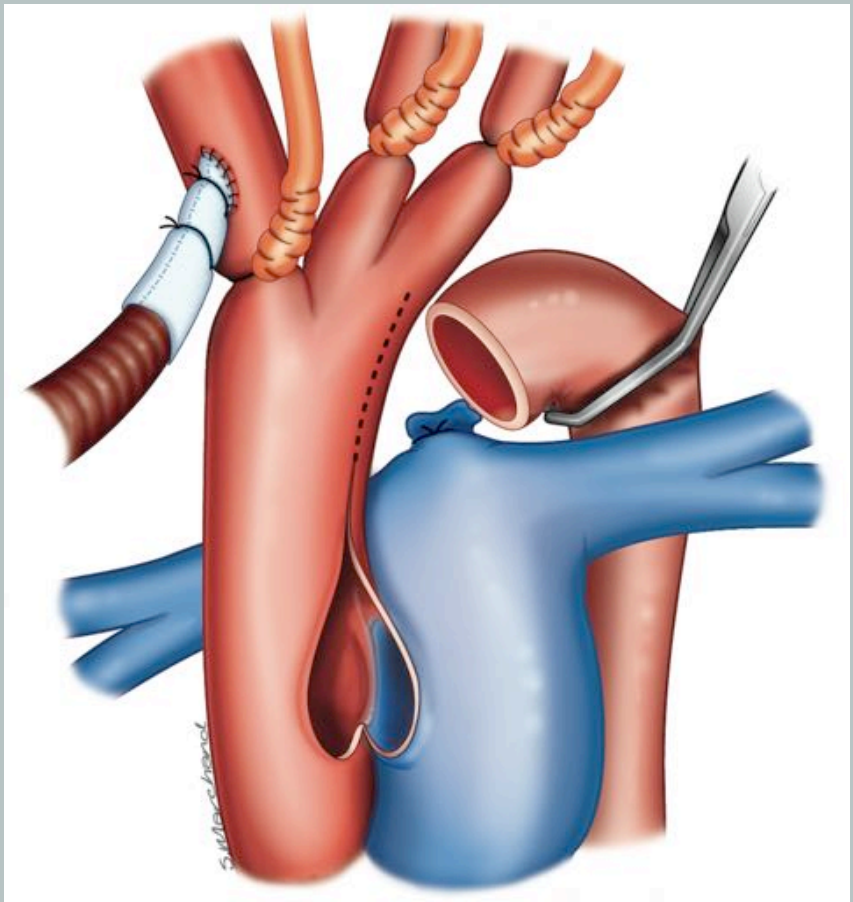
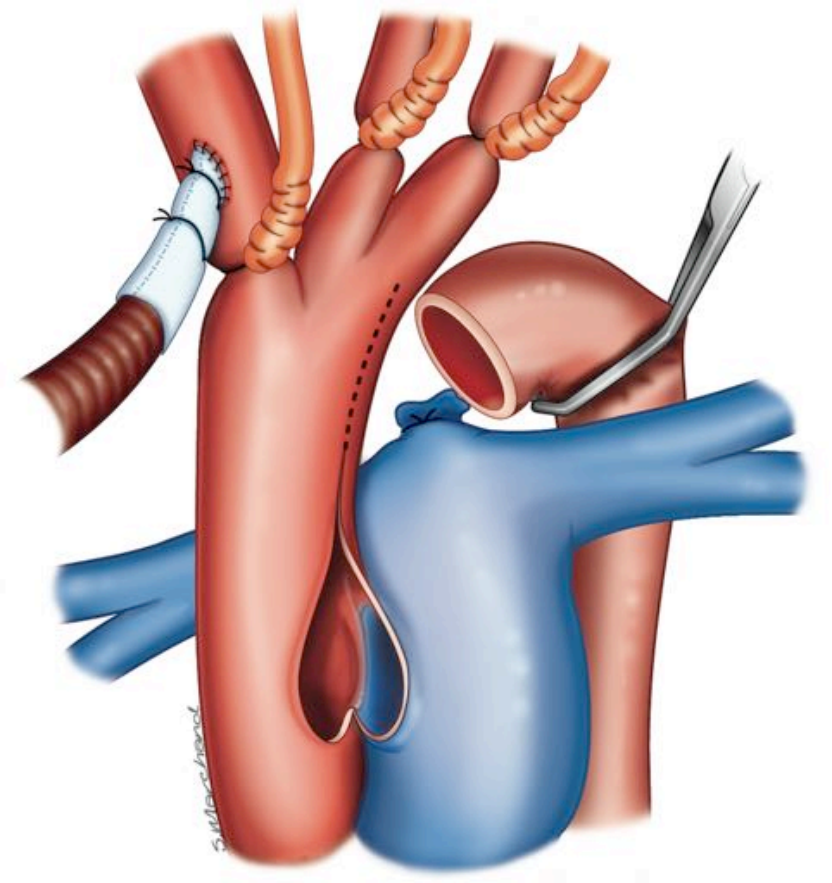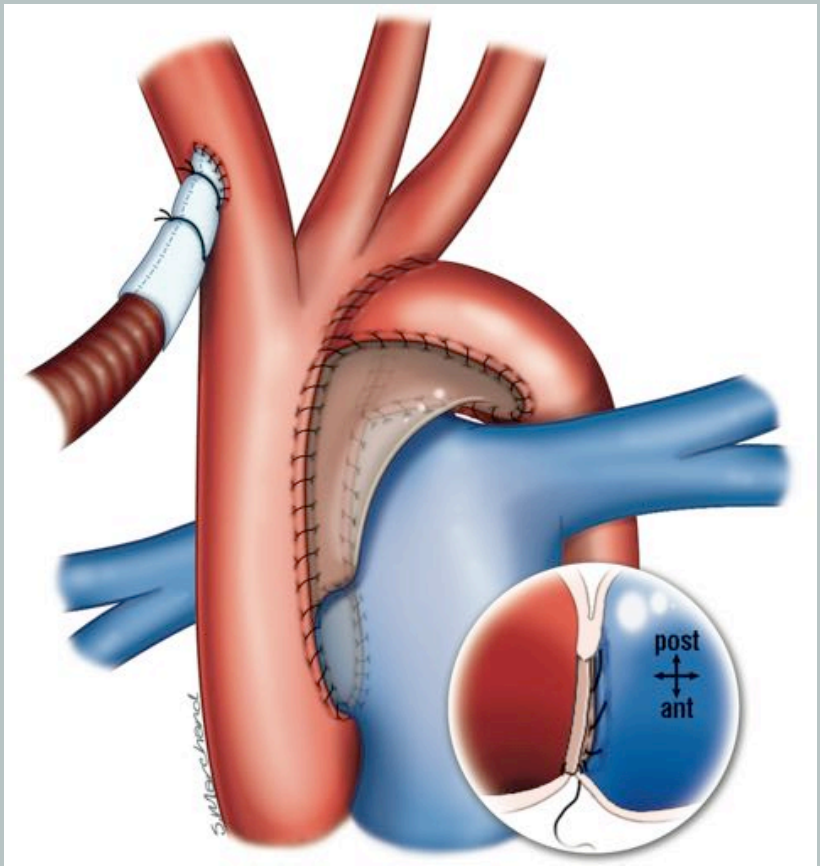
FAP et IAA