Communication

Inter

Ventriculaire

CIV

Anatomie
Traitement chirurgical
Formes associées (fuite aortique)
Les problèmes techniques

ANATOMIE DU SEPTUM INTERVENTRICULAIRE

- Septum conal
  = infundibulaire
  = outlet septum
- Septum d ’admission = inlet septum
- Septum trabéculé
- Septum membraneux

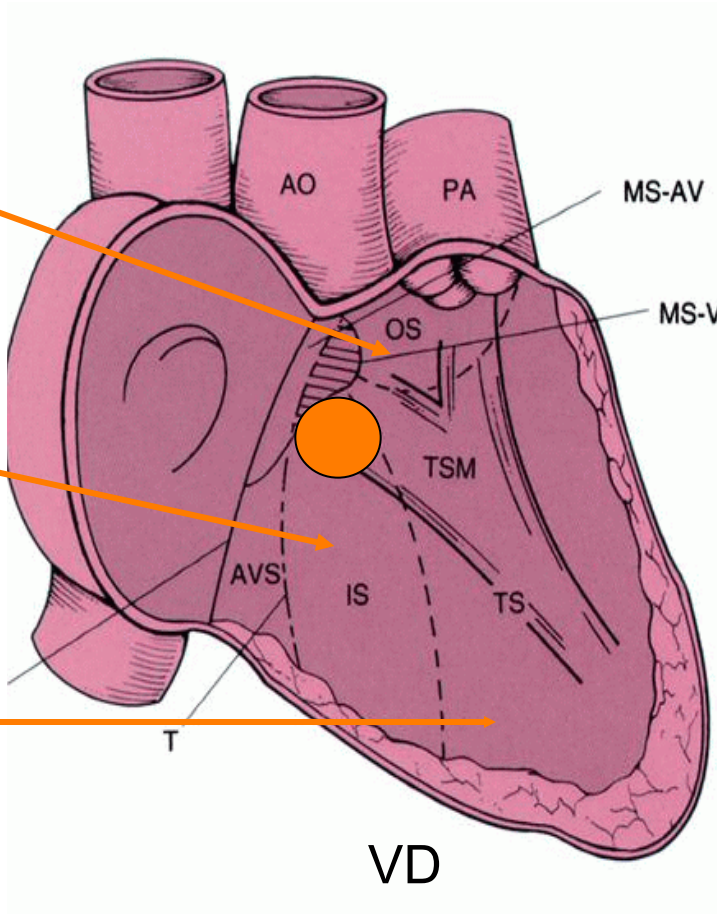

Anatomie chirurgicale

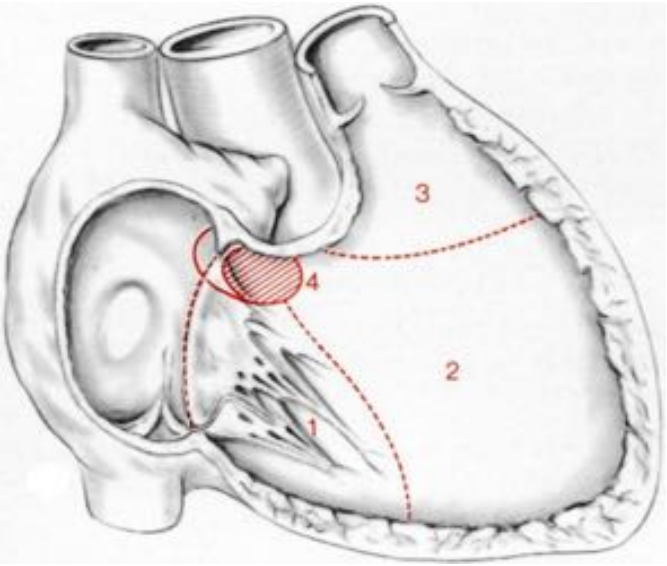

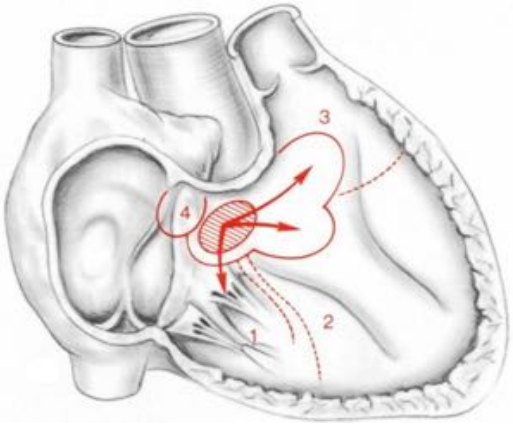

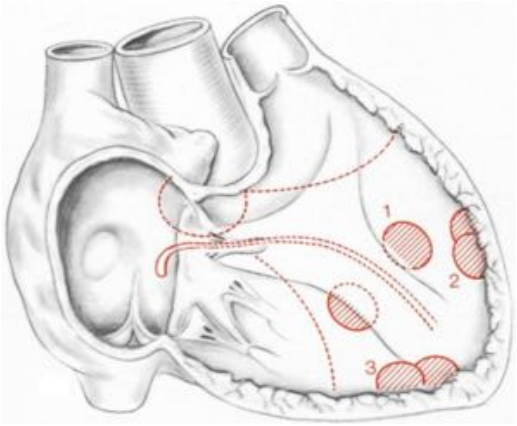

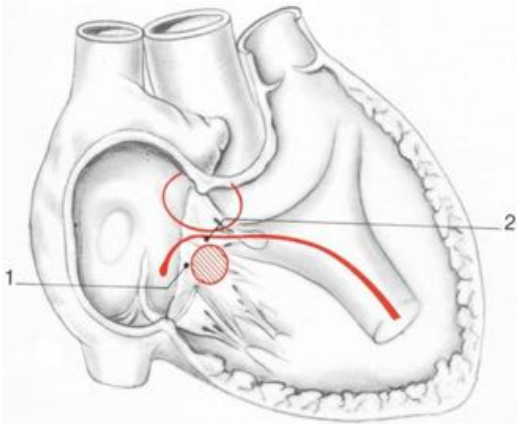

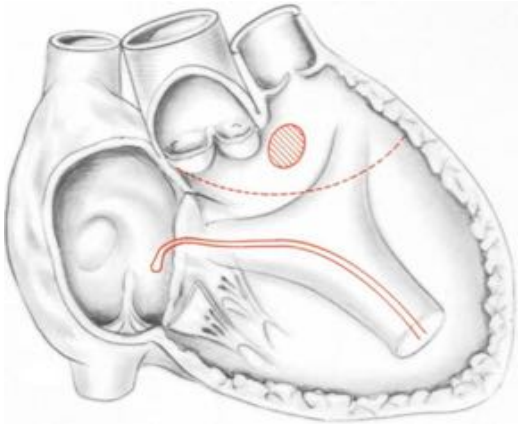

CIV multiples

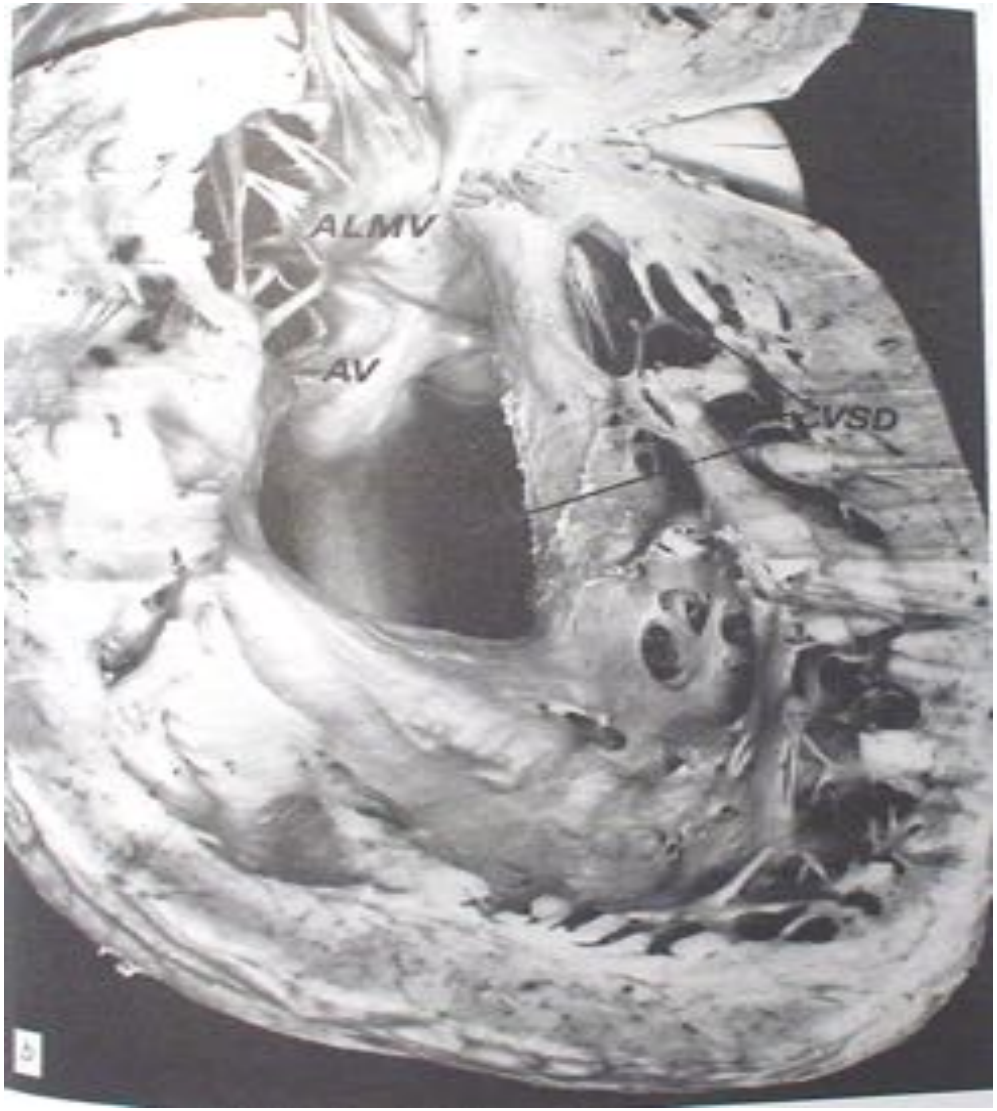

INDICATIONS

- CIV large ,deux situations:

1. CIV avec HTAP (non restrictive) :Chirurgie
2. CIV sans HTAP (restrictive) avec hyperdébit:Patienter si bonne prise staturo-pondérale

- CIV petite:pas de chirurgie sauf:

1. Insuffisance aortique qui se developpe
2. Endocardite infectieuse
3. Dilatation du VG ?

INDICATIONS

- fermeture sous CEC
- cerclage pulmonaire
  - CIV multiples
  - contre-indication CEC (CIV unique)

Fermeture chirurgicale des CIV périmembraneuses par voie transatriale

- Contrôle premier du canal artériel dès le départ en CEC

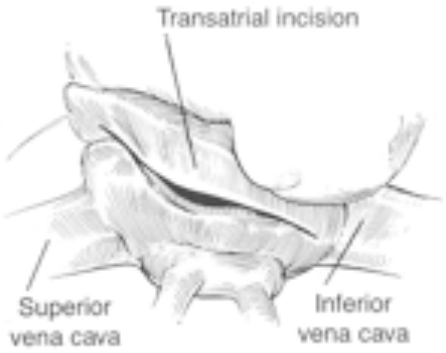

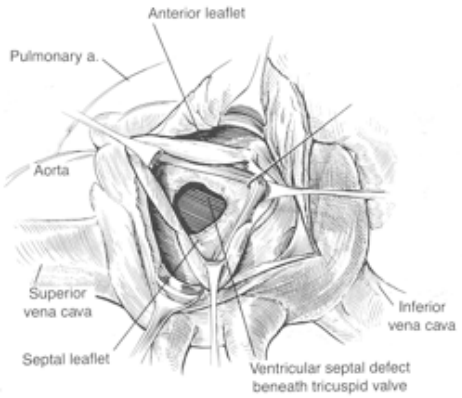

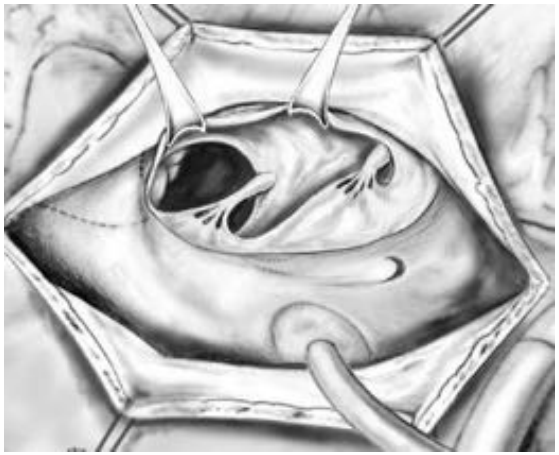

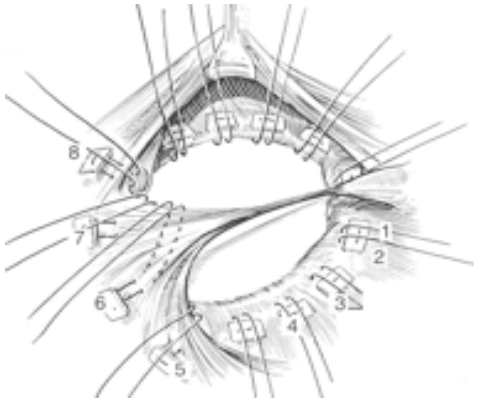

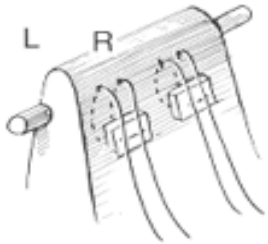

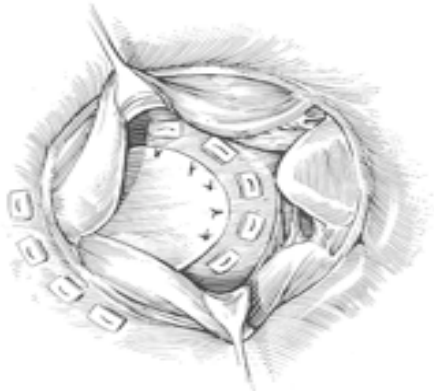

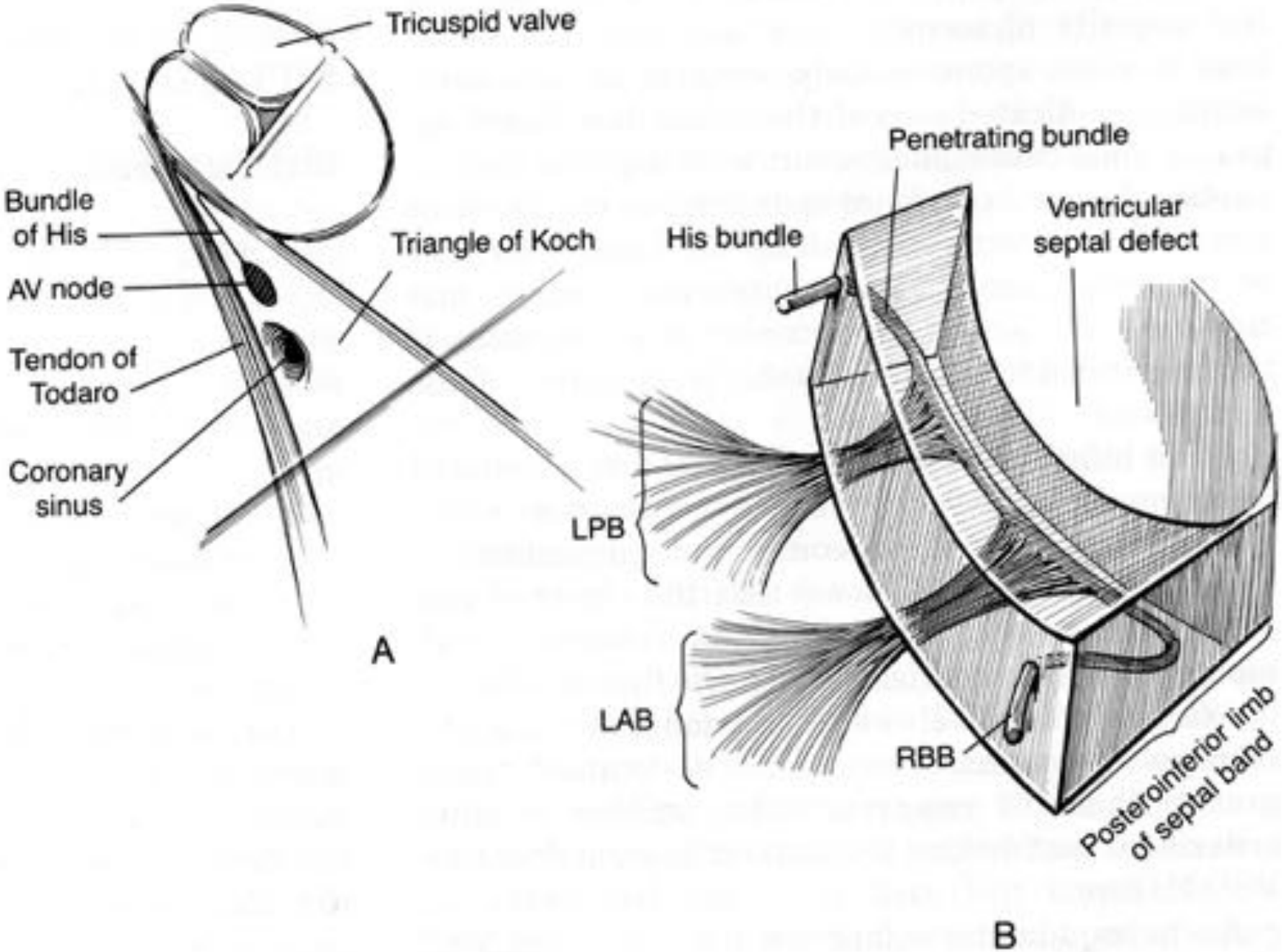
Tricuspid valve
Bundle of His
AV node
Tendon of Todaro
Coronary sinus
Triangle of Koch
A
Penetrating bundle
His bundle
Ventricular septal defect
LPB
LAB
RBB
Posteroinferior limb of septal band
B

Fermeture chirurgicale des CIV d'admission par voie transatriale

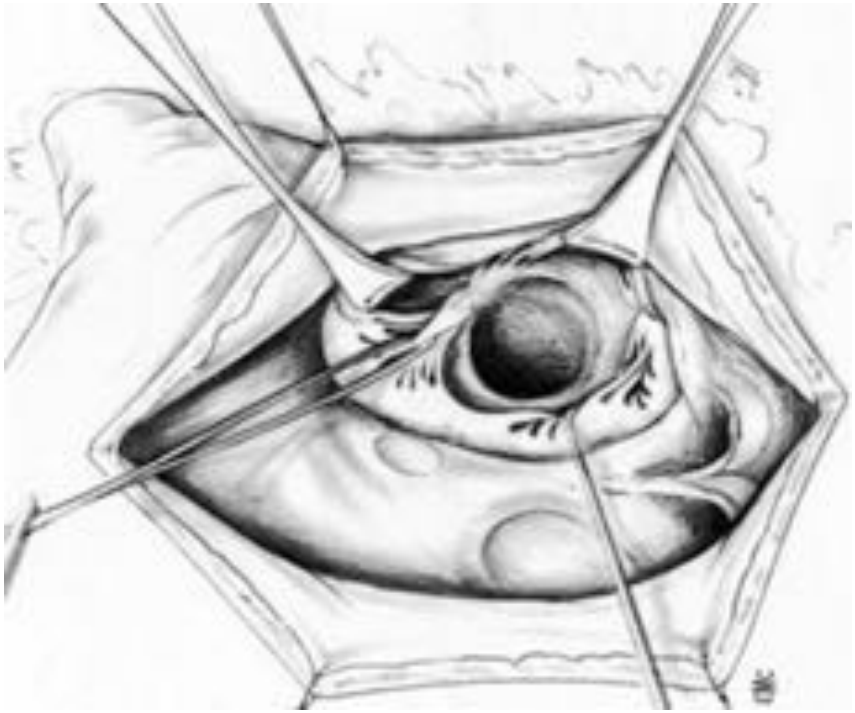

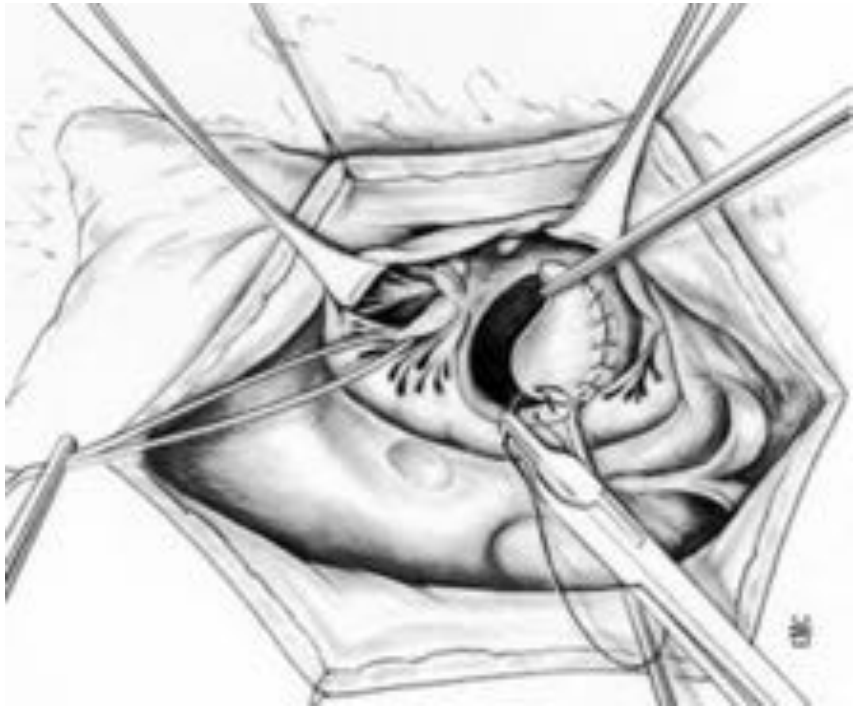

Fermeture chirurgicale des CIV infundibulaires

Voie Transpulmonaire

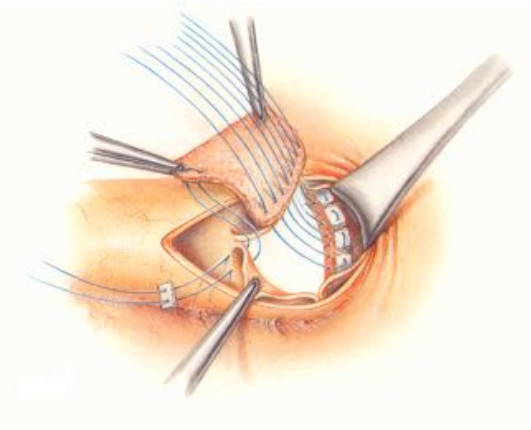

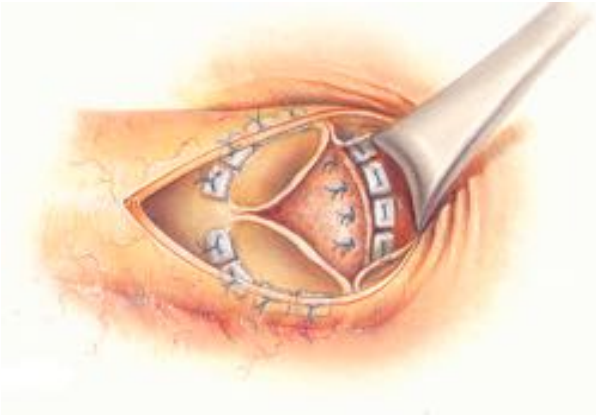

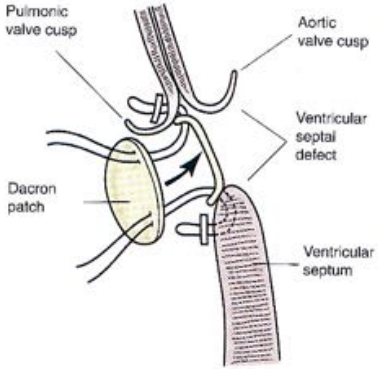

Voie Transinfundibulaire

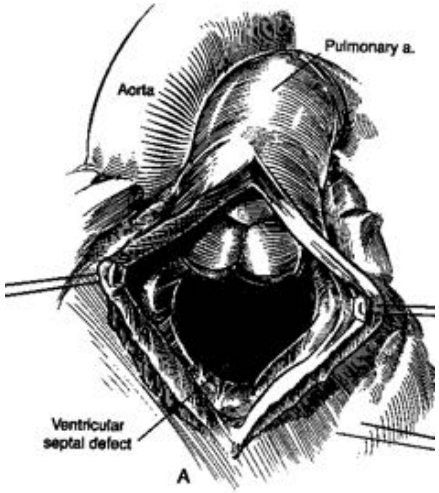

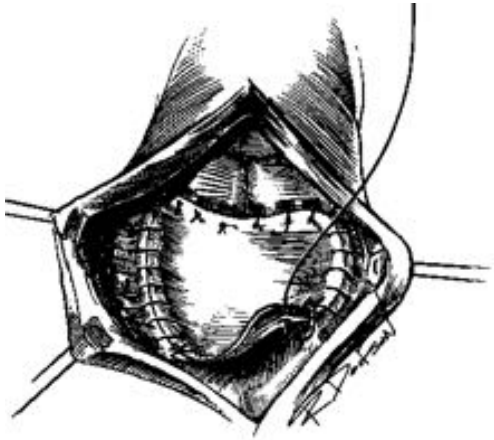

Fermeture chirurgicale des CIV trabéculée

Voie transatriale pour CIV trabéculées haute ou moyenne

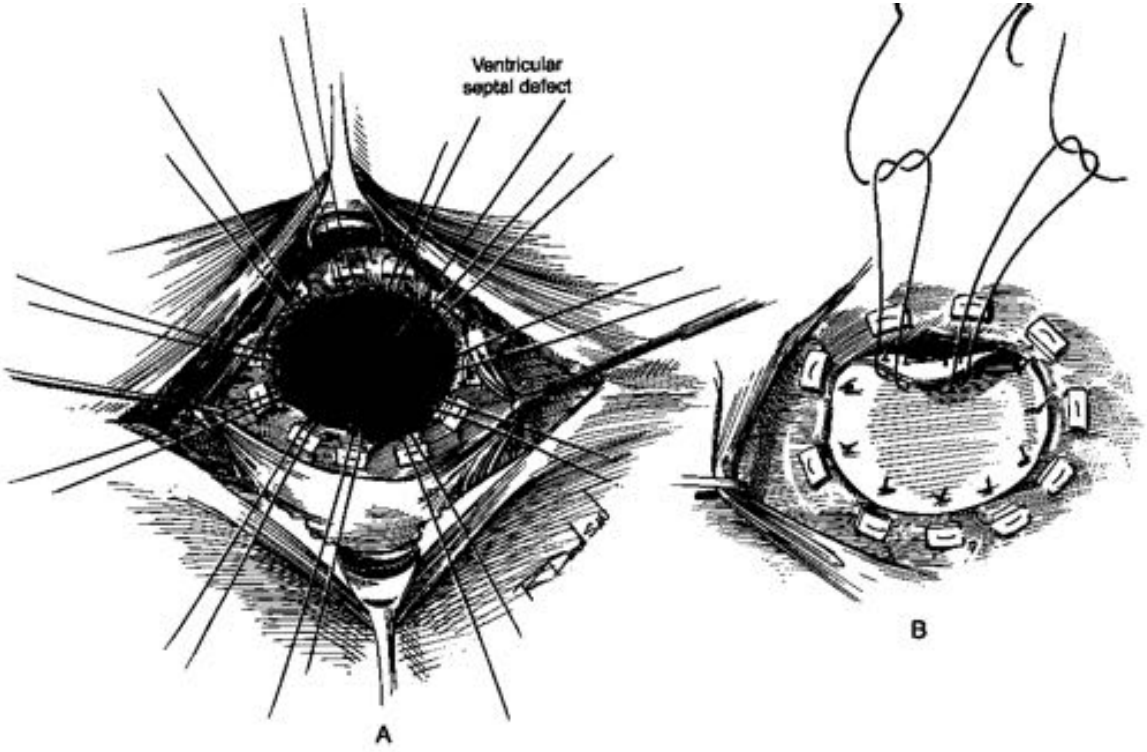

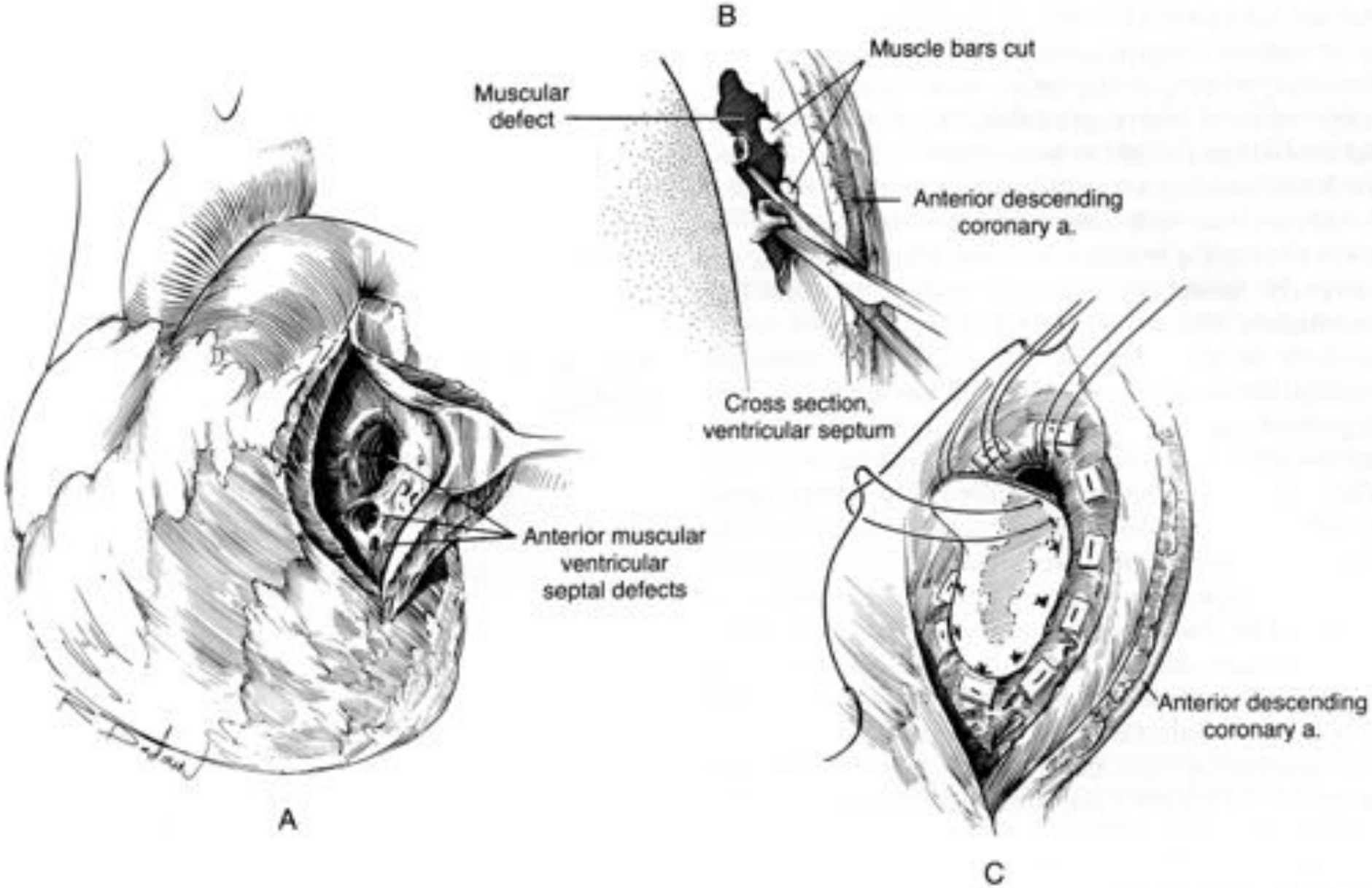
B
Muscle bars cut
Muscular defect
Anterior descending coronary a.
Cross section, ventricular septum
Anterior muscular ventricular septal defects
Anterior descending coronary a.
A
C

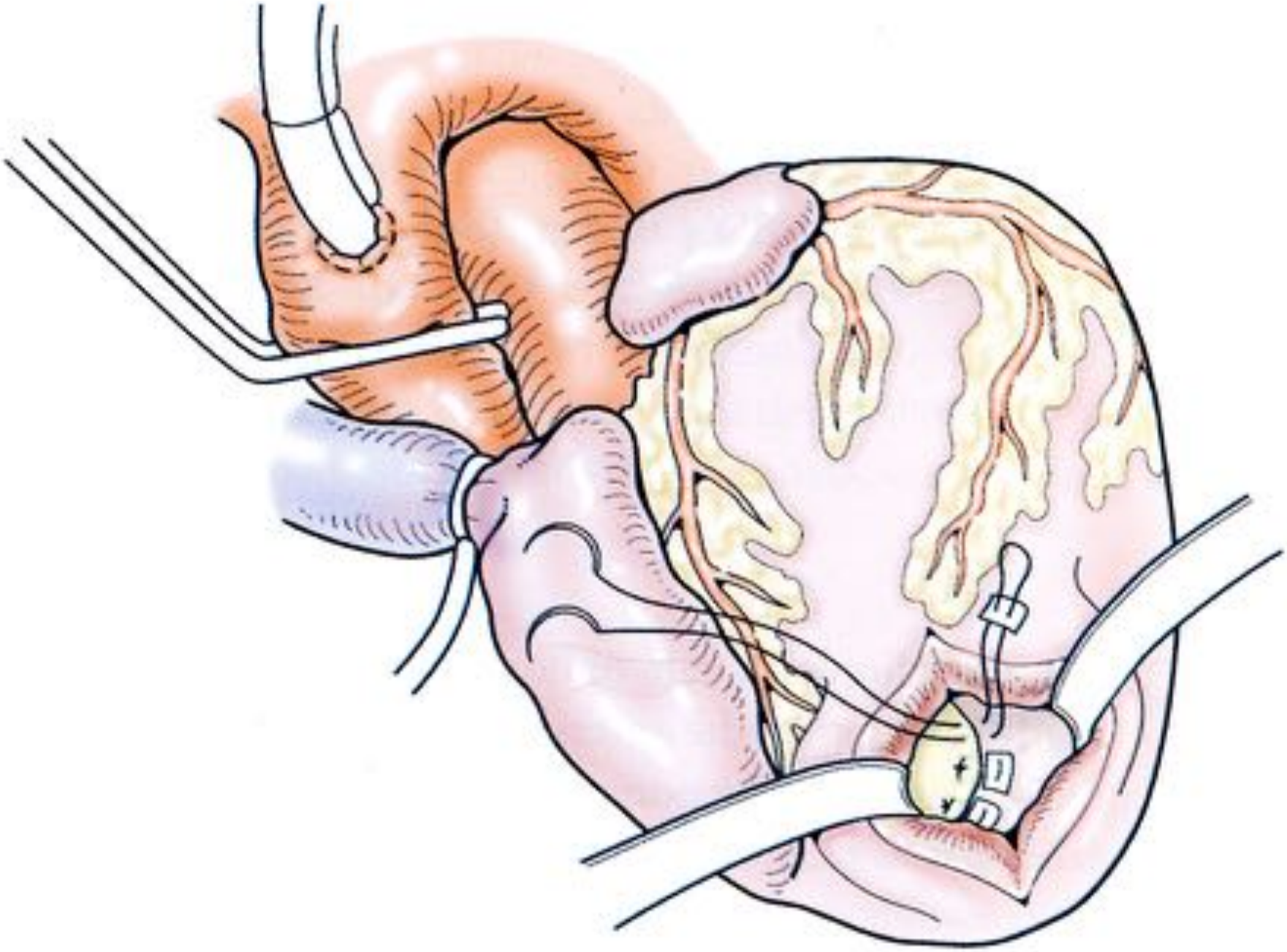

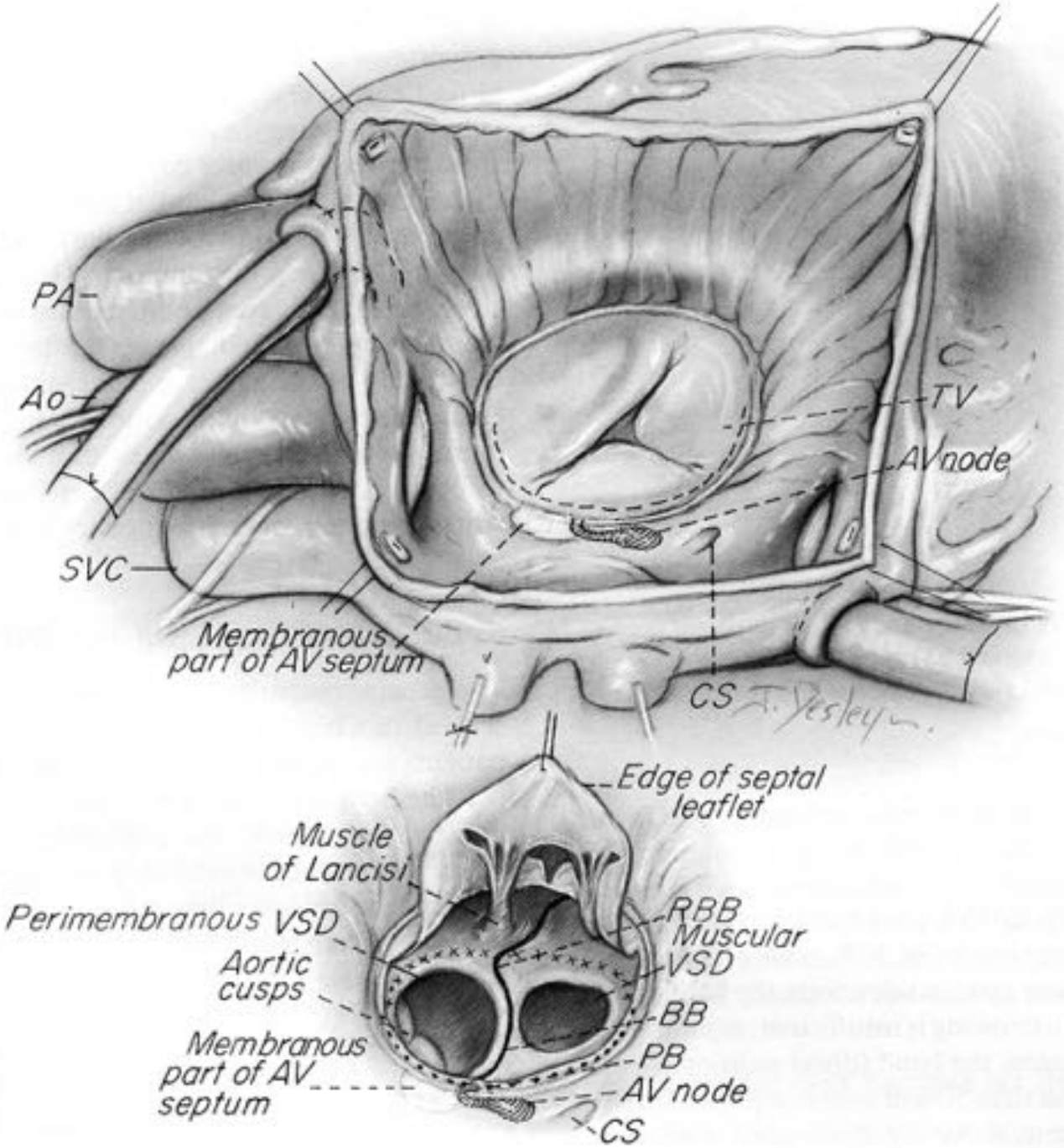
PA
Ao
SVC
TV
AV node
Membranous part of AV septum
CS
Edge of septal leaflet
Muscle of Lancisi
Perimembranous VSD
Aortic cusps
Membranous part of AV septum
RBB
Muscular VSD
BB
PB
AV node
CS

- pm et cono-troncale: OD (±VD)
- infundibulaire : AP (± VD)
- inlet : OD
- trabéculées (souvent multiples)
  - moyennes : OD
  - antérieures : VD
  - apicales : VD (VG)

Management per-opératoire

- CIA résiduelle restrictive
  - G/D : défaillance VG
  - D/G : HTAP

- détection CIV résiduelle (CIV multiples)
  - saturations étagées
  - échocardiographie per-opératoire

CIV + IAo

- IAo minime
  - indication formelle fermeture CIV
  - pas de geste sur valve aortique

- IAo significative
  - plastie valvulaire aortique
  - résultats aléatoires

Lésion associées

- Fuite aortique (PM ou OUTLET)

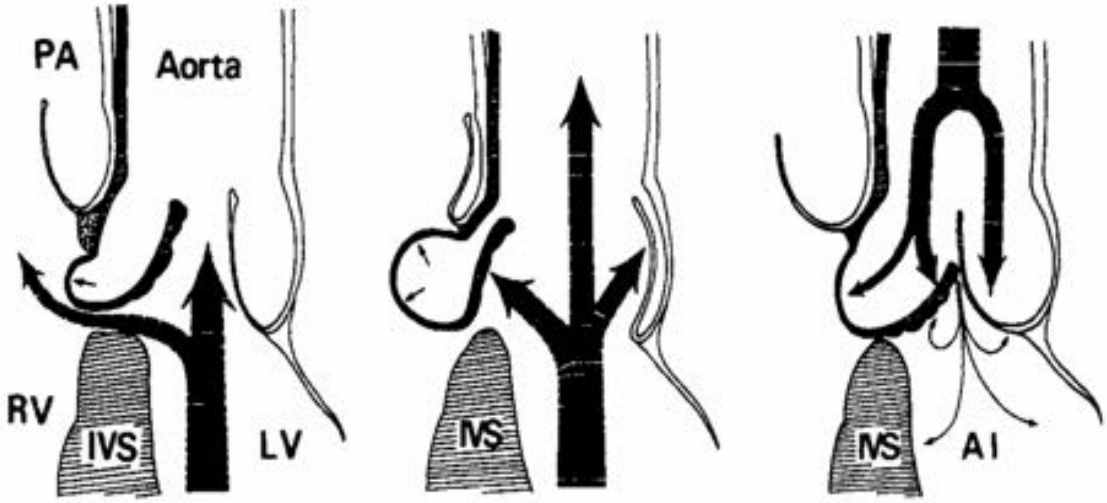

Complications spécifiques après fermeture chirurgicale des CIV

Risques communs :
- HTAP (Résistances Pulmonaires élevées +/- CIVr)
- Rythme jonctionnel

Risques spécifiques

CIV PM
- *CIVr*
- *BAV*
- *Valves aortique et tricuspide*

CIV Inlet
- *CIVr*
- *BAV ++*

CIV Outlet
- *CIVr*
- *Valve aortique et pulmonaire*

CIV Trabéculée
- *CIVr ++ (souvent CIVm)*