

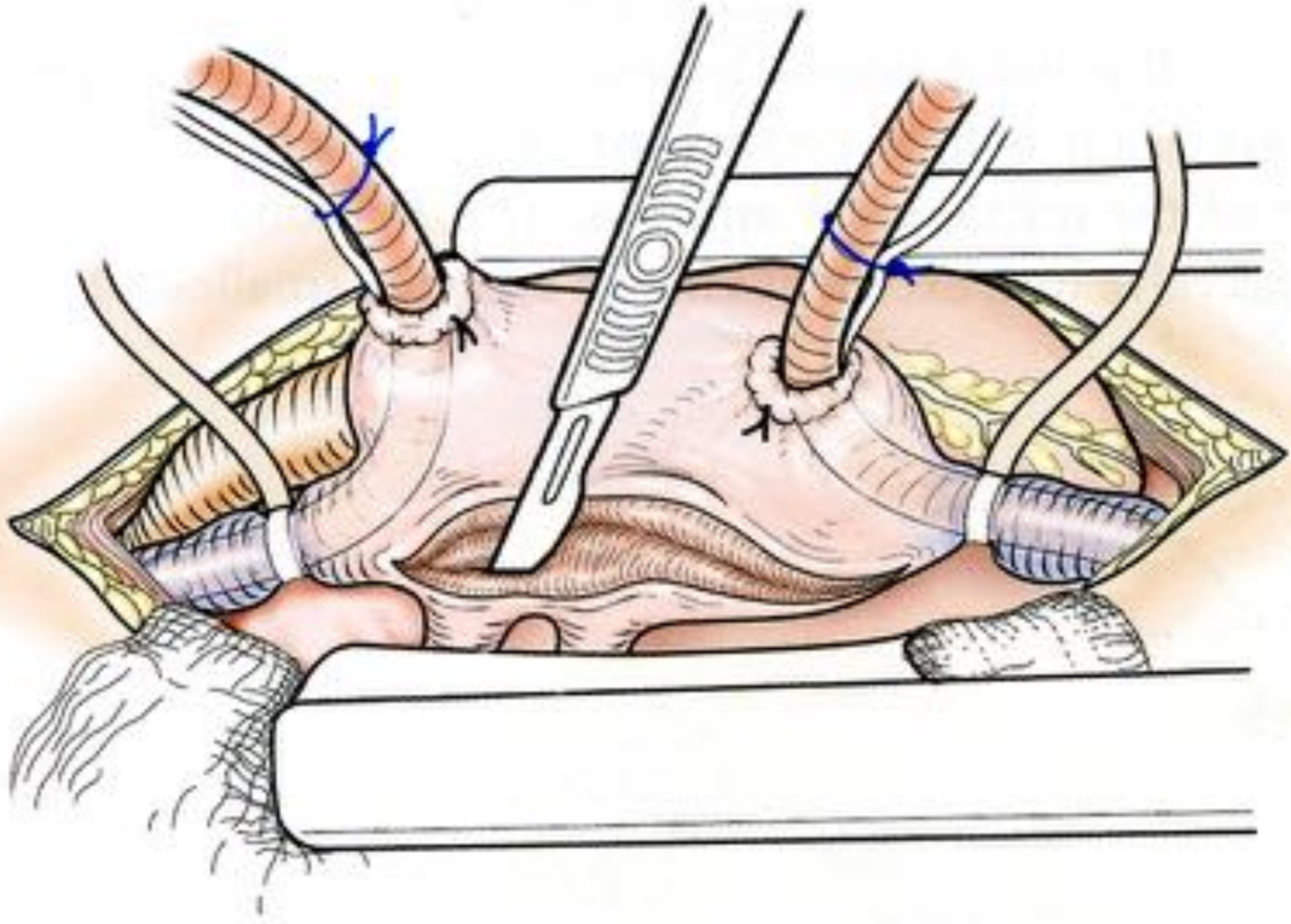
Valve mitrale:
enfants

- complexes, atteintes très variables
- étiologie: congénitale (rhumatismal)
- malformations cardiaques associées
- principes
 - évaluation fonctionnelle
 - réparation fonctionnelle
(et pas anatomique !)
 - pas d'anneau prothétique

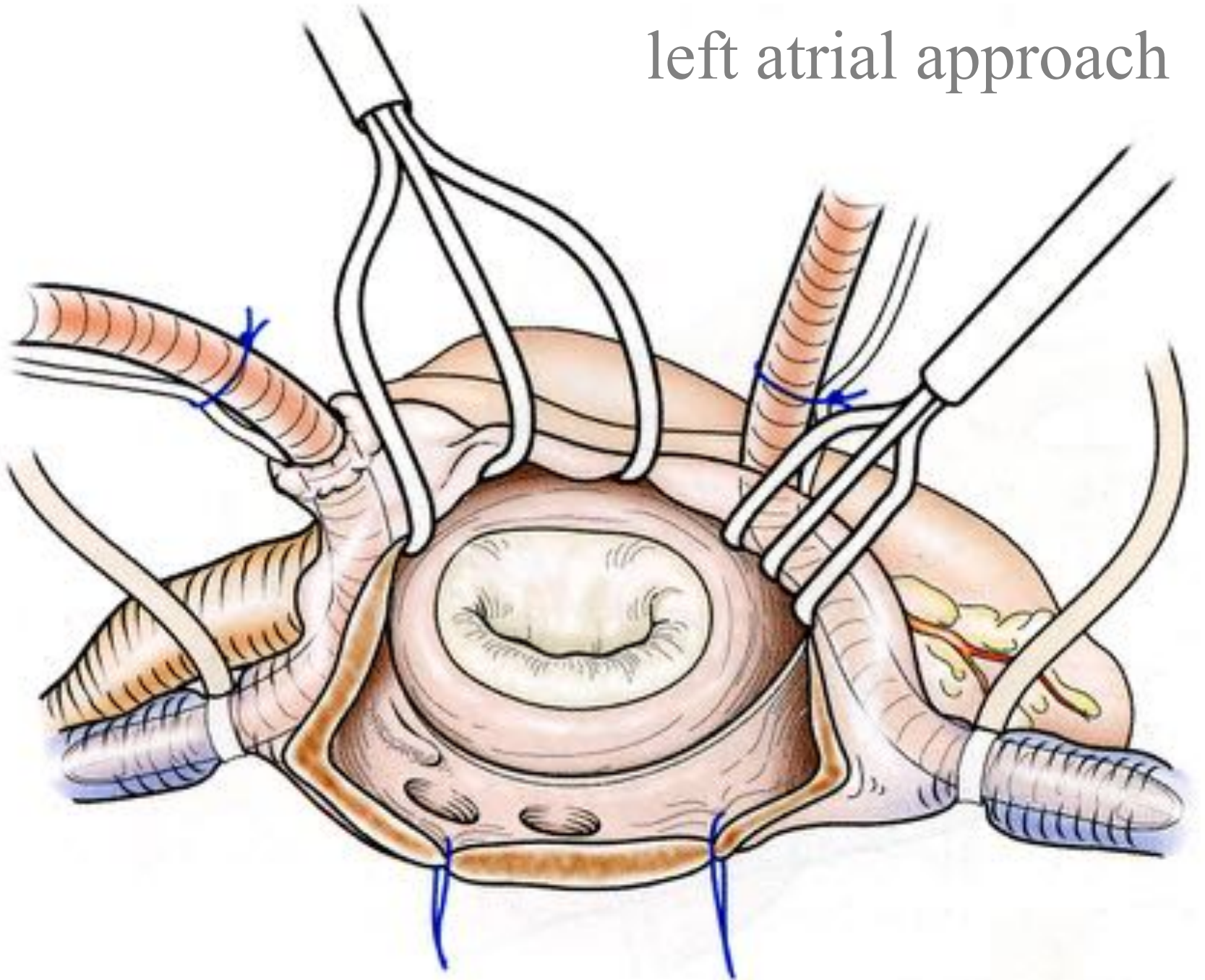
Evaluation fonctionnelle

- ETT pré-op
- ETO pré-op immédiat +++
- confrontation aux constatations chirurgicales
- ETO per-op et post-op

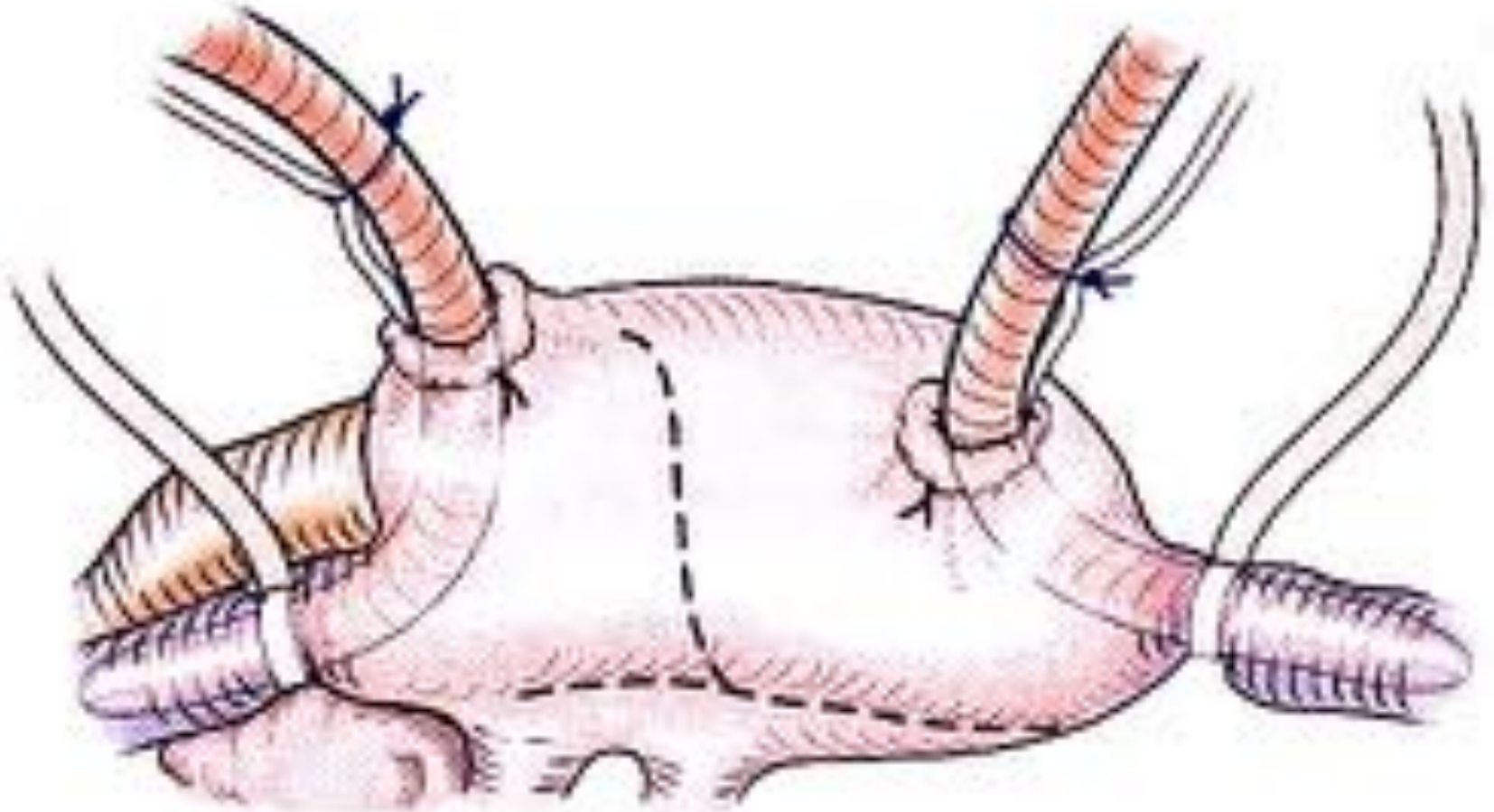
left atrial approach



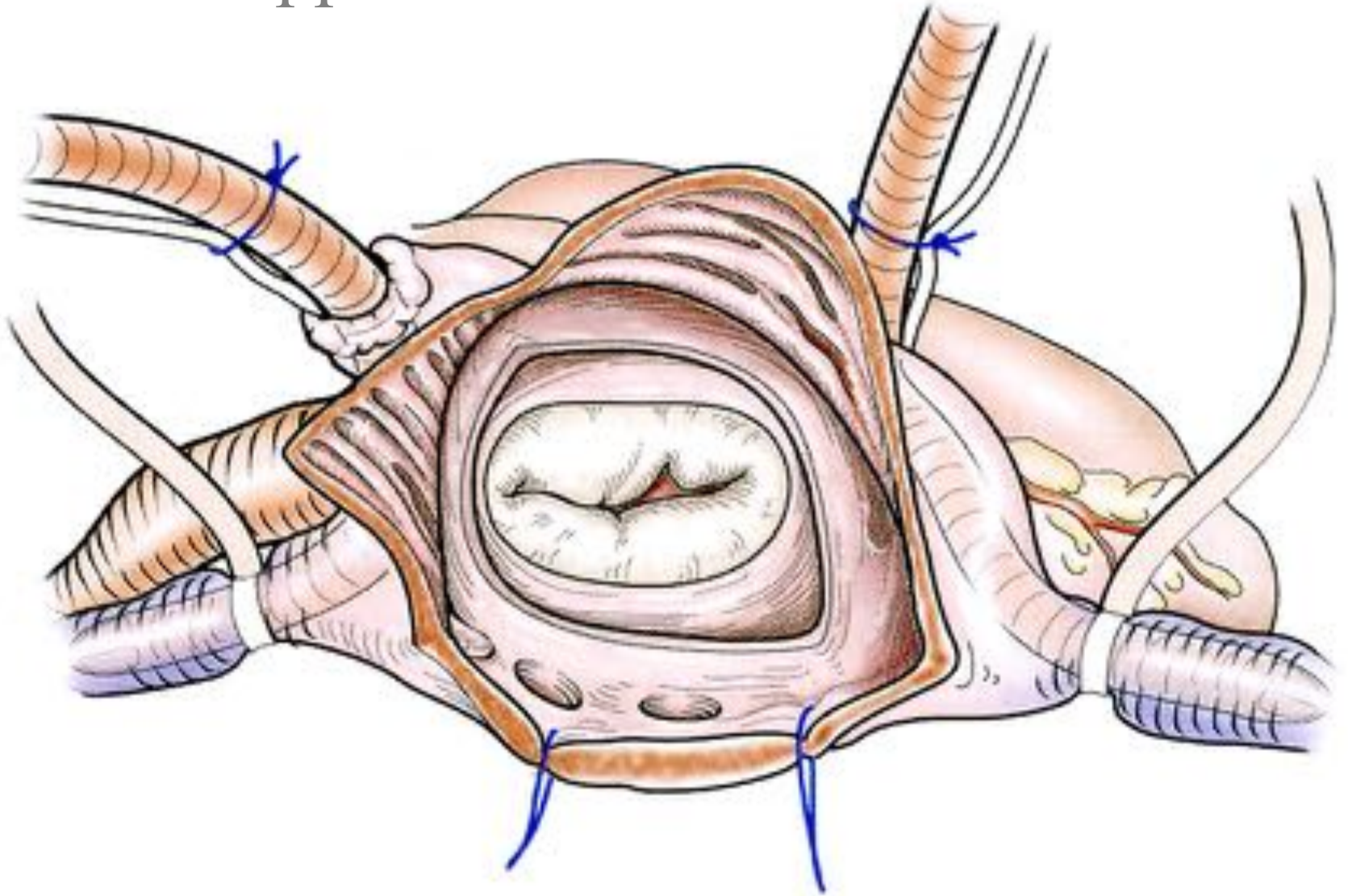
left atrial approach



bi-atrial approach



bi-atrial approach



Classification fonctionnelle

1/ « jeu » valvulaire normal

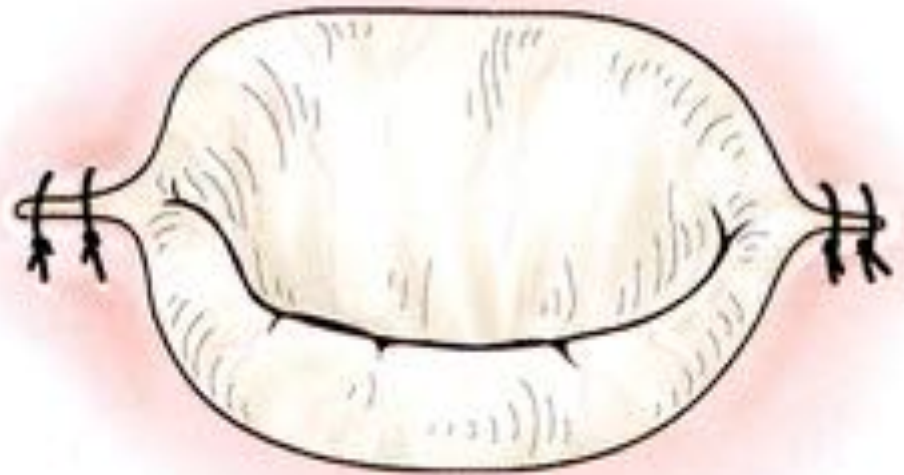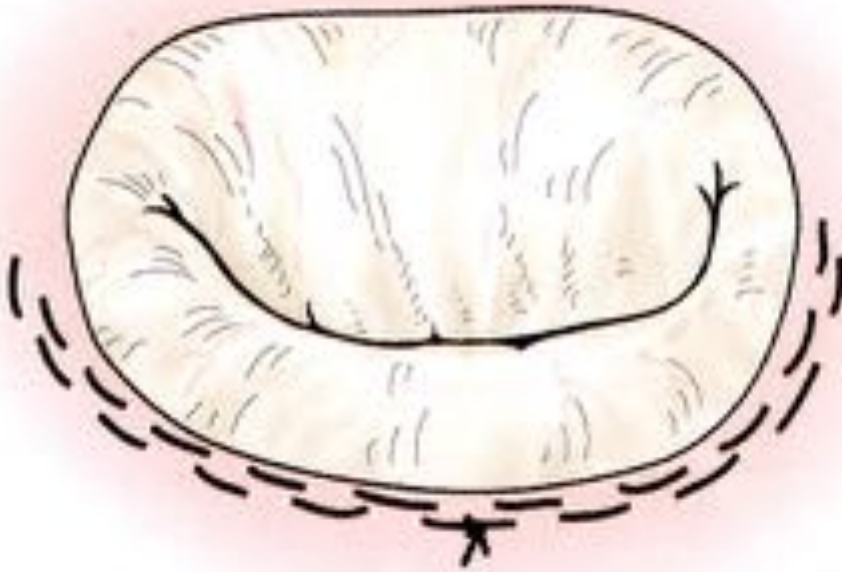
- **dilatation isolée de l'anneau +++**
- **fente mitrale ++**
- double orifice
- « defect » tissu valvulaire
 → fuite mitrale

Réparation fonctionnelle

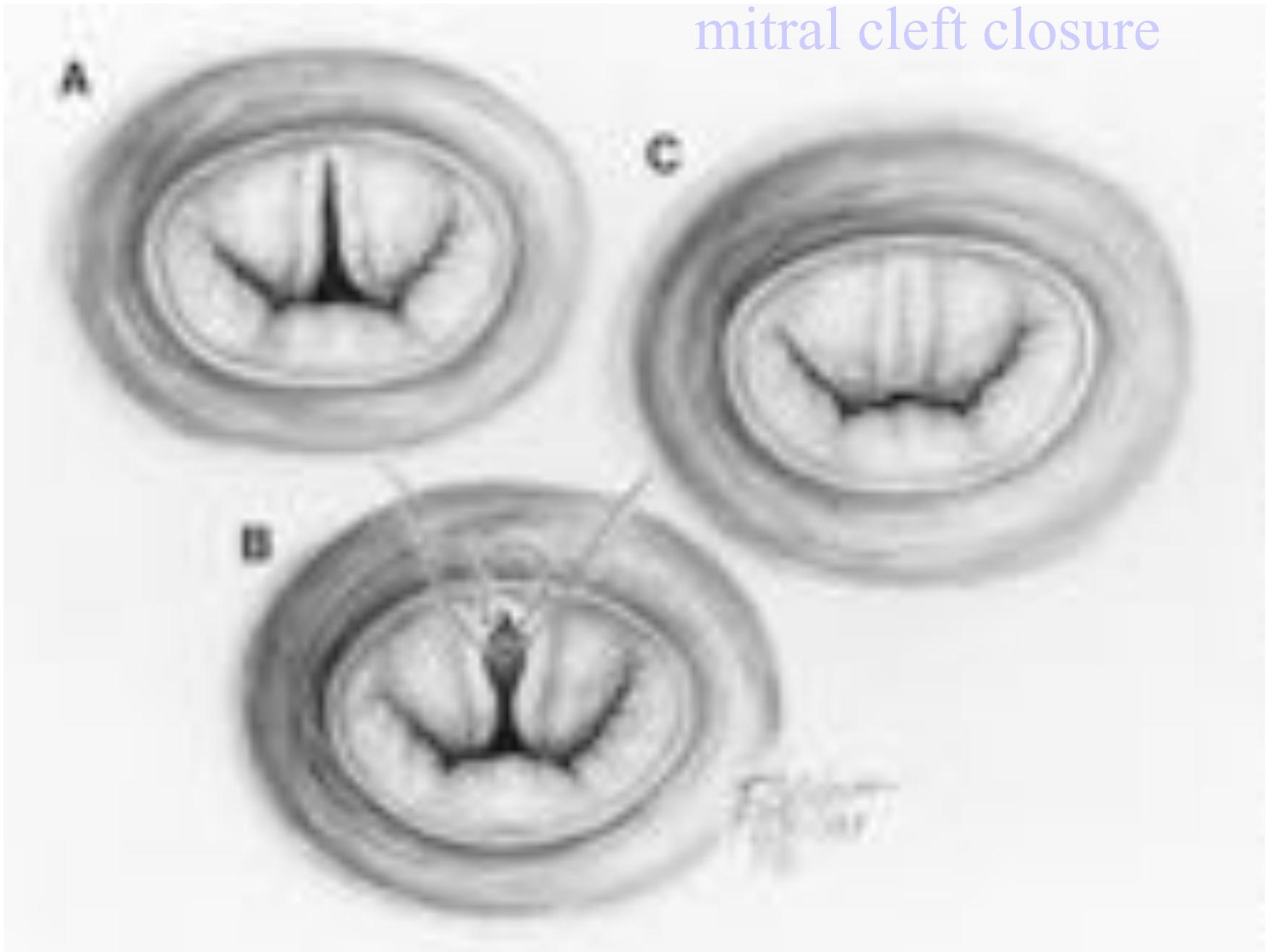
« jeu » valvulaire normal

- dilatation isolée de l'anneau
 - annuloplastie (fil résorbable)
 - annuloplastie semi-circulaire
 - pas d'anneau prothétique
- fente mitrale: fermeture
- double orifice:
 - fermeture fente orifice principal
 - orifice accessoire : rien +/- fermeture
- « defect » tissu valvulaire: extension péricarde

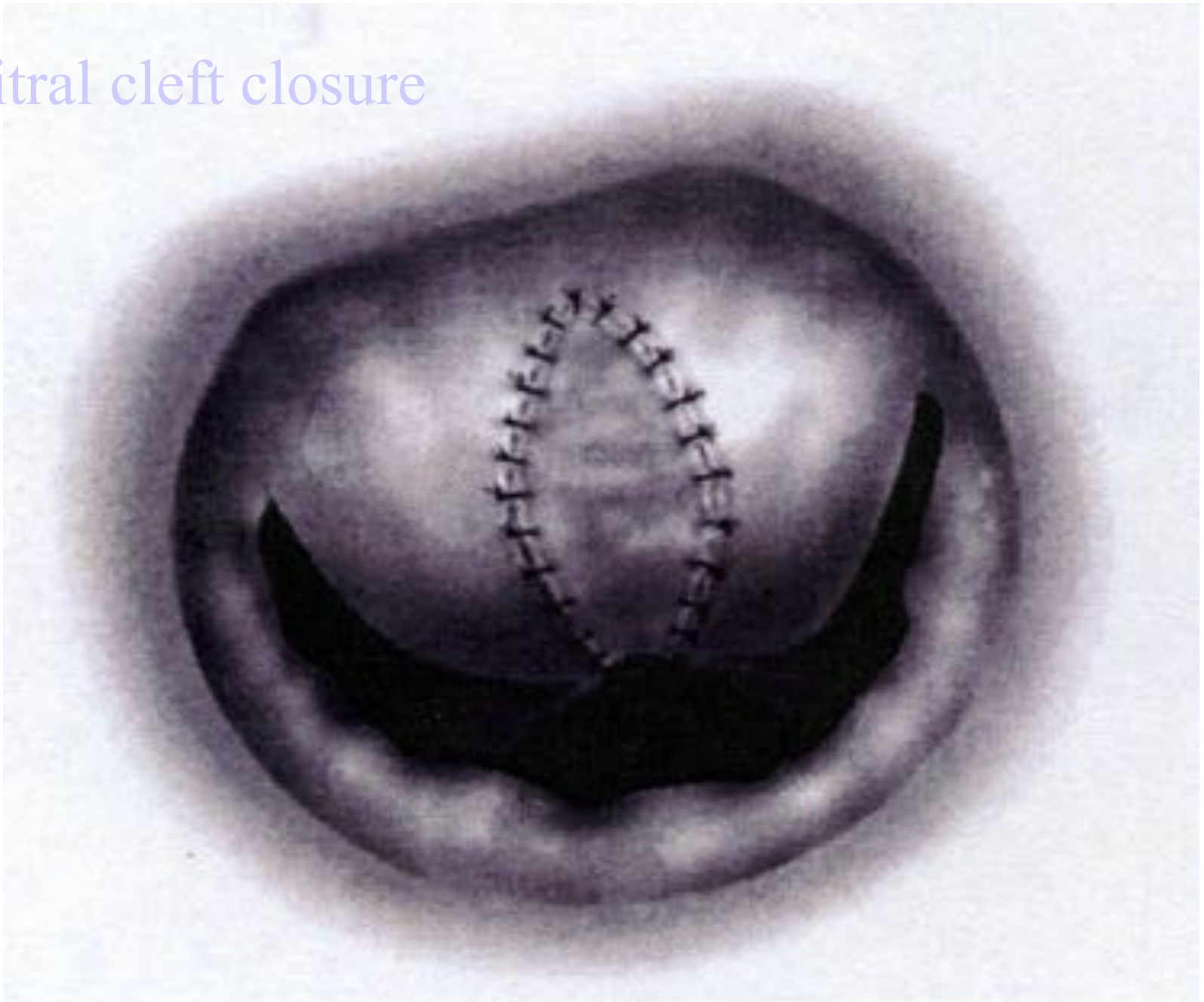
annuloplastie



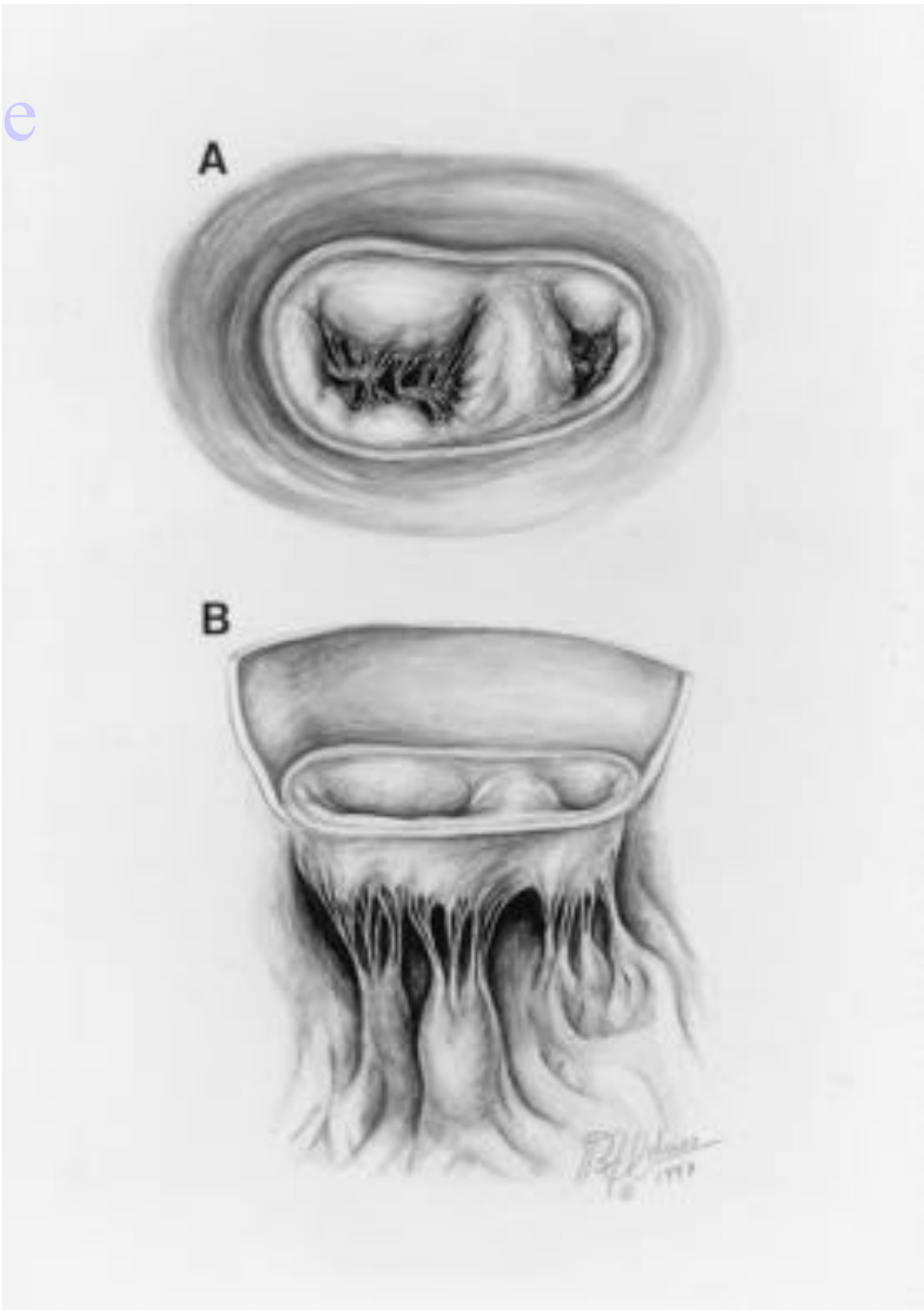
mitral cleft closure



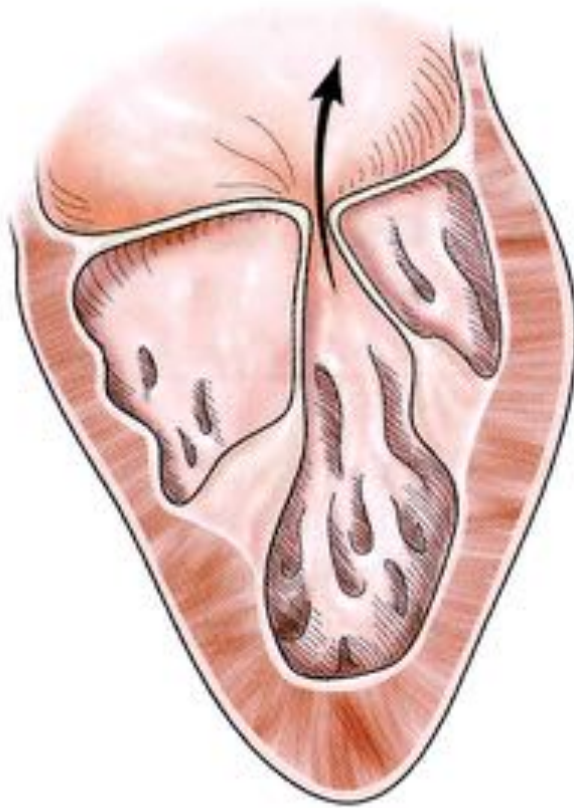
mitral cleft closure



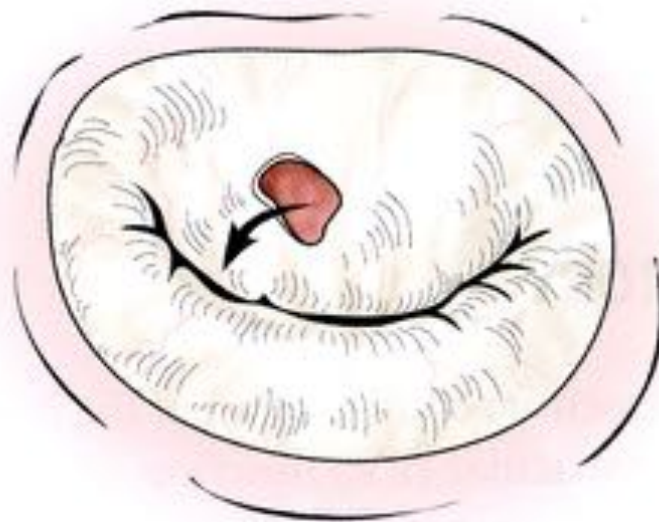double orifice



Dilatation anneau



→ **Fuite mitrale**

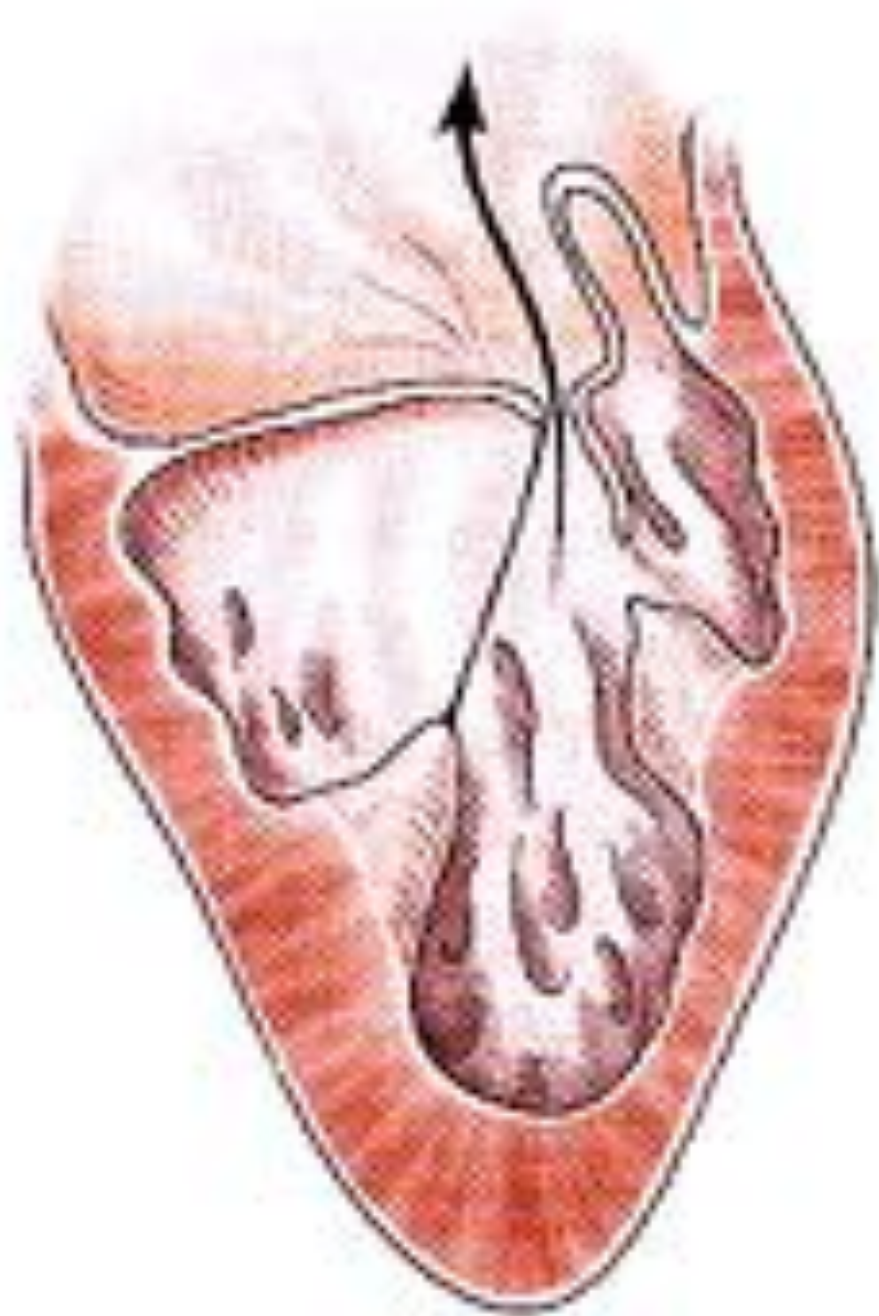


Perforation

Classification fonctionnelle

2/ prolapsus valvulaire

- absence ou rupture de cordage
- cordage étiré
- m. papillaire étiré
 - fuite mitrale

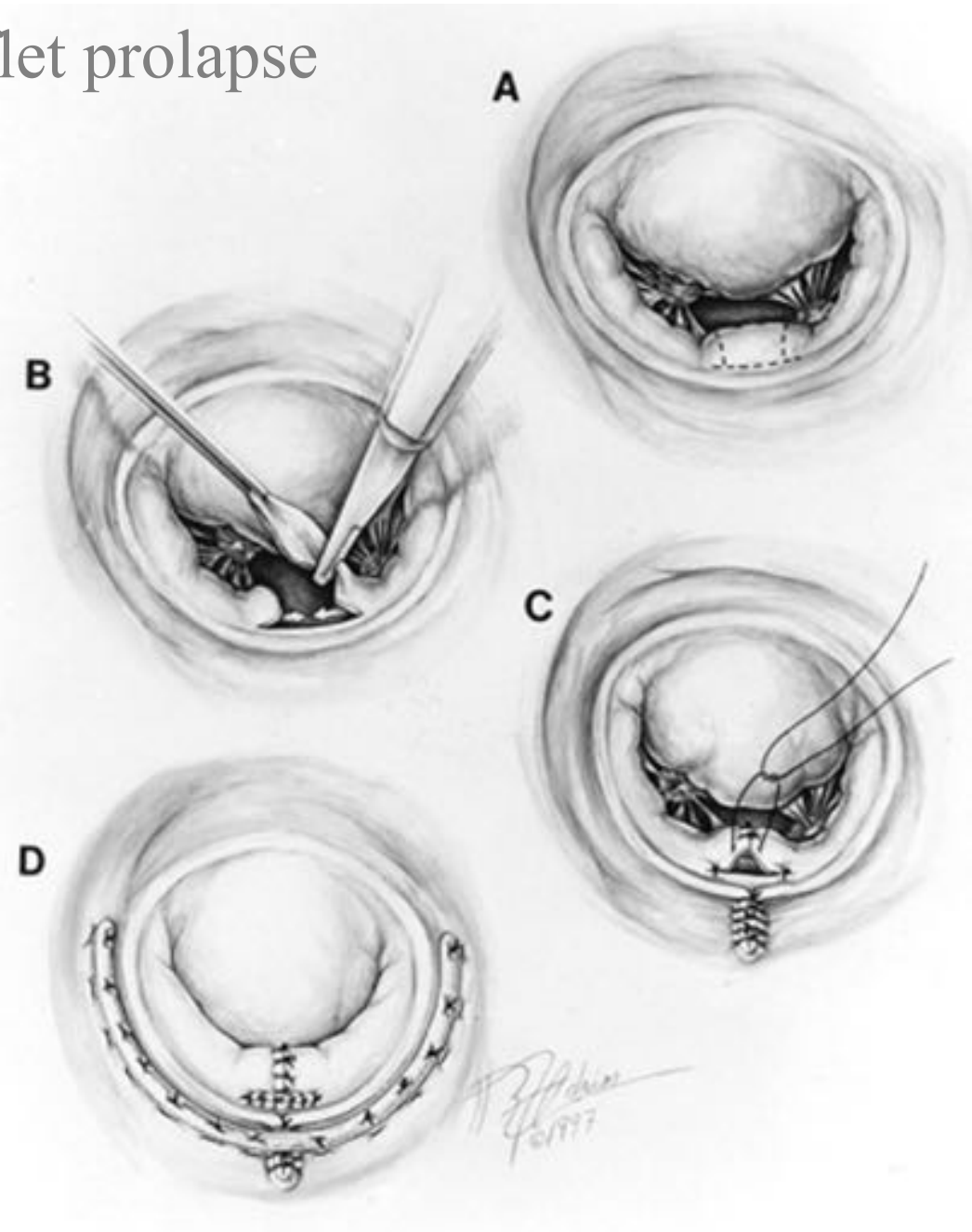


Réparation fonctionnelle

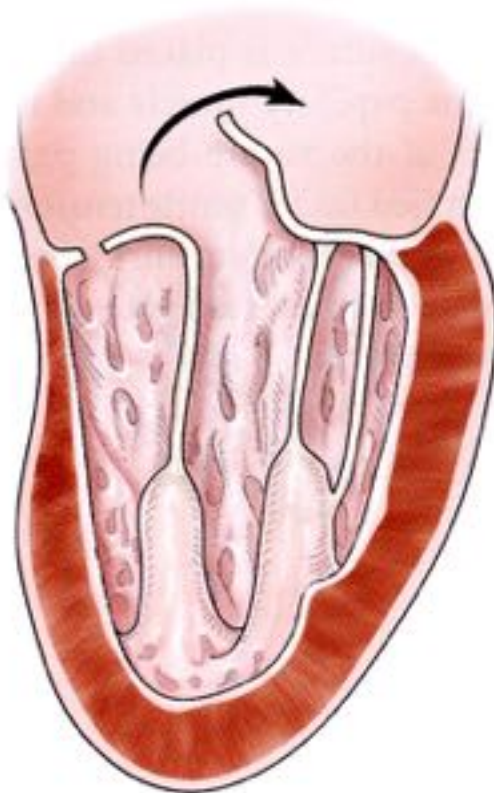
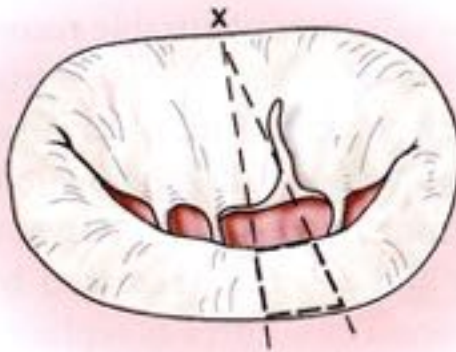
prolapsus valvulaire

- absence ou rupture de cordage
 - résection quadrangulaire (valve postérieure)
 - transposition cordage (valve antérieure)
 - cordage artificiel en goretex
- cordage étiré
 - raccourcissement cordage
 - cordage artificiel en goretex
- m. papillaire étiré
 - raccourcissement m. papillaire

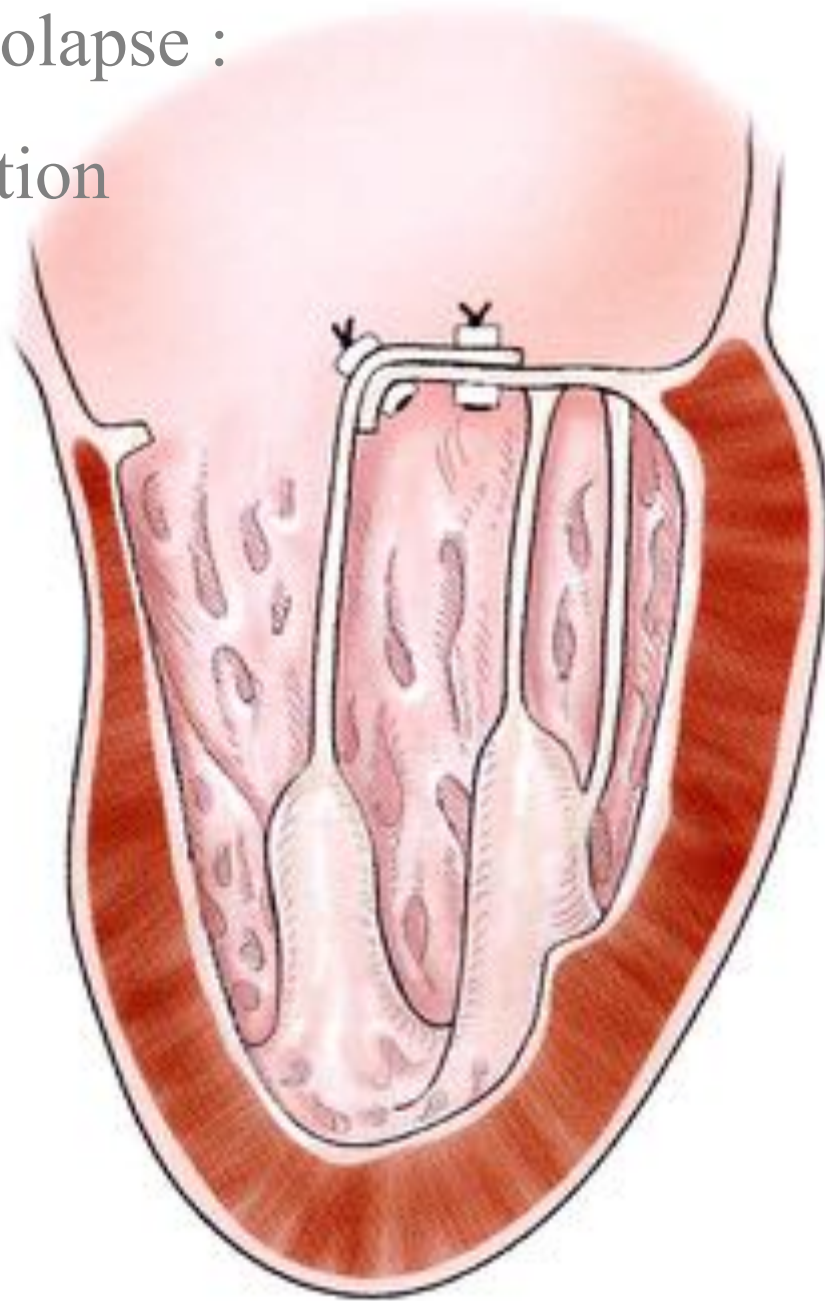
posterior leaflet prolapse



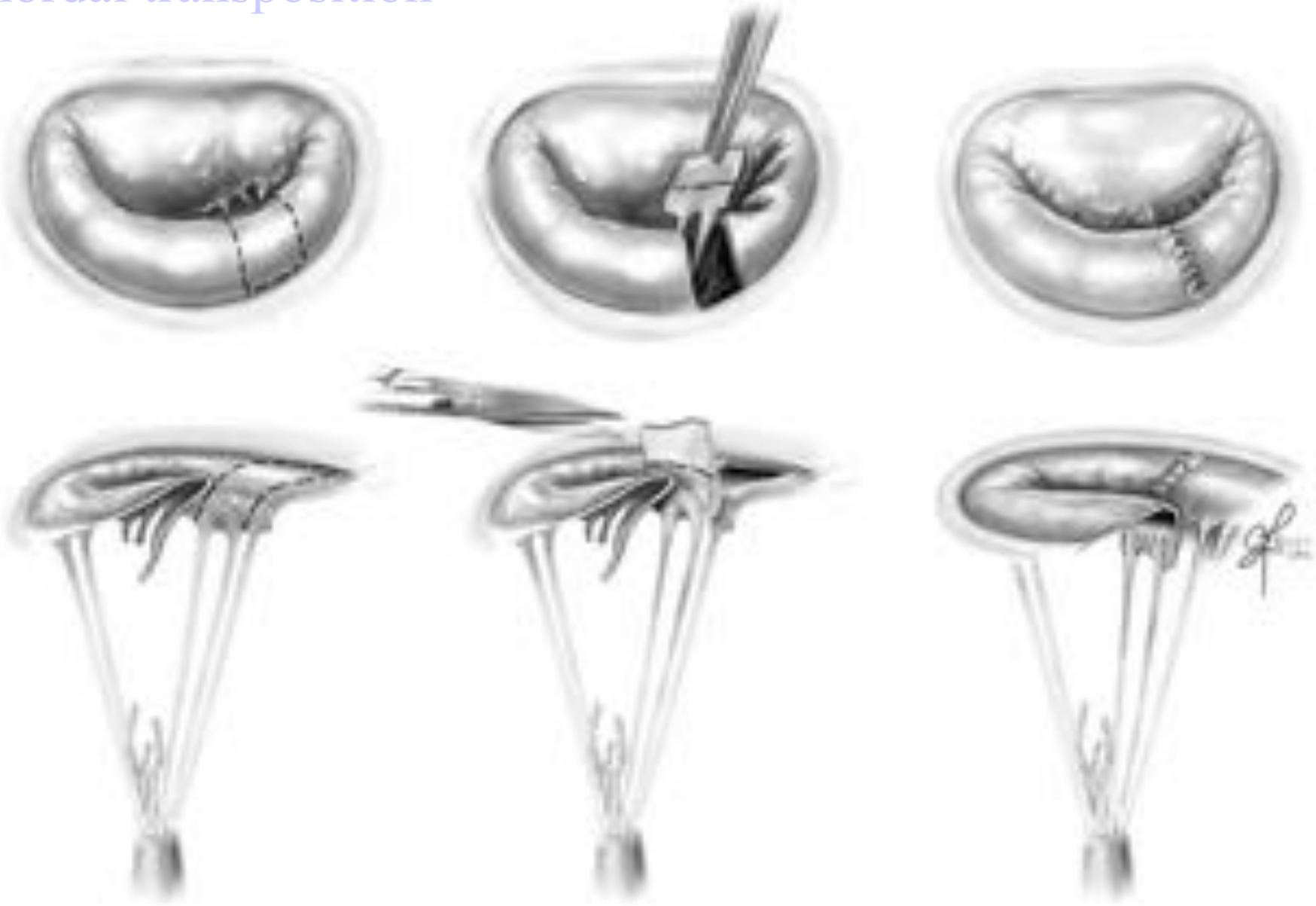anterior leaflet prolapse :
chordal transposition



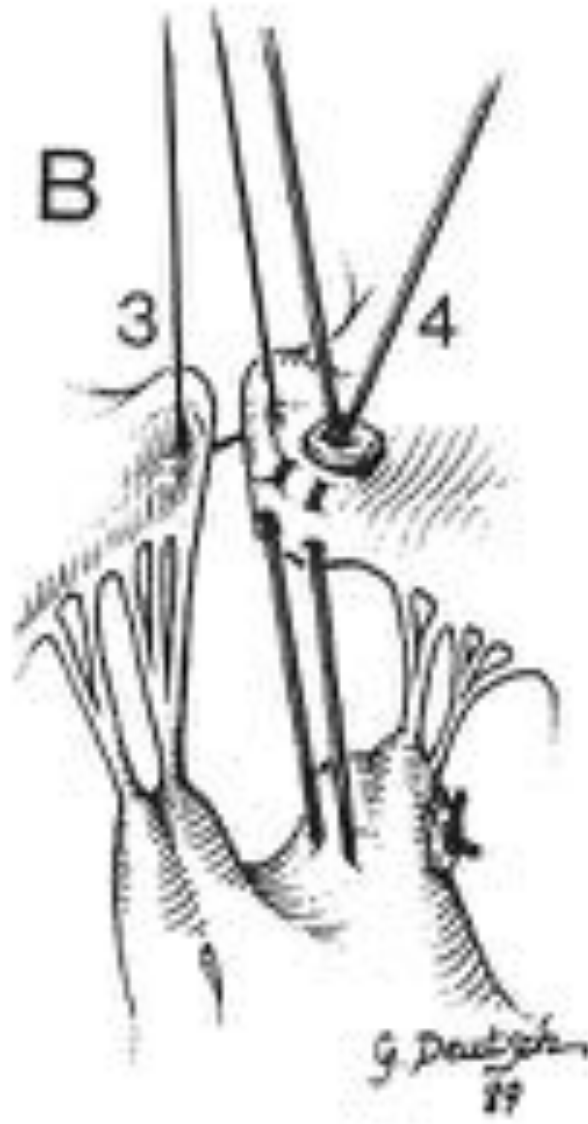
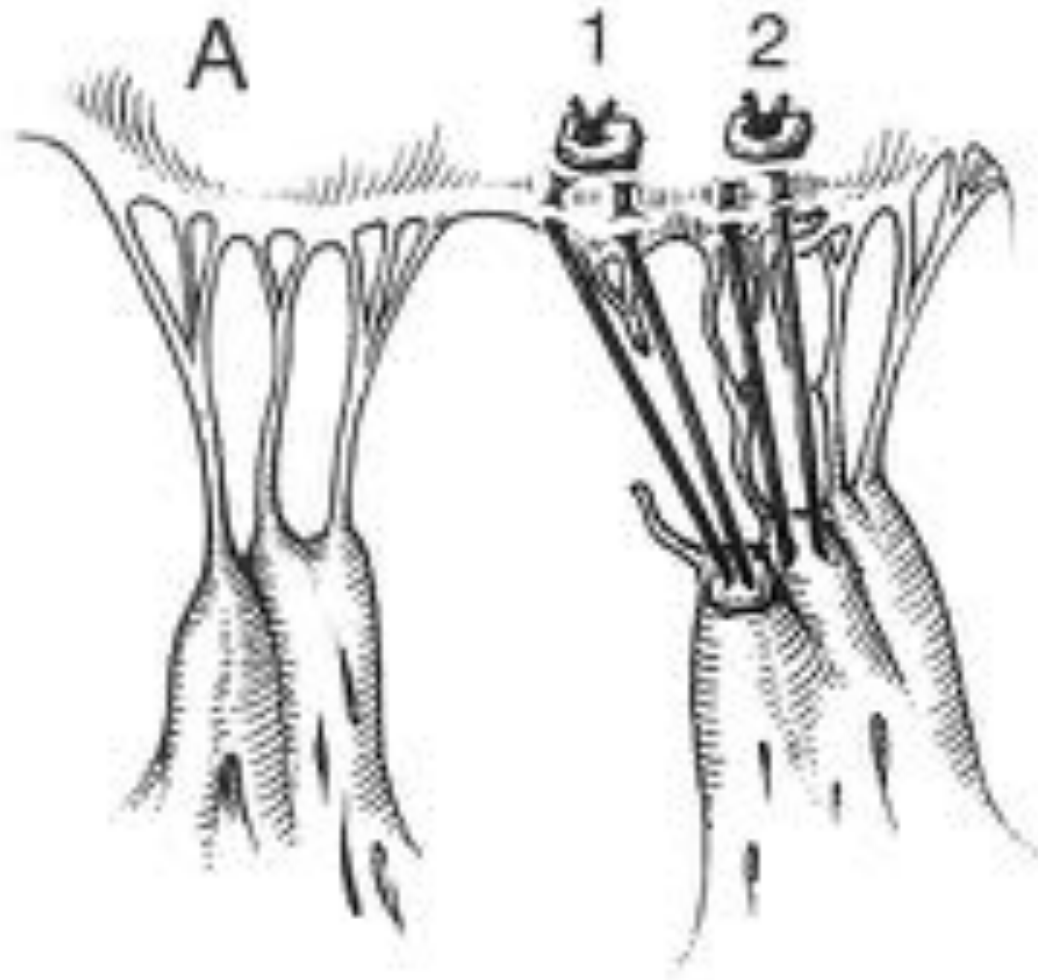
anterior leaflet prolapse :
chordal transposition

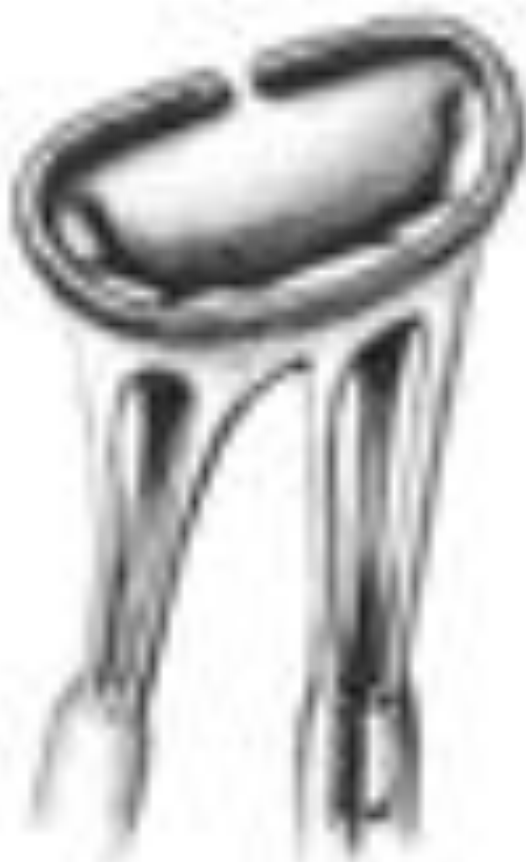
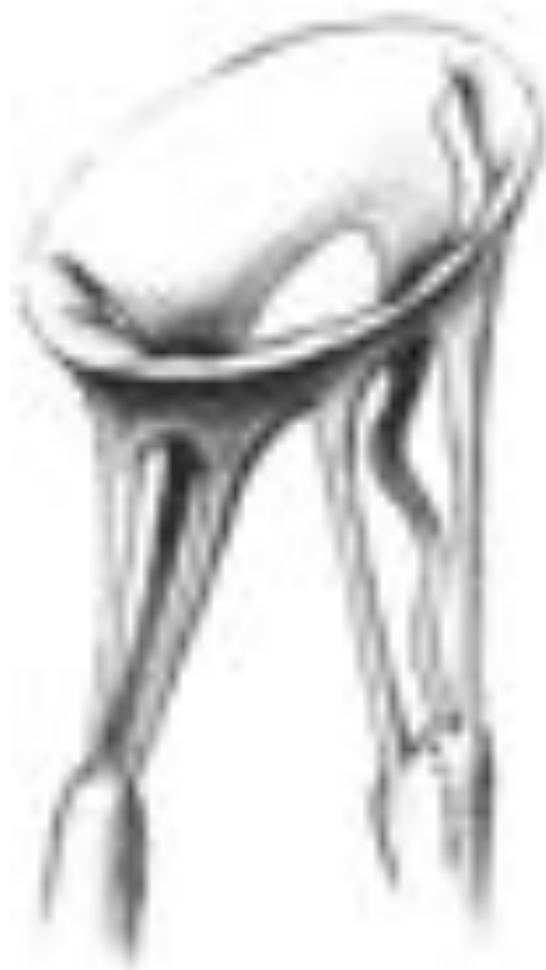
chordal transposition

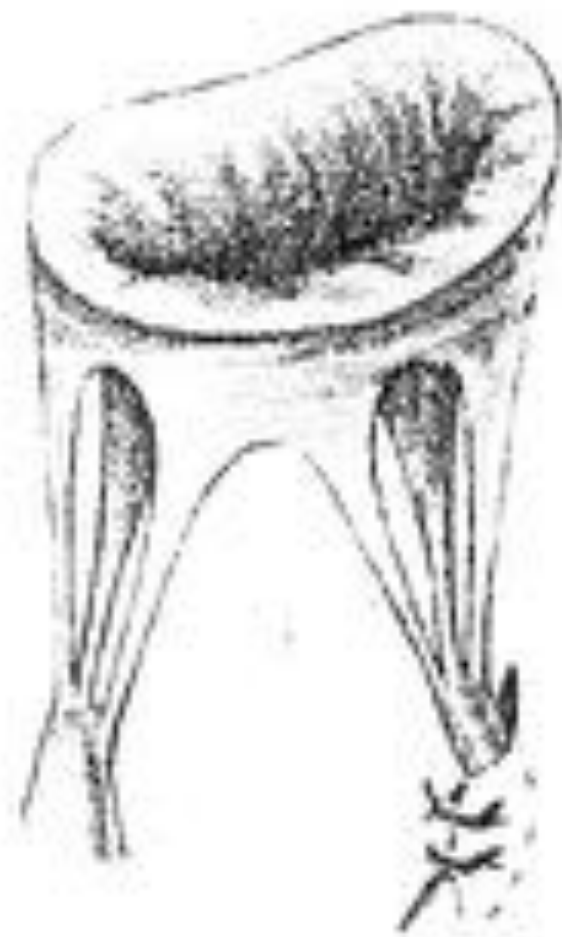
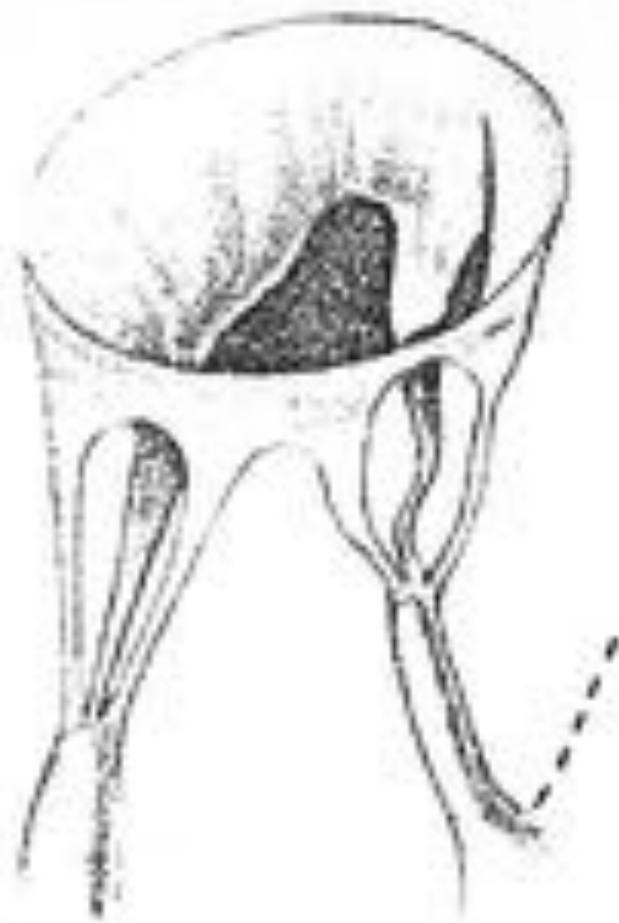


artificial PTFE chordae



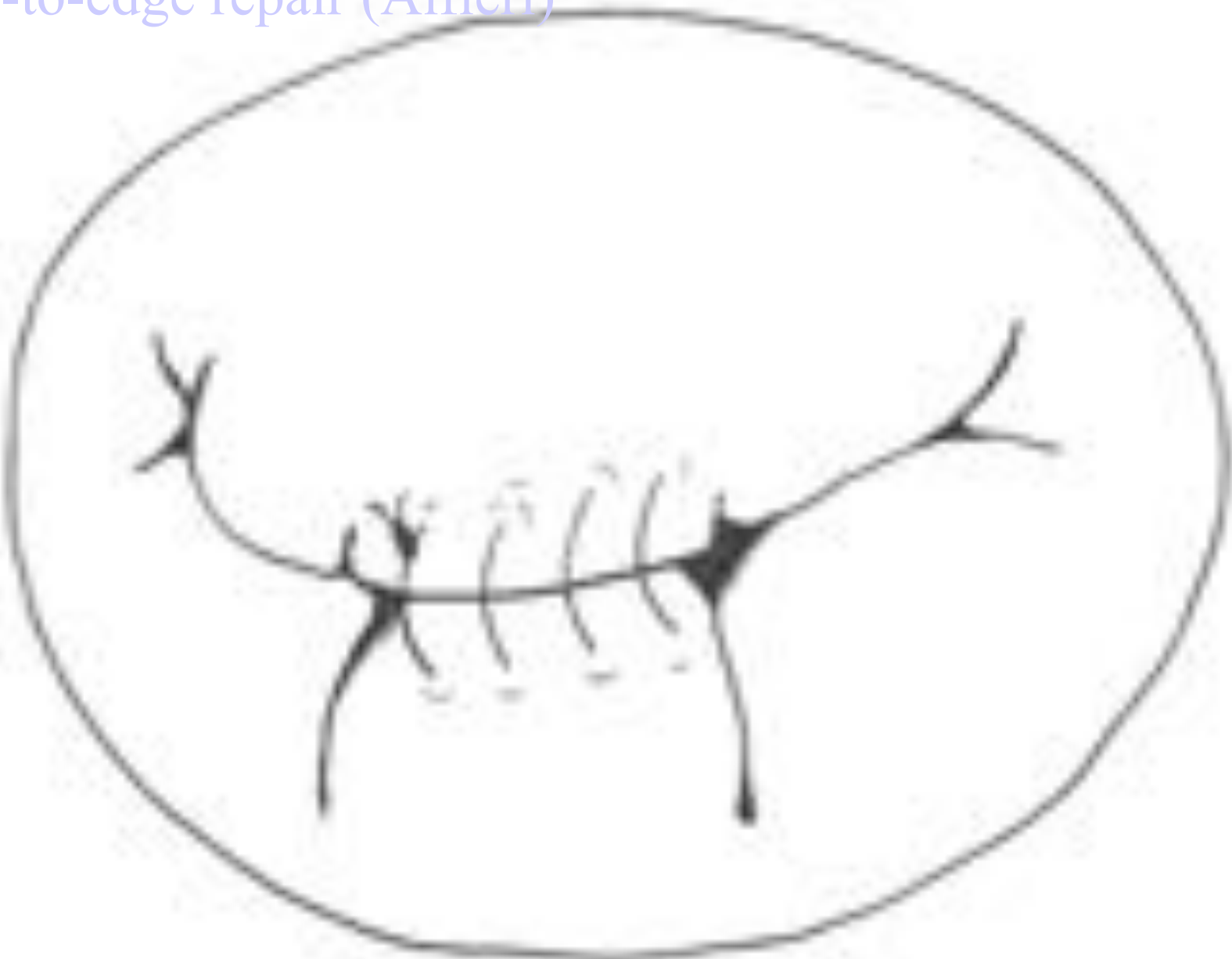


chordal shortening



papillary muscle shortening

edge-to-edge repair (Alfieri)

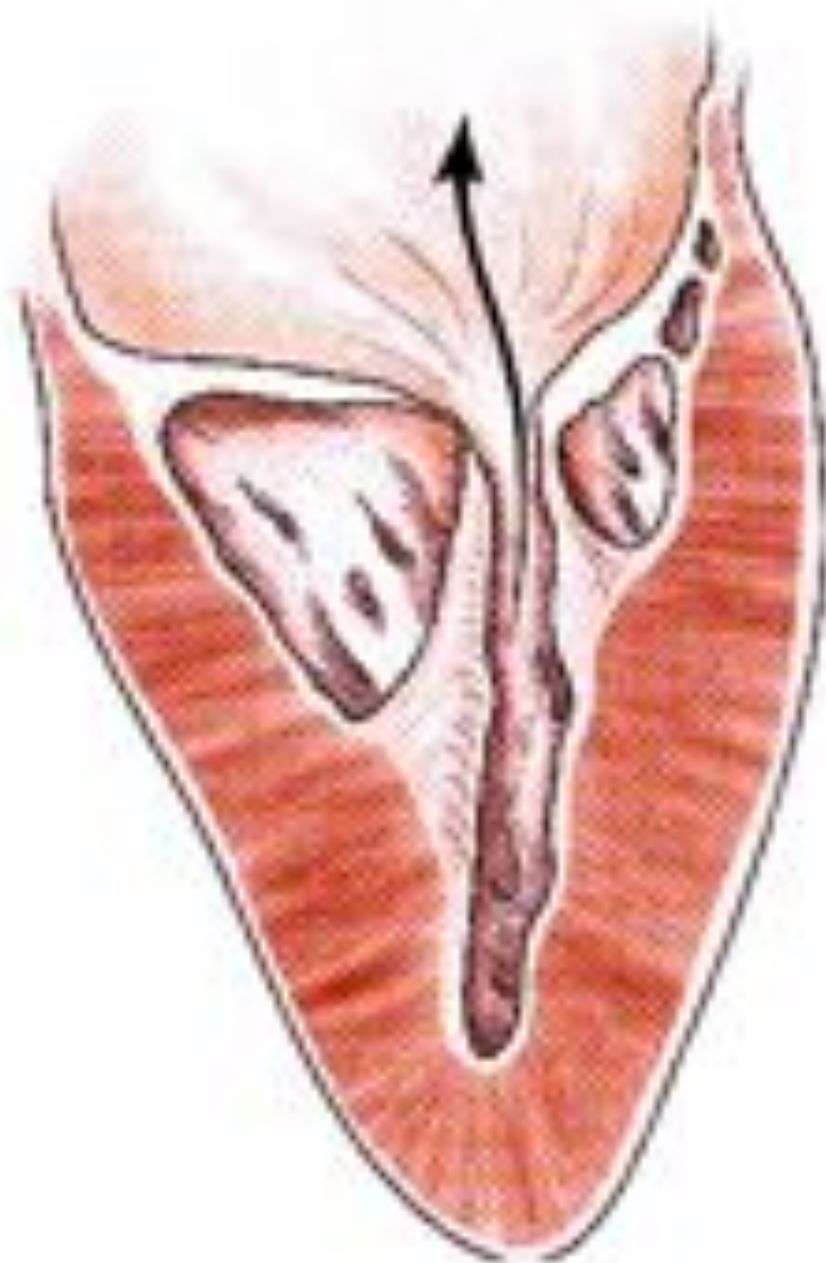


Classification fonctionnelle

3/ « jeu » valvulaire réduit

- **avec m. papillaires normaux**
 - ring ou anneau supra-valvulaire
- **avec m. papillaires anormaux**
 - fusion m. papillaire-commissure
 - valve en parachute
 - hammock
 - agénésie

➔ fuite et sténose (++) mitrale



Réparation fonctionnelle

« jeu » valvulaire réduit

➤ **avec m. papillaires normaux**

- ring ou anneau supra-valvulaire

- excision / énucléation

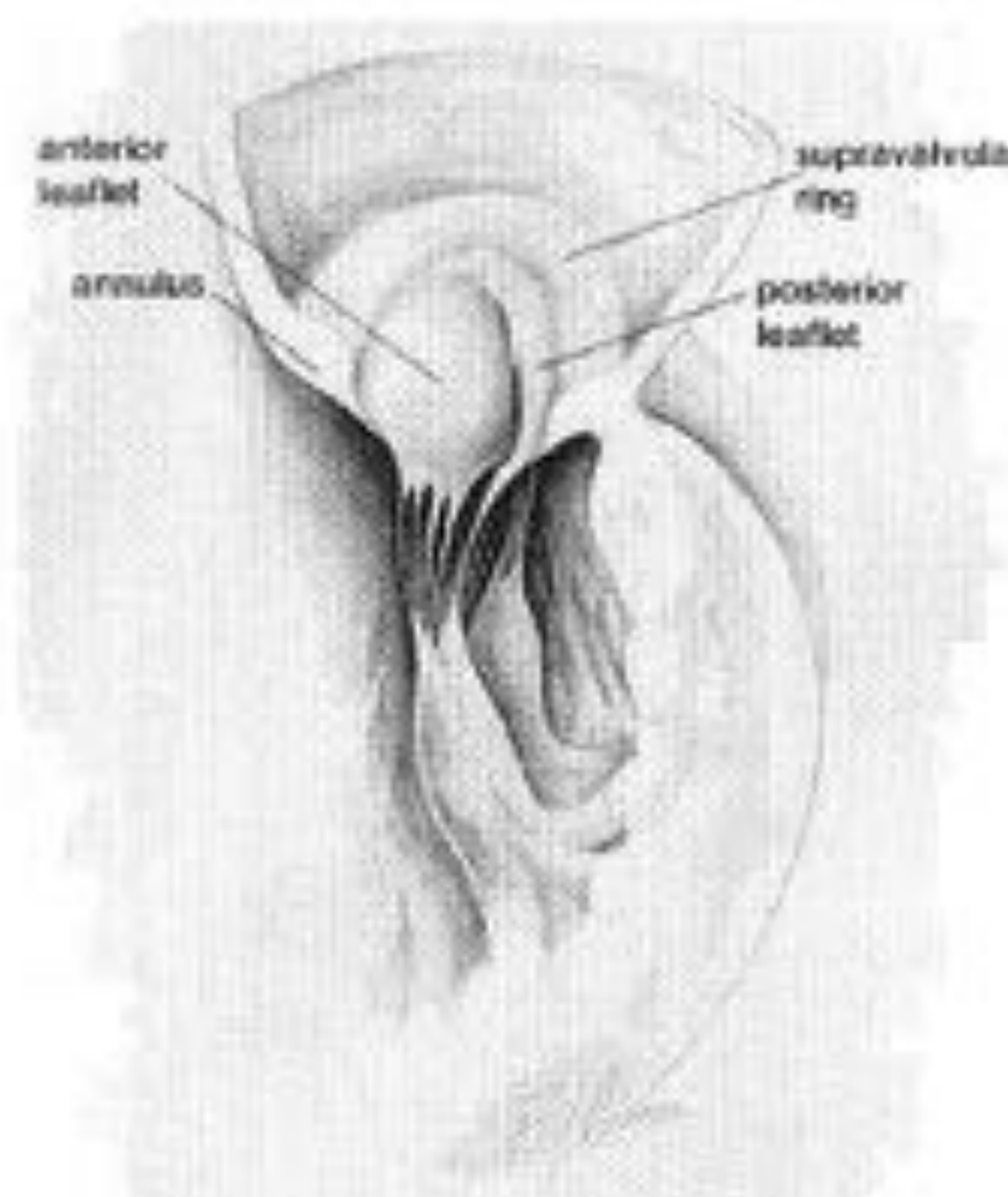
- malformation mitrale associée +++

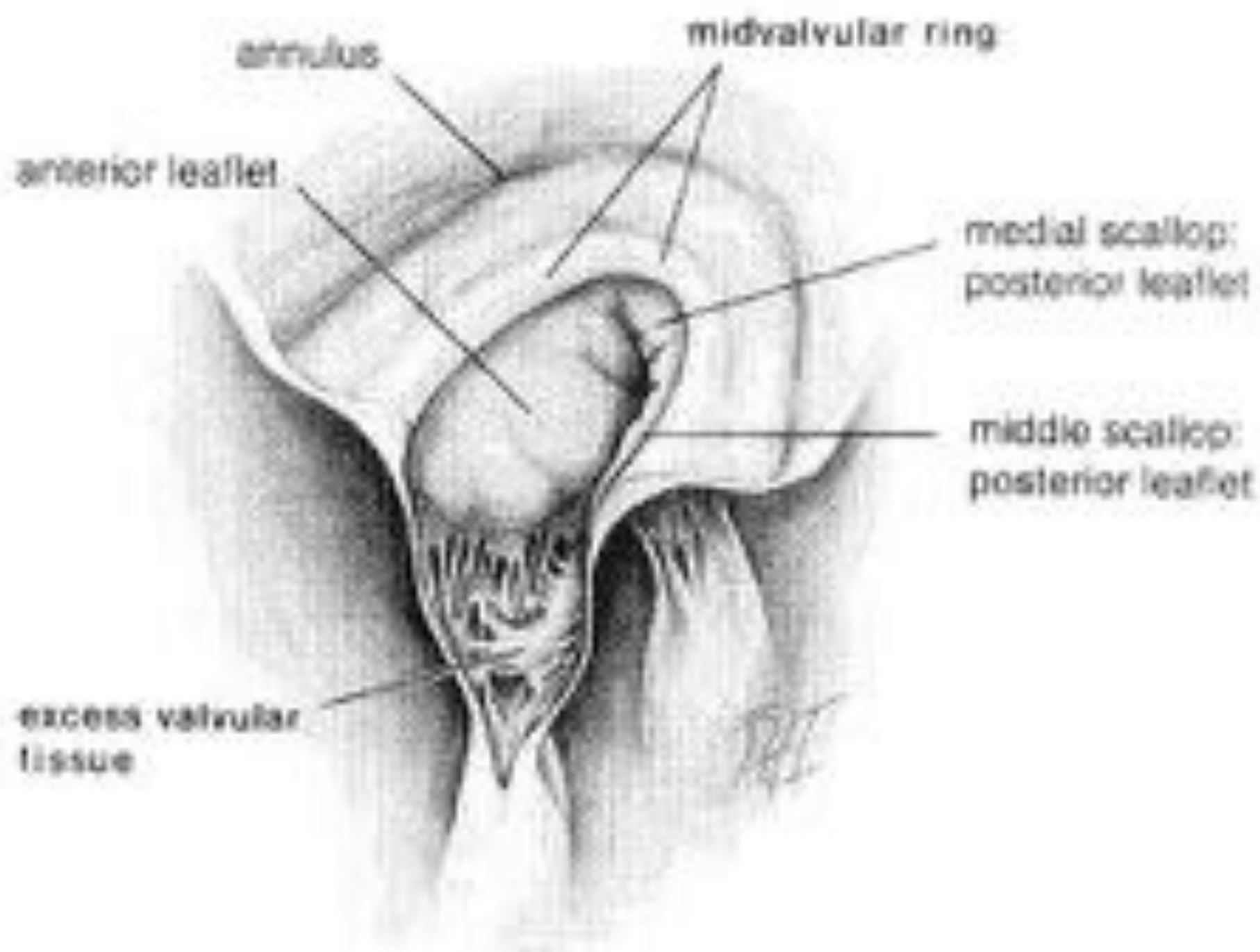
anterior
leaflet

annulus

supraventricular
ring

posterior
leaflet





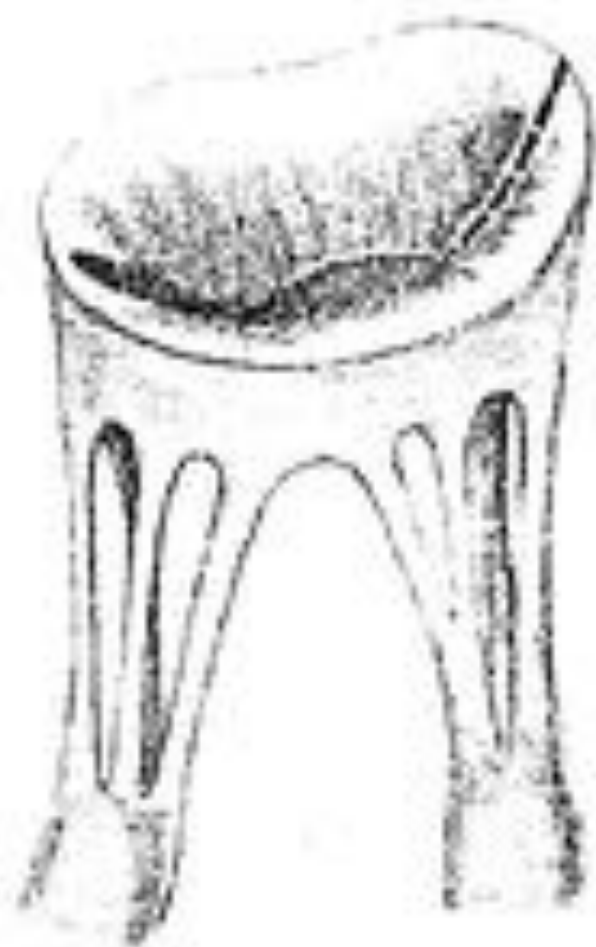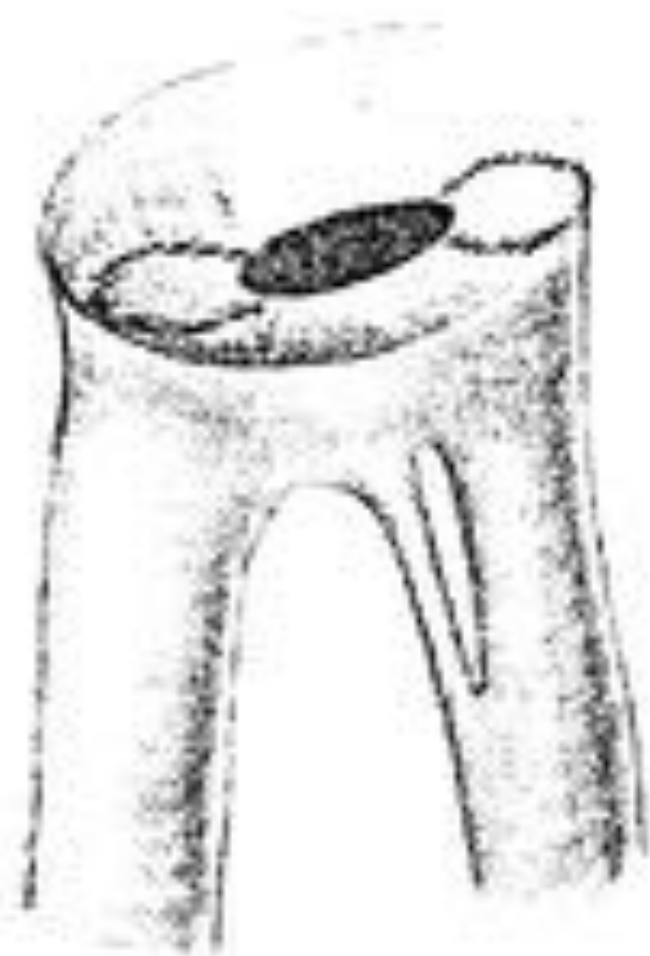
Réparation fonctionnelle

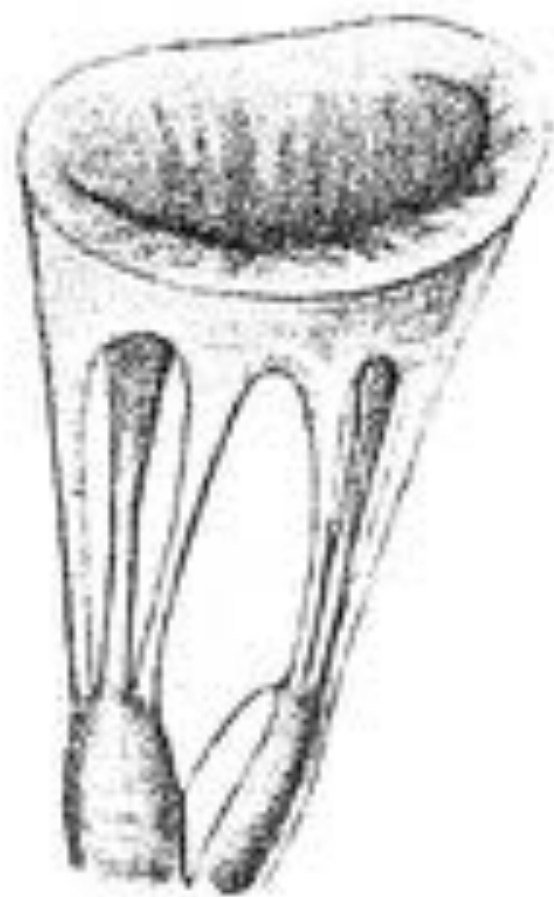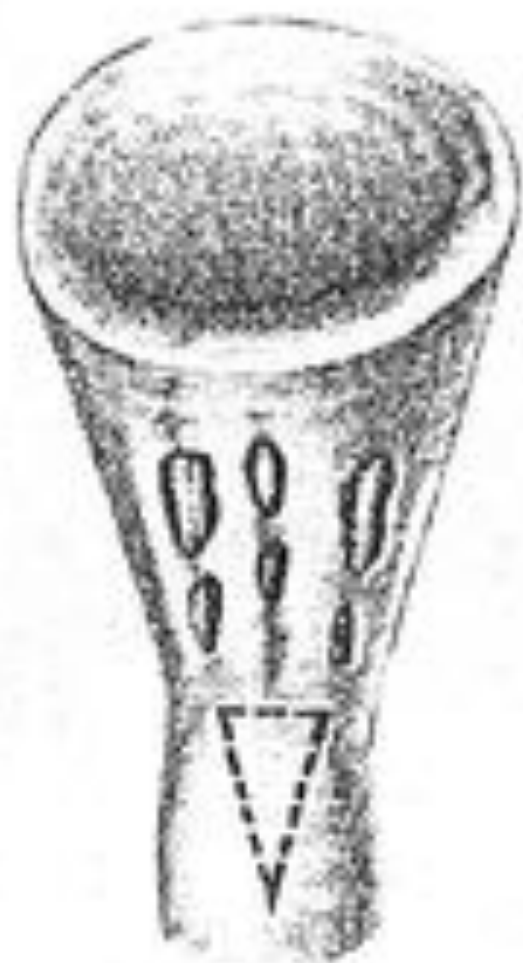« jeu » valvulaire réduit

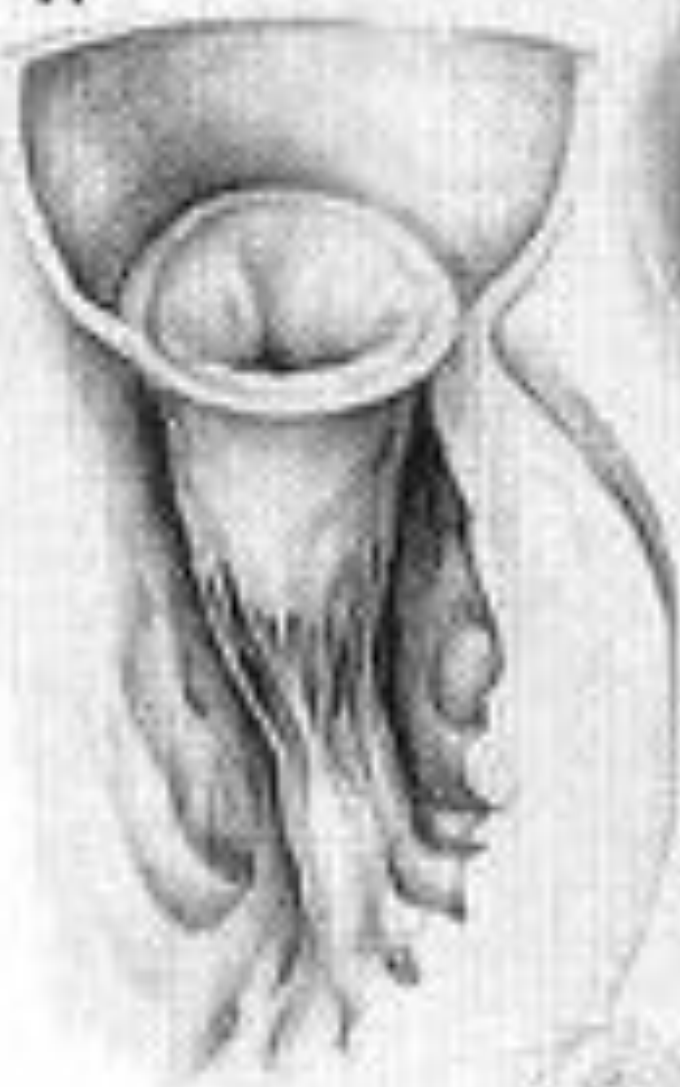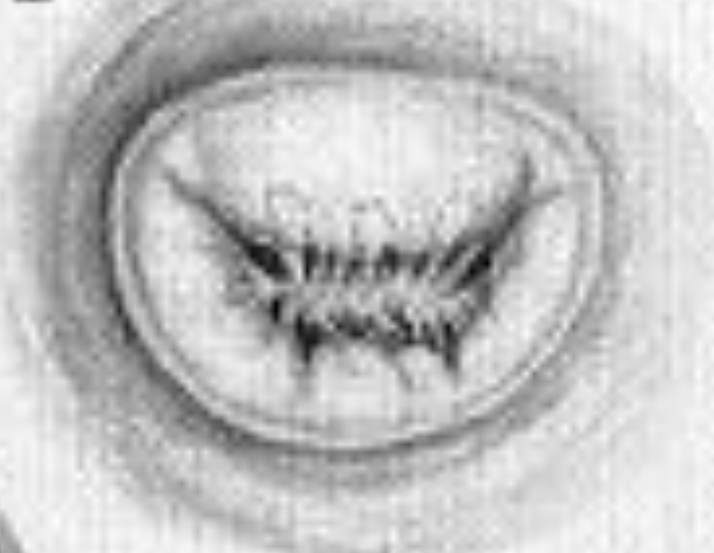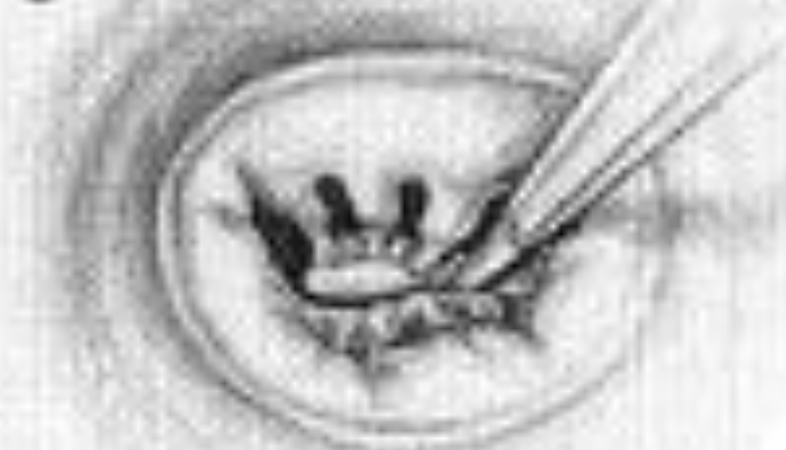➤ **avec m. papillaires anormaux**

- commissurotomie
- fenestration cordage
- fenestration m. papillaire

- But: retarder le RVM

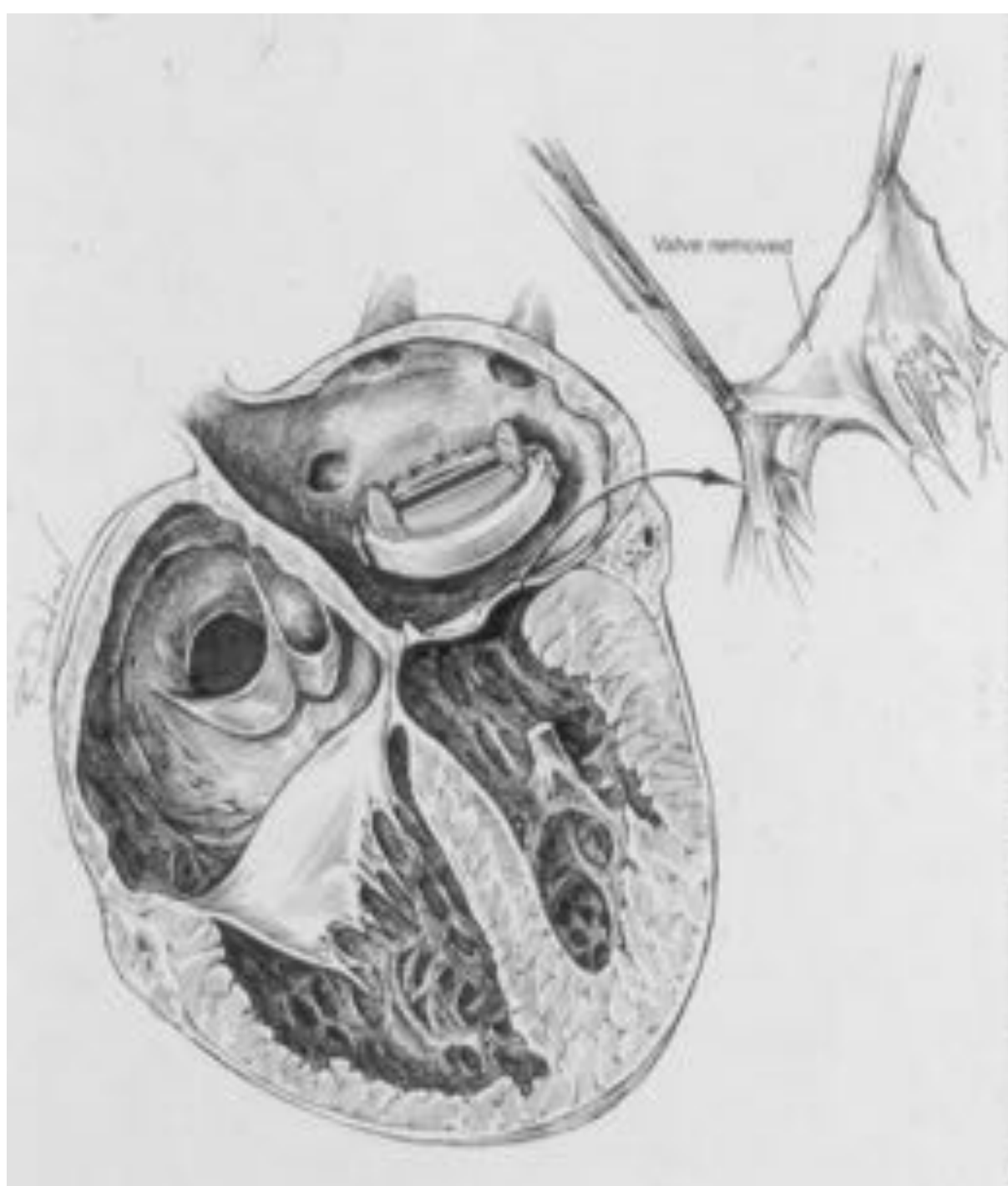


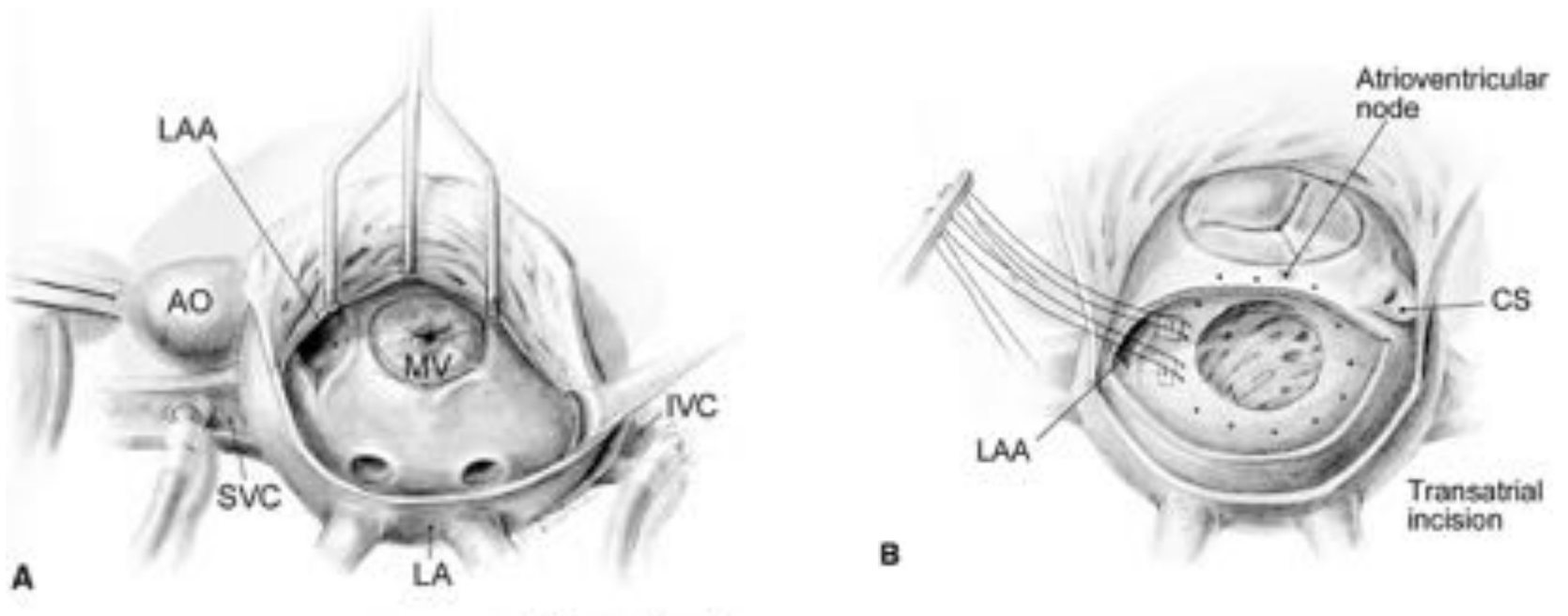


A**B****C**

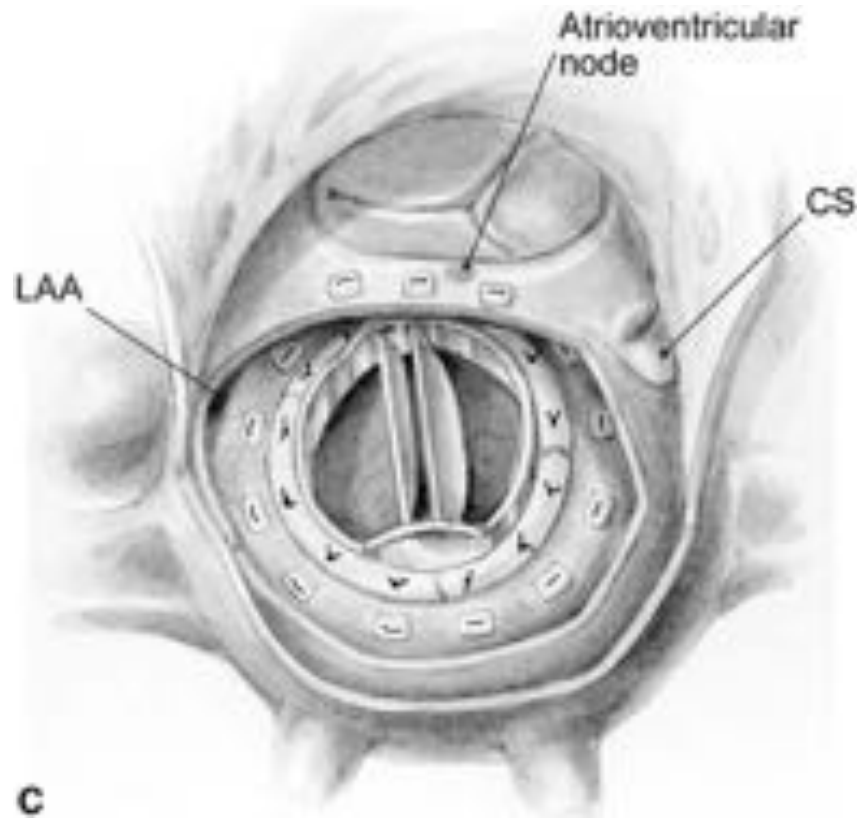
RVM

- Valve mécanique
 - position annulaire
 - position supra-annulaire
- l'opération de Ross mitral



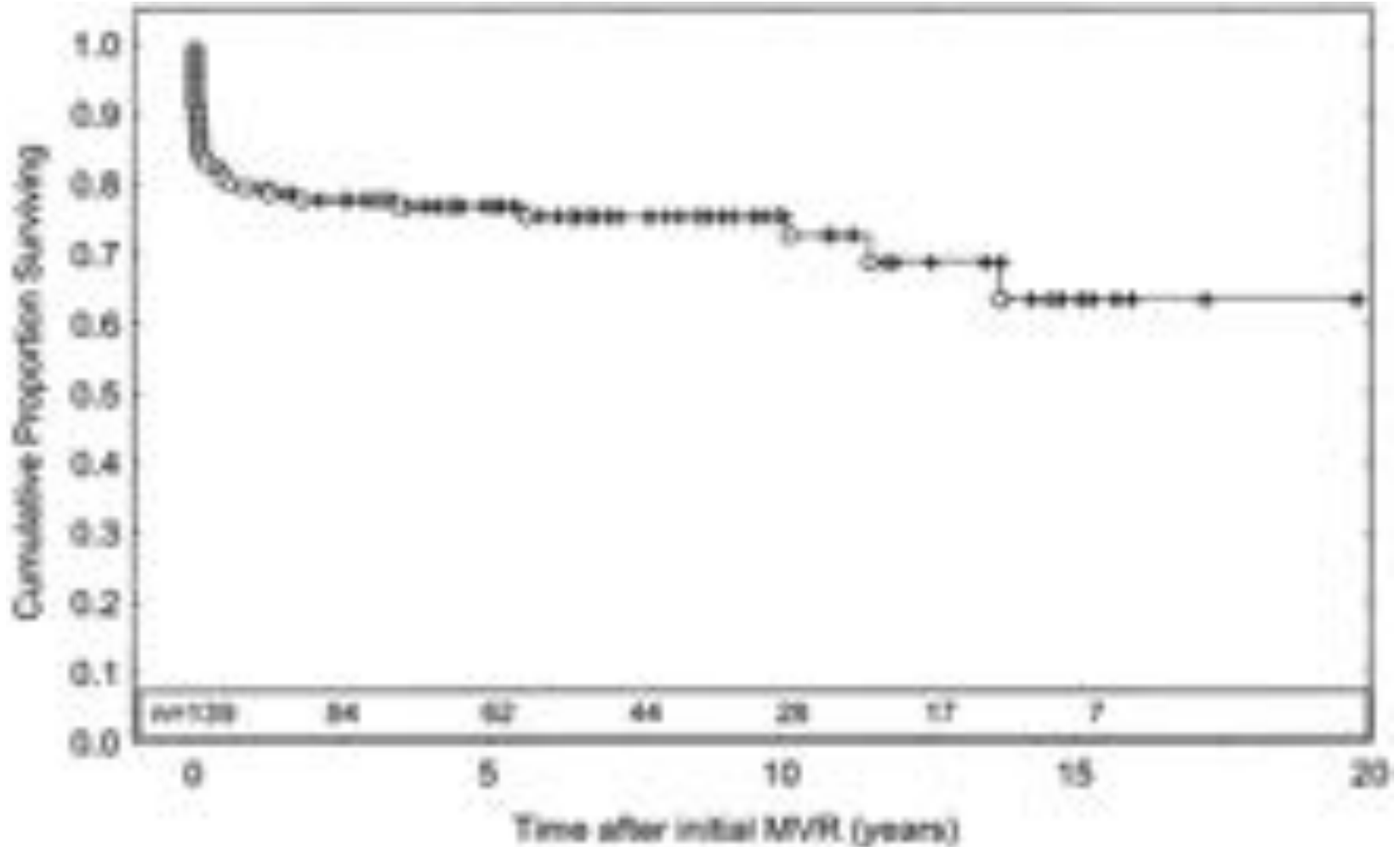


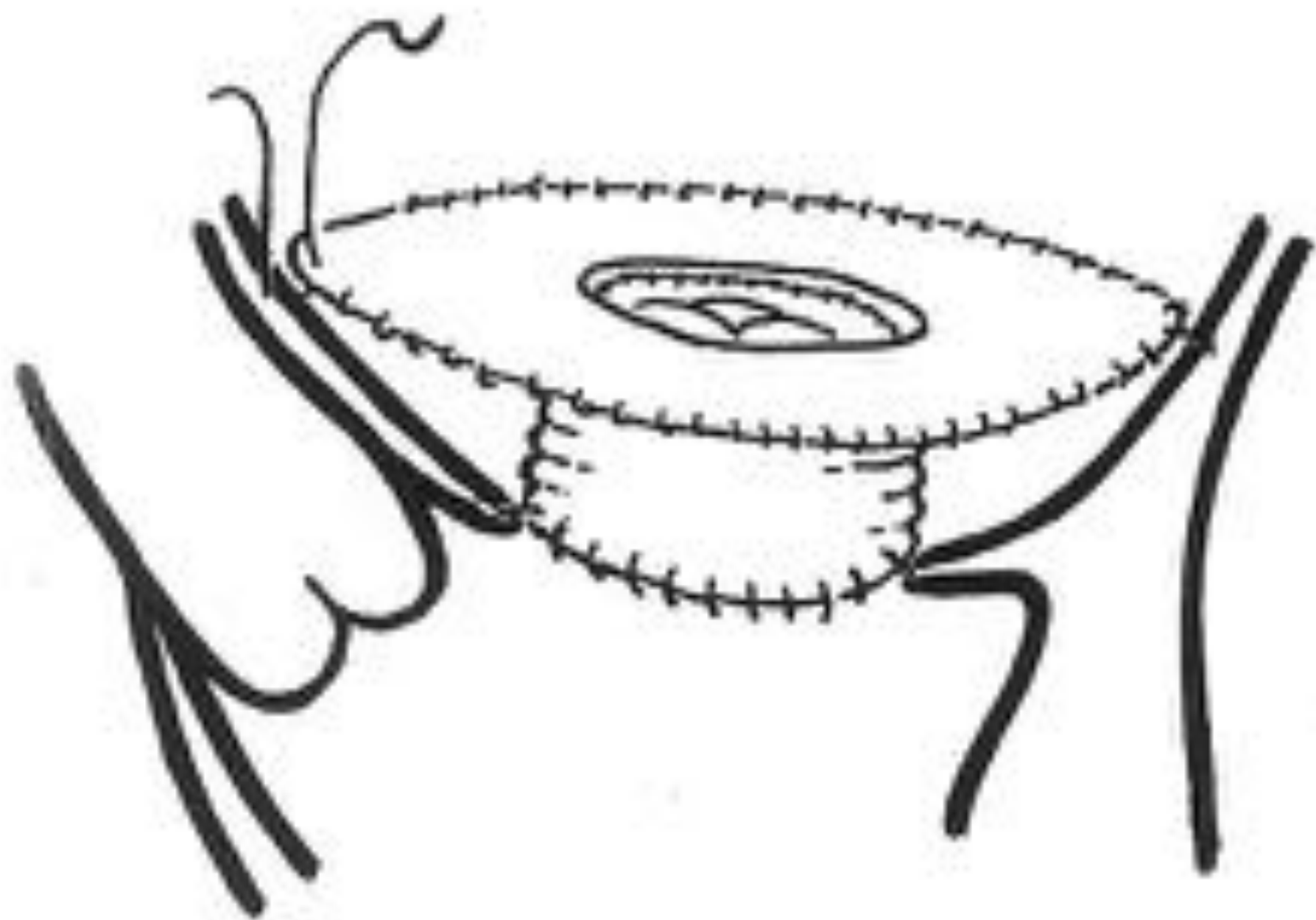
Position supra-annulaire



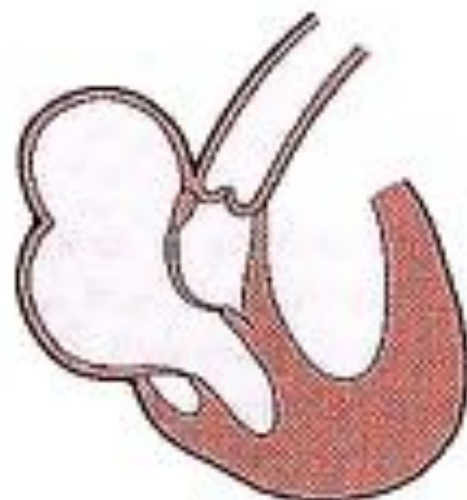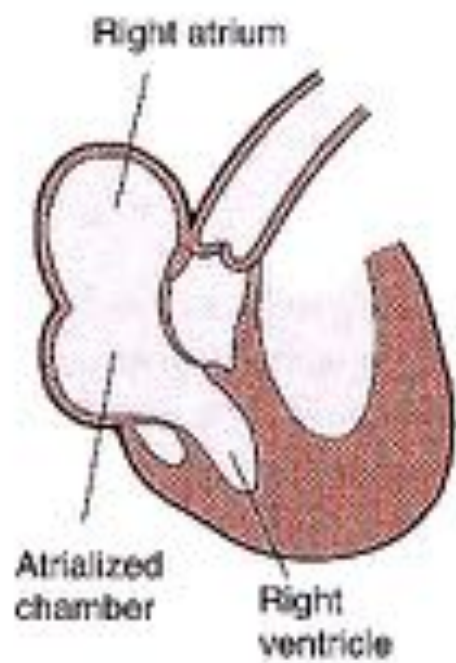
Position supra-annulaire

MVR (mechanical) < 5 years



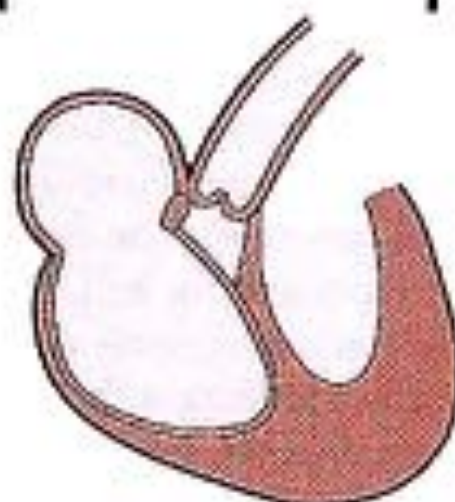
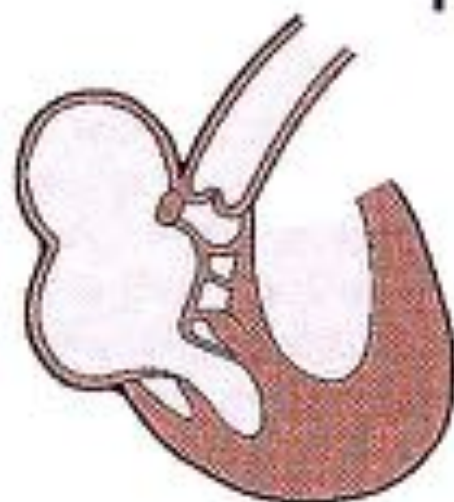


Ebstein:
enfants



1a

1b



1c

1d

