Functionnaly single ventricle Glenn and Fontan

Xavier Iriart
Department of congenital heart disease
Bordeaux, France

Echographic assessment in Fontan patients: sequential segmental approach

1. Cavopulmonary connection
2. Branch PAs

PRELOAD

3. Pulmonary veins

4. Atrial septum

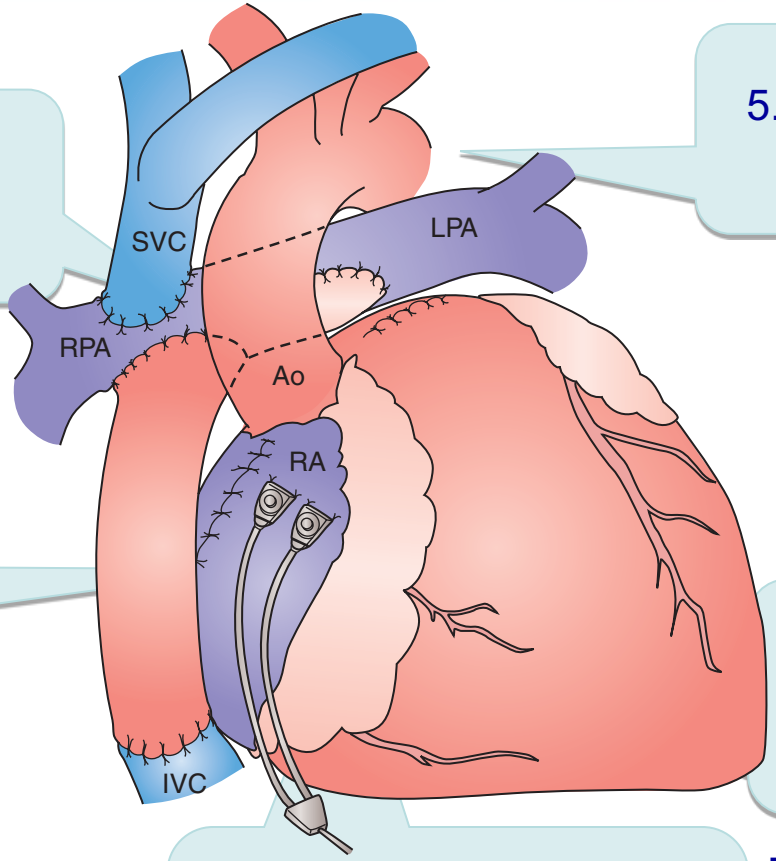

5. Systemic outflow tract
8.Aortic arch

AFTERLOAD

6.Systemic ventricular function

7. Atrioventricular valves

FUNCTION

pathophysiology

- Absence of the RV to PA coupling: influence on the systemic venous return and the pulmonary circulation.

- Approximately 1/3 of the energy generated by the right ventricle absorbed by the arterial compliance in systole and restituted in diastole to maintain the patency of the distal vessels . The loss of that energy increases pulmonary vascular impedance and therefore afterload.

- The same lack of ventriculoarterial coupling explains the role of external factors:
  - hydrostatic forces
  - ventilatory mechanic
  - role of gravity on regional pulmonary pulmonary blood
  - deleterious effects of positive pressure ventilation, and the beneficial effects of negative pressure ventilation

- Venous return is classically divided into the superior 30% and inferior vena caval territories 70%.more logical to divide the systemic venous system into three subsystems:
- the superior vena caval system
- the systemic inferior vena caval system
- the splanchnic system.

- The splanchnic system > portal vein > capillary liver bed (sinusoids).
  - Sinusoids: most permeable walls of all capillary beds.
  - important hemodynamic consequences: liver= new resistance to splanchnic flow.
  - venous pressure in the splanchnic system is 2-3x higher than that in the systemic inferior caval system.
  - additional resistance imposed by the pulmonary circulation placed in series with the same systemic venous return > propensity to develop effusions and protein-losing enteropathy.

Khambadkone S. Ann Pediatr Cardiol. 2008
De Leval Ped cardiol 1998

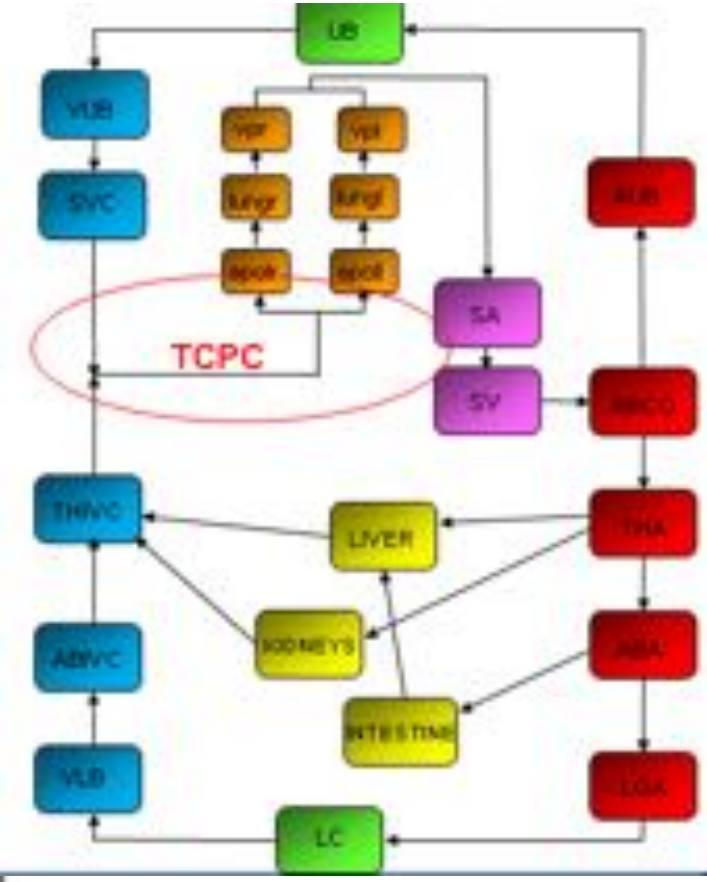

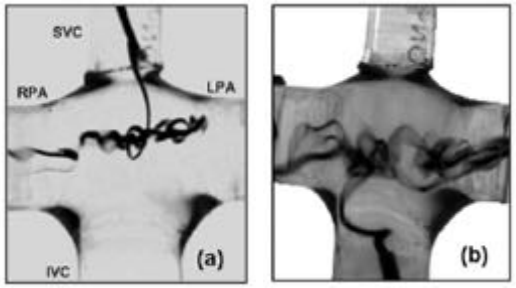

De Zelicourt et al 2005

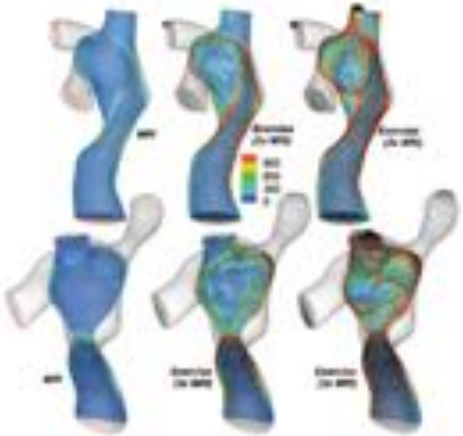

Whitehead et al 2007

Courtesy of Daria Cosentino, Great Ormond street hospital and UCL London

The Fontan operation


Surgical repair of tricuspid atresia

- First described in 1971
- Initially designed for tricuspid atresia
- Extension to all forms of functionally UVH

Ann Chir Thorac Cardiovasc 1971;10:39-47.

Choussat's 10 commandments revisited

1971

Choussat's ten commandments

Age>4 years
Sinus rhythm
Normal systemic venous return
Normal right atrial volume
Mean pulmonary artery pressure<15 mm Hg
Pulmonary arteriolar resistance<4 Wood units/m2
Pulmonary artery–aorta ratio>0.75
Left-ventricular ejection fraction>0.60
Competent mitral valve
Absence of pulmonary artery distortion

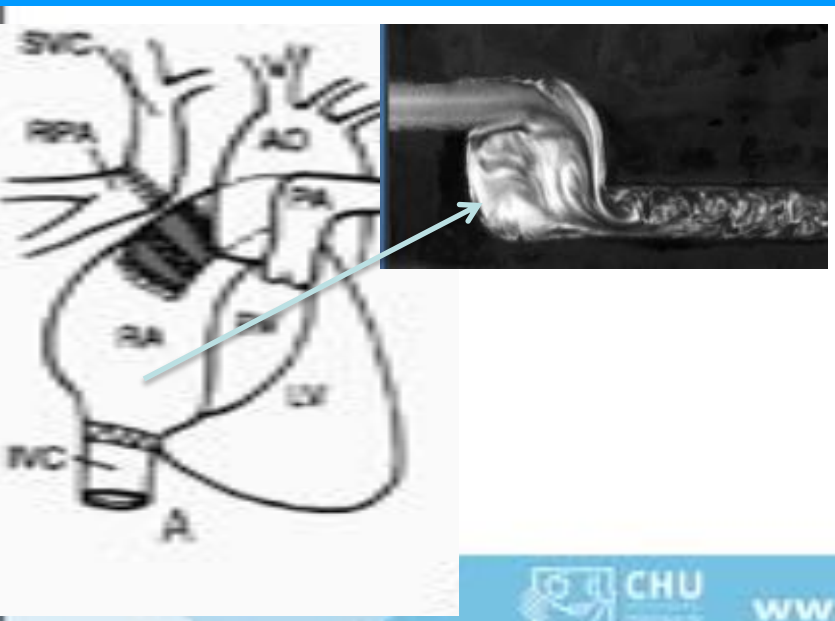

2015

Choussat's ten commandments REVISITED

Sinus rhythm

Mean pulmonary artery pressure<15 mm Hg
Pulmonary arteriolar resistance<4 Wood units/m2

Left-ventricular ejection fraction>0.60

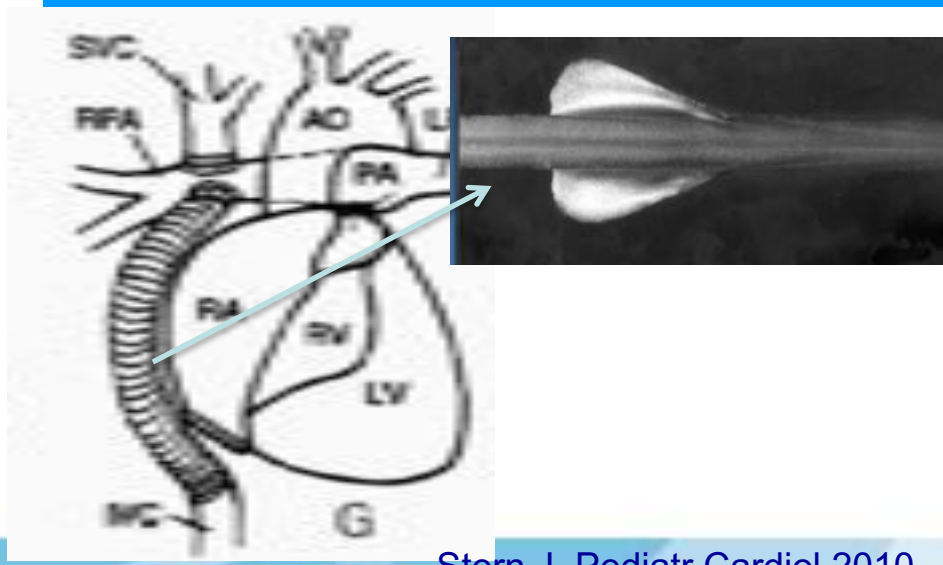

Stern J. Pediatr Cardiol 2010
Kilner P. CITY 2005

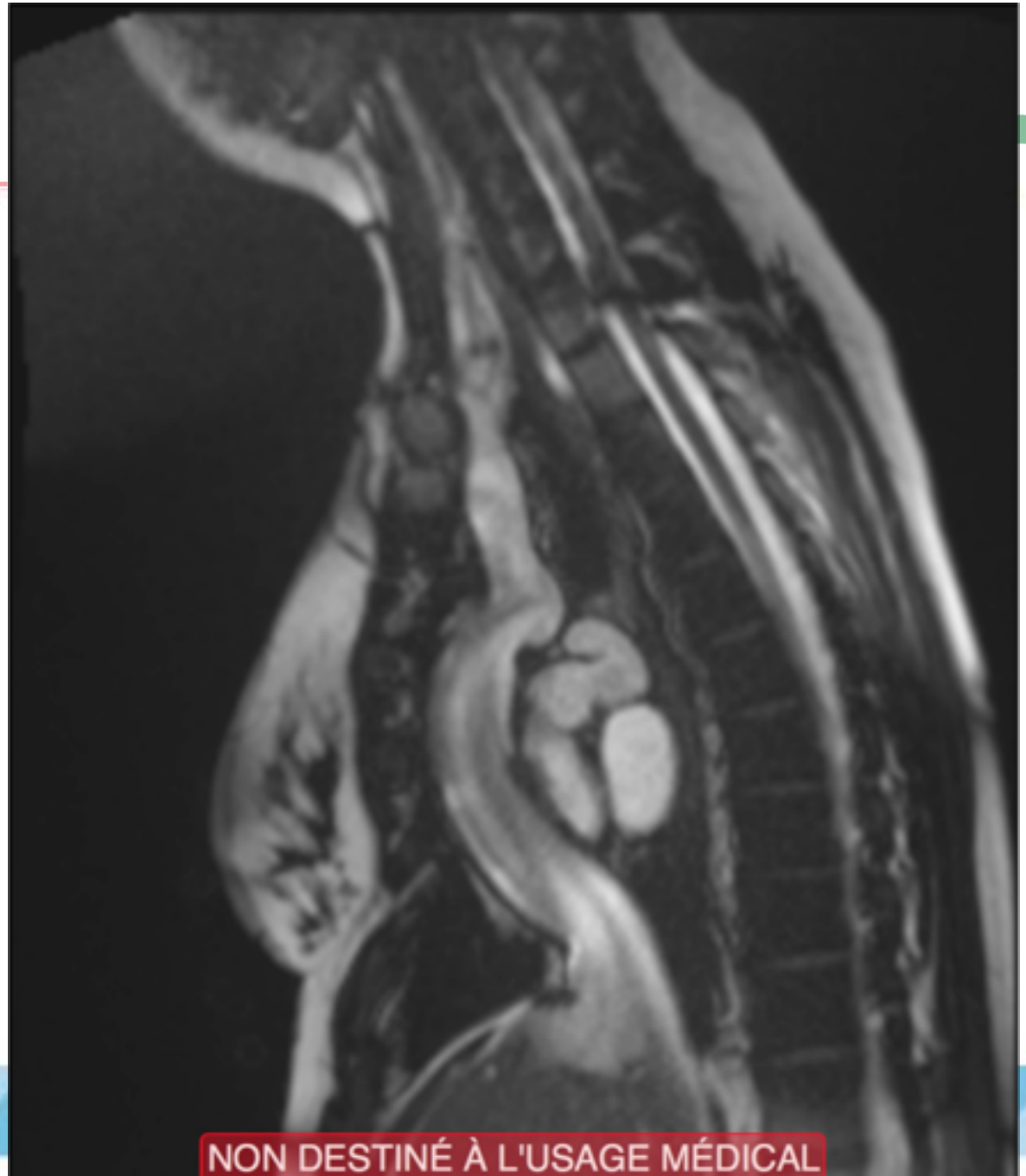
NON DESTINÉ À L'USAGE MÉDICAL

Goal of pre Fontan surgical management

- Balance aortic / pulmonary blood flow
- Optimize PA growth
- Protect from pulmonary vascular disease
- Surgical timing: limit the period of ventricular overload

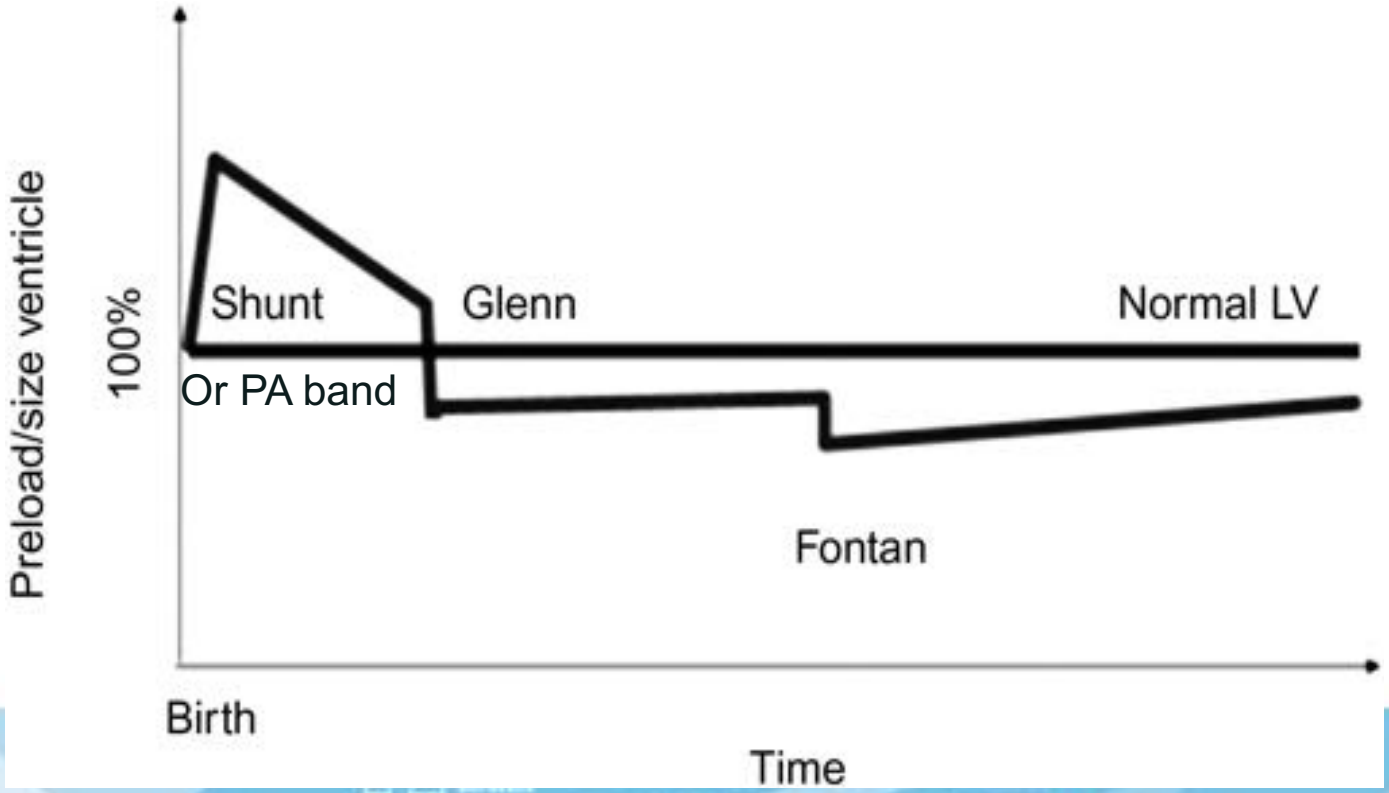

Early palliative approach: systemic to pulmonary shunt or banding

First months of life

volume overload (by PA band or SPS)

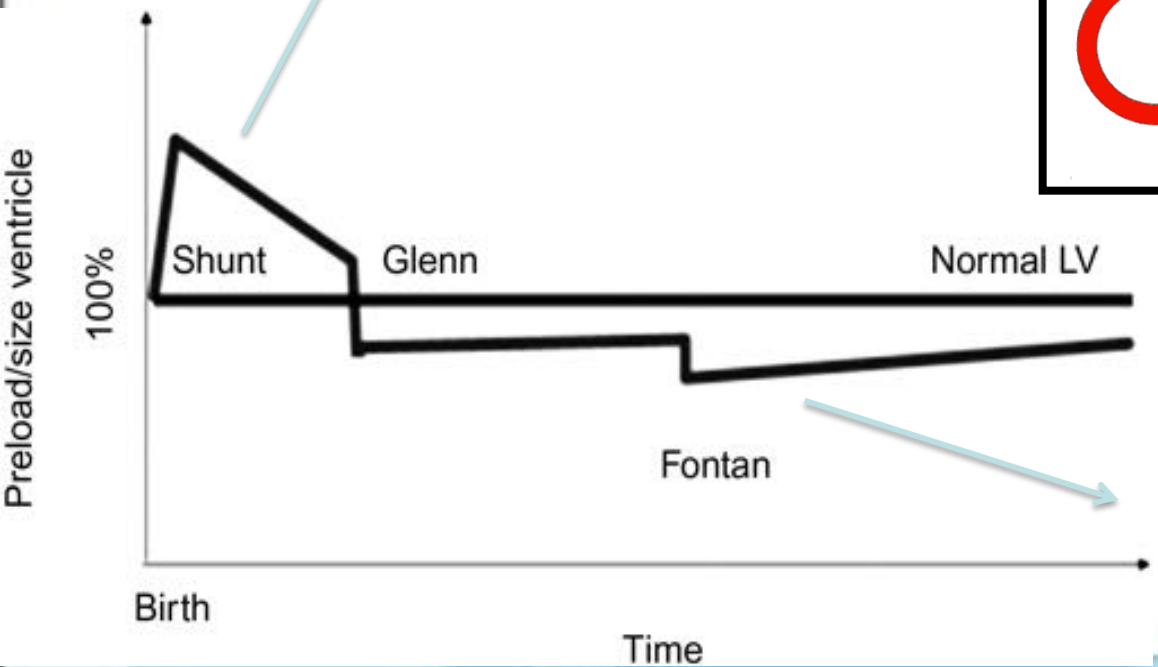



Fontan (TCPC)

Reduced preload (below normal)

Reduced compliance

Poor ventricular filling

Single ventricule physiology

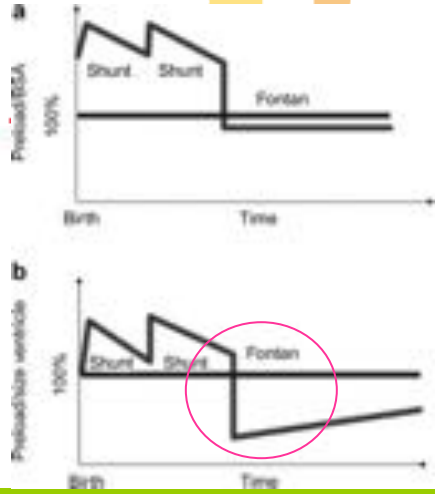

From 1971, emphasis shifted towards reducing the volume load of the ventricle

palliation for UVH in the 1950–1970s
-large systemic to pulmonary artery (PA) shunts for adequate long-term relief of cyanosis
-The dictum was: as pink as possible for as long as possible
-The enormous volume overload of the lungs: satisfactory relief of cyanosis, but significant ventricular dysfunction, congestive HF and PAH
-few survivors beyond the 4th decade

From 1990: The staged palliation with early placement of a partial cavopulmonary Glenn shunt
-further shifted the emphasis to limitation of volume load as early as possible.
-This strategy allowed the neonatal shunt to become smaller, typically lasting only a couple of months. Results improved even further, paralleled by an improvement of ventricular function

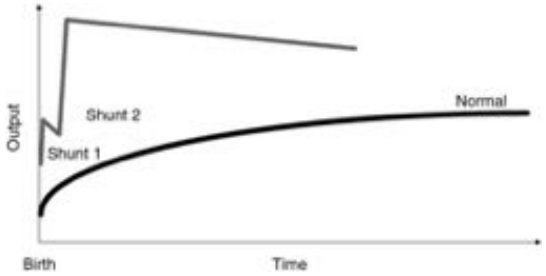

The dictum has become: as blue as possible in order to keep the ventricle maximally unloaded.

good ventricular function, but suffer from poor function of the Glenn shunt (significant cyanosis, congestion in upper body), and have an even worse Fontan circulation with low output and significant congestion

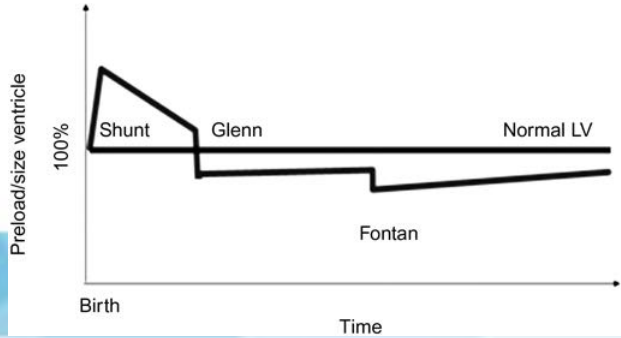

SV with high pulmonary blood flow: PA banding

- SV-PA gradient: cw doppler (SAX/A4C)
- Pulmonary valve regurgitation: 2D/ color doppler
- Migration of PA banding: pulmonary branch distortion (RPA)

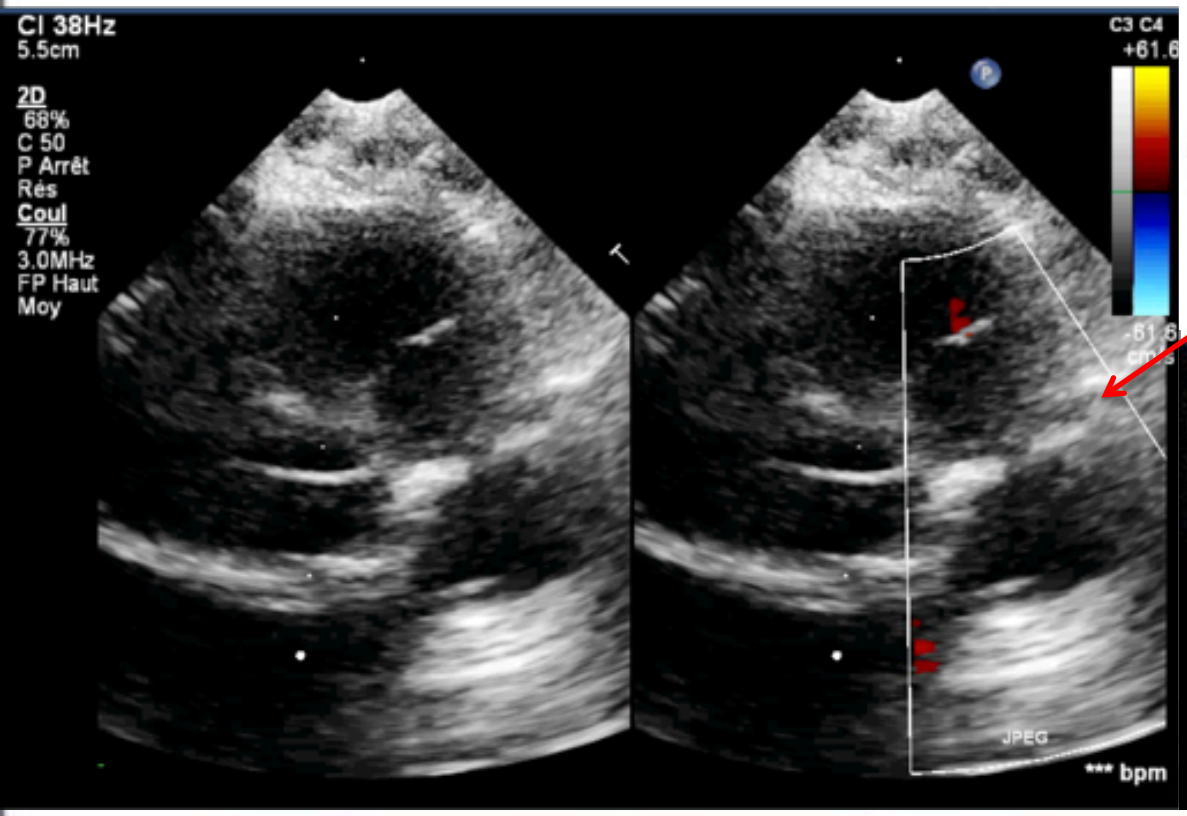

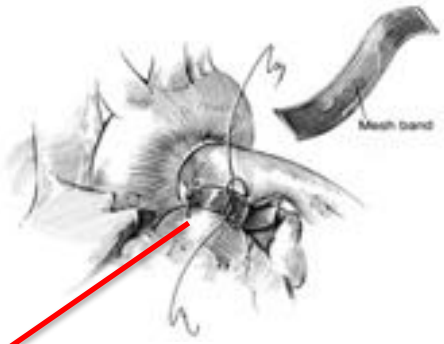

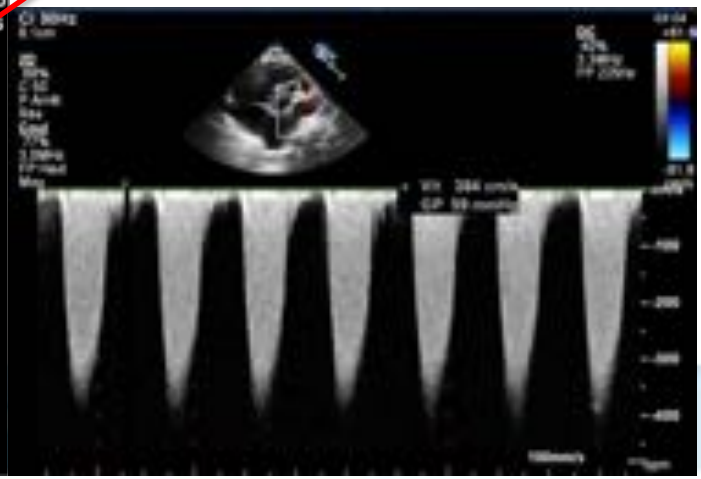

SV with low pulmonary blood flow: SPS



- First SPS: direct connection between SCA (CBTS)/ Ao (Waterston) and PA
  - Unpredictibility of shunt flow
  - PA branch distortion

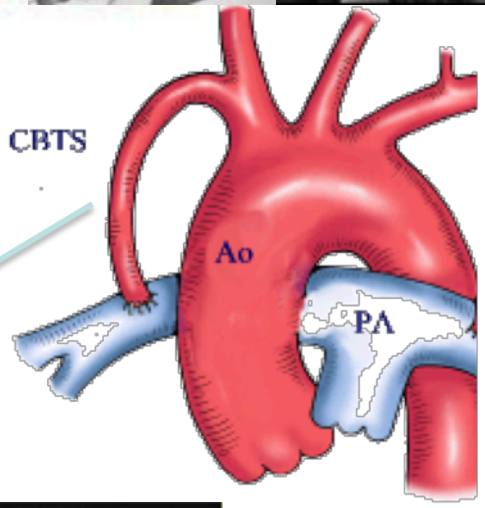

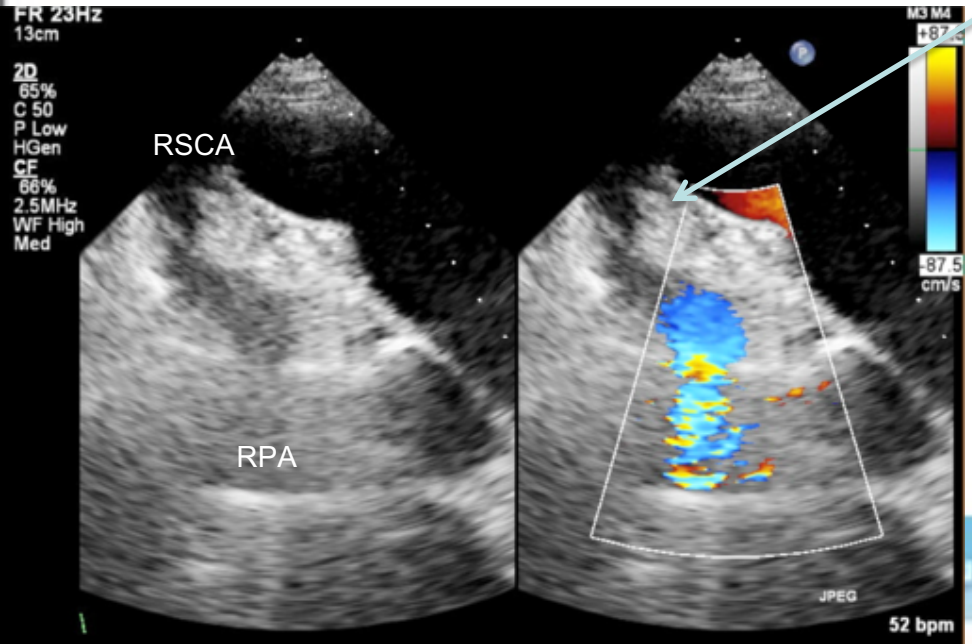

Systemic to pulmonary shunt

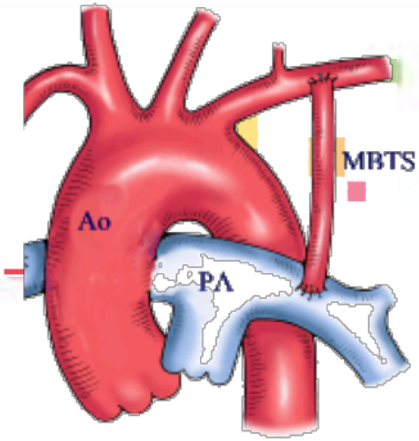

- Current modified BT shunt: prosthetic PTFE graft
- Innominate artery or SCA connected to ipsilateral PA branch

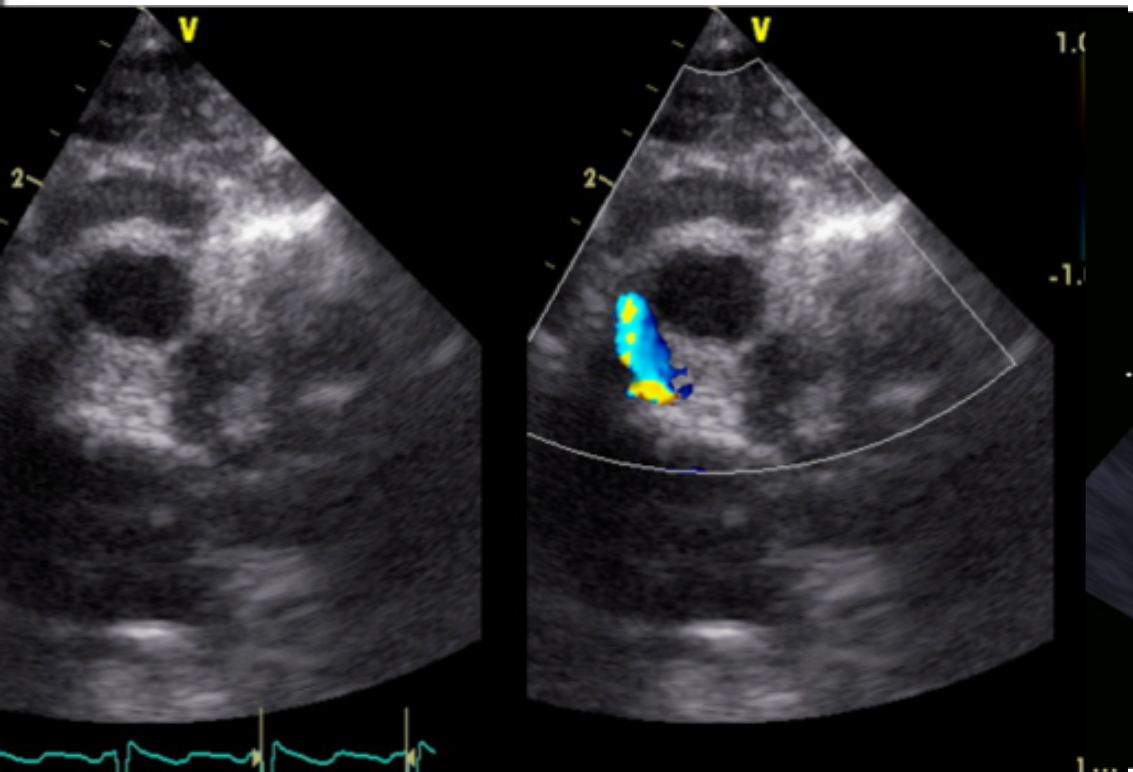

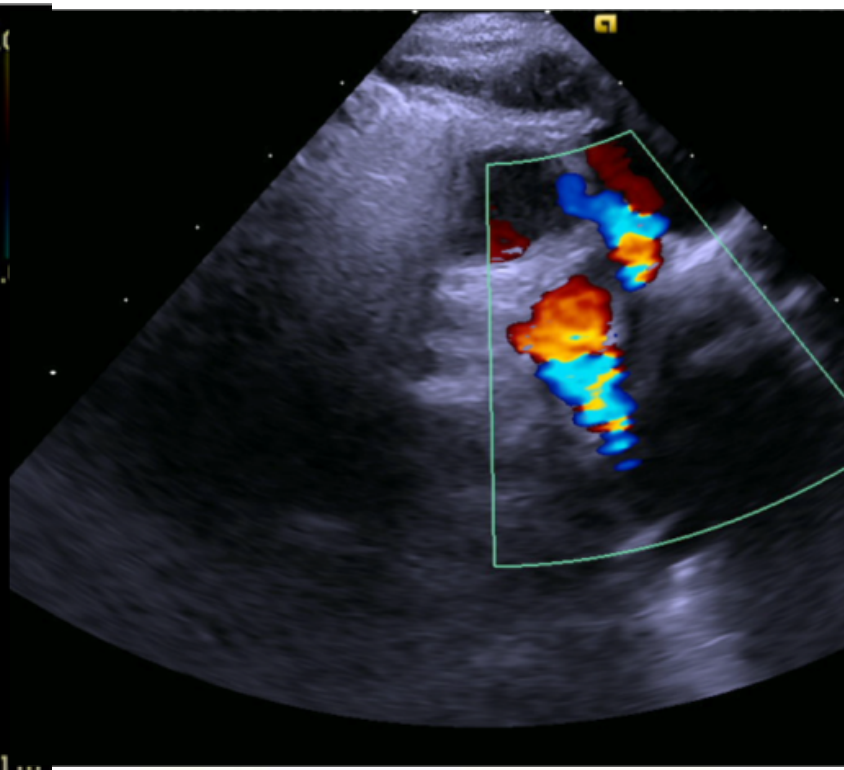

Systemic to pulmonary shunt

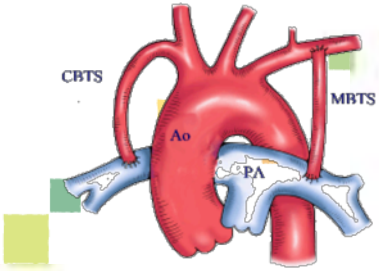

- Imaging: CW doppler: characteristic sawtooth doppler pattern

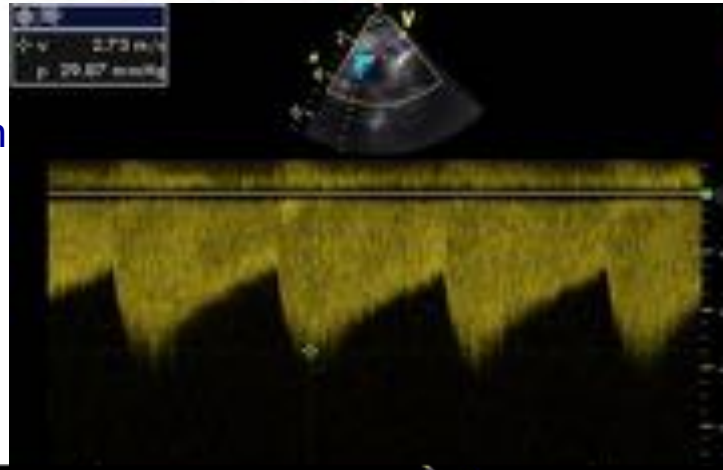

- Potential anomalies: distortion of inn Artery or PA branch, narrowing of prox or distal anastomosis (challenging)

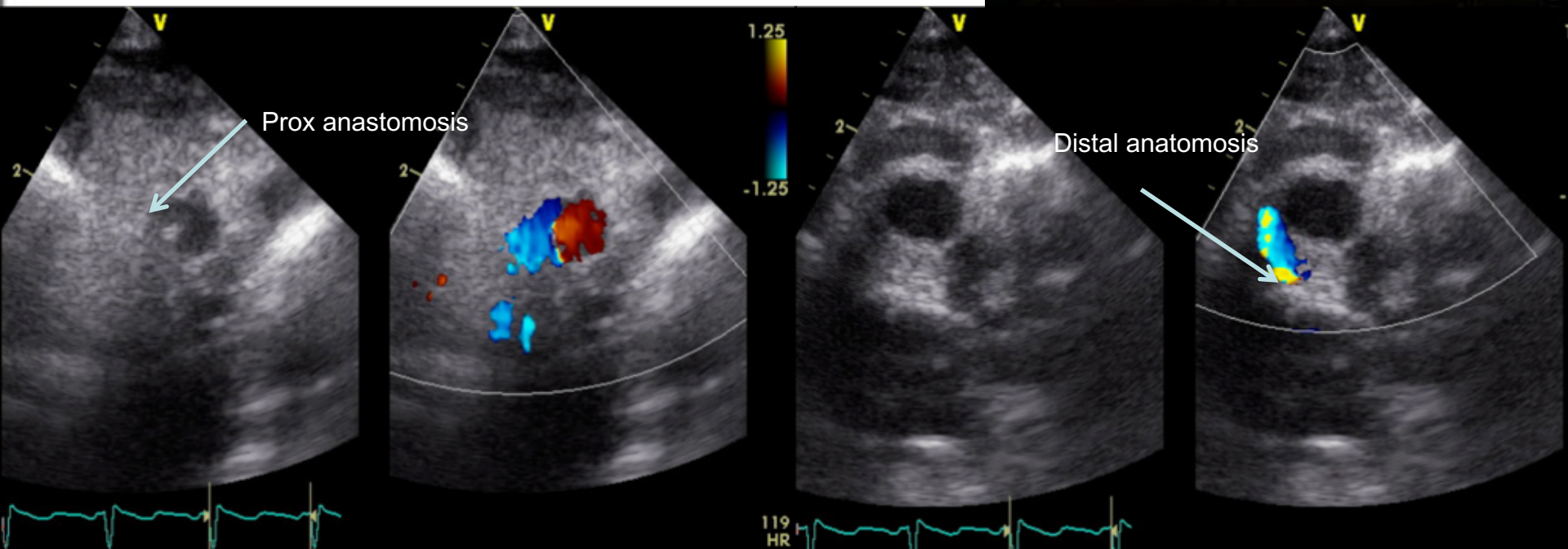

The Fontan circulation: stage 1

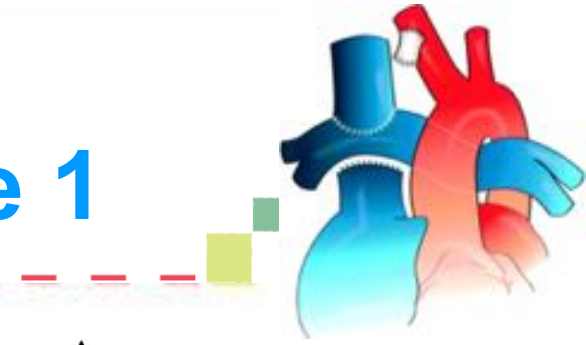

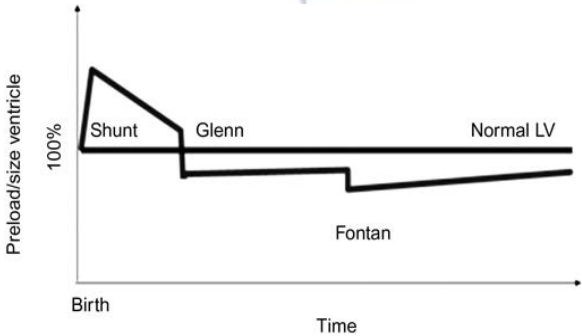

- Staged approach
- Stage 1: BCPC – Glenn procedure
  - Routing SVC blood flow to pulmonary circulation
  - More desaturated blood shunted to the lungs
  - Diversion of 1/3 of the SVR to the lungs
  - Reduction of SV volume overload

Echocardiographic assessment

1. Cavopulmonary connection

2. Branch PA

Echocardiographic assessment of the Glenn anastomosis

- Suprasternal / high parasternal view
- Laminar flow of low velocity with respiratory variation (adapt the velocity range+++)
- Rule out stenosis at the anastomosis site

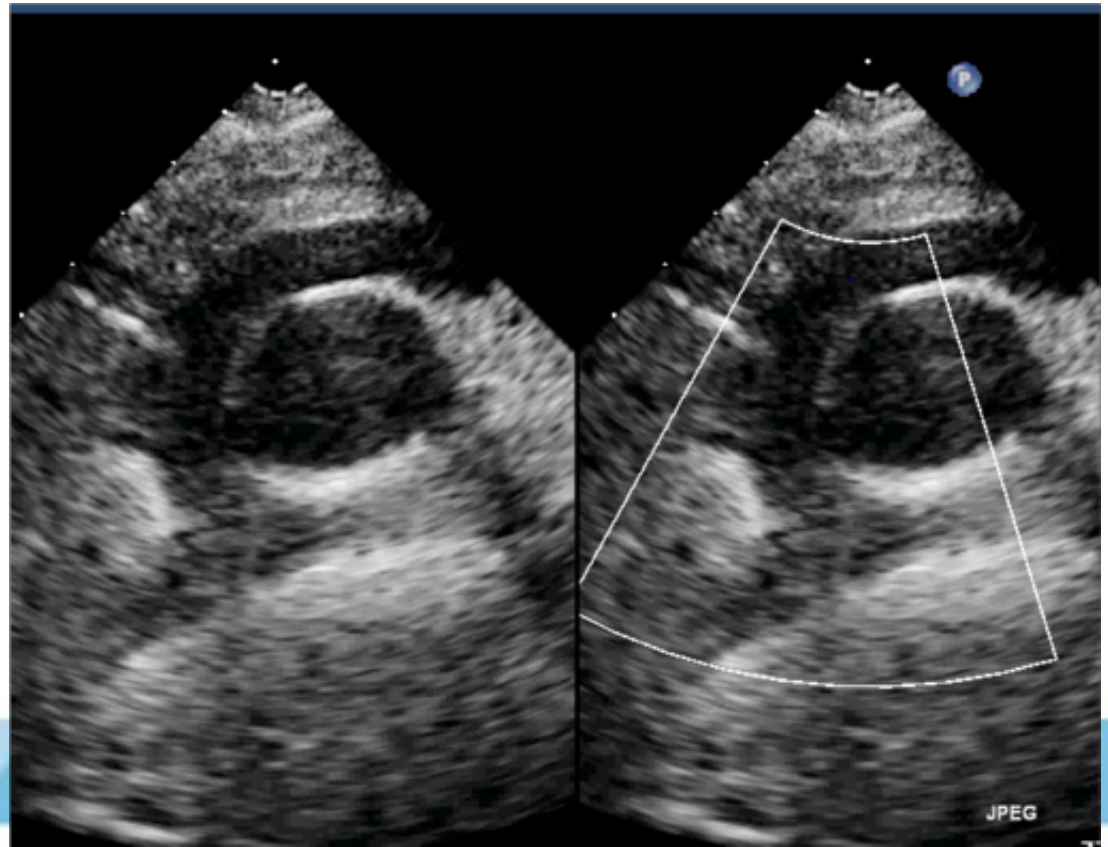

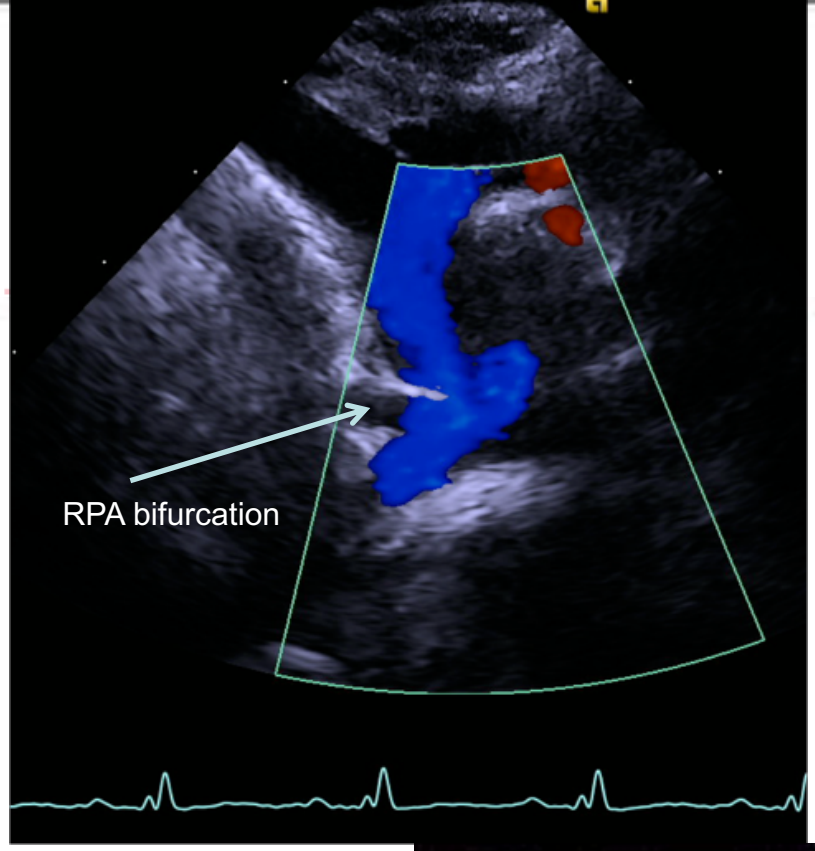
RPA bifurcation

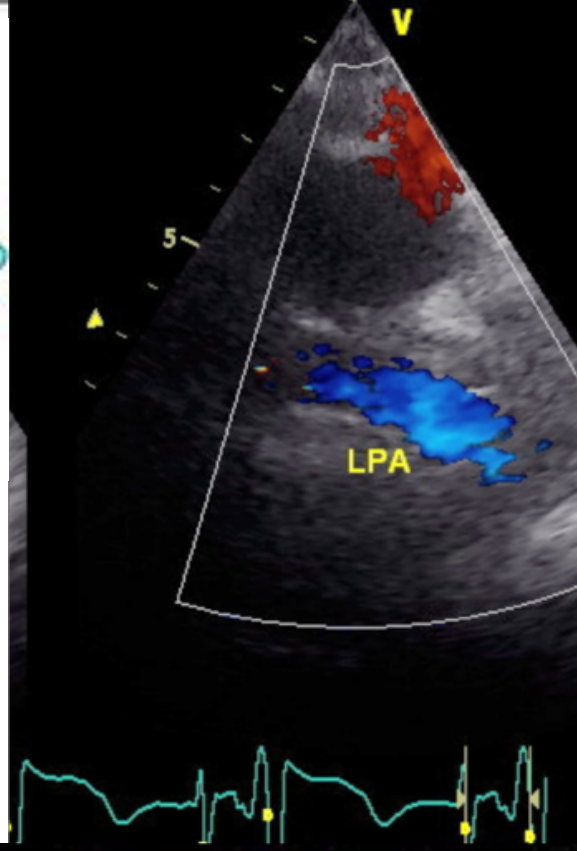
V
5
LPA

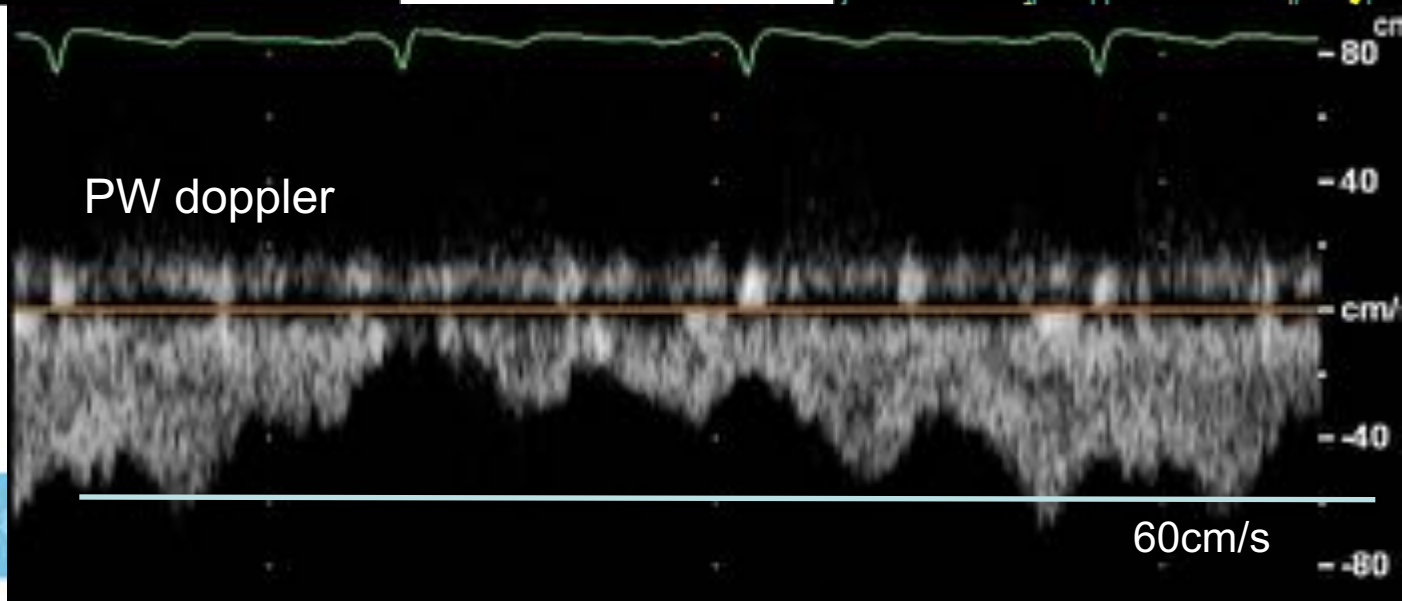
PW doppler
80
40
cm/
-40
-80
60cm/s

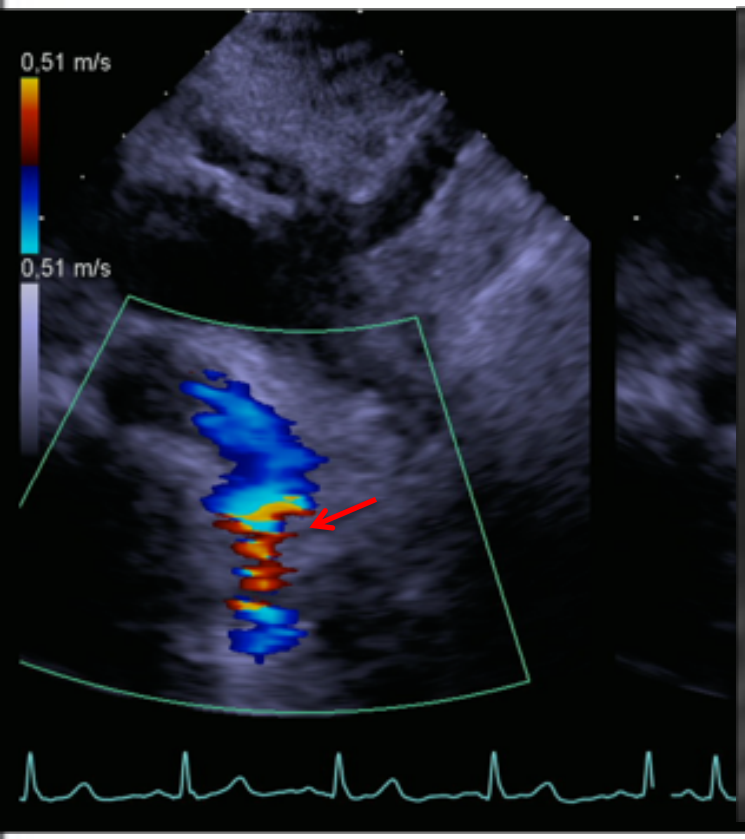
0,51 m/s
0,51 m/s

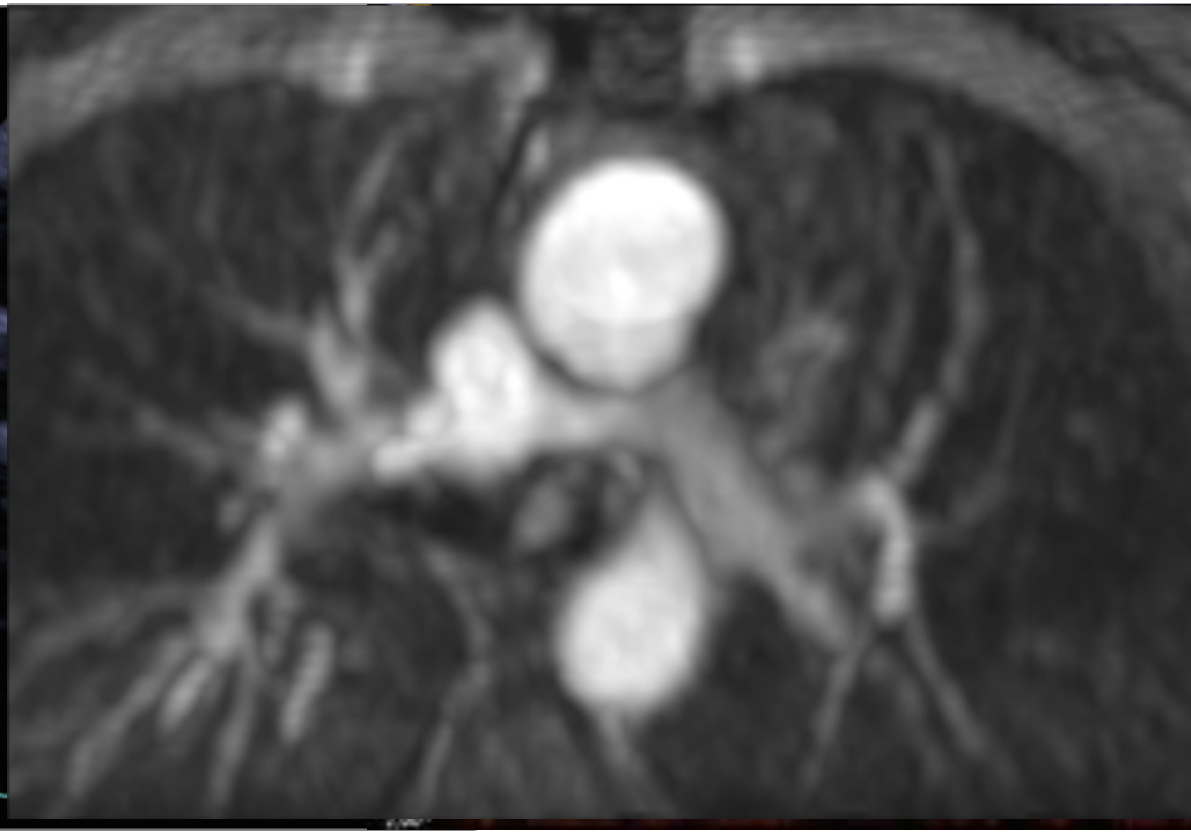

Pulmonary arteries

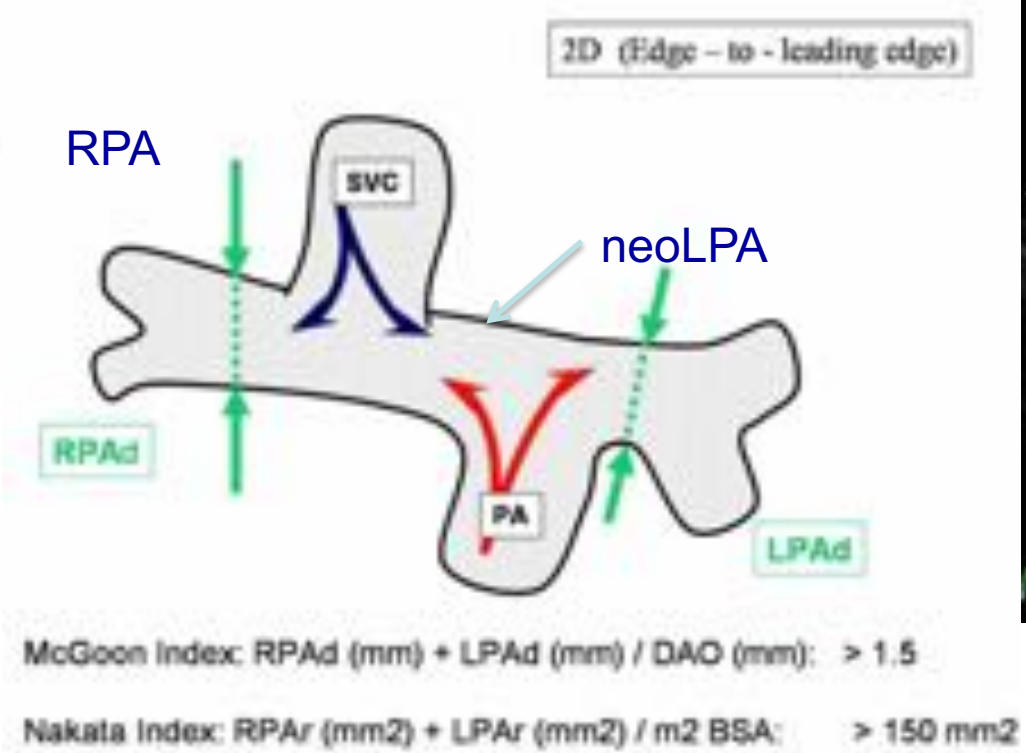

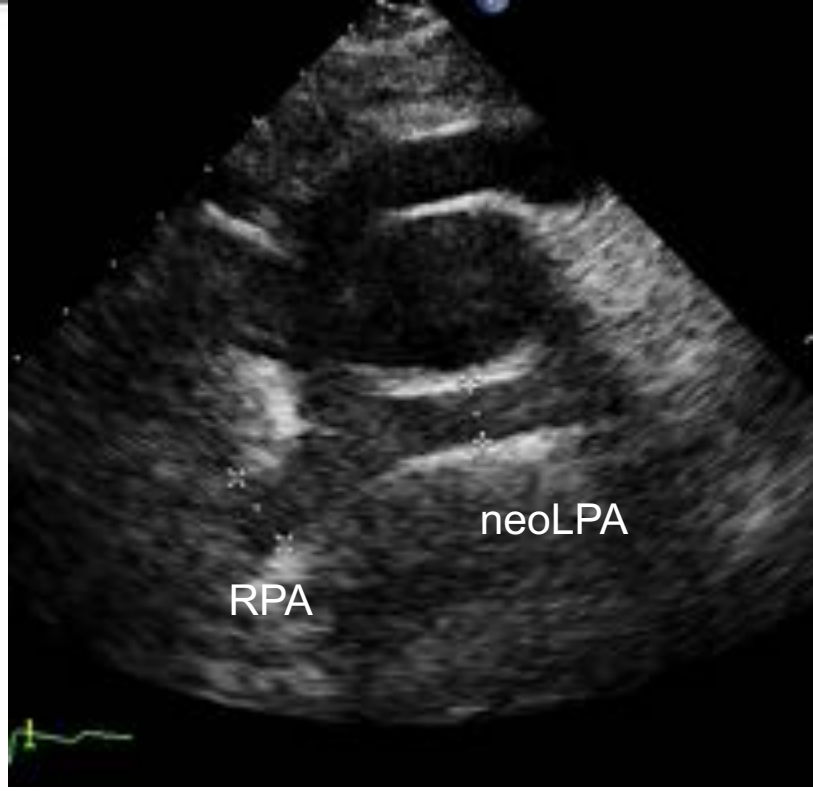

- Potential PA branch distortion following early palliative surgery
  - SPS / Banding
  - DKS (LPA hypoplasia or stenosis)

Pulmonary vascular growth

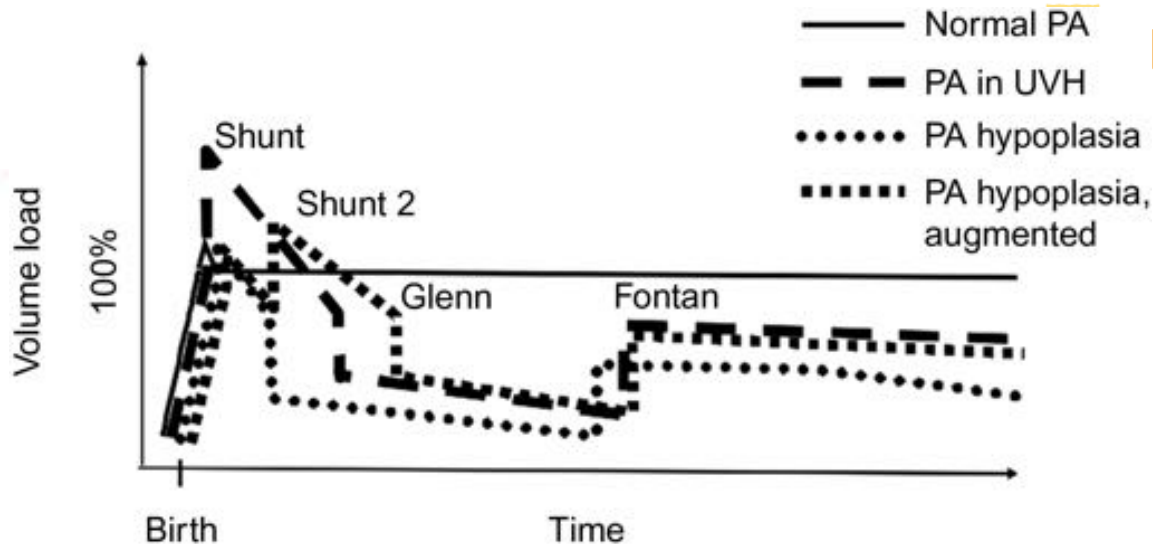

- Decrease of PA index after BDG
  - Relation with decrease amout of blow flow
  - Absence of pulsatile flow
- Adaptive remodeling?
- No definite cut-off
- Multiparametric assessment including
  - mPAP, PVR, PA size
  - SV and AVV function

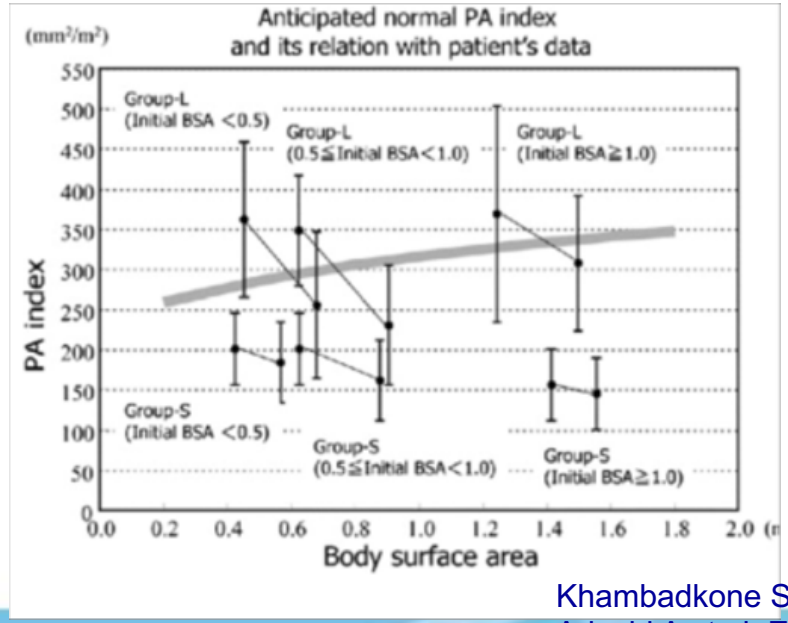

Khambadkone S. Ann Pediatr Cardiol. 2008
Adachi A et al. Eur J cardvasc S 2007

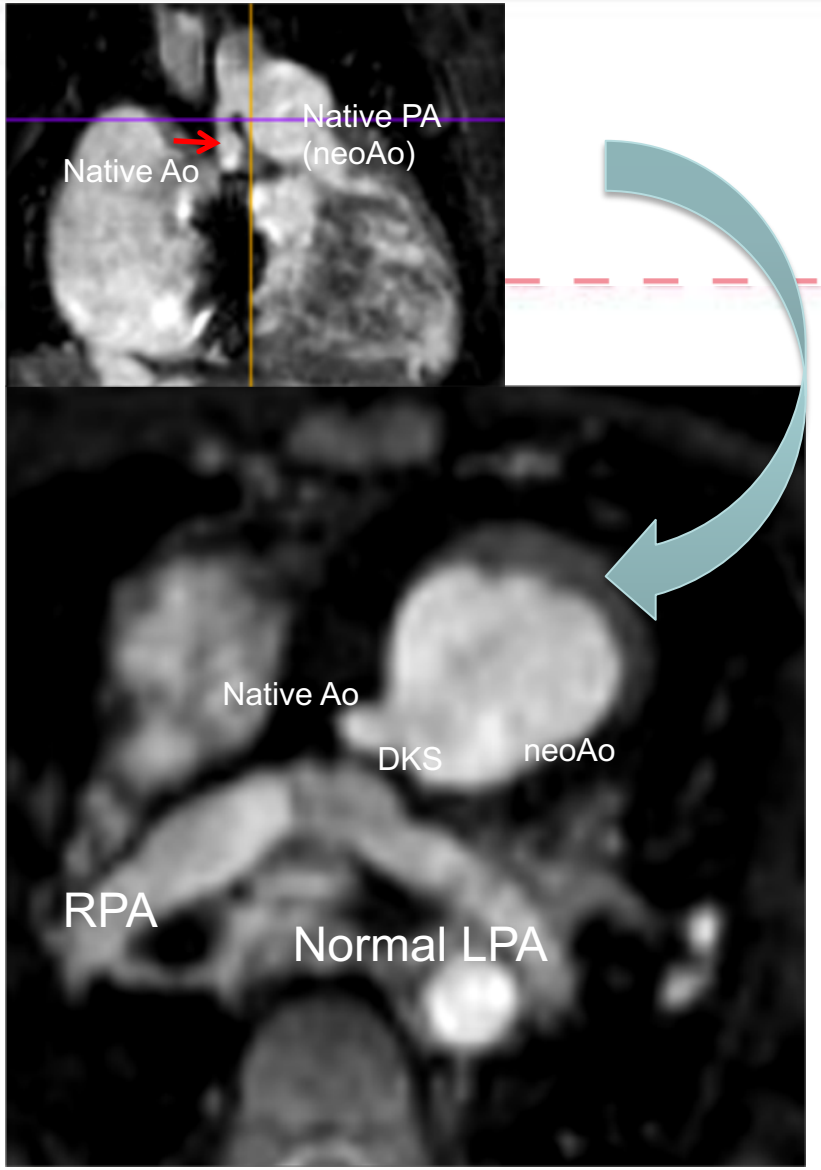

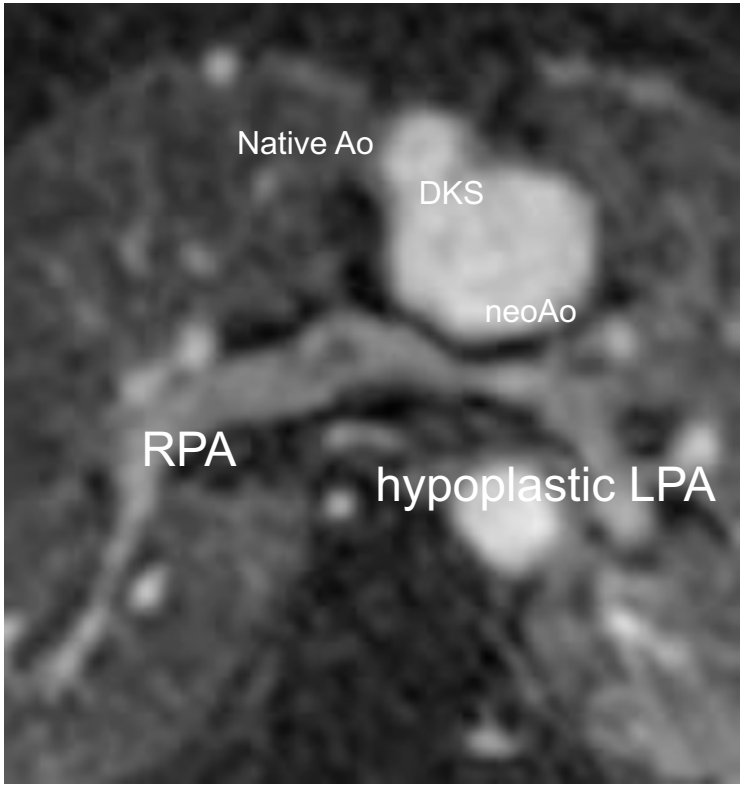

Look at the portion of the PA behind the reconstructed neo aorta

Pulmonary artery branches and BCPC

- Risk of LPA stenosis post Norwood procedure

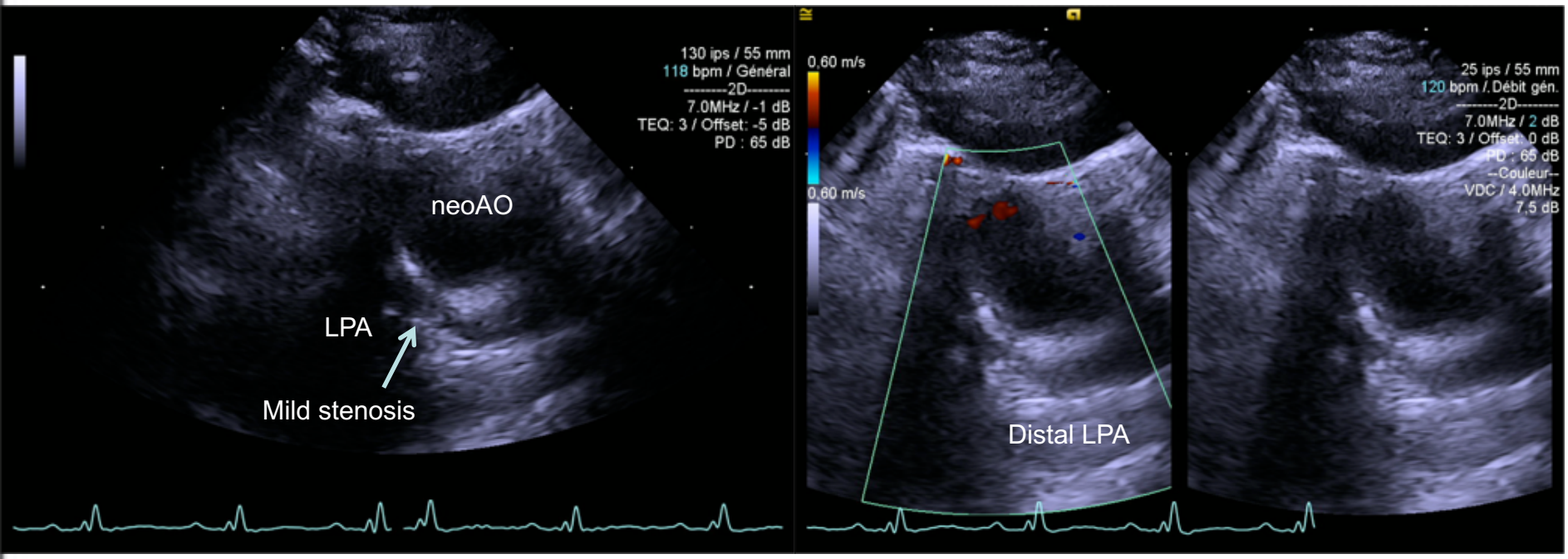

Abnormal cyanosis after BCPC

- Reopening of decompressing veins from SVC

- In the IVC: azygos vein
- In the atria: left SVC
- Diagnosis:
  - Suprasternal frontal view
  - color doppler/ saline contrast

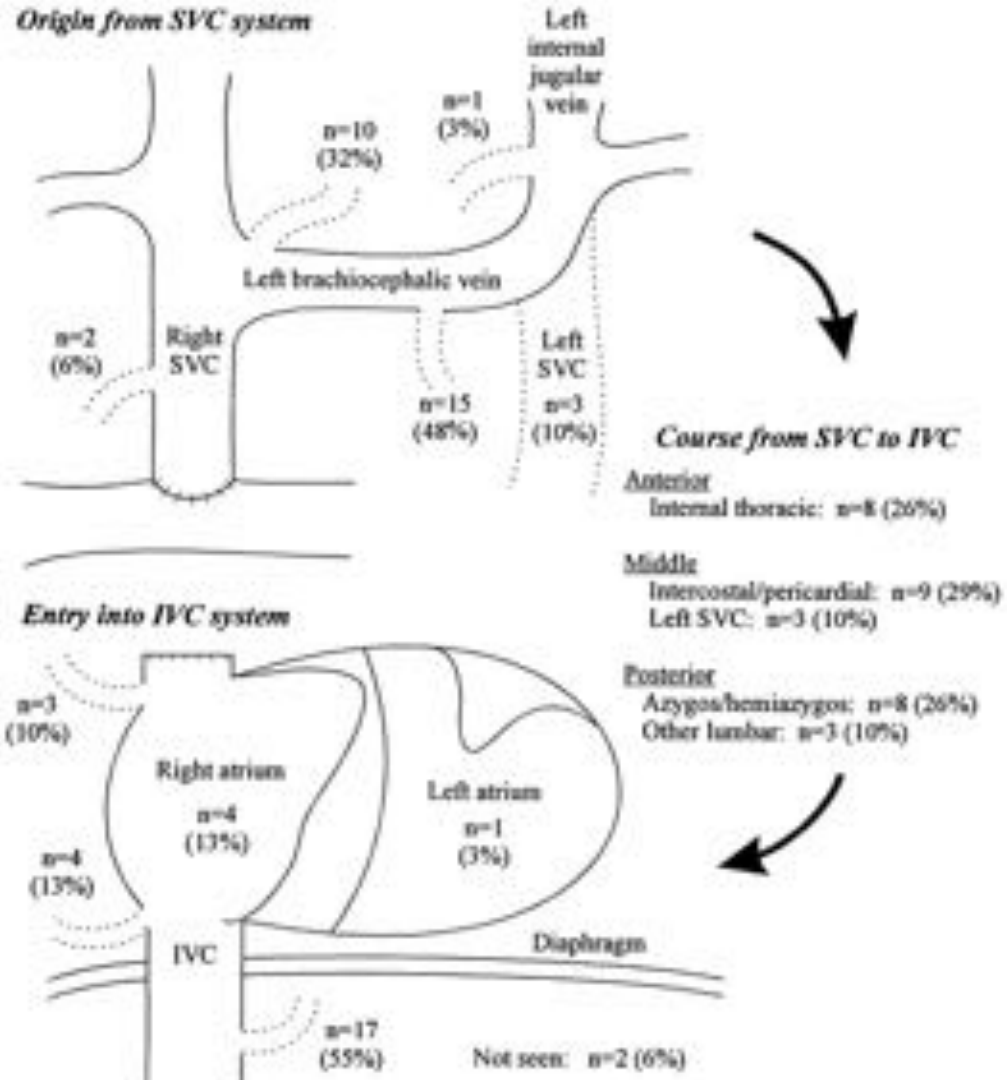

Abnormal cyanosis after BCPC

- Pulmonary AV malformations
  - heterotaxy syndrome
  - Lack of hepatic factor
  - Diagnosis: saline contrast

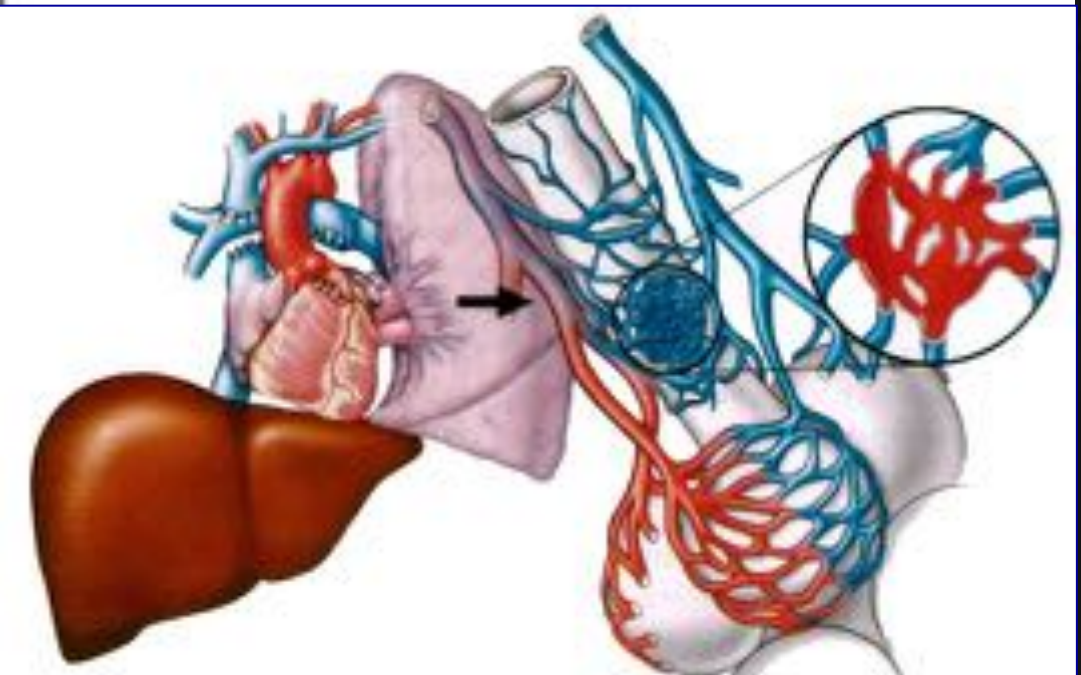

The Fontan circulation stage 2: TCPC

- SVC and Glenn anastomosis
- IVC to PA conduit assessment
- Conduit fenestration
- IVC and HV flow
- Thrombus in the Fontan pathway

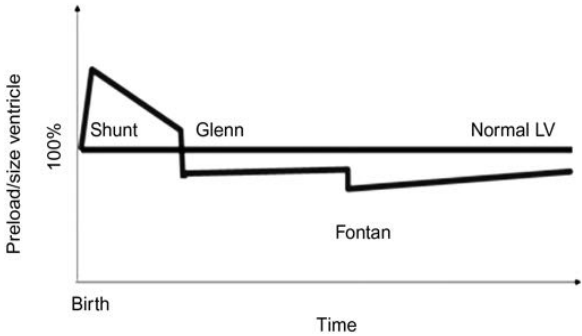

TCPC

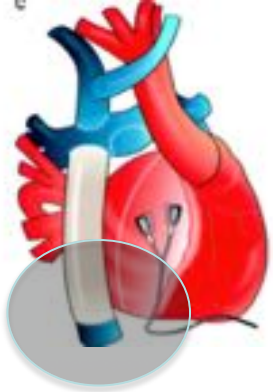

Proximal connection subcostal views

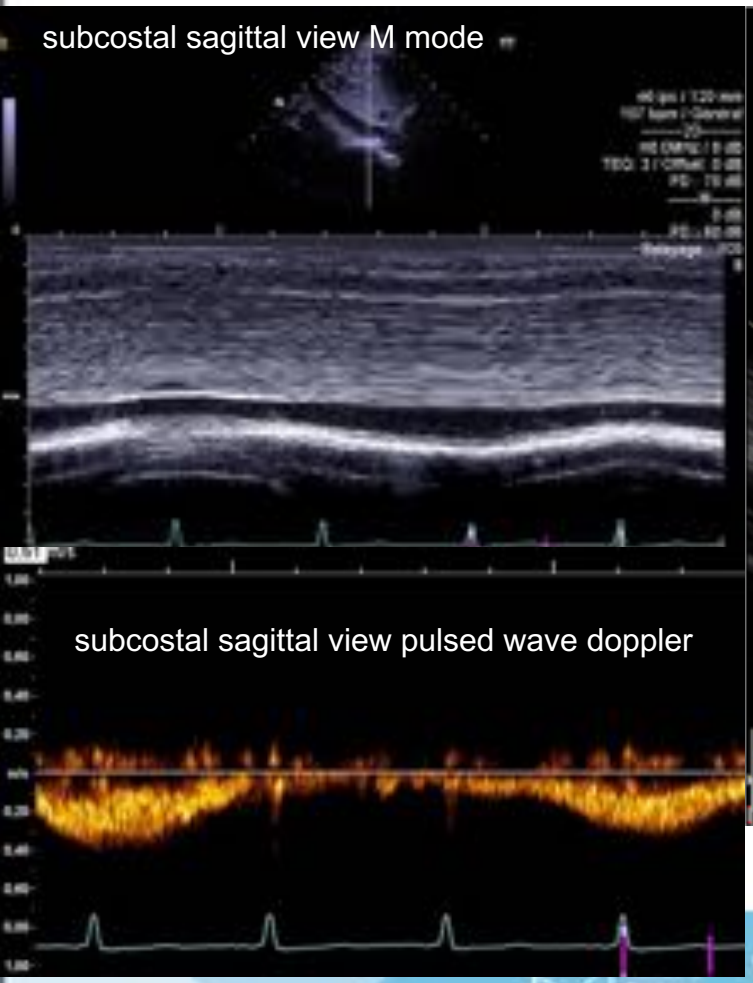

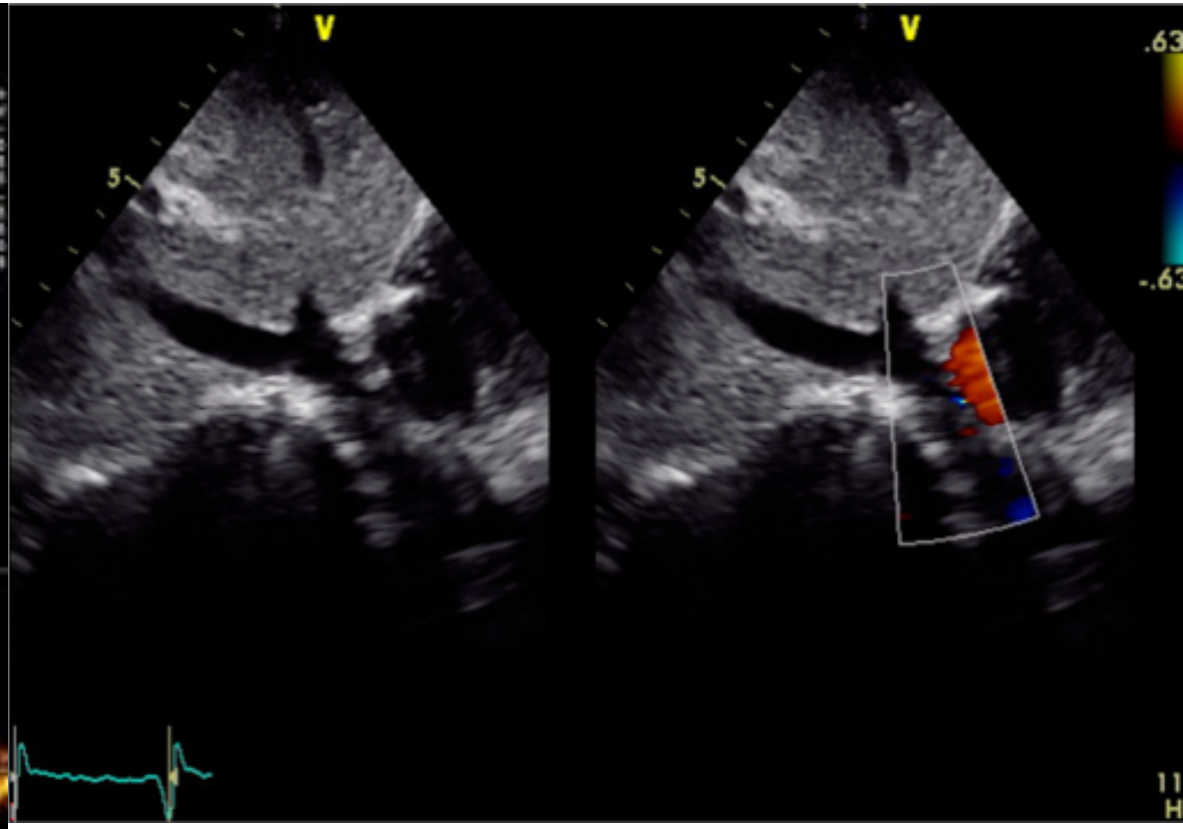

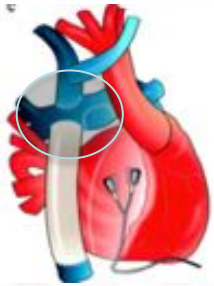

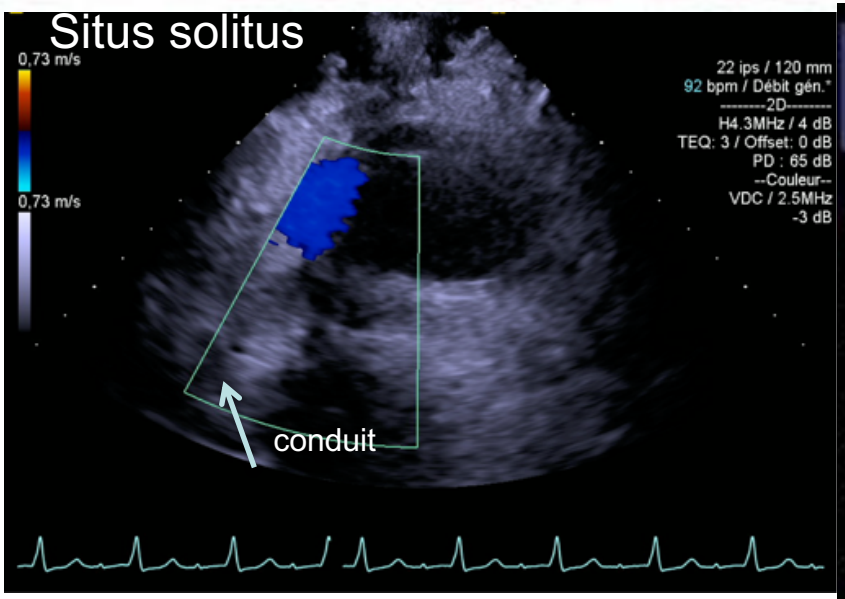

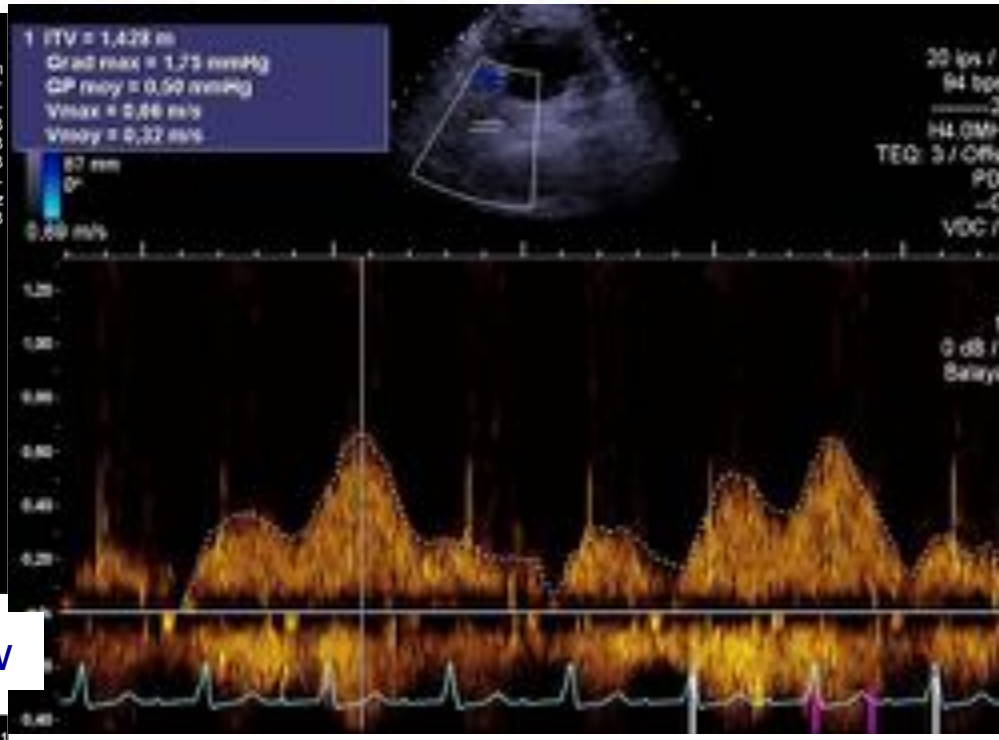

Distal connexion high parasternal view

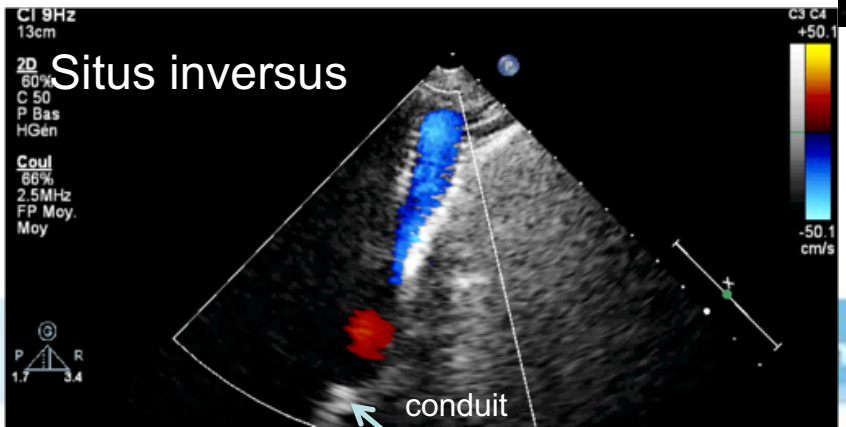

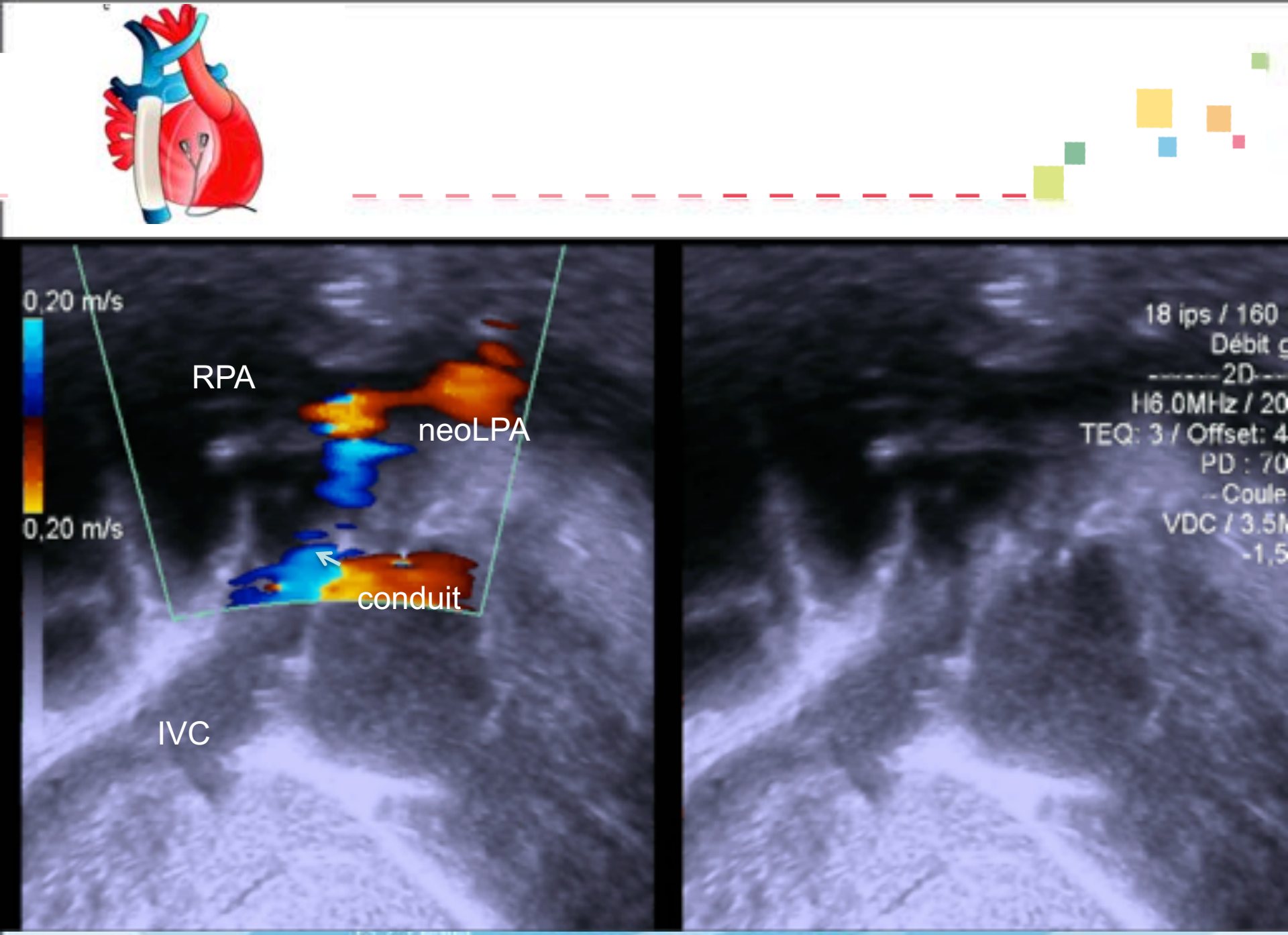
0,20 m/s
RPA
neoLPA
0,20 m/s
conduit
IVC
18 ips / 160
Débit g
2D
H6.0MHz / 20
TEQ: 3 / Offset: 4
PD : 70
Coule
VDC / 3.5M
-1,5

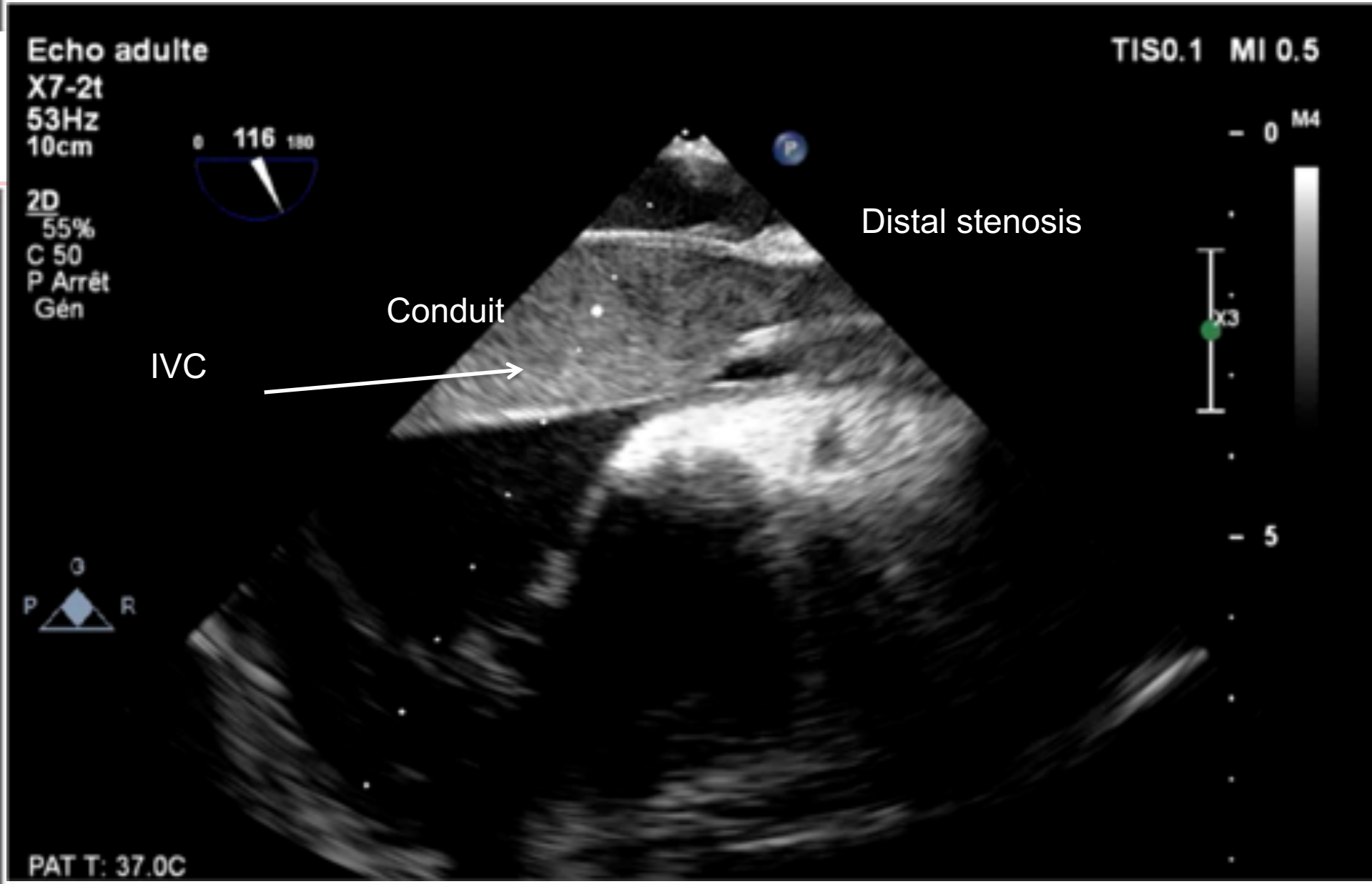
Echo adulte
X7-2t
53Hz
10cm
2D
55%
C 50
P Arrêt
Gén
116
TIS0.1 MI 0.5
M4
Distal stenosis
Conduit
IVC
PAT T: 37.0C

Fenestration assessement

- Right to left shunt
  - Decompress the systemic venous pathway
  - Maintain cardiac output

AO SaO2 84±6%
Qs:2.4±0.7 l1*min'*m-2
SOT*425±154ml

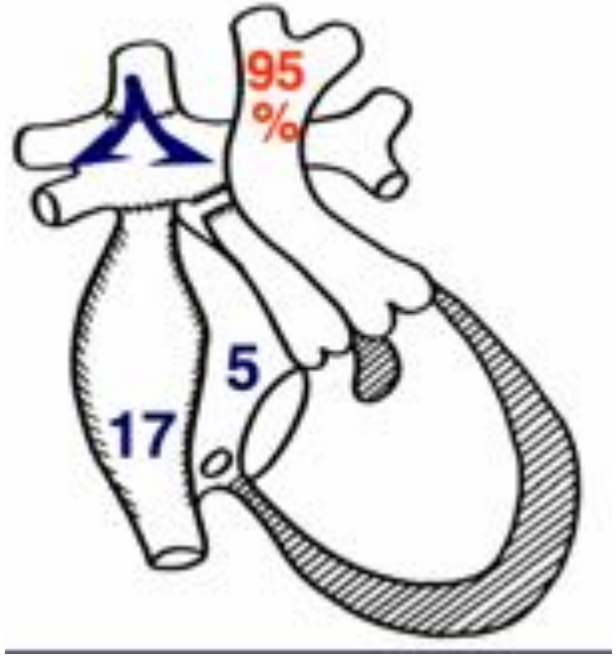

AO SaO2 95±3%
Qs: to1.8+0.4l1*min'*m-2
SOT: 366±112ml

* Systemic oxygen transportation

Hijazi et al. Circulation 1992

Fenestration assessement

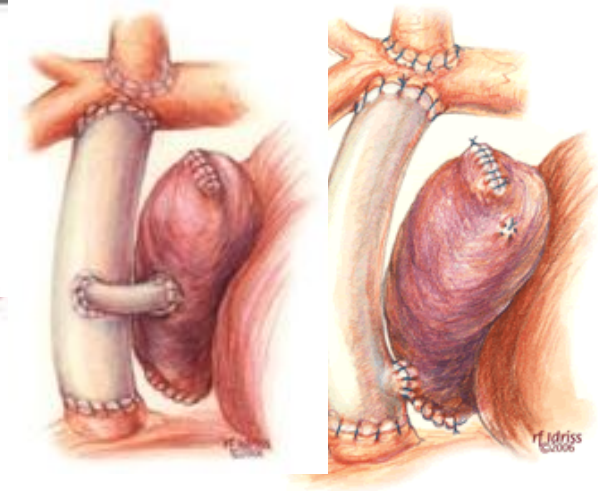

- Transpulmonary gradient
  - Mean gradient over several cardiac cycles
  - A4C/ PW doppler

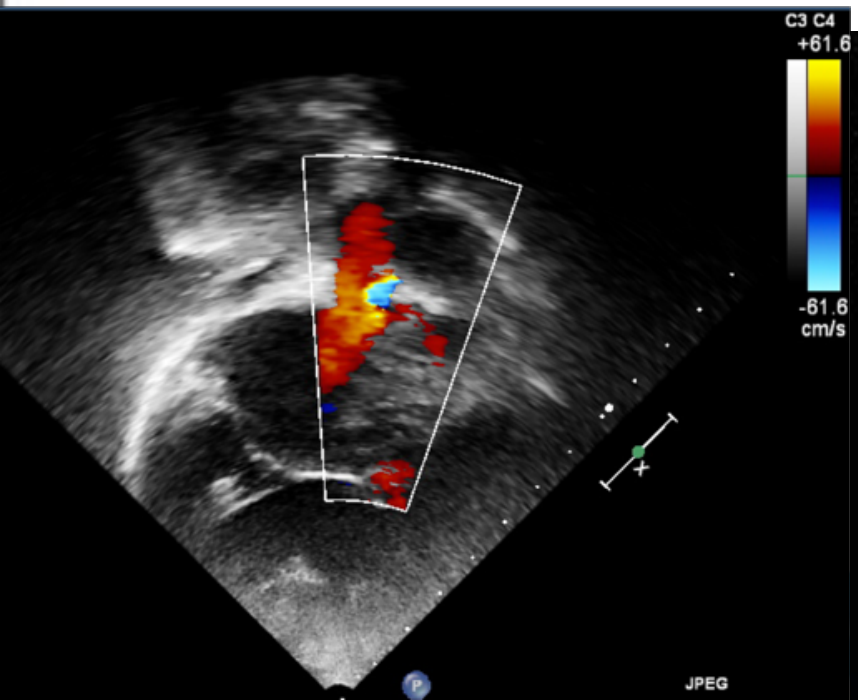

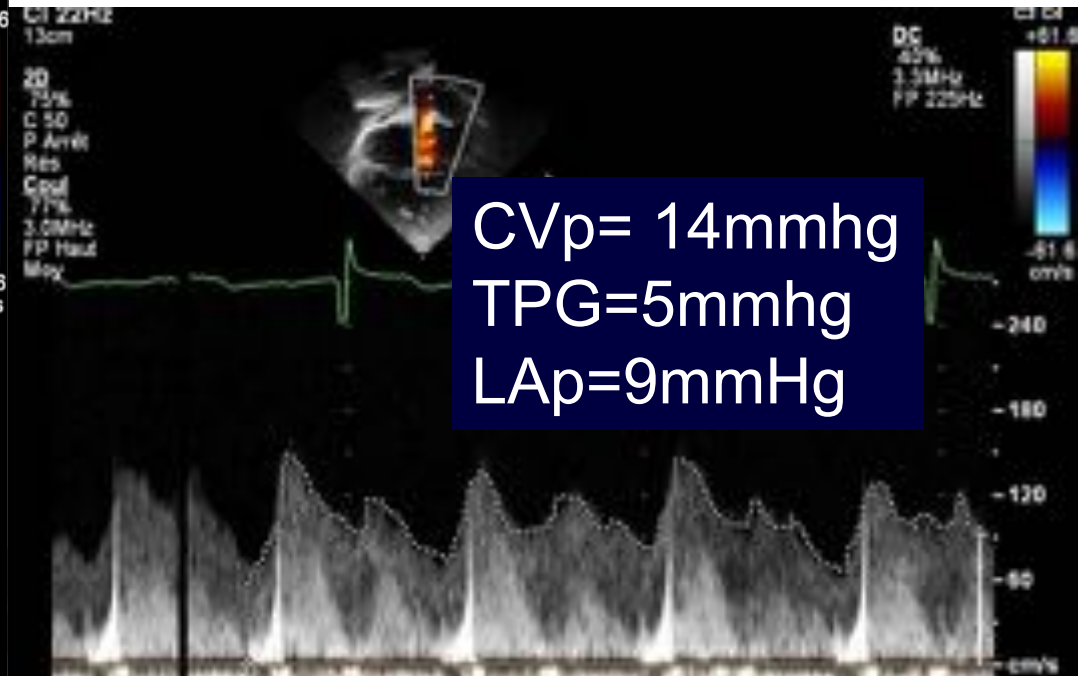


Rythme sinusal
FC
143
Pouls
143
ESV
0
SpO2
89
PA
83/50 (61)
PVC
(17)
CVP
POG
(10)
LA
FR
45
TPG=7mmhg

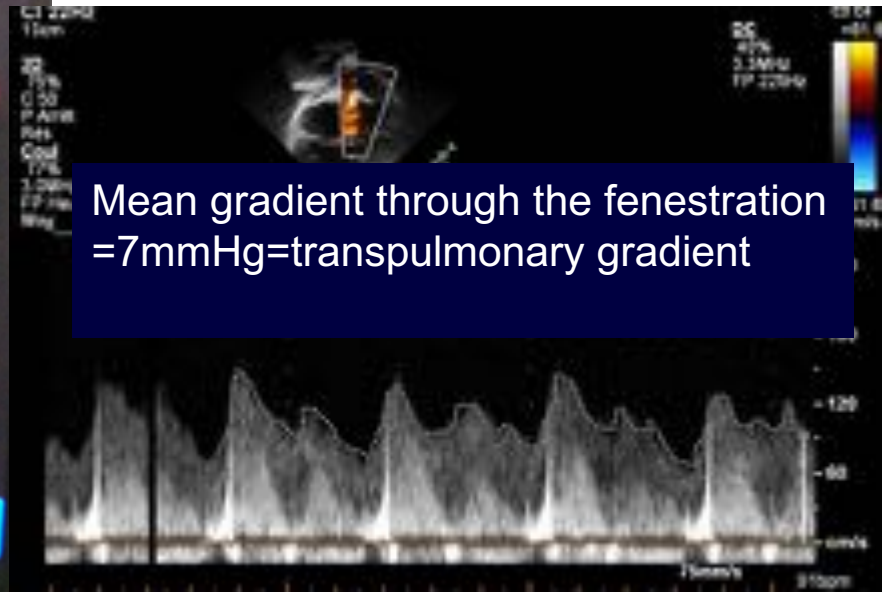
Mean gradient through the fenestration
=7mmHg=transpulmonary gradient

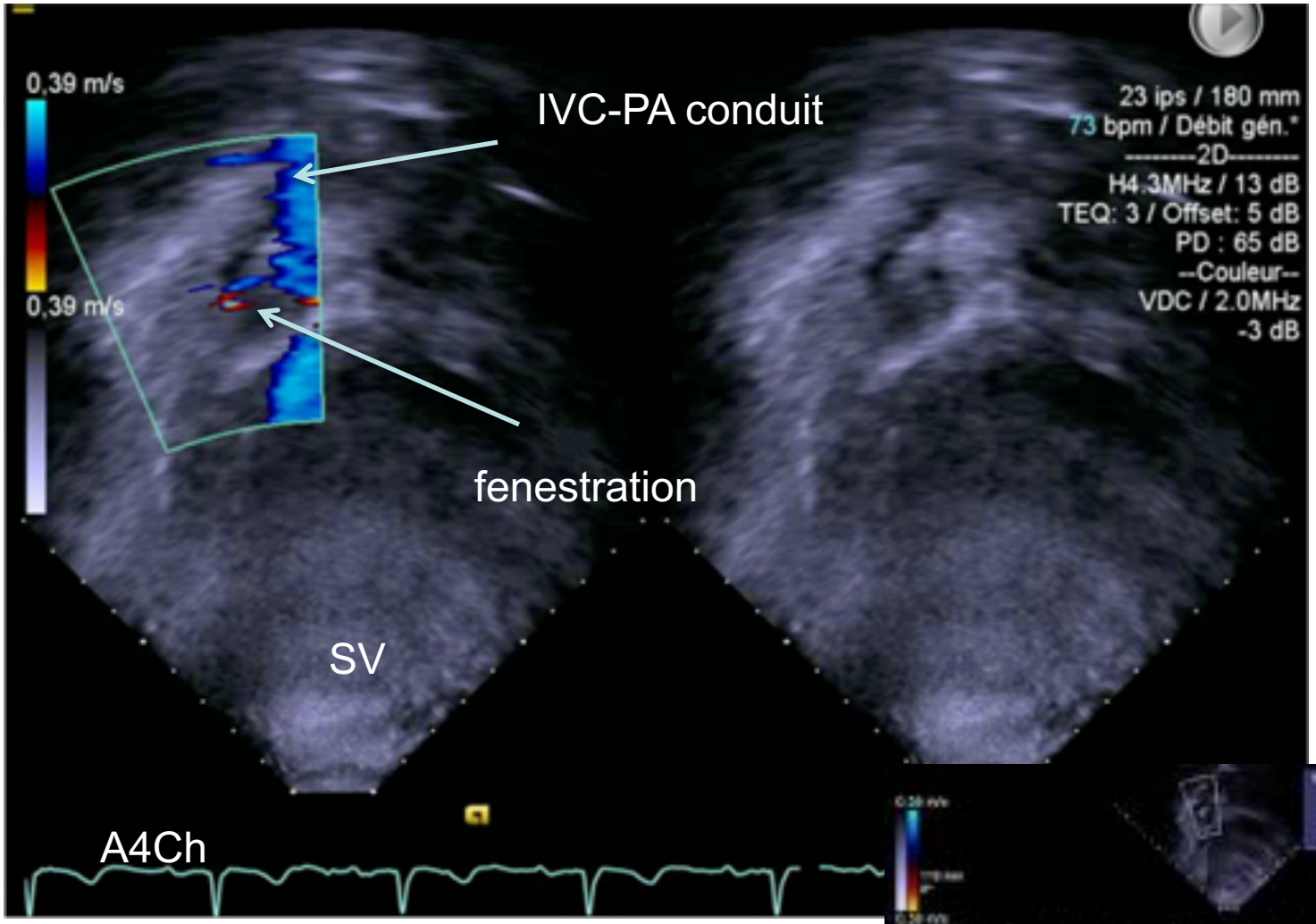
0,39 m/s
0,39 m/s
IVC-PA conduit
fenestration
SV
A4Ch
23 ips / 180 mm
73 bpm / Débit gén.*
--------2D--------
H4.3MHz / 13 dB
TEQ: 3 / Offset: 5 dB
PD : 65 dB
--Couleur--
VDC / 2.0MHz
-3 dB

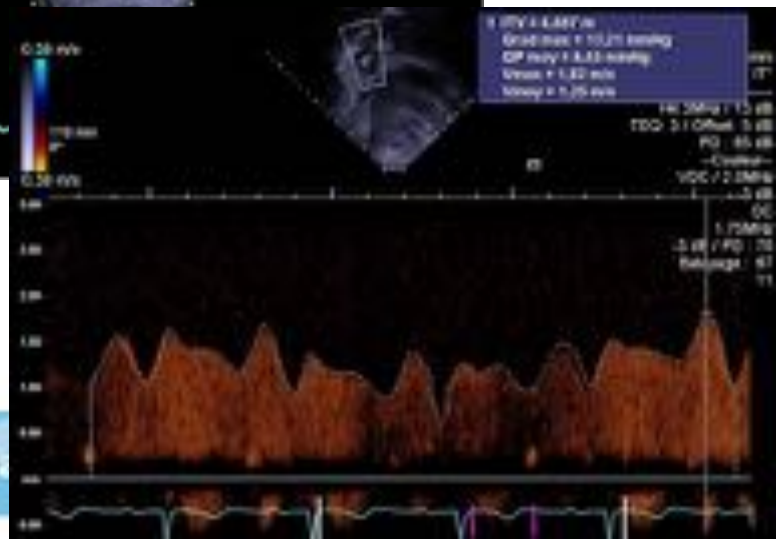

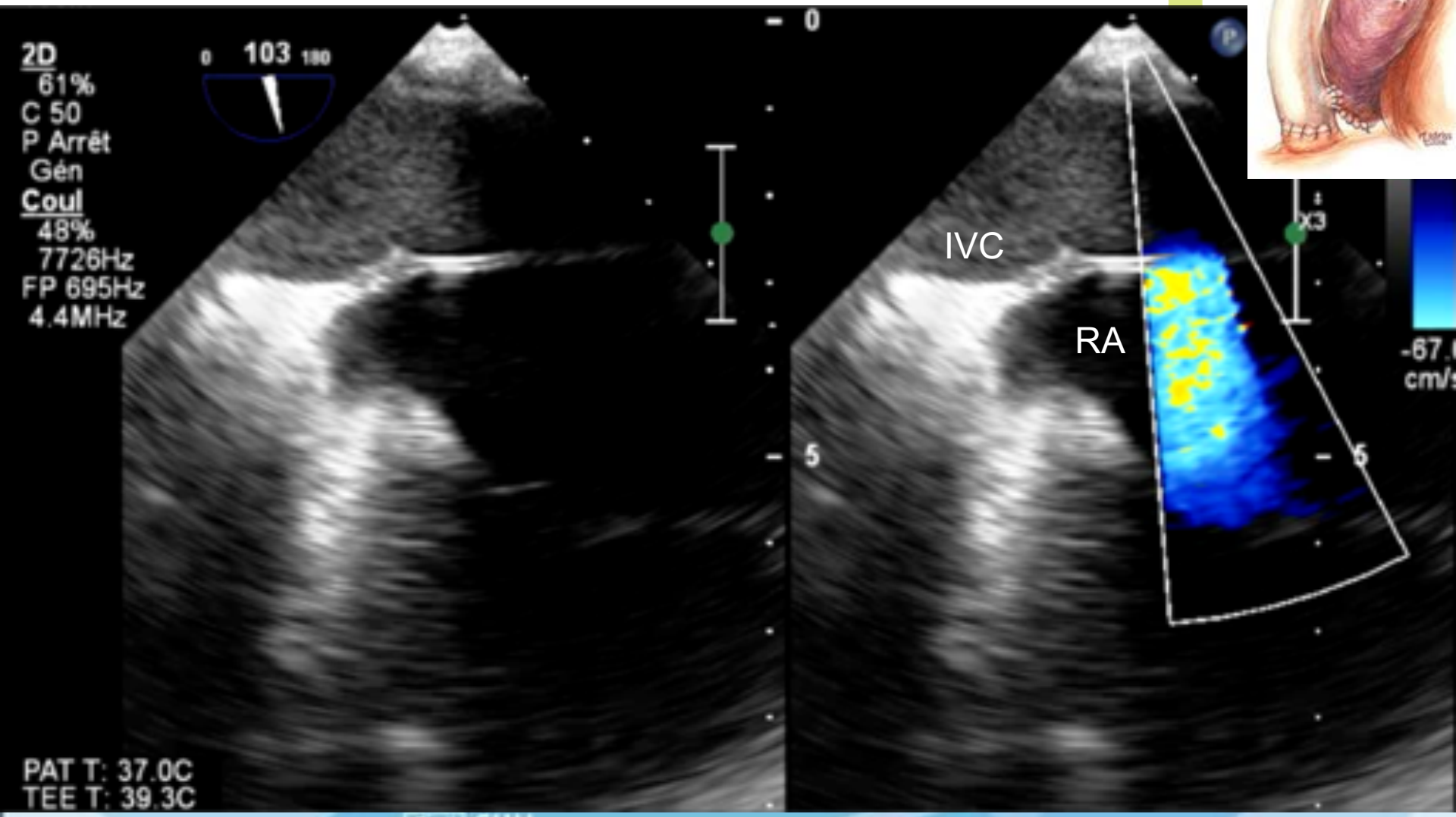
2D
61%
C 50
P Arrêt
Gén
Coul
48%
7726Hz
FP 695Hz
4.4MHz
0
103
180
PAT T: 37.0C
TEE T: 39.3C
IVC
RA
x3
-67.
cm/s

percutaneous fenestration guiding

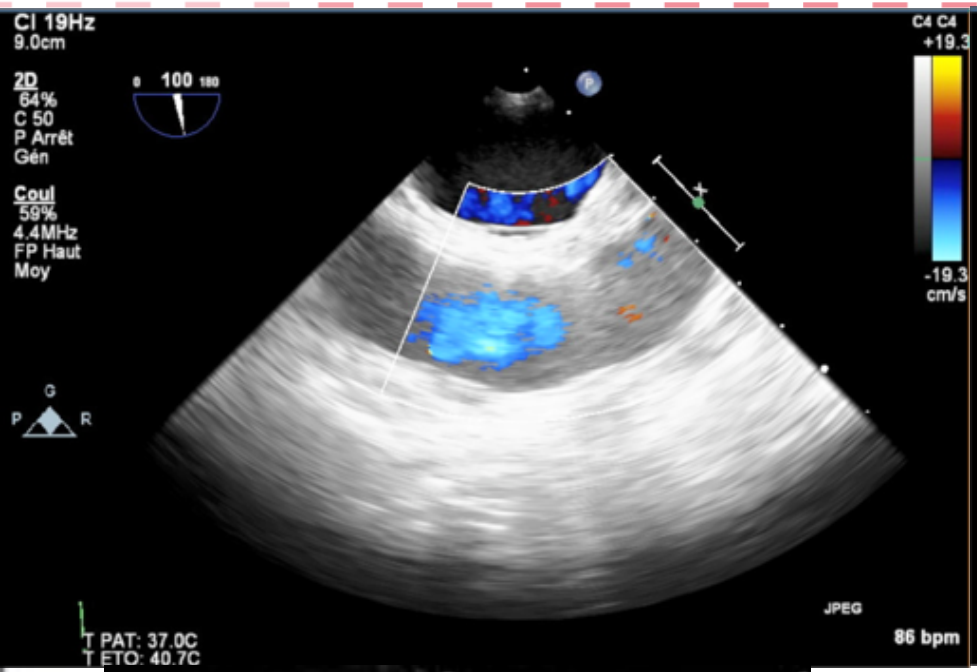

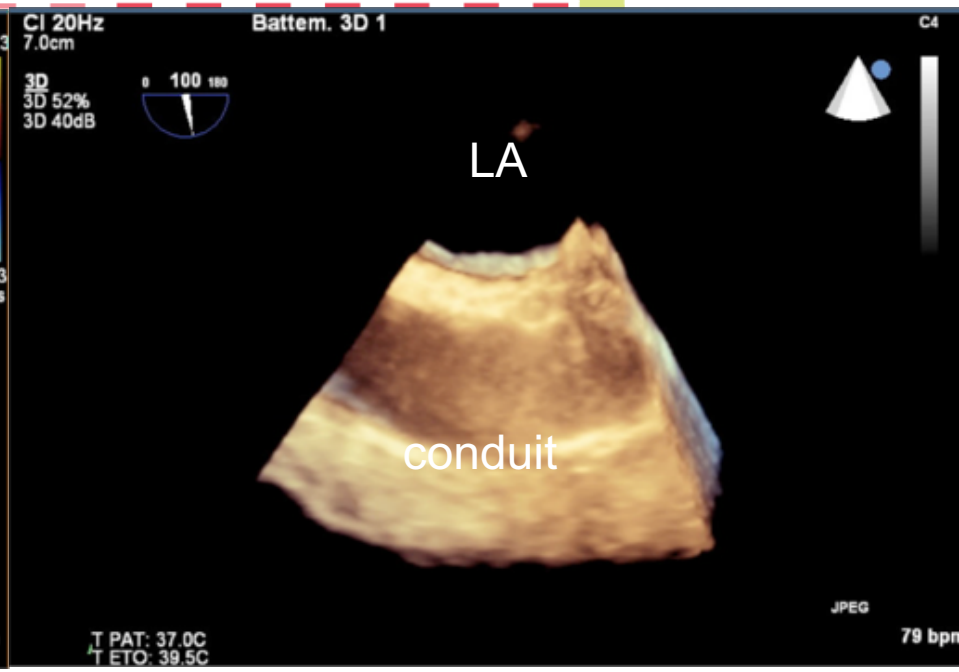

Percutaneous fenestration guiding

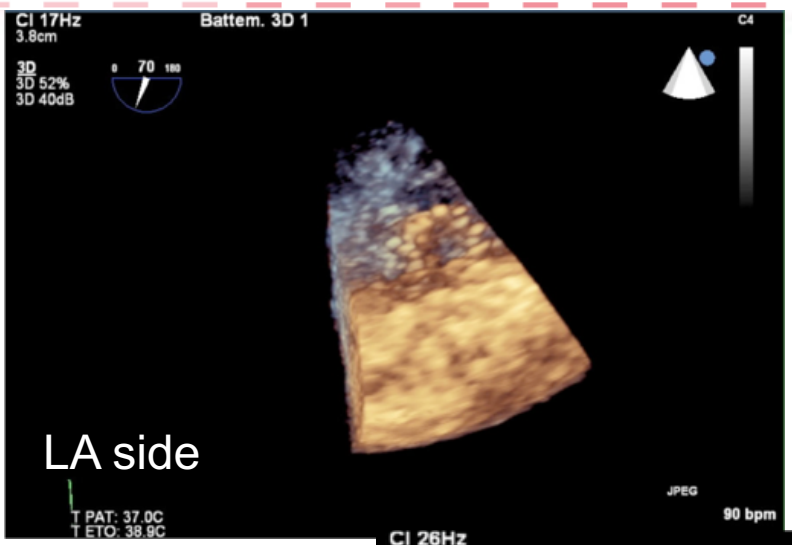

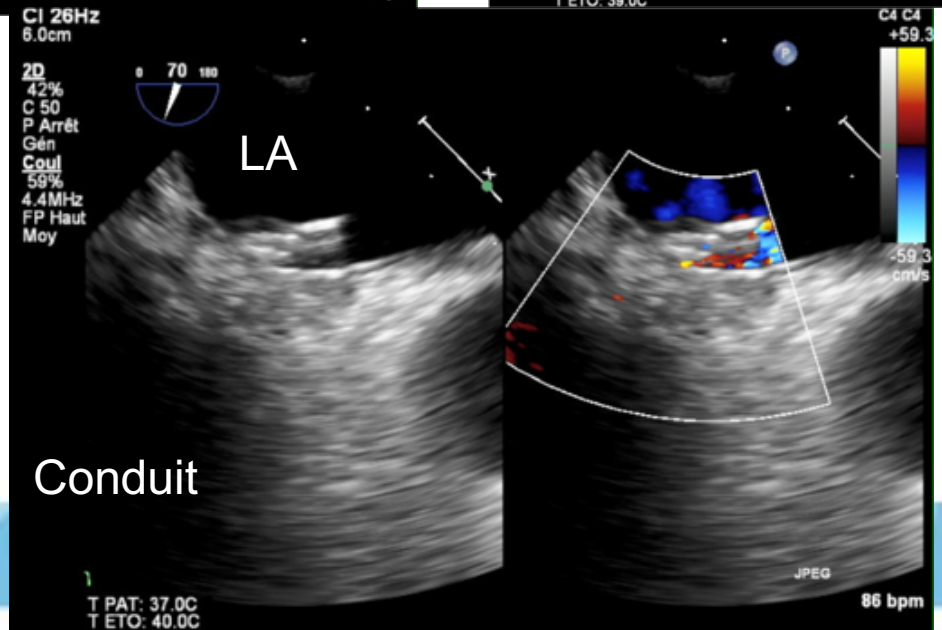

IVC flow after TCPC

- Normal: continous anterograde flow of low velocity, respiratory variation

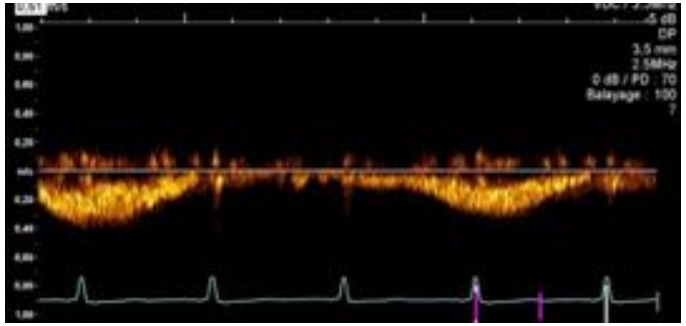

- Retrograde A wave:
  - failing fontan (↗CVP-arrythmia)

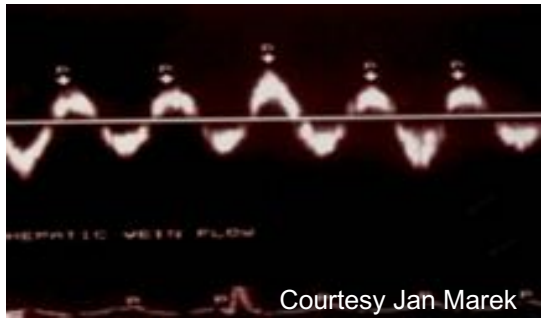

- Retrograde S wave:
  - AV regurgitation: IVC
  - Antegrade flow (pulm stenosis): SVC

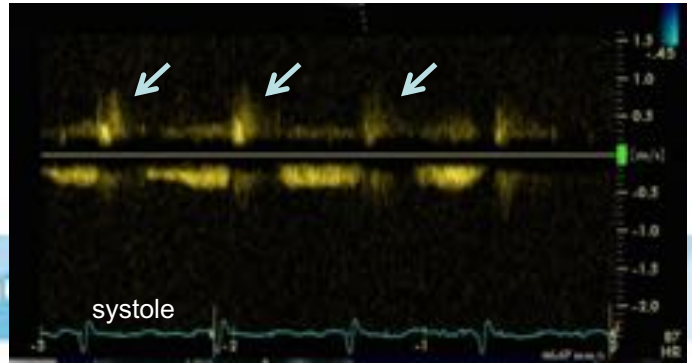

Thrombosis in TCPC

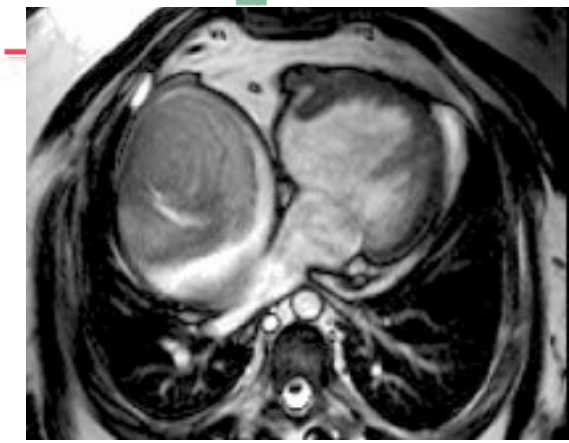

- Systemic venous pathway (TCPC)
  - IVC, RA (atriopulmonary connection), lateral tunnel/ conduit, fenestration,PAs, SVC
- Intra cardiac chambers
  - Intracardiac: LA, LAA, SV (poor systolic function)
- Native PA trunk
  - PAs divided and pulm valve non sutured

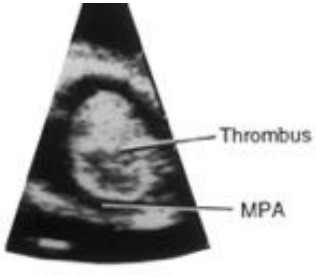

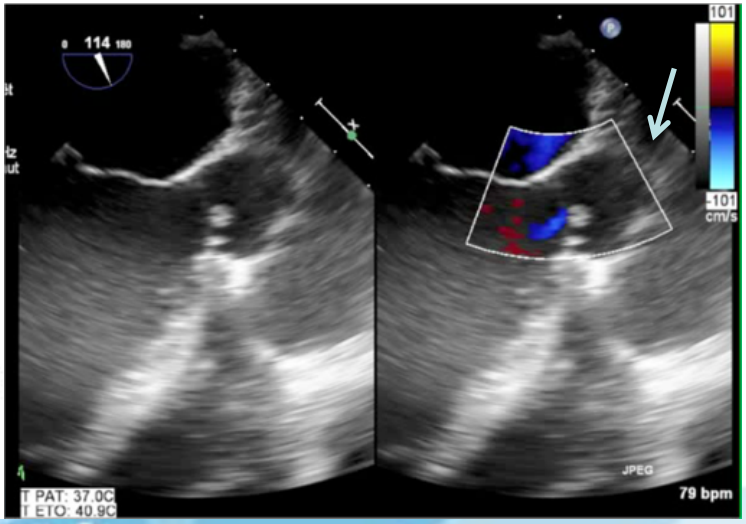

Persistent cyanosis after TCPC

- Conduit fenestration
  - Balance between PVR and early diastolic function
- Systemic venous pressure> pulmonary vein pressure
  - VV collaterals to pulmonary veins or systemic atrium
    - origin: LSVC, RSVC, inn Vein, hepatic veins
- Baffle leaks (intra cardiac type of connection)

Superior veno venous collateral

- Left « SVC » to the RA

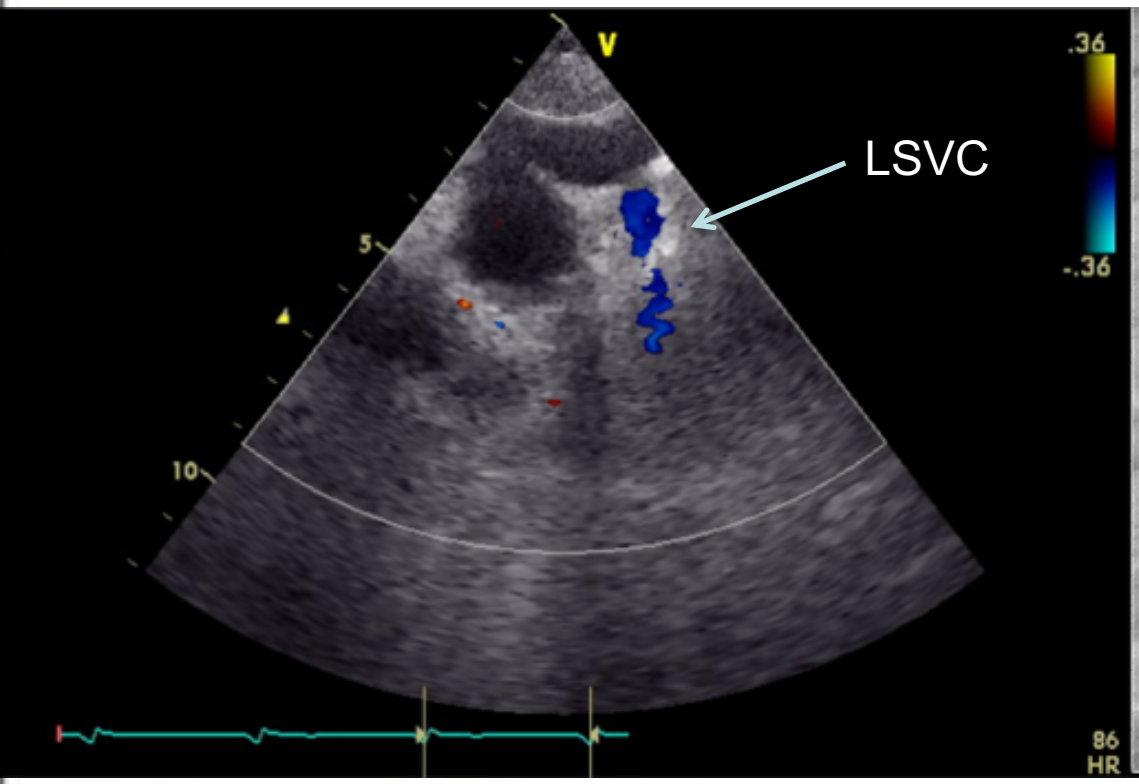

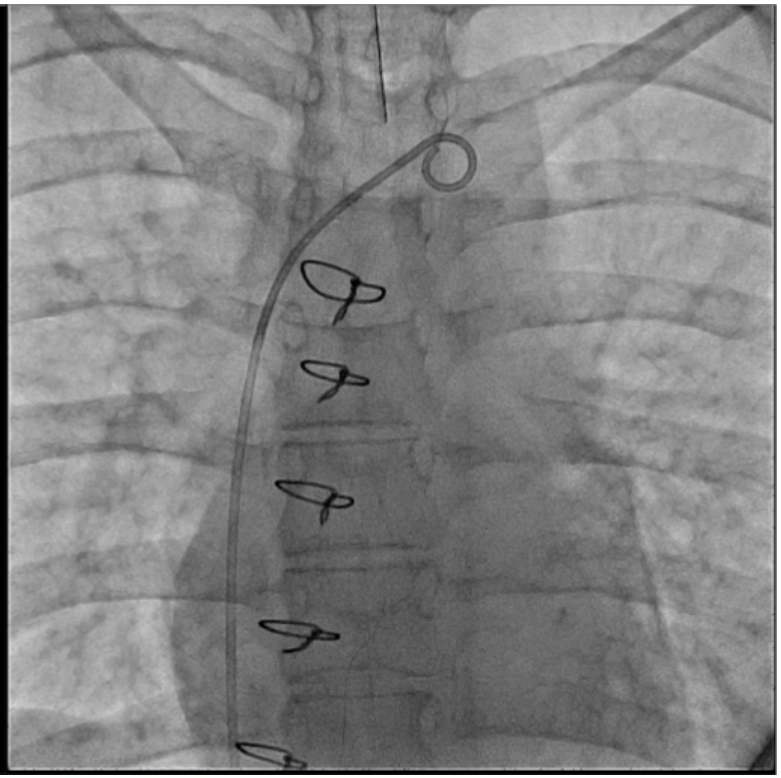

Inferior veno venous collateral

- HLHS S/P TCPC. Persistant mild hypoxemia
  - Shunt between HV and cardiac veins

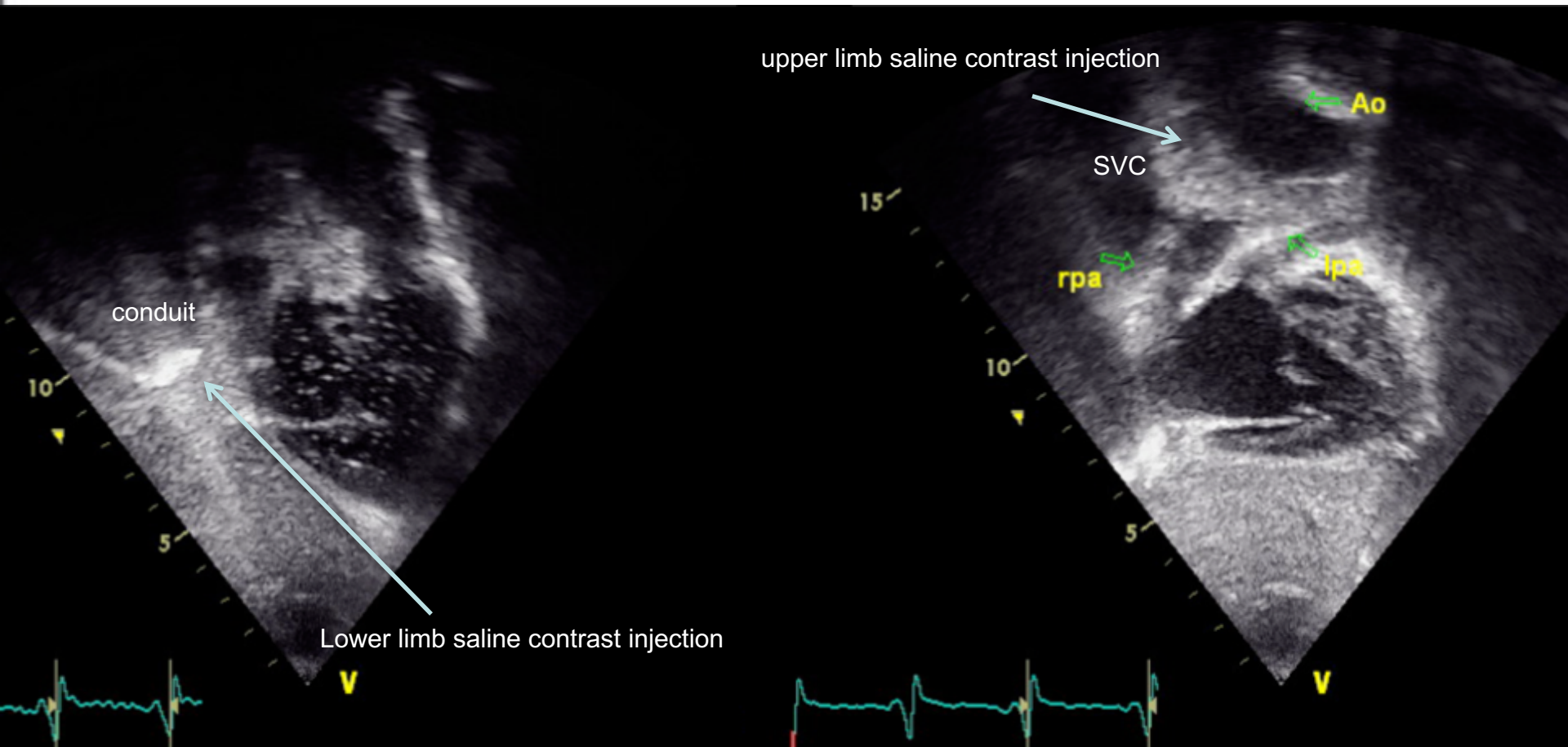

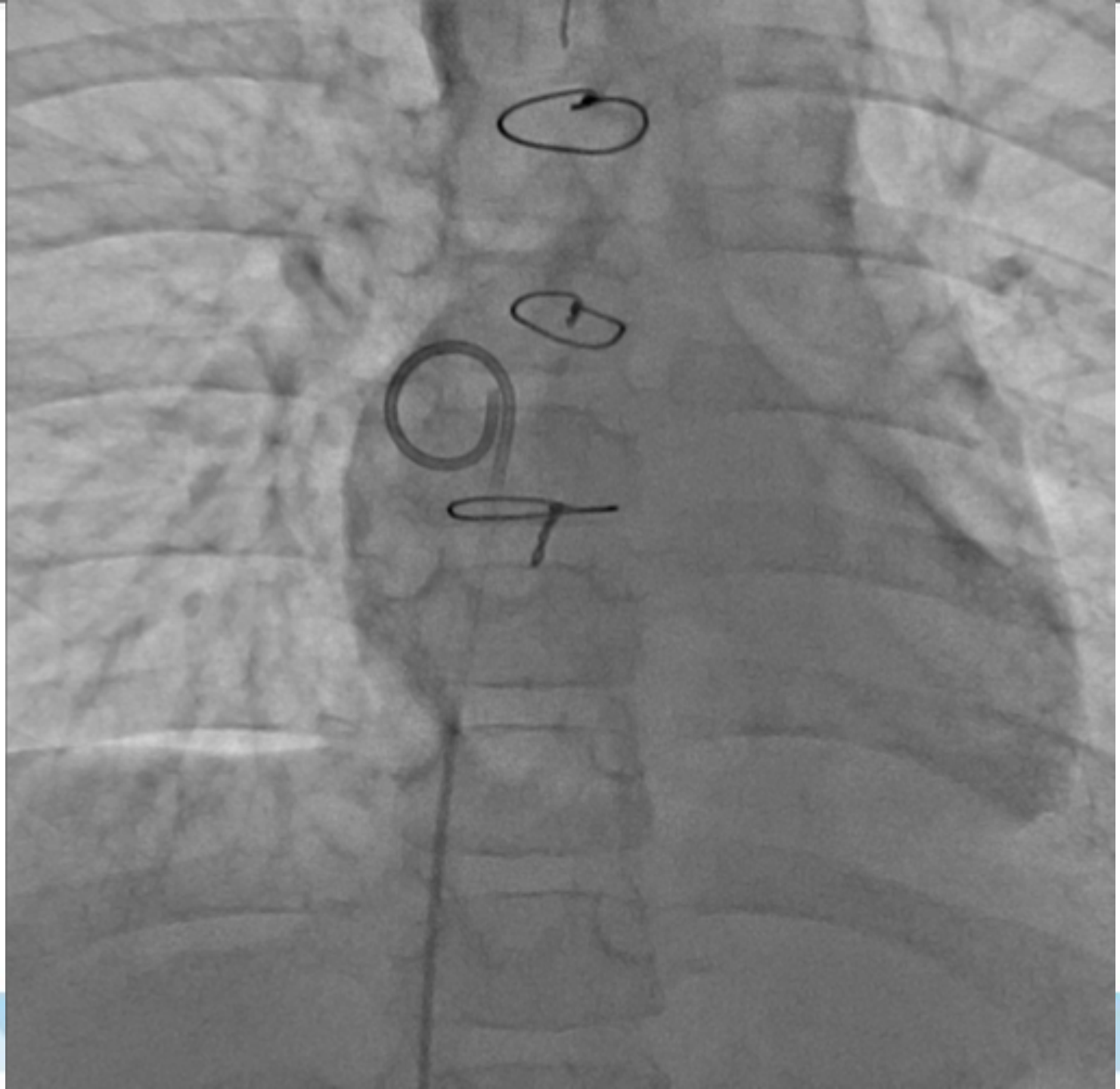

Echographic assessment

3. Pulmonary veins

4. Atrial septum

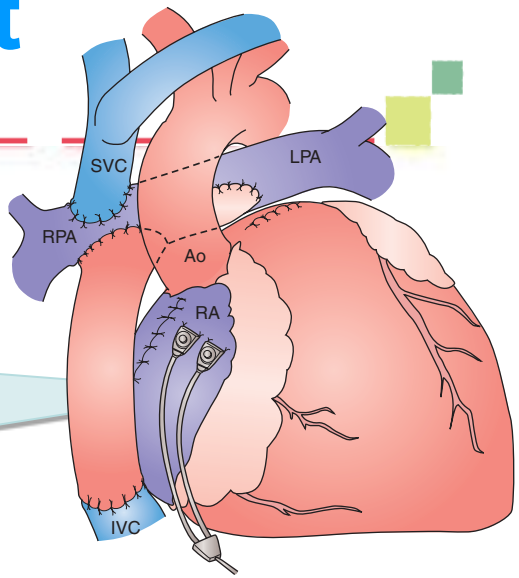

- PV compression
  - Atriopulmonary connection
  - Intracardiac tunnel
  - Heterotaxy syndrome

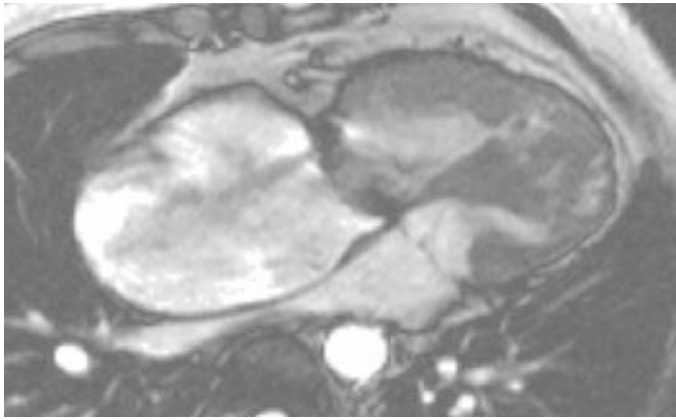

- Restriction of interatrial shunt in HLHS

- Potential cause of elevated PA pressure

Pulmonary veins and atrial septum

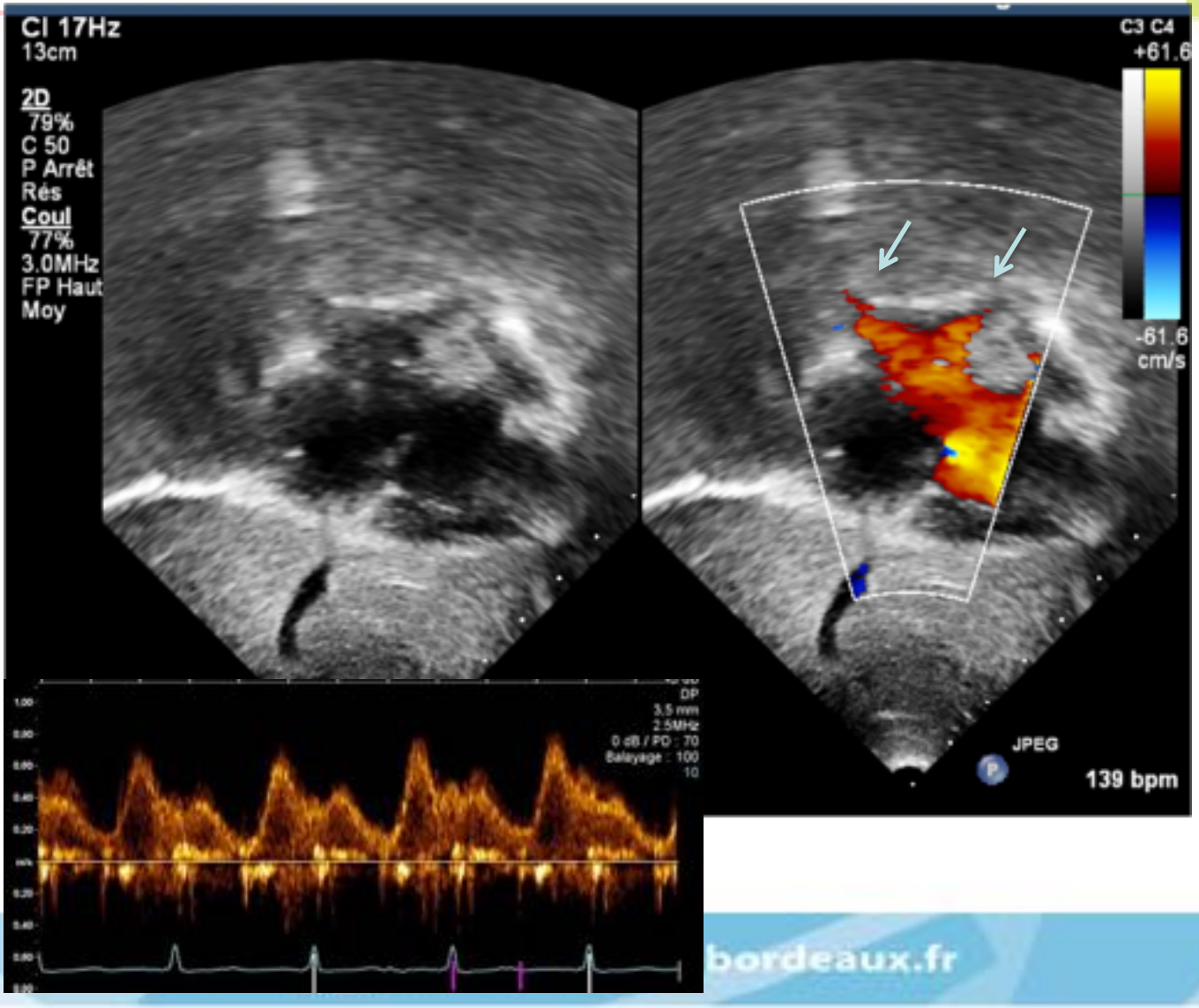

Restrictive PFO in HLHS

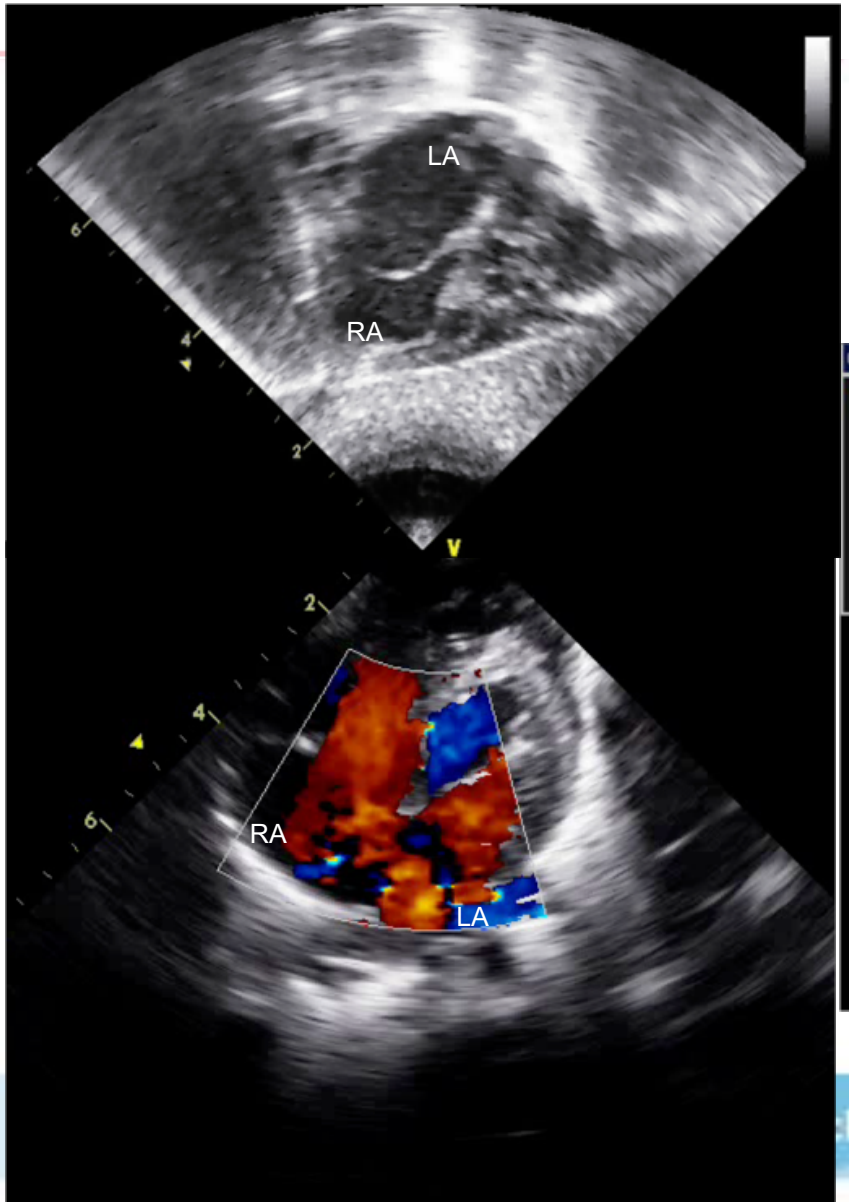

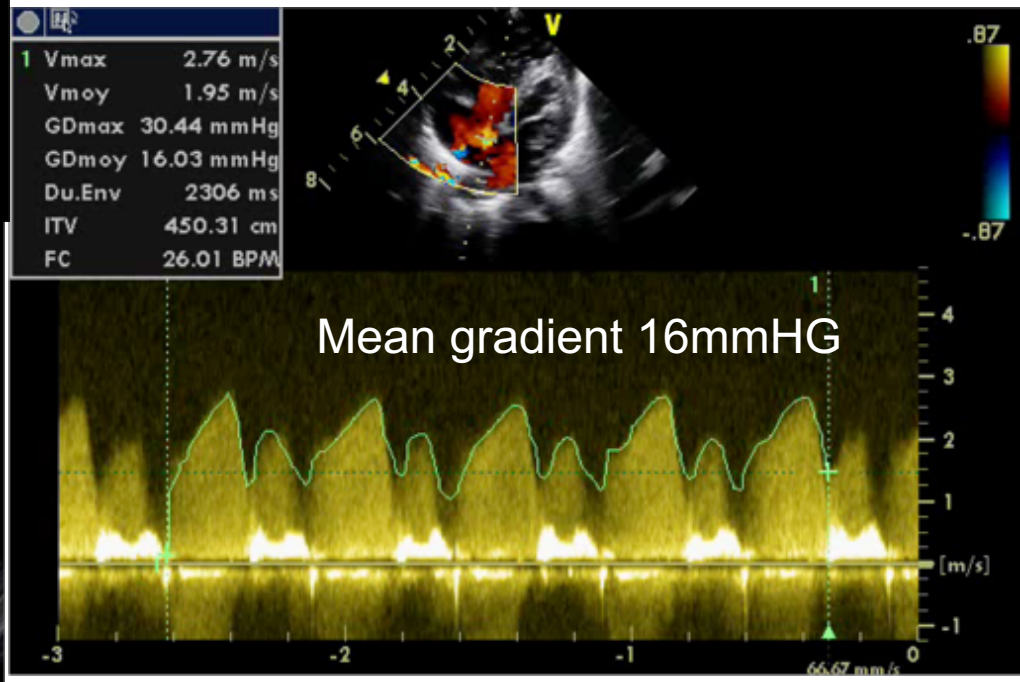

Post balloon atrial septostomy

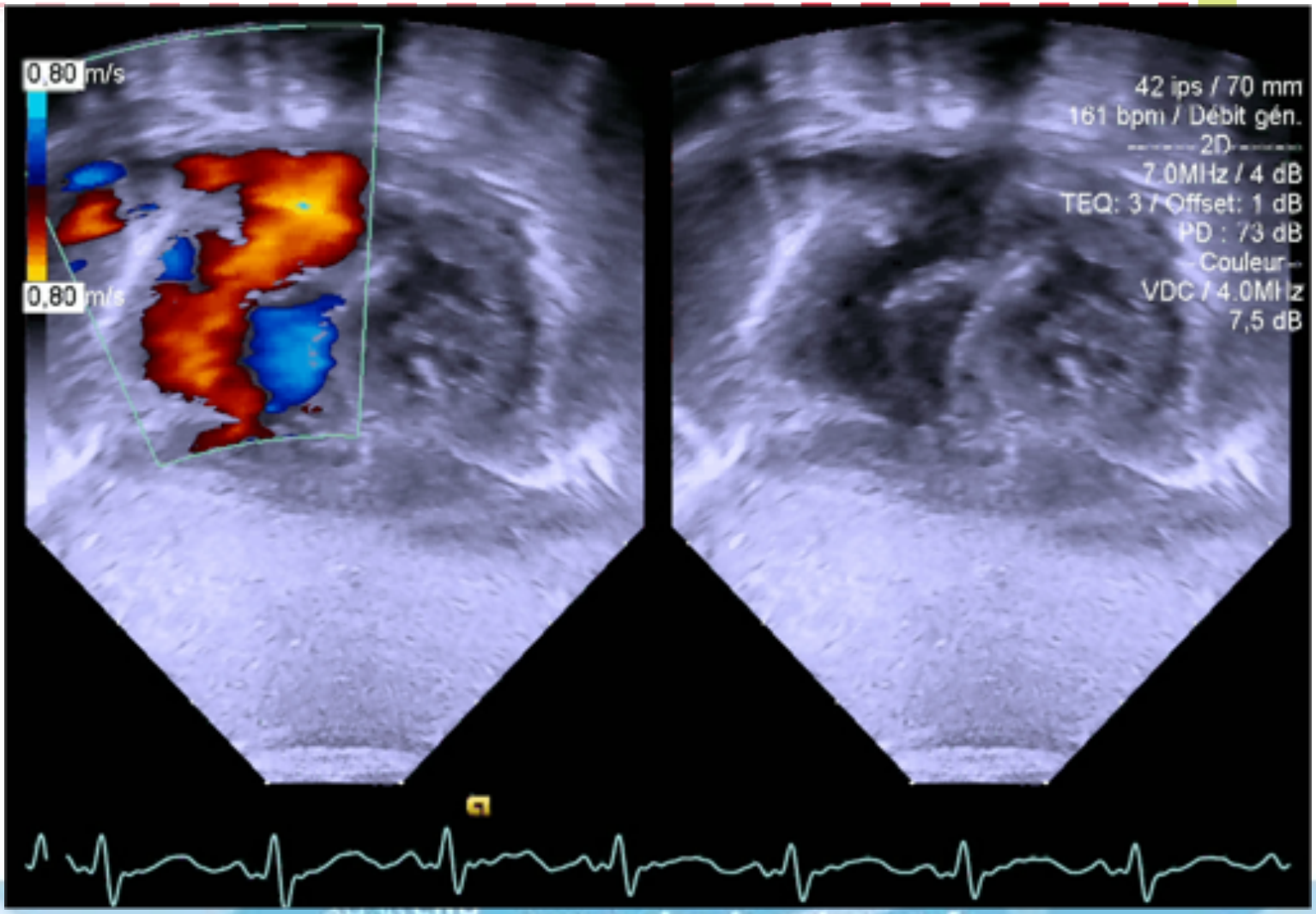

Echographic assessment

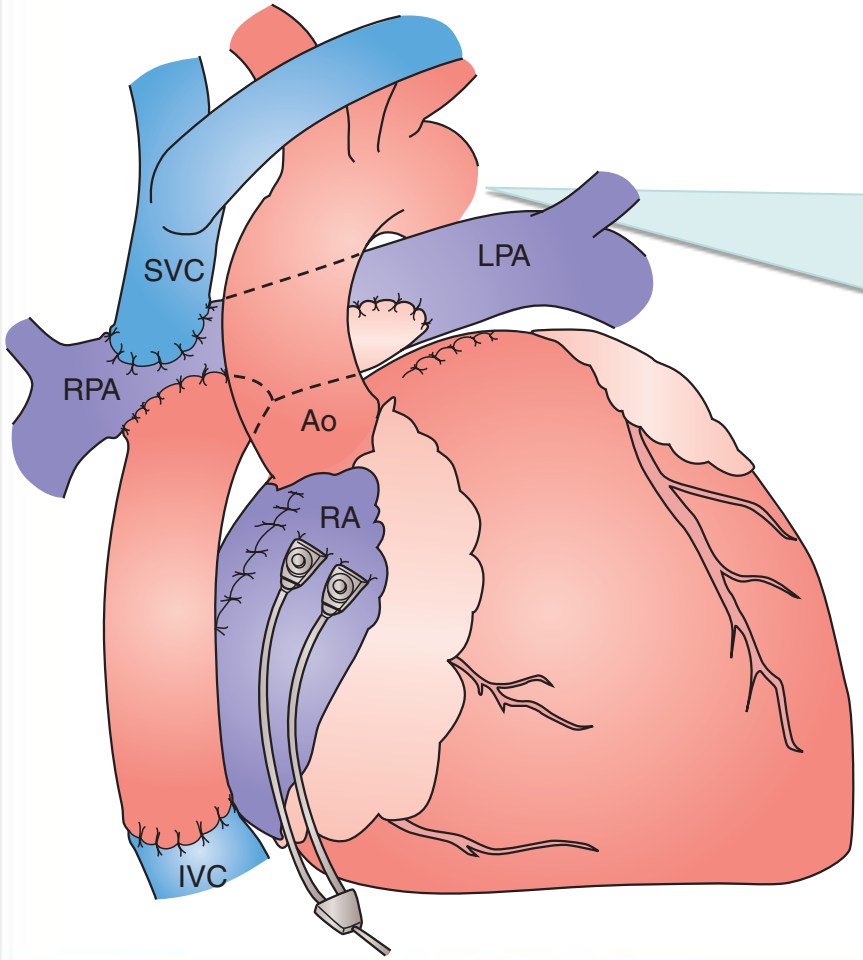

SV AFTERLOAD

6. Systemic outflow tract

7.Aorta

Restrictive systemic outflow tract in DILV

- Proximal anastomosis
  - Restritive bulboventricular foramen: DKS

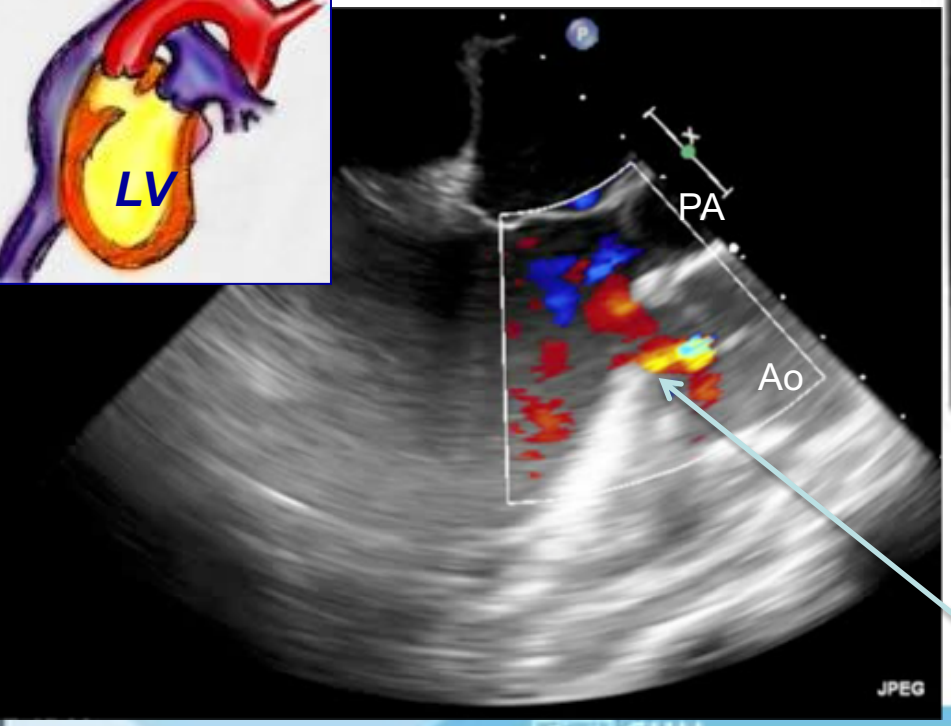

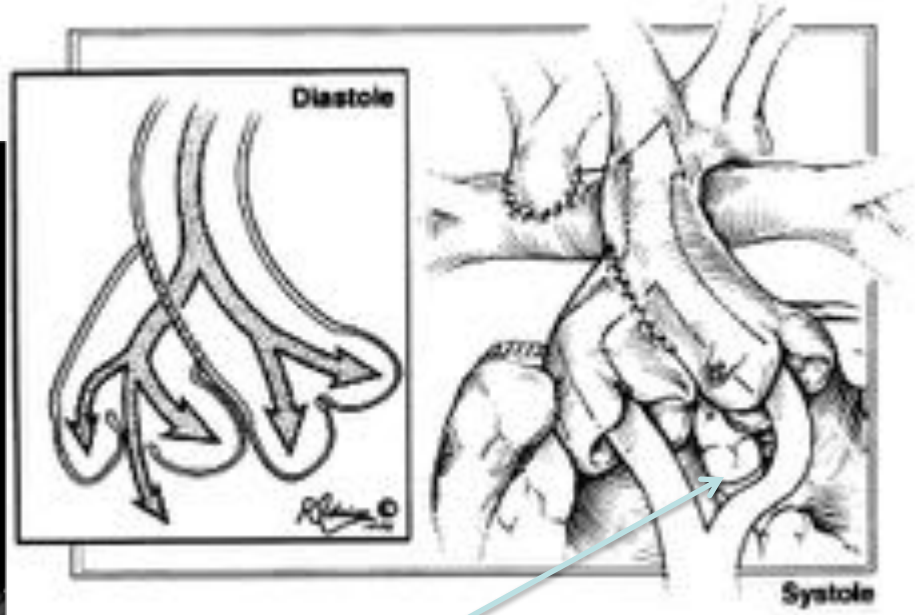

Restritive bulboventricular

Restrictive systemic outflow tract

- Proximal anastomosis
  - Restritive bulboventricular foramen: DKS

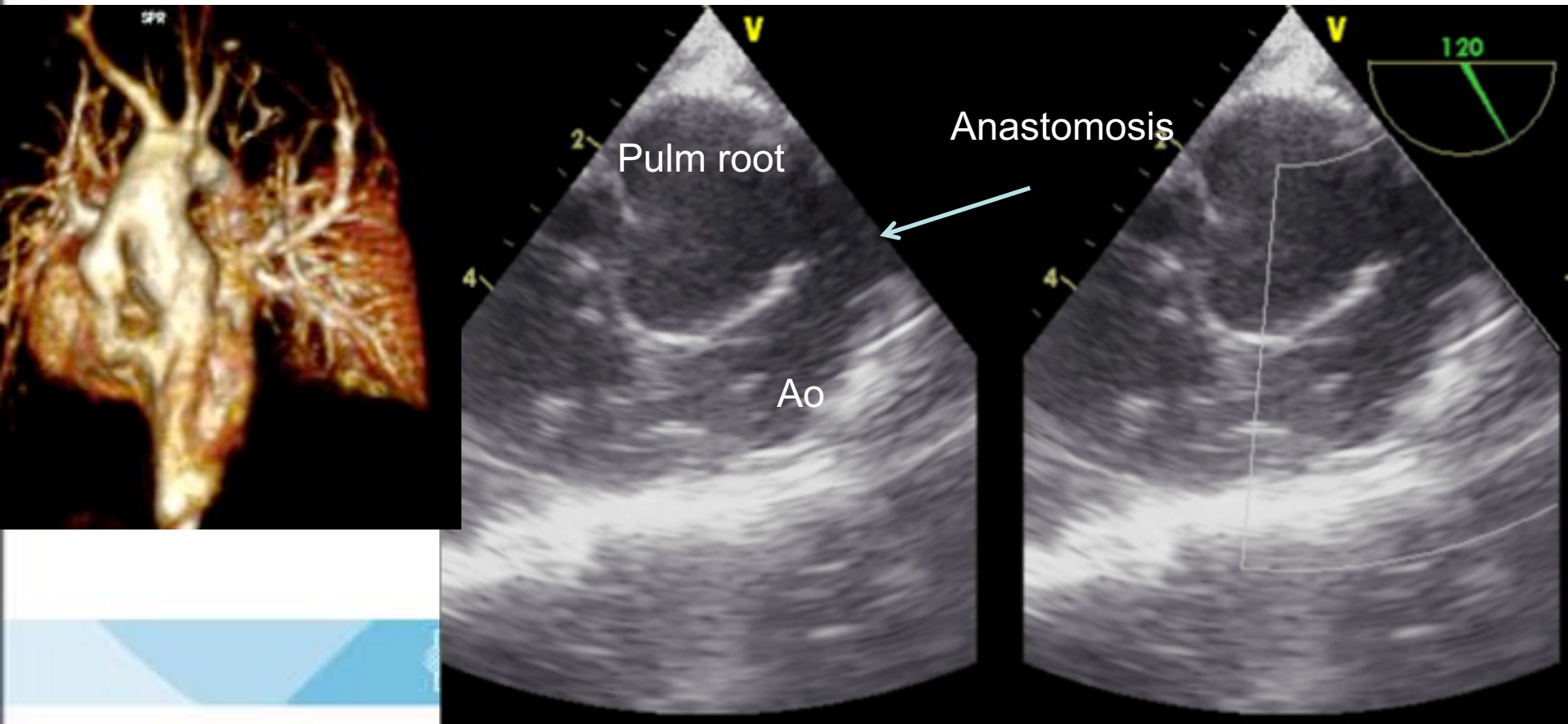

Systemic outflow tract after Norwood procedure in HLHS

- Proximal anastomosis
  - DKS stenosis
  - Neoaortic valve regurgitation

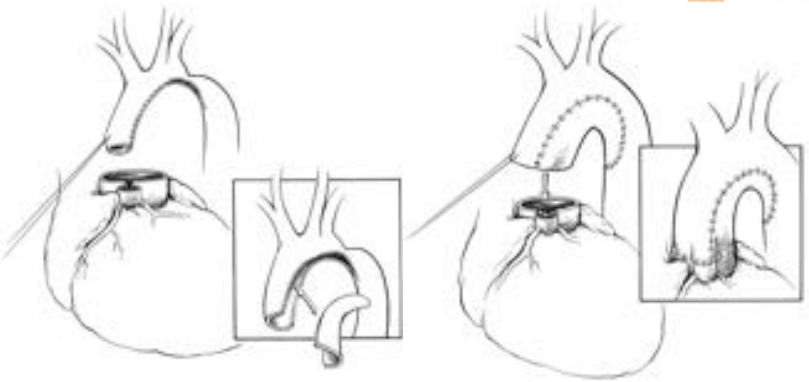

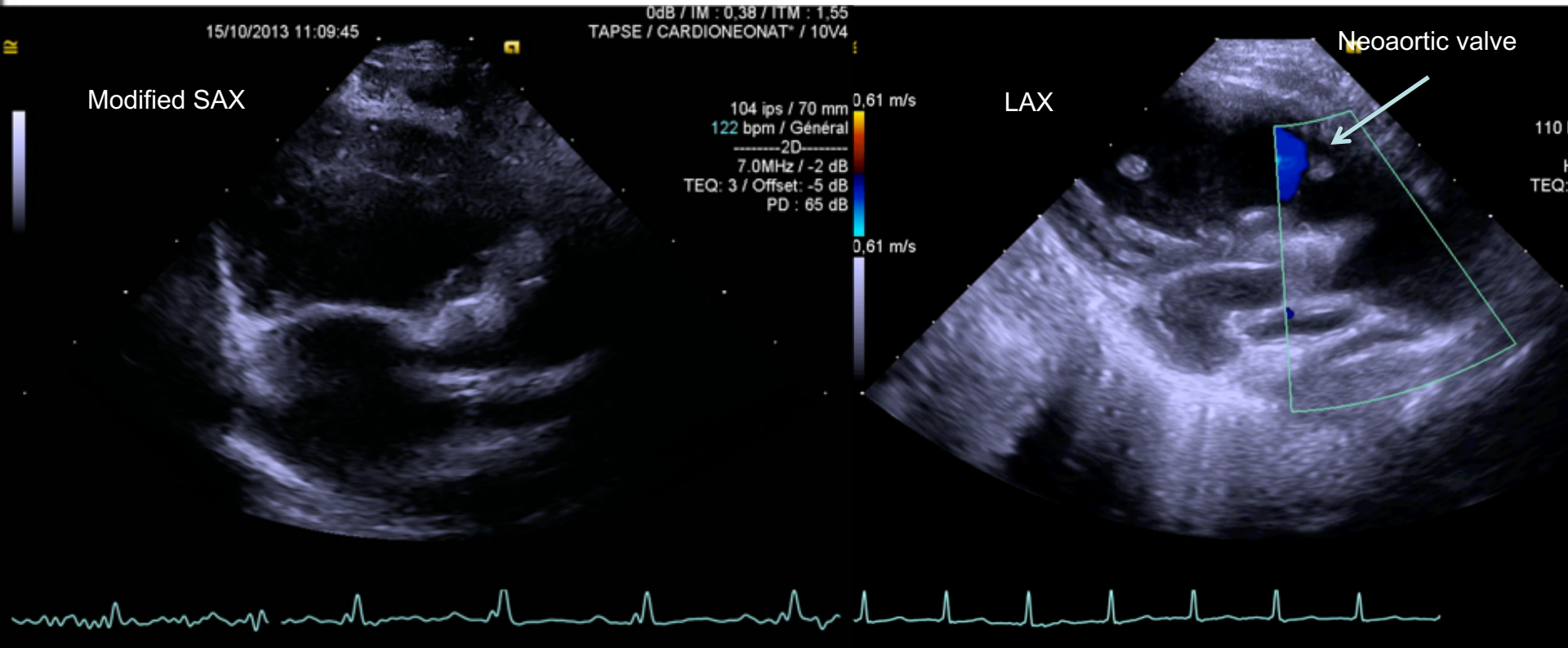

Aortic arch assessment

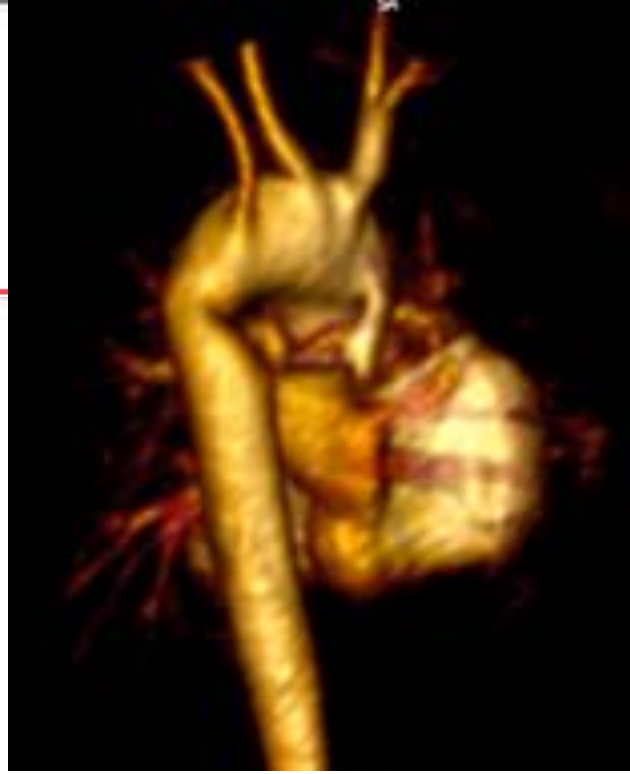

Distal anastomosis

- Supra sternal sagital view
- Potential increased velocity (HLHS)

- Pitfall: potential absence of diastolic runoff pattern in coarctation
  - change in Ao arch geometry/ patch/mBTshunt
  - CoA index:
    - Desc Ao ratio narrowest/ widest diam <0.7
    - Peak gradient > 30mmHg

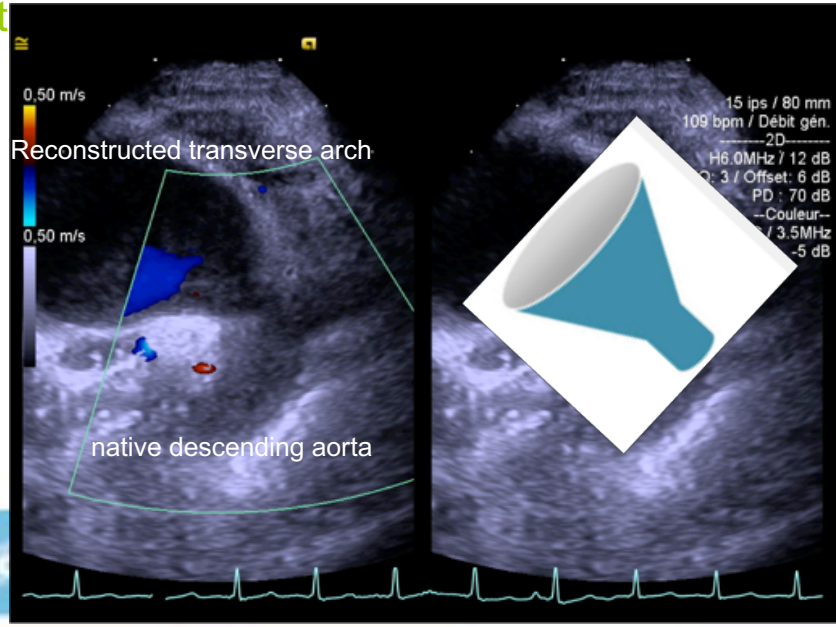

Aorto-to-pulmonary collateral flow

- Present in most patients (80%)
- Suprasternal frontal and sagittal views
- Limited assessment with TTE
- Consider alternative imaging: MRI/Cath
  - MRI: quantification of aortic to pulmonary shunt flow
  - Cath: PAP, PVR measurements and percutaneous closure

Echographic assessment

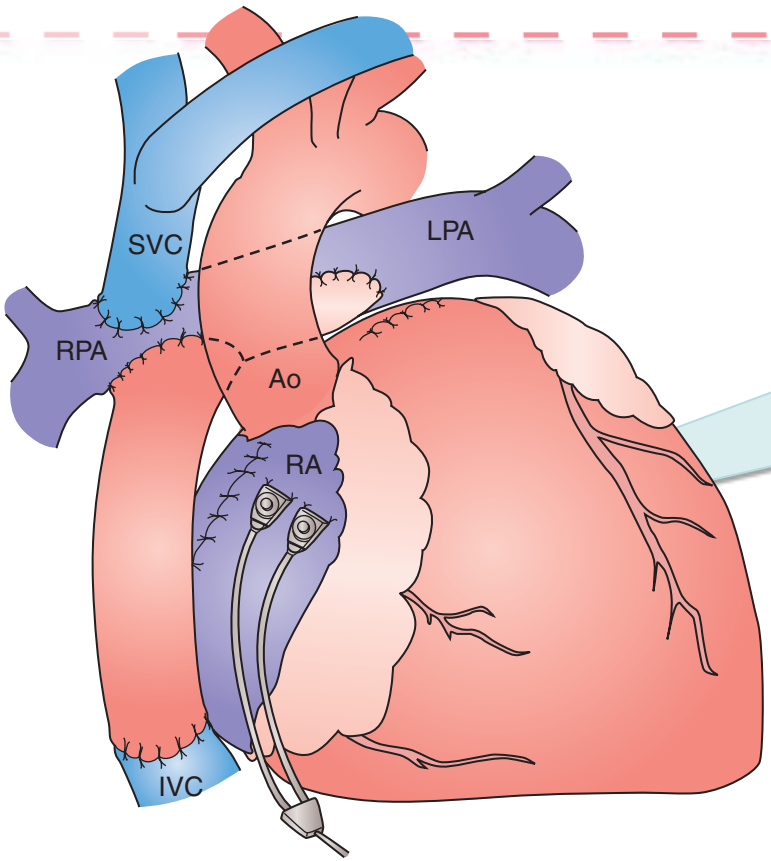

5. Atrio-ventricular valves

Echographic assessment of AV valves

- Assessment of an heterogeneous group
  - Various anatomy
  - Different loading conditions/ different stage
  - Serial measurements++++

- Echo report
  - AVV diameter and function
  - Location of papillary muscles/chordal attachement
  - Difference between functional and anatomical regurgitation

LAVV anomalies in DILV

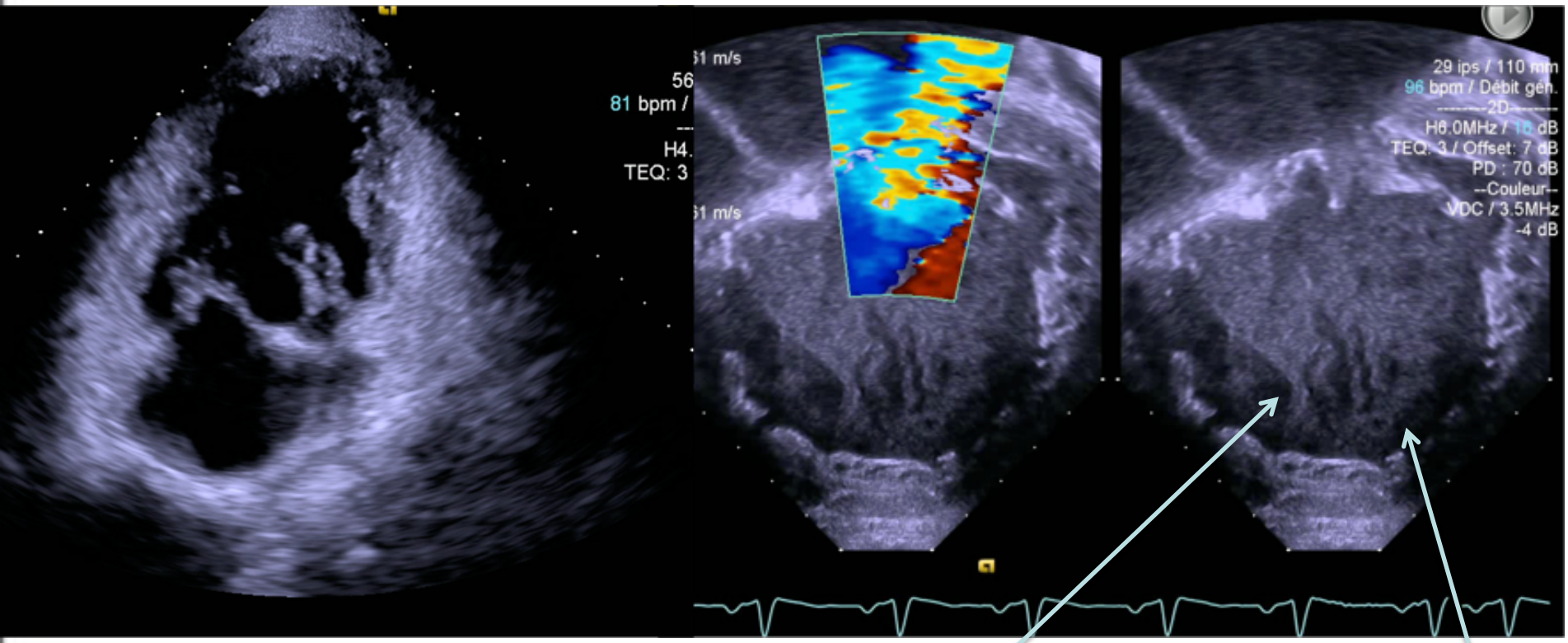

Restrictive bulboventricular foramen
Increased AFTERLOAD

PA banding/MR
Increased PRELOAD

LV spherical remodeling : secondary MR worsening

Unbalanced AVSD

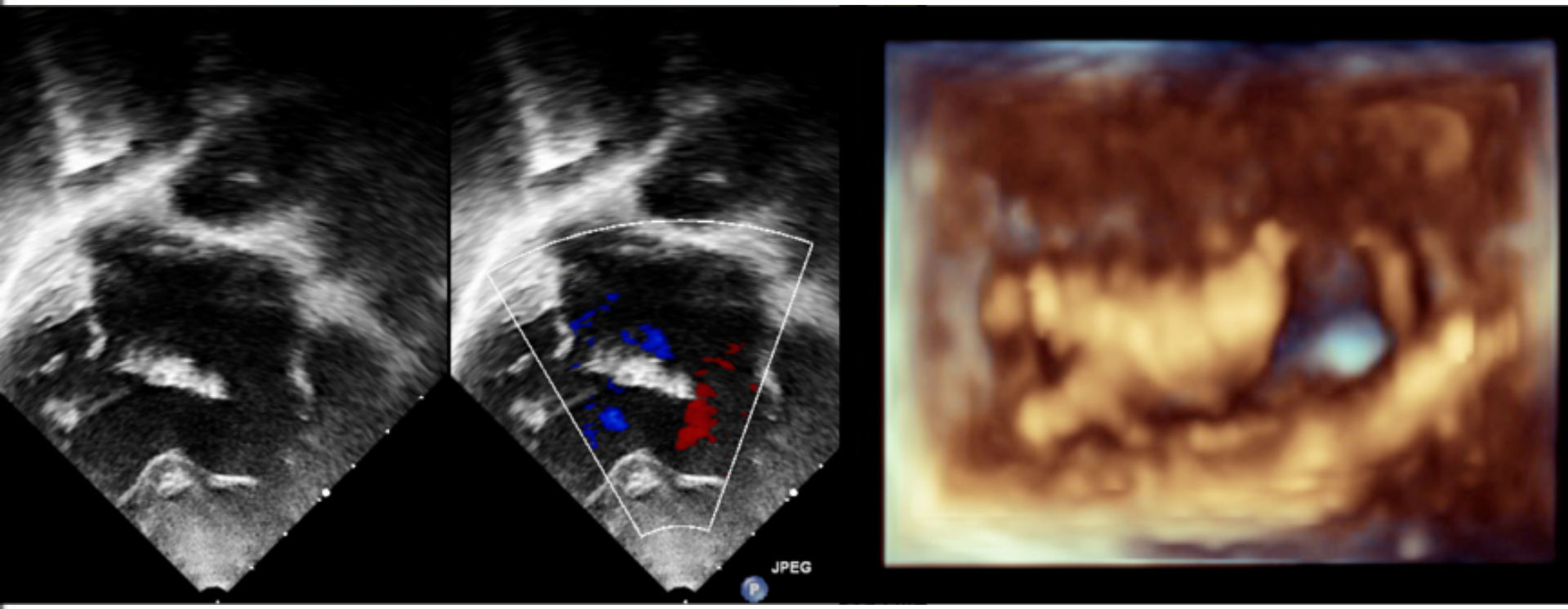

TR in systemic right ventricle

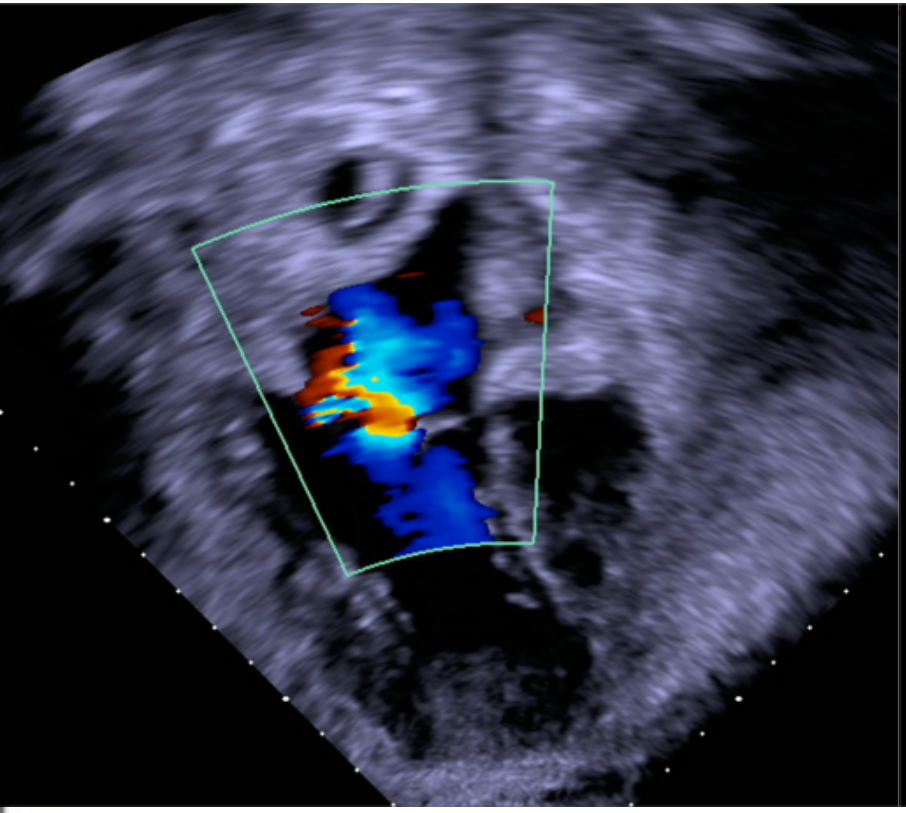

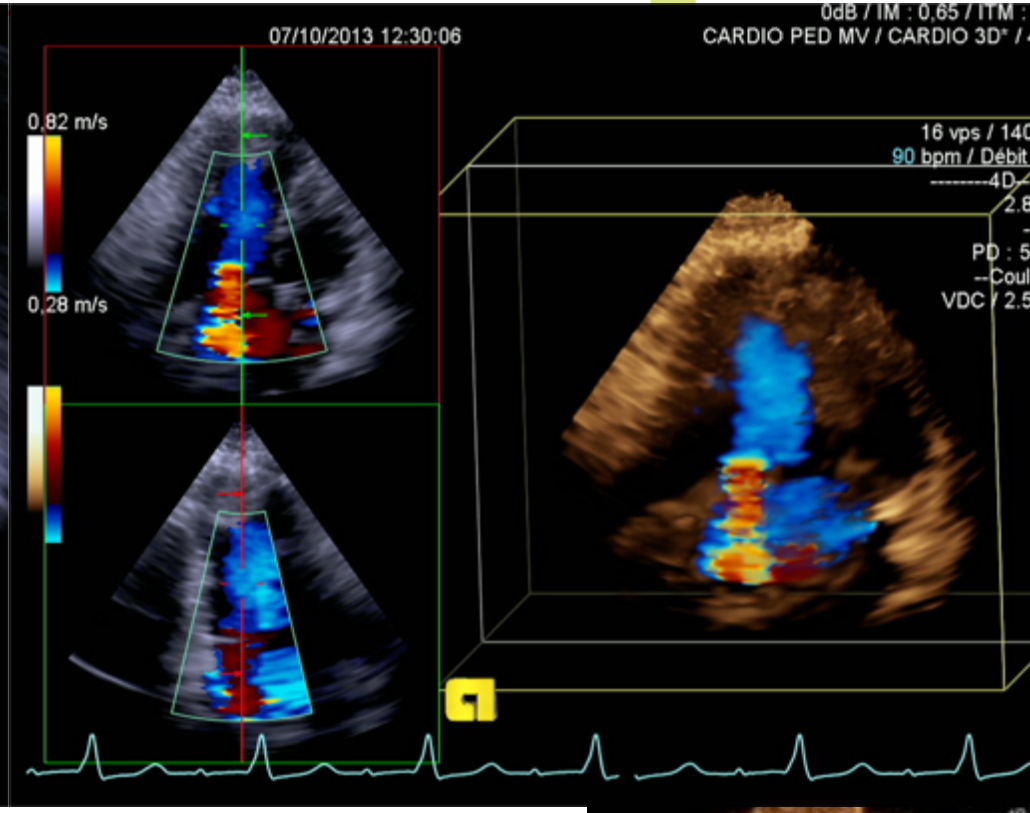

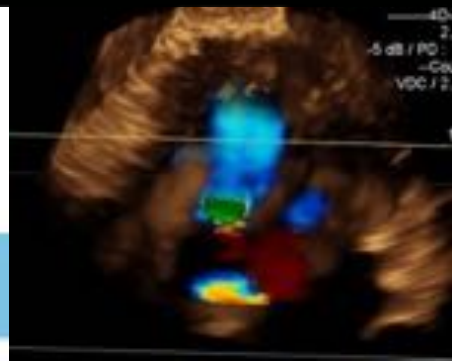

Echographic assessment

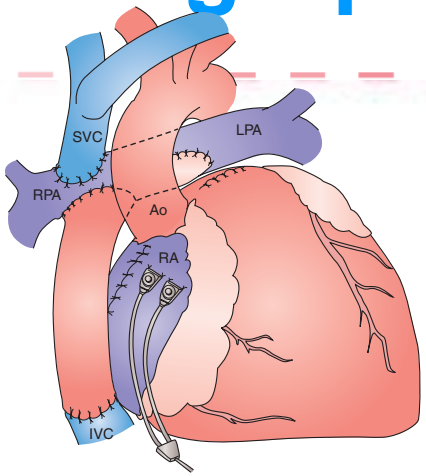

8.Systemic ventricular function

- Systolic and diastolic(+++) function
  - No single morphology
  - Important confunding variables
    - Preload (surgical stage/ AVVR/ PVR/PA compliance)
    - Afterload (restrictive outflow trat, CoA)
- Eye balling/ EF (TM, 2D) / myocardial deformation
- Ongoing research on advanced parameters

Conclusion: echocardiography in Fontan circulation

- Easily accessible and cost-effective tool
- Good assessment of the Fontan pathway in children but may be limited in adults
- Best imaging modality for AVV assessment
- UVH systolic and diastolic function assessment remains challenging
- Consider alternative imaging modalities for extracardiac lesions (Ao-pulm collaterals, complex aortic arch stenosis)

Essential reading

- Nature Clinical Practice Cardiovascular Medicine 2005. The Fontan Circulation: A Challenge to William Harvey?

  Marc R de Leval