

EDITORIAL COMMENT

Intrarenal Venous Flow

A Window Into the Congestive Kidney Failure Phenotype of Heart Failure?*



W.H. Wilson Tang, MD,^{a,b} Takeshi Kitai, MD, PhD^b

Although the importance of congestion in the disease progression of heart failure has long been recognized (1), much has focused on how cardiac impairment can lead to renal dysfunction. Over the past decade, there is increasing recognition that the ability of the kidneys to compensate for fluid overload can be influenced not only by reduced arterial perfusion or underlying intrinsic renal abnormalities, but also by increased venous pressure (2-4). However, unlike the heart, the lack of reliable bedside tools that can provide insights into real-time renal physiology has somewhat limited our abilities to better understand the factors contributing to cardio-renal syndrome. To date, clinicians rely on surrogates of venous congestion that are primarily inferred by structural and vascular flow abnormalities in the right heart, inferior vena cava, or hepatic veins (Figure 1) (5-7). Although there have been promises of directly quantifying renal perfusion using ultrasound contrast, they are yet to be clinically applicable (8).

Being a versatile, noninvasive tool for evaluating abnormal renal artery stenosis or obstructive uropathy, renal Doppler ultrasonography has rarely been investigated for profiling renal hemodynamics in the setting of heart failure. Recent reports have suggested that estimating the degree of arterial

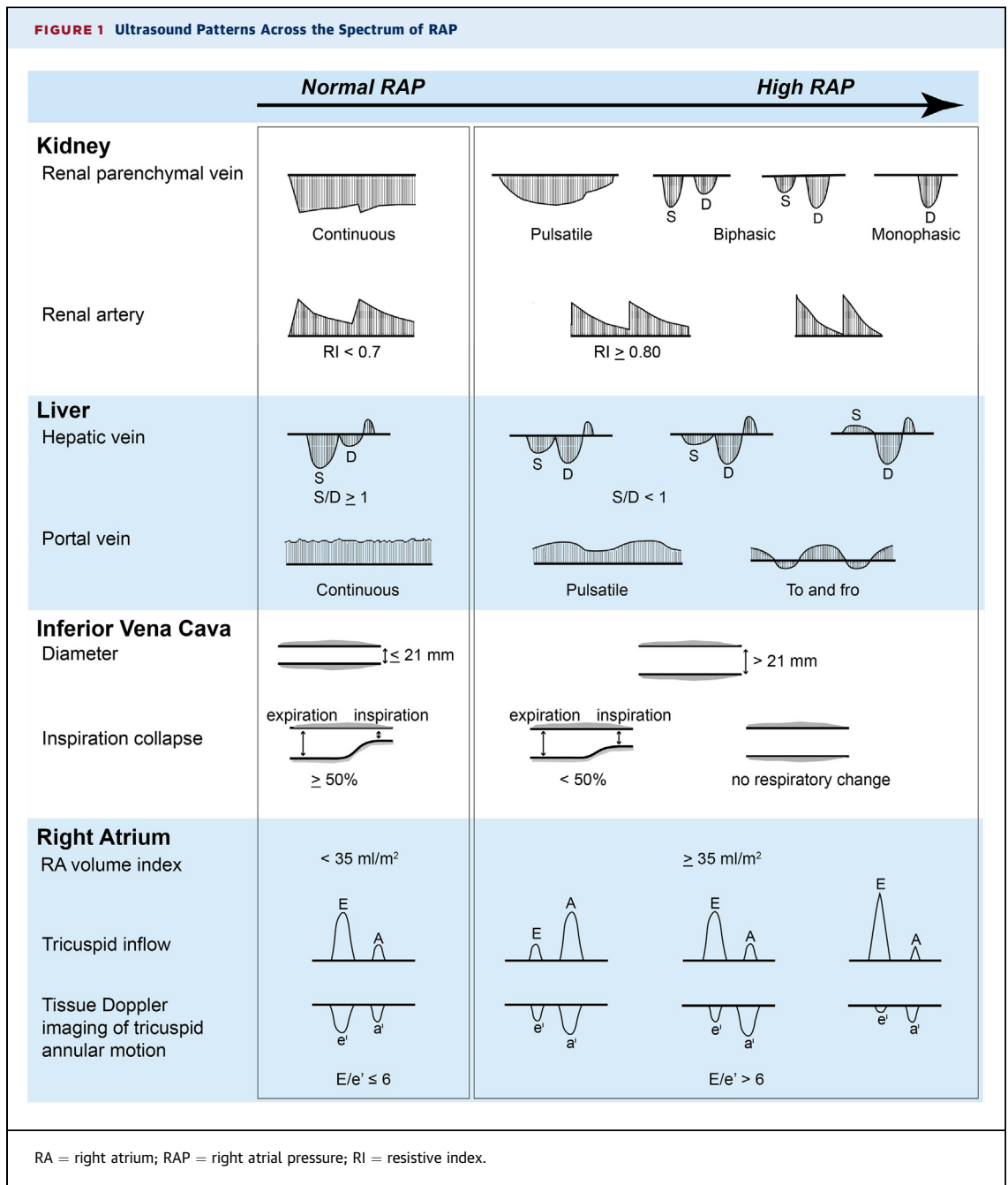
renal blood flow with the renal resistive index may identify higher-risk patients with heart failure (9,10). Meanwhile, a low intrarenal venous impedance index (VII) calculated from the renal venous waveforms has been associated with raised renal interstitial pressure caused by non-heart failure conditions such as acute ureteral obstruction (11,12) or diabetic nephropathy (13). In this issue of *JACC: Heart Failure*, Iida et al. (14) systematically examined distinct renal Doppler flow patterns in patients with largely nonischemic heart failure sta-

SEE PAGE 674

bilized either following hospital admission or in the outpatient setting. Interestingly, this patient cohort included ~40% patients with either heart failure with preserved ejection fraction or pulmonary arterial hypertension. Despite relatively preserved cardiac and renal function, 43% had advanced (New York Heart Association functional class III to IV) symptoms and yet only 28% demonstrated an increase in right atrial pressures. The authors first observed that VII was difficult to quantify in this population, in part because there were disruptions of the normal continuous intrarenal venous flow (IRVF) pattern. They therefore speculated that the IRVF patterns were largely attributable to altered renal interstitial pressures in the setting of increased venous congestion (as reflected by estimated right atrial pressure). Indeed, venous congestion can produce elevated right-side pressures that transmit backward into the renal parenchyma similar to that observed in hepatic venous flow patterns (Figure 1), leading to increased pulsatility of the IRVF signal. This pulsatility (so-called “discontinuous IRVF pattern”) may reflect increased compliance of renal parenchyma and its venous vessels in response

*Editorials published in *JACC: Heart Failure* reflect the views of the authors and do not necessarily represent the views of *JACC: Heart Failure* or the American College of Cardiology.

From the ^aCenter for Clinical Genomics, Cleveland Clinic, Cleveland, Ohio; and the ^bHeart and Vascular Institute, Cleveland Clinic, Cleveland, Ohio. Dr. Tang is supported by grants from the National Institutes of Health (R01HL103931 and R01DK106000). Dr. Kitai has reported that he has no relationships relevant to the contents of this paper to disclose.



to increasing venous pressure within the encapsulated kidneys. It can manifest by biphasic forward velocity that peaks during each cardiac cycle (biphasic pattern), or a gradual diminution of velocity throughout systole that evolves into a diastolic-only flow pattern (monophasic pattern). Because patients in this study were relatively lean (mean body mass index of 23 kg/m²) and the fact that all IRVF measurements were performed by a

single individual, the technical feasibility and consistency of Doppler waveform sampling of interlobular vessels in a more diverse group of patients and sonographer should be investigated. It is also important to note that discontinuous or biphasic patterns of IRVF and lower VII are not specific to heart failure, and have been described in normal pregnancies to at least in part be explained by reduced vascular compliance from increased renal

interstitial pressure subsequent to partial obstruction of the ureters by the gravid uterus (15). Because not all patients had direct invasive cardiac or renal hemodynamic assessments concurrent to their Doppler ultrasounds, mechanistic relationships between discontinuous venous flow patterns and raised renal interstitial pressures remain hypothesis-generating.

Another interesting finding of the study was the fact that IRVF patterns, rather than renal resistive index, provided incremental prognostic value. To put their findings into perspective, over one-half of the patient cohort (54%) exhibited a continuous IRVF pattern that invariably had low right atrial pressures (estimated <10 mm Hg) and favorable prognosis (>95% survival at 1 year). In contrast, about one-quarter of patients with discontinuous IRVF, either with increased right atrial pressures (26%) or monophasic patterns (23%), had the poorest prognosis (<40% survival at 1 year). The fact that a subset of patients with continuous IRVF pattern still experienced worsening renal function (by rising creatinine measures) was consistent with prior reports showing favorable prognosis in those that achieved decongestion and hemoconcentration rather than acute kidney injury (16,17). Overall, these findings are largely associative, and there is still a lack of evidence to demonstrate the reversibility of such abnormal IRVF patterns with any current therapeutic strategy (diuretic agents, vasodilators, or mechanical circulatory support). In other words, we have yet to understand how recognizing IRVF patterns can affect our therapeutic decision-making. With the wide confidence interval of the multivariate analyses, whether these IRVF patterns can

provide incremental insights above and beyond other estimates of venous congestion requires further validation.

Despite these limitations, the study by Iida et al. (14) may have given us a glimpse into a unique window of a potential “congestive kidney failure” phenotype of patients with heart failure and a disrupted venous flow as a possible prodrome of the dreaded cardiorenal syndrome. Clearly, alterations of ultrasound patterns are evident across the venous system as right atrial pressures rise (Figure 1), and the ability to directly visualize IRVF gives credence to the concept that impediment to renal venous outflow can be identified and targeted for interventions. With the excitement of newer neurohormonal therapies and cardiac implantable electrical devices that provide mortality and morbidity benefits, these observations may remind us that the age-old cardiorenal hypothesis of “congestive” heart failure may still be relevant in the contemporary era (18), and that effective handling of salt and water by the nephrons requires an intact and intricate balance between both the inflow and outflow of the renal vasculature. Beyond altered autoregulation and neurohormonal activation, we need to better understand the evolution of these IRVF patterns in the natural history of cardiorenal syndrome, and should aim to develop targeted strategies that can better decongest the kidneys.

REPRINT REQUESTS AND CORRESPONDENCE: Dr. W.H. Wilson Tang, Heart and Vascular Institute, Cleveland Clinic, 9500 Euclid Avenue, Desk J3-4, Cleveland, Ohio 44195. E-mail: tangw@ccf.org.

REFERENCES

1. Metra M, Davison B, Bettari L, et al. Is worsening renal function an ominous prognostic sign in patients with acute heart failure? The role of congestion and its interaction with renal function. *Circ Heart Fail* 2012;5:54-62.
2. Damman K, van Deursen VM, Navis G, Voors AA, van Veldhuisen DJ, Hillege HL. Increased central venous pressure is associated with impaired renal function and mortality in a broad spectrum of patients with cardiovascular disease. *J Am Coll Cardiol* 2009;53:582-8.
3. Hanberg JS, Sury K, Wilson FP, et al. Reduced cardiac index is not the dominant driver of renal dysfunction in heart failure. *J Am Coll Cardiol* 2016;67:2199-208.
4. Mullens W, Abrahams Z, Francis GS, et al. Importance of venous congestion for worsening of renal function in advanced decompensated heart failure. *J Am Coll Cardiol* 2009;53:589-96.
5. Lee HF, Hsu LA, Chang CJ, et al. Prognostic significance of dilated inferior vena cava in advanced decompensated heart failure. *Int J Cardiovasc Imaging* 2014;30:1289-95.
6. Pellicori P, Carubelli V, Zhang J, et al. IVC diameter in patients with chronic heart failure: relationships and prognostic significance. *J Am Coll Cardiol Img* 2013;6:16-28.
7. Tsutsui RS, Borowski A, Tang WH, Thomas JD, Popovic ZB. Precision of echocardiographic estimates of right atrial pressure in patients with acute decompensated heart failure. *J Am Soc Echocardiogr* 2014;27:1072-8.e2.
8. Wei K, Le E, Bin JP, Coggins M, Thorpe J, Kaul S. Quantification of renal blood flow with contrast-enhanced ultrasound. *J Am Coll Cardiol* 2001;37:1135-40.
9. Ciccone MM, Iacoviello M, Gesualdo L, et al. The renal arterial resistance index: a marker of renal function with an independent and incremental role in predicting heart failure progression. *Eur J Heart Fail* 2014;16:210-6.
10. Ennezat PV, Marechaux S, Six-Carpentier M, et al. Renal resistance index and its prognostic significance in patients with heart failure with preserved ejection fraction. *Nephrol Dial Transplant* 2011;26:3908-13.
11. Bateman GA, Cuganesan R. Renal vein Doppler sonography of obstructive uropathy. *AJR Am J Roentgenol* 2002;178:921-5.
12. Oktar SO, Yucel C, Ozdemir H, Karaosmanoglu D. Doppler sonography of renal obstruction: value of

venous impedance index measurements. *J Ultrasound Med* 2004;23:929-36.

13. Jeong SH, Jung DC, Kim SH. Renal venous Doppler ultrasonography in normal subjects and patients with diabetic nephropathy: value of venous impedance index measurements. *J Clin Ultrasound* 2011;39:512-8.

14. Iida N, Seo Y, Sai S, et al. Clinical implications of intrarenal hemodynamic evaluation by Doppler ultrasonography in heart failure. *J Am Coll Cardiol HF* 2016;4:674-82.

15. Karabulut N, Baki Yagci A, Karabulut A. Renal vein Doppler ultrasound of maternal kidneys in normal second and third trimester pregnancy. *Br J Radiol* 2003;76:444-7.

16. Testani JM, Brisco MA, Chen J, McCauley BD, Parikh CR, Tang WH. Timing of hemoconcentration during treatment of acute decompensated heart failure and subsequent survival: importance of sustained decongestion. *J Am Coll Cardiol* 2013;62:516-24.

17. Testani JM, Chen J, McCauley BD, Kimmel SE, Shannon RP. Potential effects of aggressive

decongestion during the treatment of decompensated heart failure on renal function and survival. *Circulation* 2010;122:265-72.

18. Dupont M, Mullens W, Tang WH. Impact of systemic venous congestion in heart failure. *Curr Heart Fail Rep* 2011;8:233-41.

KEY WORDS cardiorenal syndrome, Doppler ultrasound, heart failure, prognosis, renal congestion