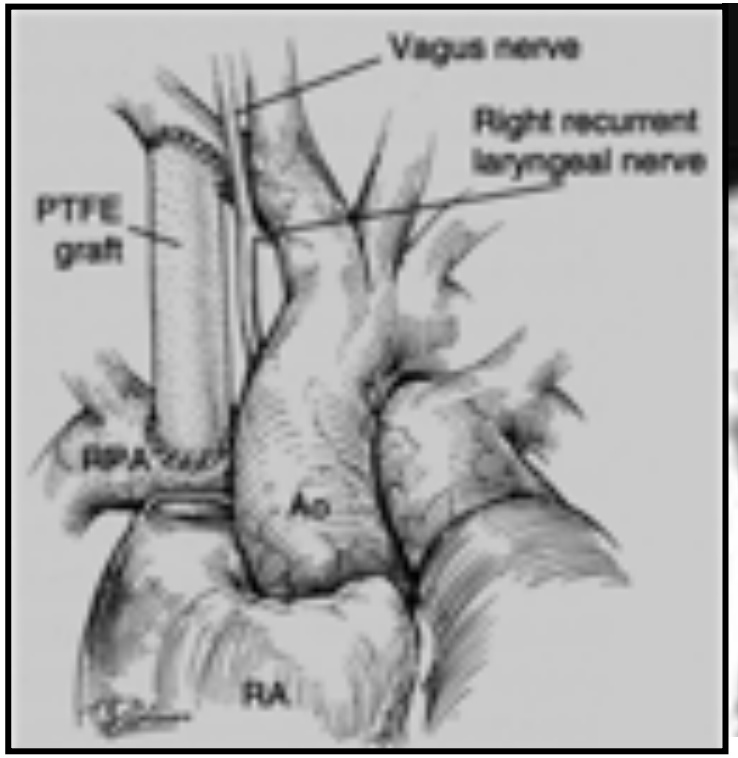

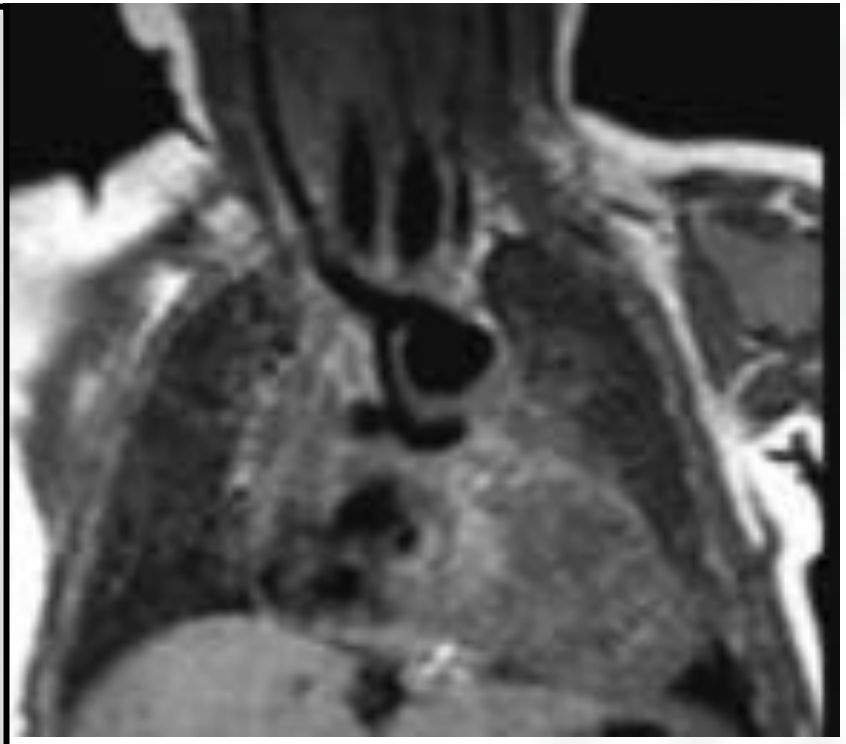

CREATION DE SHUNTS

Drs. Xavier Iriart / Zakaria Jalal

Service des cardiopathies congénitales de l'enfant et de l'adulte- Hôpital cardiologique Haut Lévêque - Bordeaux

Duct dependent Pulmonary Blood Flow

- Anatomy: Atresia/Hypoplasia of Right Heart structures (Tric/ pulm Atresia)

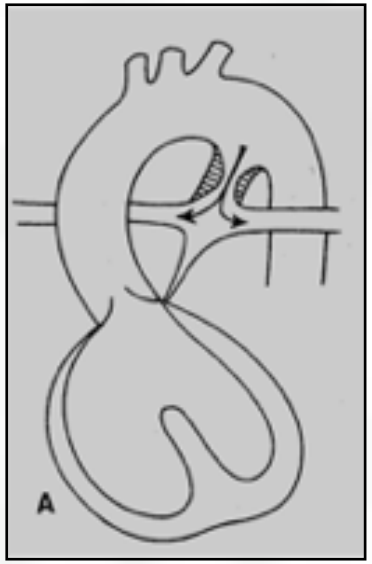

- **Immediate** action to establish **adequate** Pulmonary Blood Flow
  - Prostaglandin to maintain ductal patency
    - Flow: Aorta to Pulmonary artery

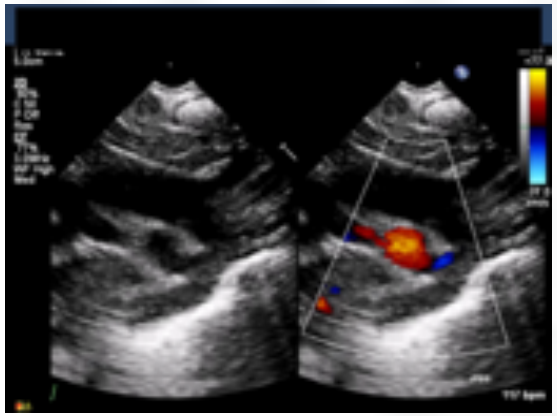

- Subsequent need for **Reliable** Pulmonary Blood Flow
  - Modified BT shunt
  - PDA stent

Single ventricle physiology

Palliation for UVH in the 1950–1960s

- large systemic to pulmonary artery (PA) shunts for adequate long-term relief of cyanosis
- dictum: “as pink as possible for as long as possible”
- few survivors beyond the 4th decade

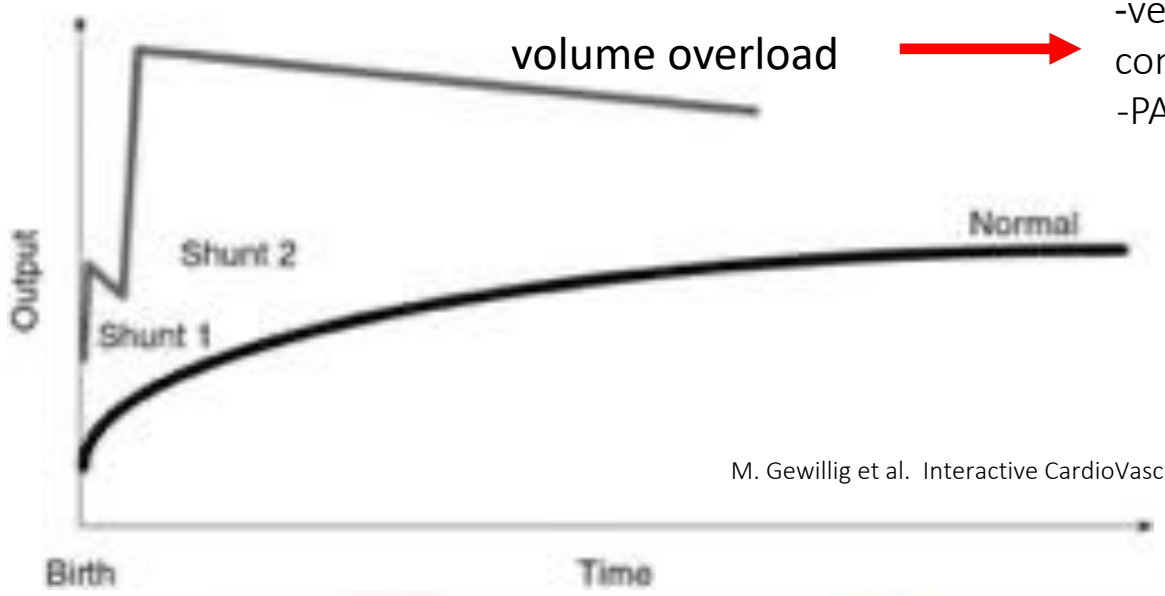

-ventricular dysfunction-
congestive HF
-PAH

M. Gewillig et al. Interactive CardioVascular and Thoracic Surgery 2010

The Fontan operation

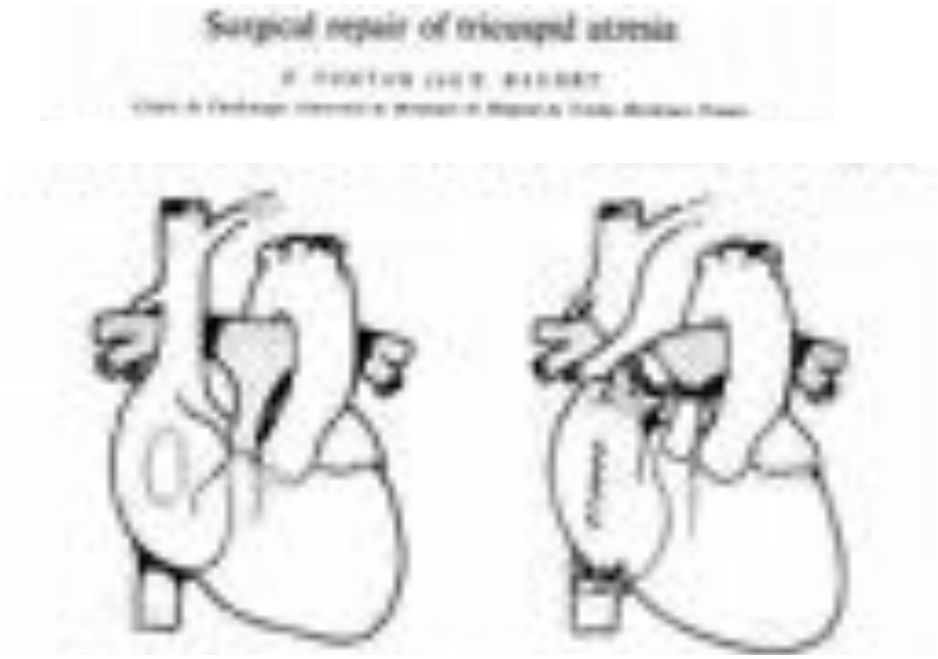

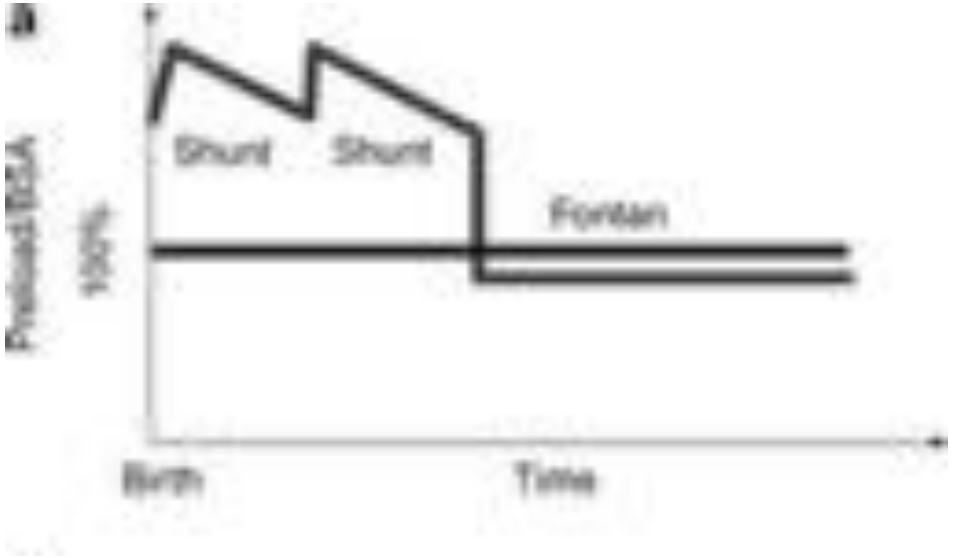

Emphasis shifted towards reducing the volume load of the ventricle

M. Gewillig et al. Interactive CardioVascular and Thoracic Surgery 2010
Fontan et al. Ann Chir Thorac Cardiovasc 1971

UVH physiology: current strategy

- From 1990's: **The staged palliation**
  - early placement of a PCPC (Glenn)
- Technical modifications
  - Smaller neonatal shunt lasting few months
- Clinical outcomes improvements
- The dictum: "as blue as possible" in order to keep the ventricle maximally unloaded.

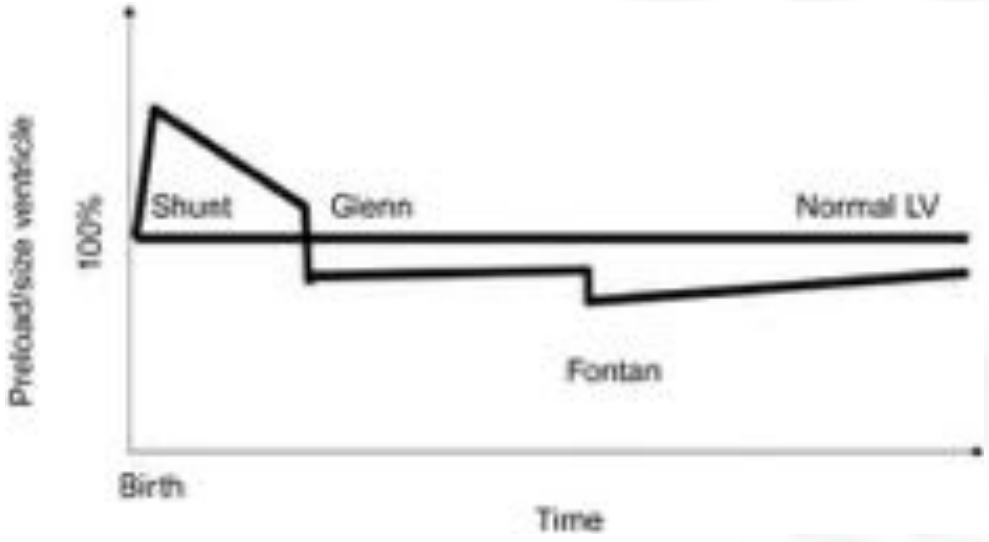

Emphasis further shifted to limitation of volume load as early as possible.

M. Gewillig et al. Interactive CardioVascular and Thoracic Surgery 2010

CREATION DE SHUNT AO/AP → *CAHIER DES CHARGES:*

Implique d'assurer (si possible) une balance QP/QS proche de 1

Objectif: optimisation de la DO2 = Qc x CaO2 :

1) **Oxygénation tissulaire satisfaisante (SaO2 = 75-80%)**
2) **Perfusion systémique optimale (SvO2 = 45-60%)**

BUT, A TERME:

- assurer la survie de l'enfant dans l'attente de la correction complète

- équilibre QP/QS # 1, gage de:

**** préservation de la fonction du futur ventricule systémique ?***

**** en corollaire, pas de fuite de la valve auriculo-ventriculaire systémique ?***

**** préservation du lit vasculaire pulmonaire (cf. futur FONTAN) ?***

**** attention à la distorsion des artères pulmonaires (cf. sténose AP)***

Duct dependent Pulmonary Blood Flow

- First SPS: direct connection between SCA and ipsilateral PA
- Frequent complications
  - Unpredictibility of shunt flow
  - PA branch distortion

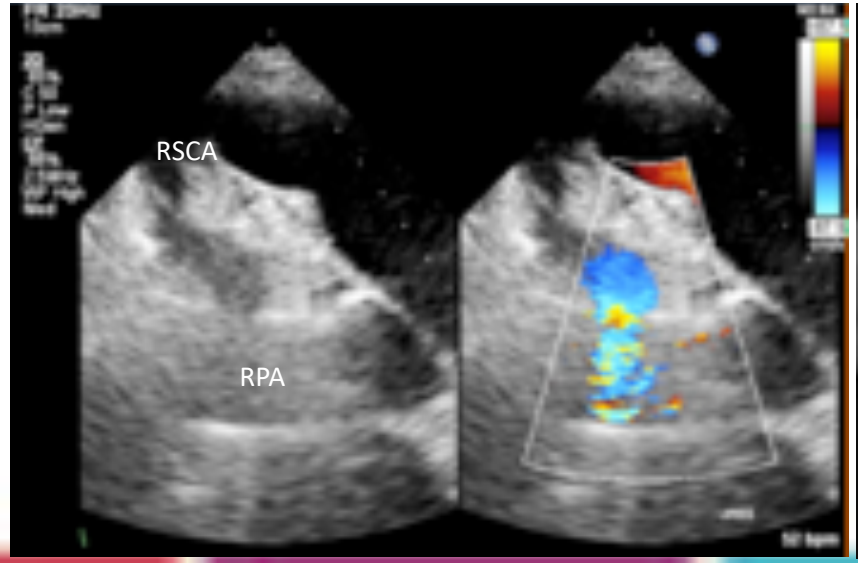

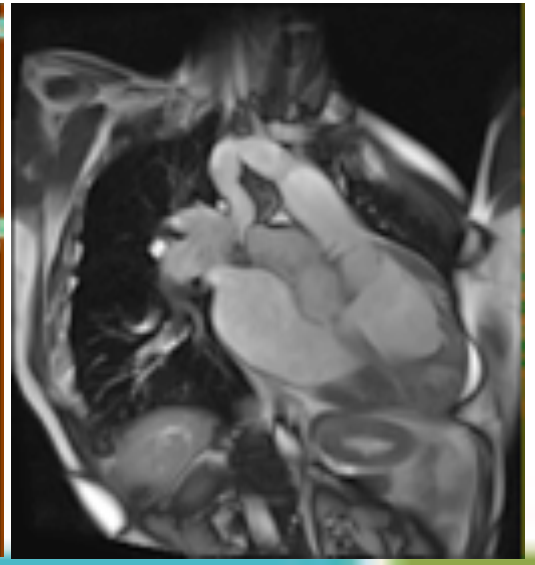

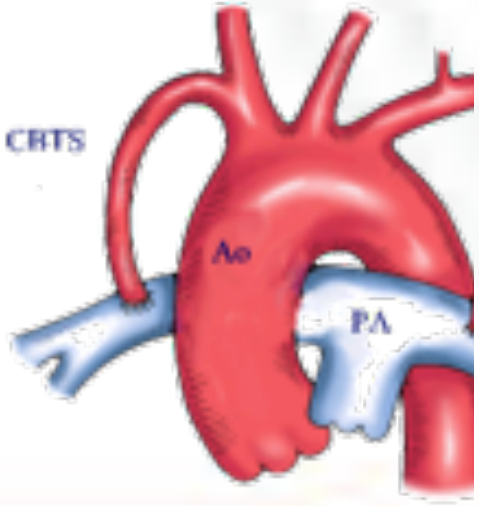

Systemic to pulmonary shunt

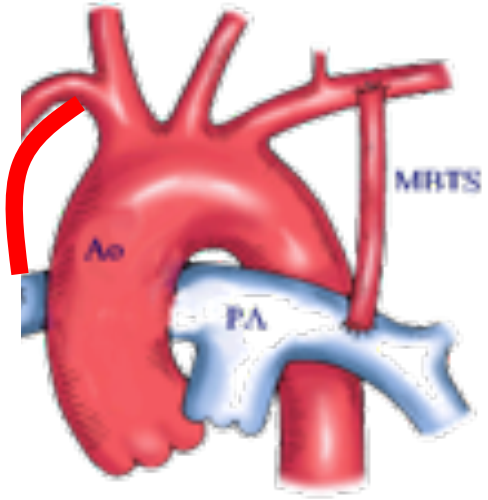

- modified BT shunt: prosthetic PTFE graft (Ø3-4mm)
- Innominate artery or SCA connected to ipsilateral PA branch
- Echo: suprasternal frontal view/ color doppler/ CW doppler

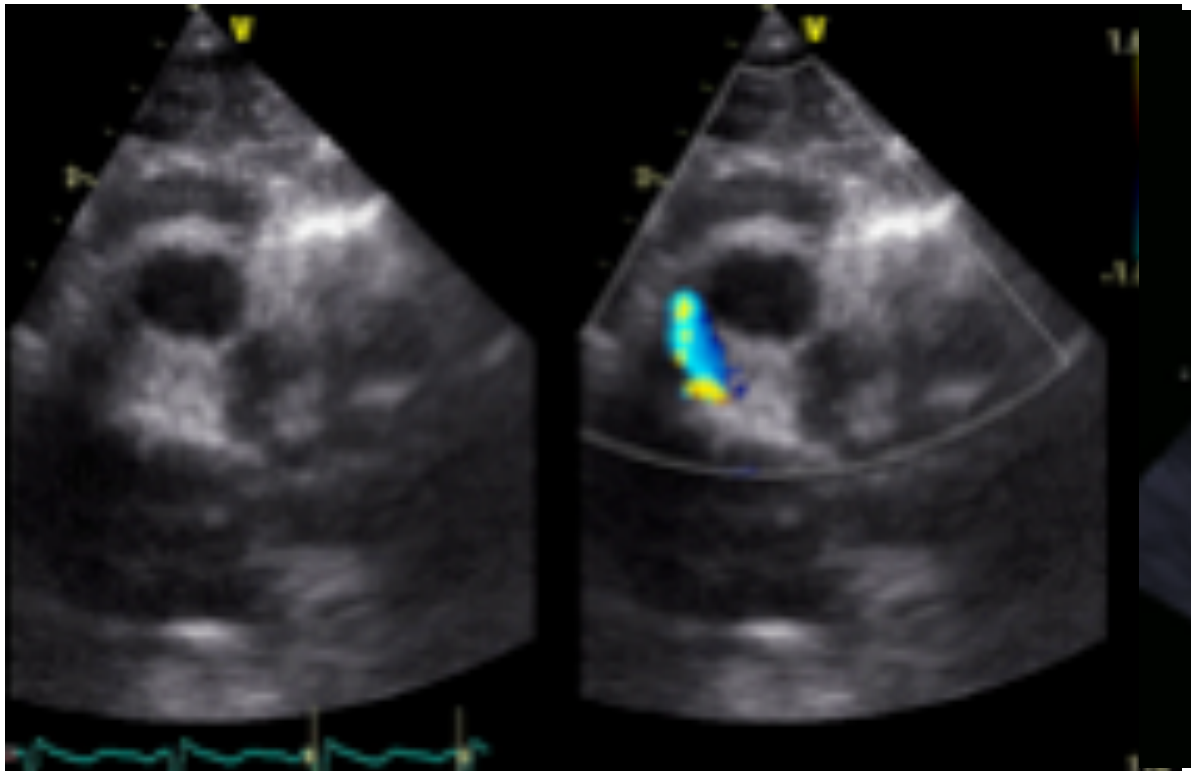

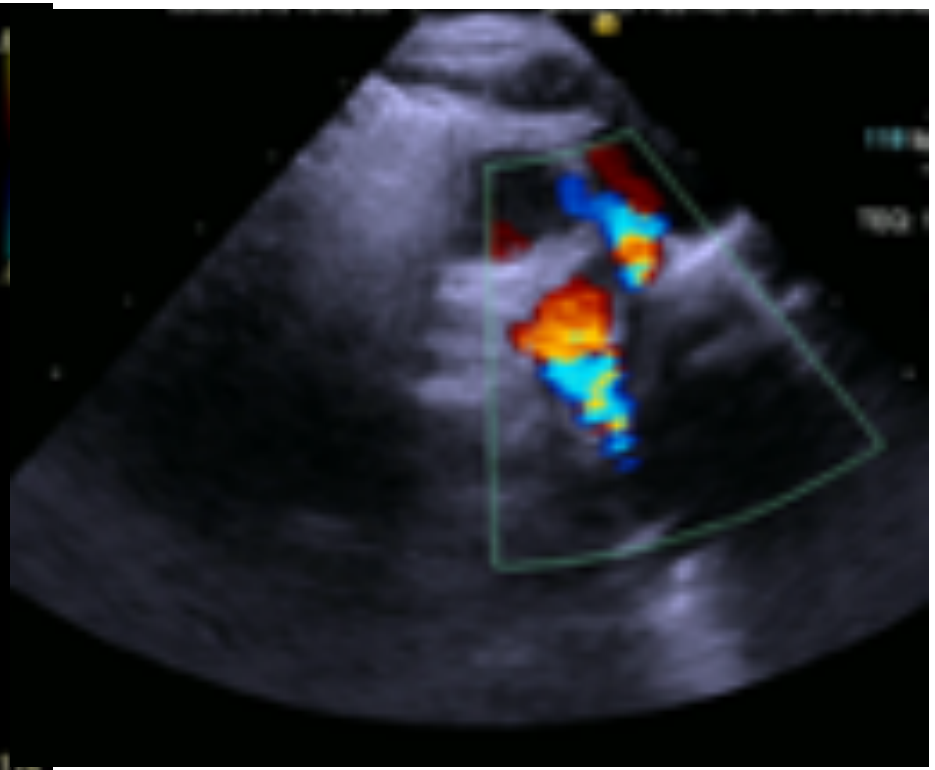

Systemic to pulmonary shunt

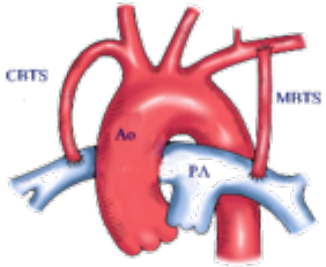

- Imaging: CW doppler: characteristic sawtooth doppler pattern

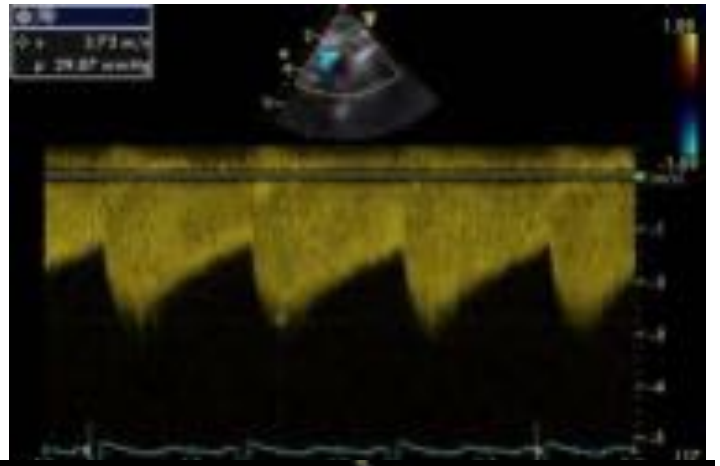

- Potential anomalies: distortion of inn Artery or PA branch, narrowing of prox or distal anastomosis (challenging)

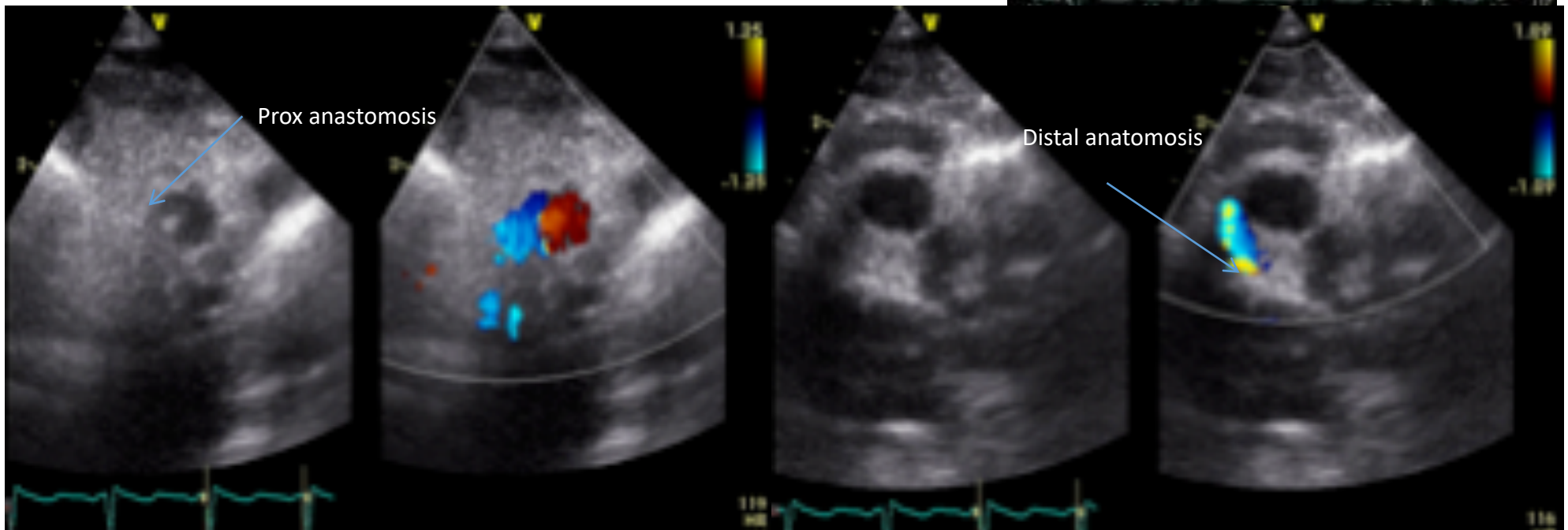


« NORWOOD »: Analyse DOPPLER

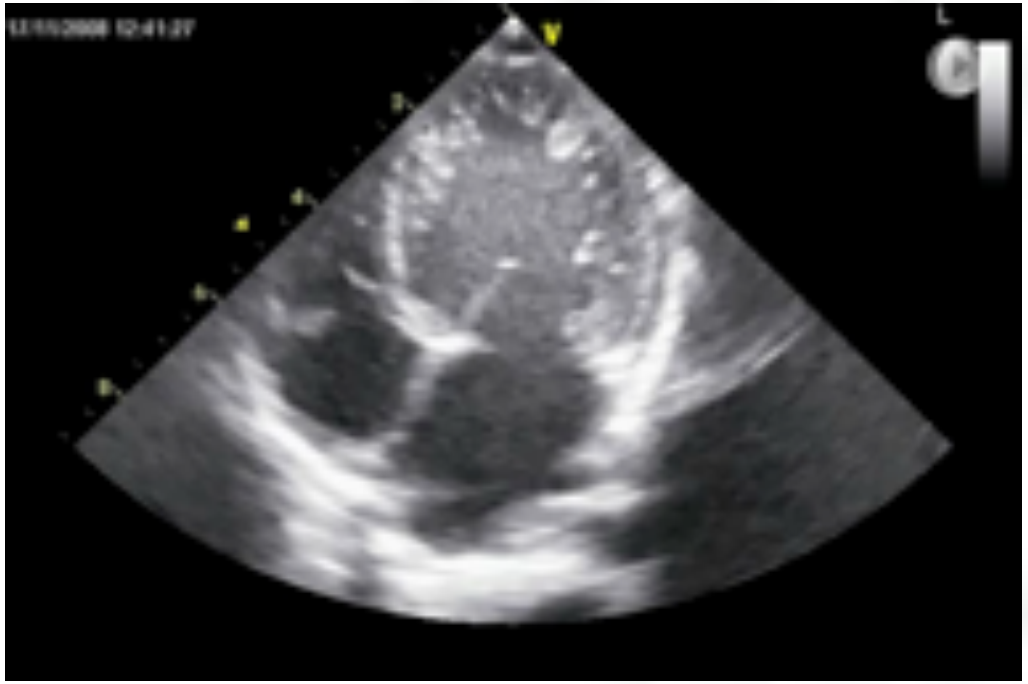

L'échographie est indissociable de la clinique

- Données cliniques: évaluation du QP/QS, NIRS, diurèse horaire
- Données biologiques: lactates, fonction rénale, troponines
- Le gradient doppler dépendent:
  - De l'hémodynamique: FE, PA, PAP, RVP, volémie
  - De l'anatomie: taille des AP
  - De la chirurgie: taille, longueur, position du blalock
  - De la rhéologie: Ht, volémie
  - De la ventilation
  - L'équation simplifiée de Bernouilli n'est pas applicable pour la mesure des gradients

Comprendre la physiologie

Anesthésie
Myorelaxation
Hypothermie
Douleur

- $SvO2 = \frac{Sa02 - VO2}{Qc.(Hb)k}$

hyperthermie
Acidose
Hypercapnie
K=1.34

Précharge
Postcharge
Inotropisme
FC

Hémorragie
Hemodilution
Transfusion

- QP/QS= SaO2 Ao-(SVO2 VCS+VCI/2) / SaO2 VP- SvO2 AP

- Physiologie normale: SaO2 Ao et VP 100%, SvO2 70% (VC=AP) (difficile à évaluer dans cette physiologie)

Visualisation of shunt and PAs

- If there is doubt or for planning next stage of surgery
- CT / MRI / Catheter
- To delineate shunt and branch PA anatomy

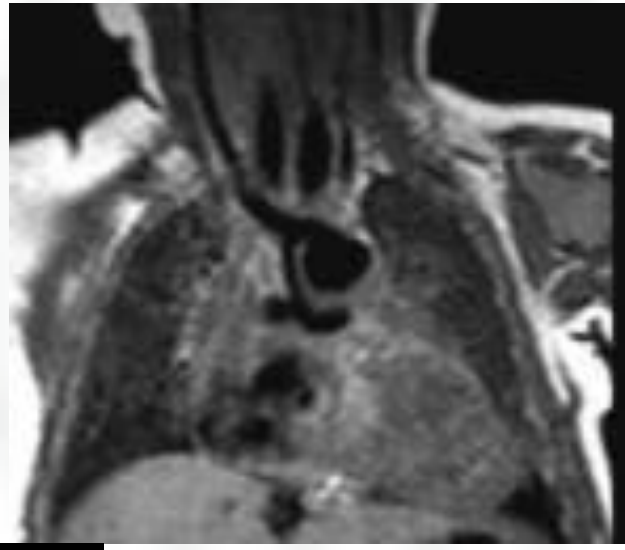

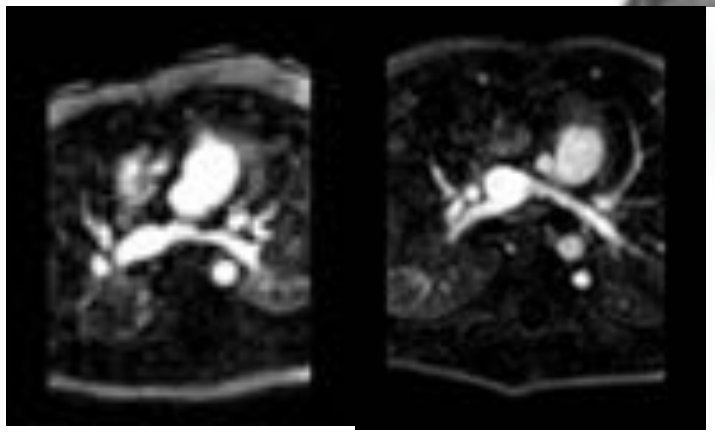

ALTERNATIVE AU BT SHUNT:DUCT STENTING

Pulmonary atresia with IVS. Severe hypoplastic RV. Duct dependent pulmonary flow

Weight 2kg. O2 Saturation 88% under PGE1

Stop PGE1 6h before the procedure

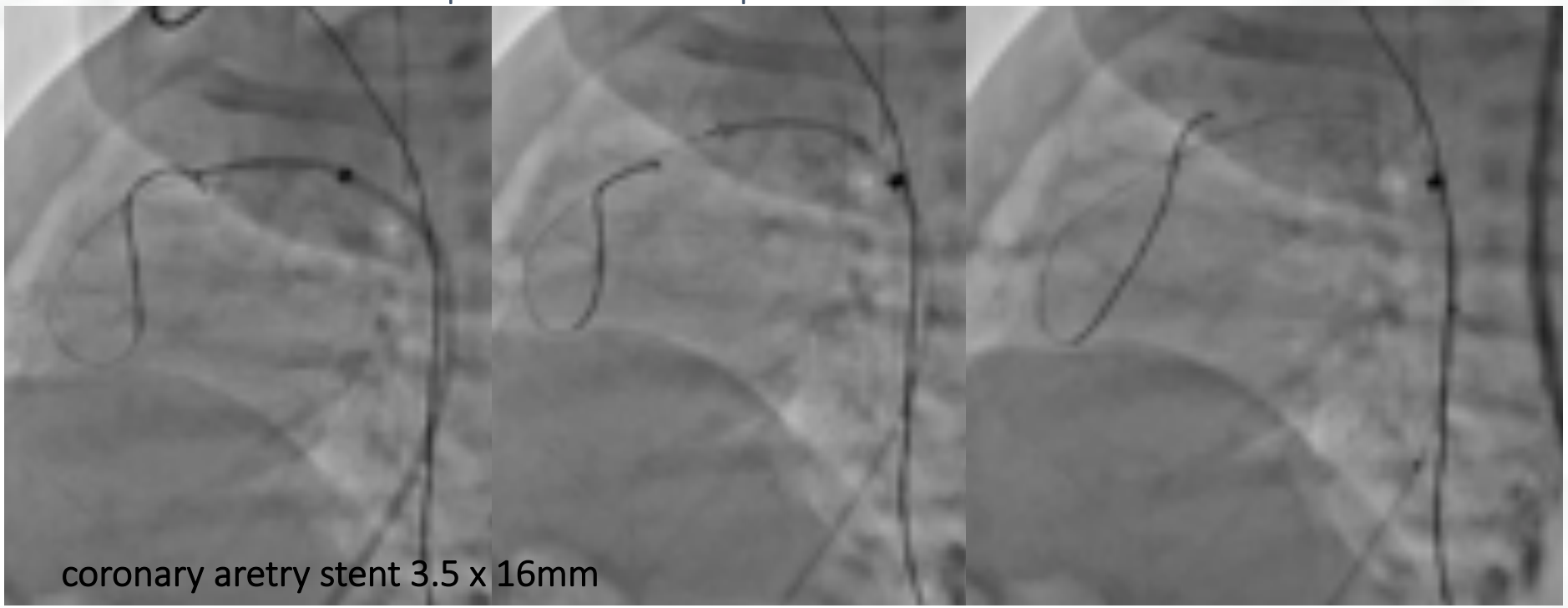

Discharge Day 5 O2 Sat85-90%

DUCT STENTING

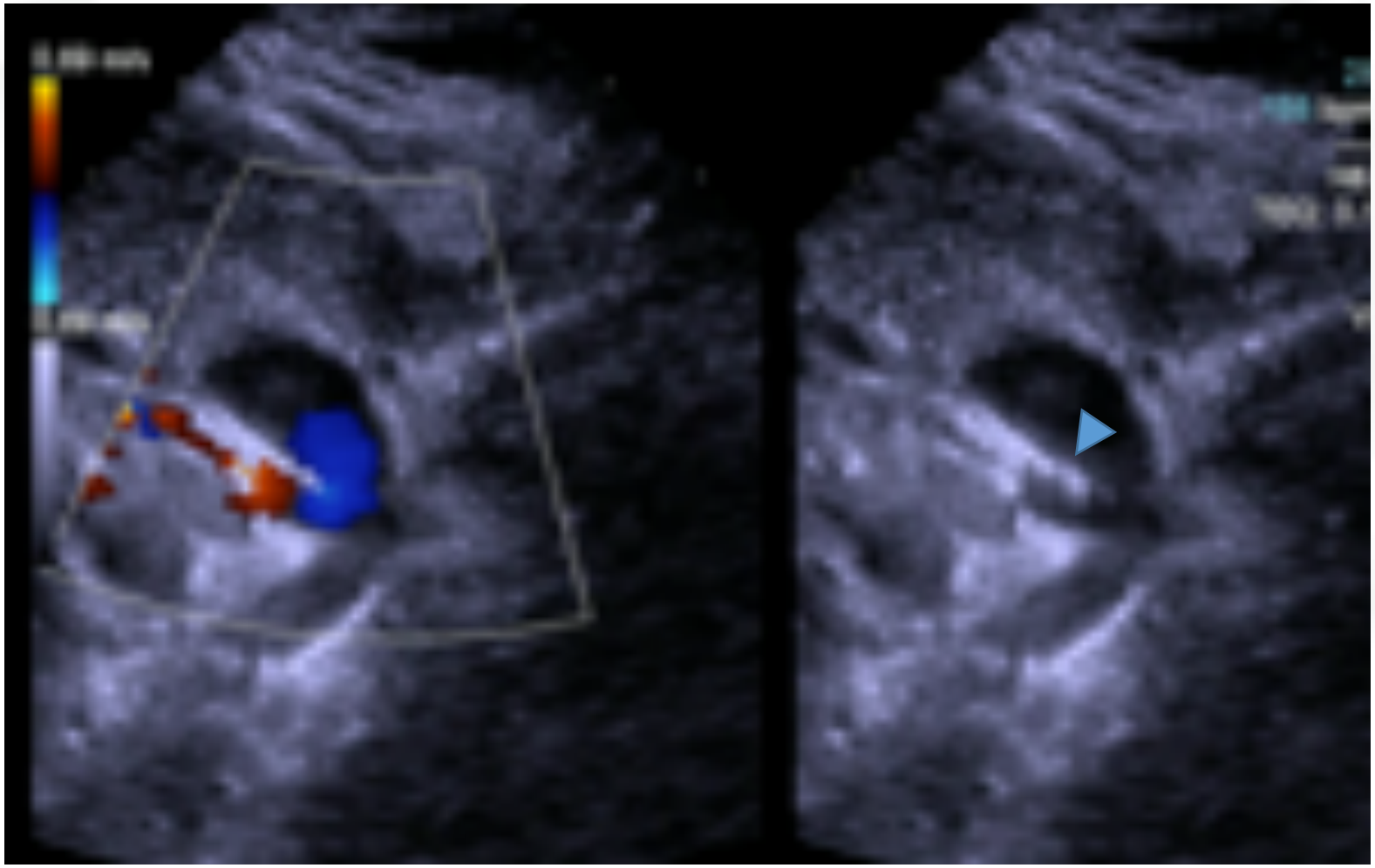

DUCT STENTING

- Acute desaturation at 3 months 60 vs 85%
- Increased peak velocity from 3.5 to 5m/s

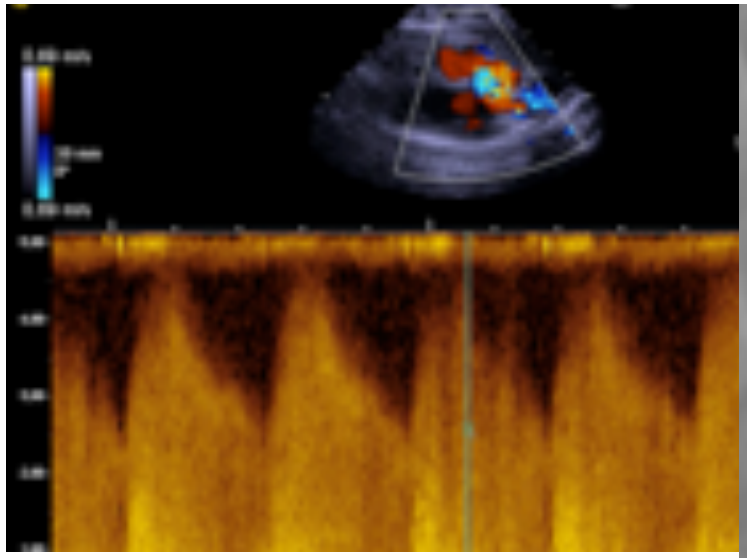

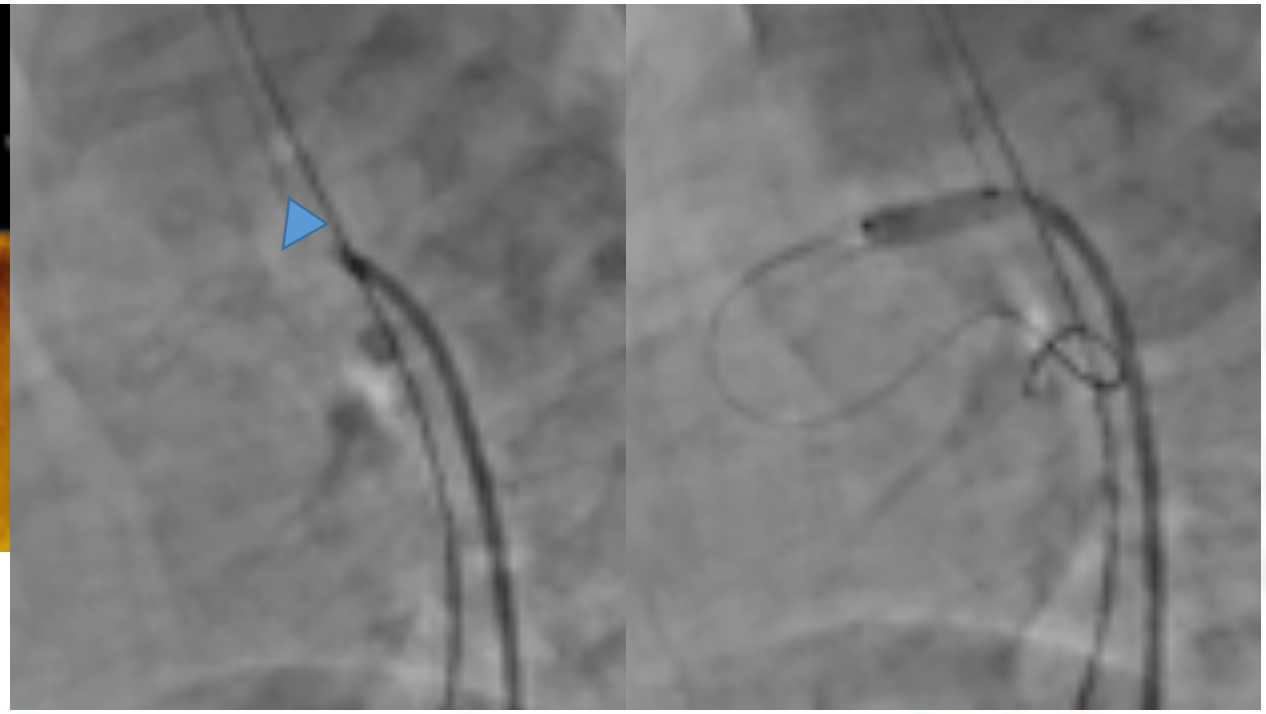

Additional stent on the aortic side

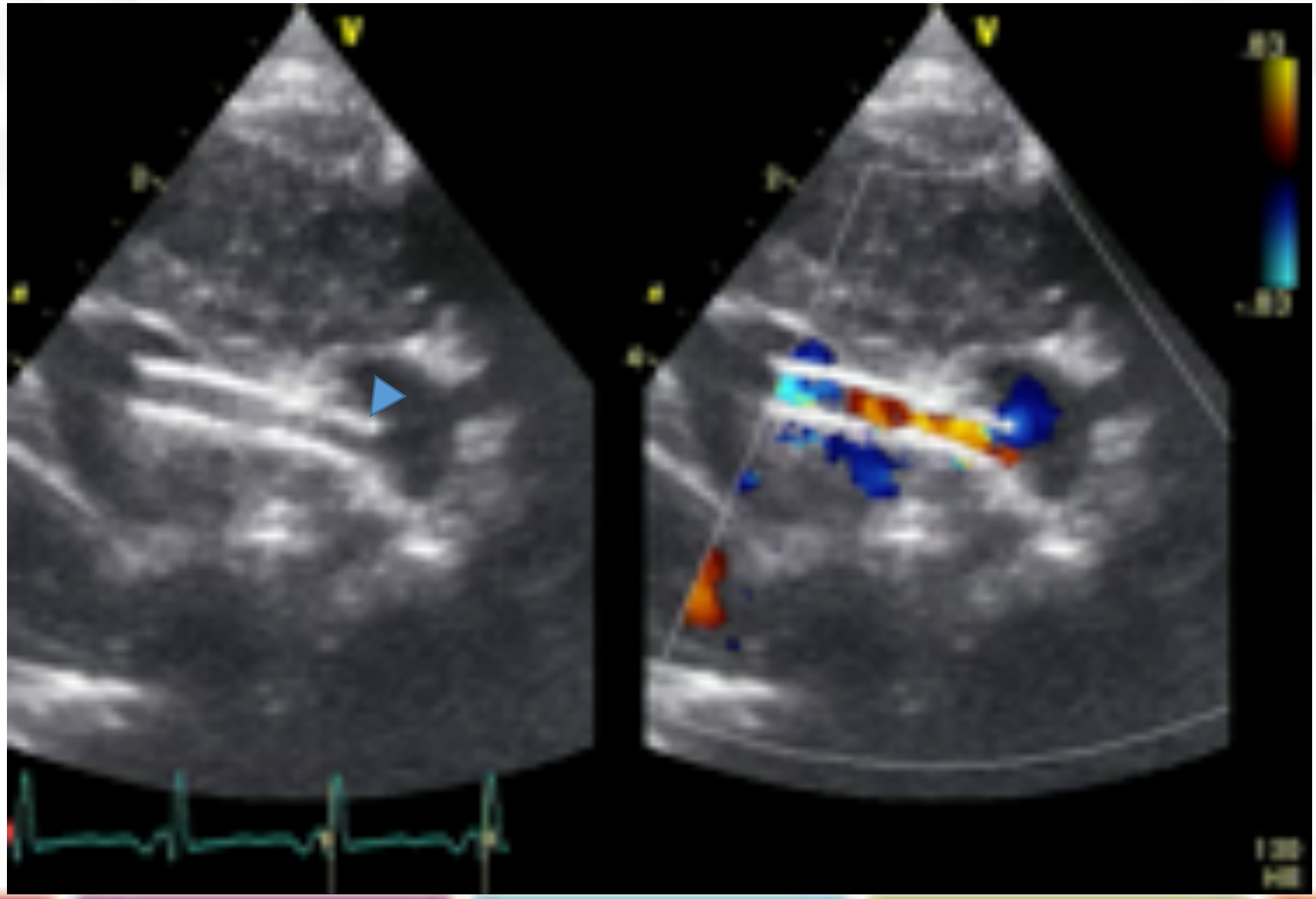

OBSTACLE INFUNDIBULAIRE

SIÈGE DE L'OBSTACLE

INFUNDIBULUM
Stenting RVOT

RATIONNEL

- Ouverture VD-AP sans CEC
- Eviter les effets délétères des shunts

LIMITES

- Taille du stent (hyper/hypodébit)
- Abord vasculaire
- Sélection des patients

CAS CLINIQUE

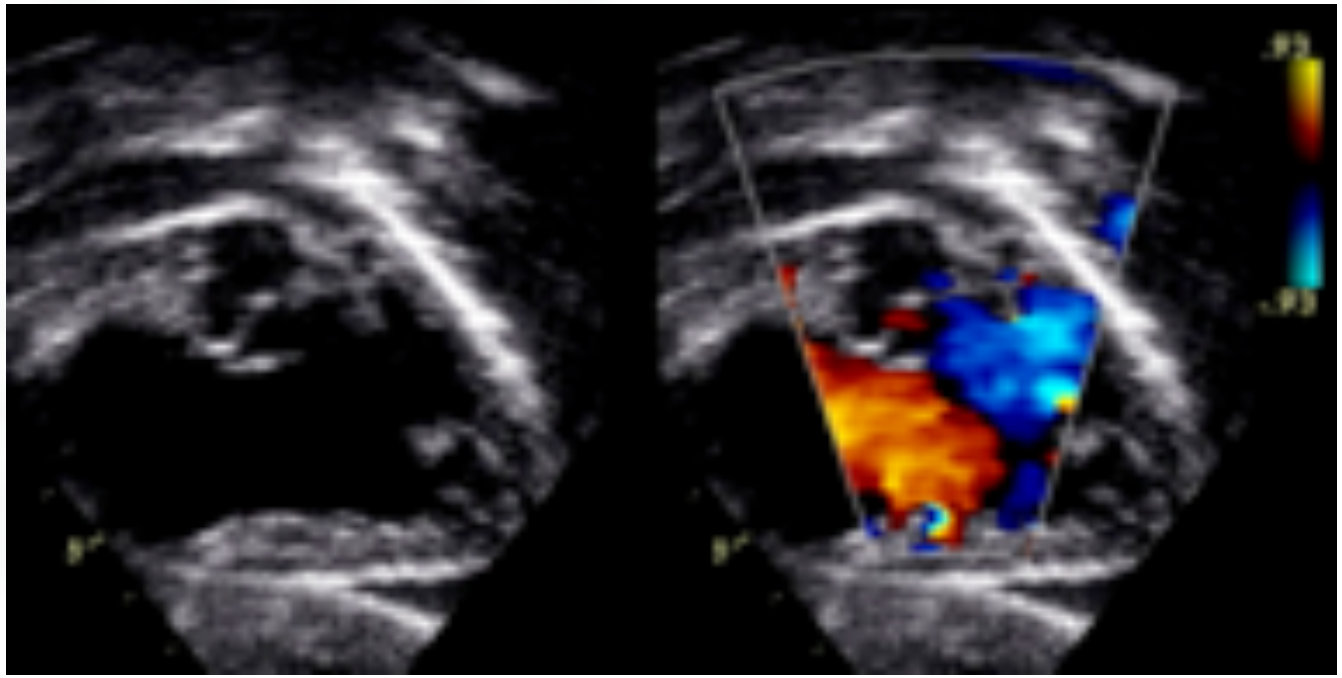

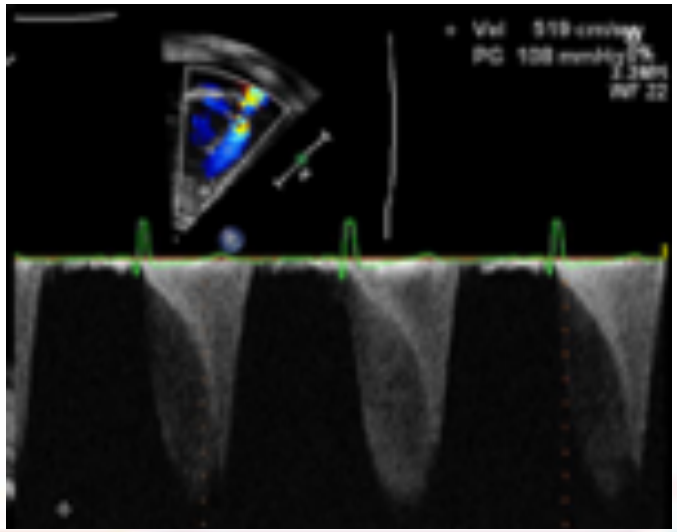

- TOF, Diagnostic anténatal
- Prématurité 30 SA, PN=1800g
- Saturation: 68%, obstacle infundibulaire +++
- PGE1
- Discussion médico-chirurgicale
  - Anastomose systémico-pulmonaire
  - Ouverture VD-AP
  - Stenting infundibulaire
- => Stenting VD-AP par Abord hybride

CAS CLINIQUE

CAS CLINIQUE

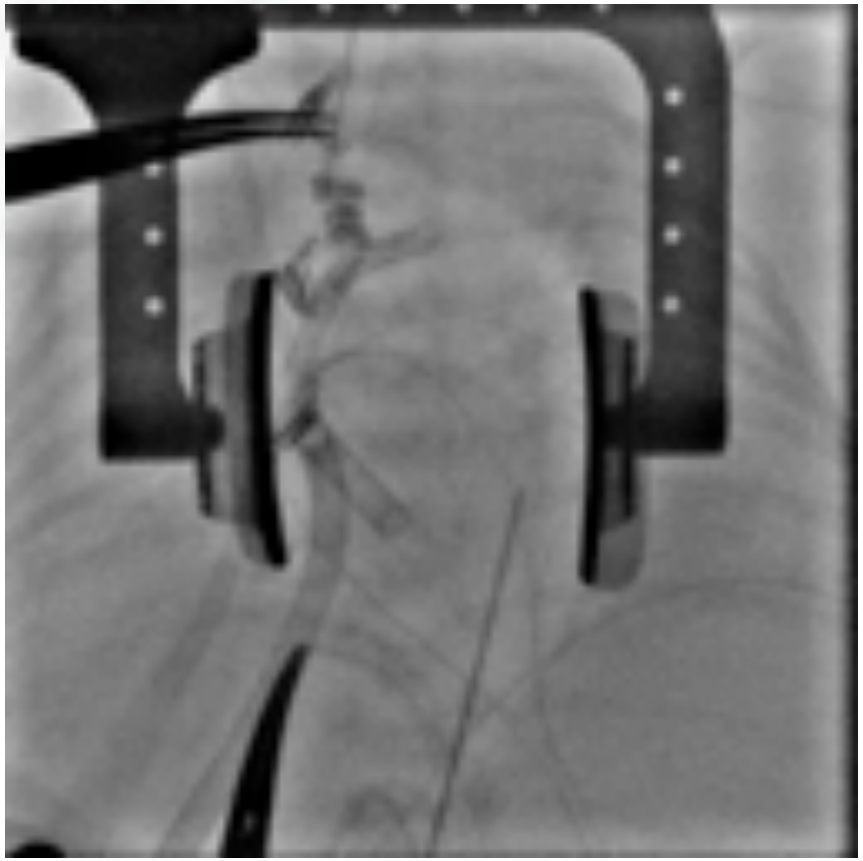

Stent Coronaire 5 x 20-mm

CAS CLINIQUE

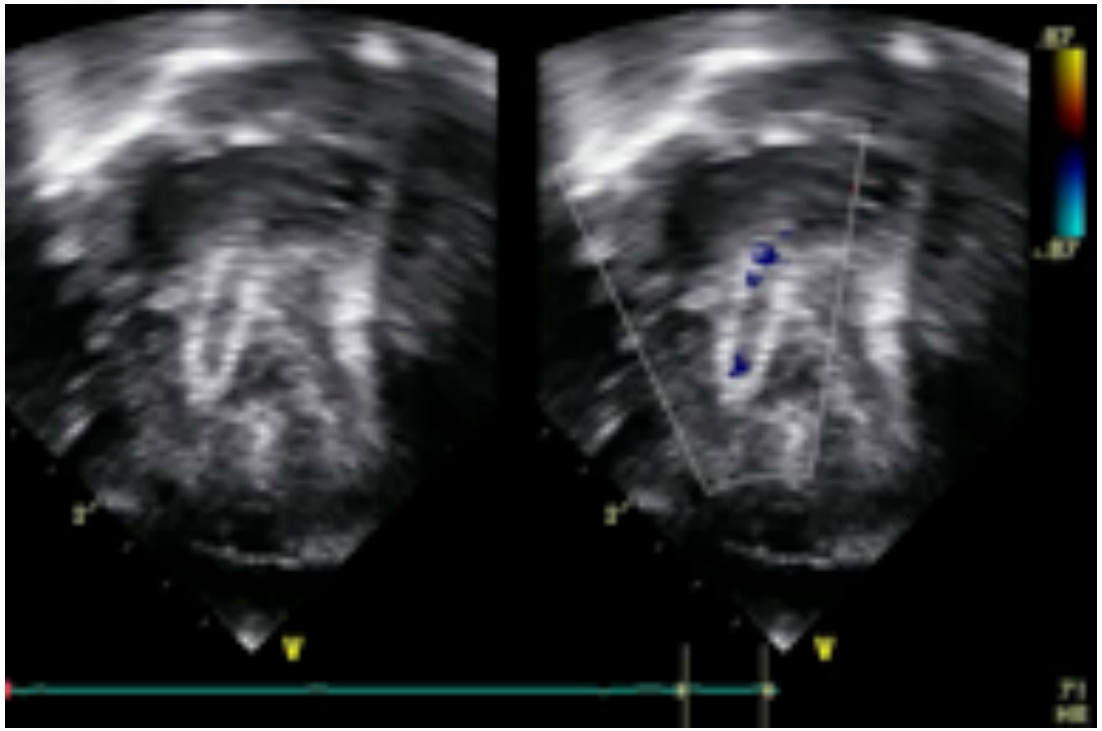

OBSTACLE VALVULAIRE

SIÈGE DE L'OBSTACLE

VALVE
Dilatation
Perforation

STÉNOSE PULMONAIRE CRITIQUE vs ATRÉSIE PULMONAIRE À SEPTUM INTACT

OBSTACLE VALVULAIRE

Recommendations for Pulmonary Valvuloplasty

Class I

1. Pulmonary valvuloplasty is indicated for a patient with critical valvar pulmonary stenosis (defined as pulmonary stenosis present at birth with cyanosis and evidence of patent ductus arteriosus dependency), valvar pulmonic stenosis, and a peak-to-peak catheter gradient or echocardiographic peak instantaneous gradient of ≥40 mm Hg or clinically significant pulmonary valvar obstruction in the presence of RV dysfunction *(Level of Evidence: A)*.

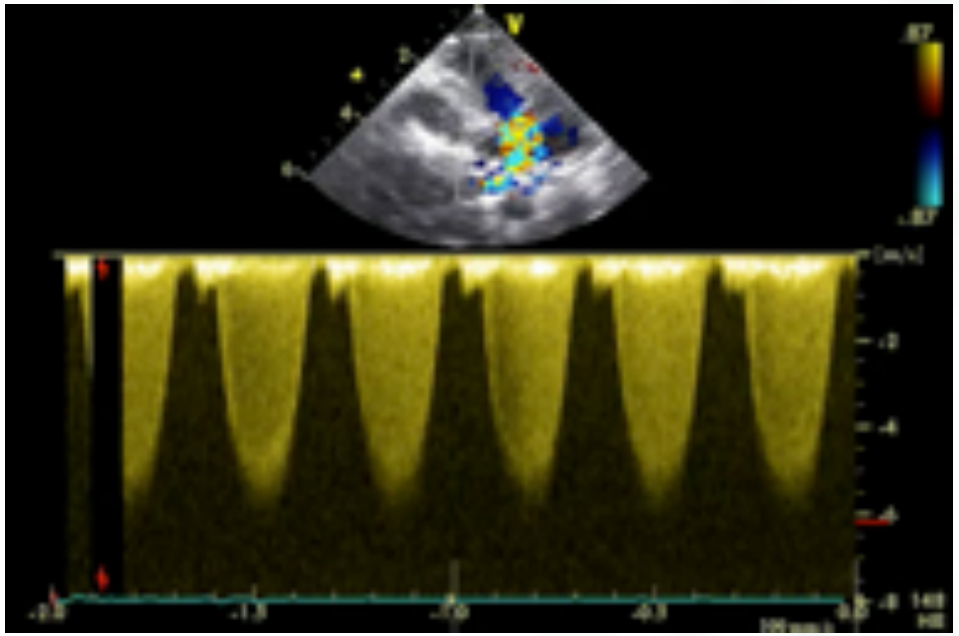

Class IIb

1. Pulmonary valvuloplasty may be considered as a palliative procedure in a patient with complex cyanotic CHD, including some rare cases of tetralogy of Fallot *(Level of Evidence: C)*.

OBSTACLE VALVULAIRE

VALVULOPLASTIE AU BALLON
Taille Ballon = 120 à 150% de l'anneau

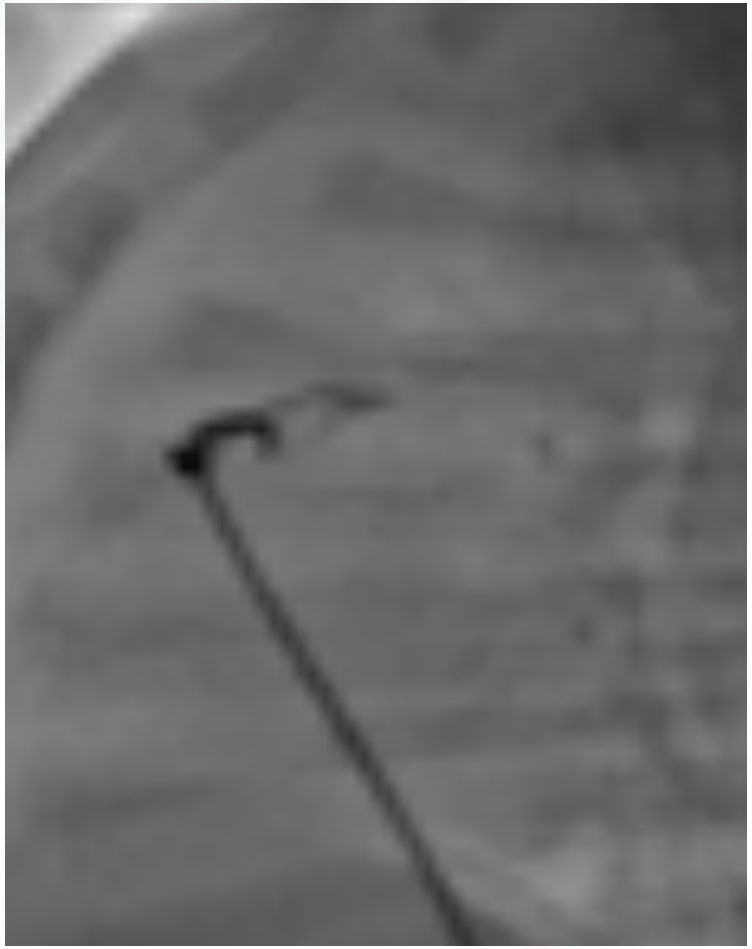

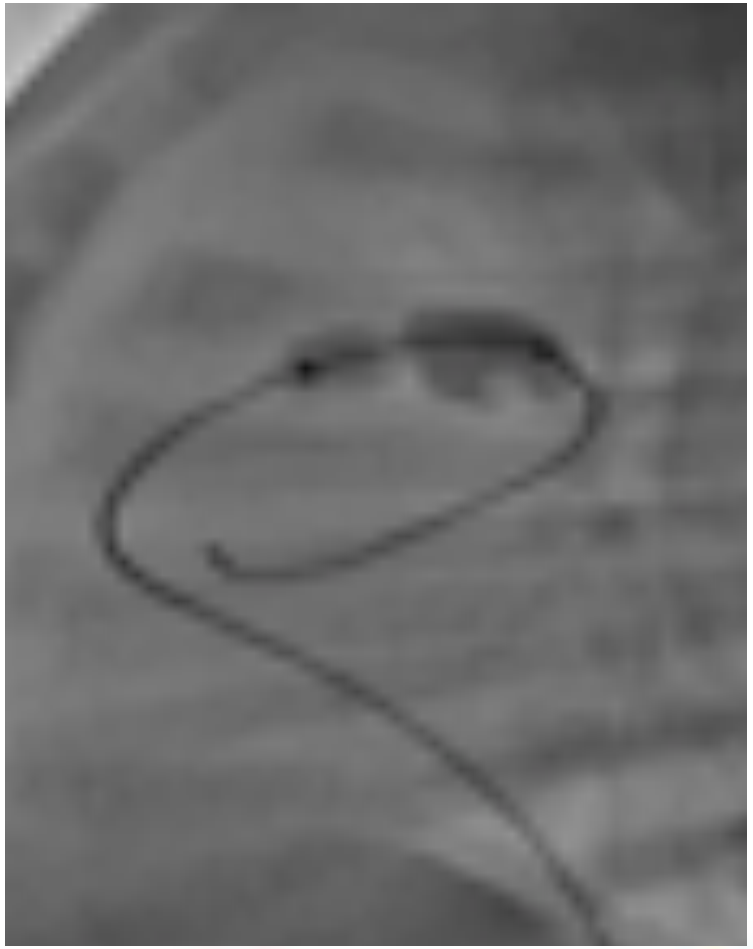

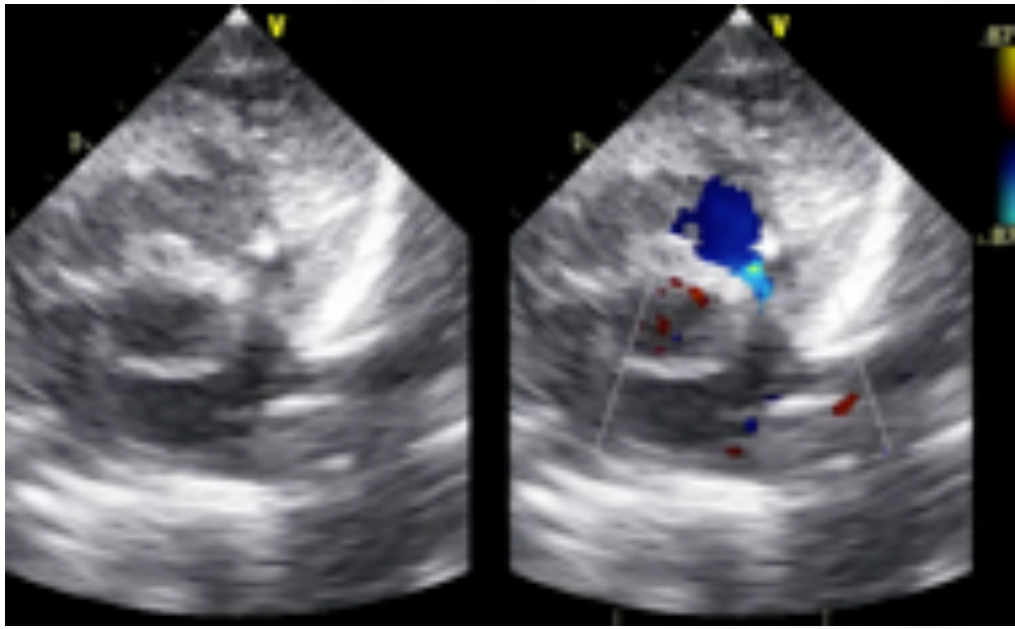

Succès > 95% (Noonan)
Complications faibles

PERFORATION APSI - RESULTATS

Outcomes of Transcatheter Approach for Initial Treatment of Pulmonary Atresia with Intact Ventricular Septum

Transcatheter pulmonary valvuloplasty in neonates with pulmonary atresia and intact ventricular septum

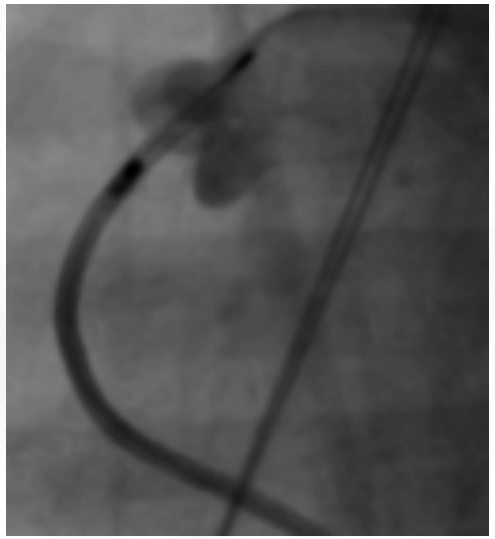

- Séries modestes: n=26 à 29 patients
- 79 à 87% de succès
- Complications :
  - 0 à 24% de mortalité péri-interventionnelle
  - 17 à 25% de complications (perforation infundibulum, perforation TAP, tamponnade)

Hasan et al.CCI 2013
Hascoet et al. ACVD 2019

PERFORATION APSI - RESULTATS

Outcomes of Transcatheter Approach for Initial Treatment of Pulmonary Atresia with Intact Ventricular Septum

Transcatheter pulmonary valvuloplasty in neonates with pulmonary atresia and intact ventricular septum

- Nécessité d'une chirurgie malgré succès de perforation: 23 à 62%
- Facteur pronostic: Z- score de l'anneau tricusupide
- Circulation biventriculaire finale: 81 à 91%
- Données encore peu nombreuses et disparates

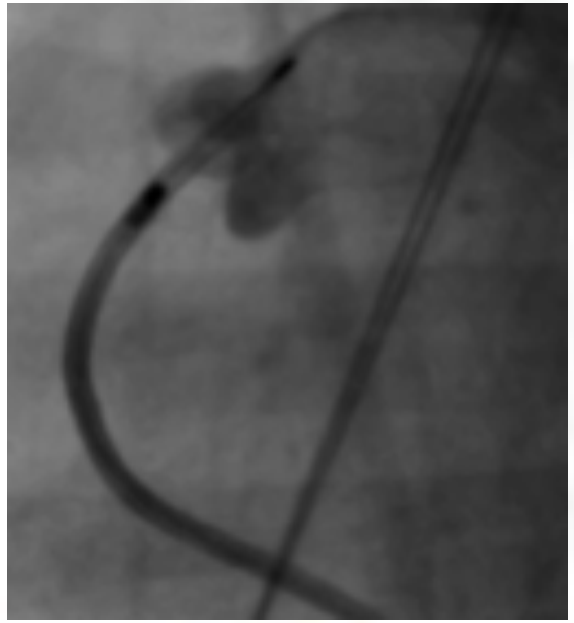

Hasan et al.CCI 2013
Hascoet et al. ACVD 2019

GESTION DES COMPLICATIONS

CAS CLINIQUE

- Diagnostic anténatal de VU avec sténose pulmonaire
- Naissance à 36 SA, PN = 3.6kg, $SatO^2$ = 86%

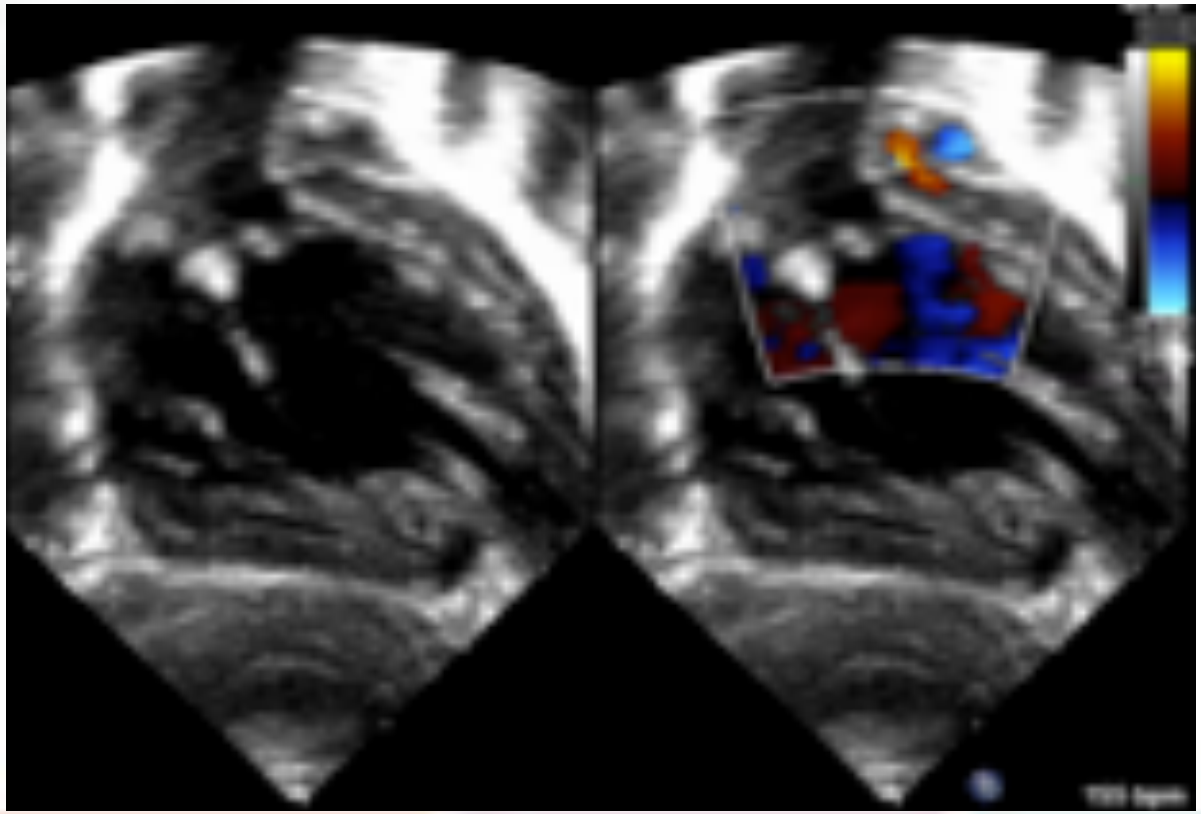

Post natal:

- VU type gauche à double entrée
- Vaisseaux normo posés
- Foramen bulbo-ventriculaire restrictif:

sténose sous valvulaire pulmonaire

S4: P=4kg, Sat=70%, malaises

BT droit 3.5mm, sternotomie

CAS CLINIQUE

- Suites HD et respiratoires simples
- Désunion cicatrice: soins locaux + ATB
- J15 PO: retrait VVC jugulaire droite-> Désaturation à 40-50 %
- Souffle de BT disparu, BT non visible en ETT

Suspicion de thrombose aigue de BT

Embole systémique sur thrombose VVC?

- HNF Bolus puis IVSE, Aspirine IV, Remplissage

Pas d'effet, signes d'insuffisance circulatoire

Attitude?

CAS CLINIQUE

Thrombose aigue, caillot frais

Désobstruction

CAS CLINIQUE

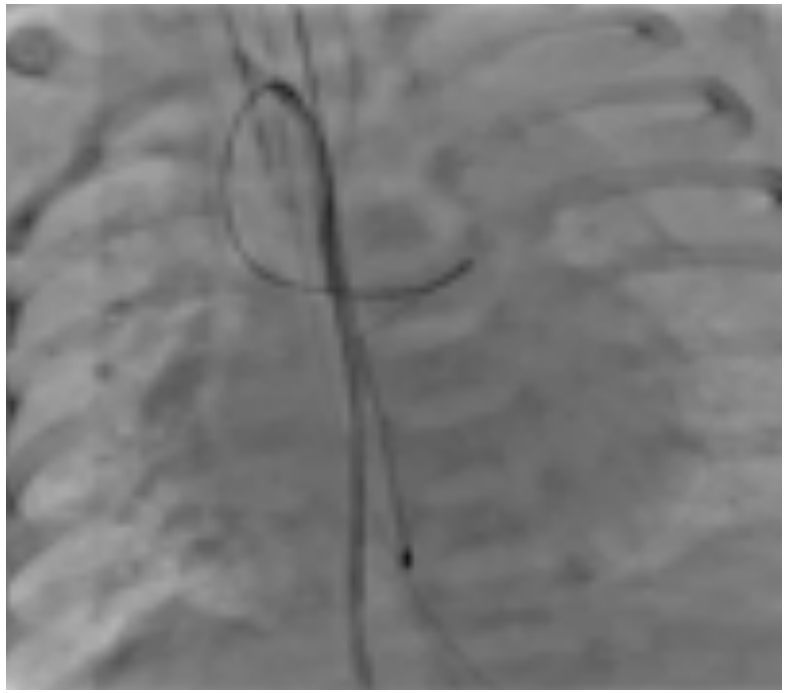

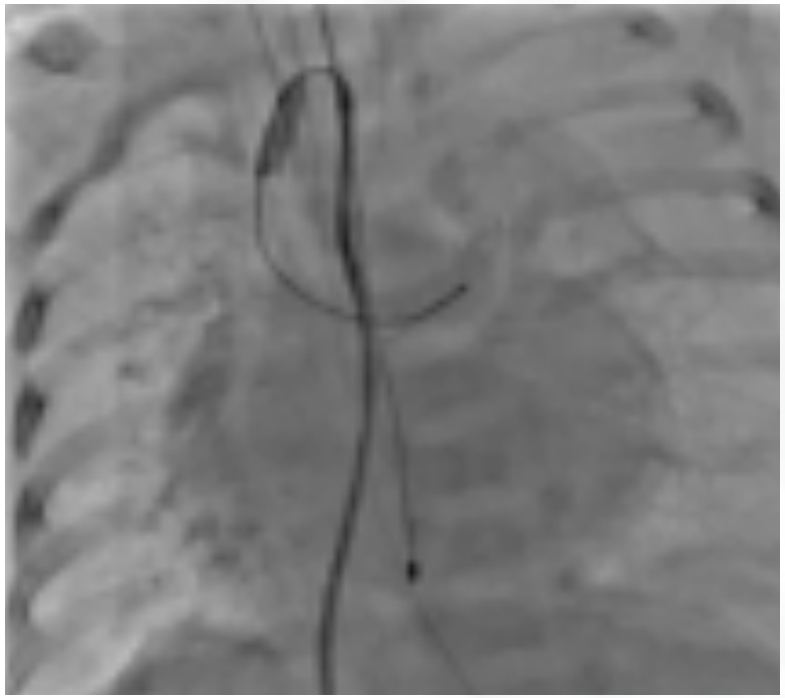

Implantation de 2 stents coronaires (3.5mm)

CAS CLINIQUE

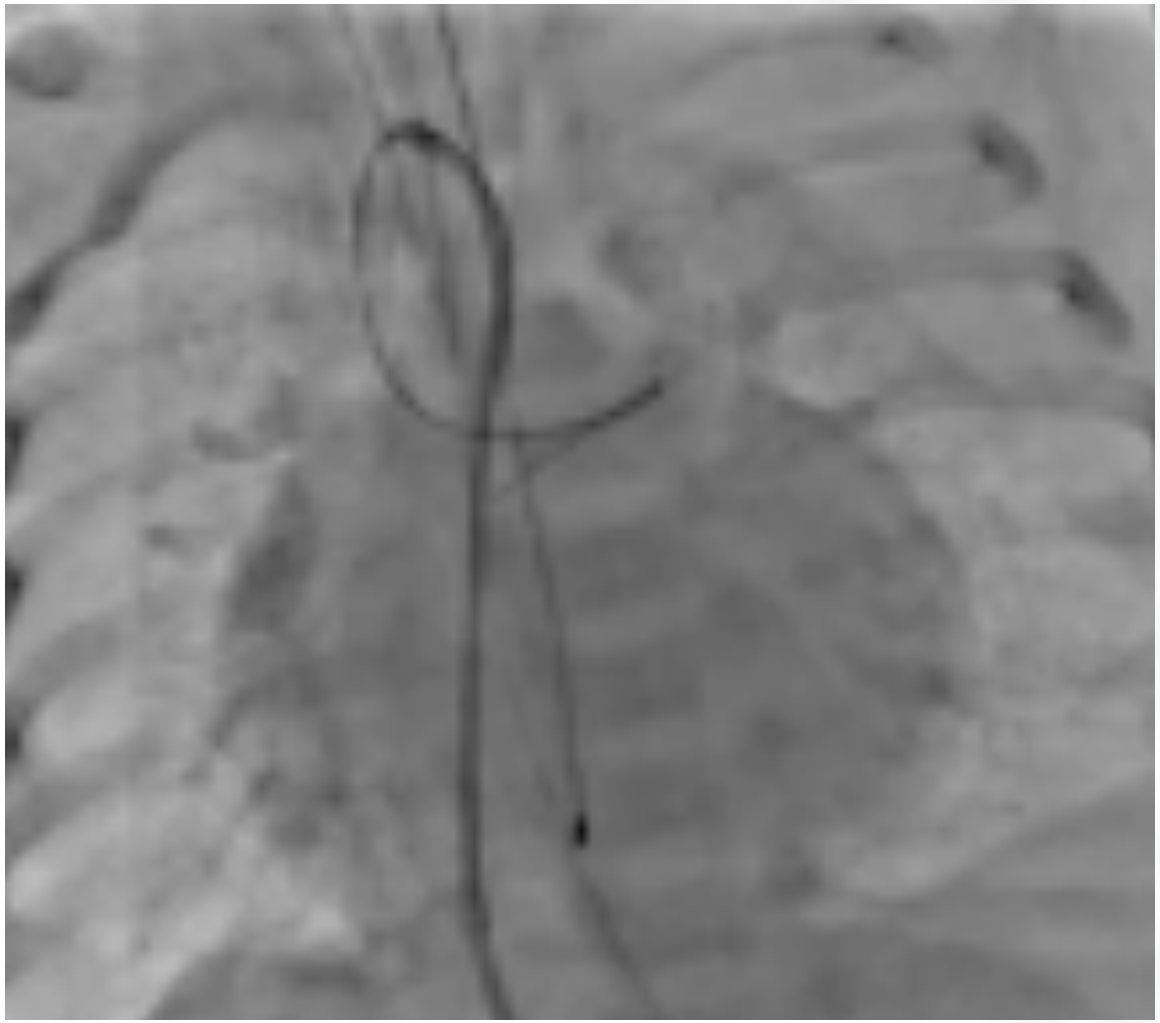

Duct dependent Systemic Blood Flow

- Anatomy: large spectrum of HLHS

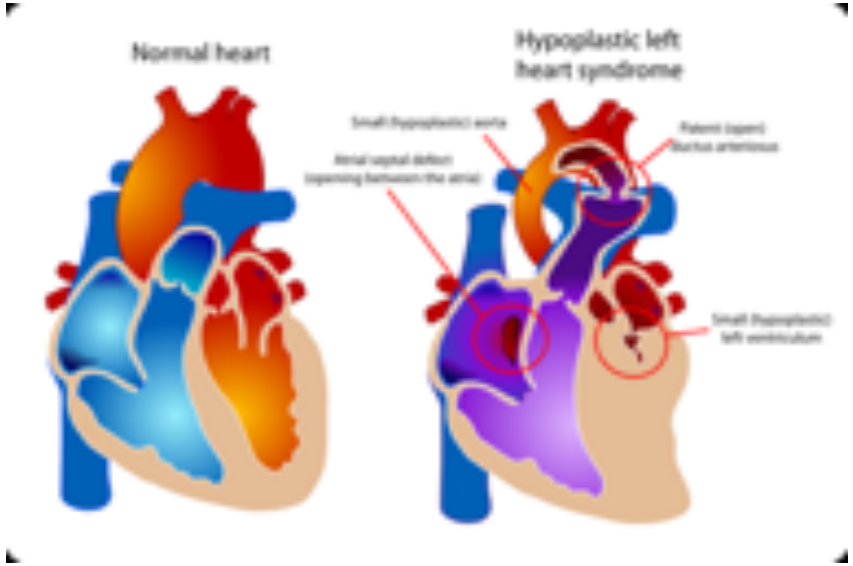

- **Immediate** action to establish **adequate** Systemic Blood Flow
  - Prostaglandin to maintain ductal patency (R to L flow)

- Subsequent need for **Reliable** systemic circulation
  - Norwood/Hybrid for HLHS
- Balloon or Surgical Aortic Valvotomy in Critical AS

Palliative approach in HLHS

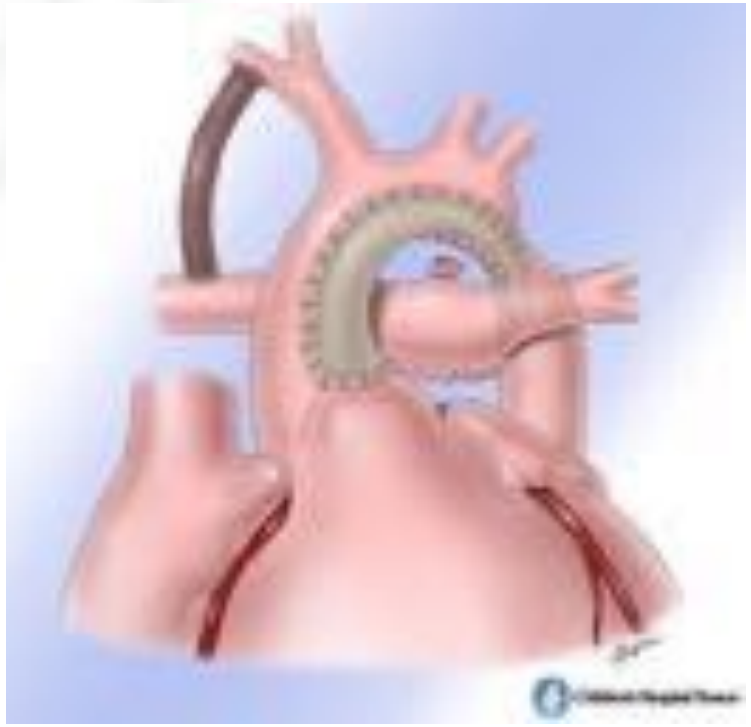

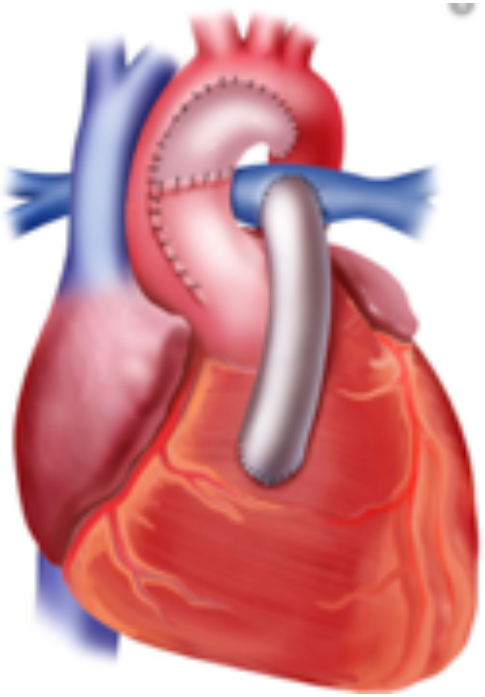

Different shunt types

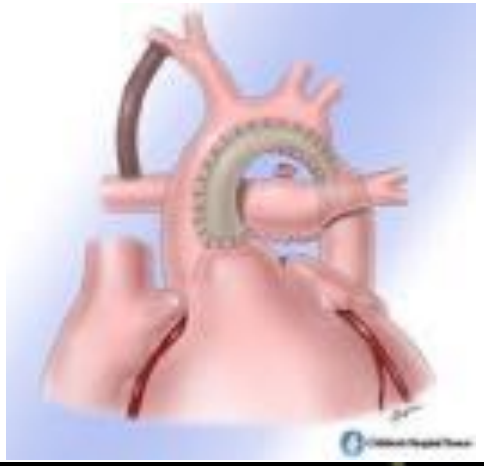

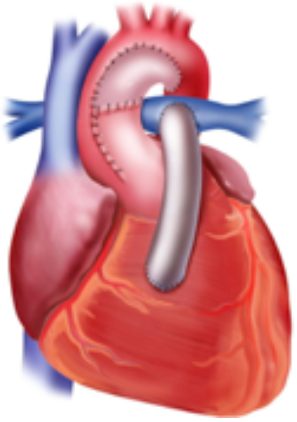

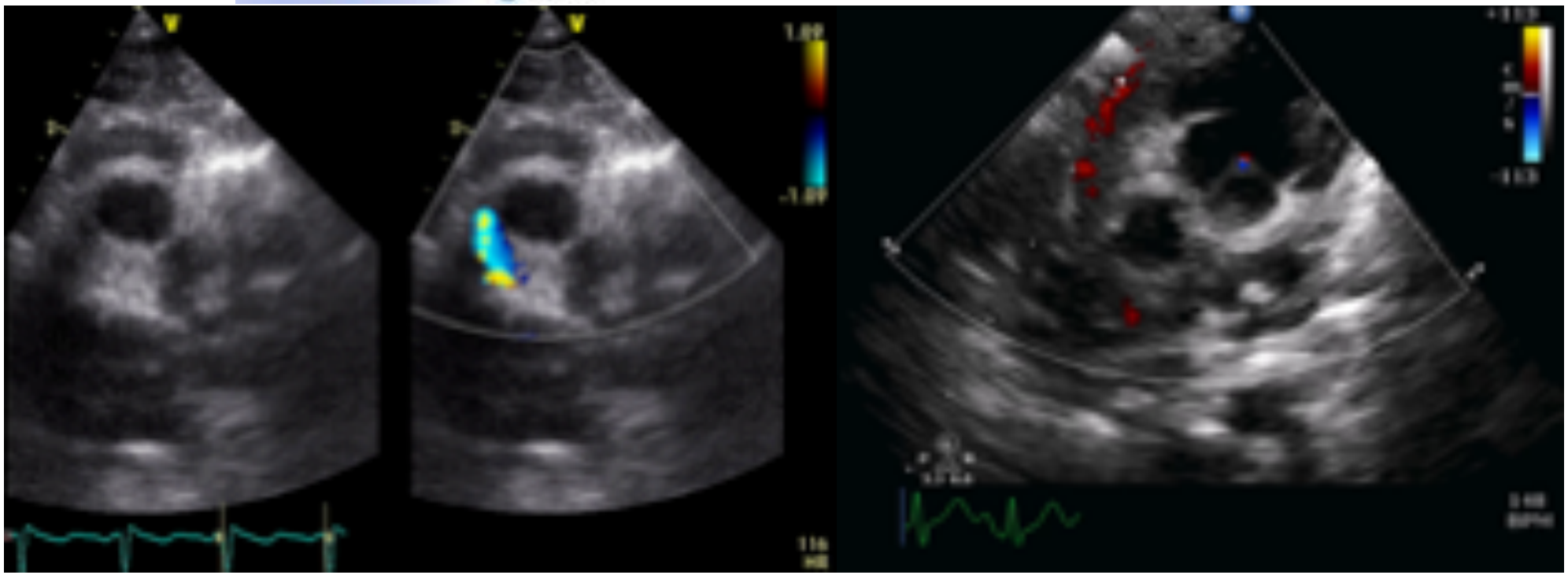

RV to PA conduit

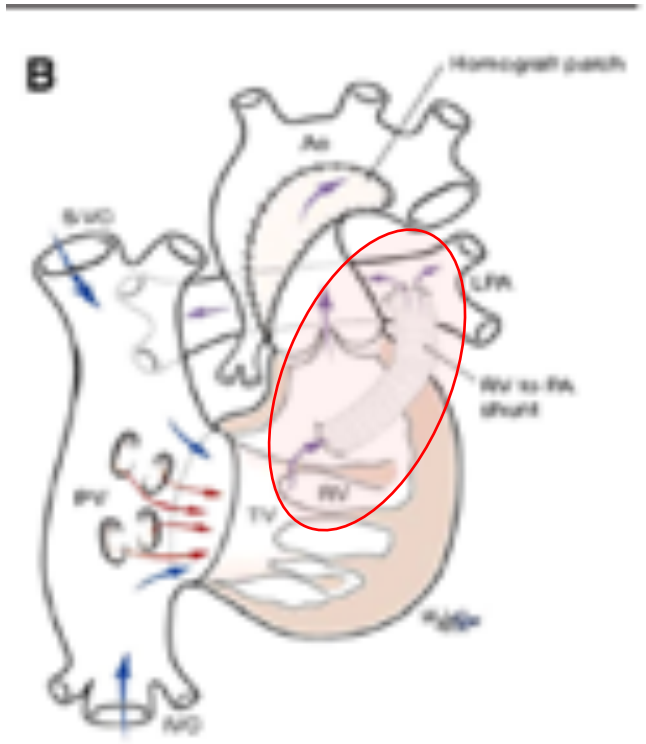

RV-PA Conduit

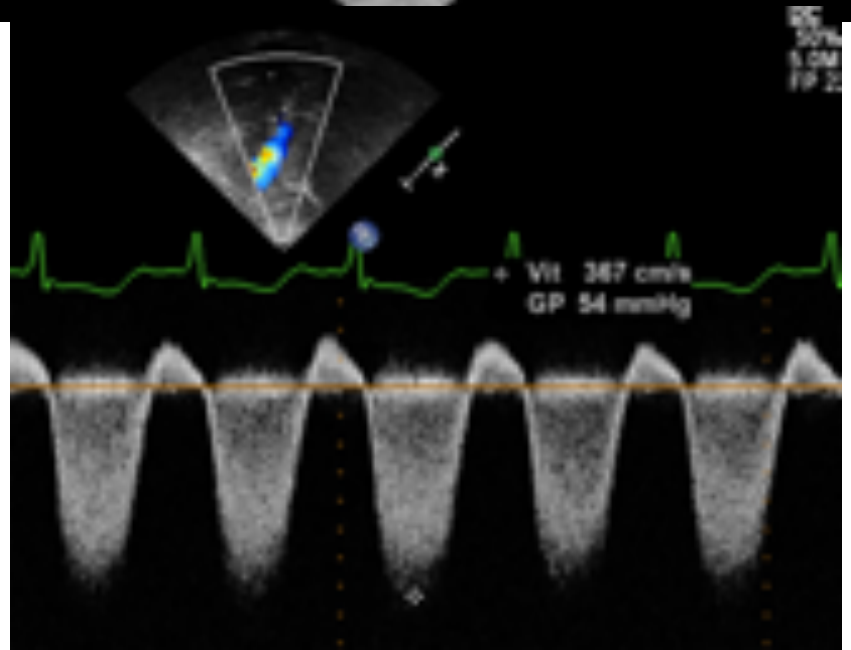

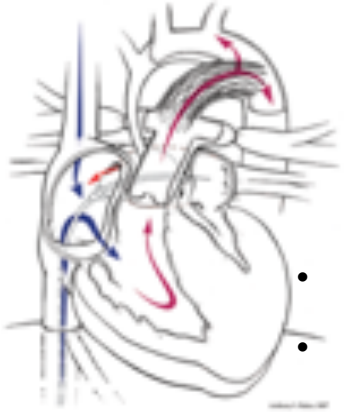

Hybrid palliation

- create a balanced physiology where the single RV supplies the systemic and the pulmonary circulation.
- complex aortic arch reconstruction (including CPB) is postponed to the stage 2 (Glenn)

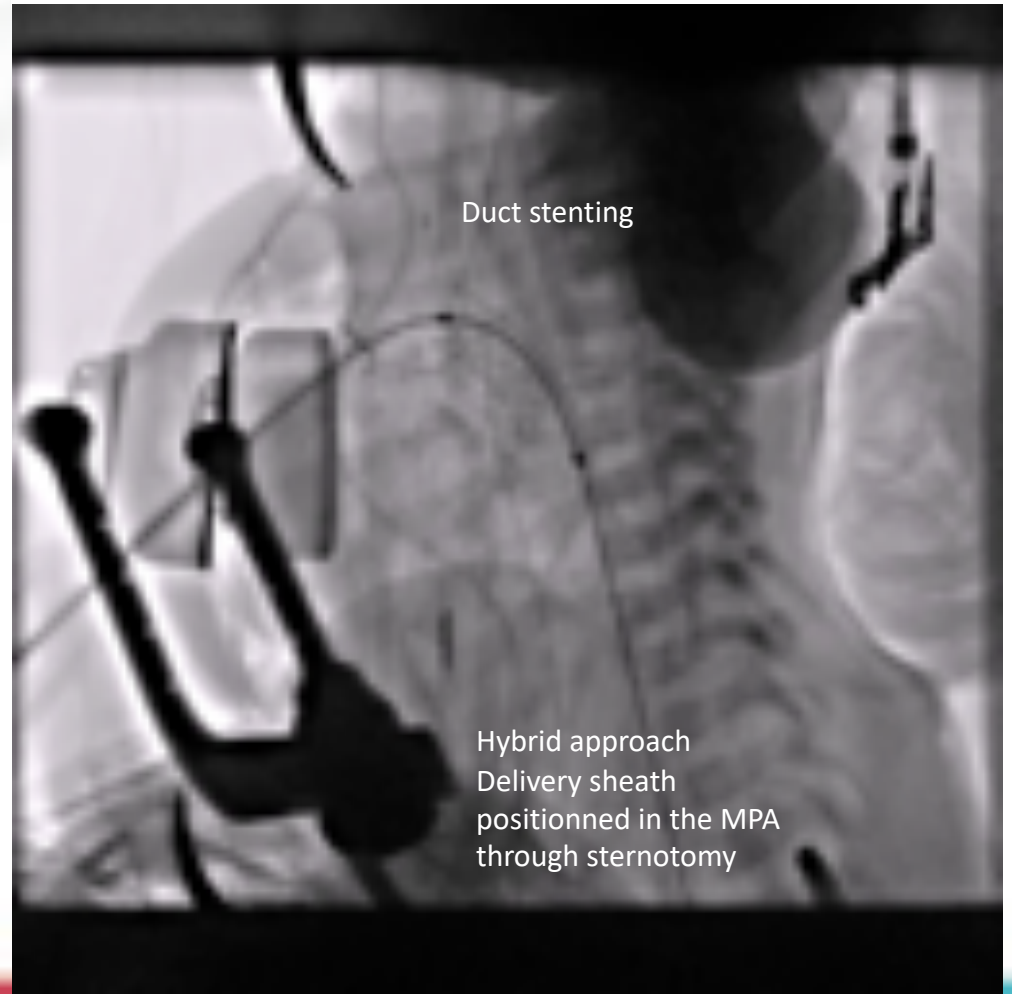

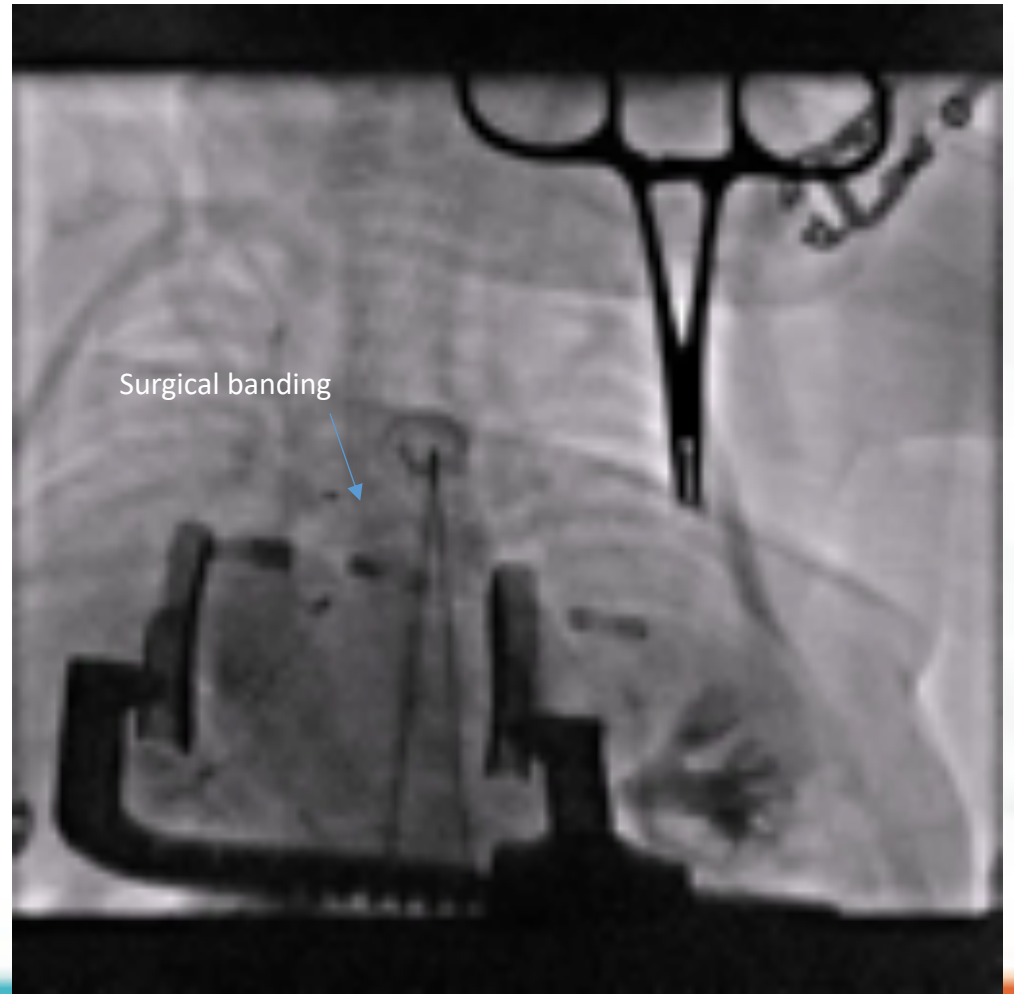

Hybrid procedure

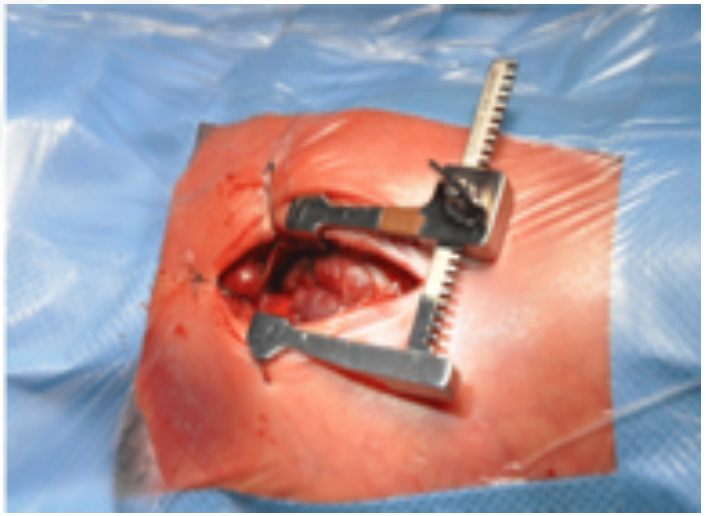

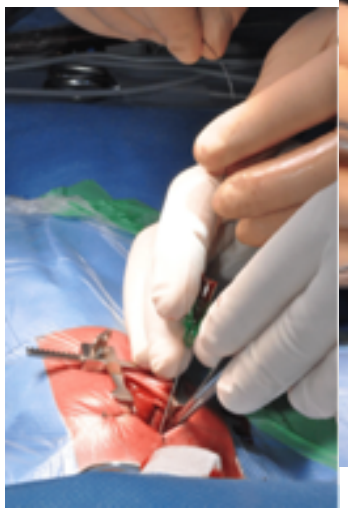

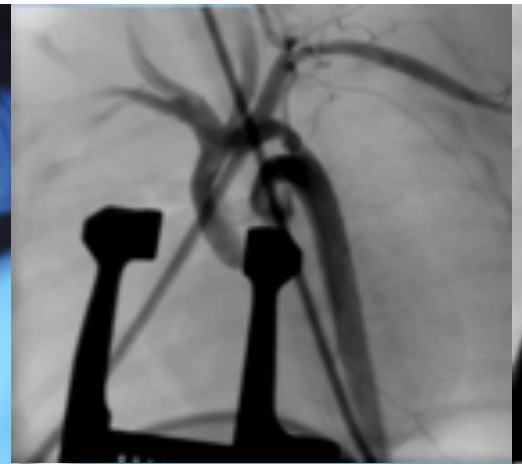



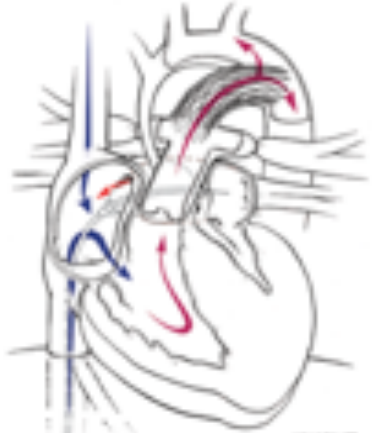

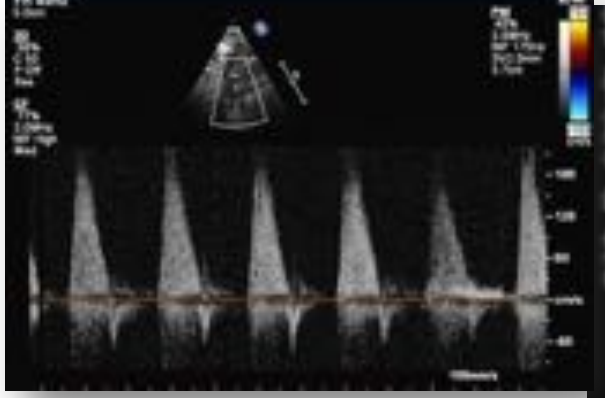

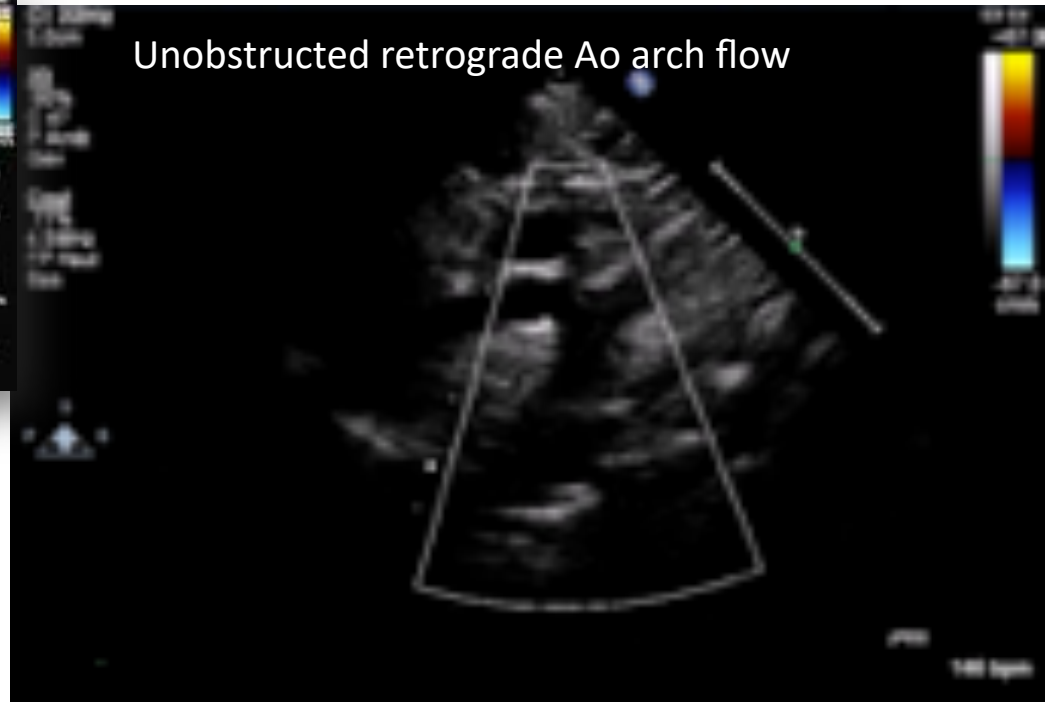
Unobstructed retrograde Ao arch flow

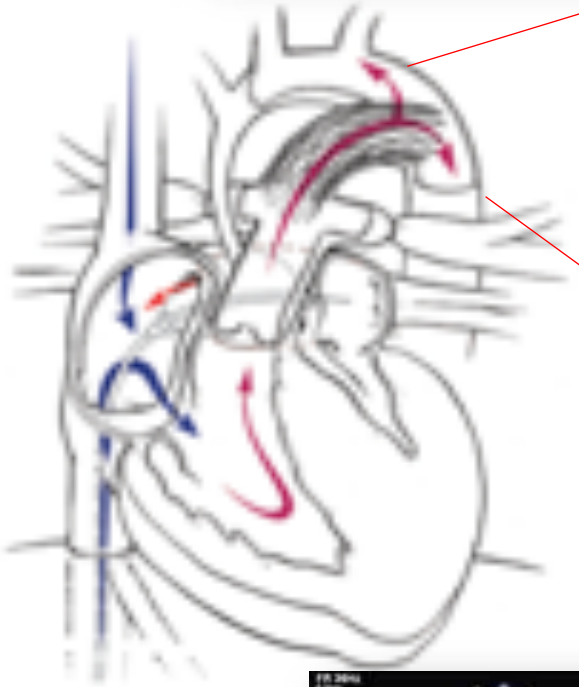

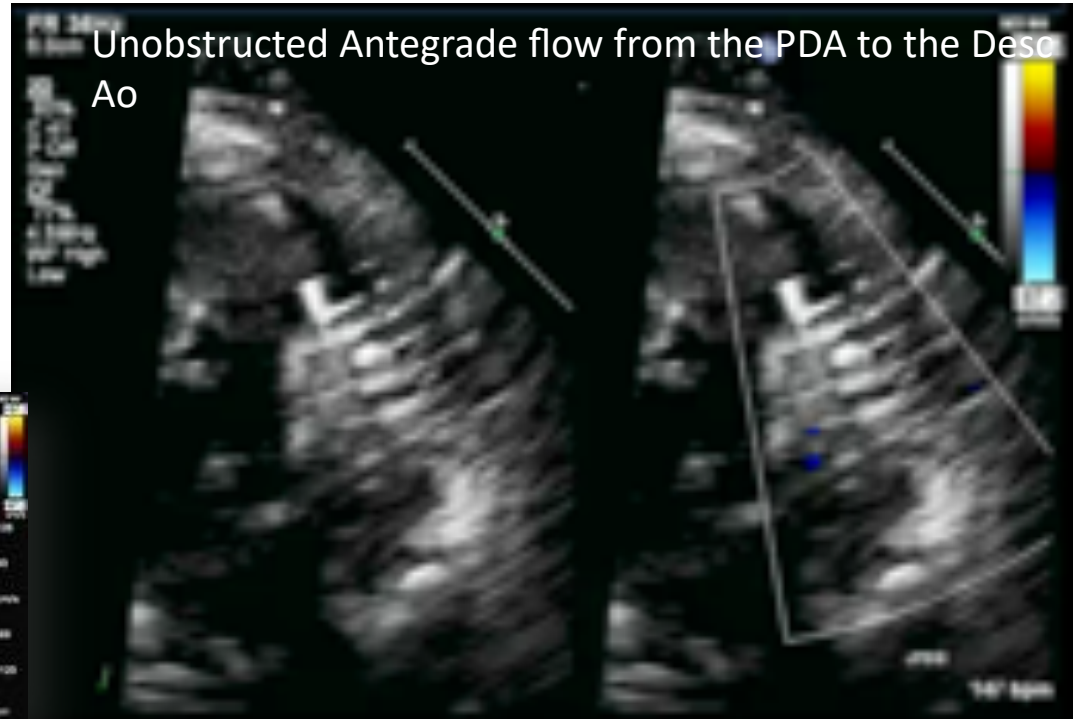
Unobstructed Antegrade flow from the PDA to the Desc Ao

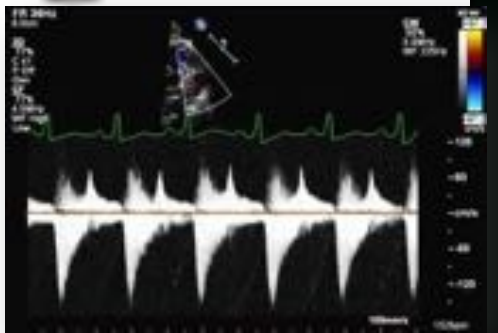

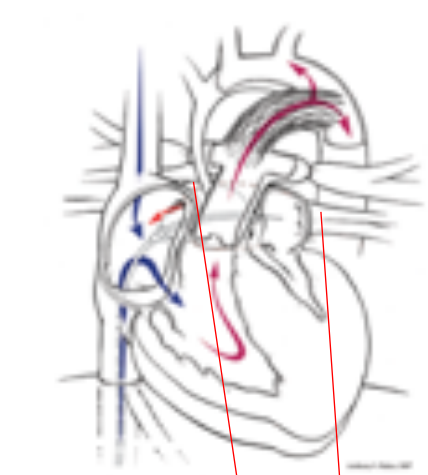

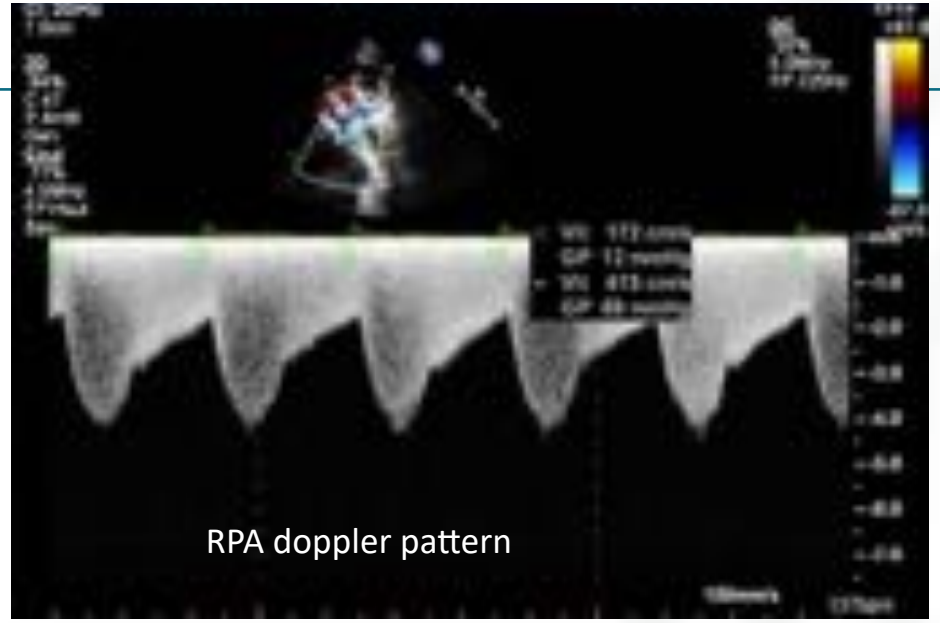
RPA doppler pattern

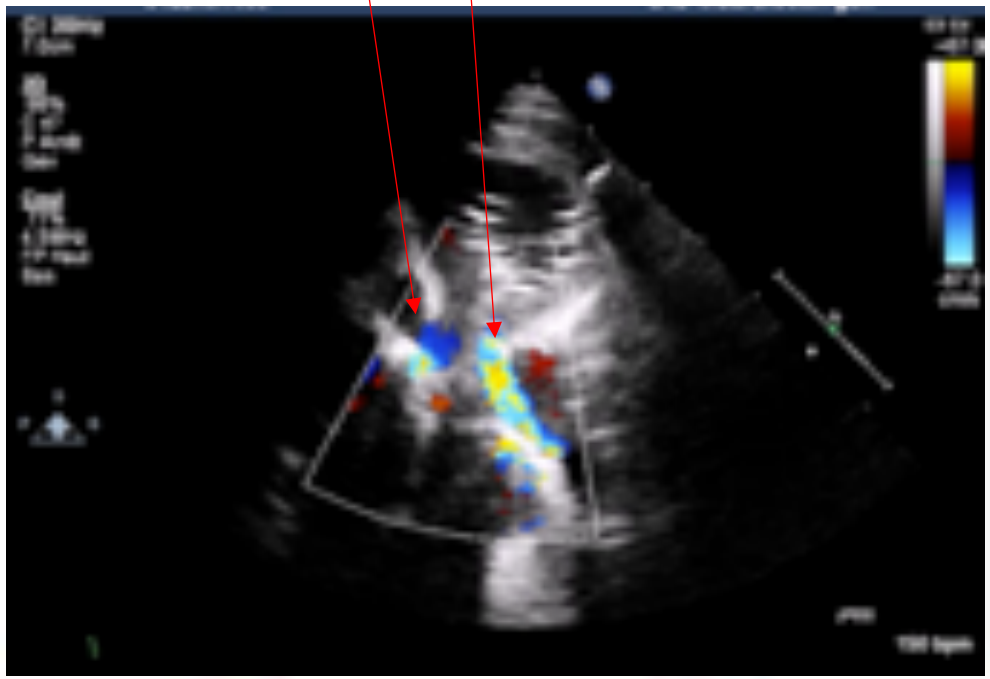

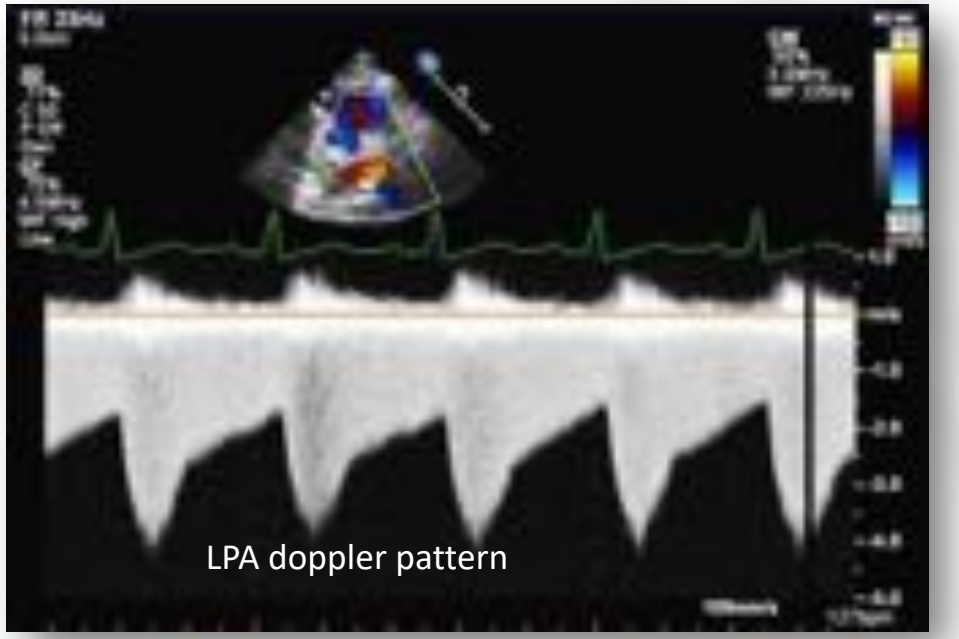
LPA doppler pattern

CAS CLINIQUE 2

Tétralogie de Fallot, DAN: Accouchement par voie basse, Poids=3kg, Sat=76%