TRANSPOSITION DES GROS VAISSEAUX

Dr Régis GAUDIN

DU REANIAMTION DES CARDIOPATHIES CONGÉNITALES - PARIS

UNIVERSITÉ PARIS DESCARTES

ASSISTANCE PUBLIQUE HÔPITAUX DE PARIS

imagine INSTITUT DES MALADIES GÉNÉTIQUES

European Reference Networks

Necker ENFANTS MALADES HÔPITAL UNIVERSITAIRE

Introduction

- réparation à l'étage atrial
  - Senning / Mustard
  - indications
    - . TGV simple avec VG « dépréparé »
    - . vs cerclage préparatoire + switch

- réparation à l'étage artériel : switch
  - TGV simple : période néonatale
  - ± CIV
  - ± coarctation

Introduction

- réparation à l'étage atrial
  - Senning / Mustard
  - indications
    - . TGV simple avec VG « dépréparé »
    - . vs cerclage préparatoire + switch

- réparation à l'étage artériel : switch
  - TGV simple : période néonatale
  - ± CIV
  - ± coarctation

Chirurgie en un temps

Introduction

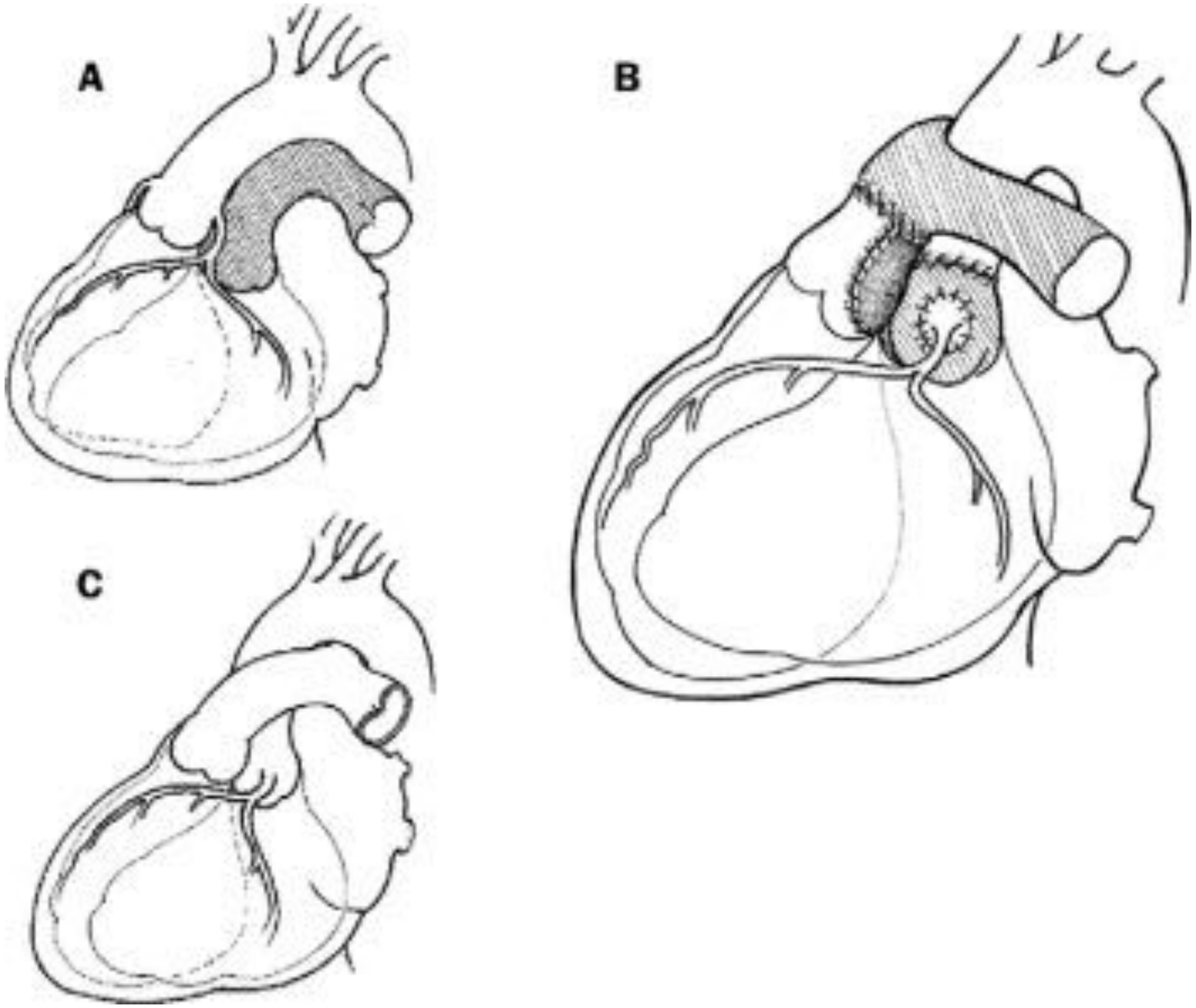

Introduction

Anatomie coronaire

- « normale » : 60%
- boucle antérieure et/ou postérieure : 35%
- entre gros vaisseaux (intramurale) : 5%

Ligature du canal artériel

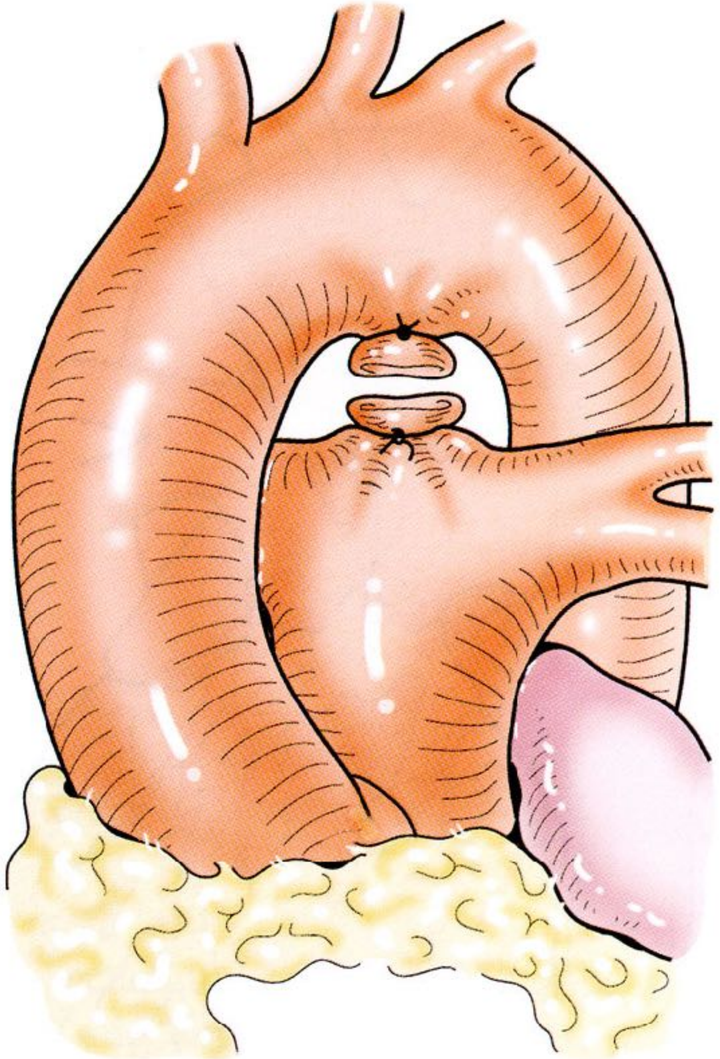

Section de l’aorte

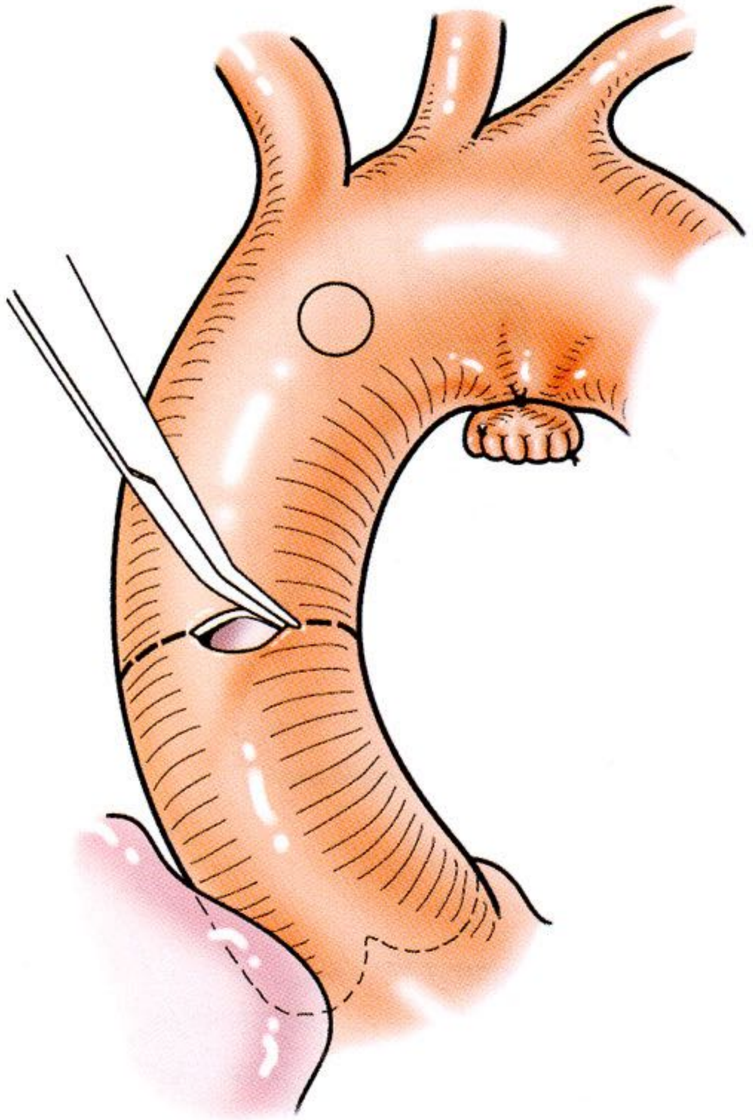

Anatomie des coronaires

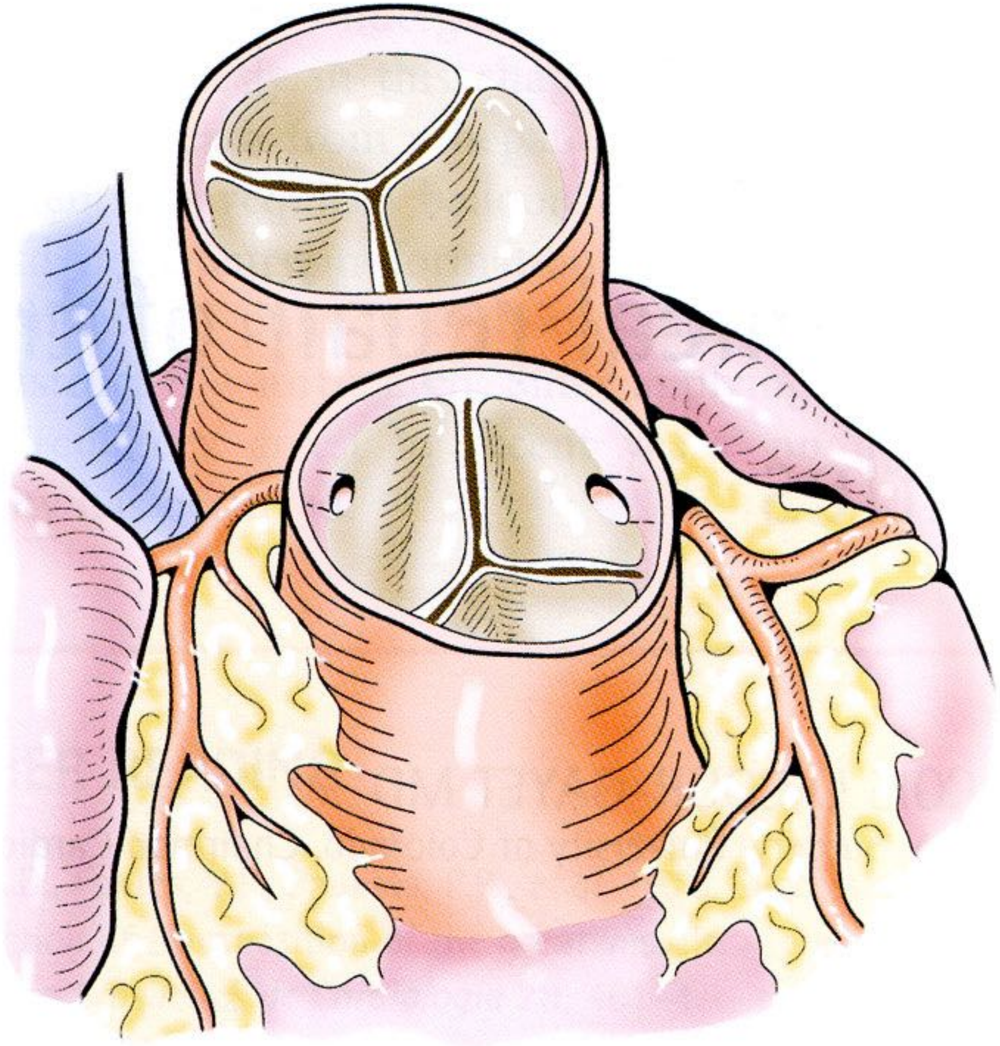

Jonas

Anatomie des coronaires

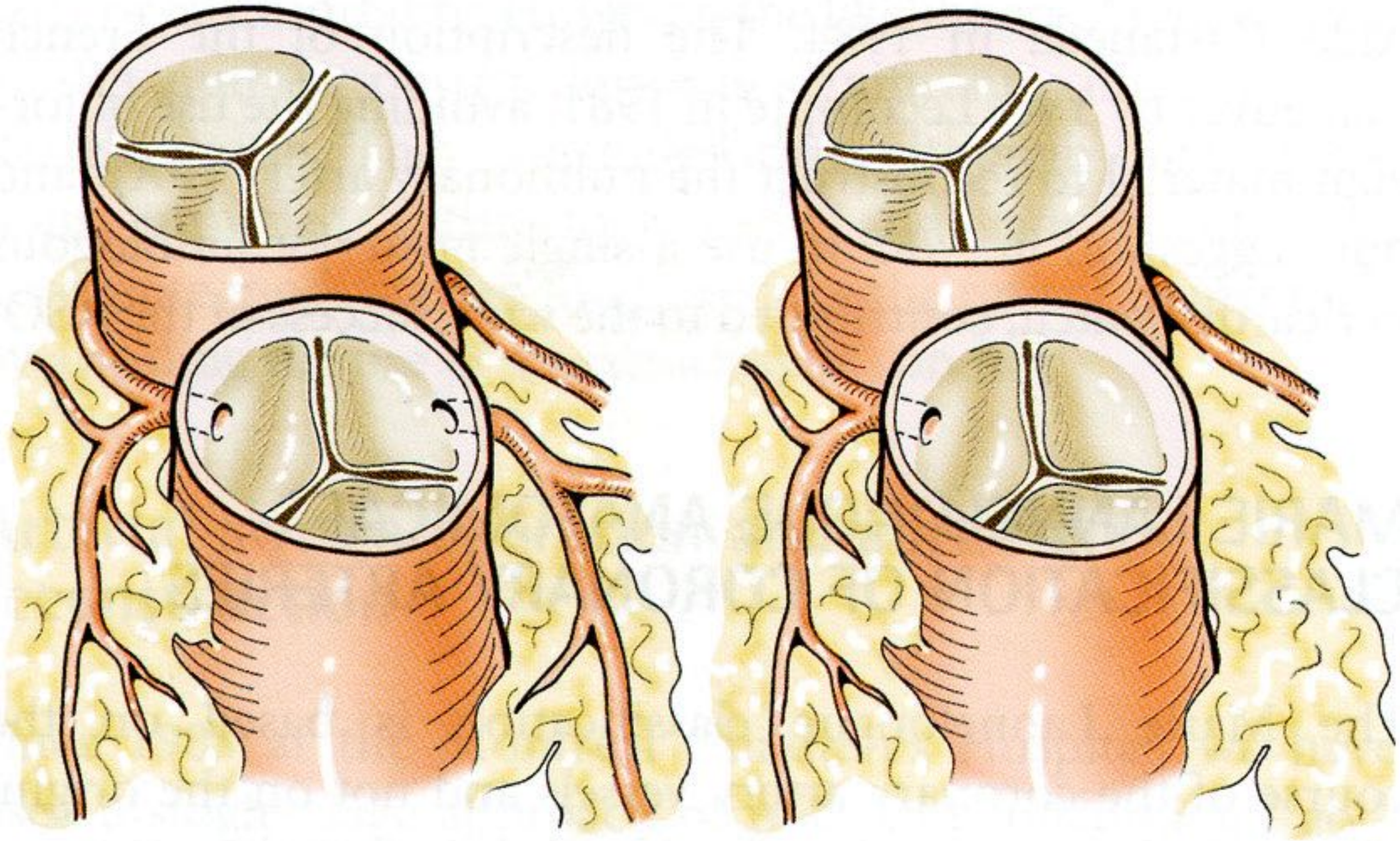

as

Anatomie des coronaires

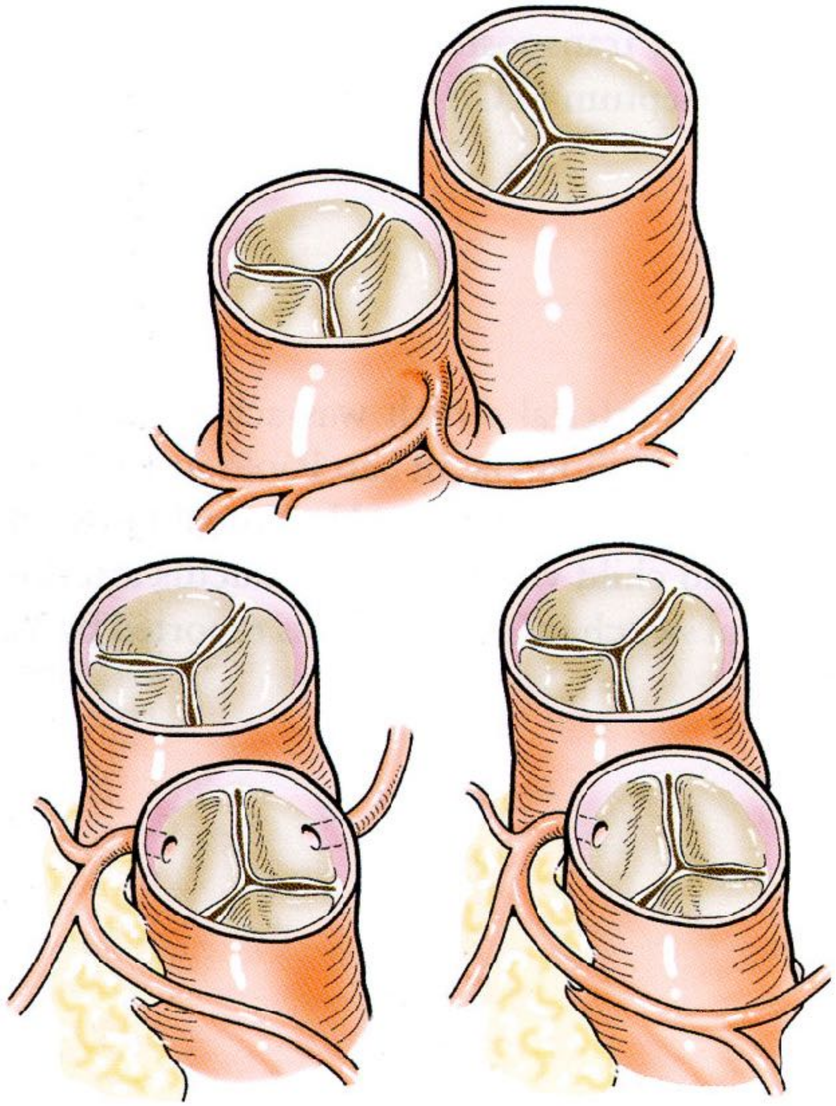

Anatomie des coronaires

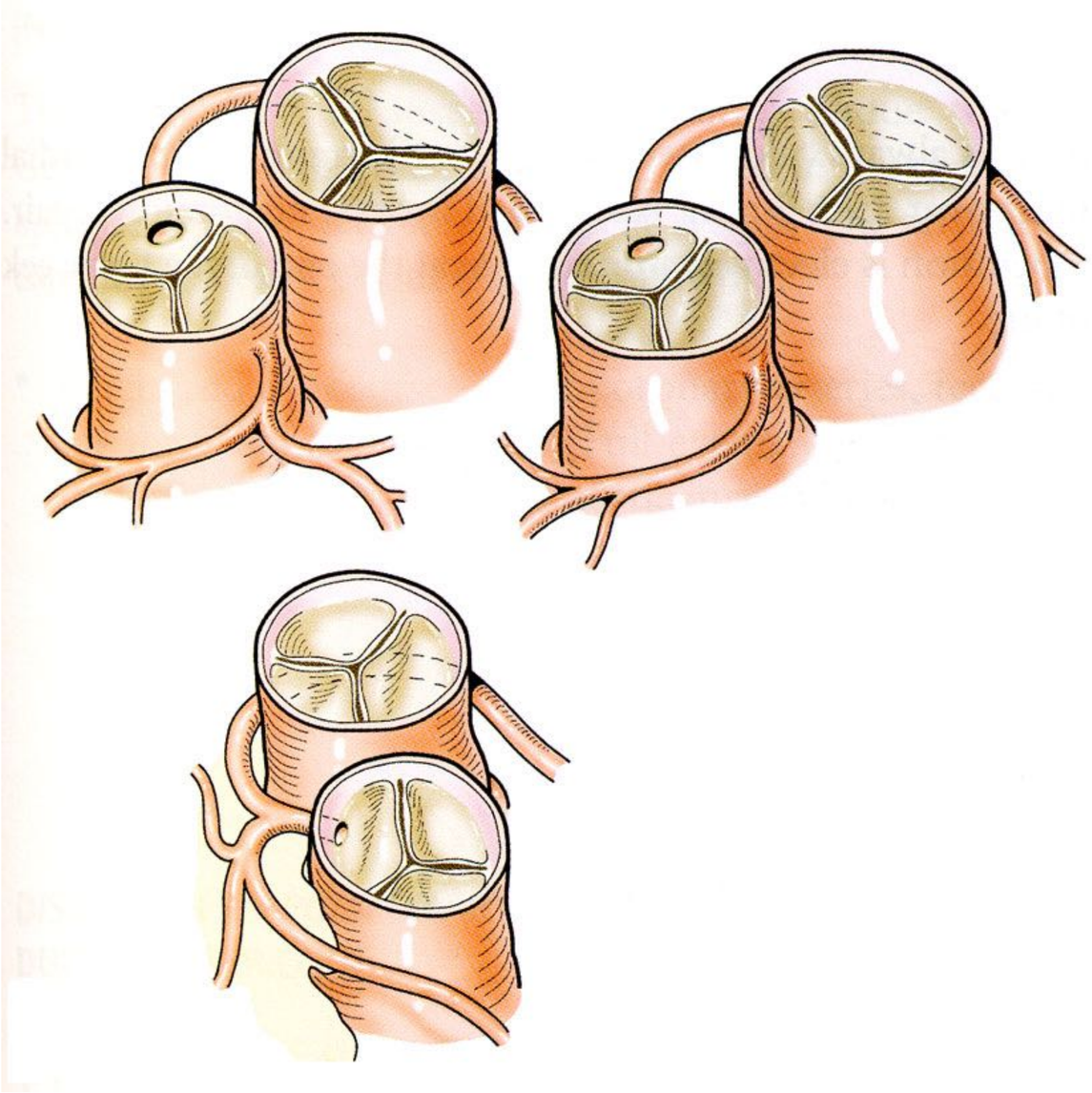

Coronaire intra-murale

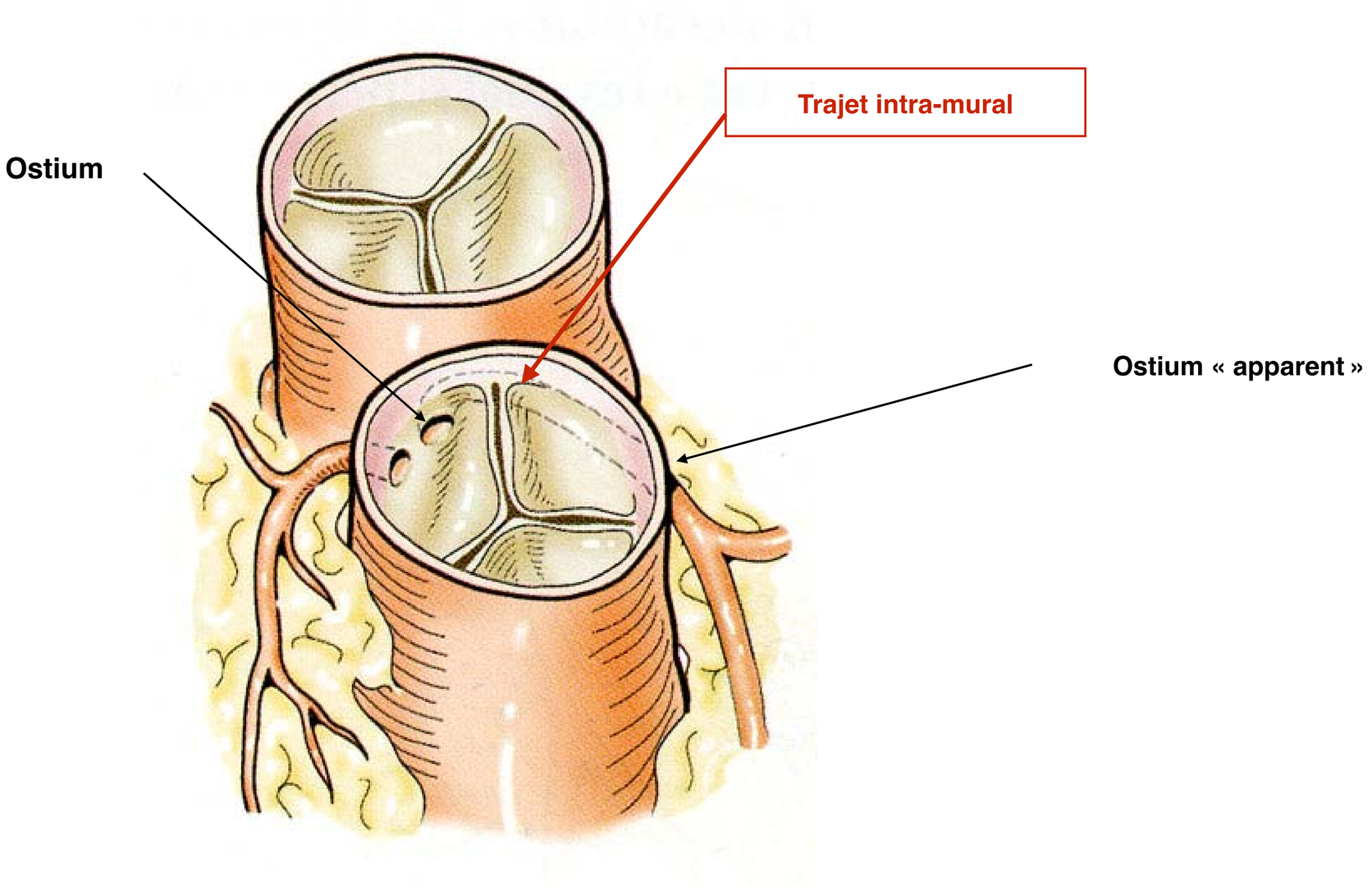

Coronaire intra-murale

Intramural coronary arteries and outcome of neonatal arterial switch operation☆

Olivier Metton [a], Davide Calvaruso [a], Régis Gaudin [a], Shafi Mussa [a], Olivier Raisky [a], Damien Bonnet [b], Daniel Sidi [b], Pascal R. Vouhé [a,*]

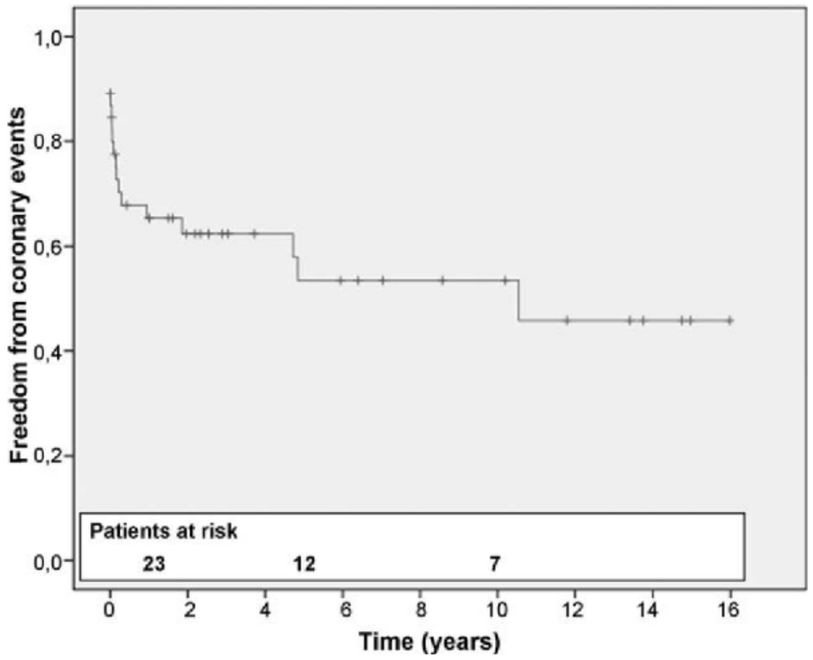

Fig. 4. Actuarial freedom from coronary events.

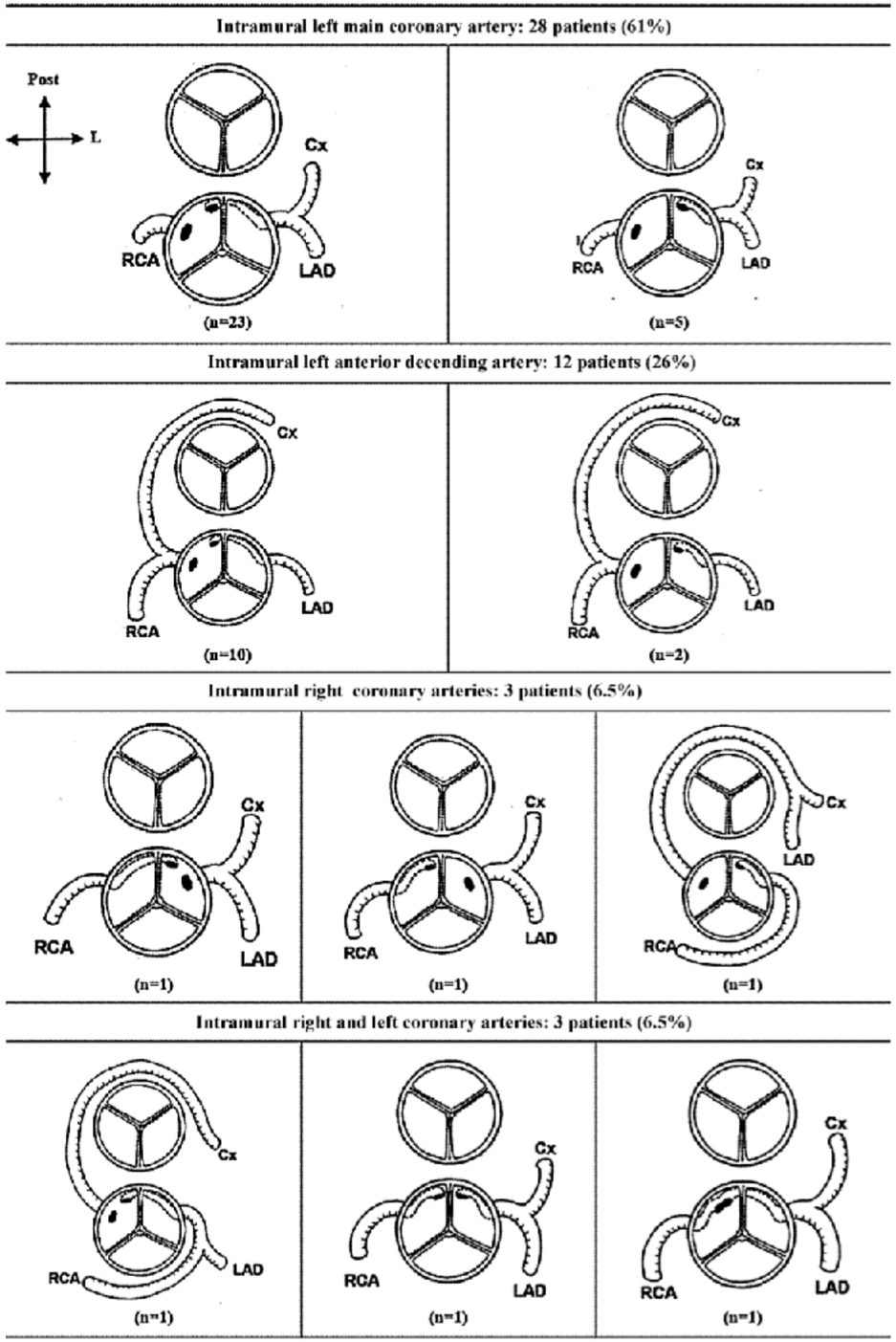

Anatomie des coronaires

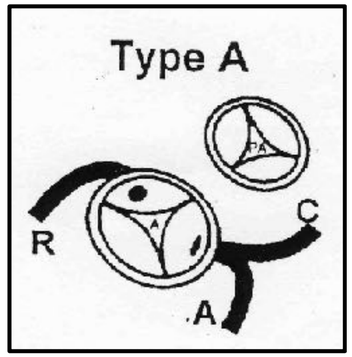

« Normal »

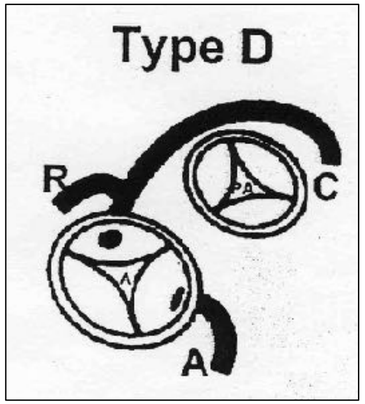

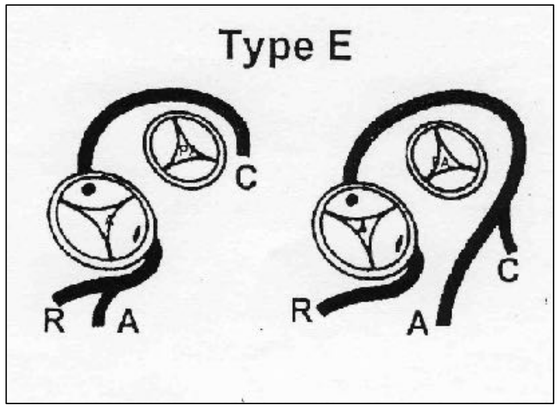

« Boucles»

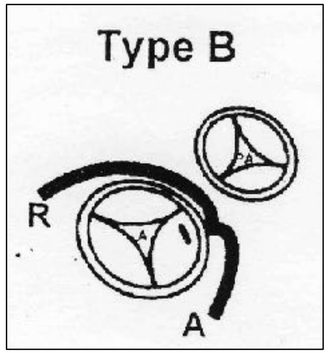

« Coronaire unique »

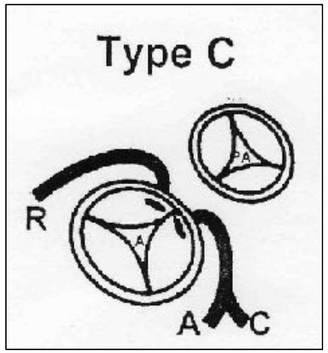

« Coronaire intra-murale »

Anatomie des coronaires

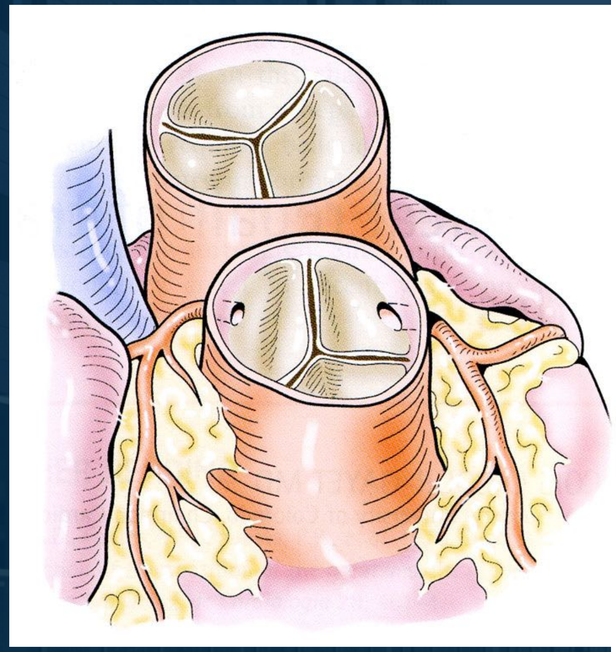

Facteurs influençant la réimplantation

- Discongruence aorto-pulmonaire
- Malalignement des commissures
- Position non Ant / Post des gros vaisseaux

Section de l’AP

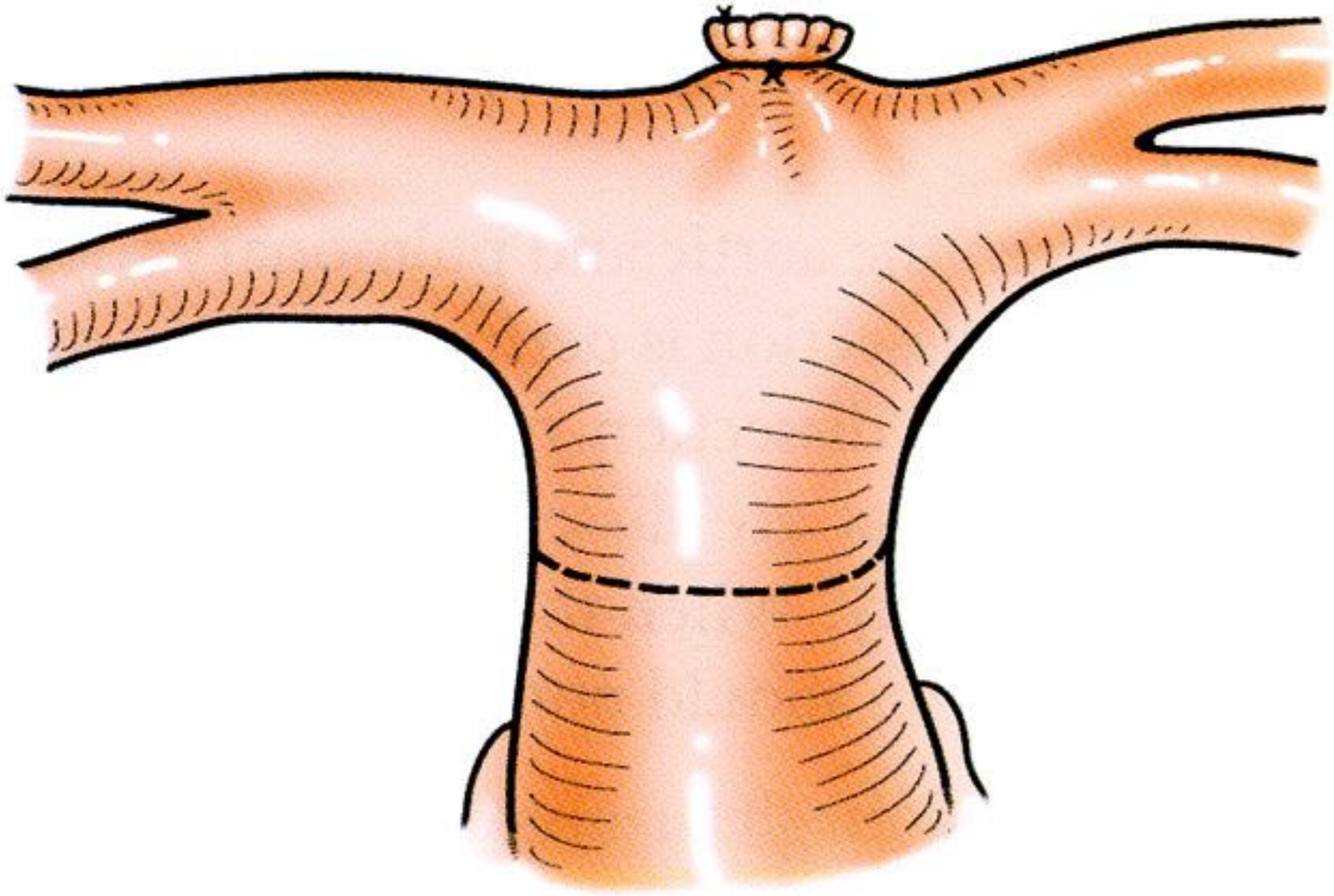

Manoeuvre de Lecompte

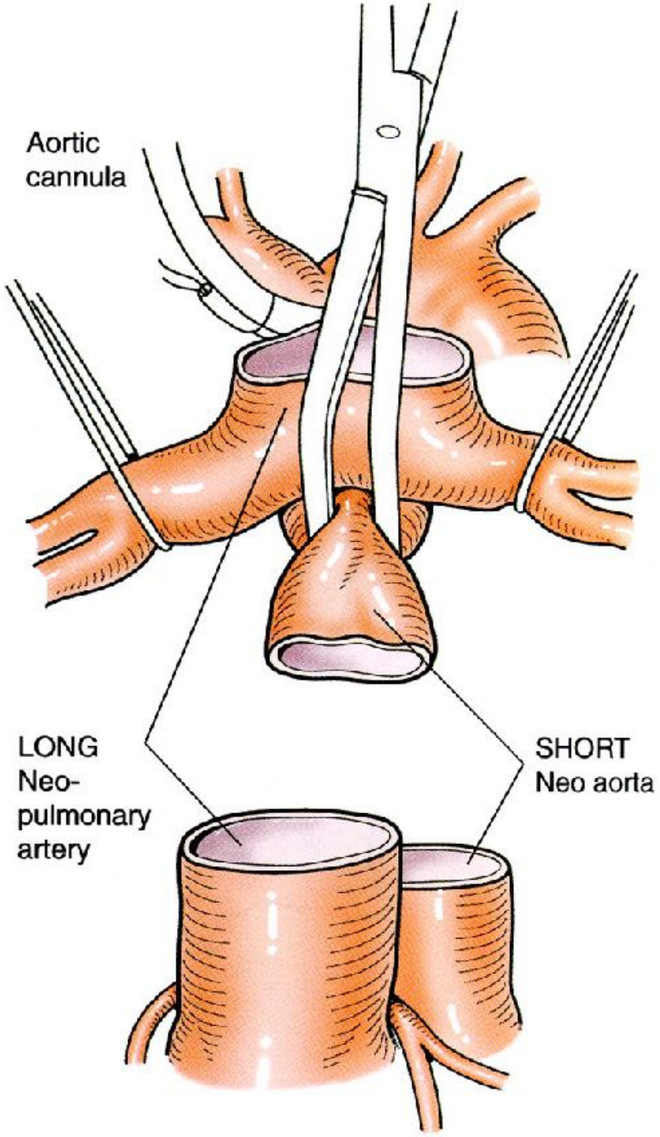

Prélèvement des coronaires

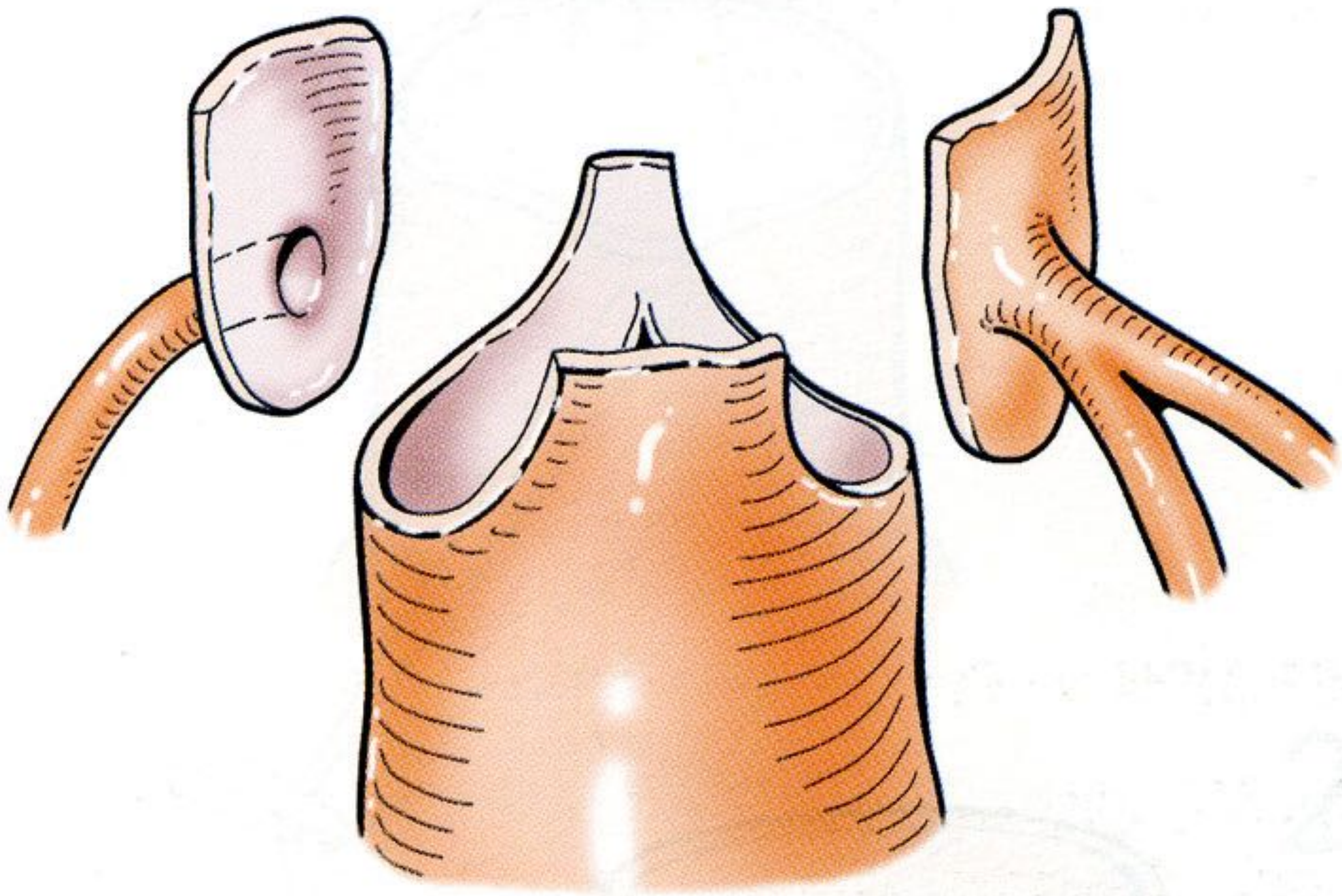

Reconstruction aorte

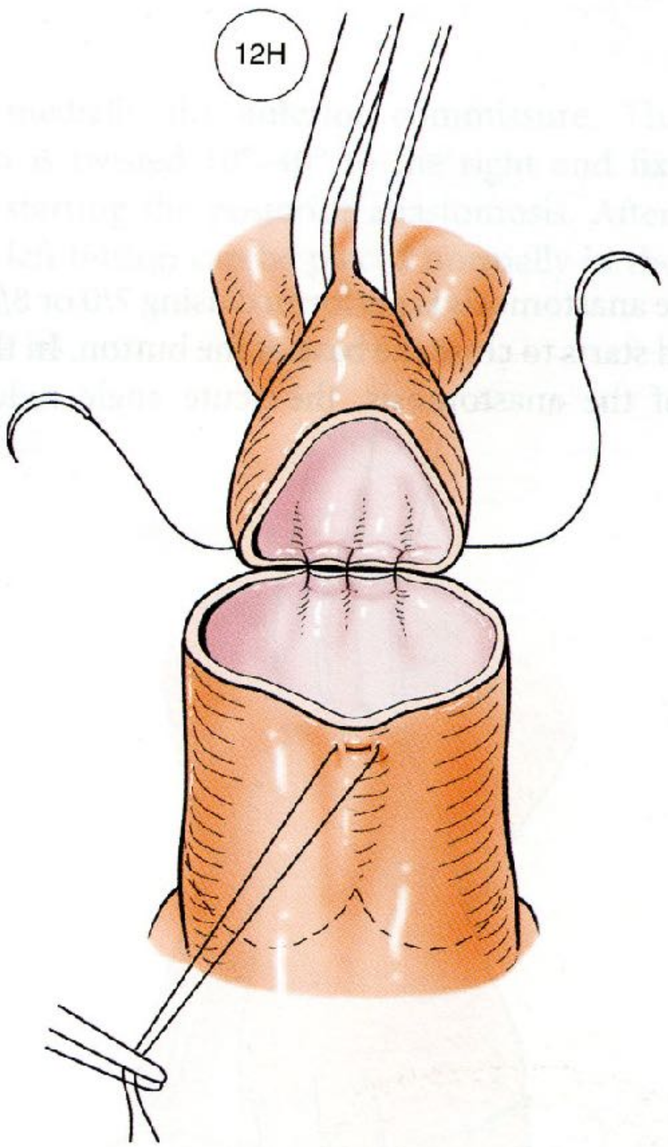

Réimplantation coronaires

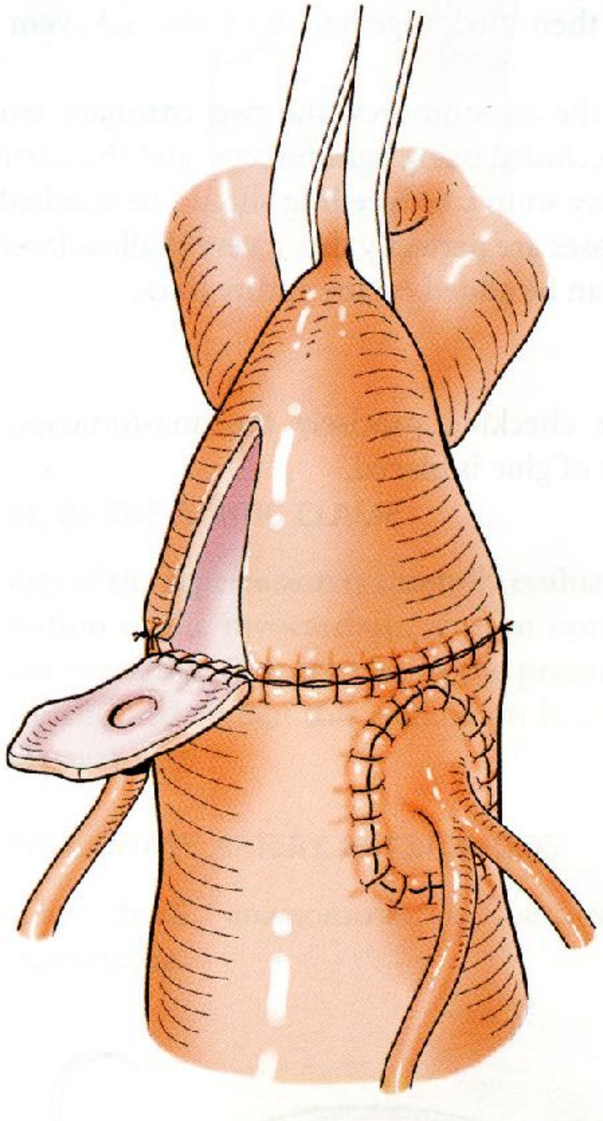

Réimplantation coronaires

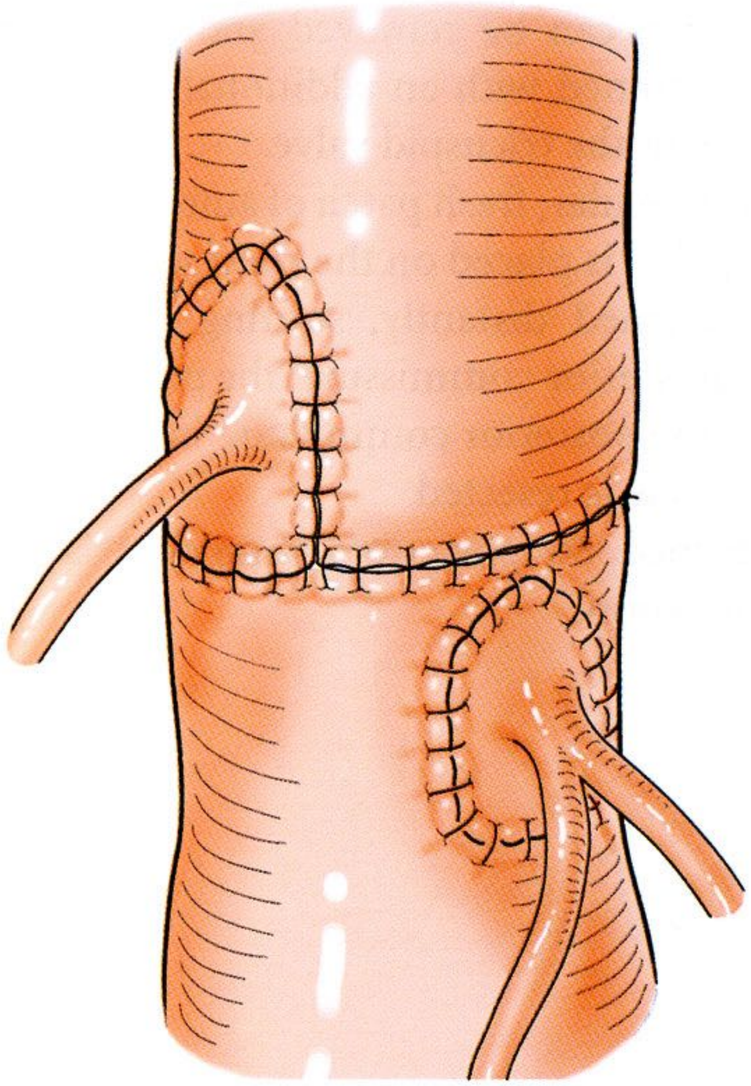

Jonas

Prélèvement péricarde frais

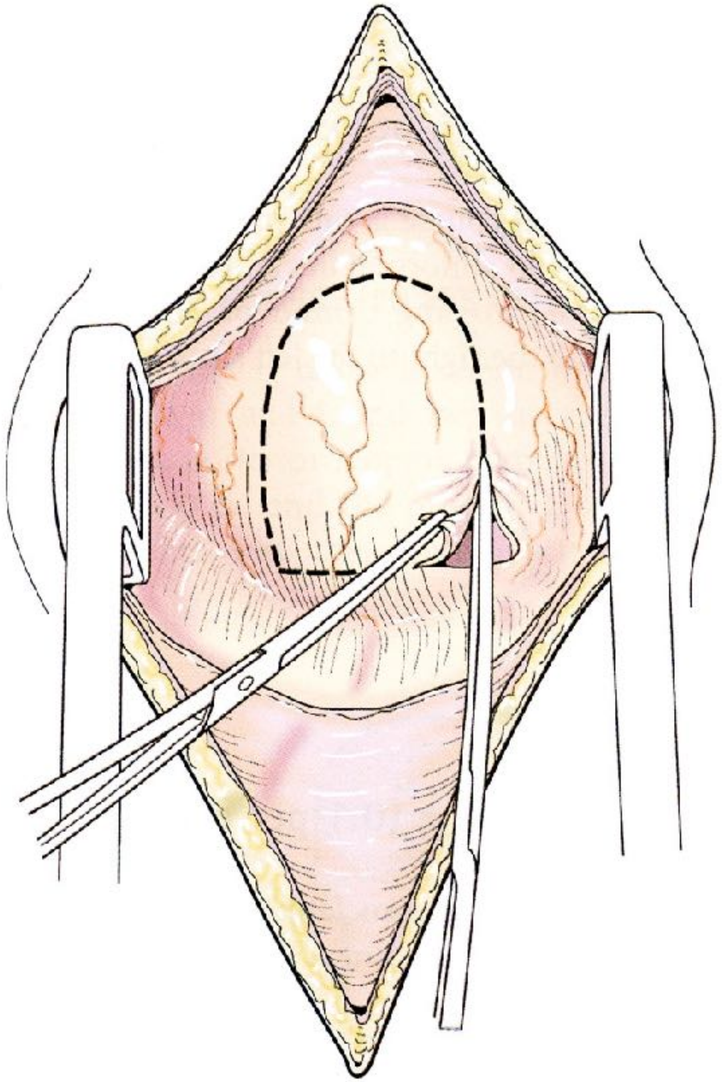

Reconstruction culot pulmonaire

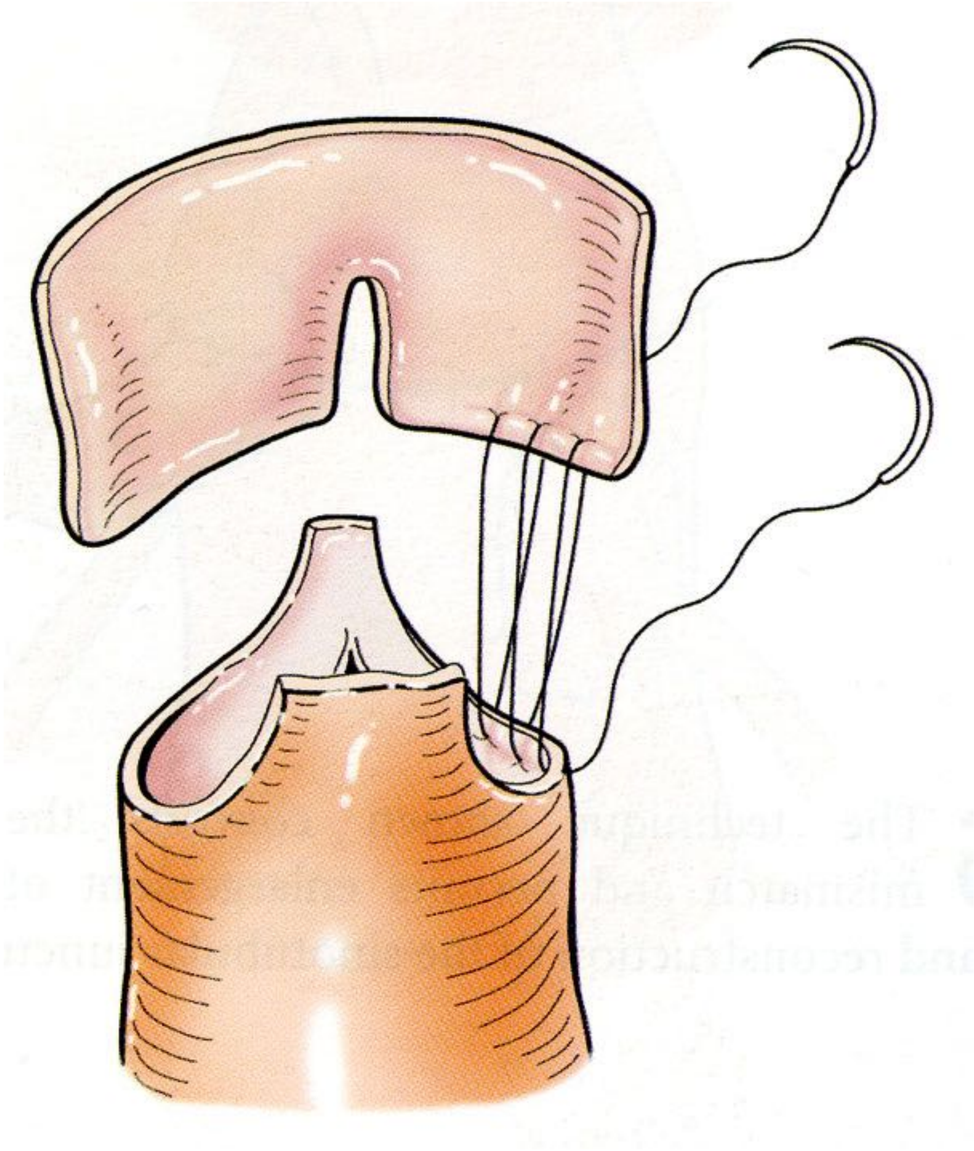

Reconstruction voie pulmonaire

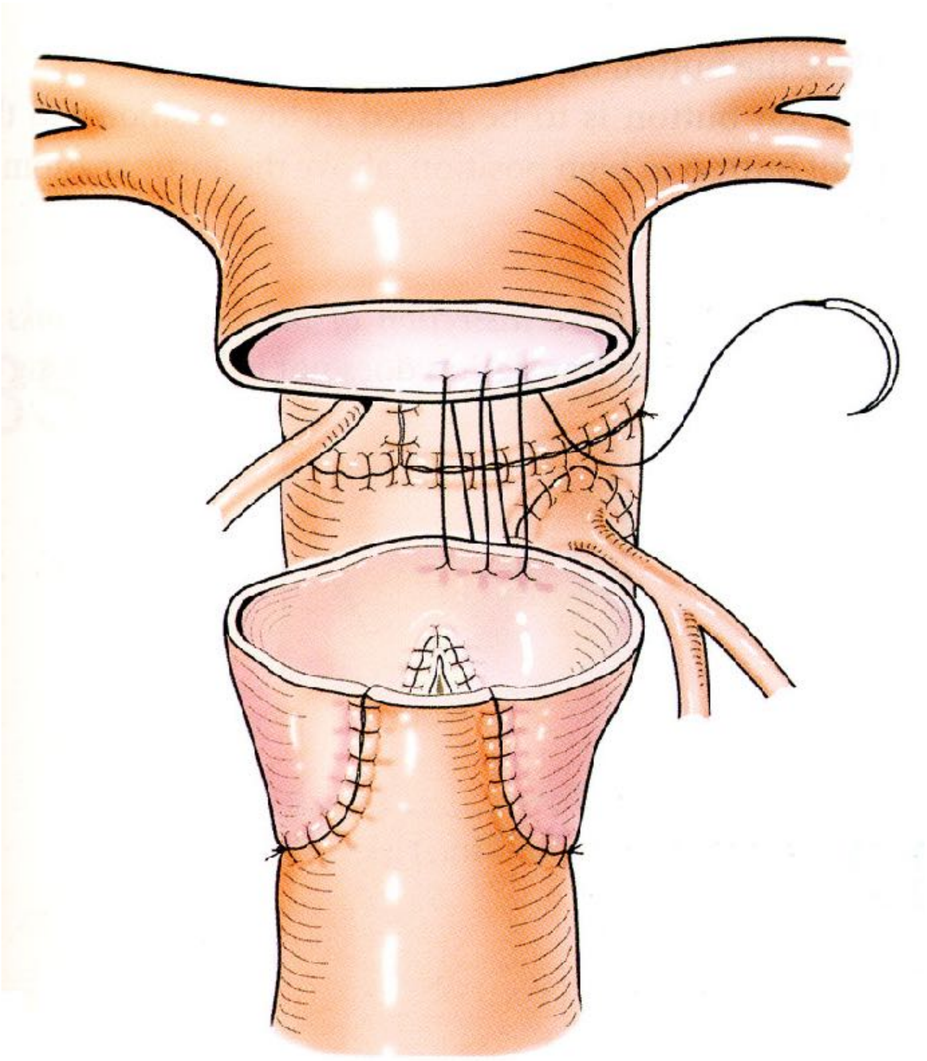

Jonas

Reconstruction voie pulmonaire

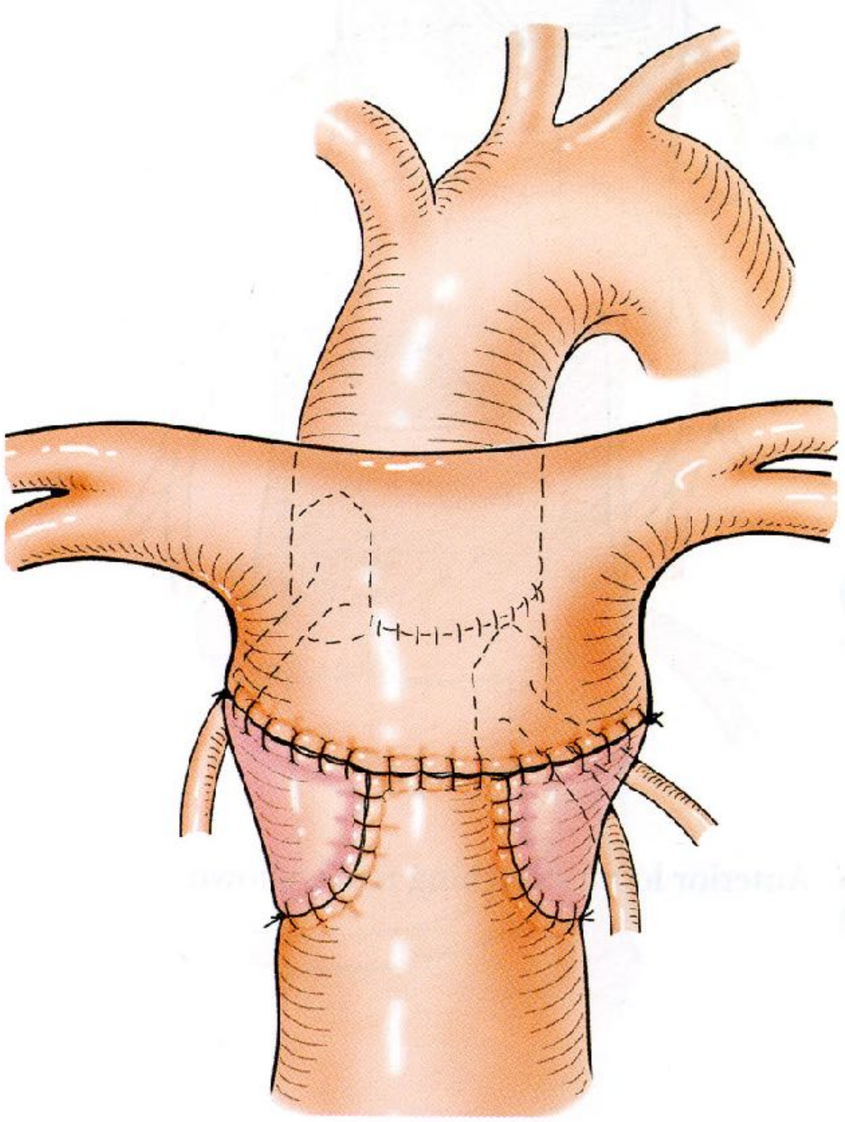

Coronaires - complications

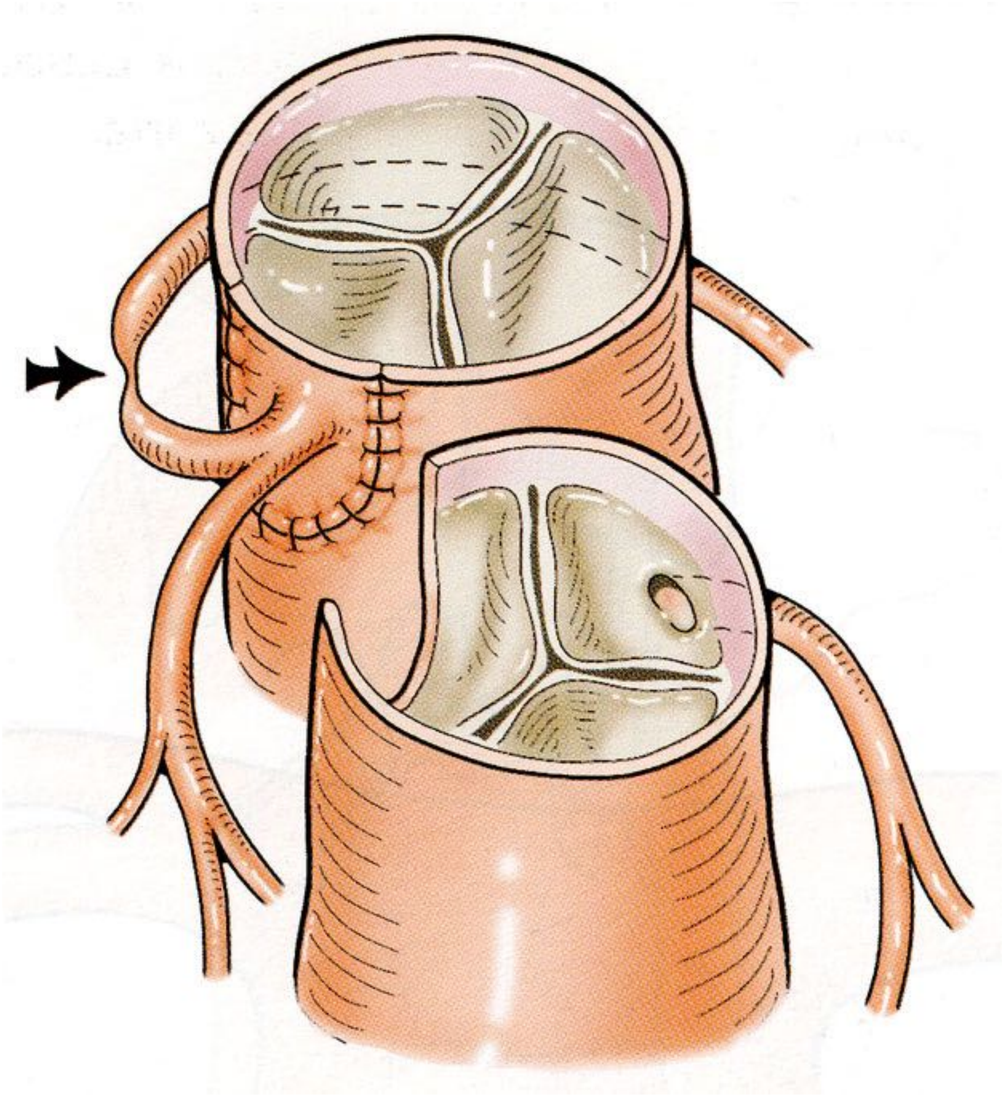

Coronaires - complications

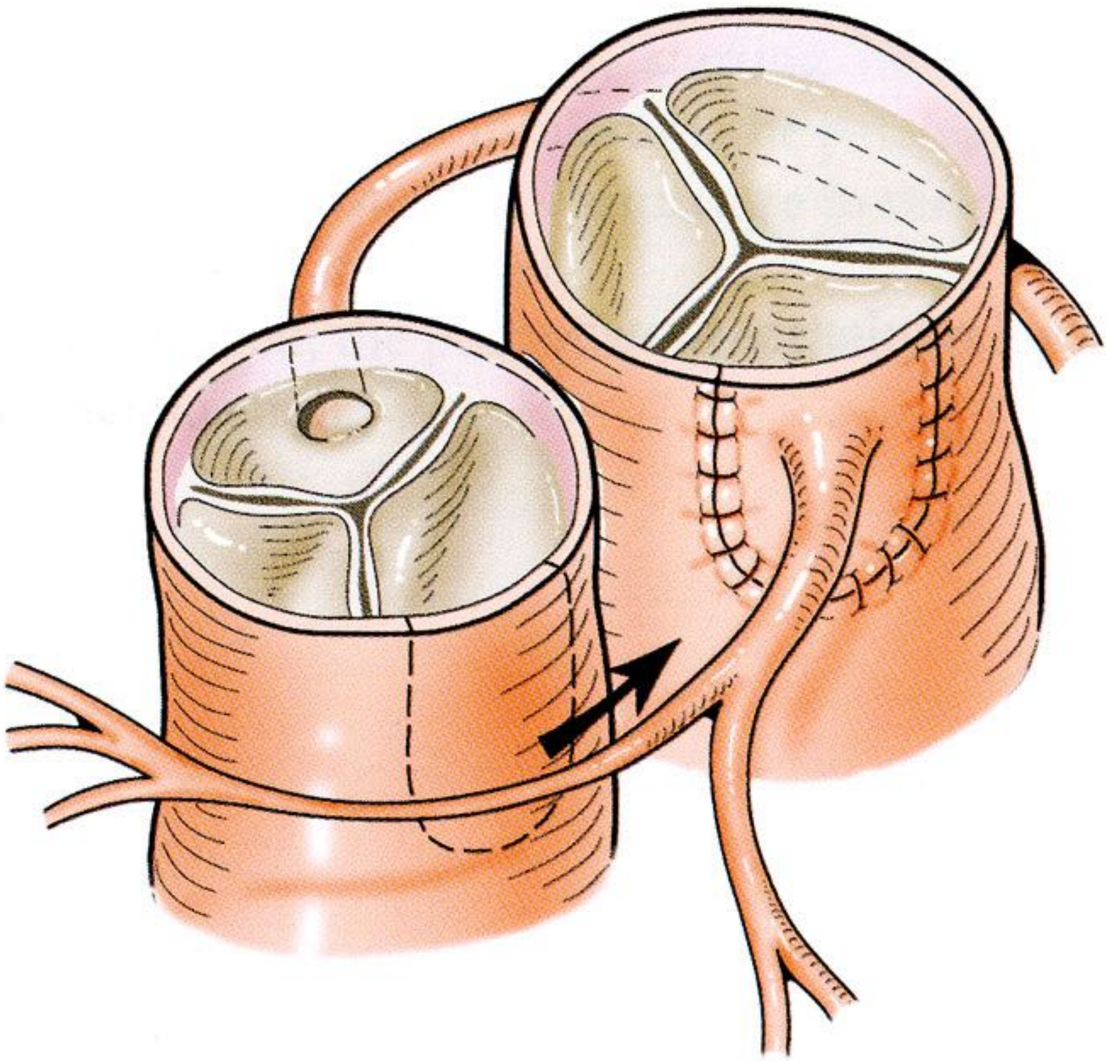

Coronaire intra-murale - technique

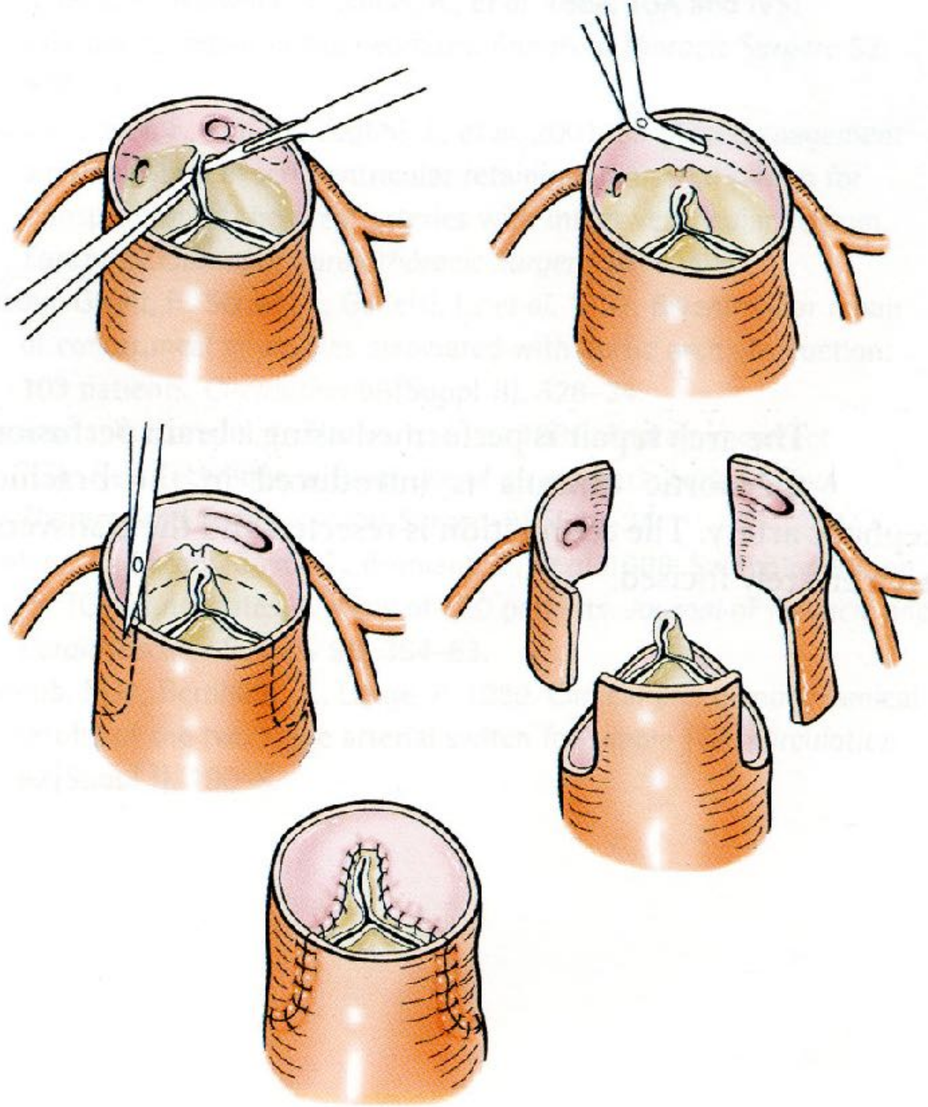

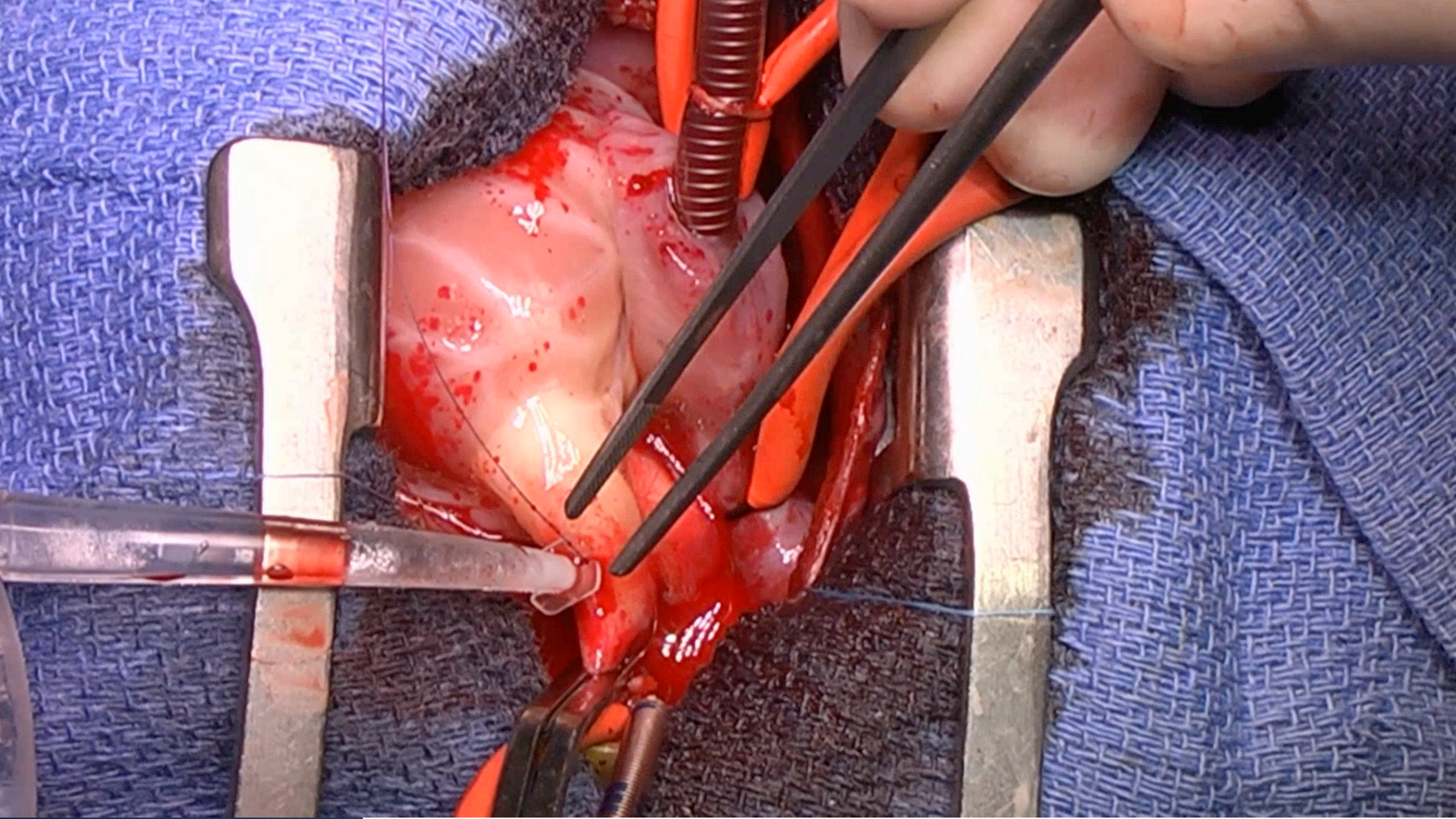

TGV CIV CoA

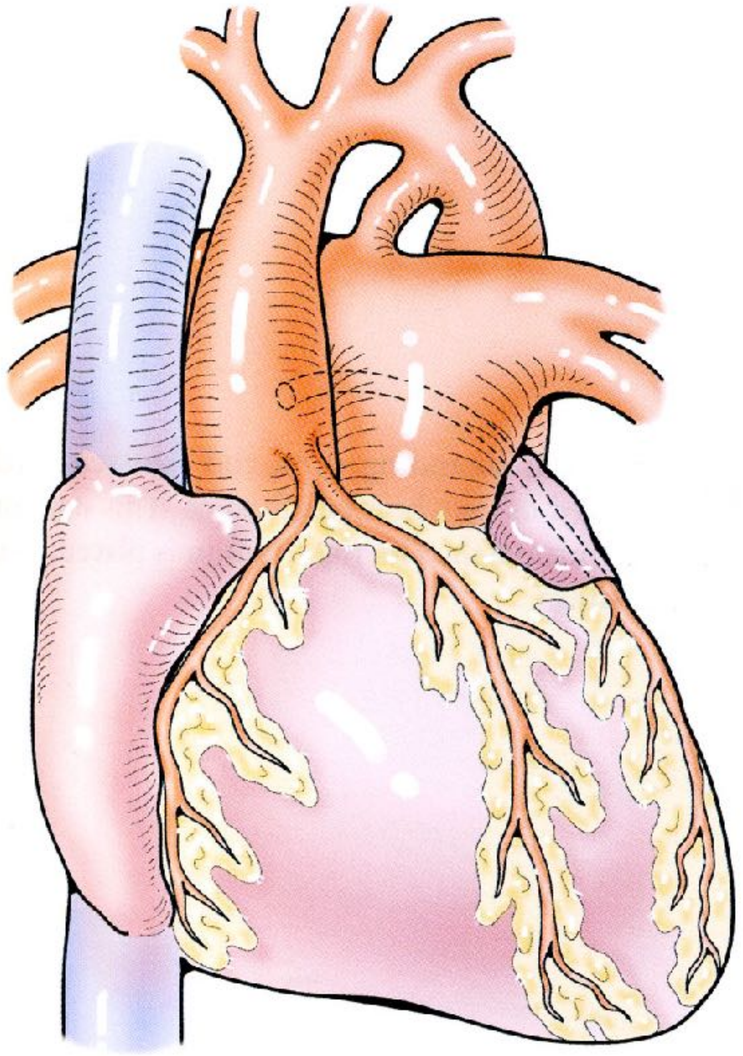

TGV CIV CoA

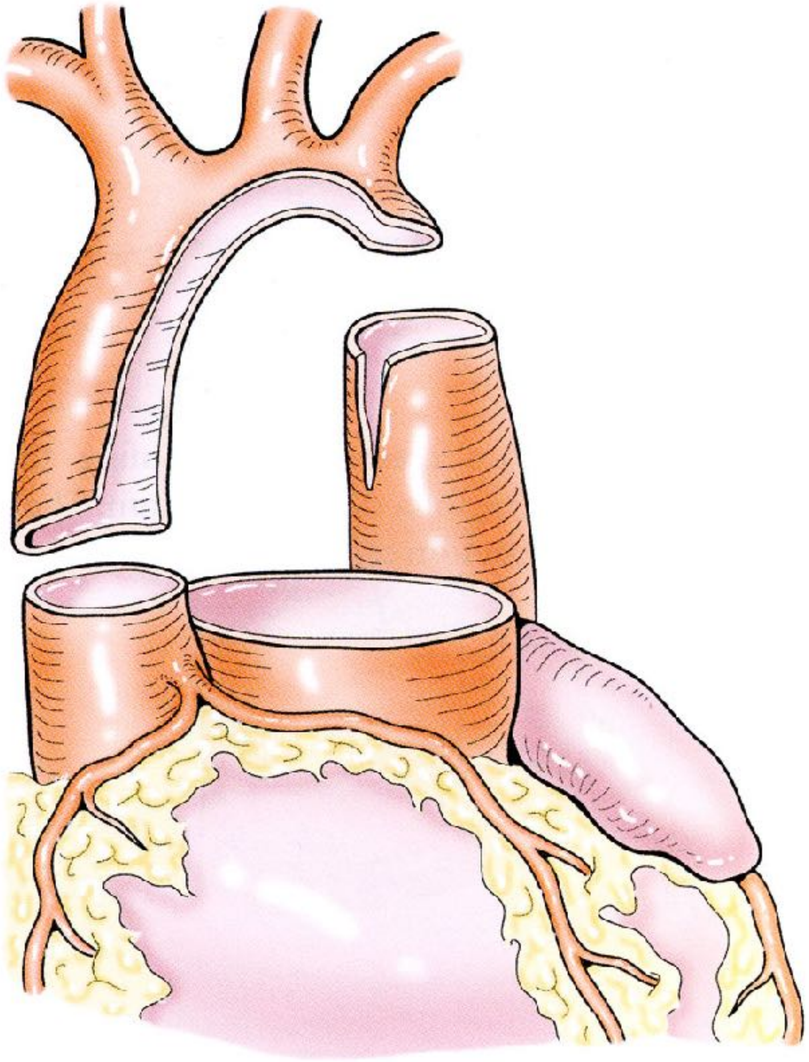

TGV CIV CoA

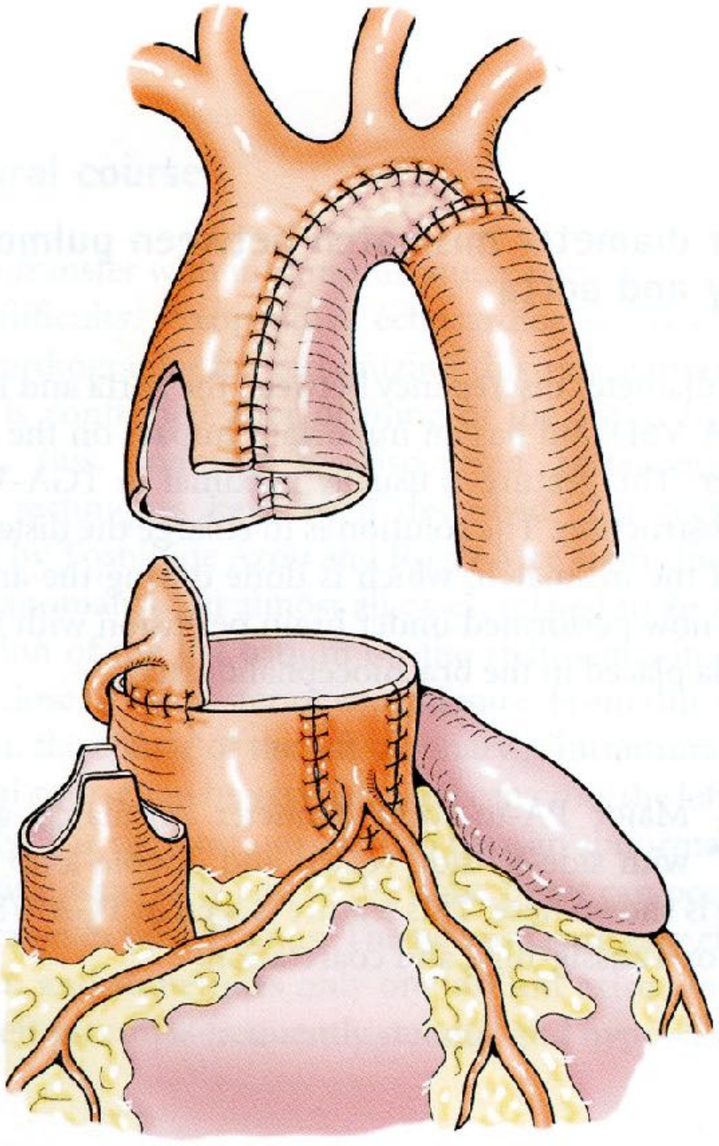

Introduction

Problèmes postopératoires

- ischémie coronarienne
  - révision peropératoire
  - sternum ouvert
  - réintervention précoce

- préparation VG
  - patience
  - assistance circulatoire

Introduction

Problèmes tardifs

- sténose coronaire
  - coronarographie
  - réintervention
- sténose voie pulmonaire
- insuffisance aortique
- HTAP (arteriolite pulmonaire)

Arigato