CHU
Hôpitaux de
Bordeaux

Congenital mitral anomalies

Dr Xavier IRIART

Department of congenital heart disease

University hospital of Bordeaux

Epidémiologie

- Prévalence: 0.5%
- Rarement isolées

  - Shone: 35%

  - Anomalies du cœur gauche: 76%
- IM:72%, Sténose:13%, IM + Sténose: 15%

Fuller et al. Semin Thorac Cardiovasc Surg Pediatr Card Surg Ann 2009

Banerjee et al. Am J Cardiol 1995

Epidémiologie

- Etude échocardiographique

- Sur 13400 enfants: 65 malformations mitrales

  - Parachute: 0.17%
  - Anneau supra-mitral: 0.15%
  - Cleft: 0.07%
  - DOMV: 0.05%

Banerjee et al. Am J Cardiol 1995.

Pathophysiology : holistic approach

- Mitral stenosis/regurgitation can involve **multiple segments** of the valve apparatus +++

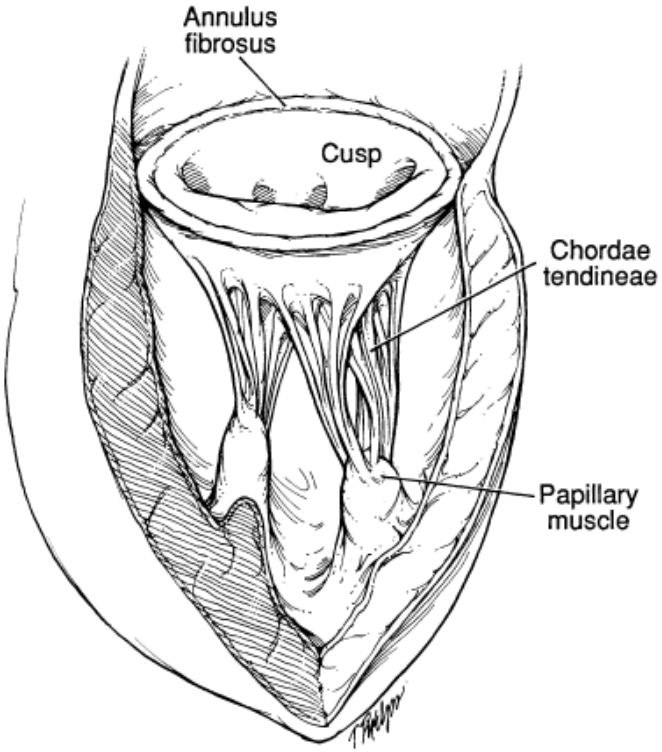

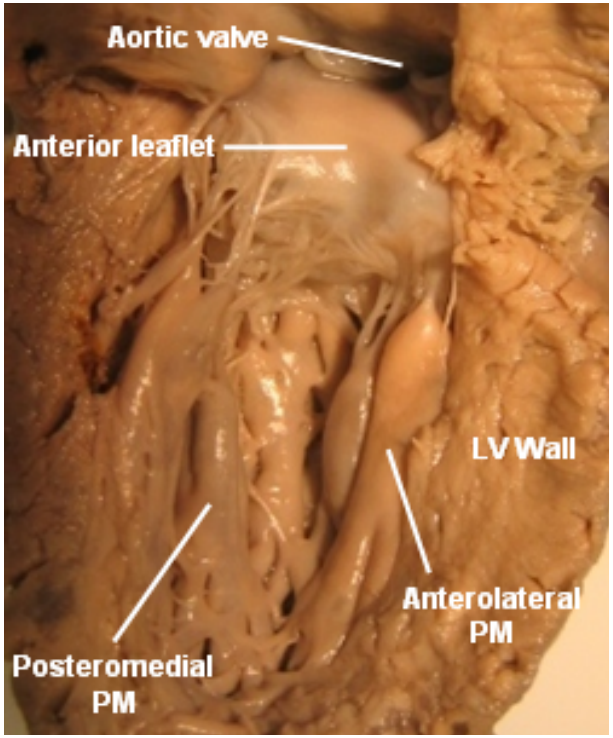

Classification des IM (CARPENTIER)

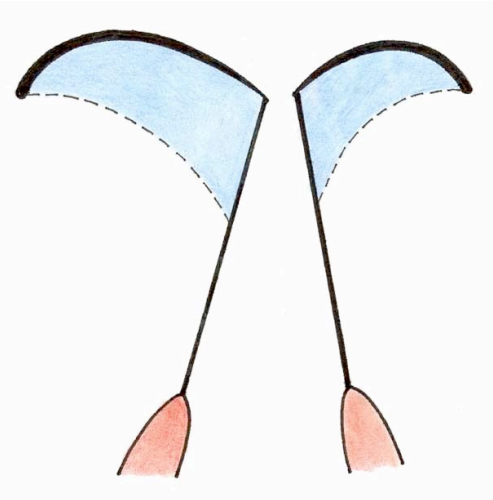

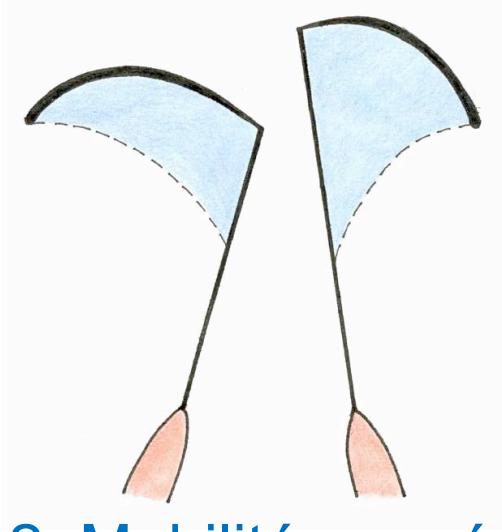

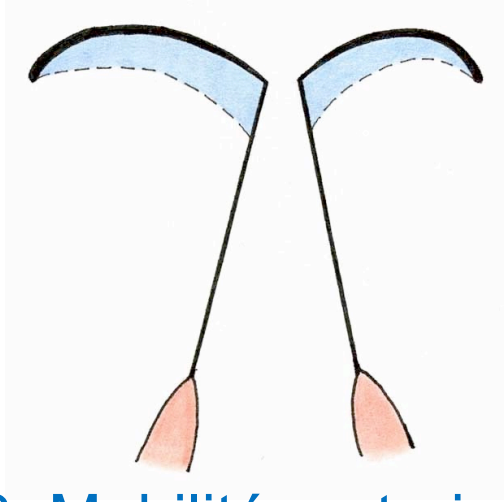

1. Mobilité normale

- Dilatation de l'anneau
- Cleft
- Double orifice

⇨**IM**

2. Mobilité exagérée

- Prolapsus

⇨**IM**

3. Mobilité restreinte

Muscles papillaires normaux

- Ring

Muscles papillaires anormaux

- Parachute
- Hamac

⇨**IM et/ou Sténose**

CHU Hôpitaux de Bordeaux

Classification des sténoses

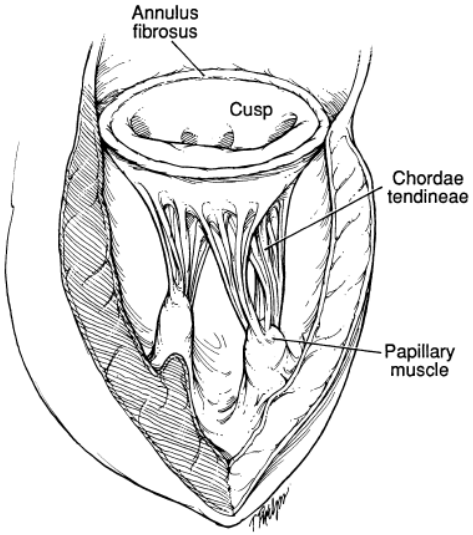

- CHS Nomenclature
  - Supra valvar
  - Valvar :
    - A. Annular
    - B. Leaflets
  - Sub valvar:
    - A. Cordal
    - B. Papillary muscle

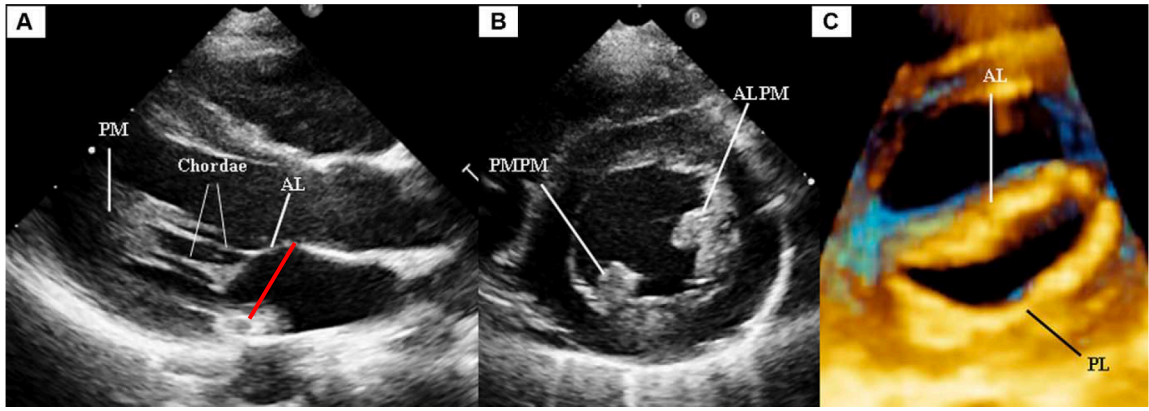

Supravalvar stenosis

- Classification determined by the position of the membrane **relative to the LAA**

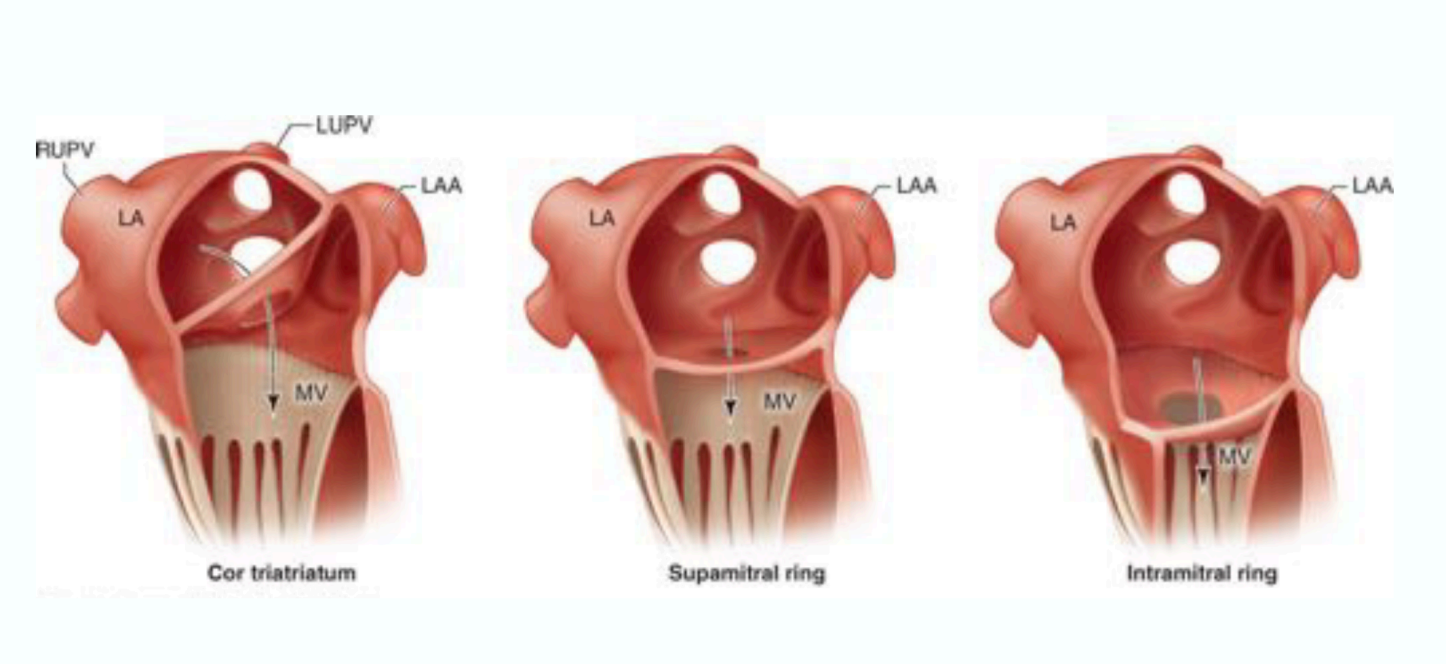

Supravalvar stenosis: cor triatrium

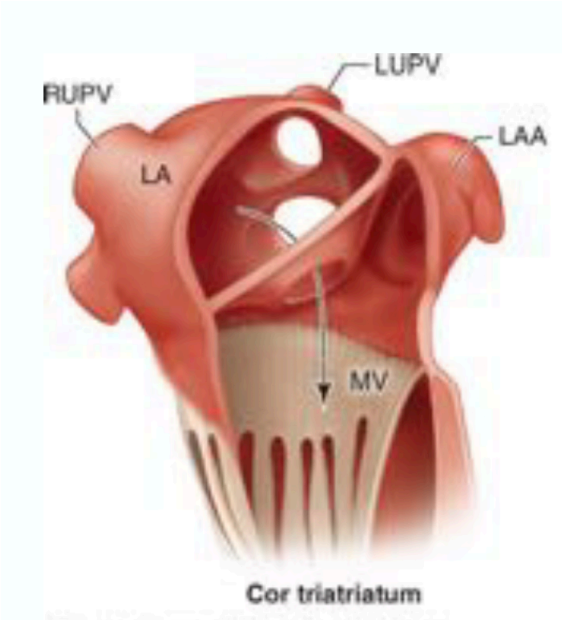

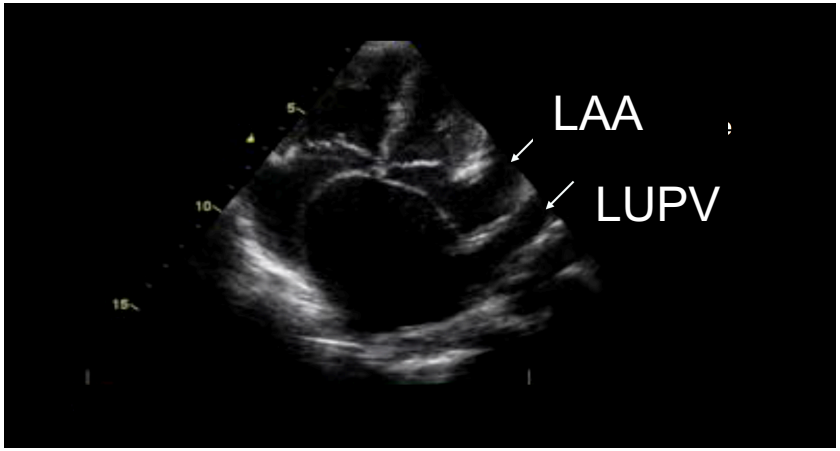

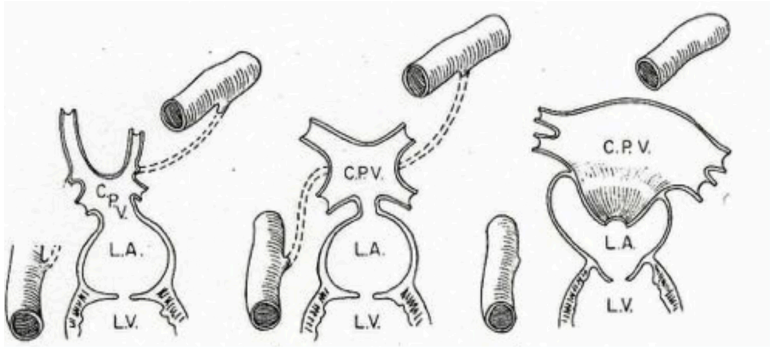

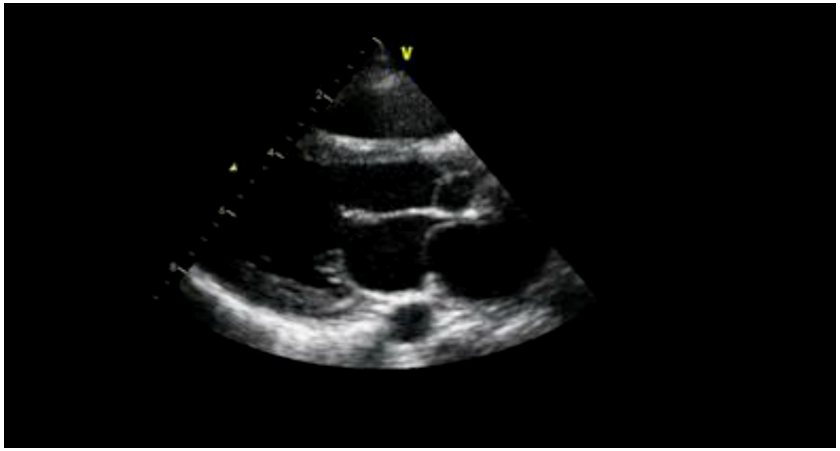

Supravalvar stenosis: cor triatrium

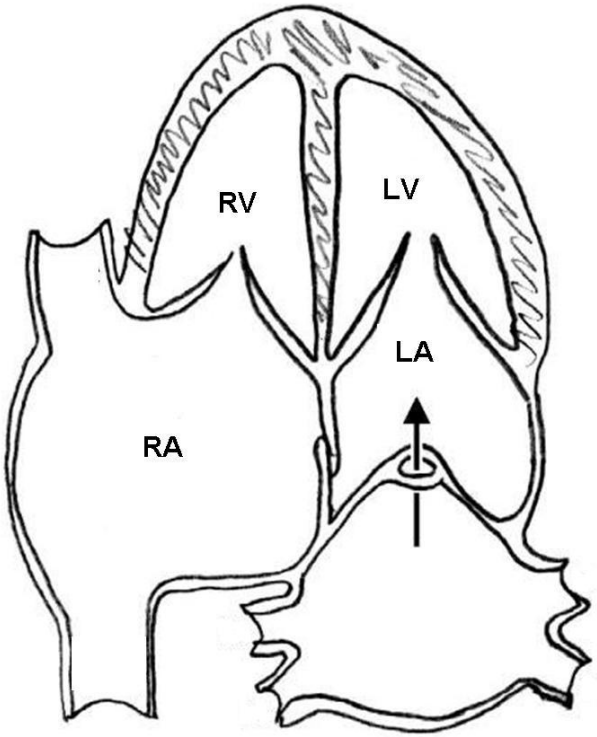

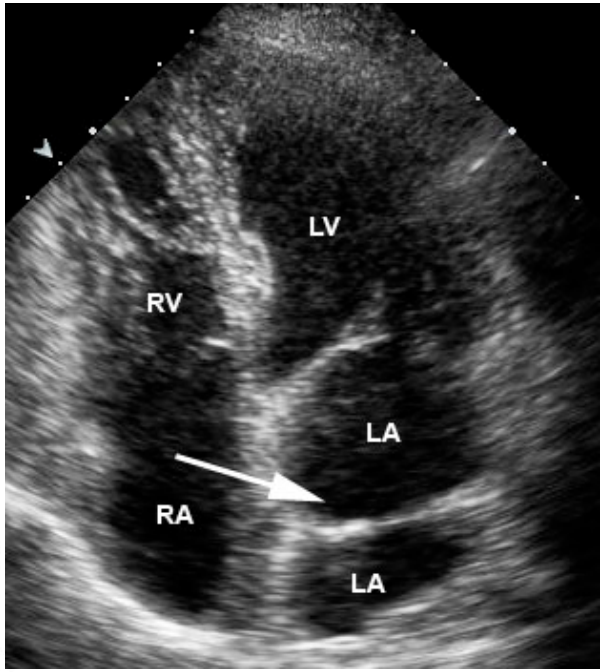

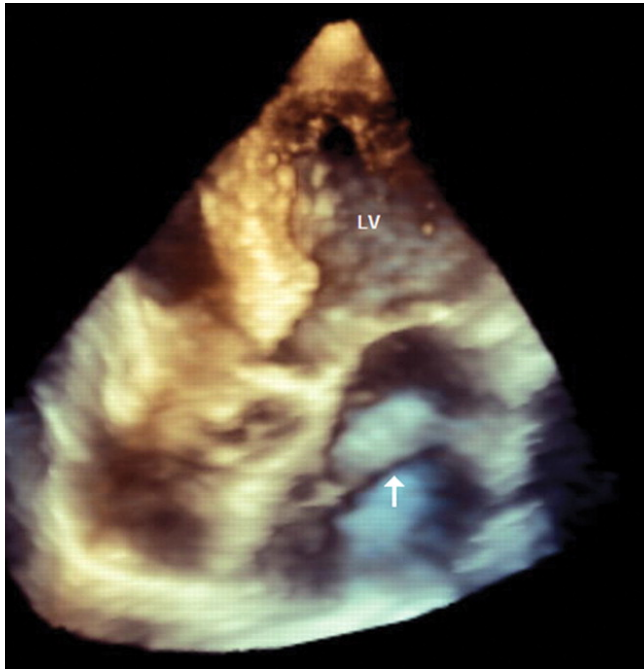

Supravalvar stenosis: cor triatrium

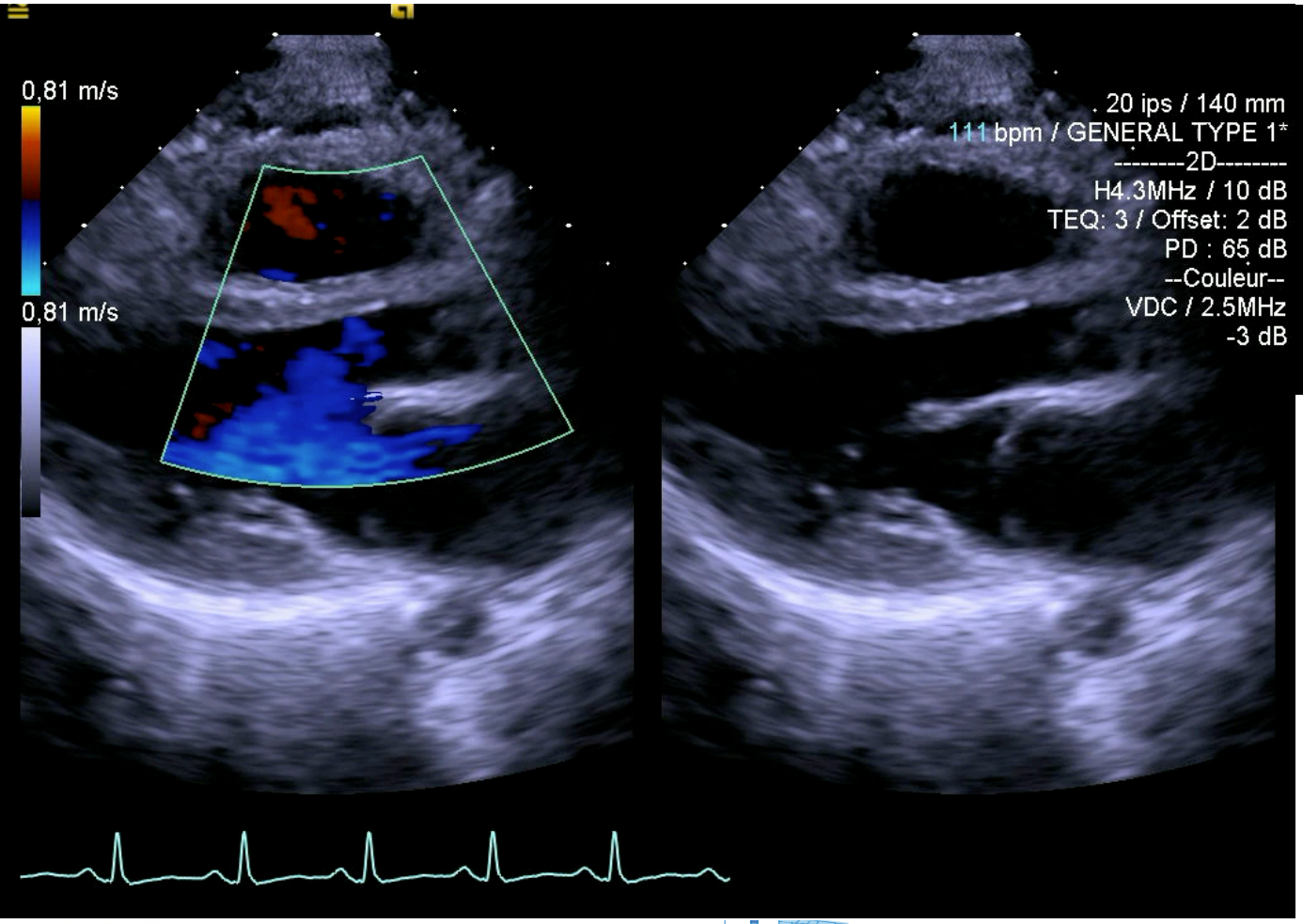

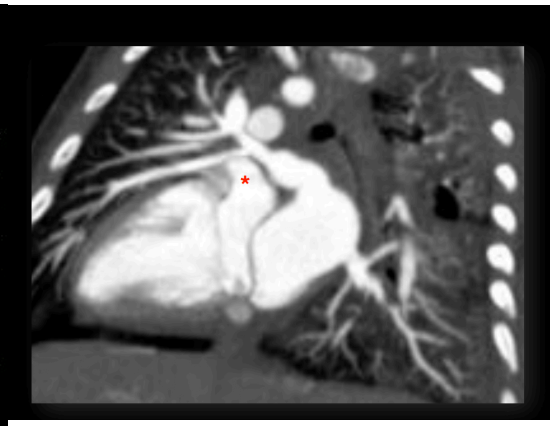

Supravalvar stenosis: cor triatrium

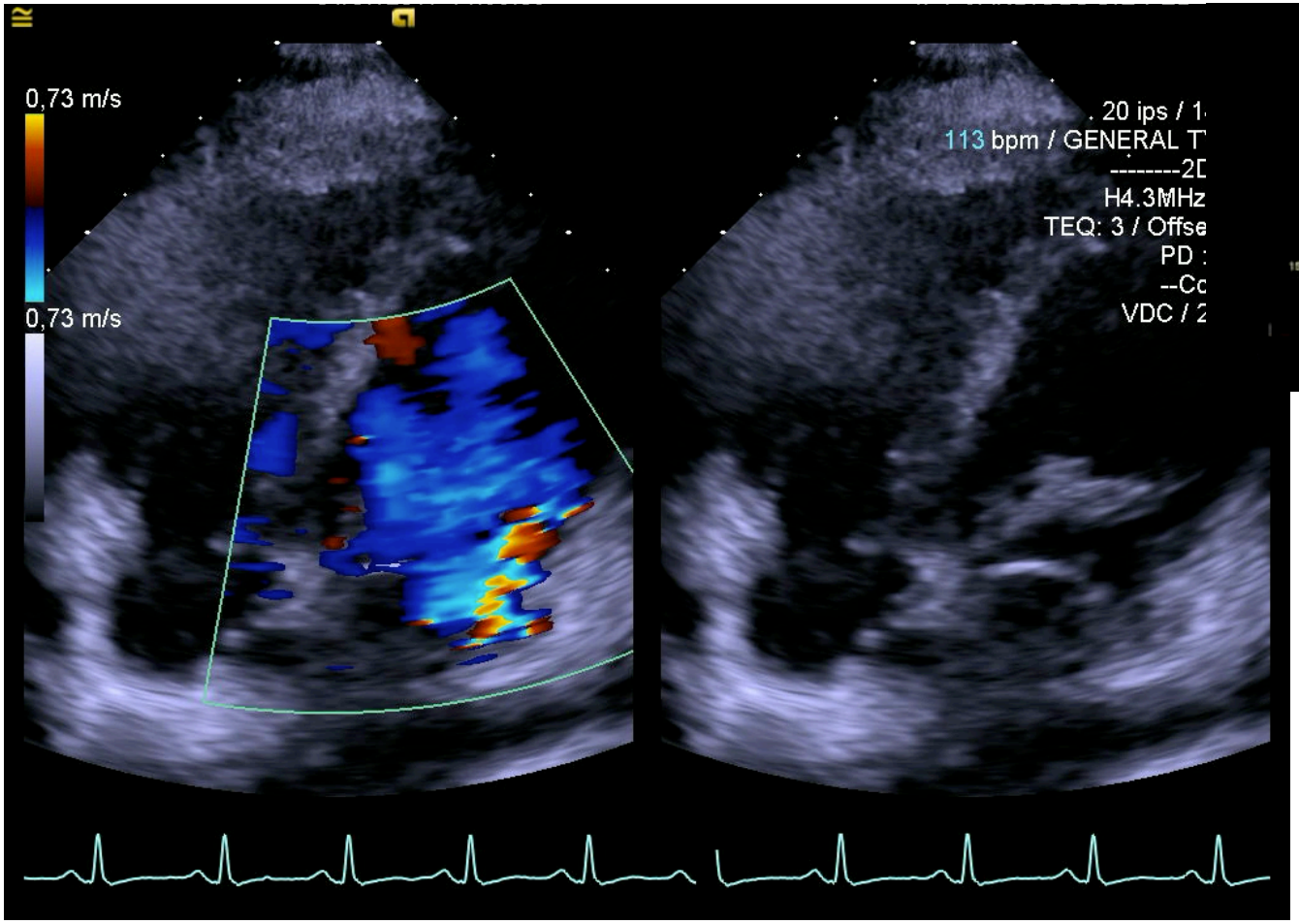

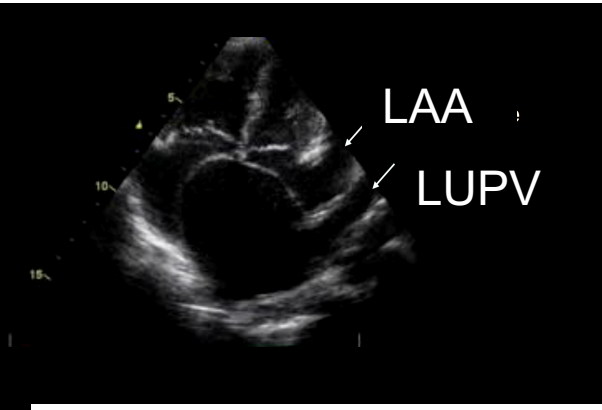

Supravalvar stenosis: supra mitral ring

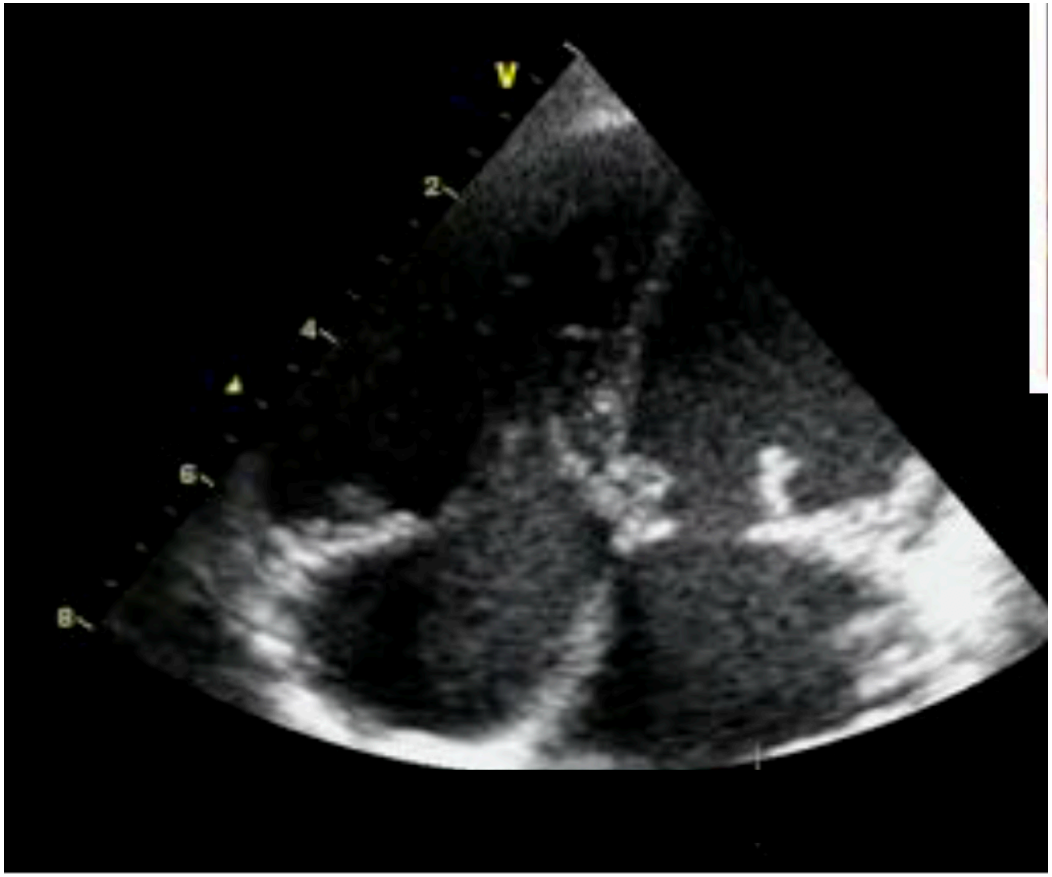

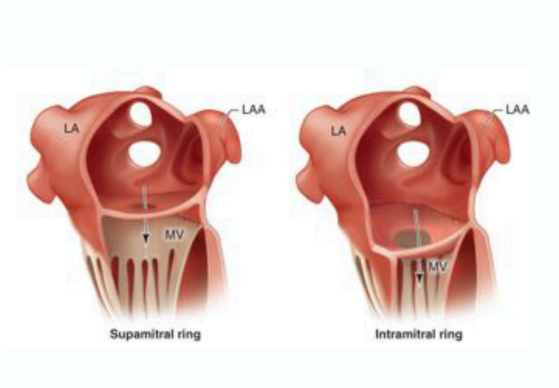

Supravalvar stenosis: supra mitral ring

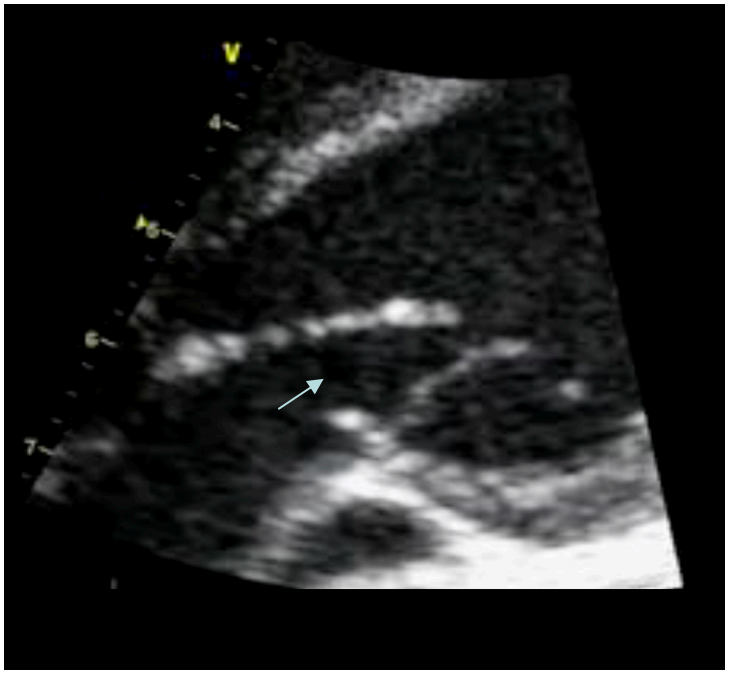

Supravalvar stenosis: supra mitral ring

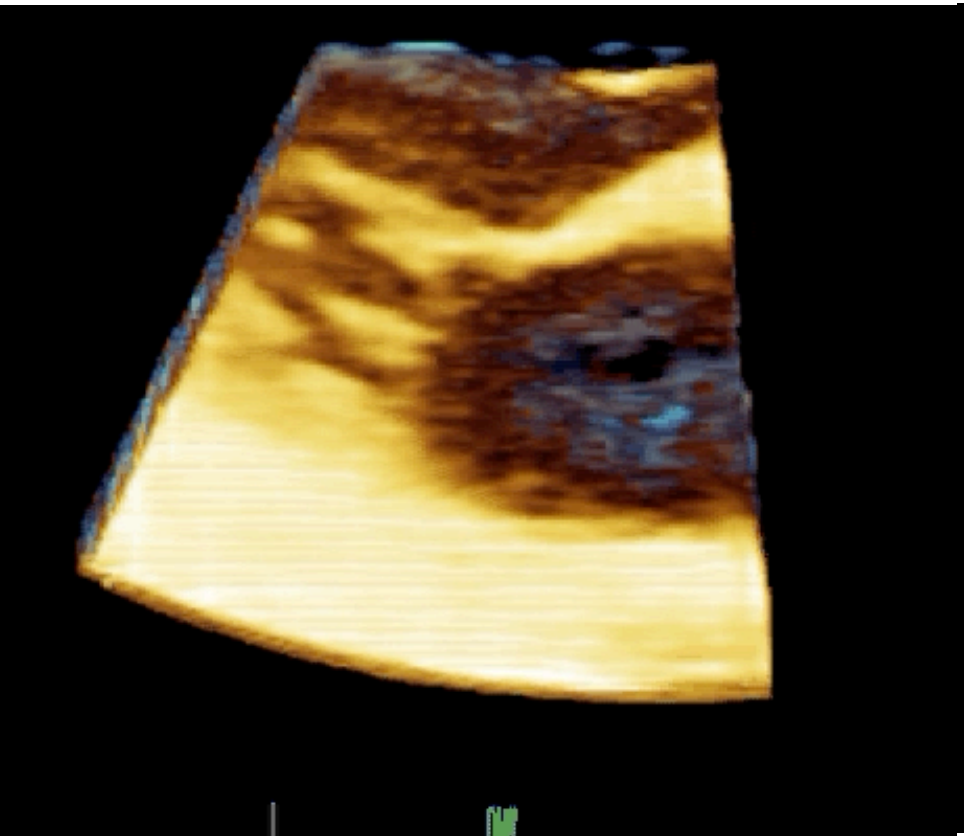

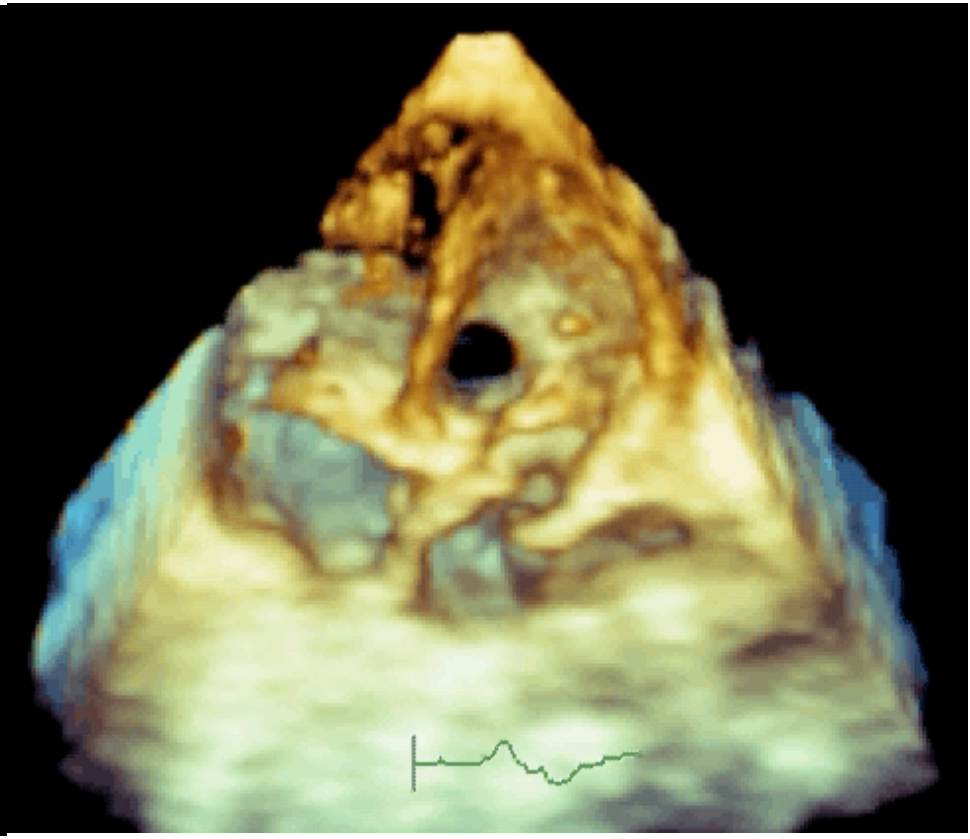

Parachute mitral valve

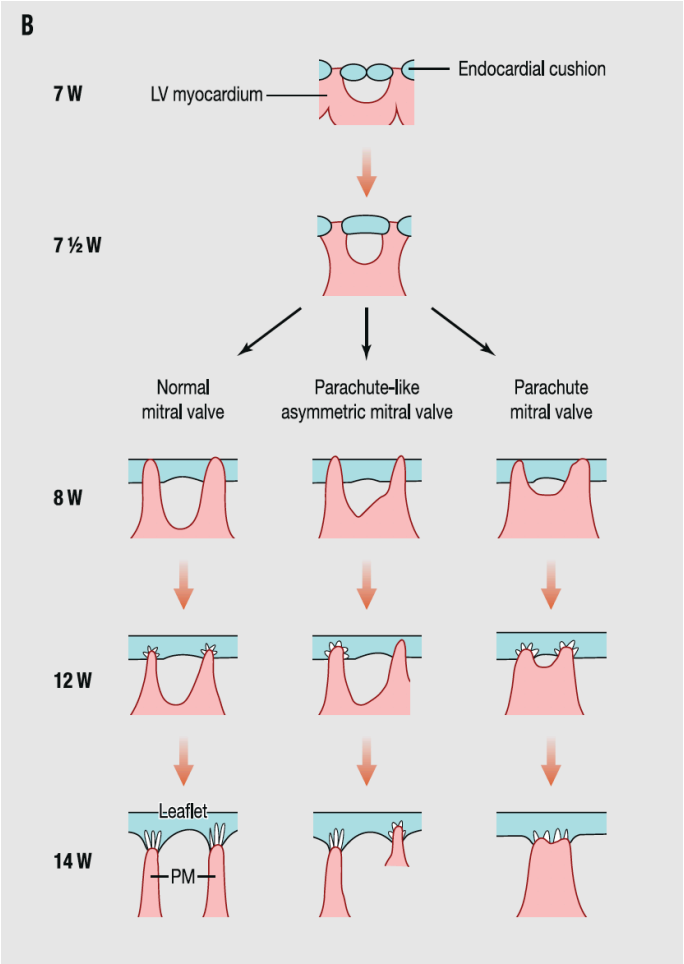

Parachute mitral/Entonnoir

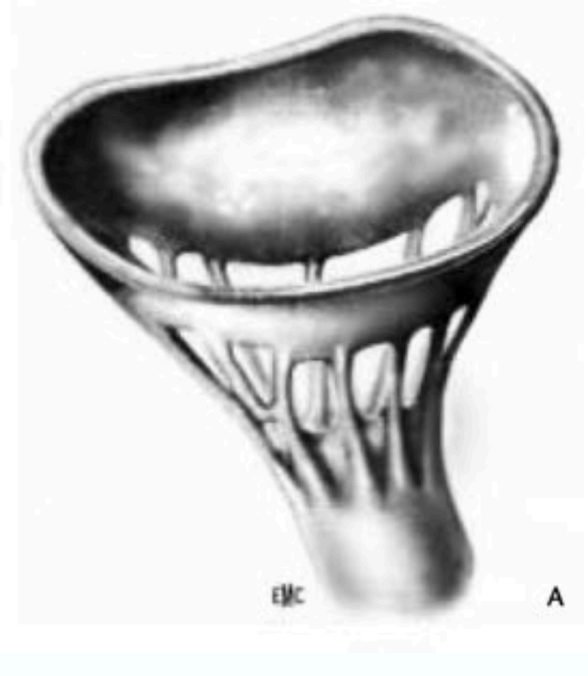

Seguela et al. ACVD 2011

CHU Hôpitaux de Bordeaux

Parachute mitral valve

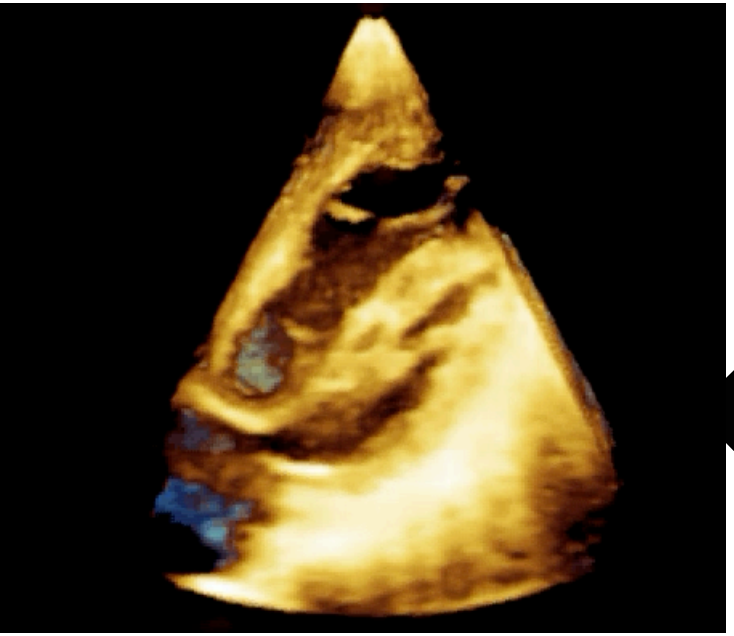



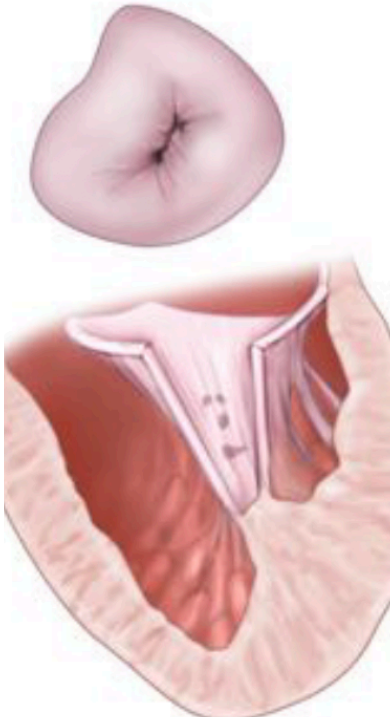

Parachute mitral valve

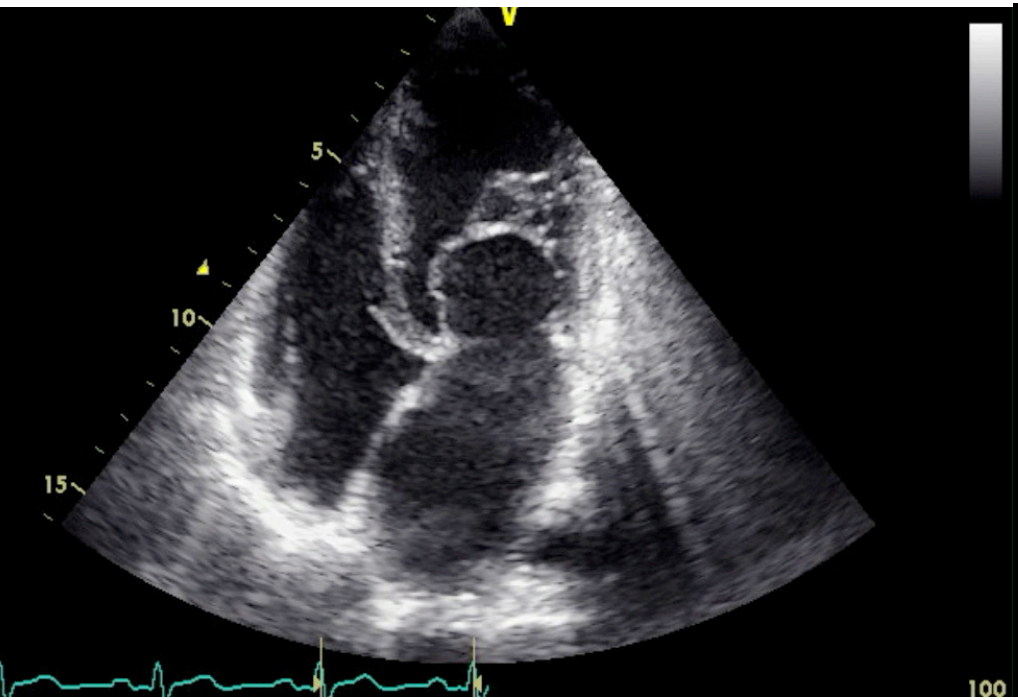

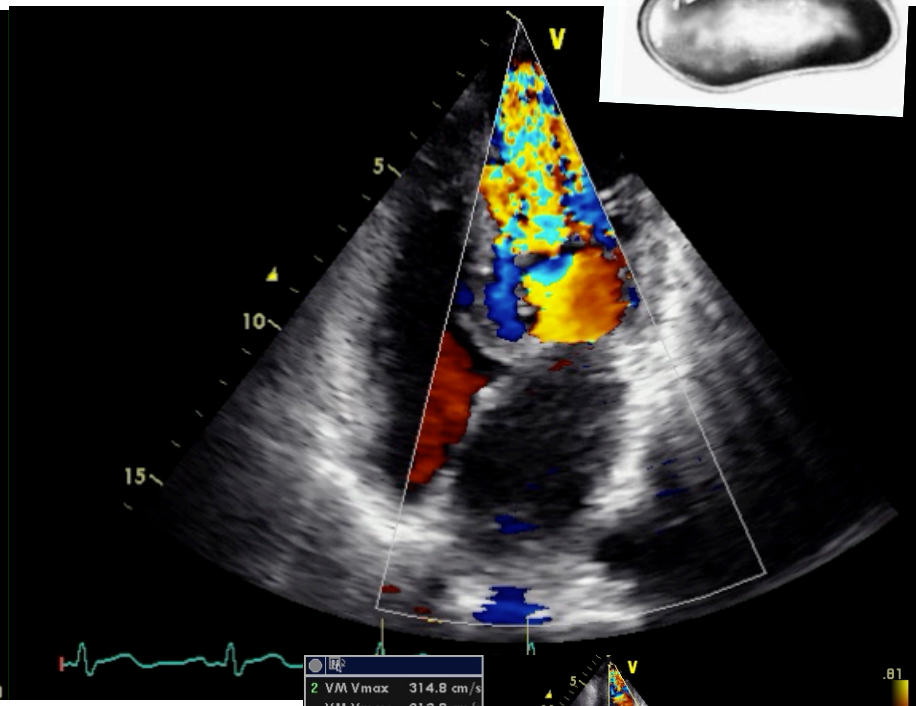

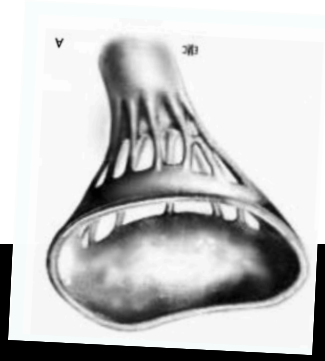

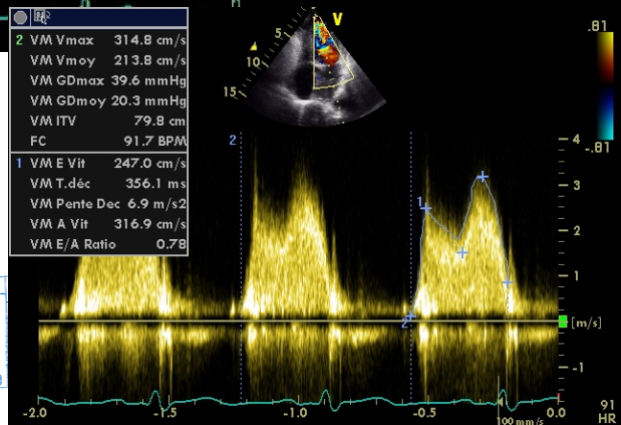

CHU Hôpitaux de Bordeaux

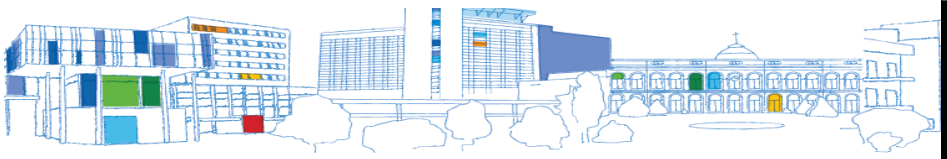

Parachute-like mitral valve

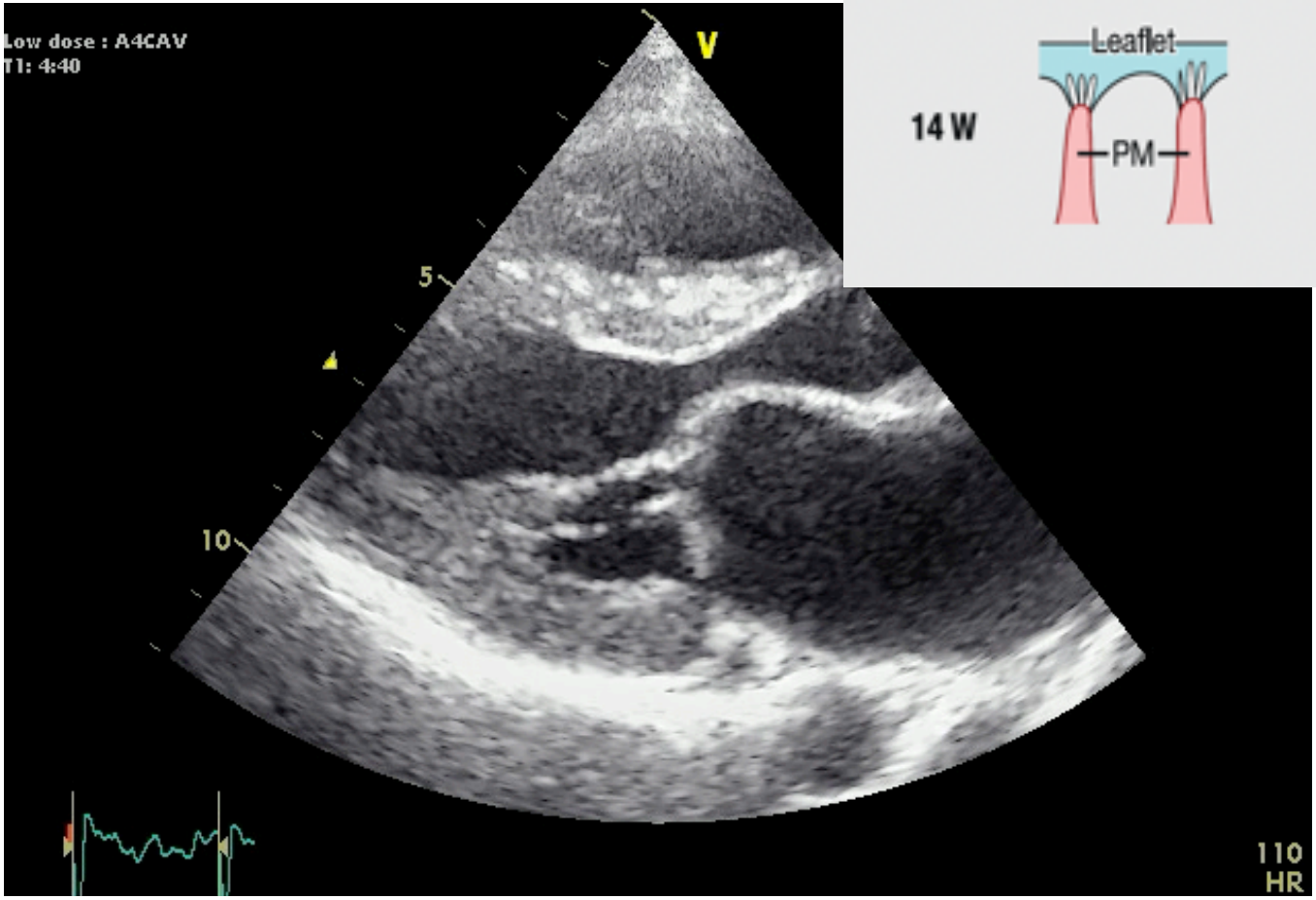

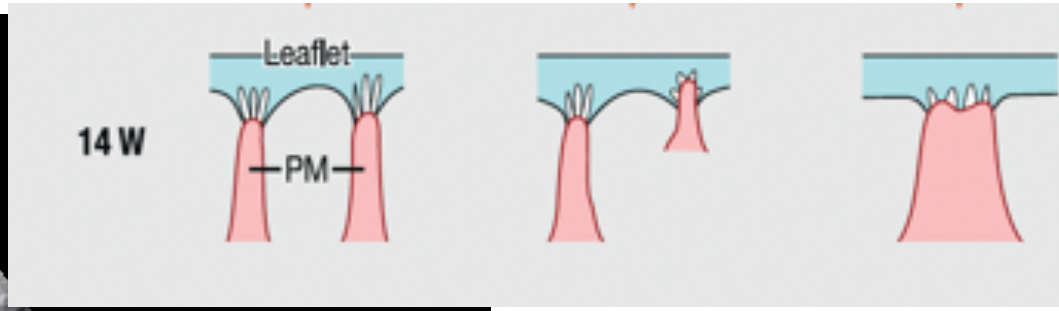

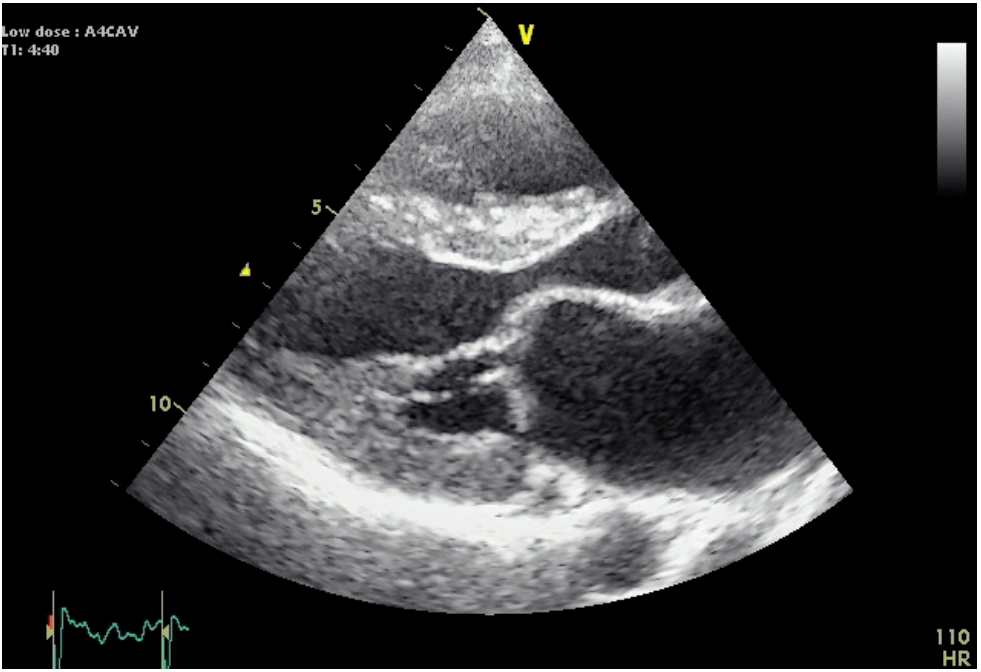
Low dose : A4CAV
T1: 4:40
V
5
10
110
HR

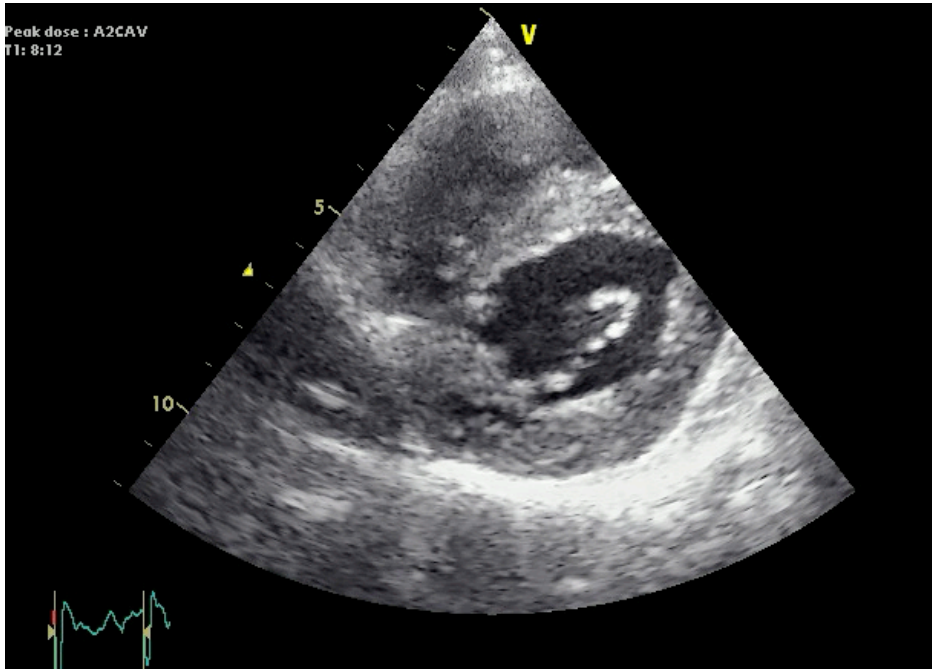
Peak dose : A2CAV
T1: 8:12
V
5
10

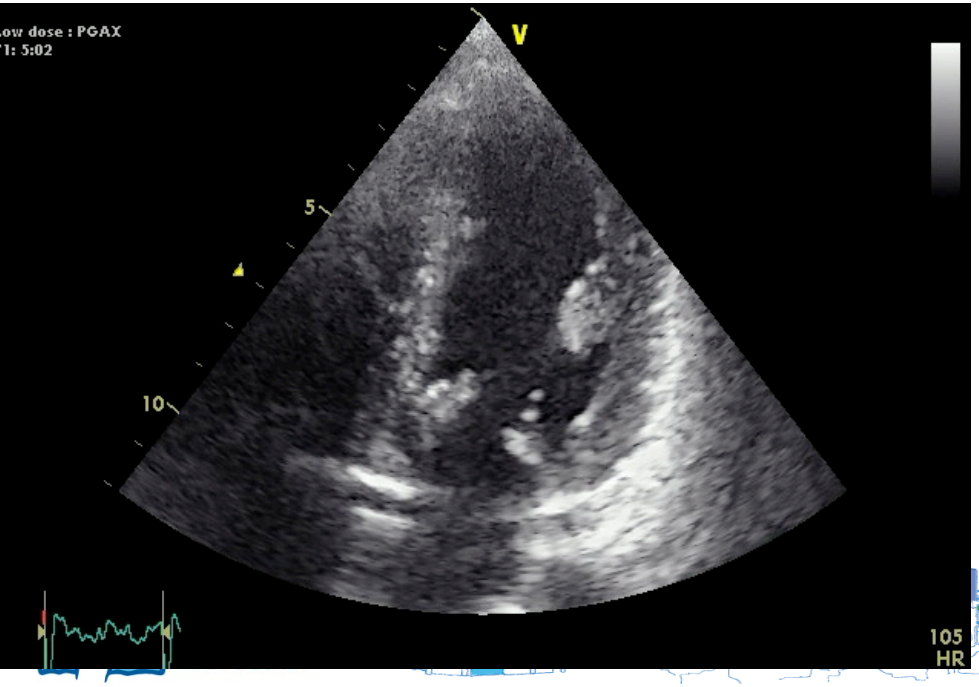
Low dose : PGAX
T1: 5:02
V
5
10
105
HR

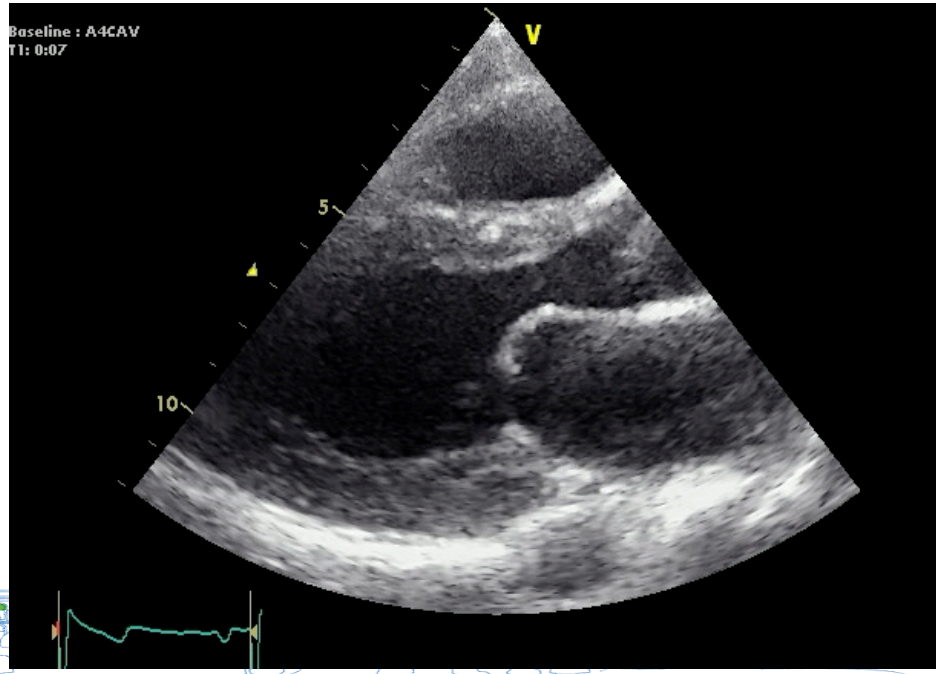
Baseline : A4CAV
T1: 0:07
V
5
10

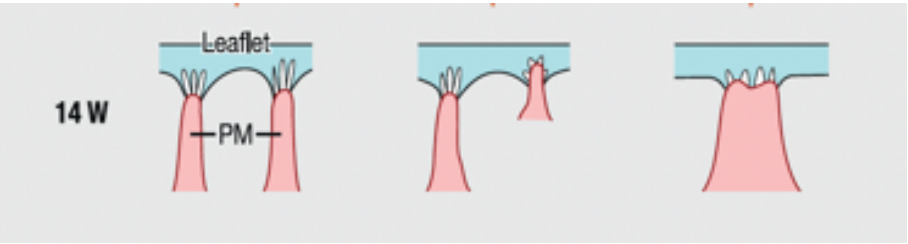

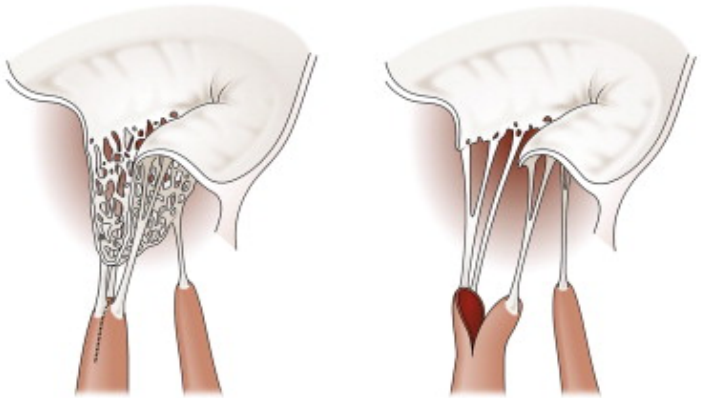

Normal mitral valve

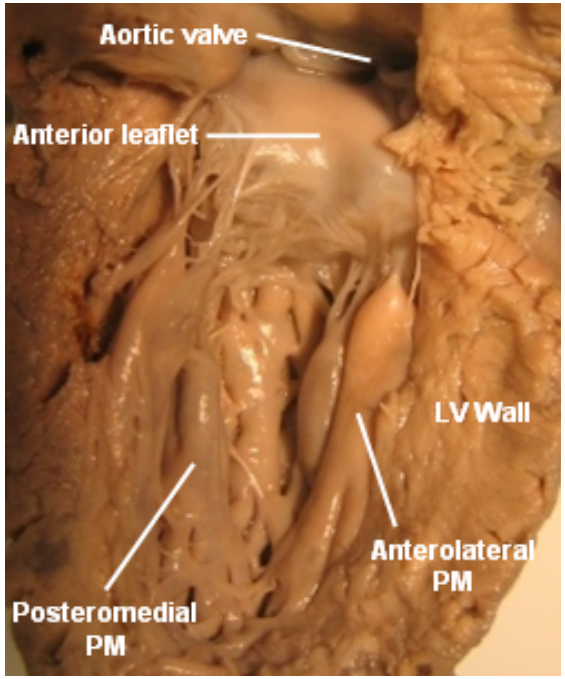

Parachute-like asymmetric mitral valve

Arcade/hammock mitral valve

Arcade/hammock

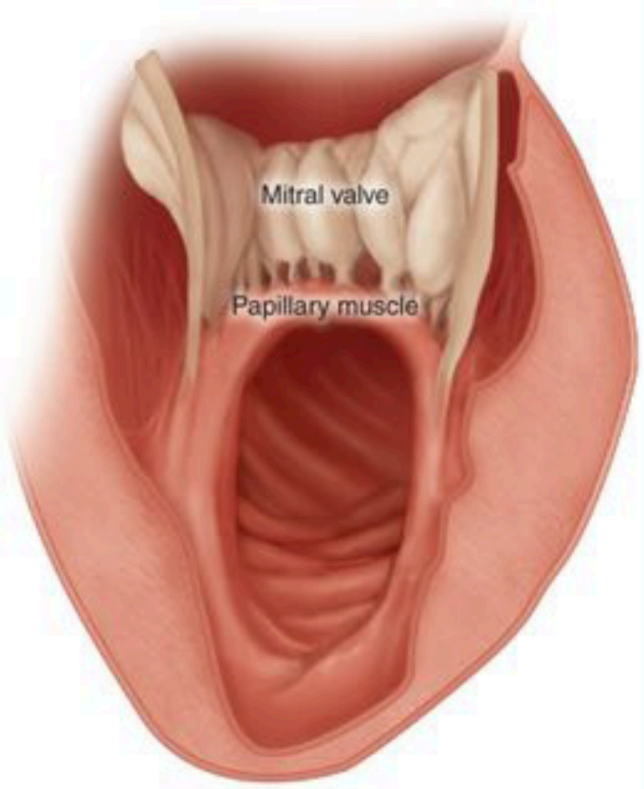

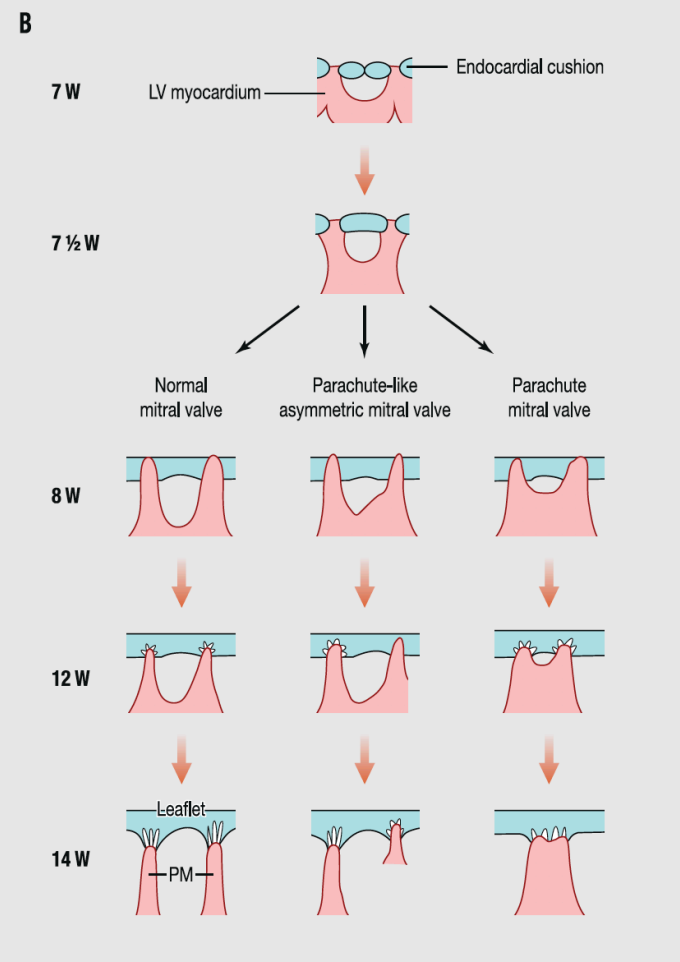

Seguela et al. ACVD 2011

Arcade/hammock mitral valve

Hamac mitral

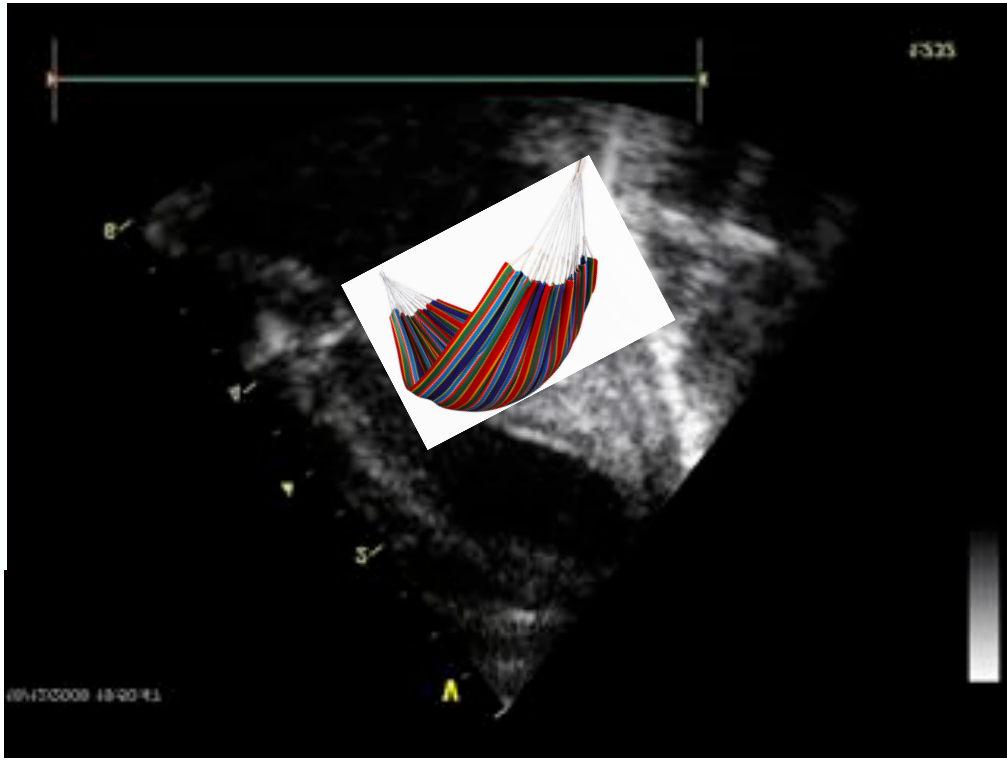

Arcade/hammock mitral valve

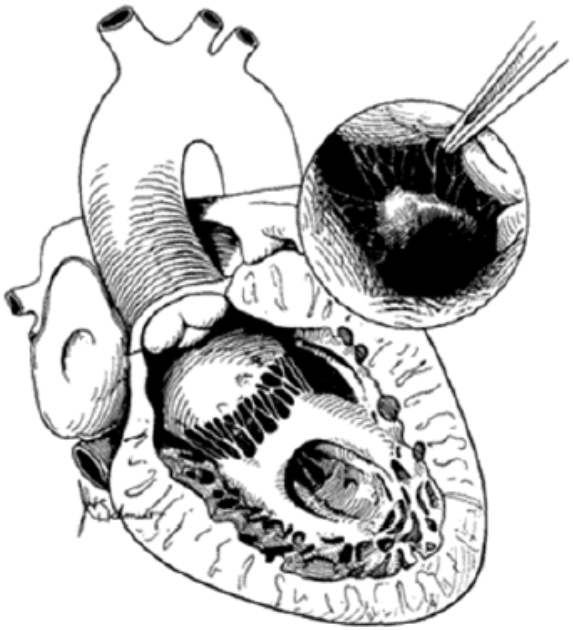

Arcade/hammock mitral valve

Arcade/hammock mitral valve

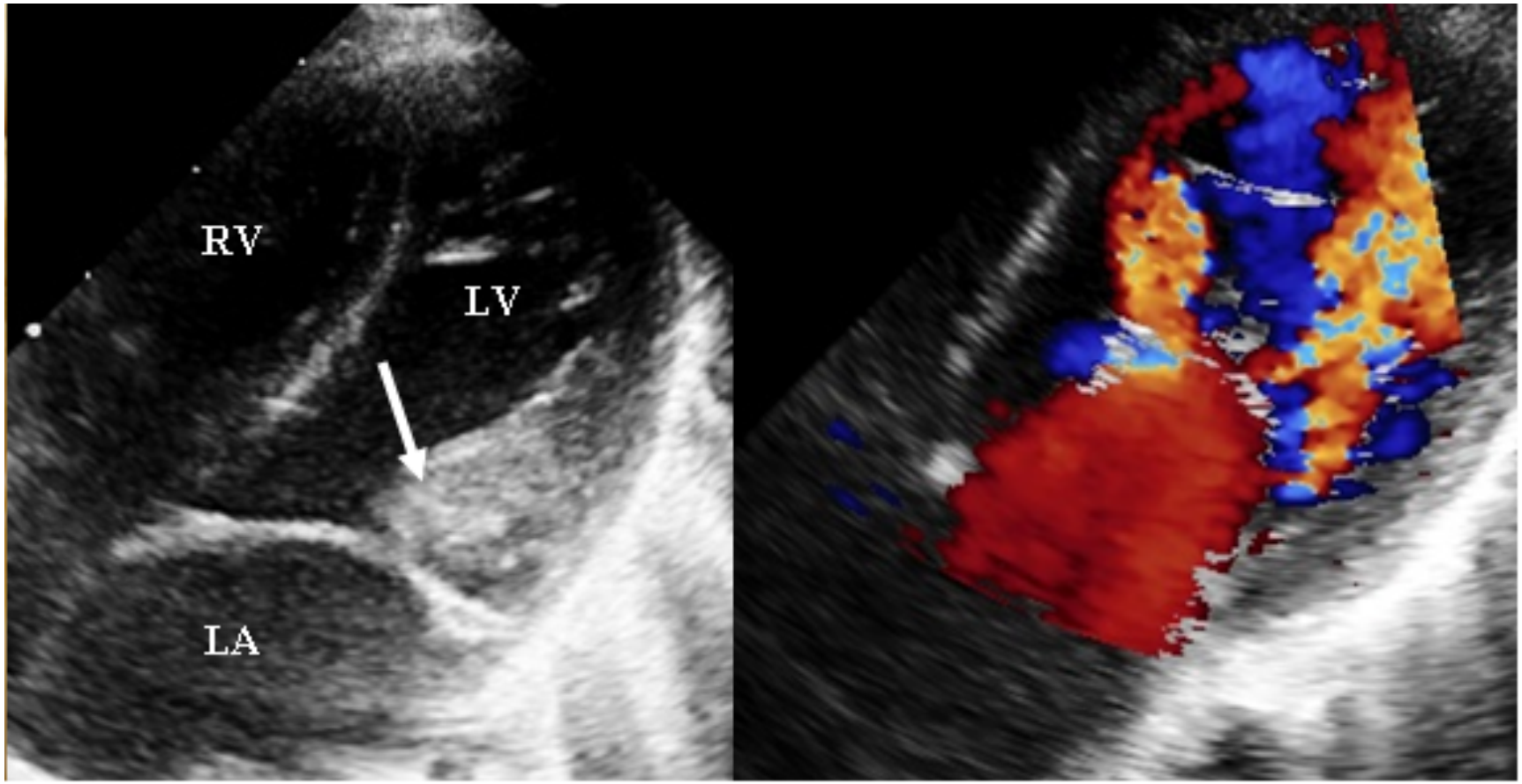

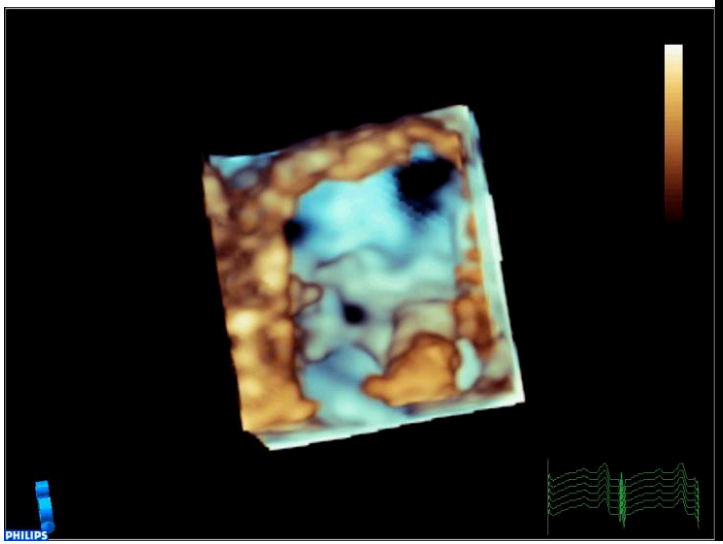
PHILIPS

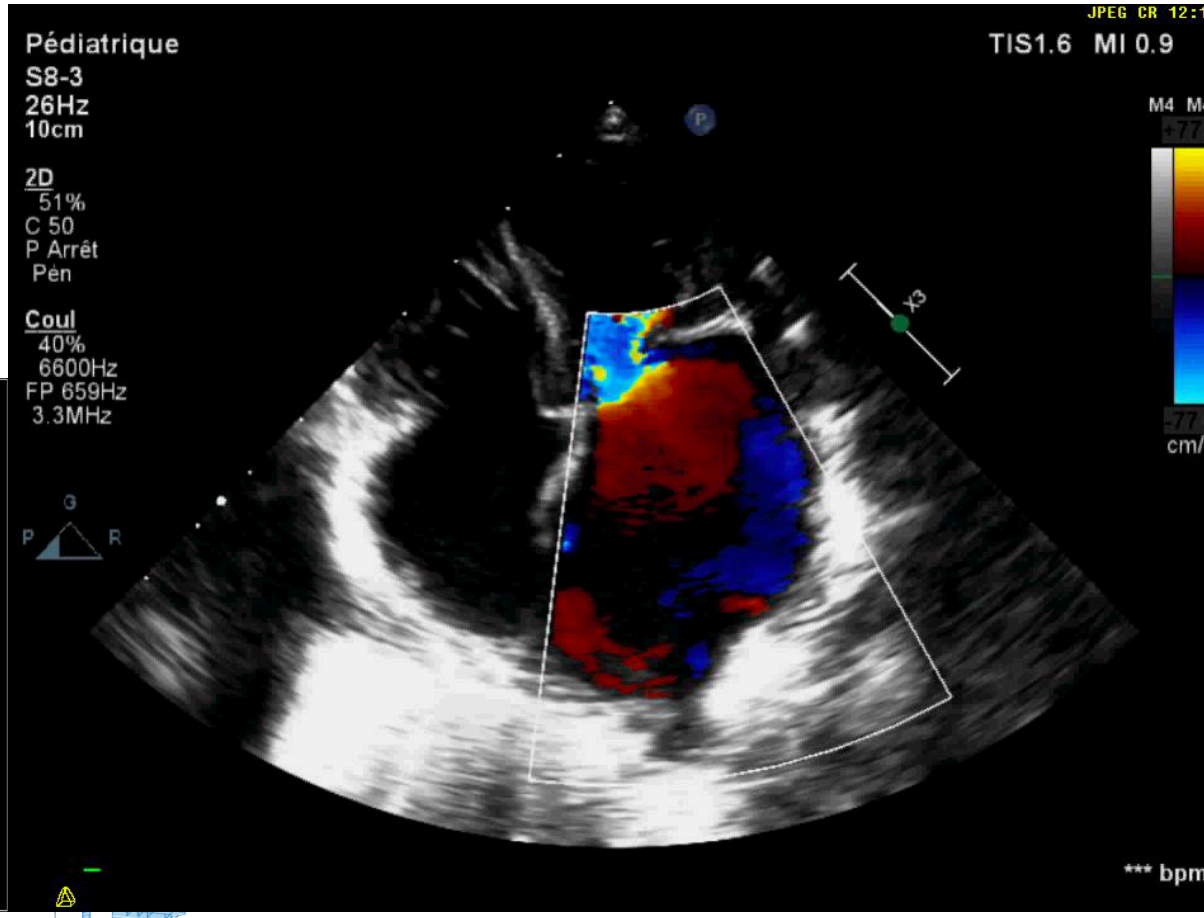
JPEG CR 12:1
Pédiatrique
S8-3
26Hz
10cm
2D
51%
C 50
P Arrêt
Pén
Coul
40%
6600Hz
FP 659Hz
3.3MHz
TIS1.6 MI 0.9
M4
cm/
X3
G
P
R
*** bpm

Arcade/hammock mitral valve

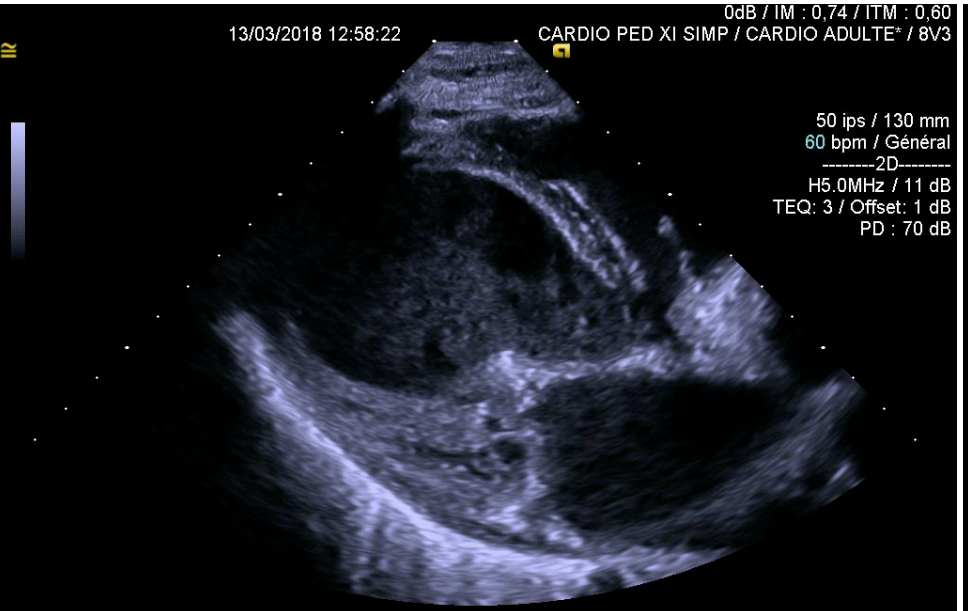

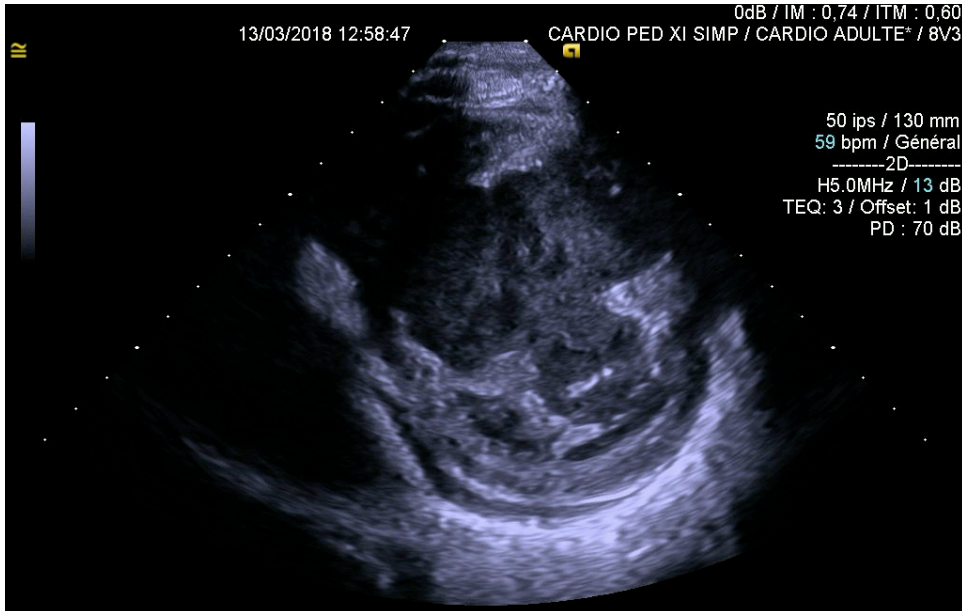

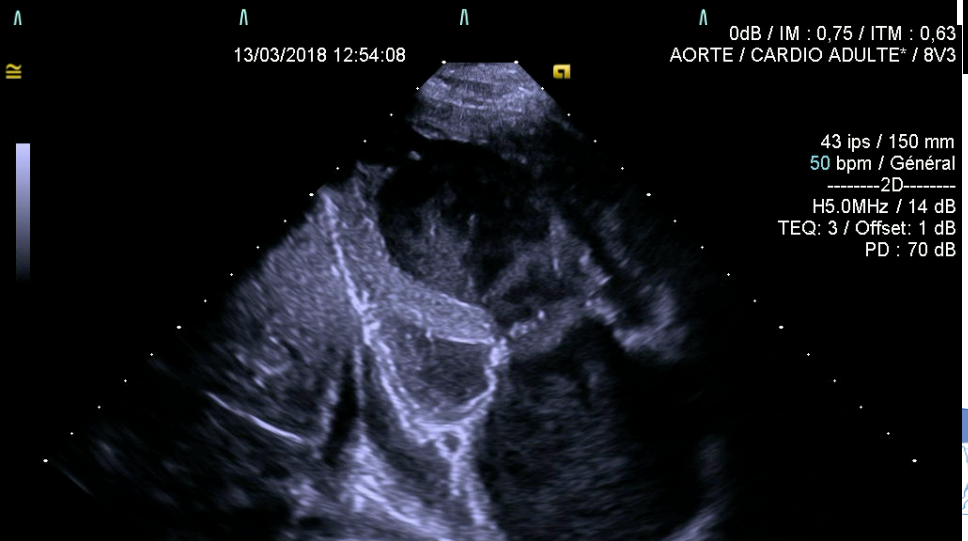

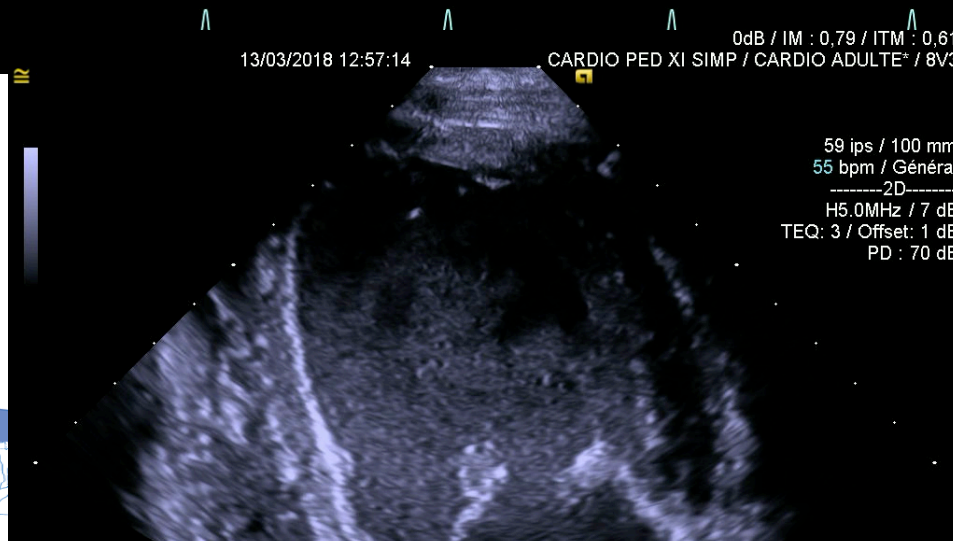

Arcade/hammock mitral valve

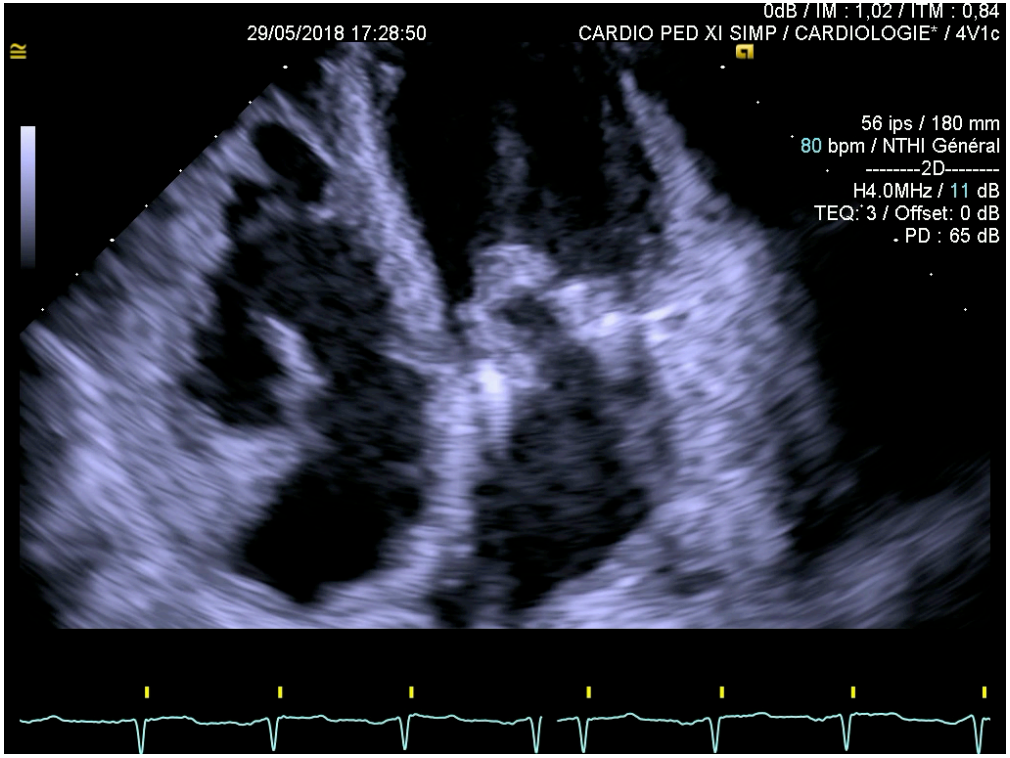

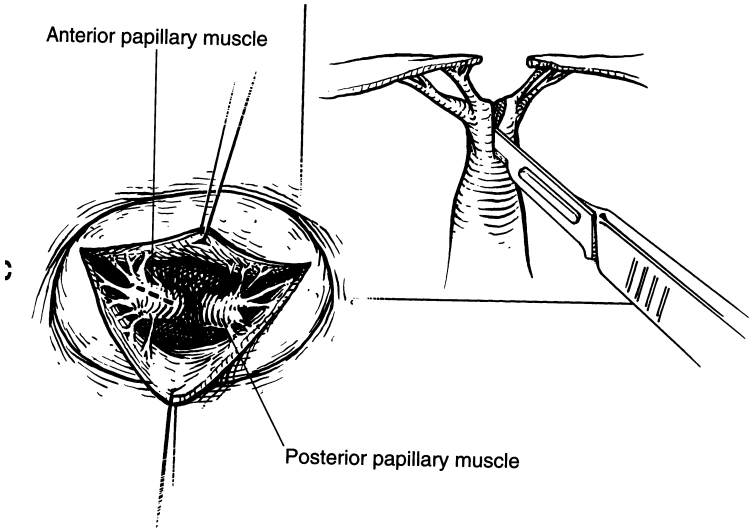

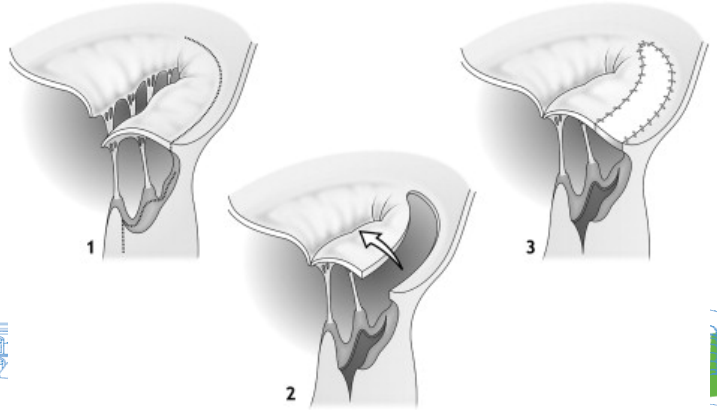

CHU Hôpitaux de Bordeaux

Hypopalstic mitral annulus

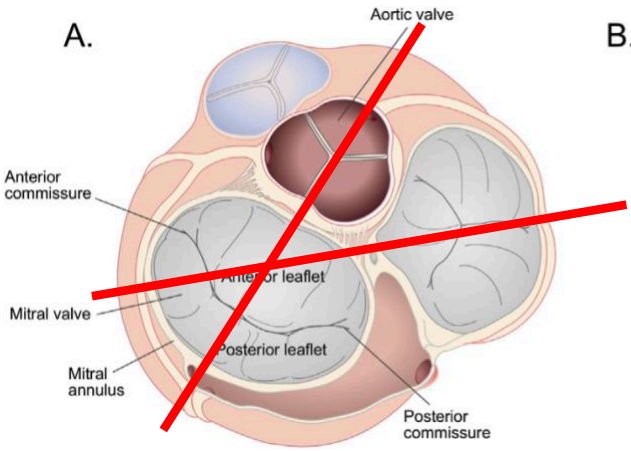

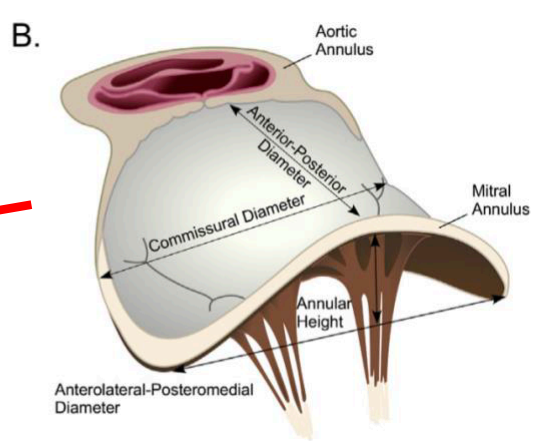

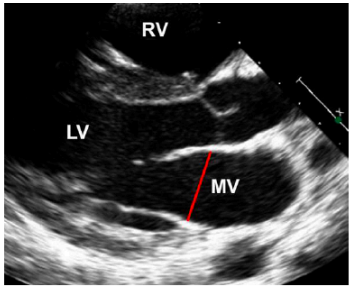

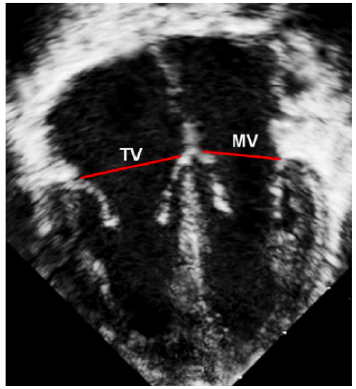

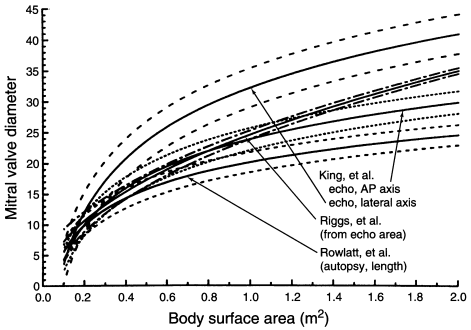

Z score < 2

CHU Hôpitaux de Bordeaux

Left SVC

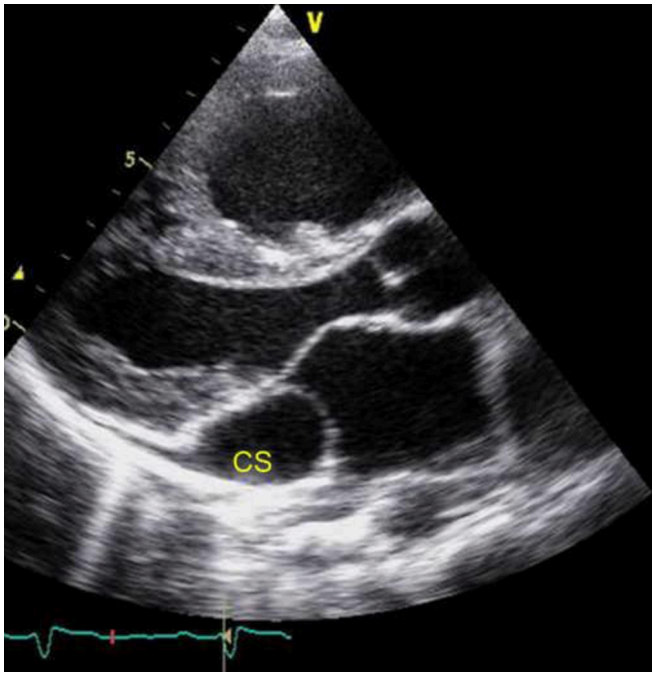

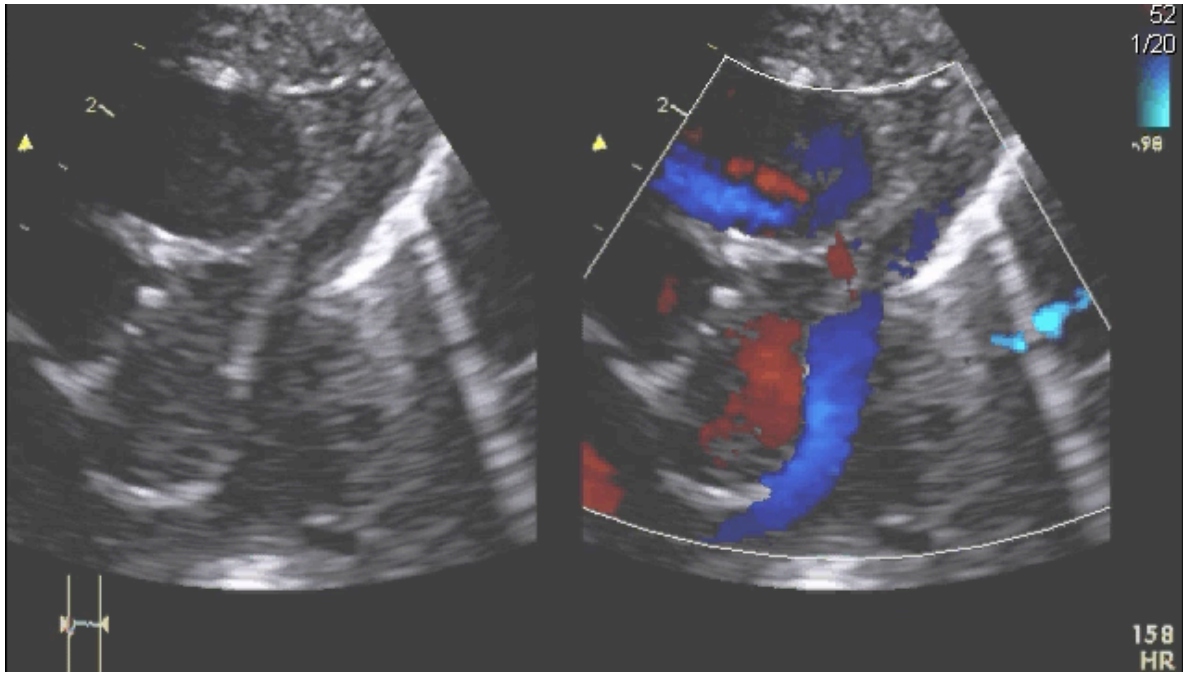

Double mitral orifice

- An accessory bridge or limbus of tissue partially or completely divide the mitral inlet into two orifices with each suborifice supported by its own chordal apparatus

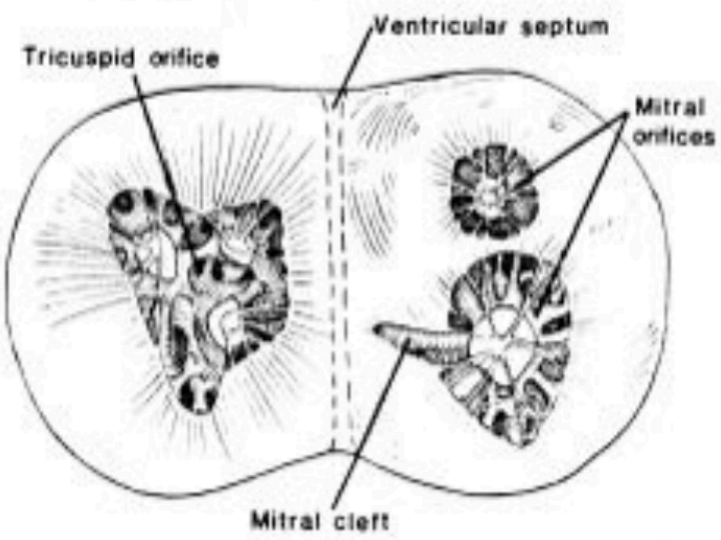

Double mitral orifice

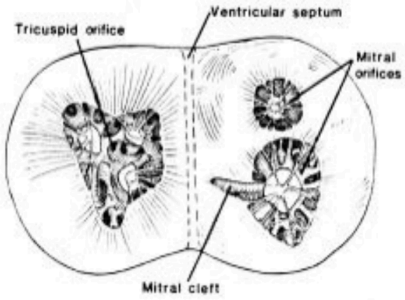

- An accessory bridge or limbus of tissue partially or completely divide the mitral inlet into two orifices with each suborifice supported by its own chordal apparatus

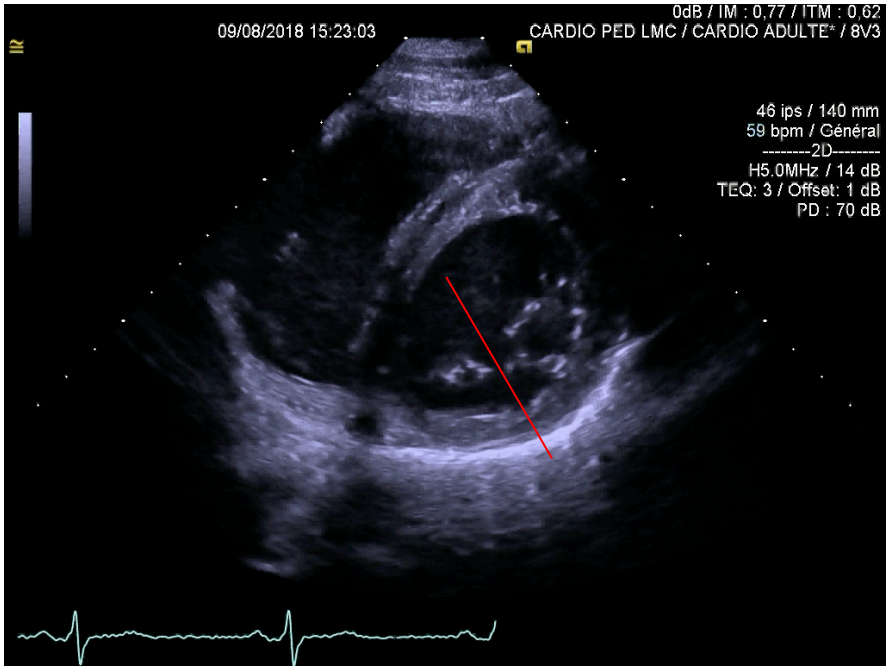

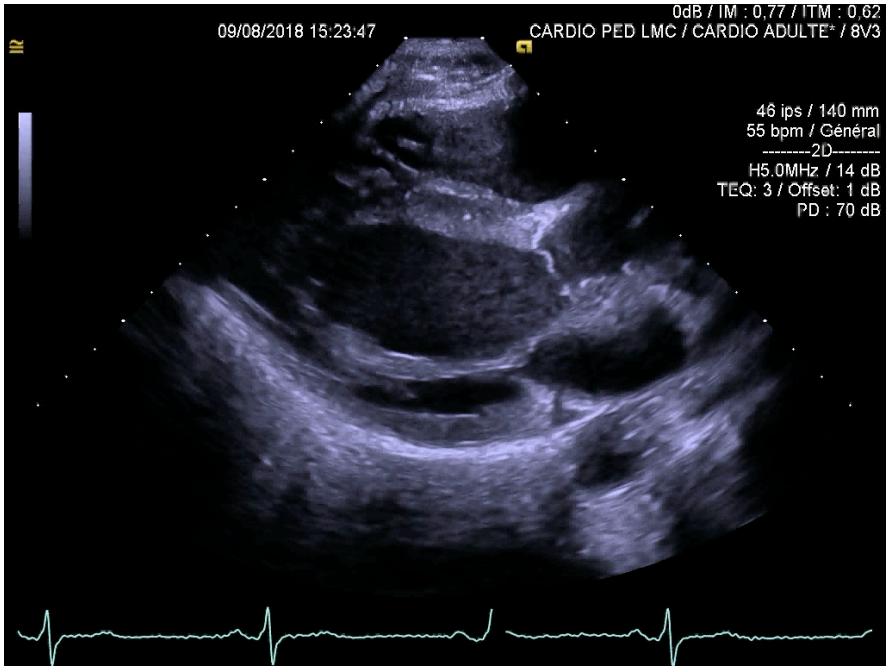

Double mitral orifice

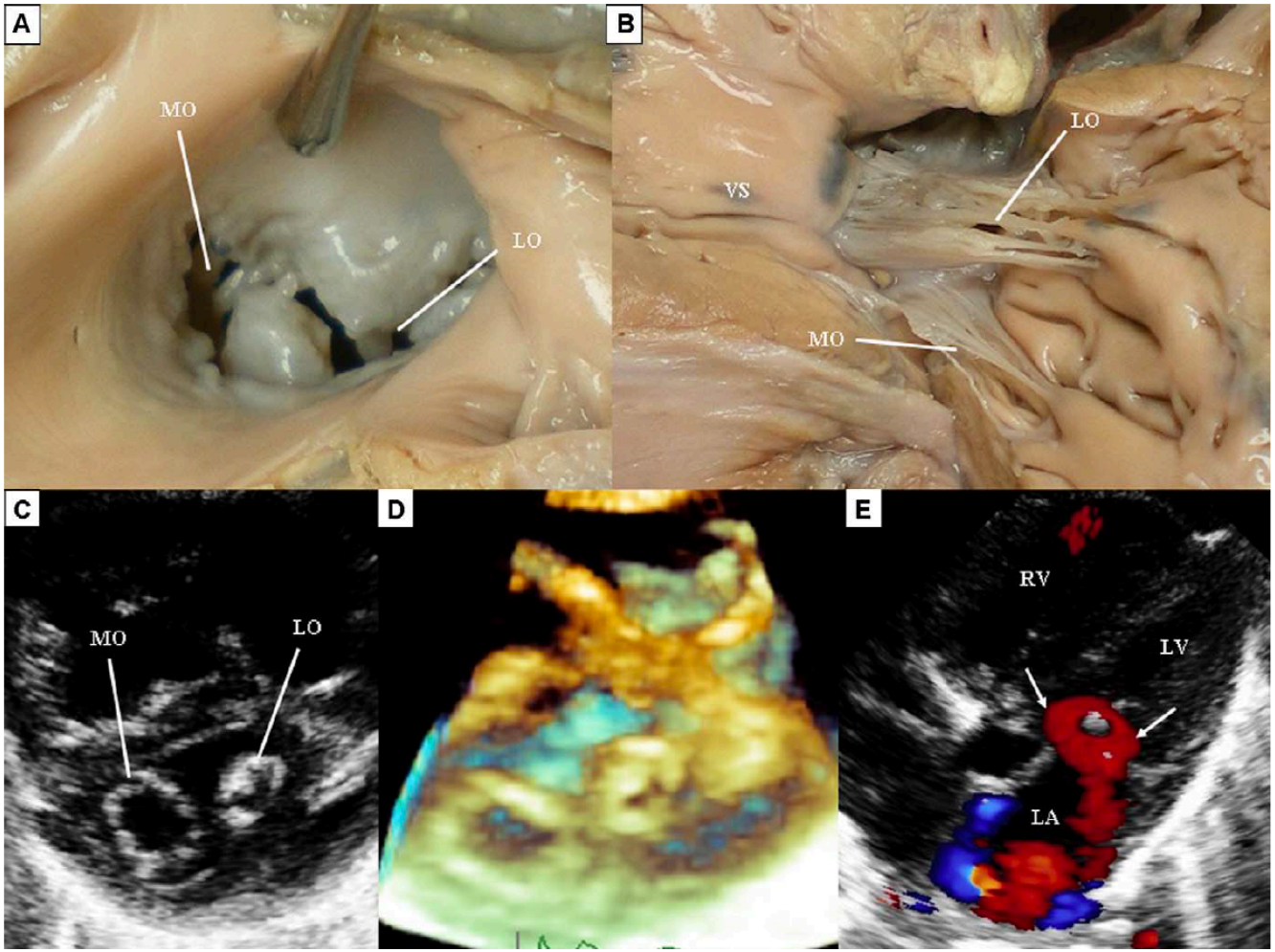

Seguela et al. ACVD 2011

CHU Hôpitaux de Bordeaux

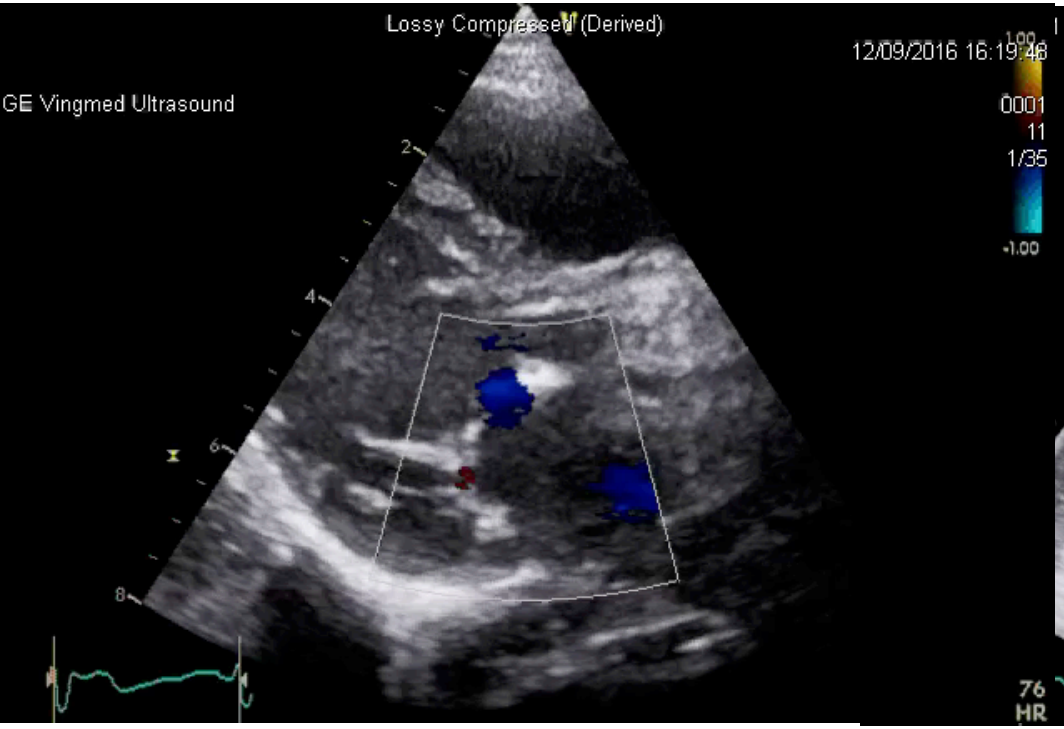
Lossy Compressed (Derived)
GE Vingmed Ultrasound
12/09/2016 16:19:48
0001
11
1/35
1.00
-1.00
76
HR

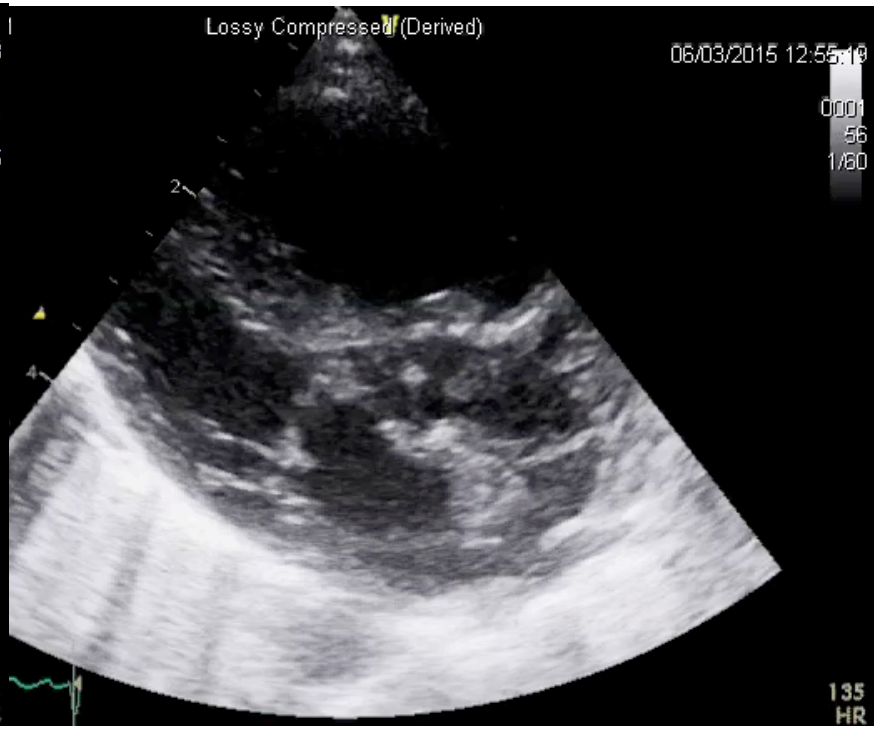
Lossy Compressed (Derived)
06/03/2015 12:55:19
0001
56
1/80
135
HR

Congenital mitral stenosis: conclusion

- Significant congenital mitral valve lesions are **rare** and estimated to affect 0.4% of CHD
- Often complex and affect **multiple segments** of the valve apparatus
- **Isolated** or in **associated (shone complex++++)** with other CHD