L'INSTITUT DE RYTHMOLOGIE ET MODÉLISATION CARDIAQUE
BORDEAUX

THÉRAPEUTIQUES PERCUTANÉES EN CARDIOLOGIE PÉDIATRIQUE ET CONGÉNITALE











Dr. Zakaria Jalal

Service des cardiopathies congénitales de l'enfant et de l'adulte- Hôpital cardiologique Haut Lévêque - Bordeaux

université de BORDEAUX · CHU Hôpitaux de Bordeaux · Inserm Institut national de la santé et de la recherche médicale · cnrs · Inria INVENTEURS DU MONDE NUMÉRIQUE

INTRODUCTION

CARDIAC CATHETERIZATION

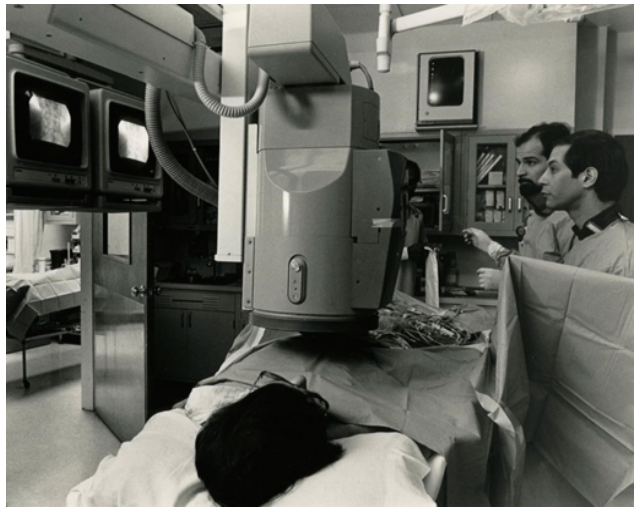

1929 → 2018

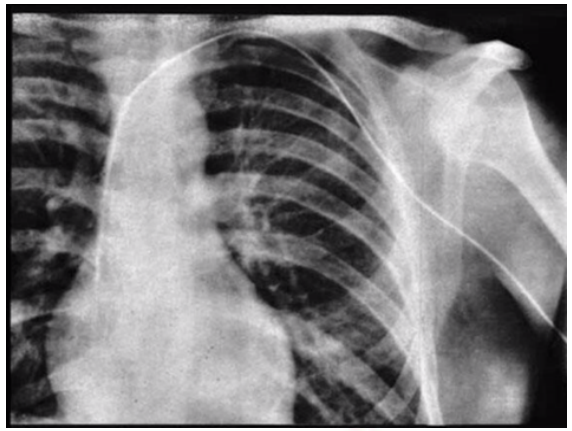

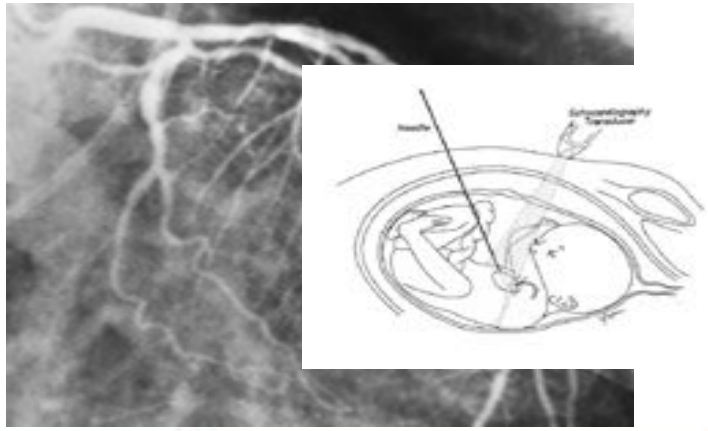

Nous ne pouvons pas afficher cette image pour l'instant.

INTRODUCTION

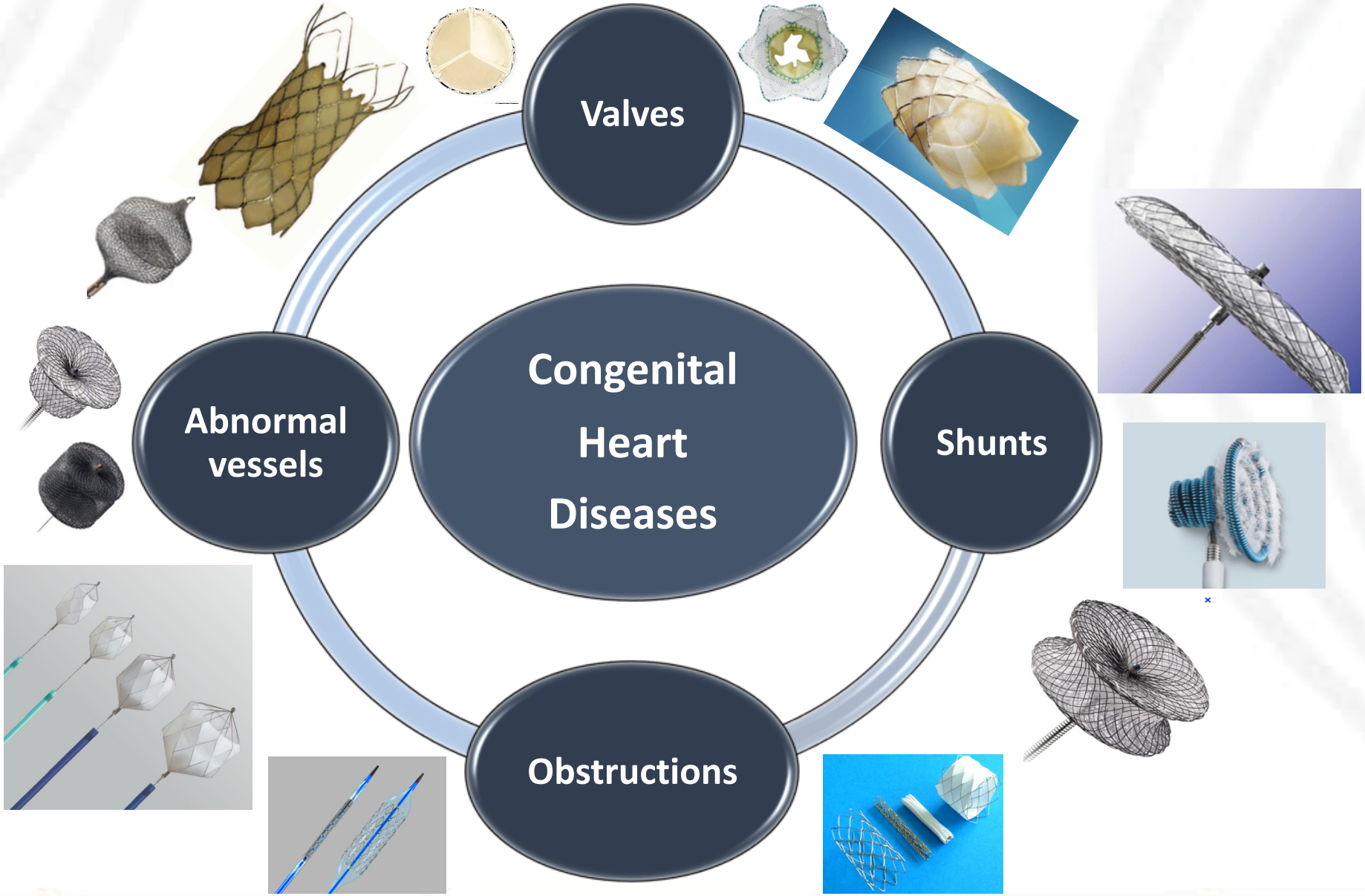

RECOMMMANDATIONS

AHA Scientific Statement

Indications for Cardiac Catheterization and Intervention in Pediatric Cardiac Disease

A Scientific Statement From the American Heart Association

Feltes et al. Circulation 2011

SHUNTS

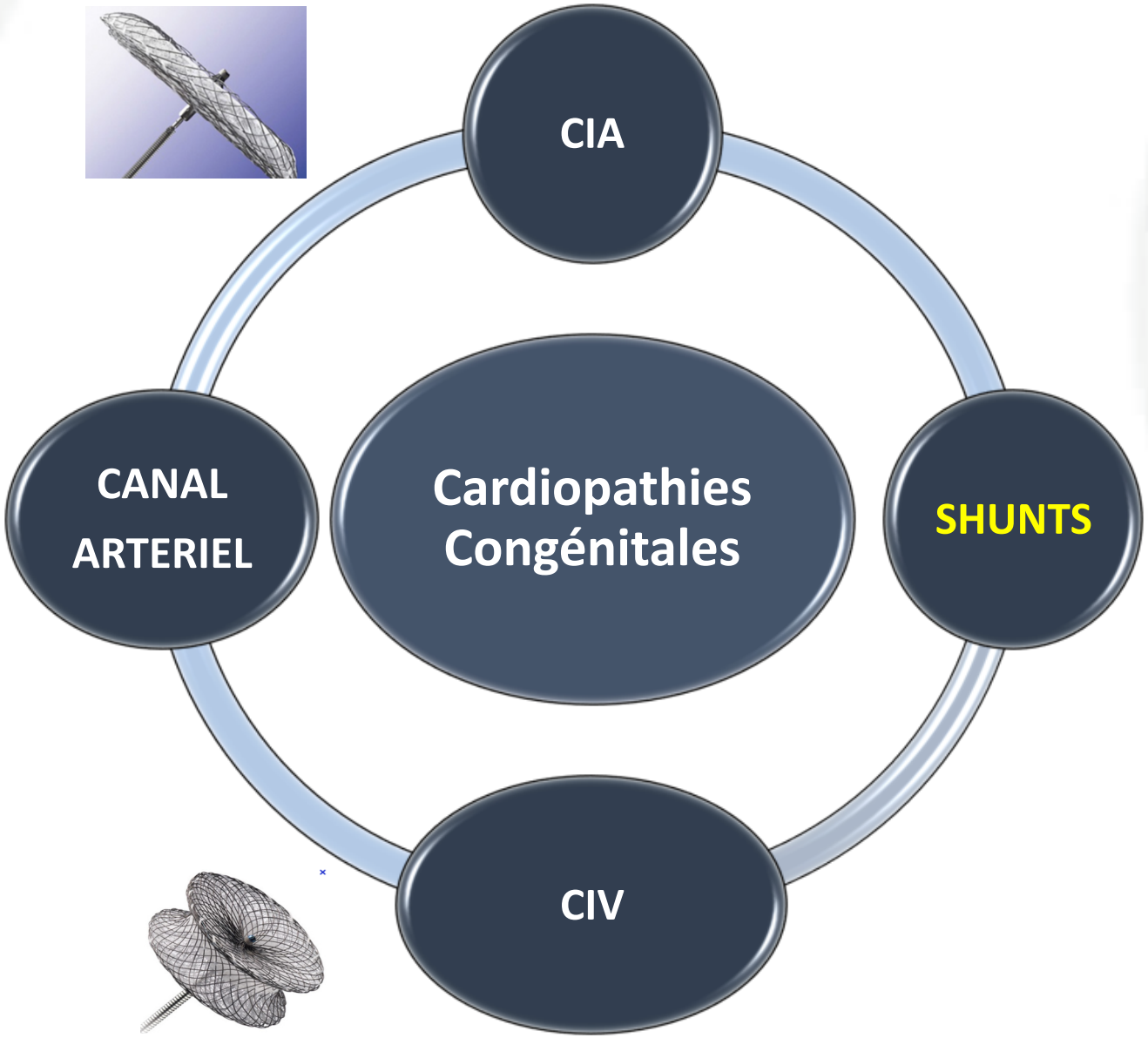
CIA
CANAL ARTERIEL
Cardiopathies Congénitales
SHUNTS
CIV

LES COMMUNICATIONS INTERATRIALES

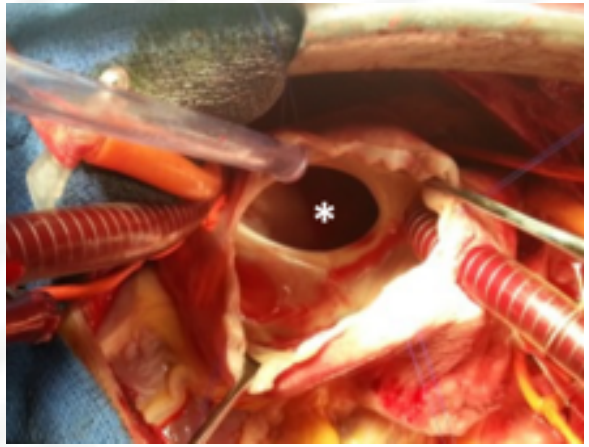

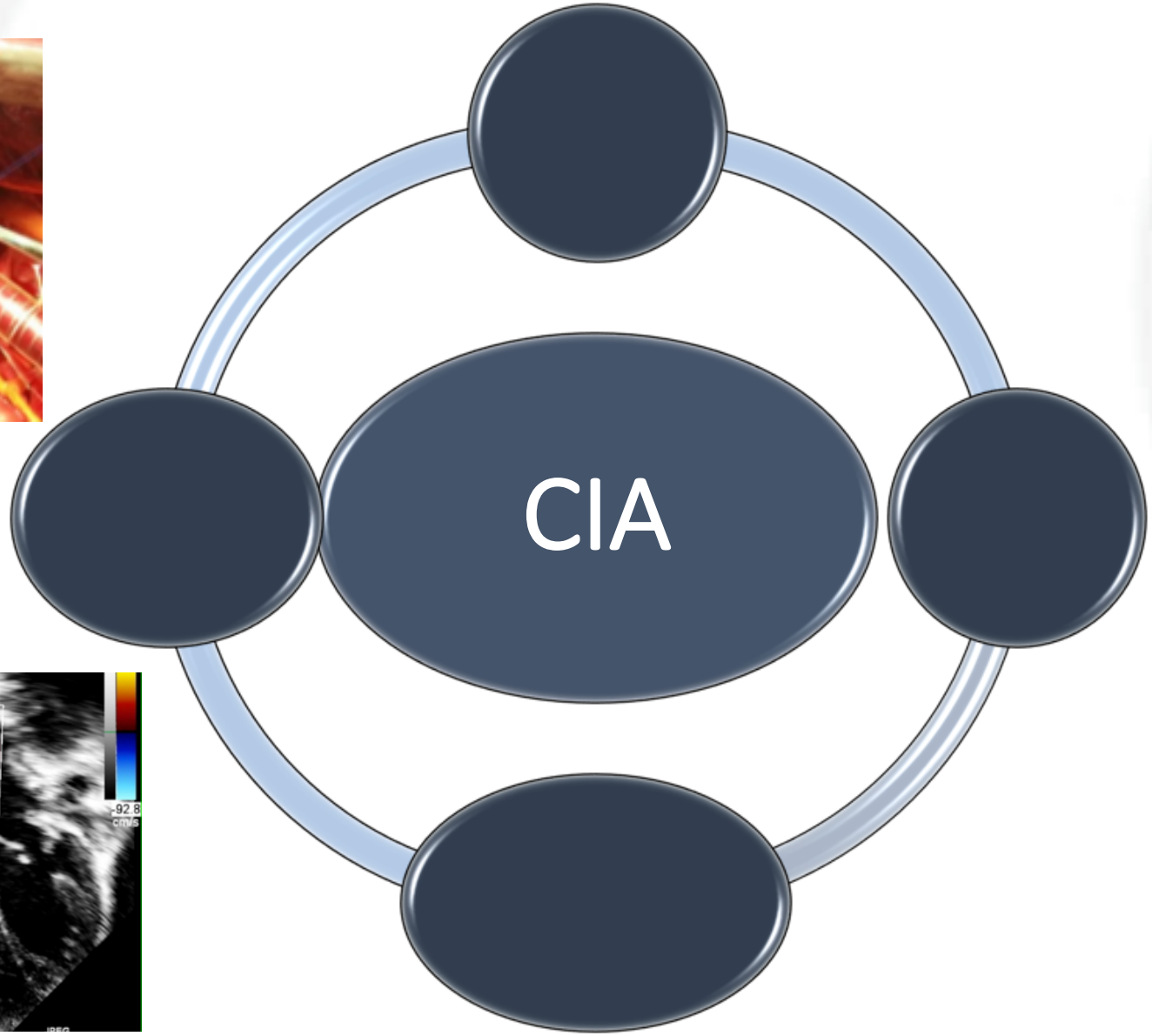



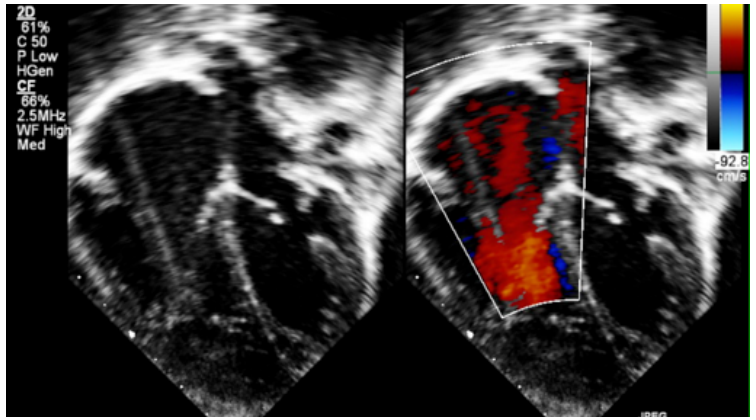

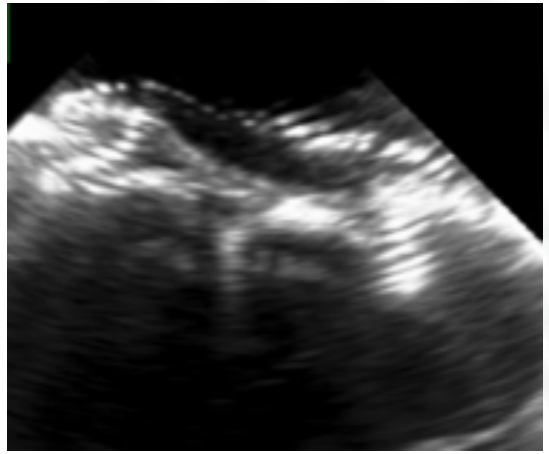

LES COMMUNICATIONS INTERATRIALES

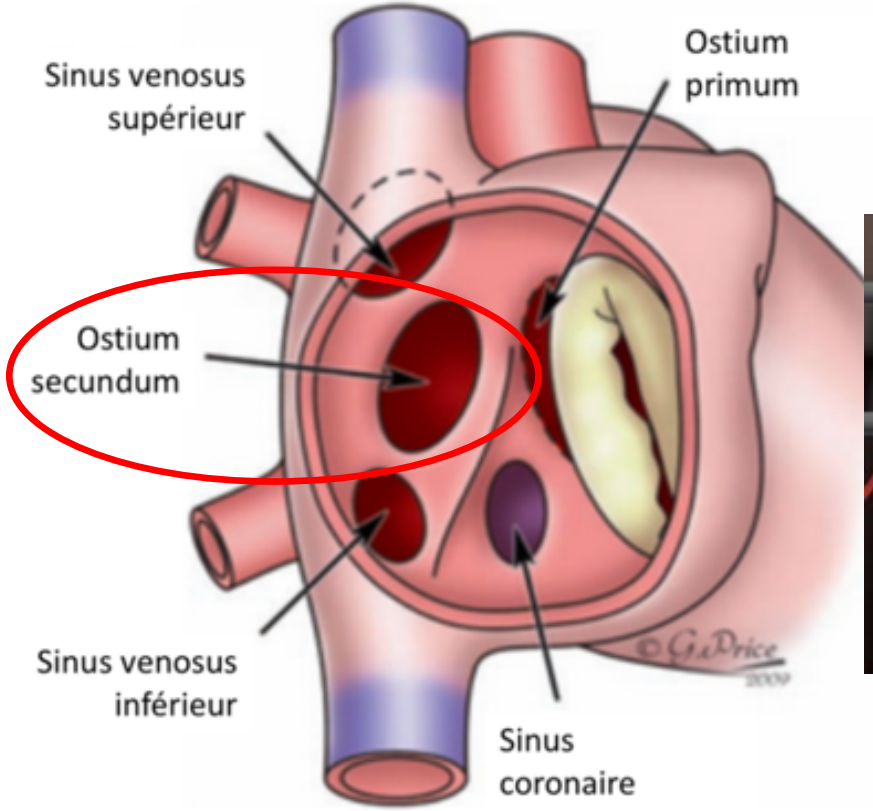

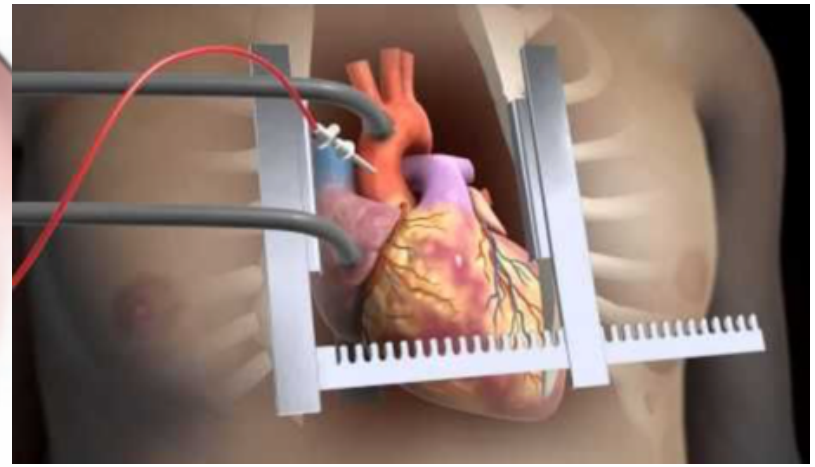

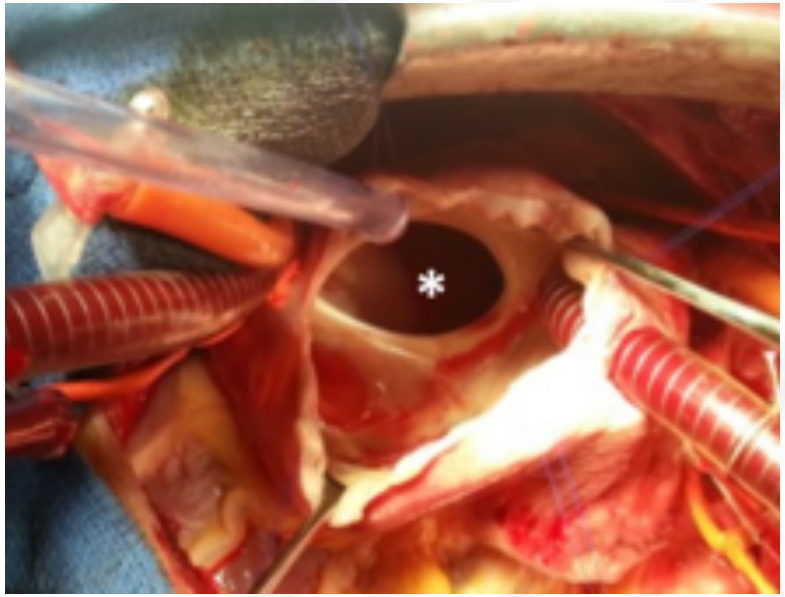

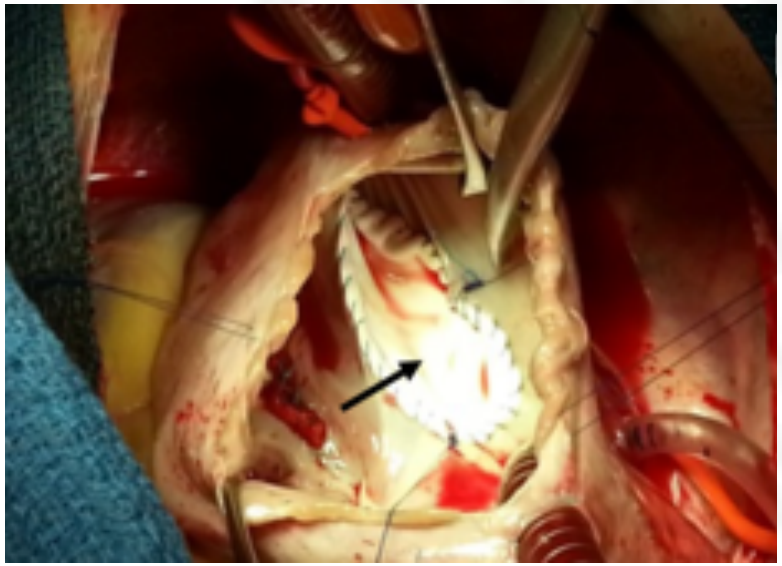

FERMETURE PERCUTANÉE – LA RUPTURE





AMPLATZER SEPTAL OCCLUDER



Nitinol (55% Ni + 45 % Ti)
+
Polyéthylène téréphtalate

Mémoire de forme
Recapturable
Biocompatibilité
Profil

FERMETURE PERCUTANÉE - INDICATIONS

Recommendations	Class[a]	Level[b]
In patients with evidence of RV volume overload[c] and no PAH (no non-invasive signs of PAP elevation or invasive confirmation of PVR <3 WU in case of such signs) or LV disease, ASD closure is recommended regardless of symptoms.[146,147]	I	B
Device closure is recommended as the method of choice for secundum ASD closure when technically suitable.	I	C

APRÈS L'IMPLANTATION:

- Antiagrégant plaquettaire
- Prophylaxie de l'endocardite infectieuse
- Pendant 6 mois
- Délai théorique de recouvrement prothétique

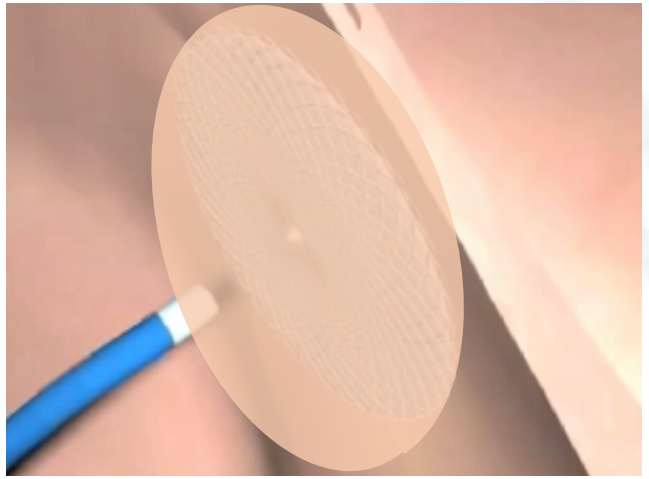

Baumgartner et al. Eur Heart Jour 2020

EVALUTATION ETT

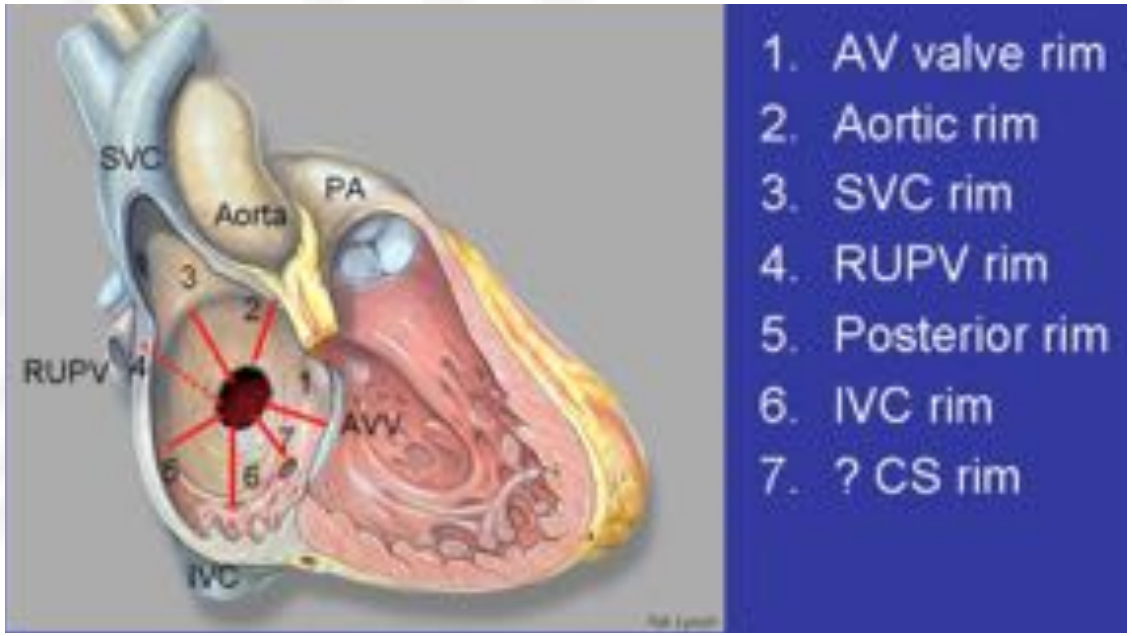

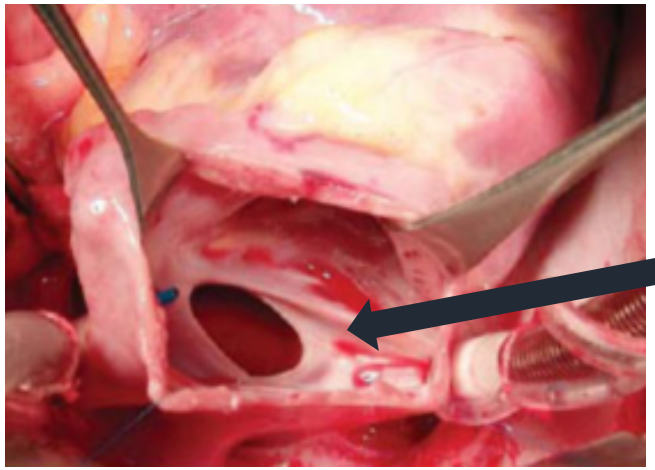

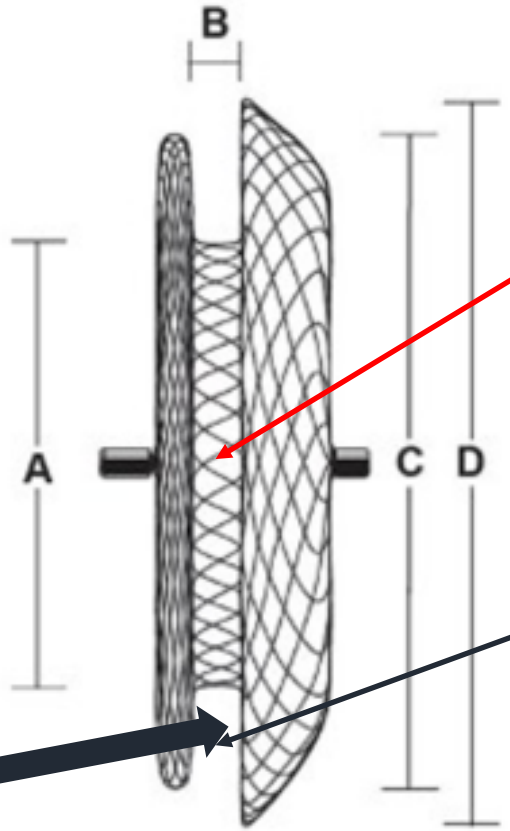

Size (central waist)	4-40 mm (every 1 mm up to 20 mm, > 20 mm, every 2 mm)
Central waist length	3-4 mm
Difference between disc and central waist	8/12 mm (ASO 4-10), 10/14 mm (ASO > 11), 10/16 mm (ASO > 34)
Release sheath size	6-12 Fr

BERGES > 5-mm

FERMETURE PERCUTANÉE - PROCÉDURE

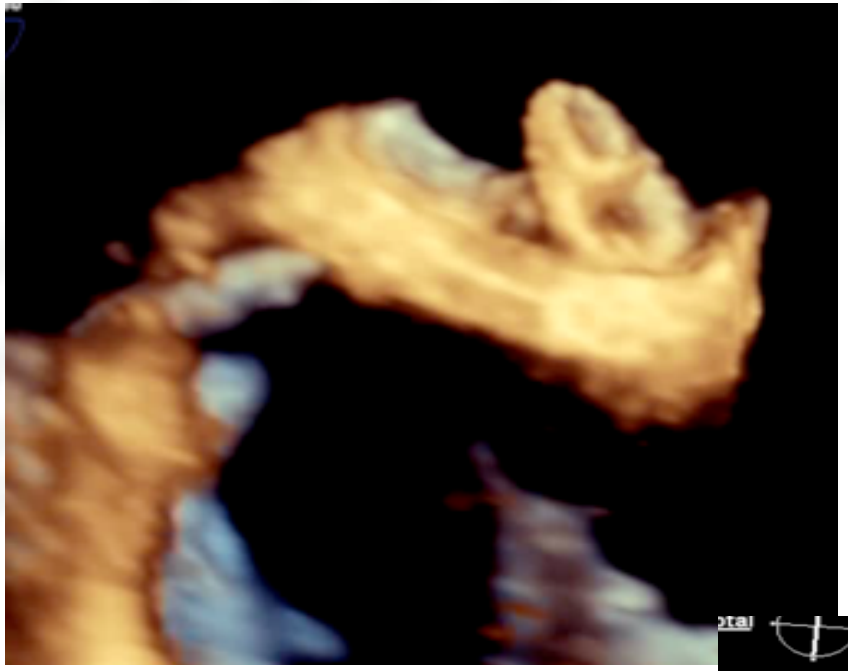

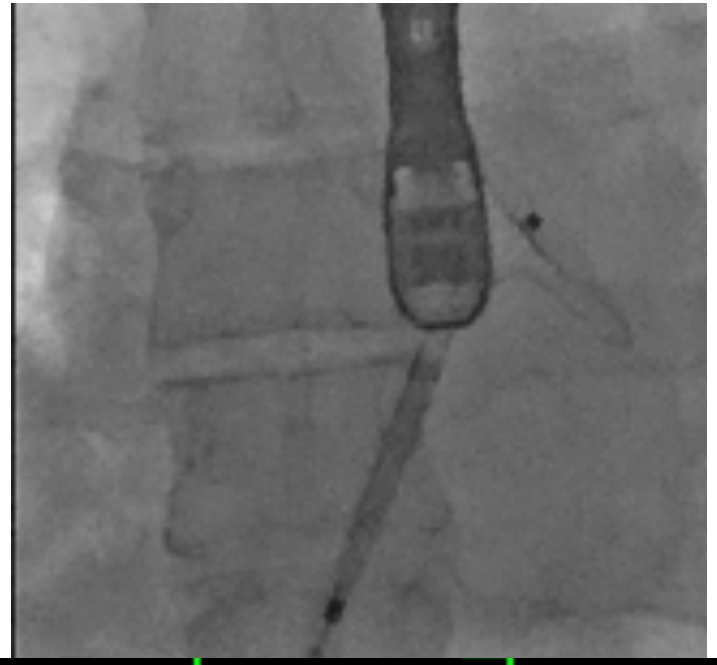

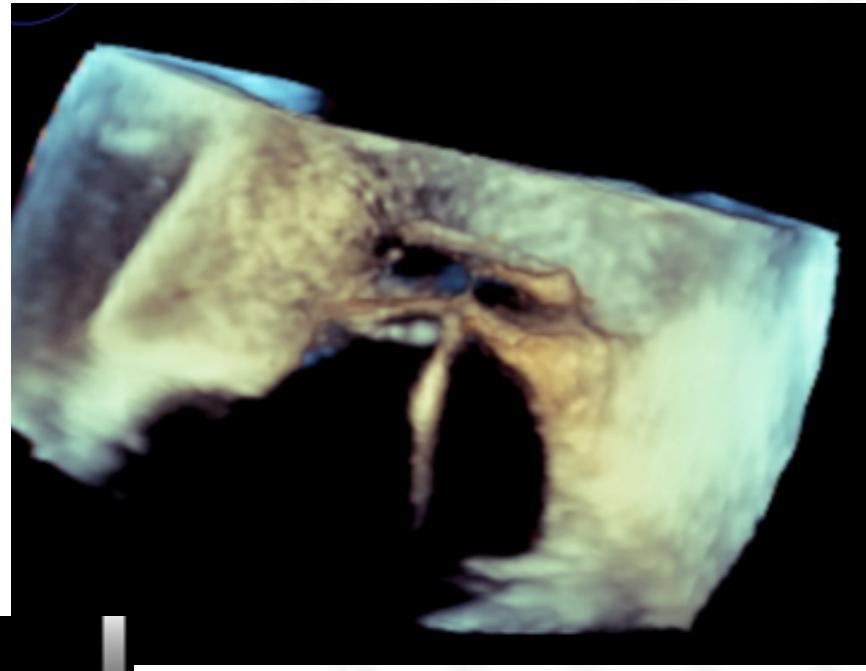

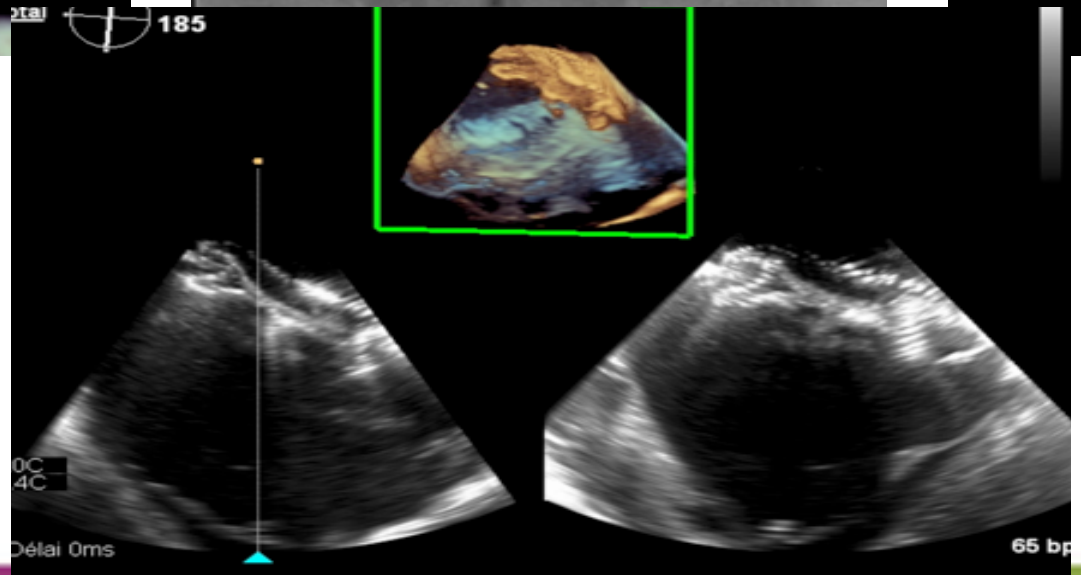

COMPLICATIONS AU LONG COURS

Review

Long-term Complications After Transcatheter Atrial Septal Defect Closure: A Review of the Medical Literature

Zakaria Jalal, MD,[a,b,c] Sebastien Hascoet, MD,[a,d] Alban-Elouen Baruteau, MD, PhD,[a,e] Xavier Iriart, MD,[b] Bernard Kreitmann, MD, PhD,[b] Younes Boudjemline, MD, PhD,[a,f,g] and Jean-Benoit Thambo, MD, PhD[a,b,c]

ÉROSION CARDIAQUE

VALVULOPATHIES

TROUBLES CONDUCTIFS

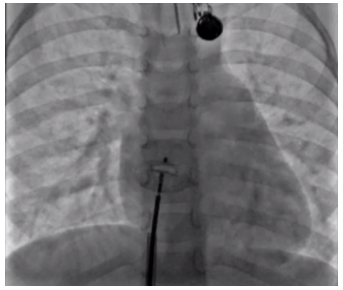

THROMBOSES

ARYTHMIES ATRIALES

AVC

ENDOCARDITE

ALLERGIE AU NICKEL

Table 1. Summary of the main long-term complications after percutaneous ASD

Complication	Incidence	Delay from closure	Complications
Cardiac erosion	0.04%-0.28%	Up to 9 y	Death (0.05%) Stroke
Device thrombosis	0.8%-1.2%	Up to 2 y	Stroke (10%-15%)
Atrial arrhythmias	11% 10 years after closure	—	Stroke
Complete AV block	5 published cases	Up to 4 y	—
Infective endocarditis	6 published cases	Up to 4 y	—

Jalal et al. Can Jour Cardiol 2016

PROJETS DE RECHERCHE EN COURS

ÉVALUATION MULTIMODALE DU RECOUVREMENT DES PROTHÈSES

Travaux Fondamentaux



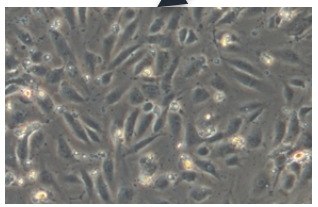

Travaux Clinique

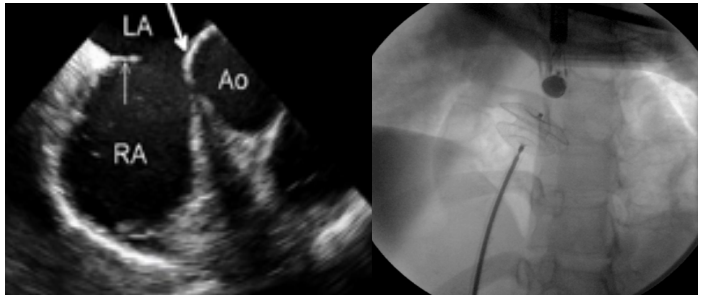

Imagerie du recouvrement

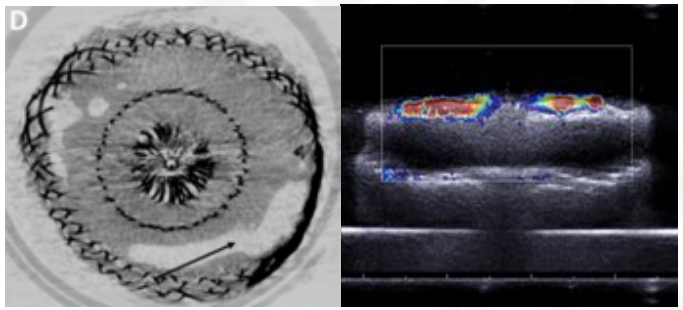

PERSPECTIVES

DISPOSITIF IDÉAL

Si les tissus du patient prennent la place et la fonction du dispositif => indispensable?

DISPOSITIFS BIORÉSORBABLE

Résorption partielle ou totale

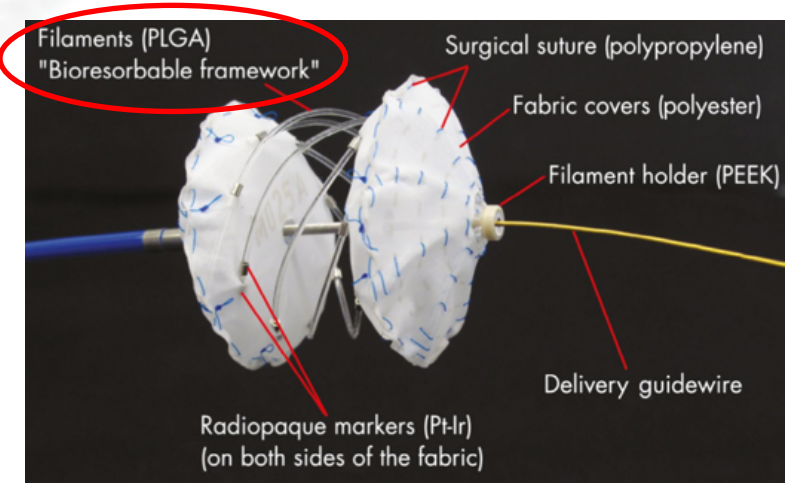

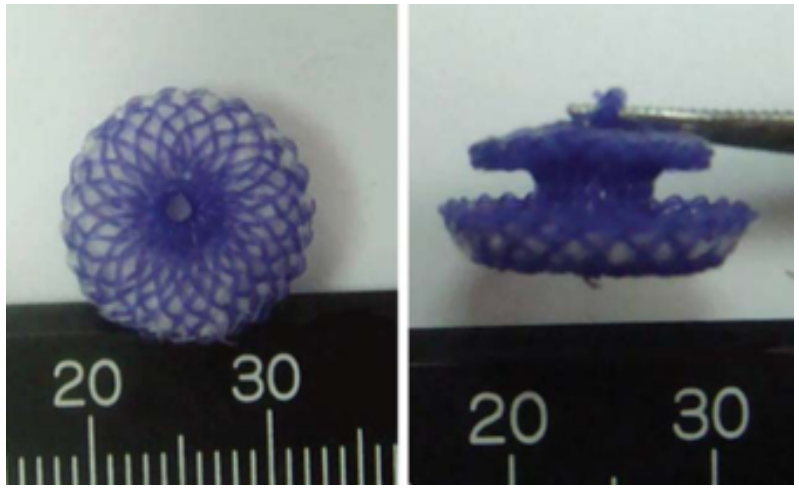

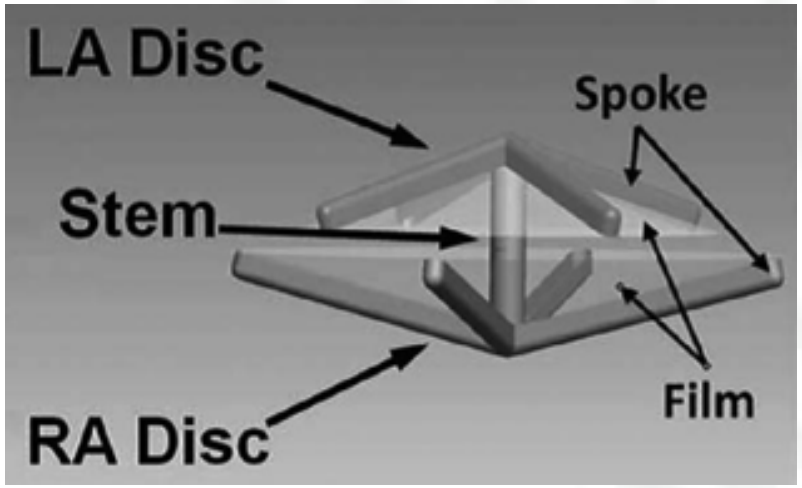

Sigler et al. EuroIntervention 2018
Duong-Hong et al. CCI 2010
Zhu et al. J Biomed Biotechnol. 2012

CIA SINUS VENOSUS – APPROCHE PERCUTANEE

STENT COUVERT JONCTION SVC - OD

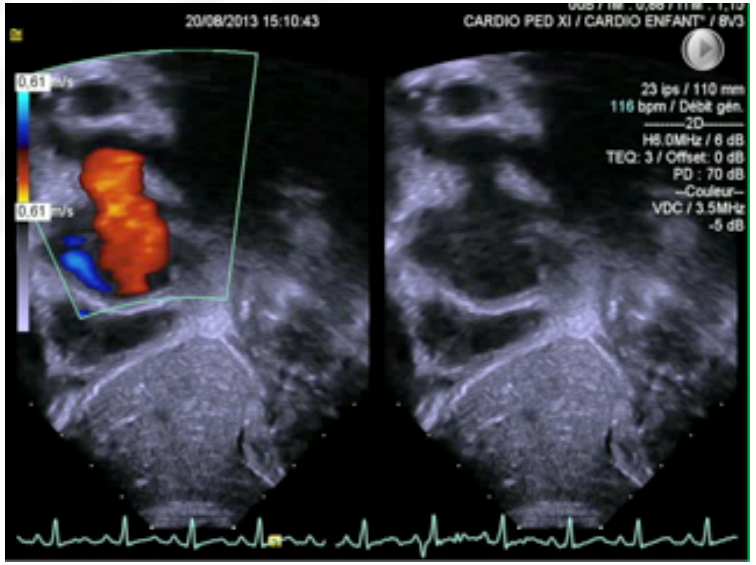

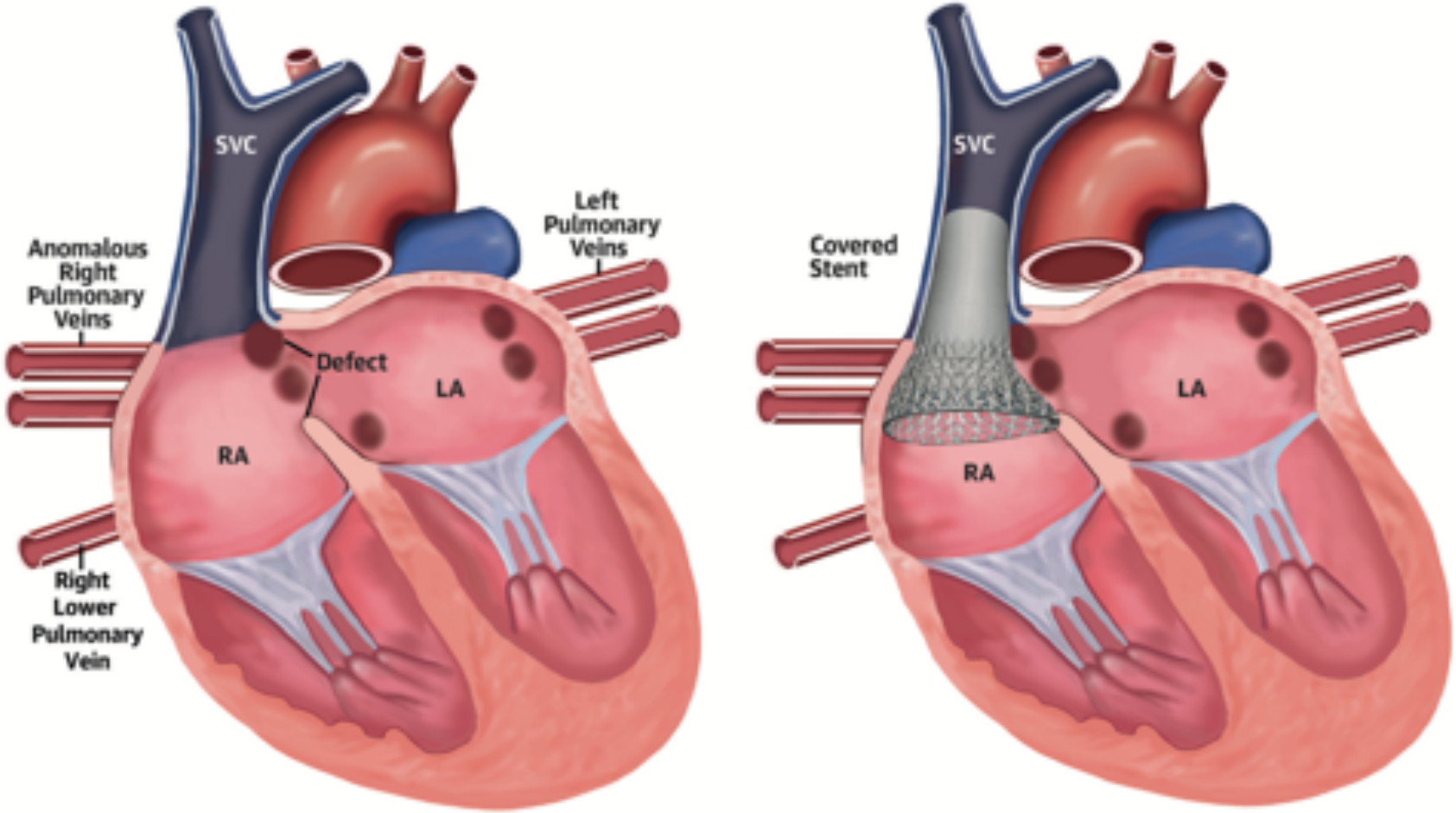

Hansen et al. JACC 2020

CIA SINUS VENOSUS – APPROCHE PERCUTANEE

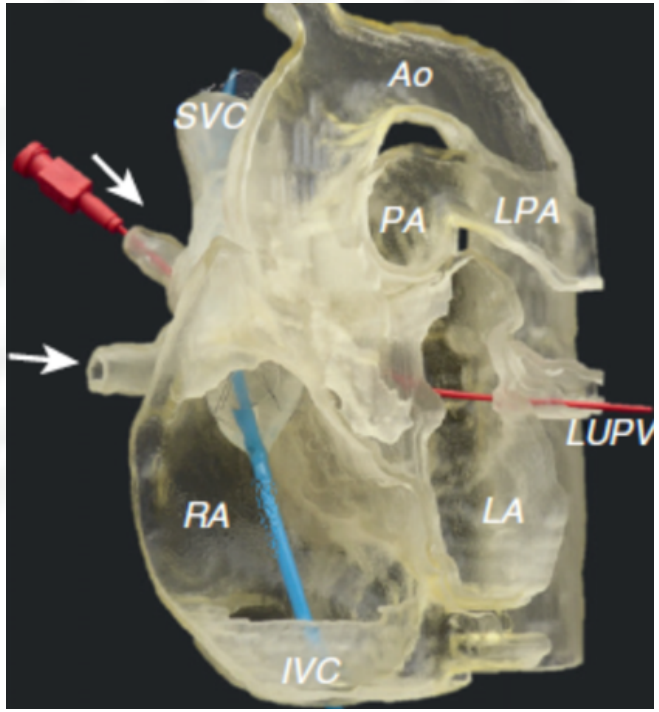

3D-PRINTED MODEL

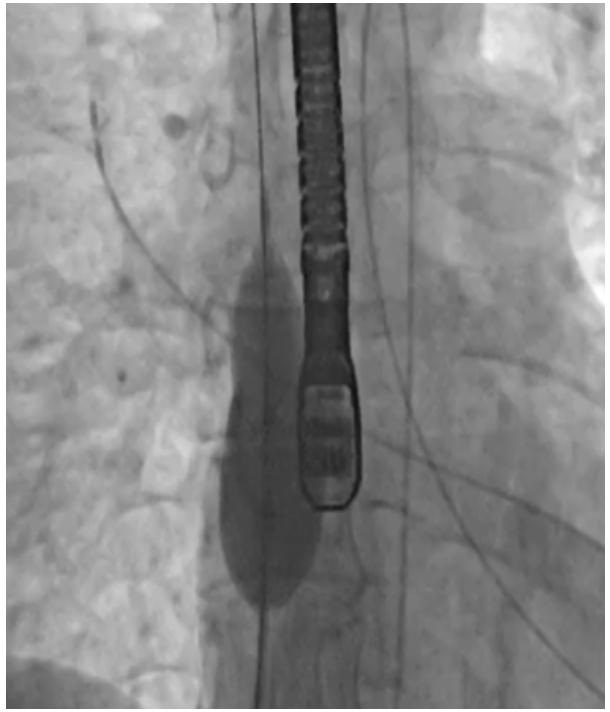

IN-VIVO ASSESSEMENT

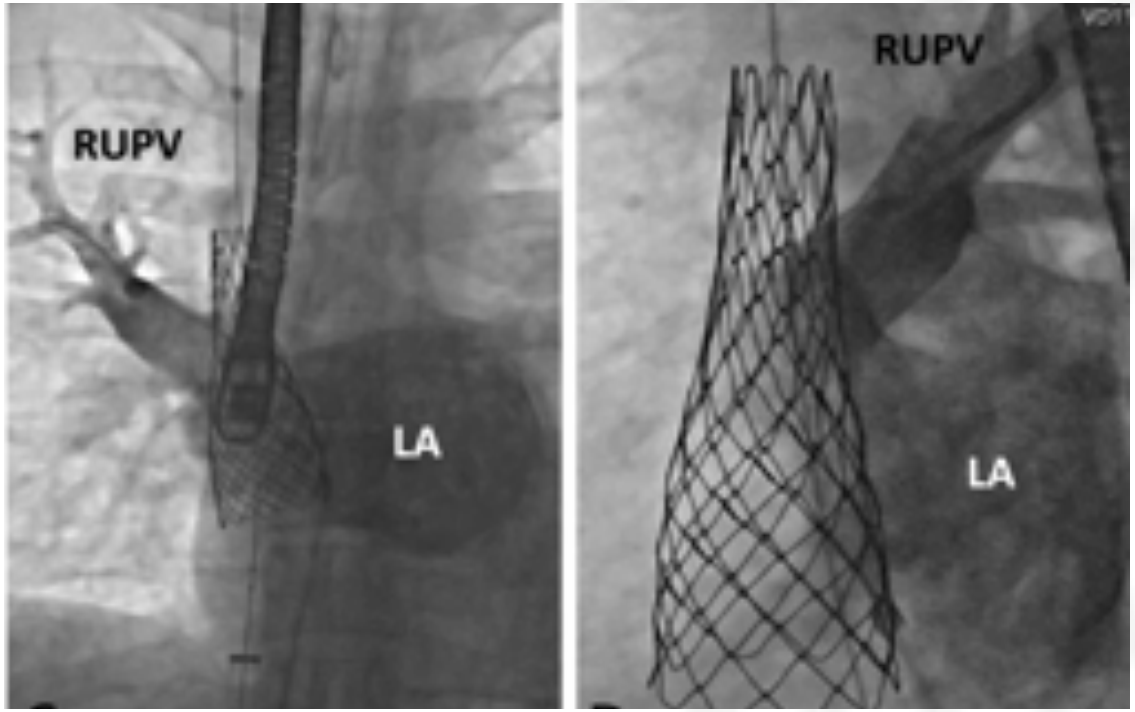

SHUNT CLOSURE RUPV PATENCY

Courtesy A. Baruteau

Hansen et al. JACC 2020

CIA SINUS VENOSUS – APPROCHE PERCUTANEE

25 patients , 45 ans (33–54)

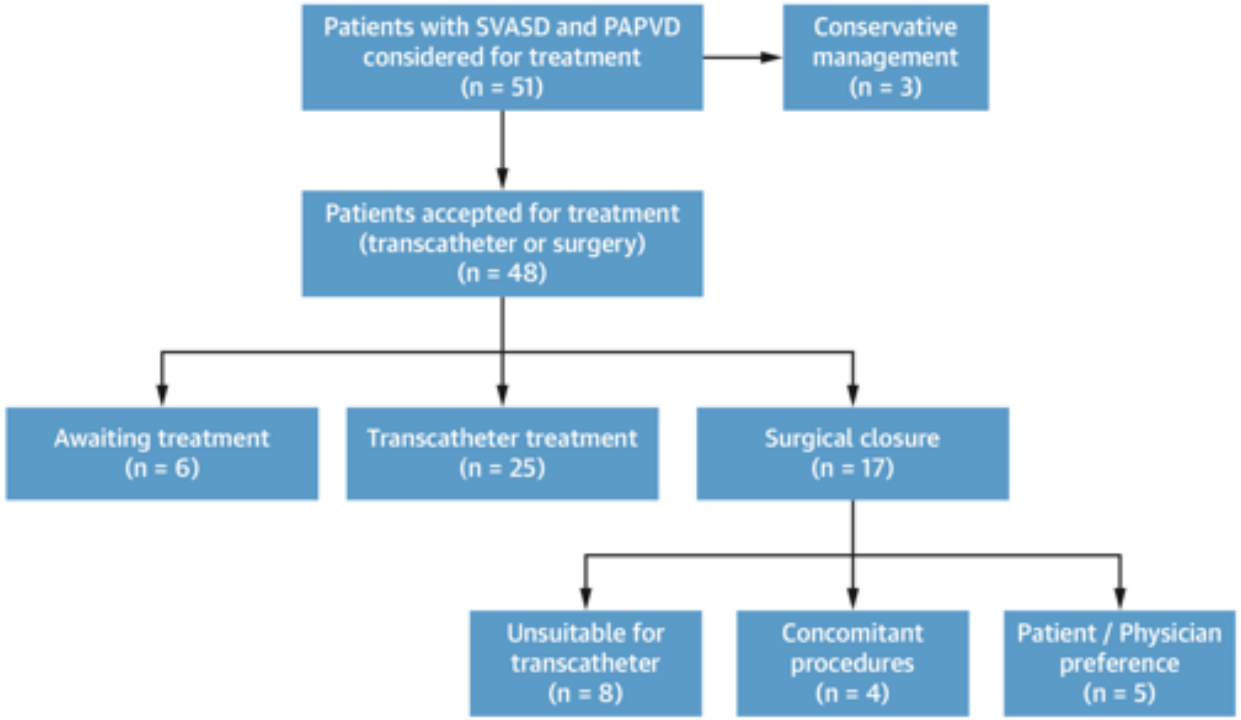

- Succès: 100%
- 1 hémopericarde, 1 embolisation précoce de stent
- Aspirine-Clopidogrel 2 mois puis Aspirine 4 mois
- Suivi: 1.4 ans: pas de shunt résiduel, 0 complications
- 100% VPSD perméable

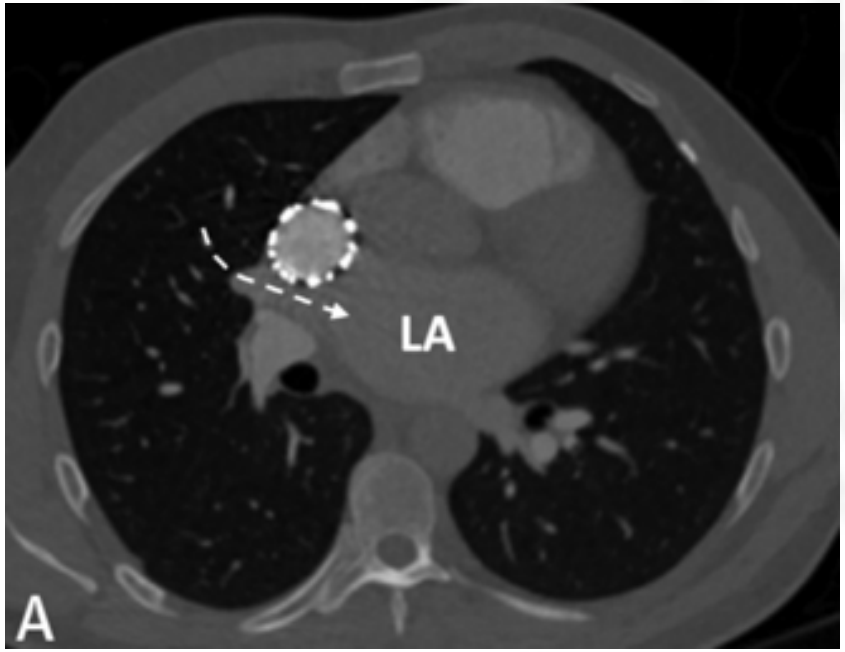

Hansen et al. JACC 2020

LES COMMUNICATIONS INTERVENTRICULAIRES

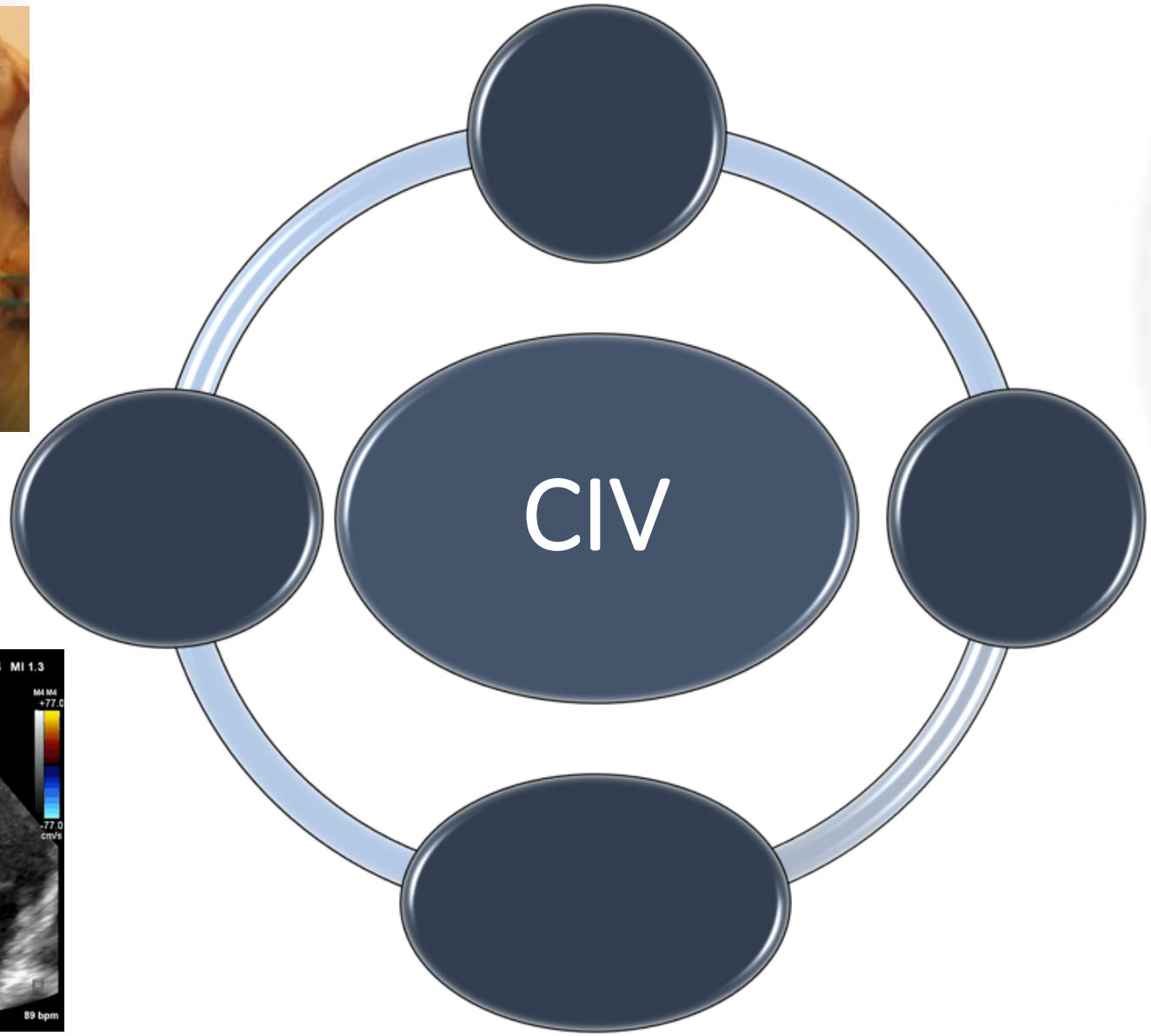

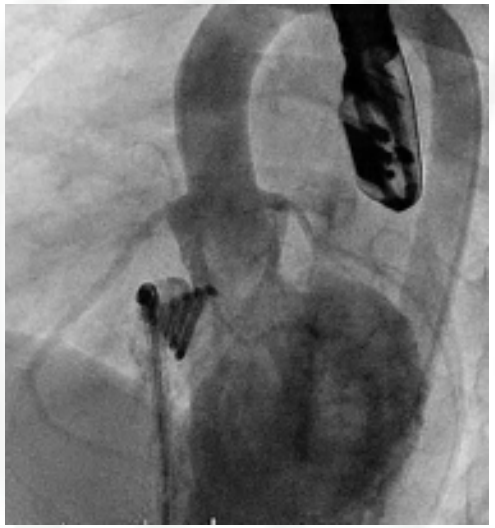

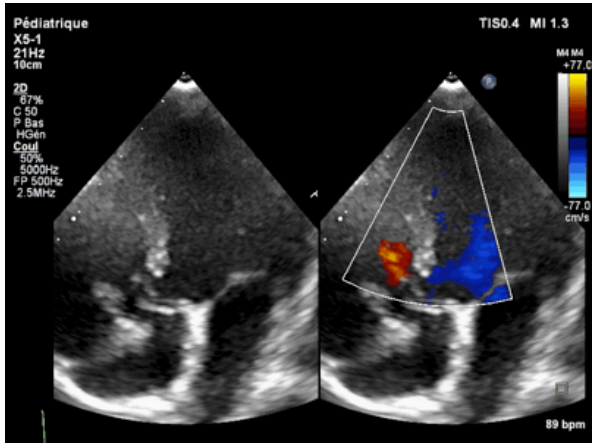

FERMETURE CIV - GÉNÉRALITÉS

- Shunt dépendant de la taille du defect et du rapport des résistances (systémiques / pulmonaires)
- Prise en charge fonction retentissement hémodynamique et clinique
- Etiologies:
  - Congénitales
  - Post chirurgicales (fermeture CIV, valve aortique, …)
  - Post IDM
  - Post traumatique

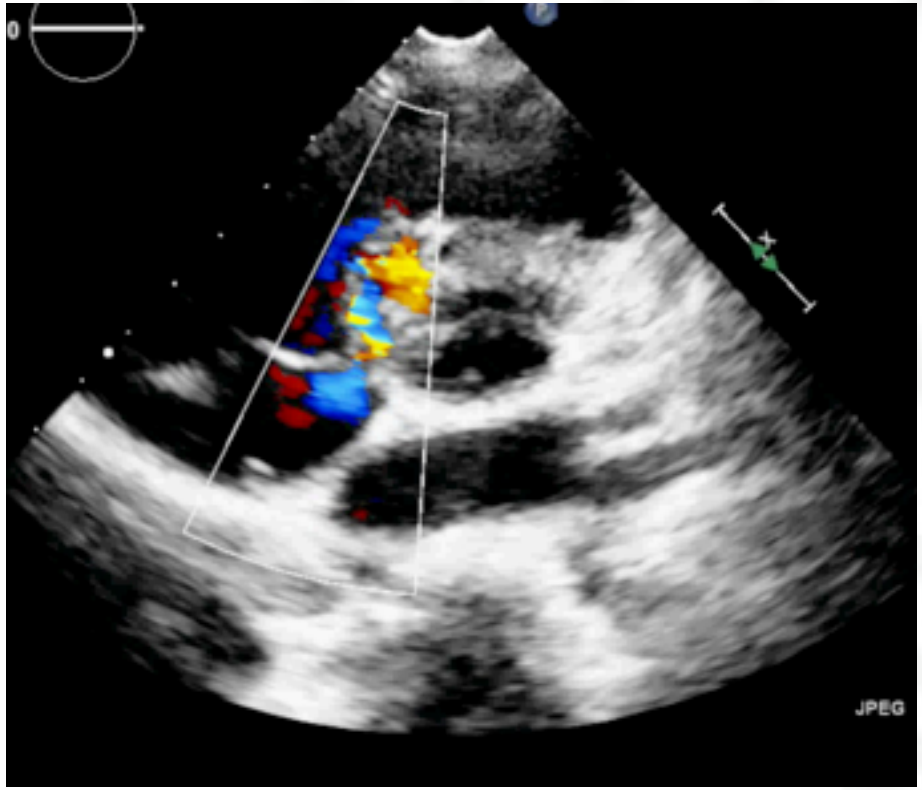

FERMETURE CIV - GÉNÉRALITÉS

Infundibulaire

Péri-membraneuse

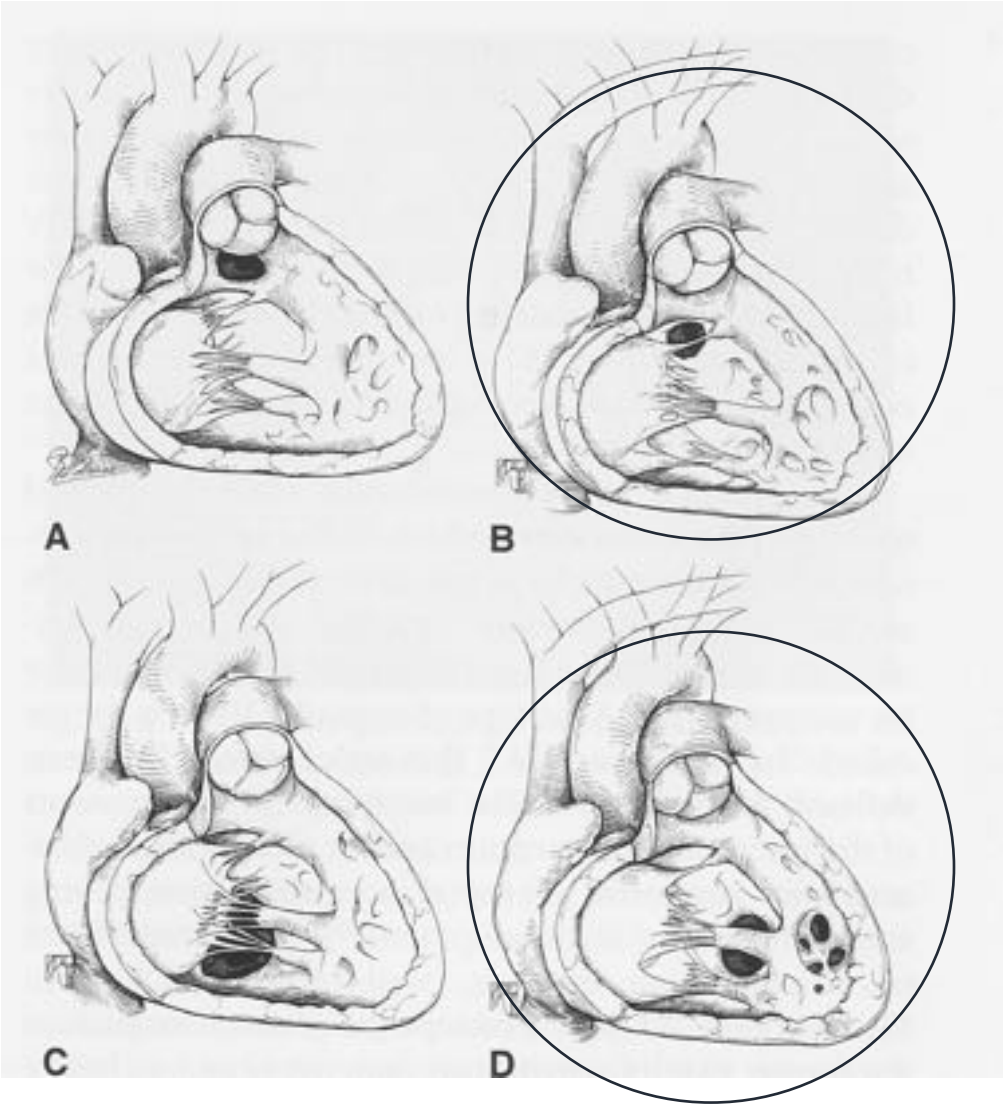

Admission

Musculaire

FERMETURE CIV - INDICATIONS

ESC Guidelines for the management of grown-up congenital heart disease

Recommendations	Class[a]	Level[b]
In patients with evidence of LV volume overload[c] and no PAH (no non-invasive signs of PAP elevation or invasive confirmation of PVR <3 WU in case of such signs), VSD closure is recommended regardless of symptoms.	I	C
In patients with no significant L–R shunt, but a history of repeated episodes of IE, VSD closure should be considered.	IIa	C
In patients with VSD-associated prolapse of an aortic valve cusp causing progressive AR, surgery should be considered.	IIa	C
In patients who have developed PAH with PVR 3–5 WU, VSD closure should be considered when there is still significant L–R shunt (Qp:Qs >1.5).	IIa	C
In patients who have developed PAH with PVR ≥5 WU, VSD closure may be considered when there is still significant L–R shunt (Qp:Qs >1.5), but careful individual decision in expert centres is required.	IIb	C
VSD closure is not recommended in patients with Eisenmenger physiology and patients with severe PAH (PVR ≥5 WU) presenting with desaturation on exercise.[d]	III	C

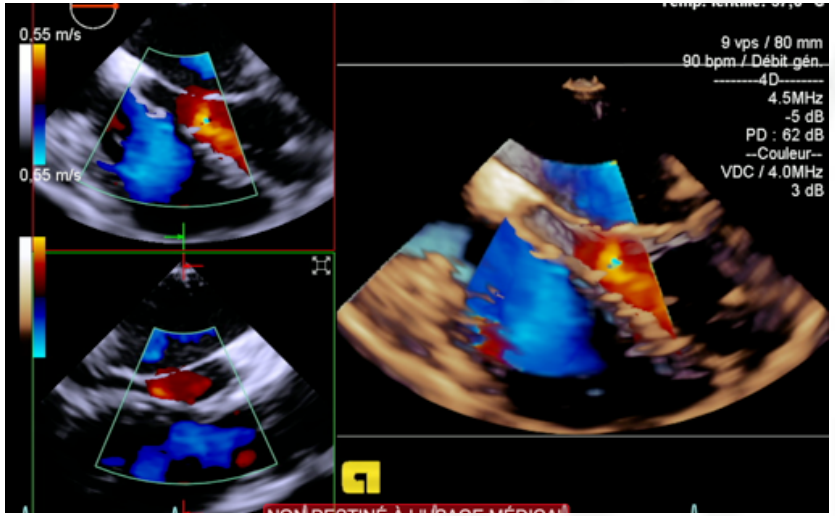

Baumgartner et al. Eur Heart Jour 2020

FERMETURE CIV - DISPOSITIFS

Cera™ Occluders

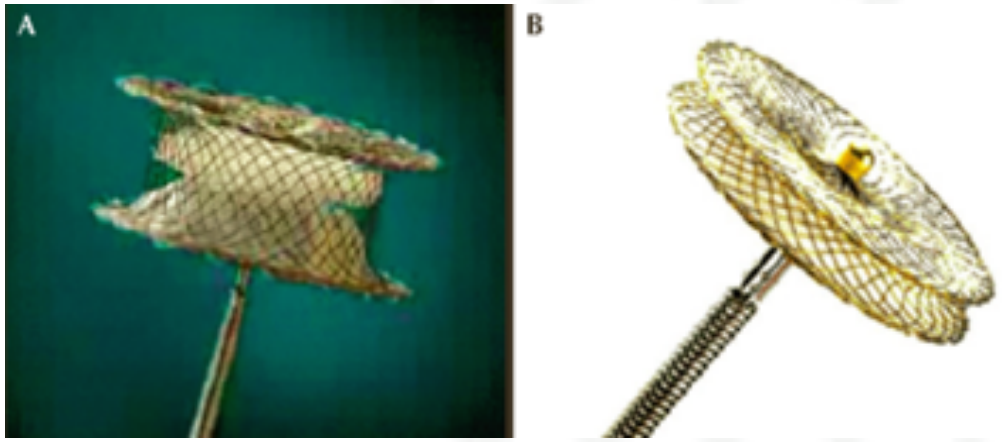

AMPLATZER VENTRICULAR SEPTAL OCCLUDER

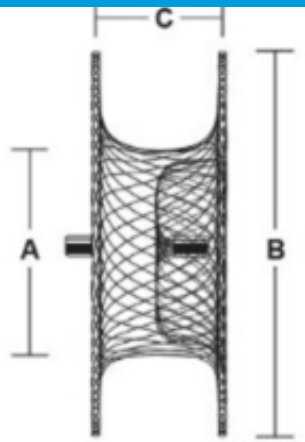

FERMETURE CIV - TECHNIQUE

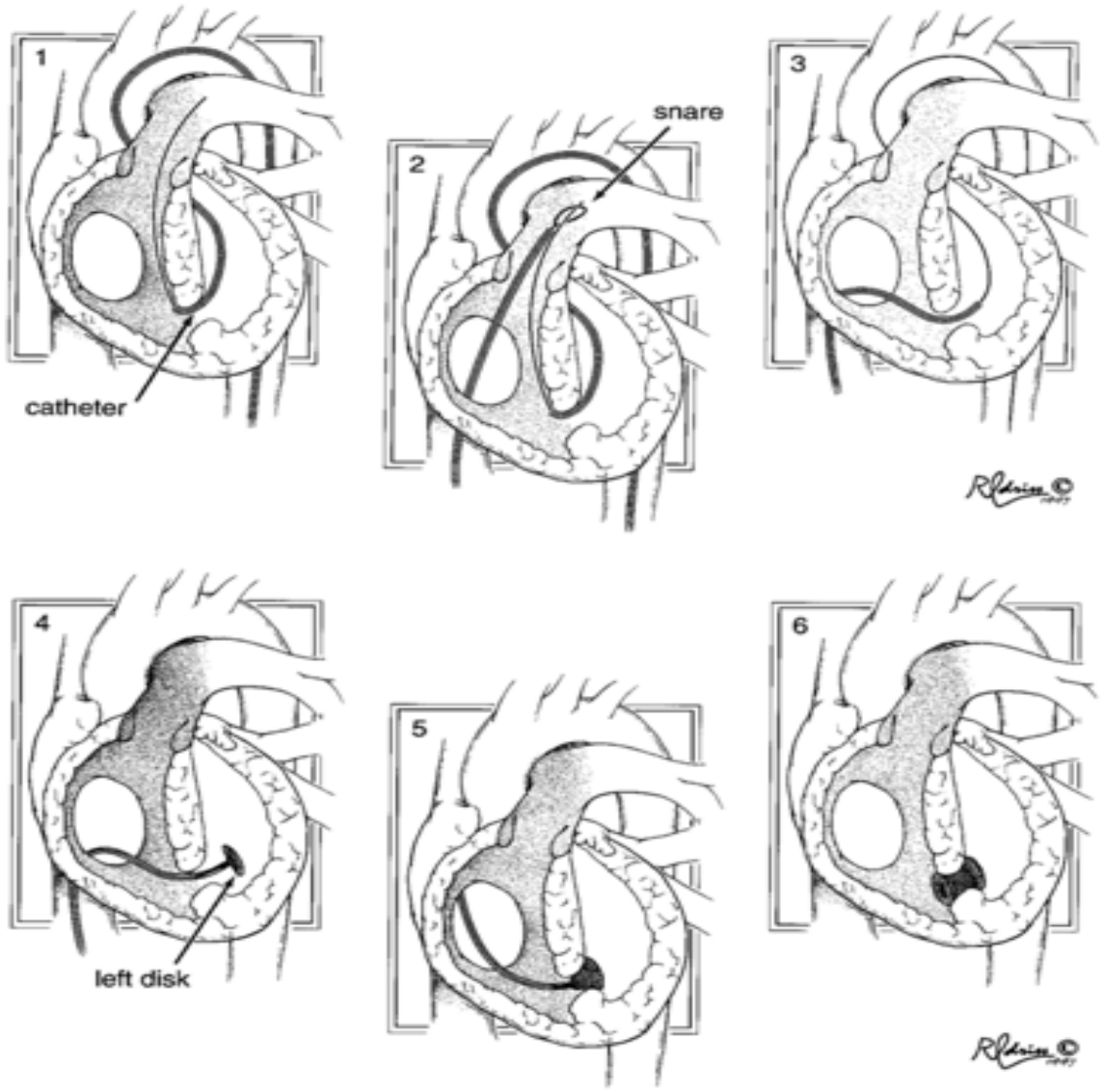

Approche artérielle ou veineuse

Prothèses CIV: minimum 6F => Boucle A-V

Dès 5-6kg (fonction taille shunt / prothèse)

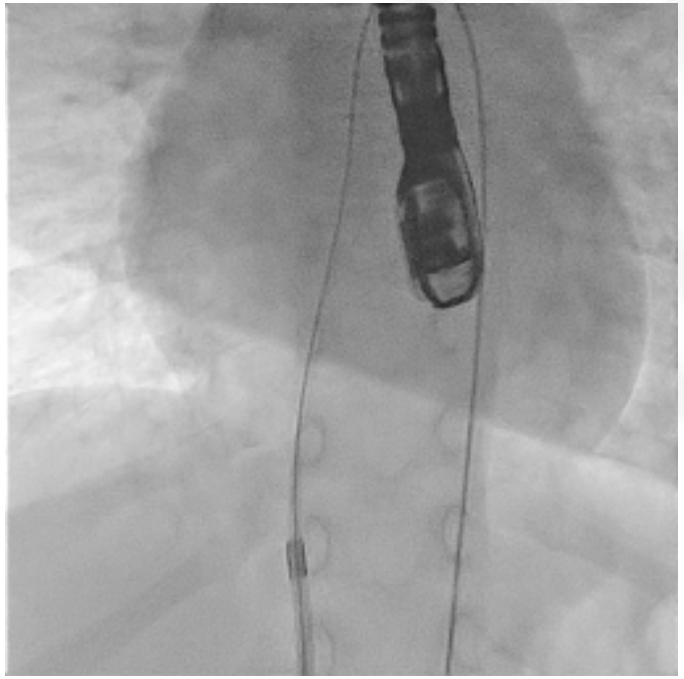

FERMETURE CIV - TECHNIQUE

- Sous AG/AL
- Contrôle ETO (ETT, ICE)
- Accès VF ou VJ + AF
- Traitement anti-thrombotique (HNF, AAP)
- CIV franchie depuis le VG
- Boucle AV++ ou fermeture rétrograde
- Taille prothèse = taille défect + 2-4mm
- Déploiement

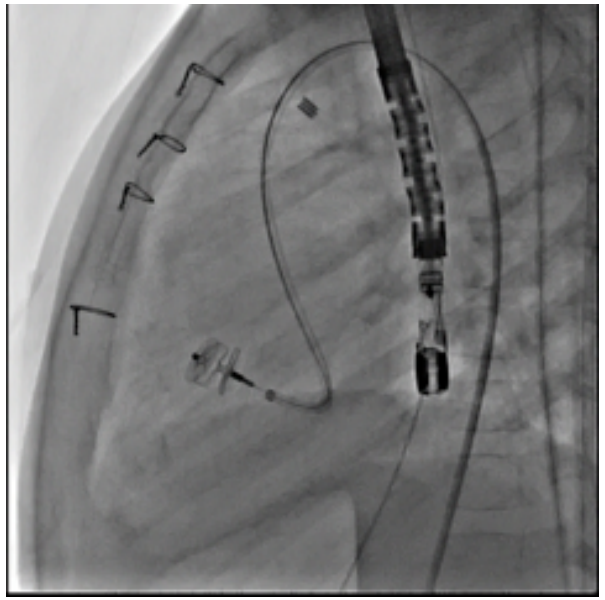

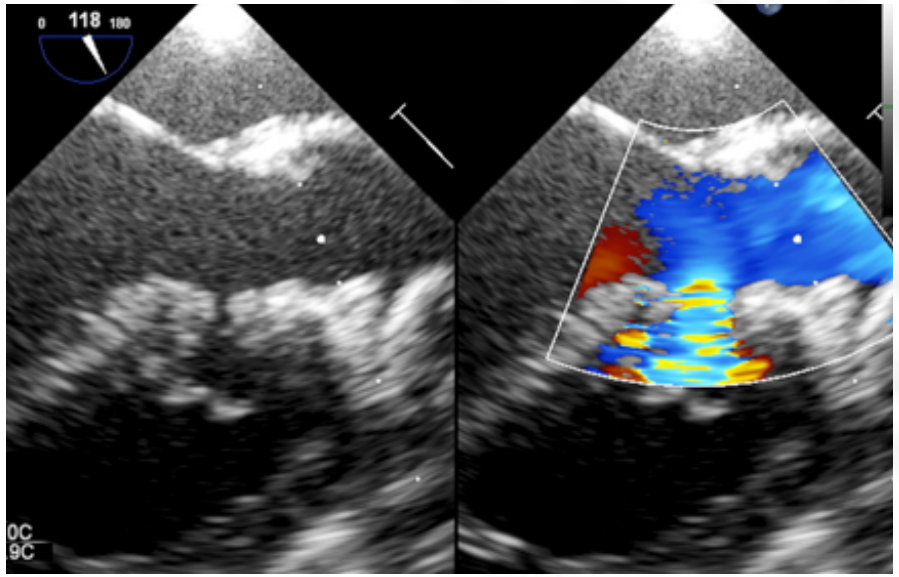

FERMETURE DES CIV MUSCULAIRES

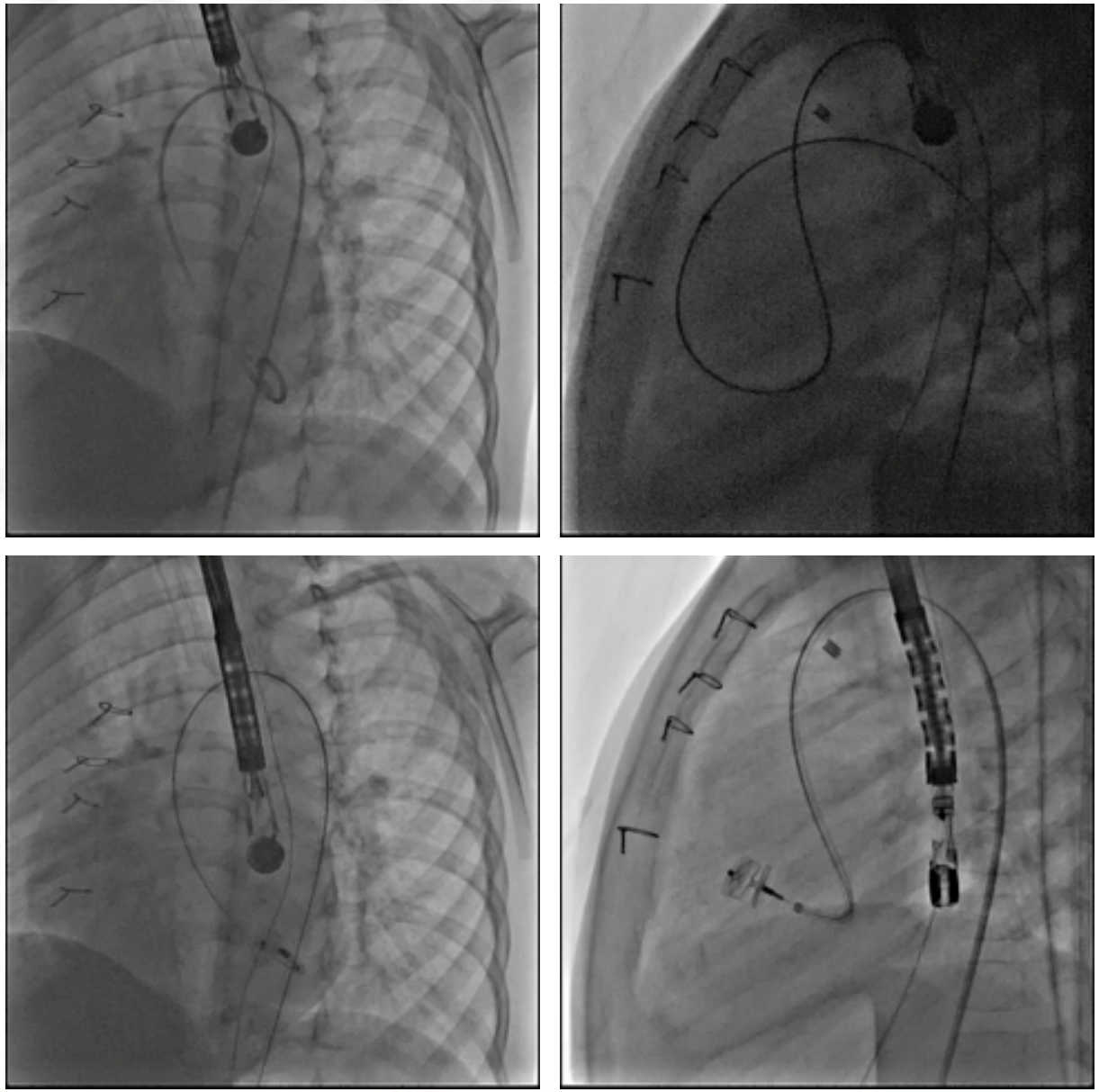

- Patient de 2 ans,
- CIV multiples larges => cerclage
- Fermeture spontanée de plusieurs CIV
- Persistance shunt plus large
- Fermeture directe voie rétrograde VG-VD

FERMETURE DES CIV MEMBRANEUSES



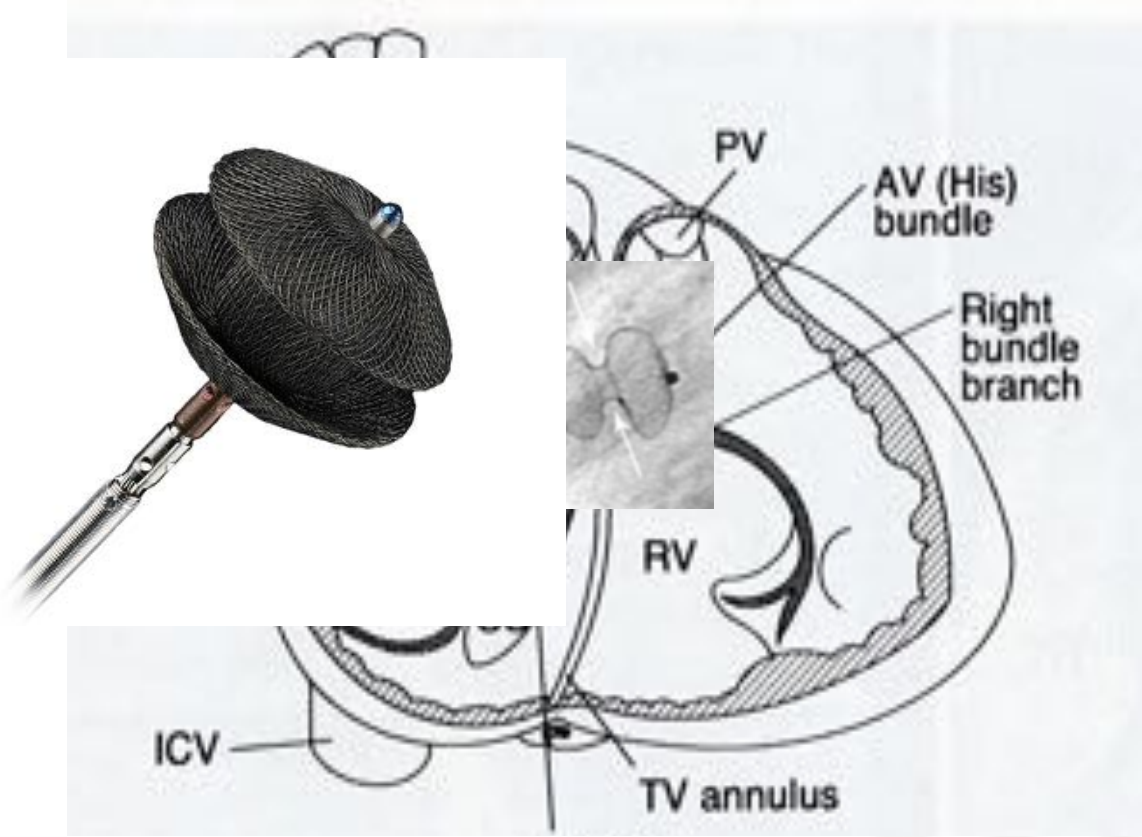

- Succès fermeture: 95-100%
- Shunt résiduel 6mois: <5%
- Mais....
- BAVc tardif : 1-5.7% (FDR: petit poid, pas d'anevrysme, oversizing...)

FERMETURE DES CIV MEMBRANEUSES

EXPÉRIENCE FRANÇAISE RÉTROSPECTIVE (2015-2018), 5 CENTRES M3C

- 46 pts, âge = 13.9 ans (0.7-60.4); poids 36.7 kg (7.1-81 kg).
- Diamètre CIV 8-mm (5-15); Anévrysme SIV : 91.3%
- Succès: 40/46; 87.0% (IC95% 73.7-95.1%)
- Complications sévères 6/46 (13.0% IC95% 4.9-26.3-%)
  - Hémolyse persistante (n=4, 8.7% IC95% 2.4-20.8%)
  - Lésion valve aortique (valvuloplastie chirurgicale) (1/46)
- Pas de BAV
- Learning curve+++, sélection des patients+++

Nit-Occlud® Lê VSD

6-7 F

8-16-mm

10kg

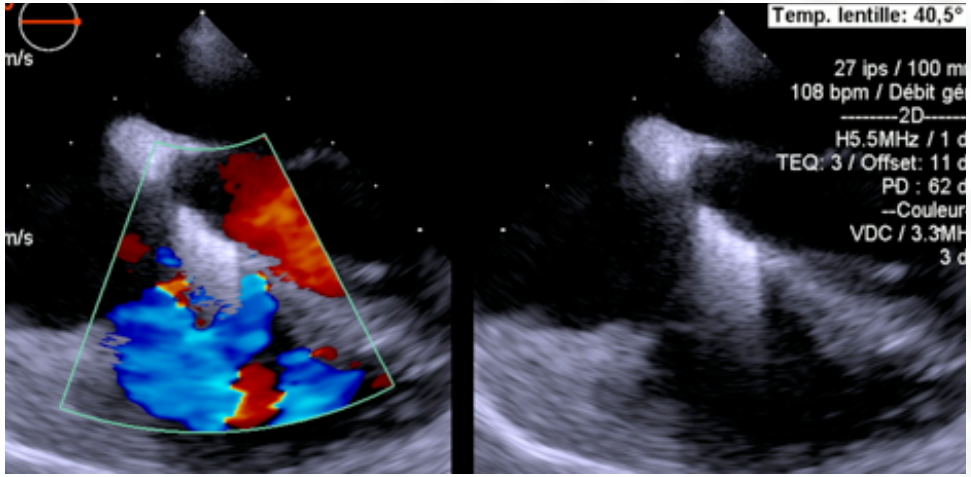

Houeijeh et al. In Press

FERMETURE DES CIV MEMBRANEUSES

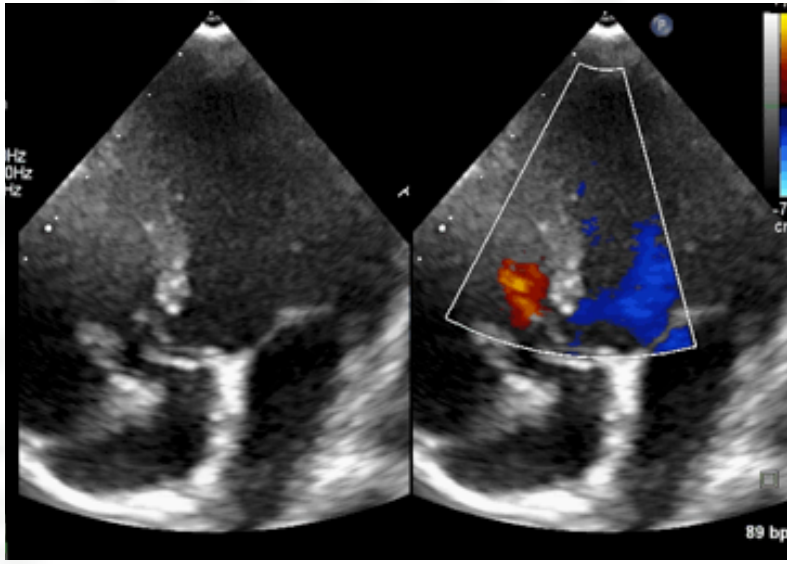

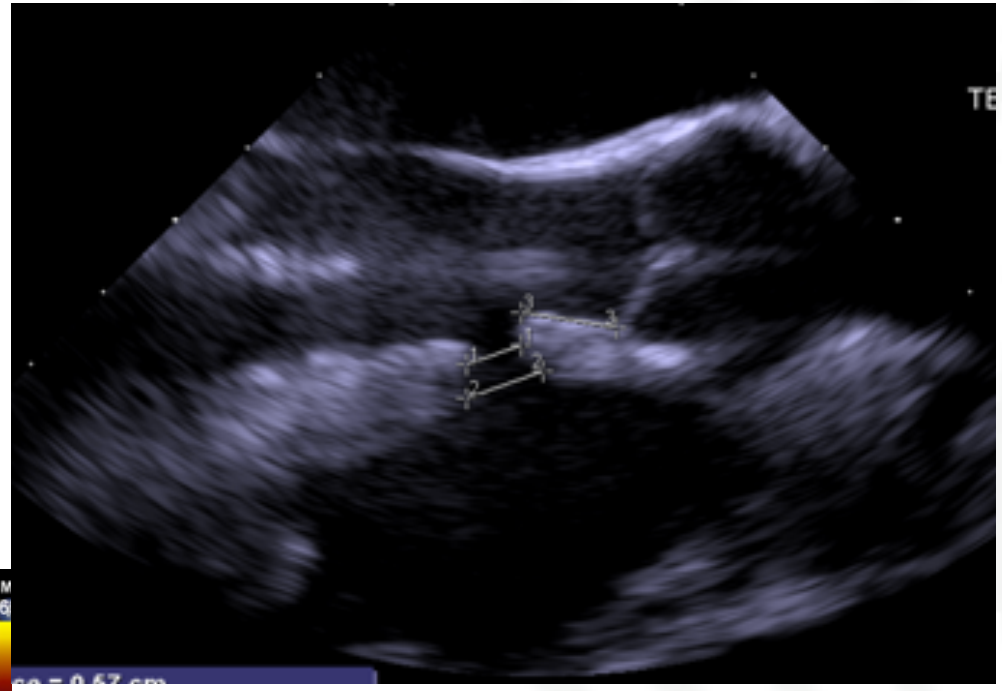

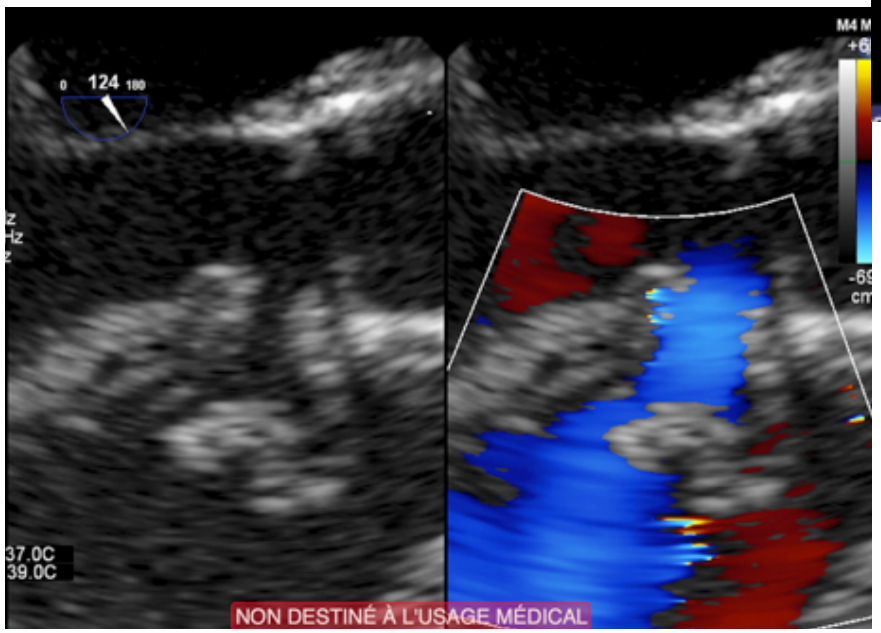

FERMETURE DES CIV MEMBRANEUSES

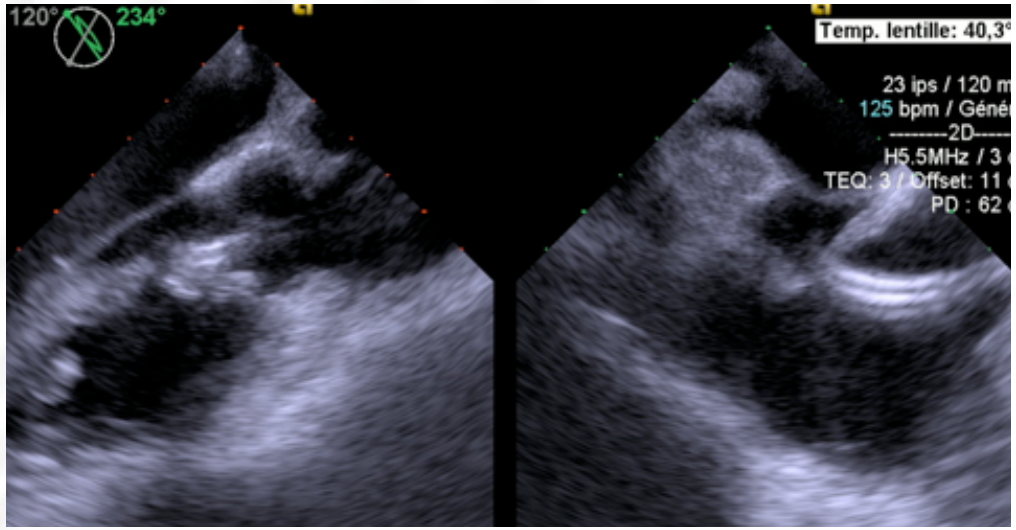

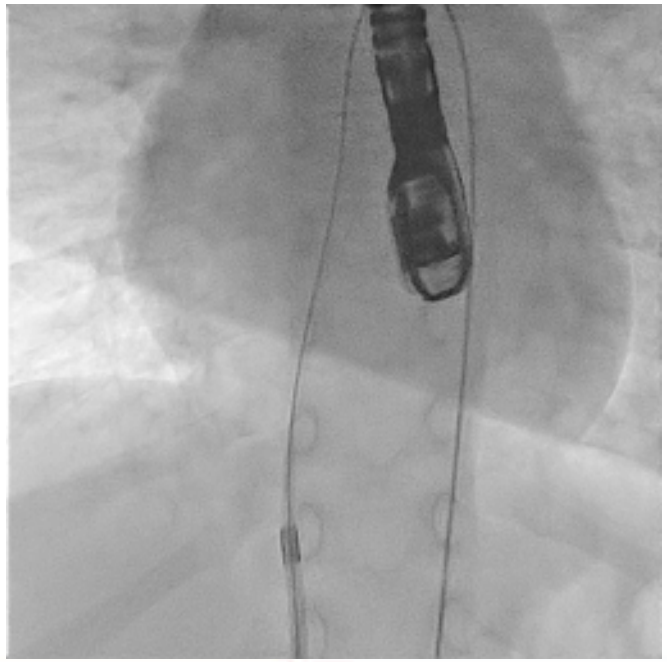

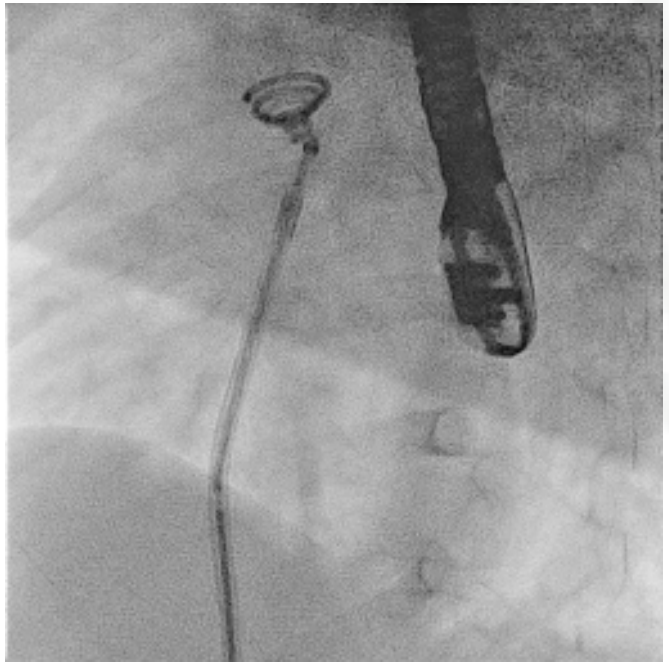

FERMETURE DES CIV MEMBRANEUSES

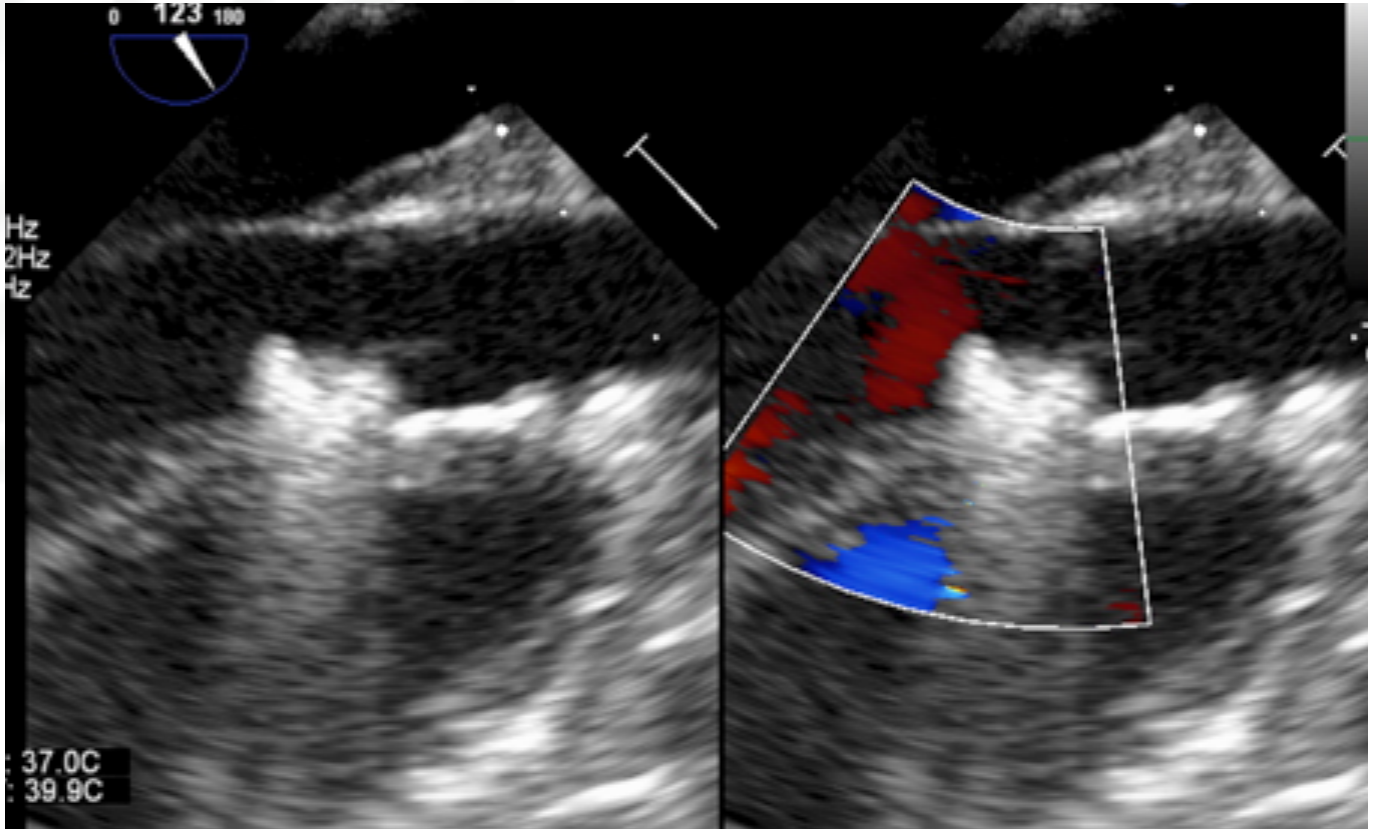

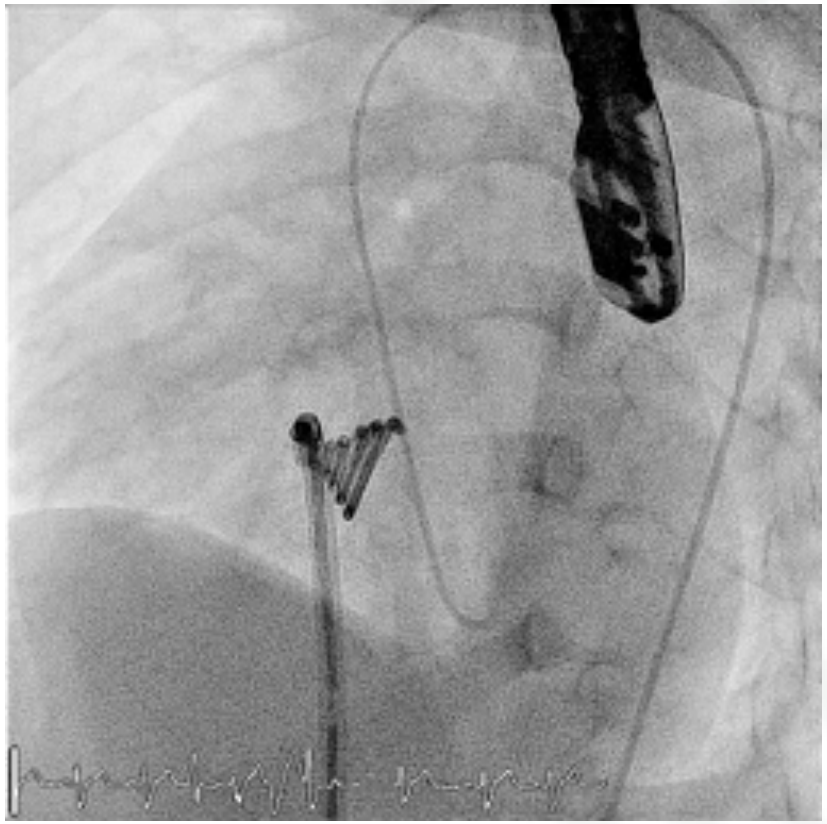

FERMETURE DE CIV MEMBRANEUSES

- 20 pts (6.4ans (0.6– 43), 17.3kg (9–74))
- Succès fermeture: 100%
- 1 embolisation
- Suivi 8.2 ± 3.0 mois
- Shunt résiduel: 15.8%
- IAo: 5%
- Pas de BAVc

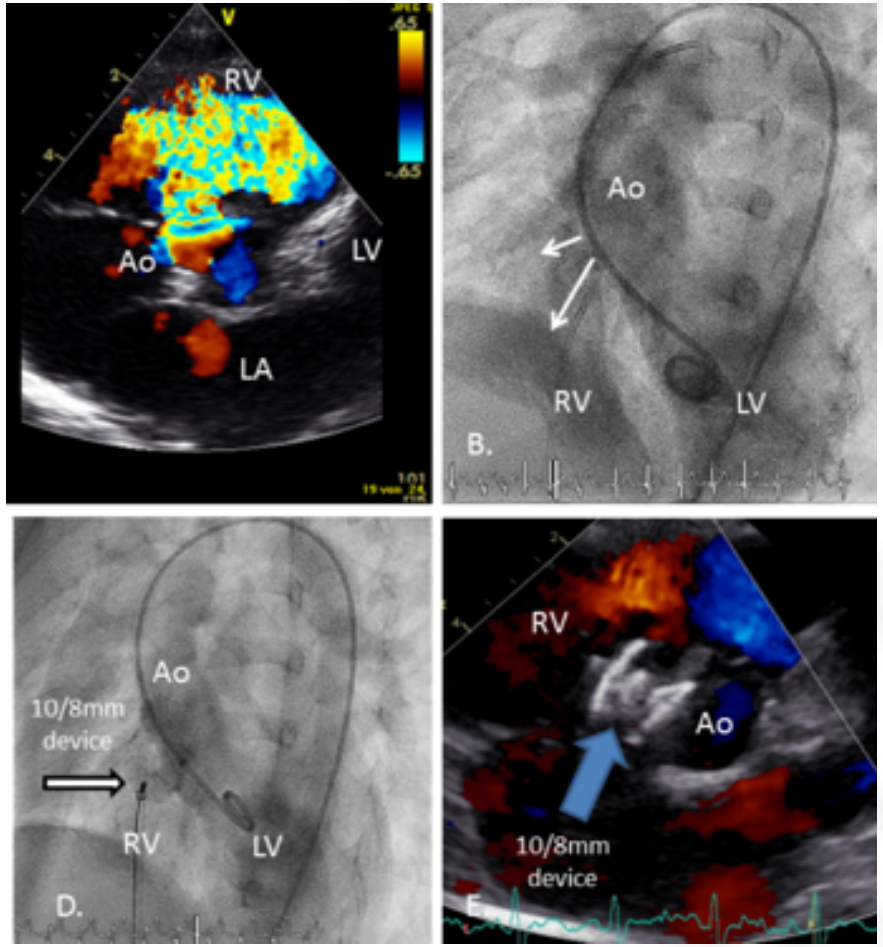

Haddad et al. CCI 2019

FERMETURE DE CIV MEMBRANEUSES

A meta-analysis of transcatheter device closure of perimembranous ventricular septal defect **54 publications 6762 patients (1.6 - 37.4 ans)**

Succès procédure: 97.8% (95% CI: 96.8 - 98.6).

Shunt résiduel: 15.9%; 95% CI: 10.9 - 21.5.

Arythmies : 10.3%; 95% CI: 8.3 - 12.4 and

Valvulopathies induites: 4.1%; 95% CI: 2.4 - 6.1.

BAVc: 1.1% (95% CI: 0.5 to 1.9) => 4% sous groupe prothèses asymétriques

Santhanam et al. Int Jour Card 2018

FERMETURE DES CIV MEMBRANEUSES

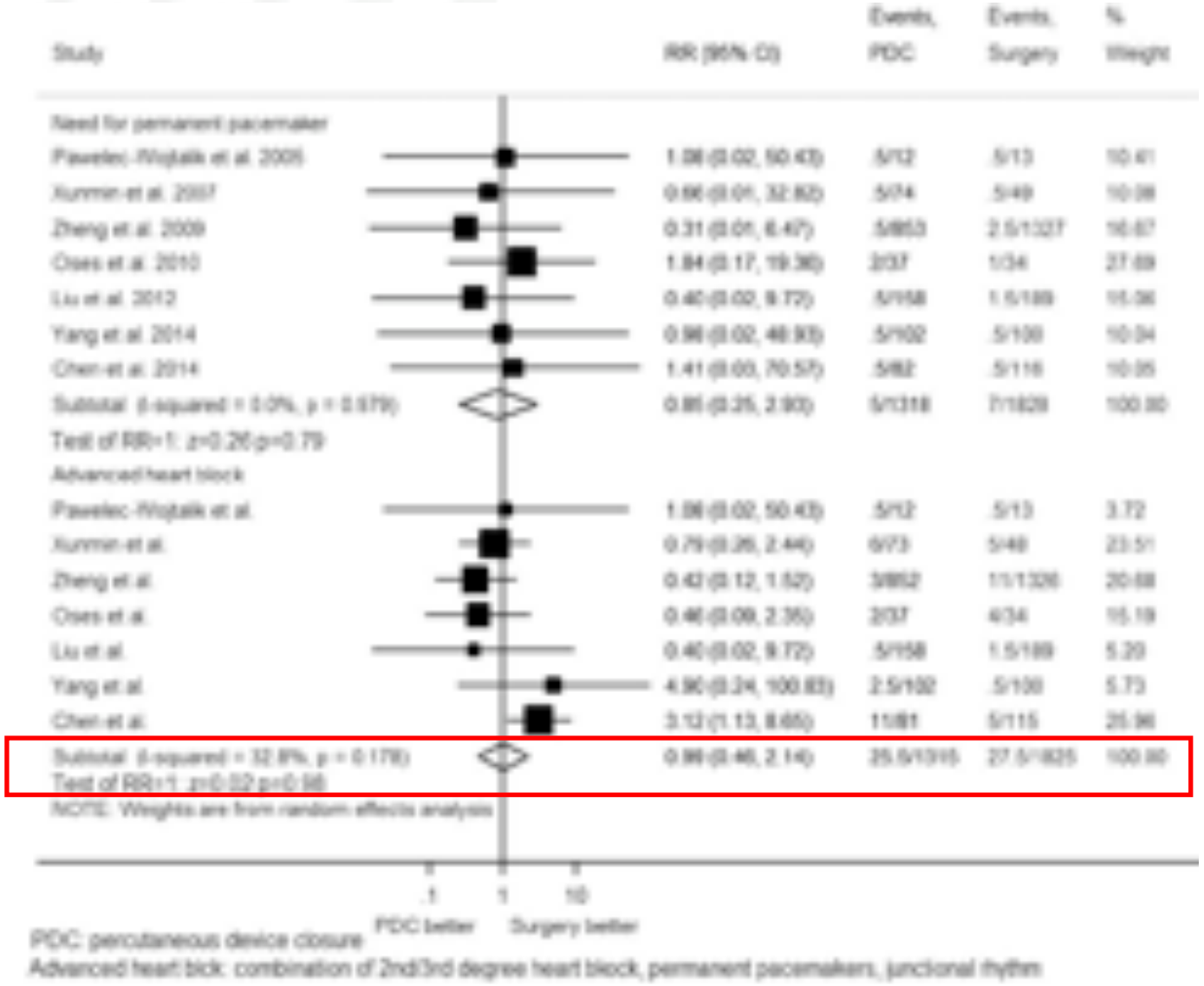

Comparison of Percutaneous Device Closure Versus Surgical Closure of Peri-Membranous Ventricular Septal Defects: A Systematic Review and Meta-Analysis

- Les 2 techniques sont équivalentes
- Succès de procédure
- Complications sérieuses
  - Shunt résiduel
  - Fuite valvulaire
  - BAV de haut degré
  - Nécessité de PM

Saurav et al. CCI 2015

LE CANAL ARTÉRIEL

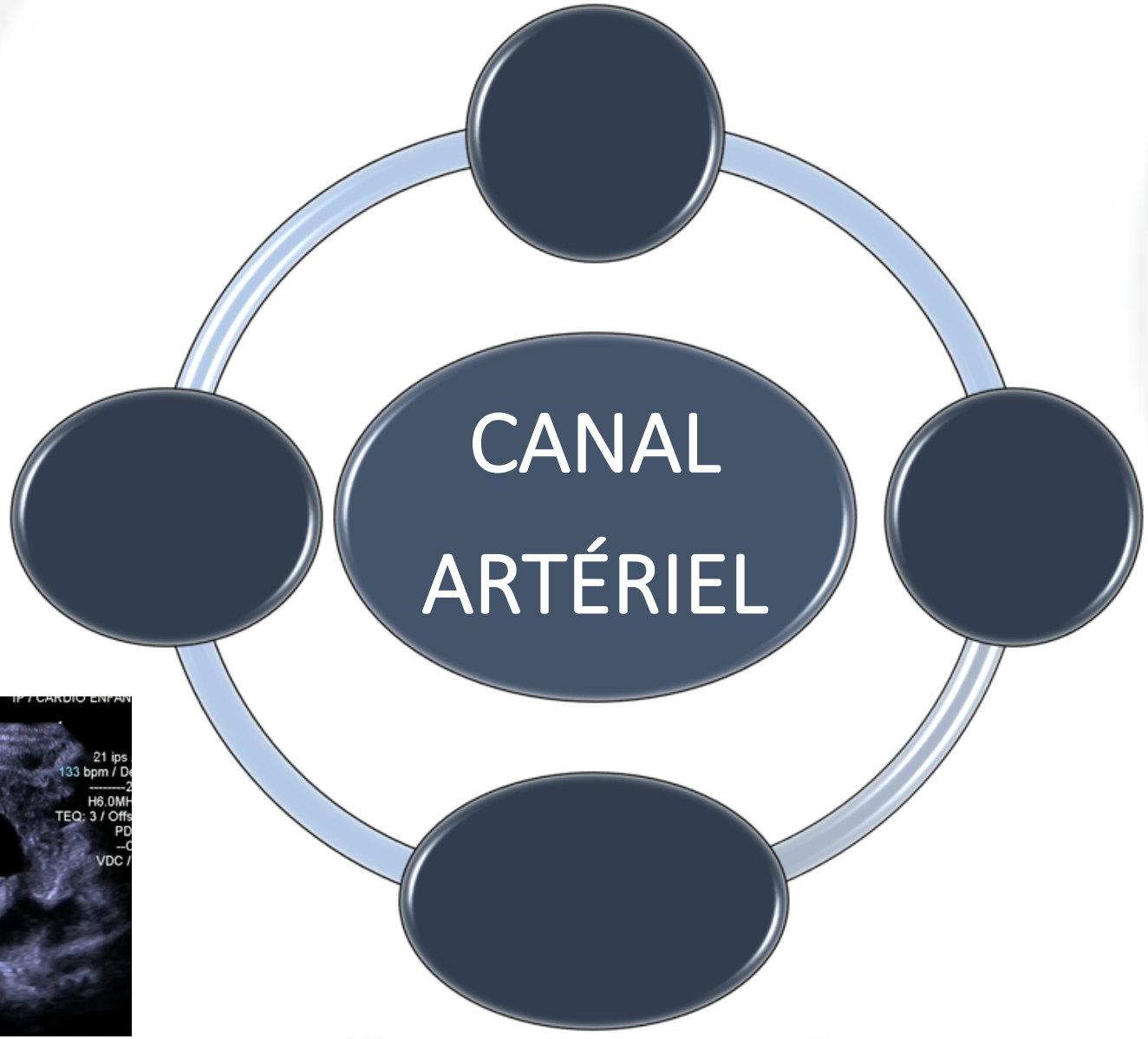

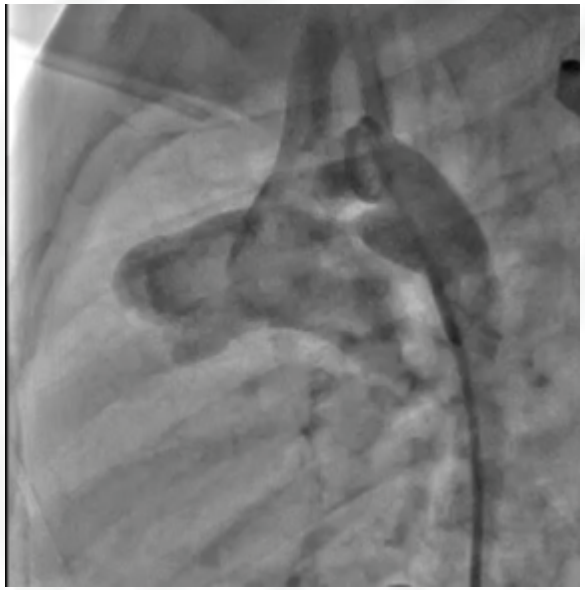

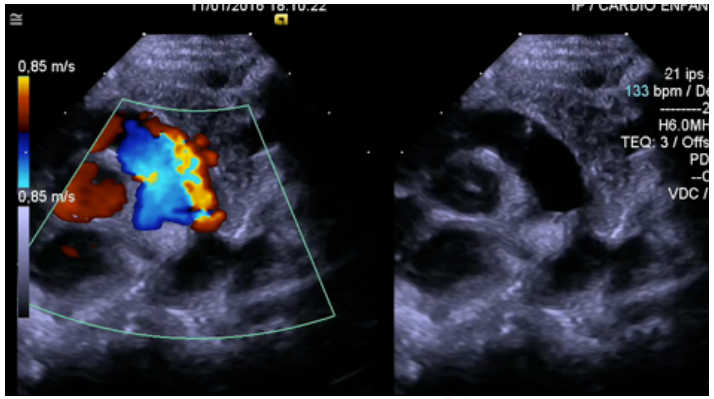

CANAL ARTÉRIEL - 1975

Transfemoral Plug Closure of Patent Ductus Arteriosus

Experiences in 61 Consecutive Cases Treated Without Thoracotomy

By Kenji Sato, M.D., Masaoki Fujino, M.D., Takahiro Kozuka, M.D., Yasuaki Naito, M.D., Soichiro Kitamura, M.D., Susumu Nakano, M.D., Choken Ohyama, M.D., and Yasunaru Kawashima, M.D.

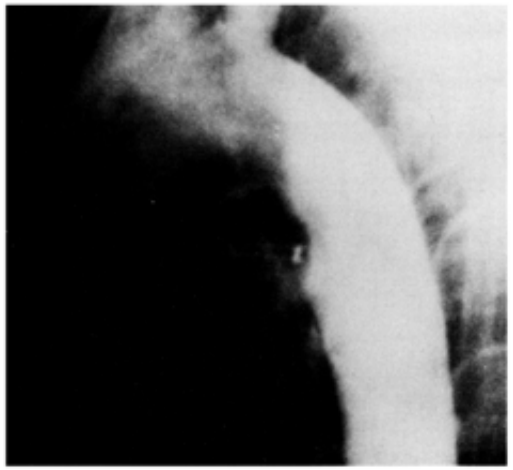

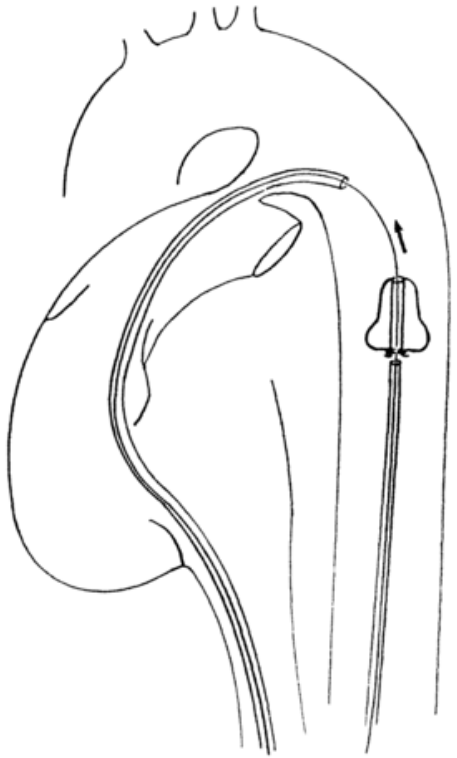

Figure 1

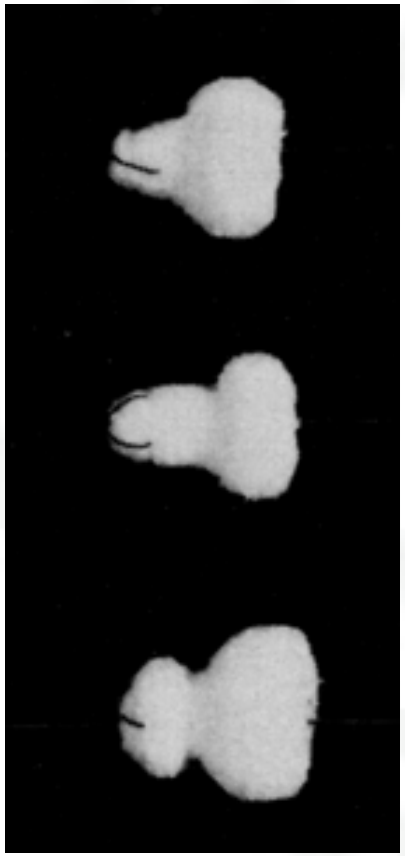

CANAL ARTÉRIEL - 2020

- Pas de limite de poids
- Toutes les anatomies
- Nouveaux dispositifs à partir de 3-4F
- Abord veineux ou artériel
- Salle de KT ou guidance ETT au lit
- Occluders vs coils

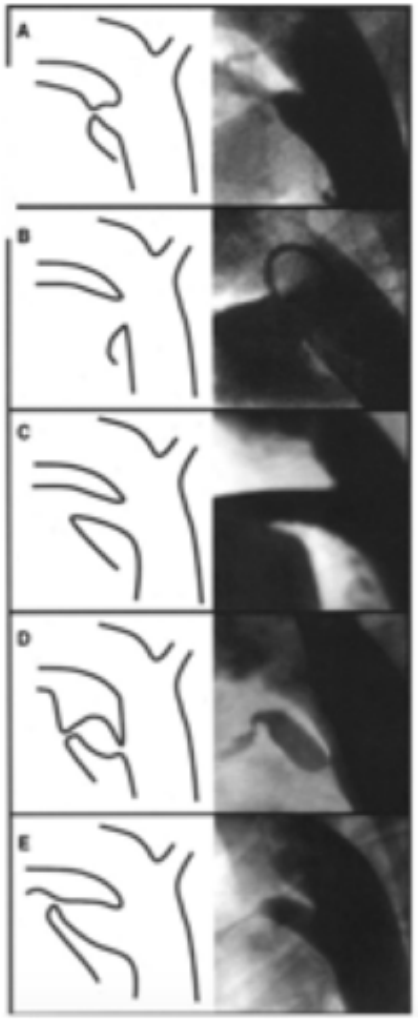

RECOMMANDATIONS

ESC Guidelines for the management of grown-up congenital heart disease

Recommendations	Class[a]	Level[b]
In patients with evidence of LV volume overload[c] and no PAH (no non-invasive signs of PAP elevation or invasive confirmation of PVR <3 WU in case of such signs), PDA closure is recommended regardless of symptoms.	I	C
Device closure is recommended as the method of choice when technically suitable.	I	C
In patients who have developed PAH with PVR 3–5 WU, PDA closure should be considered when there is still significant L–R shunt (Qp:Qs >1.5).	IIa	C
In patients who have developed PAH with PVR ≥5 WU, PDA closure may be considered when there is still significant L–R shunt (Qp:Qs >1.5) but careful individual decision in expert centres is required.	IIb	C
PDA closure is not recommended in patients with Eisenmenger physiology and patients with lower limb desaturation on exercise.[d]	III	C

SUCCÈS FERMETURE > 95%

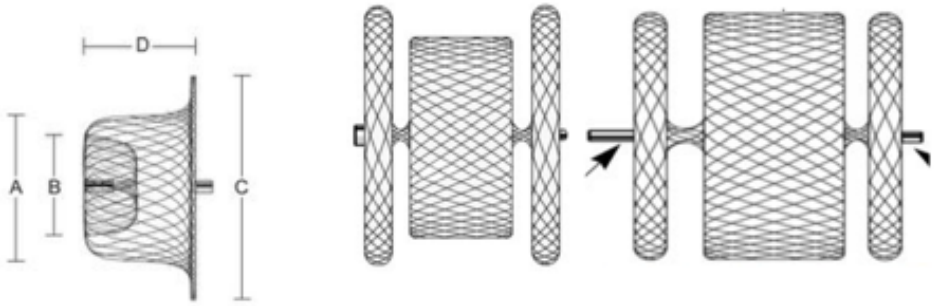



ADO

ADO II AS

AVP

ADO II

FERMETURE PAR PLUG

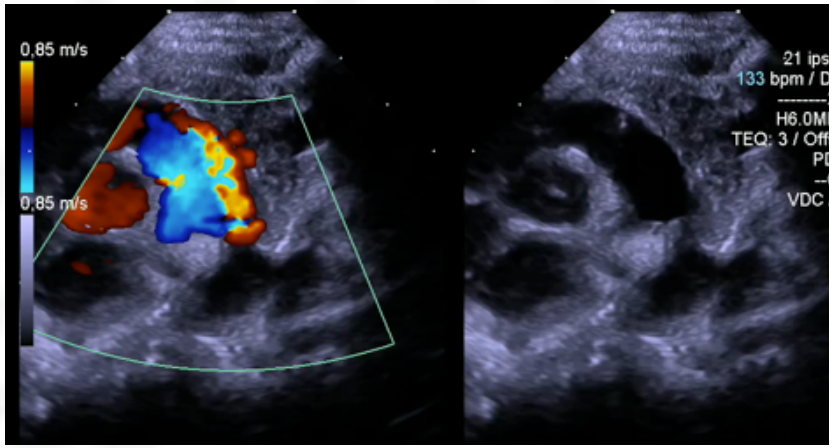

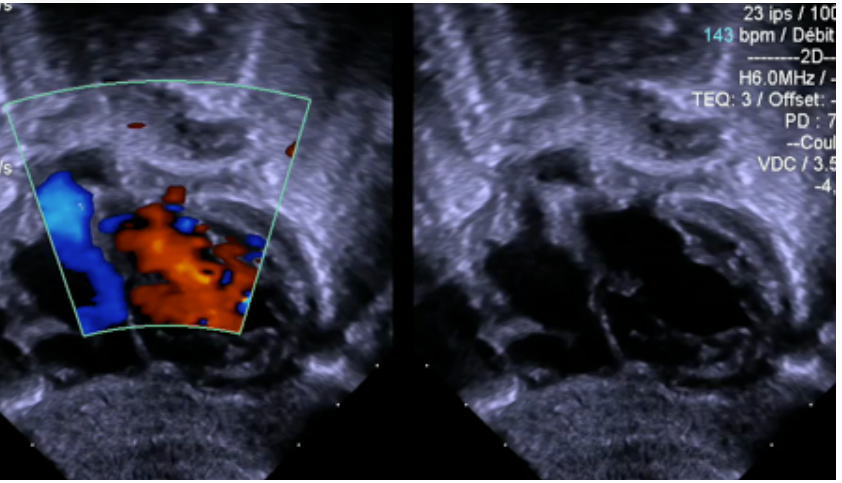

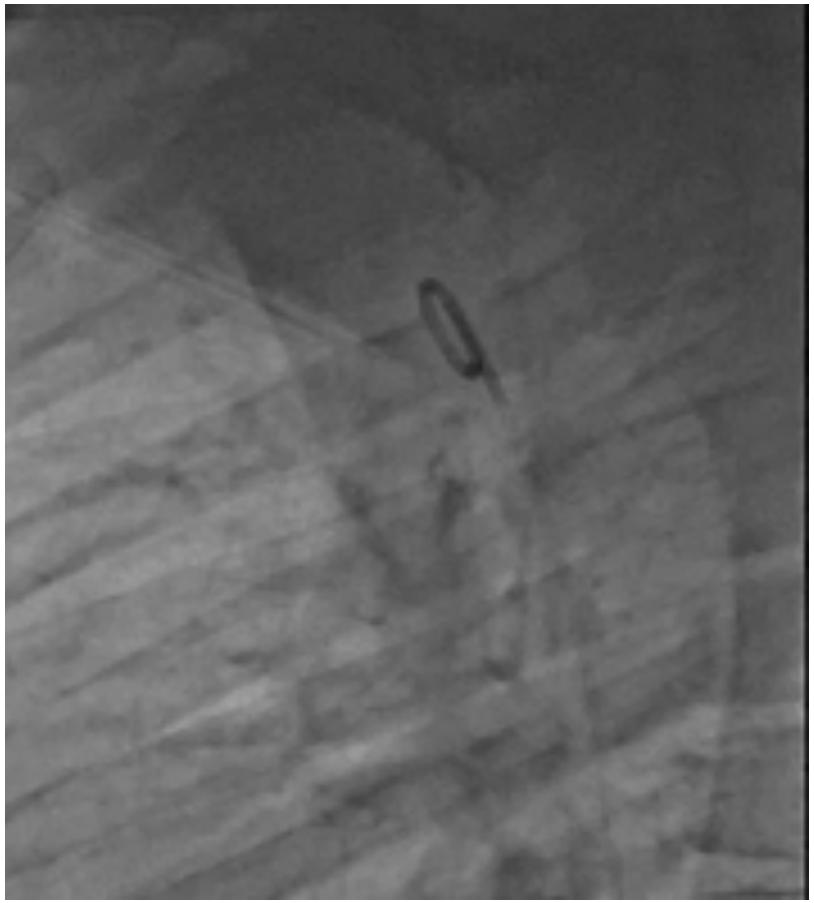

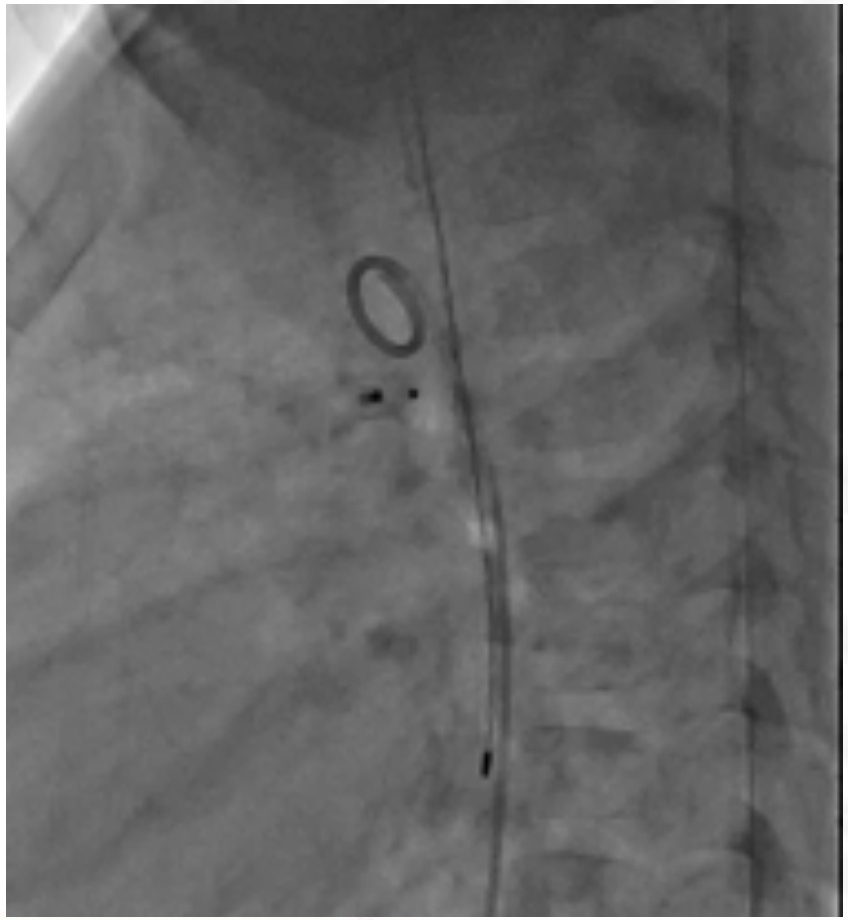

FERMETURE PAR COIL

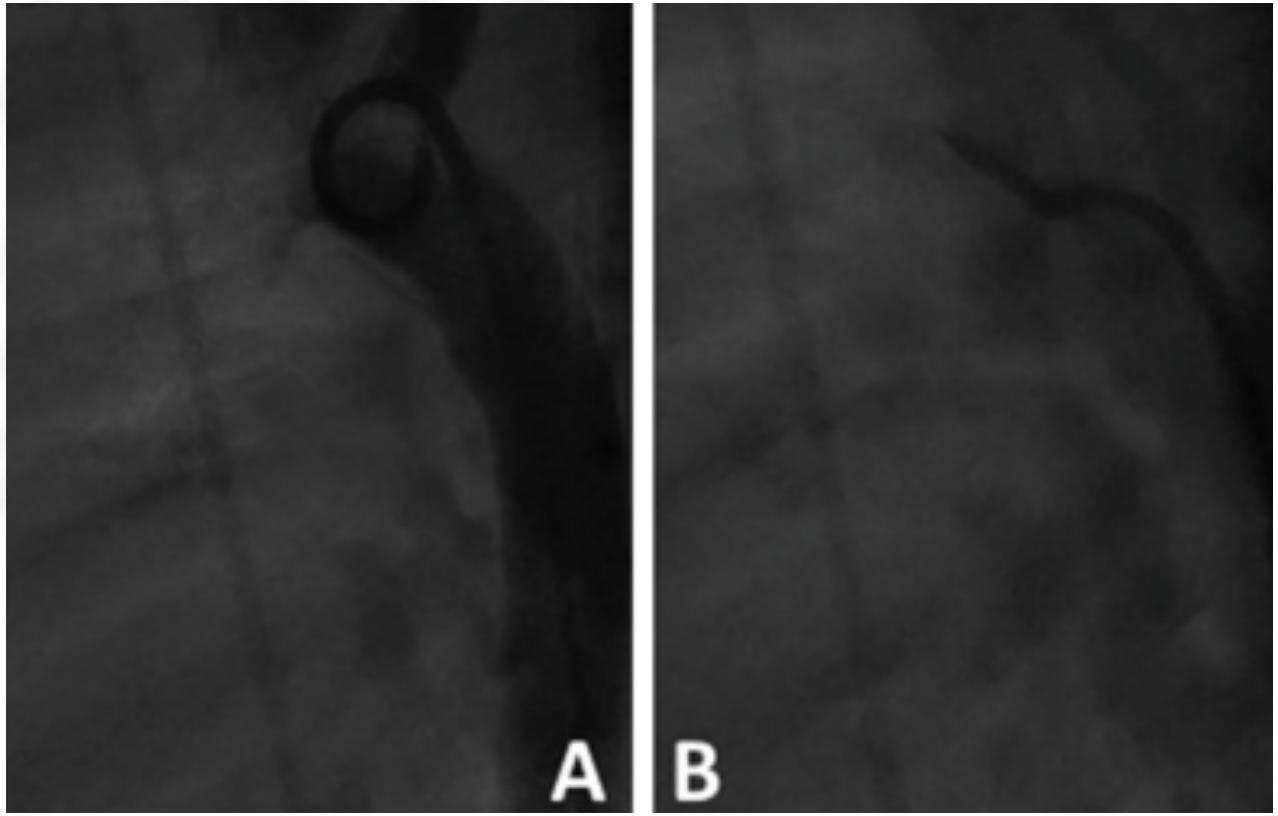

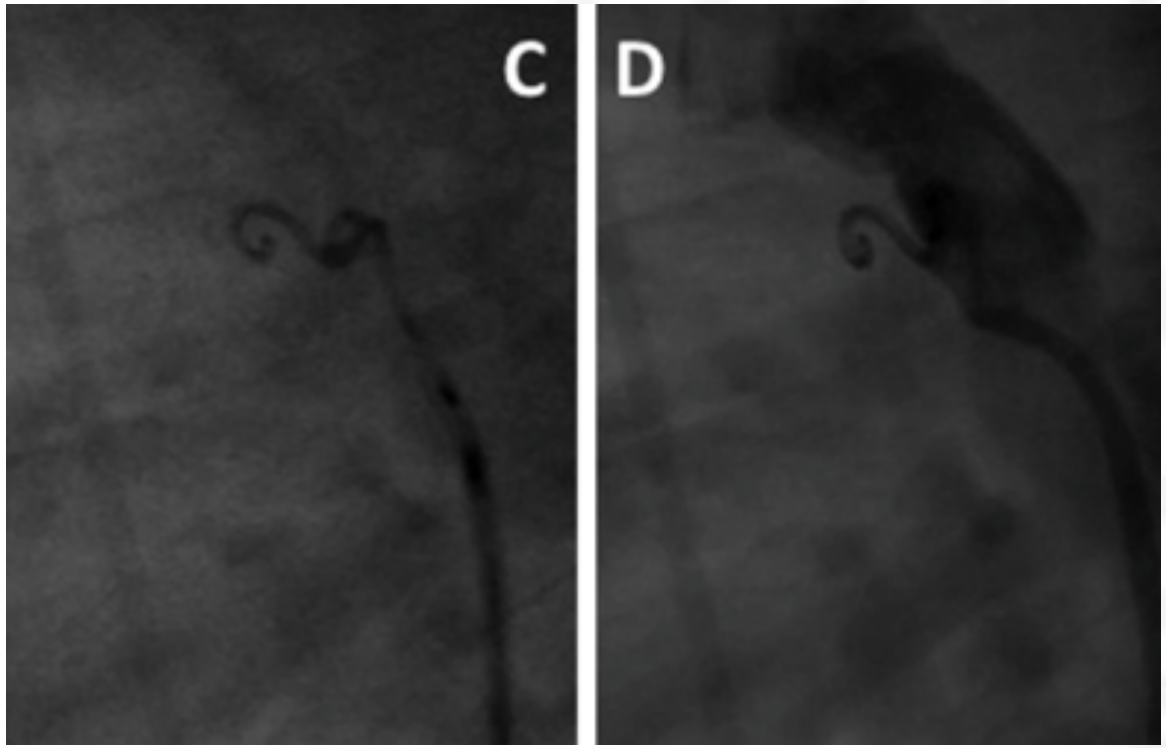

CANAL ARTÉRIEL DU PRÉMATURÉ

RISQUES DU CA DU PRÉMATURÉ

- Court Terme (< 72h) :
  - Hémorragie intra-ventriculaire
  - Hémorragie pulmonaire
- Moyen terme :
  - Insuffisance rénale
  - Réaggravation de la MMH
- Long terme :
  - Insuffisance cardiaque
  - Bronchodysplasie

CANAL ARTÉRIEL DU PRÉMATURÉ

PRISE EN CHARGE – LOGISTIQUE+++

- Salle de KT vs Couveuse
- Transport
- Température
- Sédation/Anesthésie
- Abord uniquement veineux
- Guidance échographique
- Risque thrombose
- Précarité hémodynamique

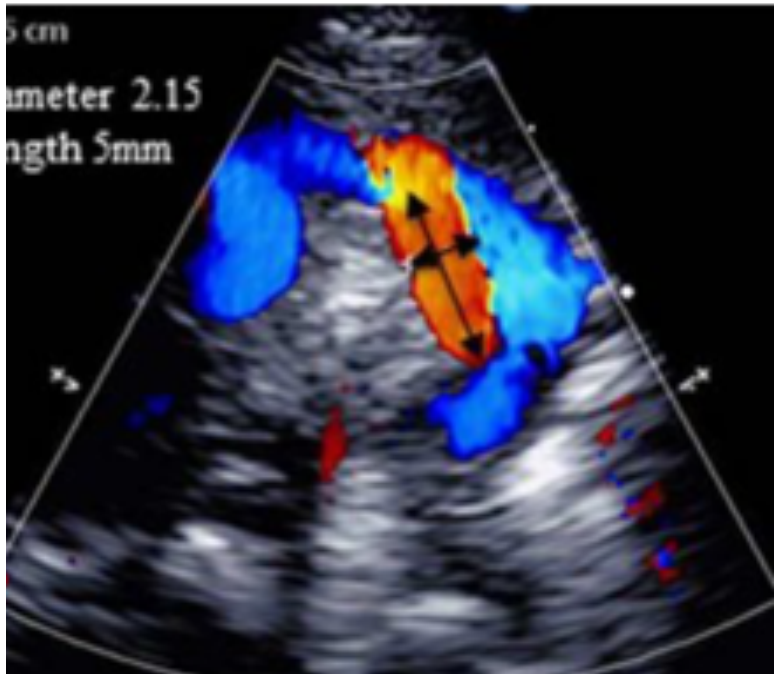

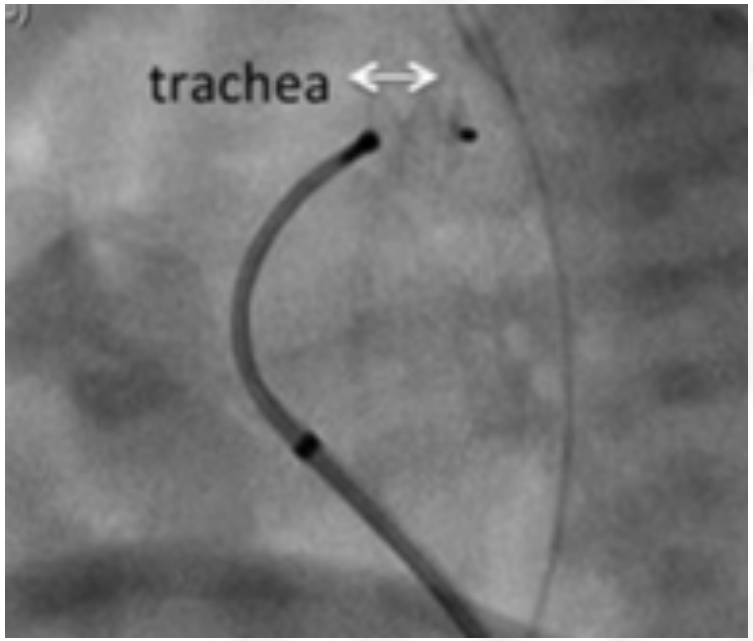

CANAL ARTÉRIEL DU PRÉMATURÉ

Pediatric and Congenital Heart Disease

Transcatheter closure of hemodynamic significant patent ductus arteriosus in 32 premature infants by amplatzer ductal occluder additional size-ADOIIAS

- Etude monocentrique (CHU Reims)
- 32 prématurés (28±3 SA)
- Fermeture à 25 jours de vie (8-70) et 1373 g (680–2480)
- Succès fermeture: 31/32
- Médianes fluoro et procédure: 11 min (3–24) et 28 min (10–90)
- 1 obstruction APG non significative
- 5 décès dont 1 lié à la procédure (680g)

Morville et al. CCI 2017

CANAL ARTÉRIEL DU PRÉMATURÉ

- Instabilité hémodynamique et respiratoire
- Échec de fermeture du canal
- Embolisation de prothèse
- Sténose APG
- Coarctation de l’aorte
- Rupture de cordage tricuspide
- Complications au point de ponction
- Infection post-cathétérisme
- Hémolyse ou endocardite si shunt résiduel

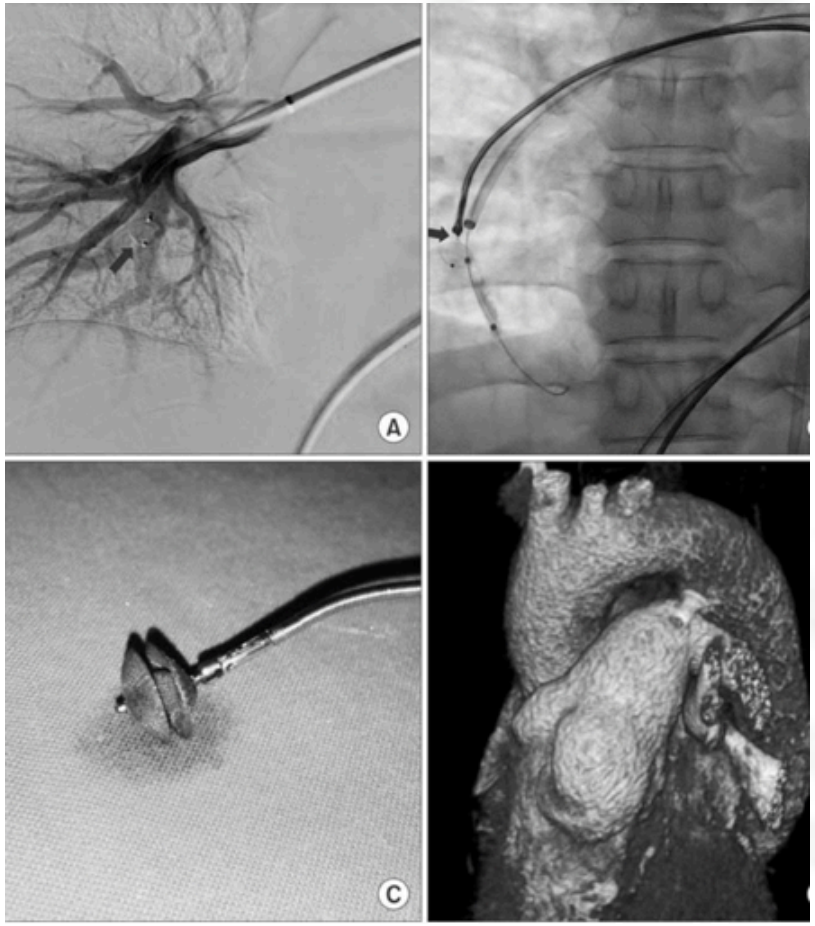

OBSTRUCTION DU CŒUR DROIT

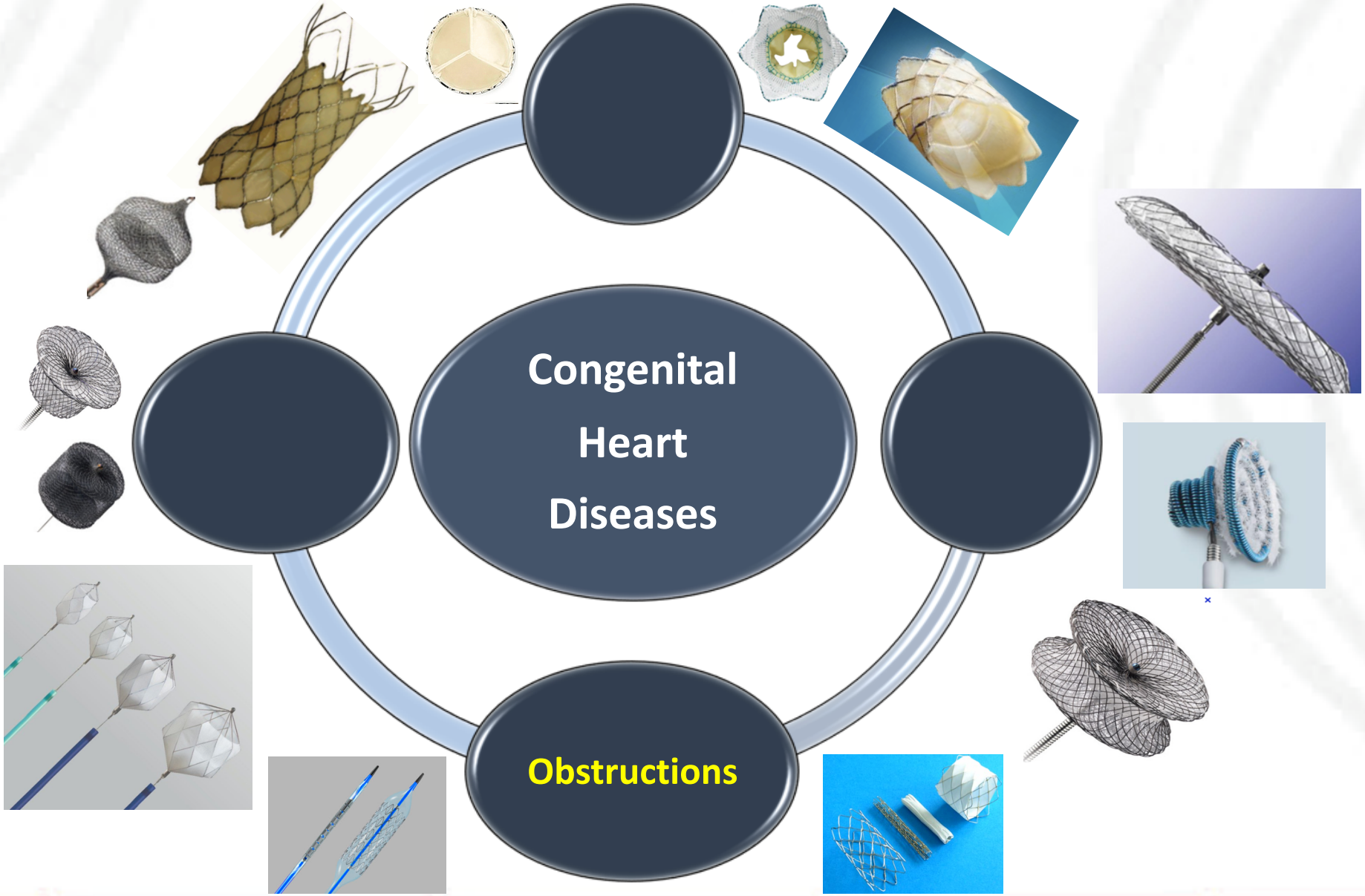

INTRODUCTION

OBJECTIF : AUGMENTATION DU DEBIT PULMONAIRE

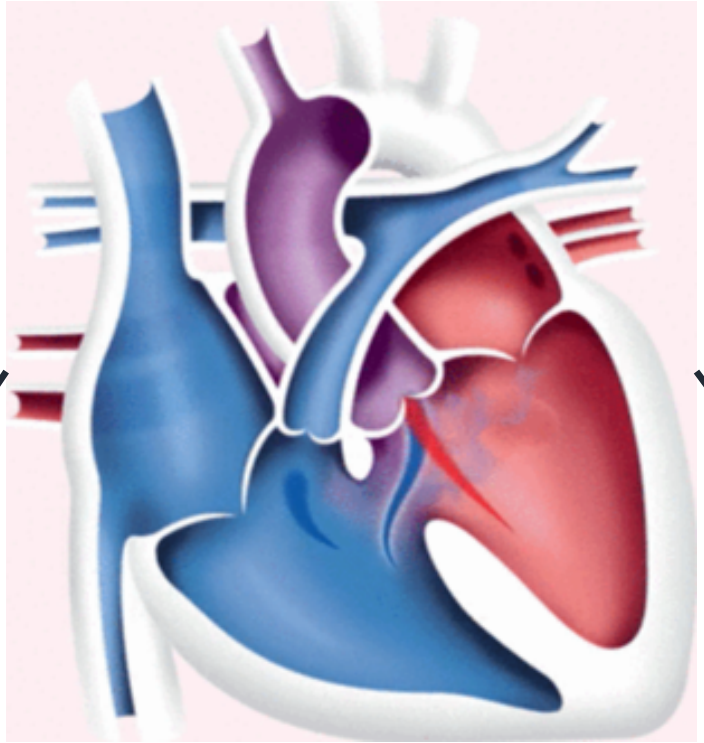

LEVER L'OBSTACLE SUR LA VOIE DROITE

ANASTOMOSE SYSTEMICO-PULMONAIRE

INTRODUCTION

SIÈGE DE L'OBSTACLE

VALVE
Dilatation
Perforation

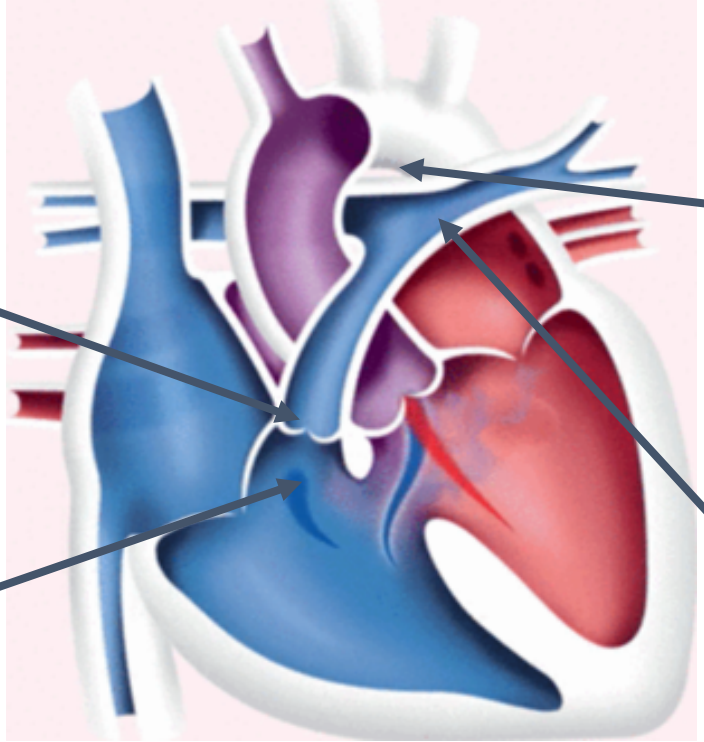

SHUNT
Stenting Canal Artériel

INFUNDIBULUM
Stenting RVOT

ARTÈRES PULMONAIRES
Dilatation
Stenting

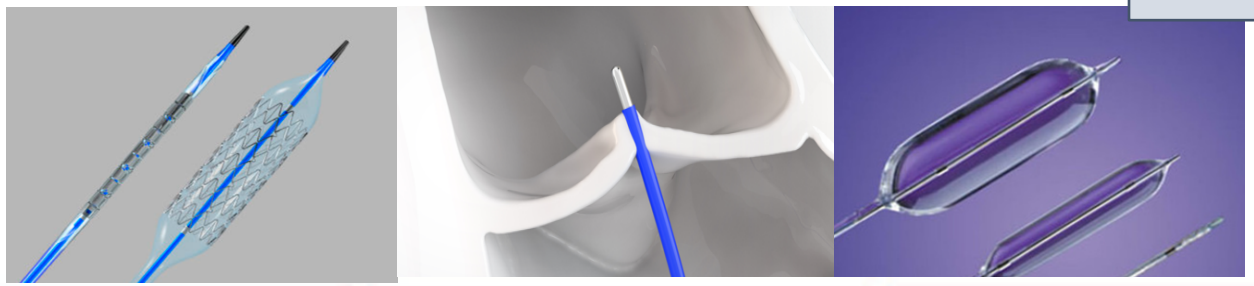

OBSTACLE INFUNDIBULAIRE

SIÈGE DE L'OBSTACLE

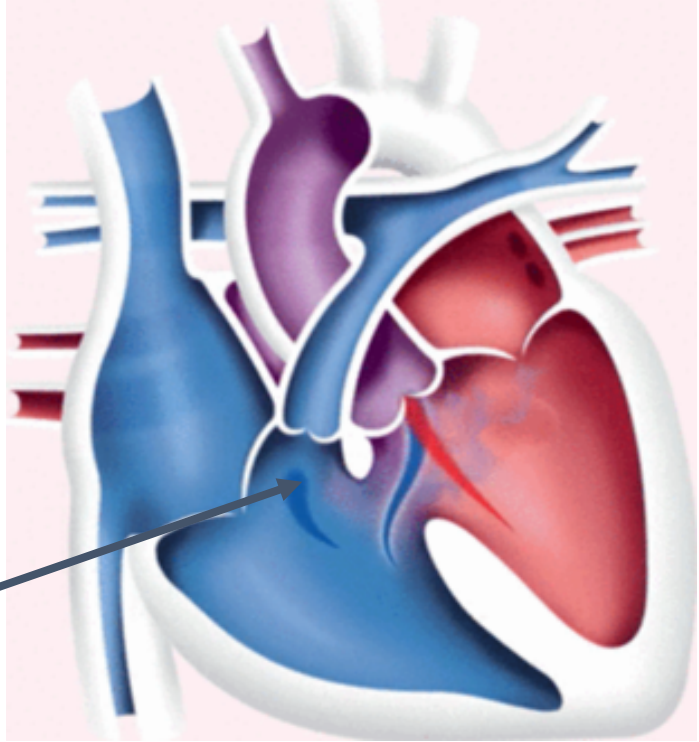

INFUNDIBULUM
Stenting RVOT

RATIONNEL

- Ouverture VD-AP sans CEC
- Eviter les effets délétères des shunts

LIMITES

- Taille du stent (hyper/hypodébit)
- Abord vasculaire
- Sélection des patients

CAS CLINIQUE

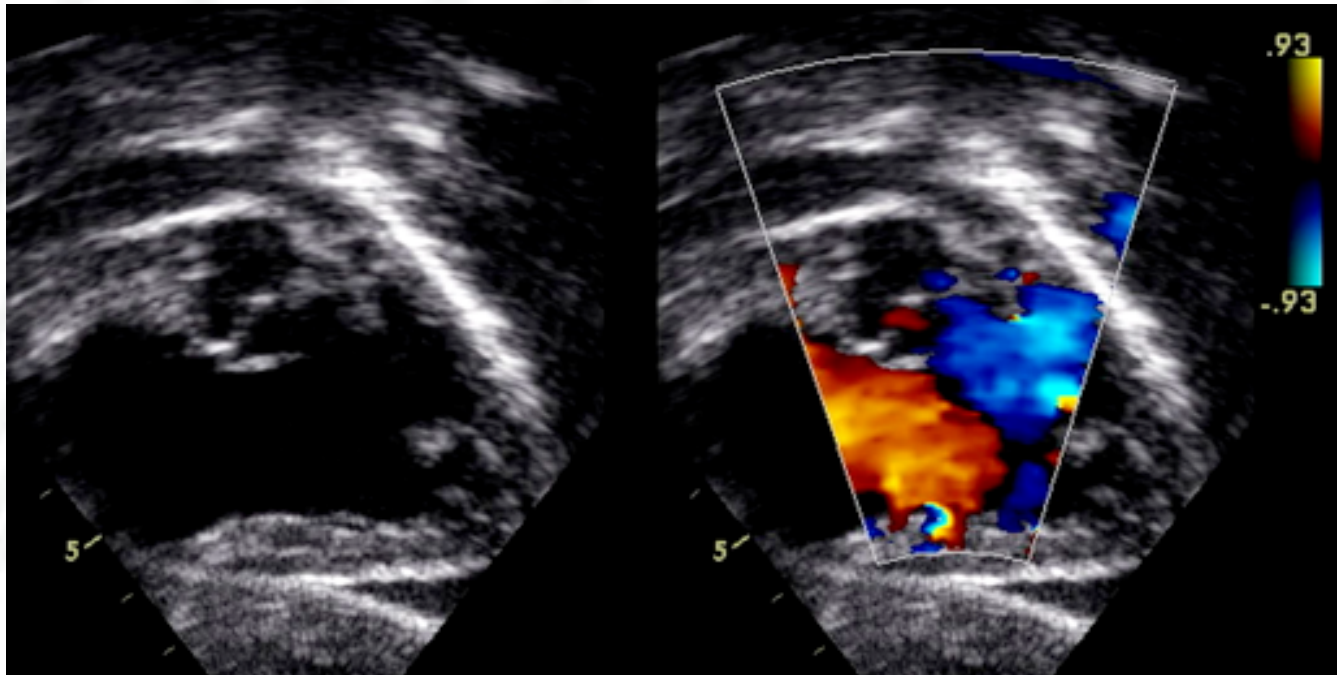

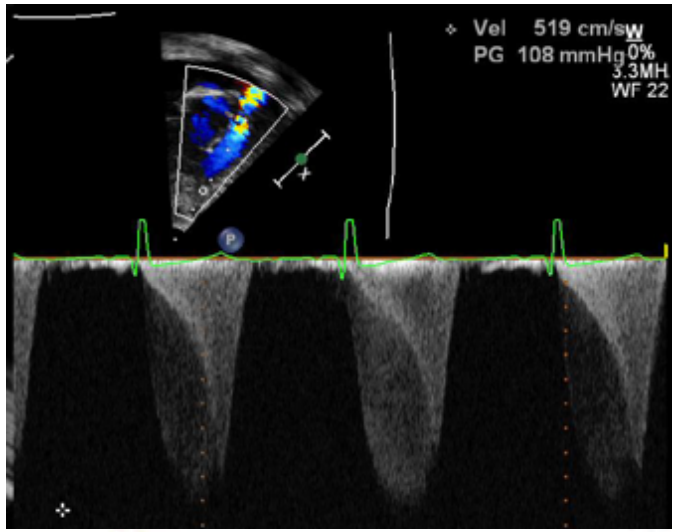

- TOF, Diagnostic anténatal
- Prématurité 30 SA, PN=1800g
- Saturation: 68%, obstacle infundibulaire +++
- PGE1
- Discussion médico-chirurgicale
  - Anastomose systémico-pulmonaire
  - Ouverture VD-AP
  - Stenting infundibulaire
- => Stenting VD-AP par Abord hybride

CAS CLINIQUE

CAS CLINIQUE

Stent Coronaire 5 x 20-mm

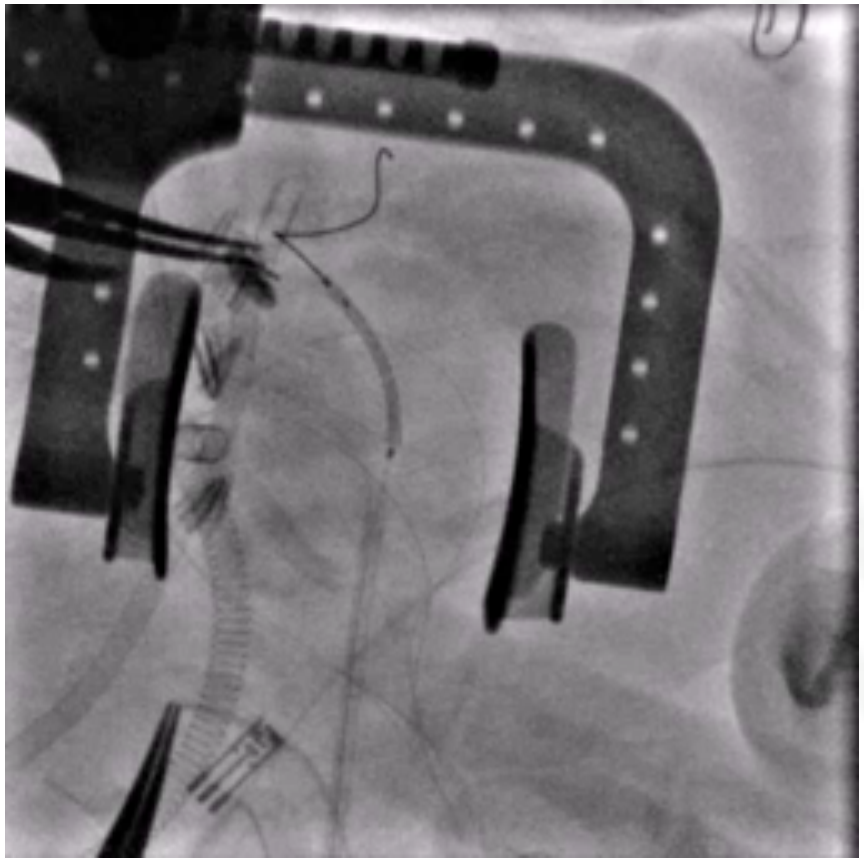

CAS CLINIQUE

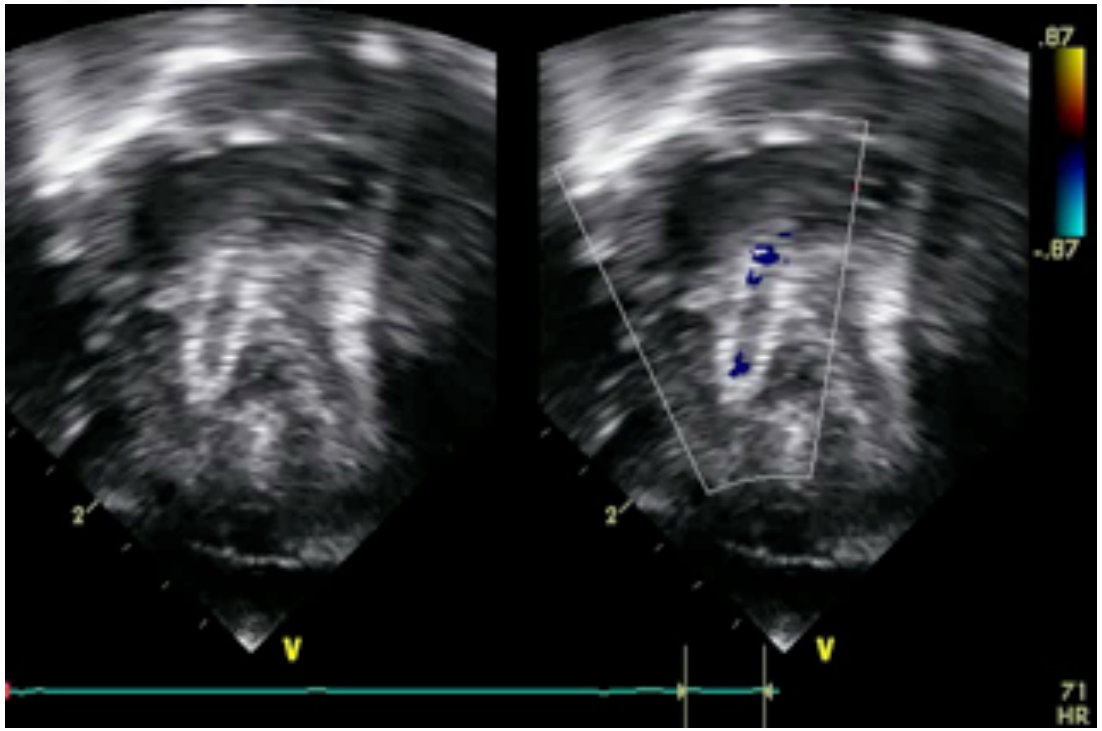

STENTING RVOT - RESULTATS

Stenting of the Right Ventricular Outflow Tract Promotes Better Pulmonary Arterial Growth Compared With Modified Blalock-Taussig Shunt Palliation in Tetralogy of Fallot-Type Lesions

- Etude monocentrique rétrospective, 67 TOF
- RVOT stent (n=39) vs BTS (n=28)
- Mortalité comparable ≃ 5%
- Stenting infundibulaire
  - Durée d'hospitalisation plus courte
  - Chirurgie réparatrice plus précoce
  - Meilleure croissance des AP

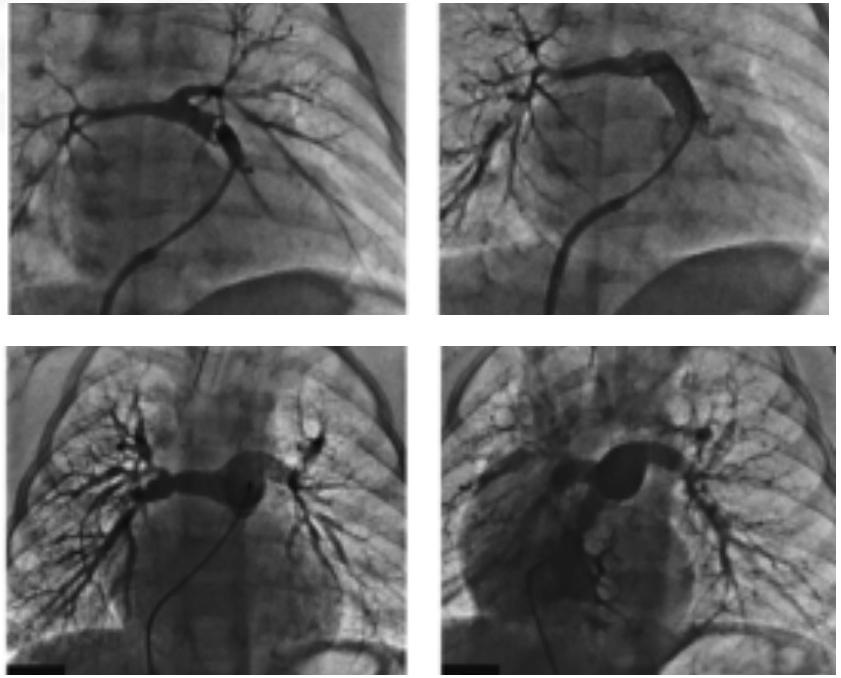

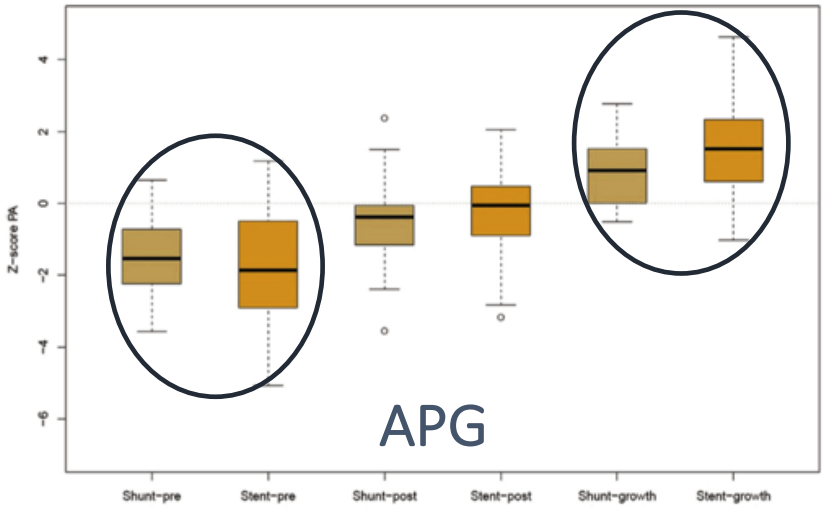

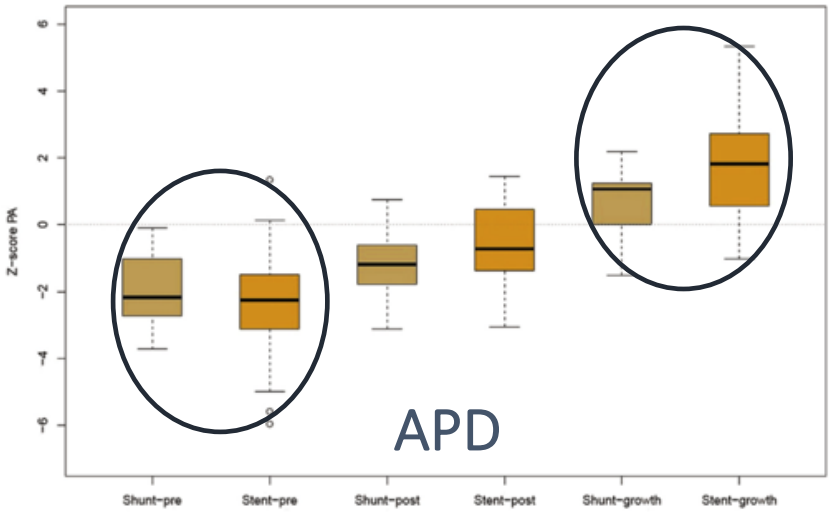

Quandt et al. J Am Coll Cardiol Intv 2017

OBSTACLE VALVULAIRE

SIÈGE DE L'OBSTACLE

VALVE
Dilatation
Perforation

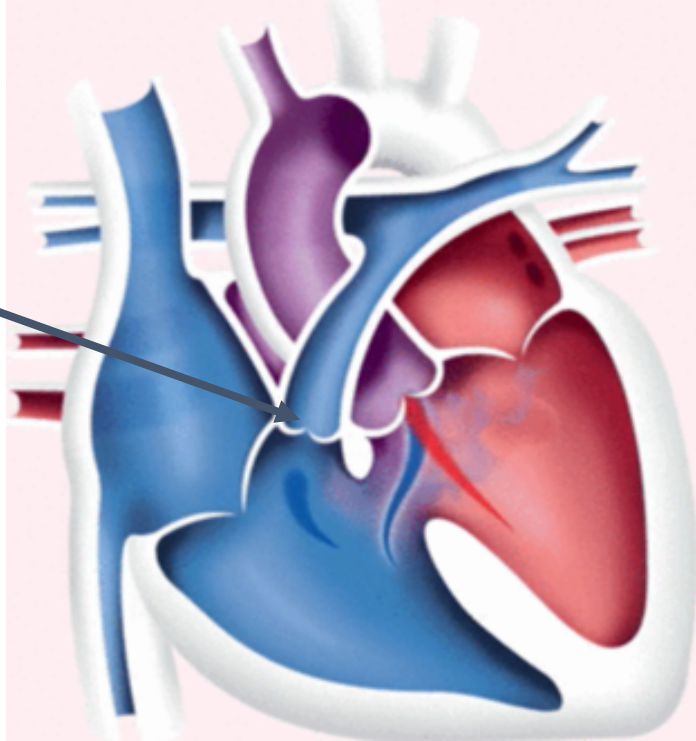

STÉNOSE PULMONAIRE CRITIQUE vs ATRÉSIE PULMONAIRE À SEPTUM INTACT

OBSTACLE VALVULAIRE

Recommendations for Pulmonary Valvuloplasty

Class I

1. Pulmonary valvuloplasty is indicated for a patient with critical valvar pulmonary stenosis (defined as pulmonary stenosis present at birth with cyanosis and evidence of patent ductus arteriosus dependency), valvar pulmonic stenosis, and a peak-to-peak catheter gradient or echocardiographic peak instantaneous gradient of ≥40 mm Hg or clinically significant pulmonary valvar obstruction in the presence of RV dysfunction (*Level of Evidence: A*).

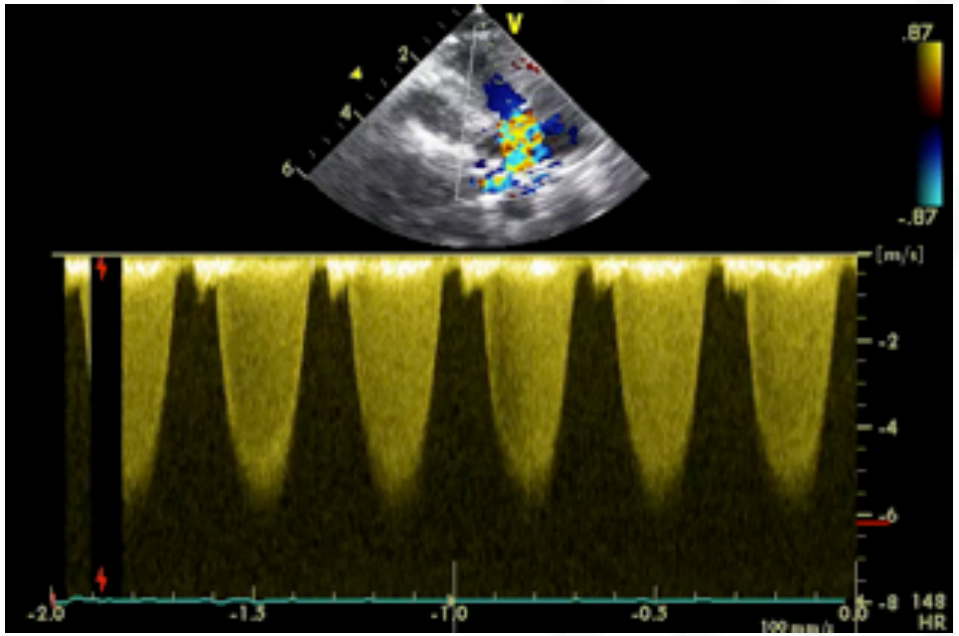

Class IIb

1. Pulmonary valvuloplasty may be considered as a palliative procedure in a patient with complex cyanotic CHD, including some rare cases of tetralogy of Fallot (*Level of Evidence: C*).

OBSTACLE VALVULAIRE

VALVULOPLASTIE AU BALLON
Taille Ballon = 120 à 150% de l'anneau

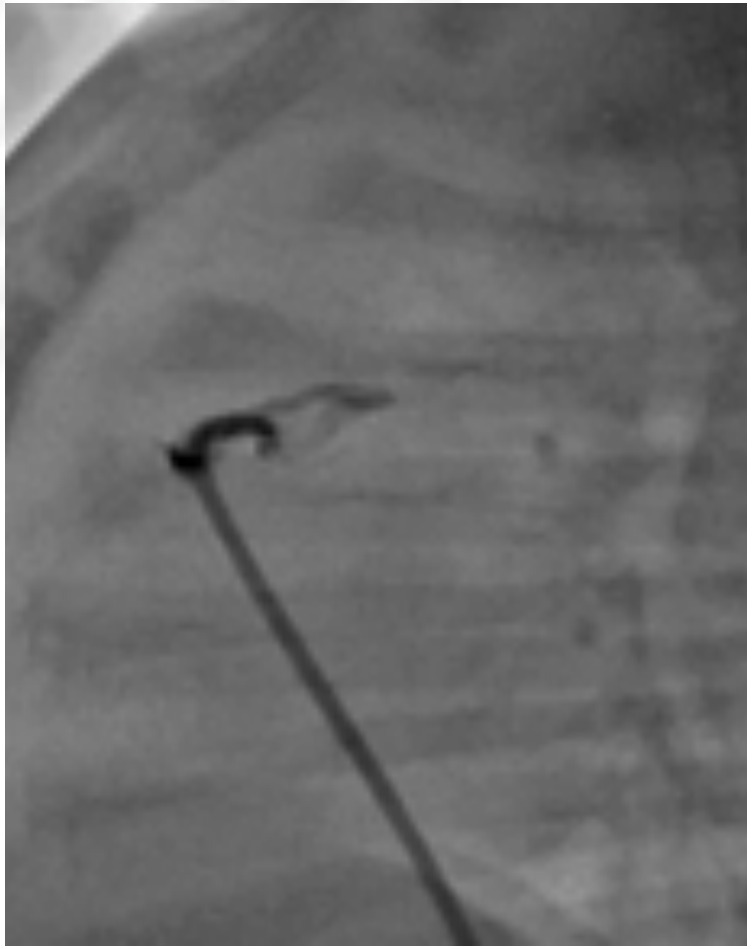

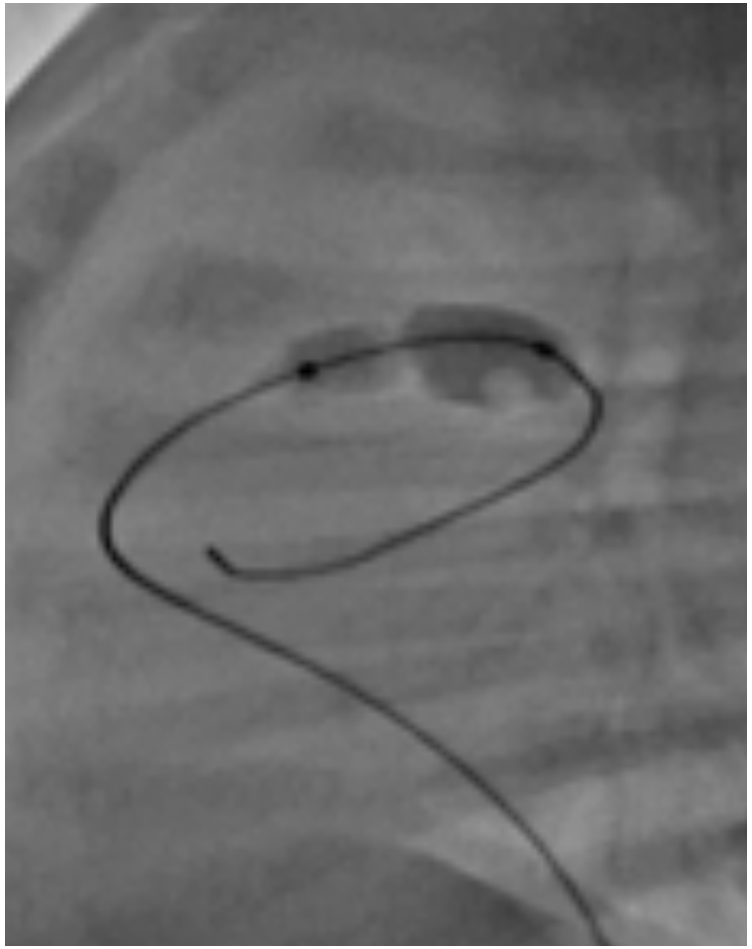

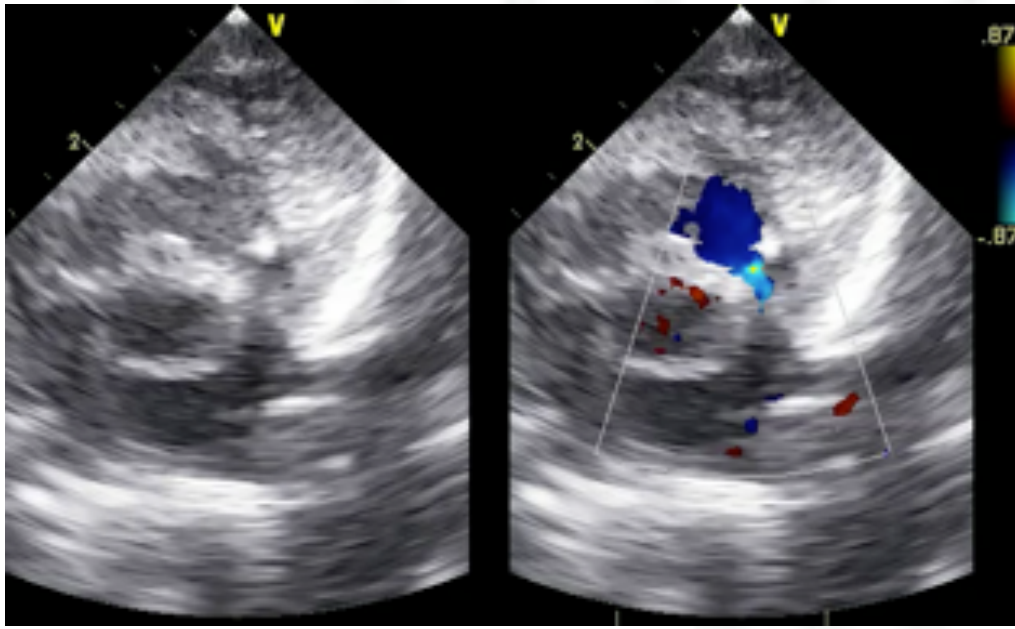

Succès > 95% (Noonan)
Complications faibles

OBSTACLE VALVULAIRE

Devenir à long terme

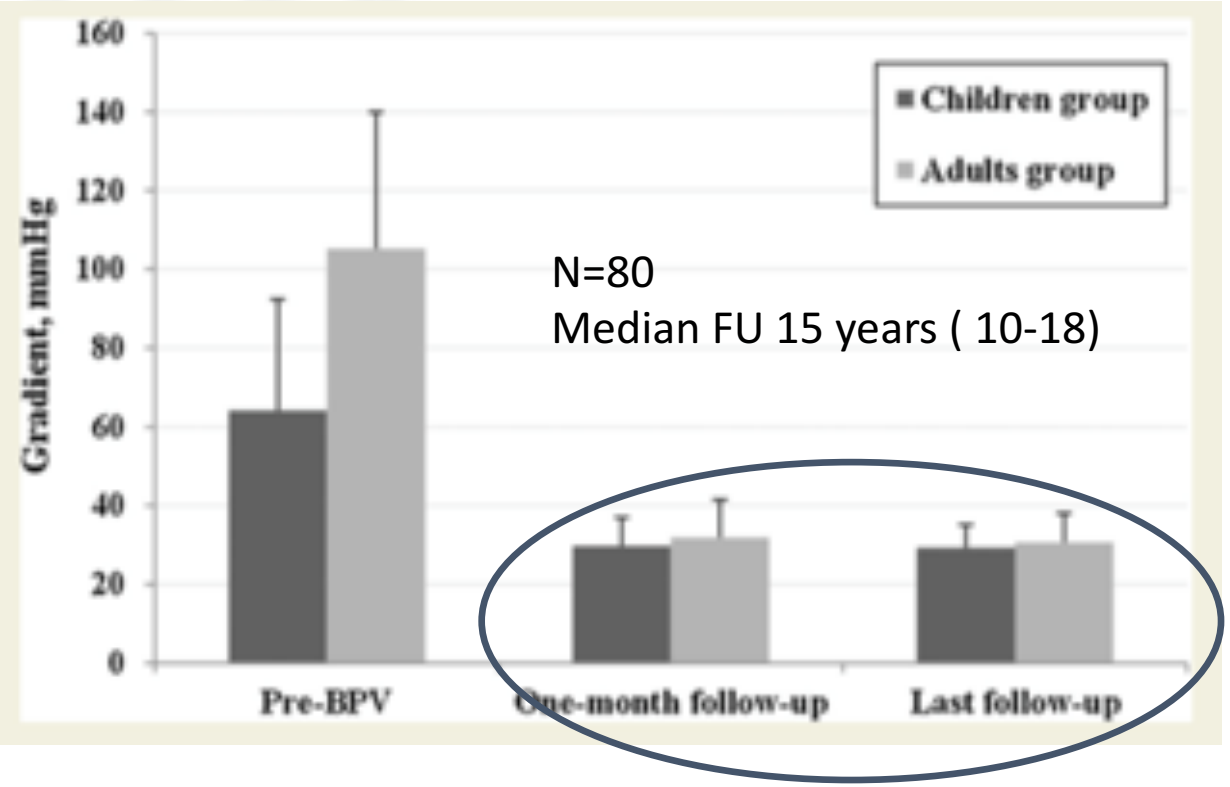

N=80
Median FU 15 years (10-18)

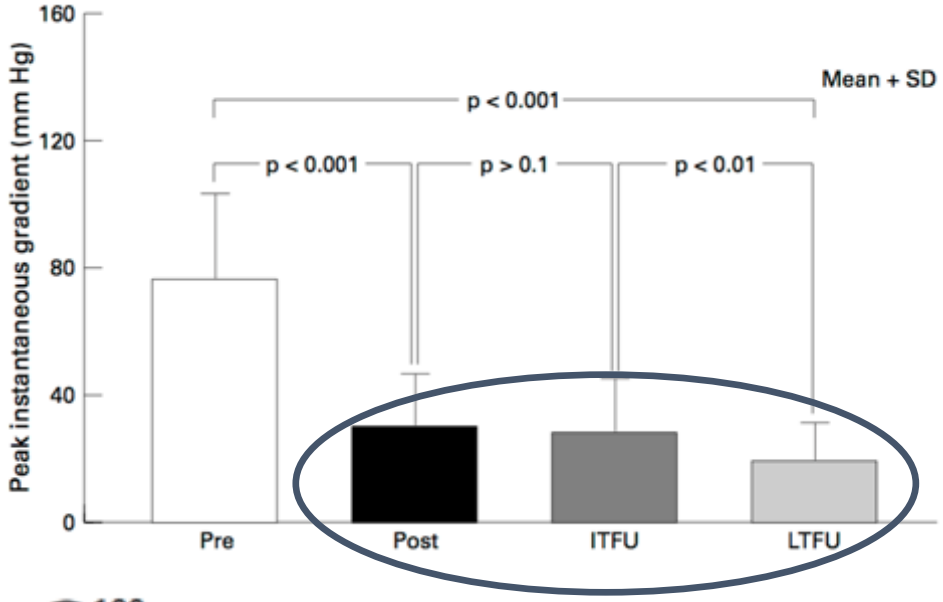

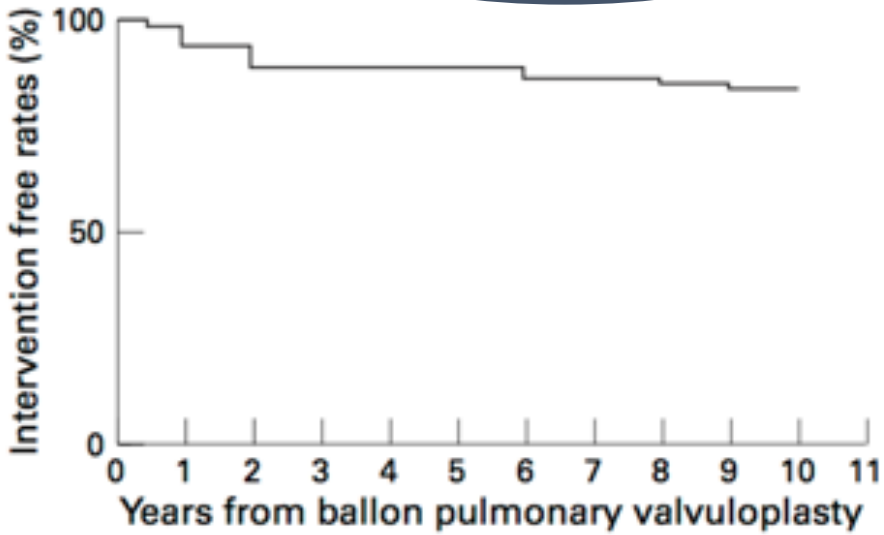

Liu et al. Heart and Lung Circulation 2015

Rao et al. Heart 1998

OBSTACLE VALVULAIRE

Réinterventions

139 KT vs 79 chir, Suivi médian 6 ans et 22 ans

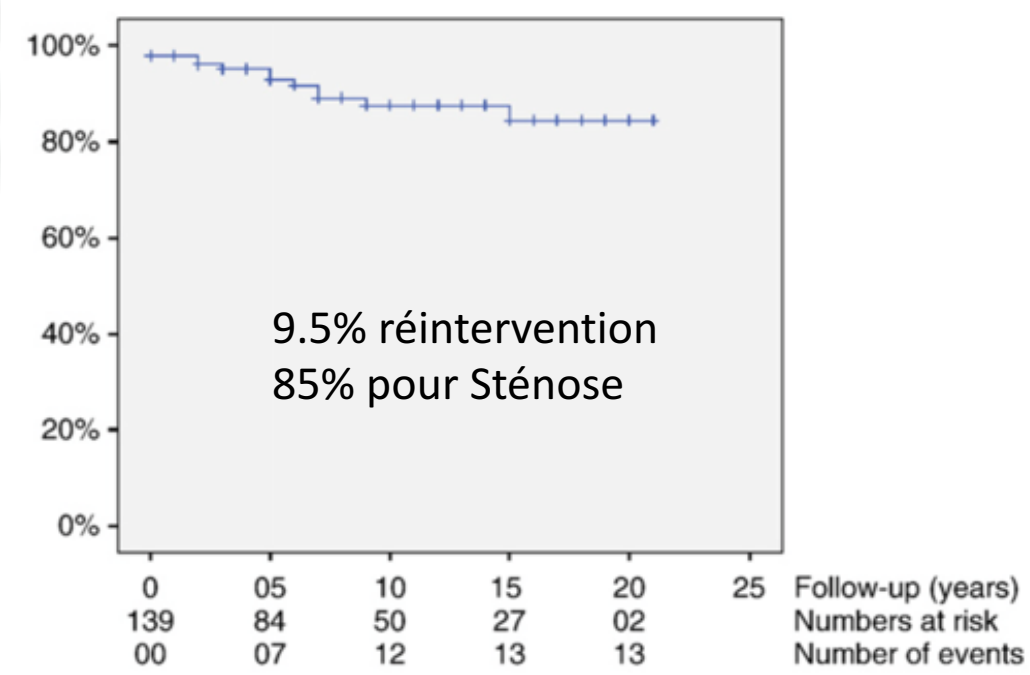

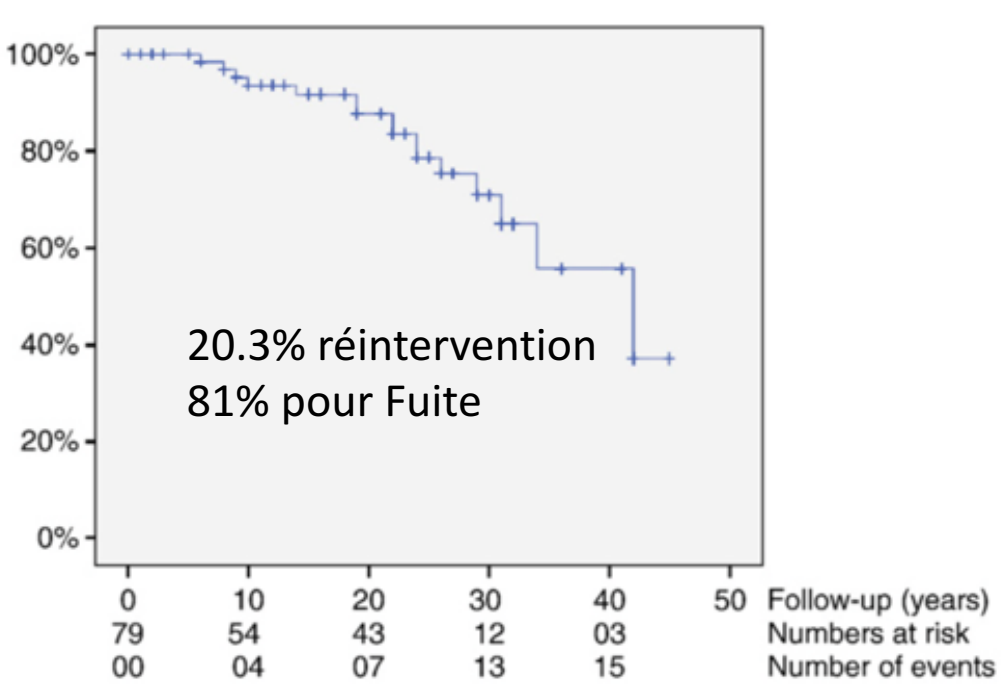

Voet et al. Int J Cardiol 2012

OBSTACLE VALVULAIRE

SIÈGE DE L'OBSTACLE

VALVE
Dilatation
Perforation

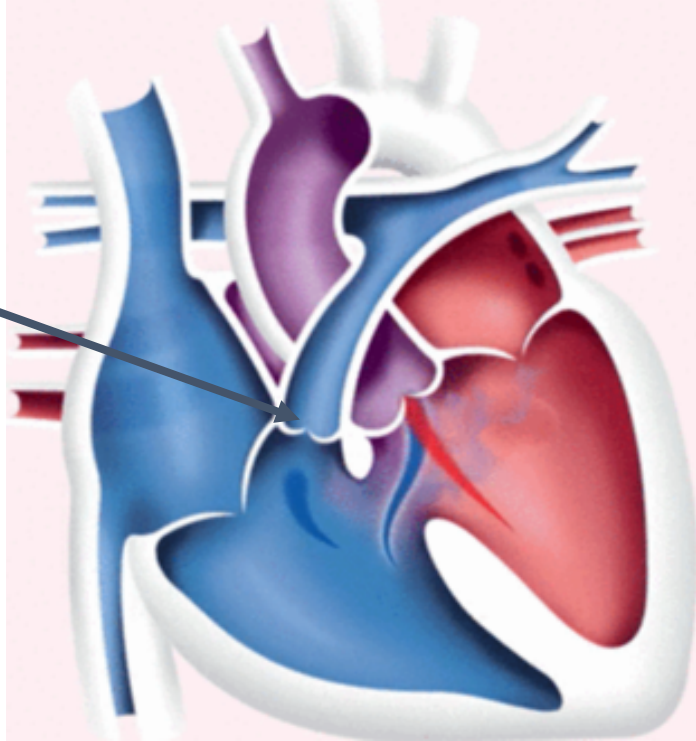

STÉNOSE PULMONAIRE CRITIQUE vs ATRÉSIE PULMONAIRE À SEPTUM INTACT

OBSTACLE VALVULAIRE

Class IIa

1. **It is reasonable to perform pulmonary valvuloplasty on a patient with valvar pulmonic stenosis who meets the above criteria in the setting of a dysplastic pulmonary valve *(Level of Evidence: C)*.**
2. **It is reasonable to perform pulmonary valvuloplasty in newborns with pulmonary valve atresia and intact ventricular septum who have favorable anatomy that includes the exclusion of RV-dependent coronary circulation *(Level of Evidence: C)*.**

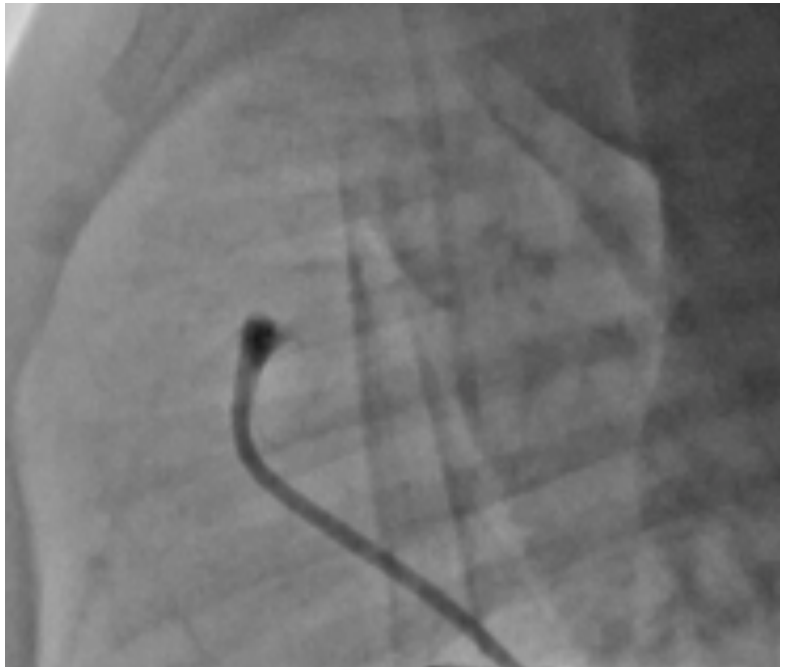

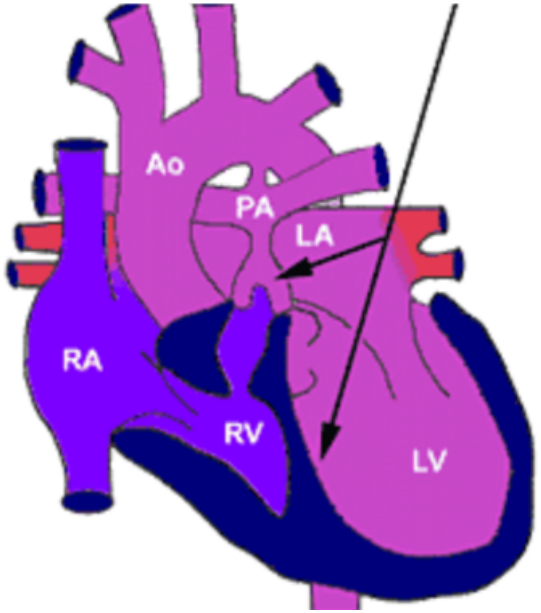

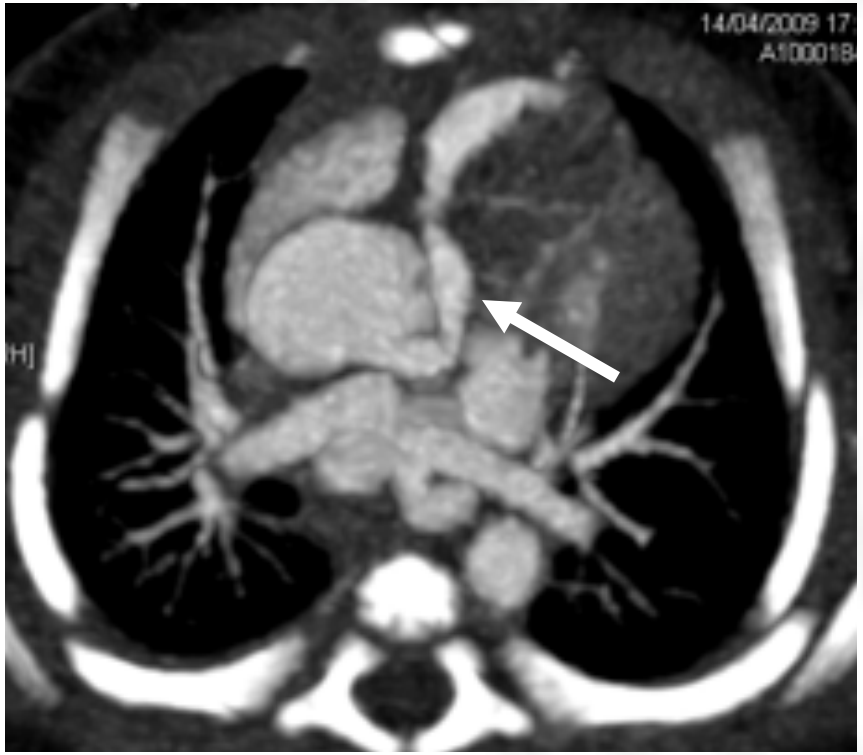

ATRÉSIE PULMONAIRE À SEPTUM INTACT

OBSTACLE VALVULAIRE

PERFORATION PAR RADIOFRÉQUENCE

- Double abord vasculaire:
  - VF-OD-VD-Plancher Valvulaire atrétique,
  - AF-AO-Canal-Plancher Valvulaire atrétique
- Guide de Radiofréquence => 1 impulsion
- Dilatation séquentielles par ballonnets de diamètre croissant
- +/- Stenting du canal artériel lors de la même procédure

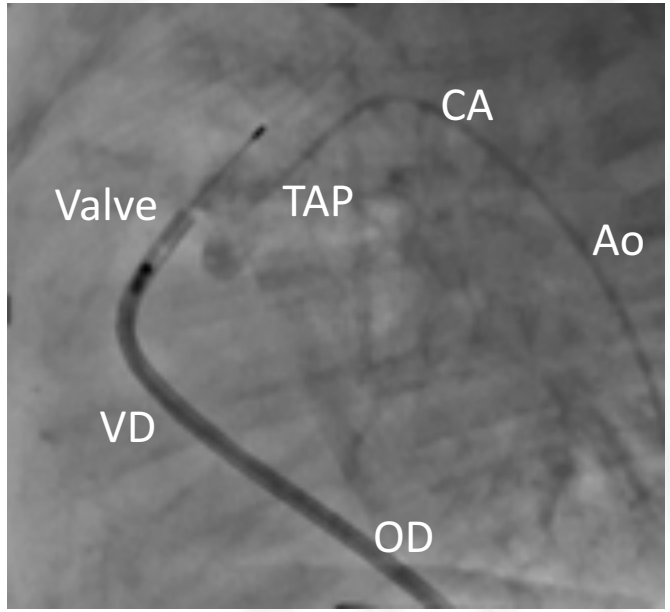

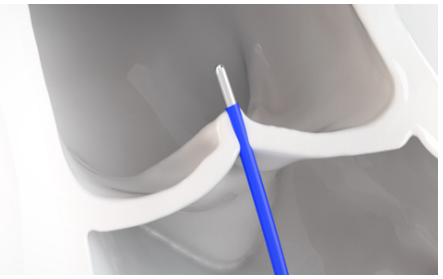

CAS CLINIQUE

- ASPI Avec VD tripartite, DAN
- PN=2.8kg, Sat=90% sous PGE1
- ETT:
  - Fuite tricuspide grade 2
  - Anneau = 9mm (Z-score -2)
  - Pas de sinusoïdes visualisées

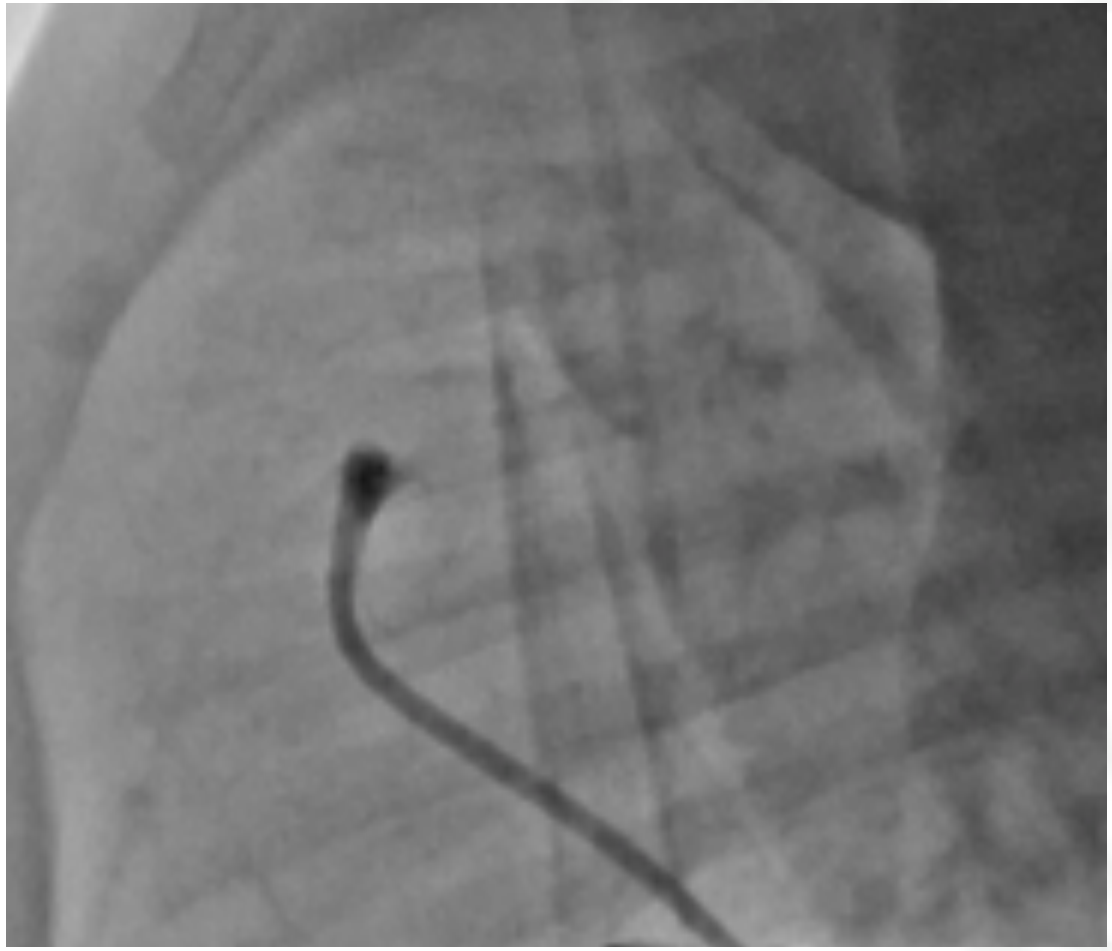

CAS CLINIQUE

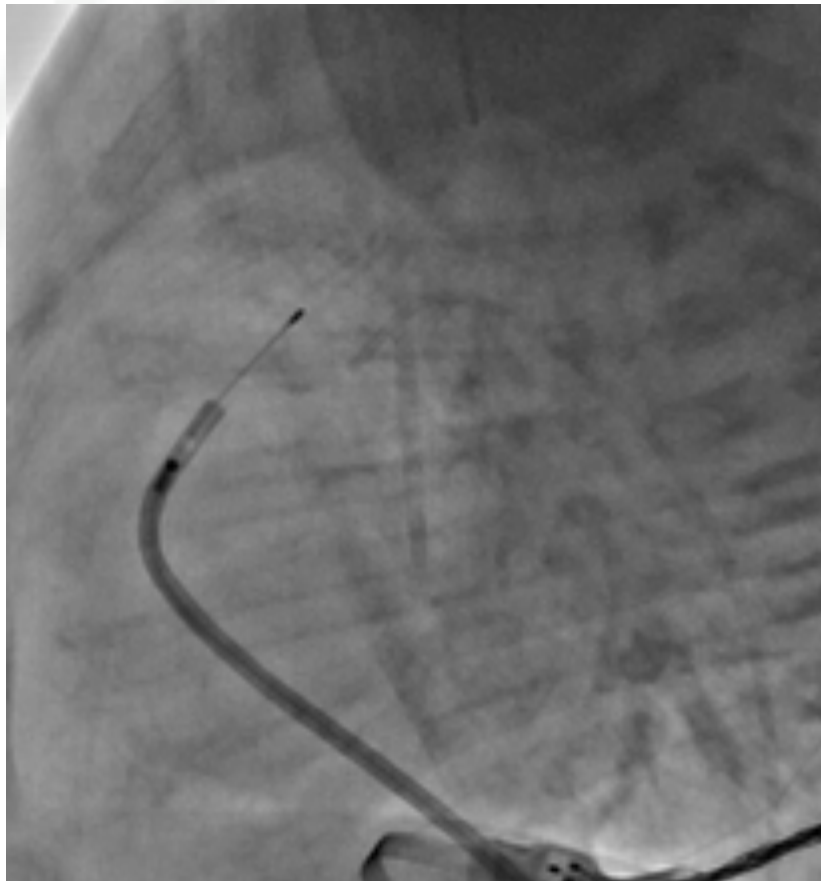

PERFORATION

CAS CLINIQUE

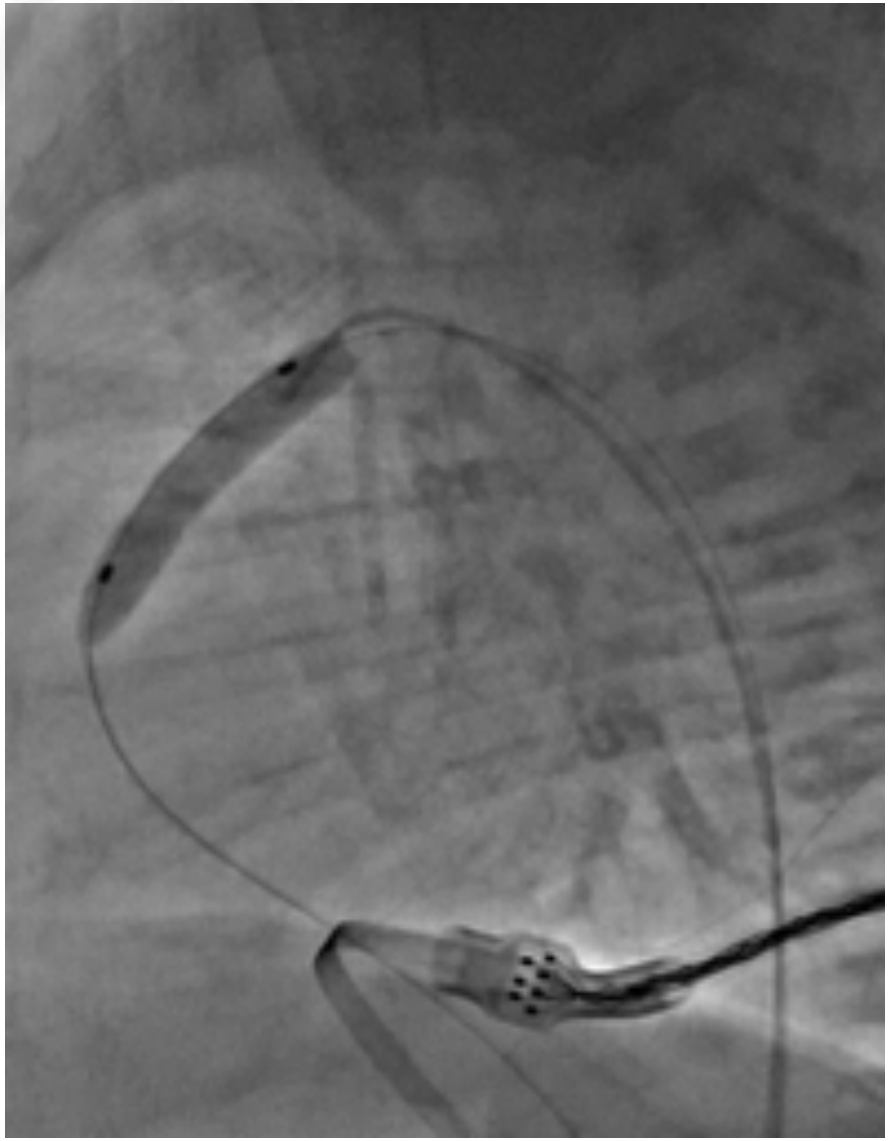

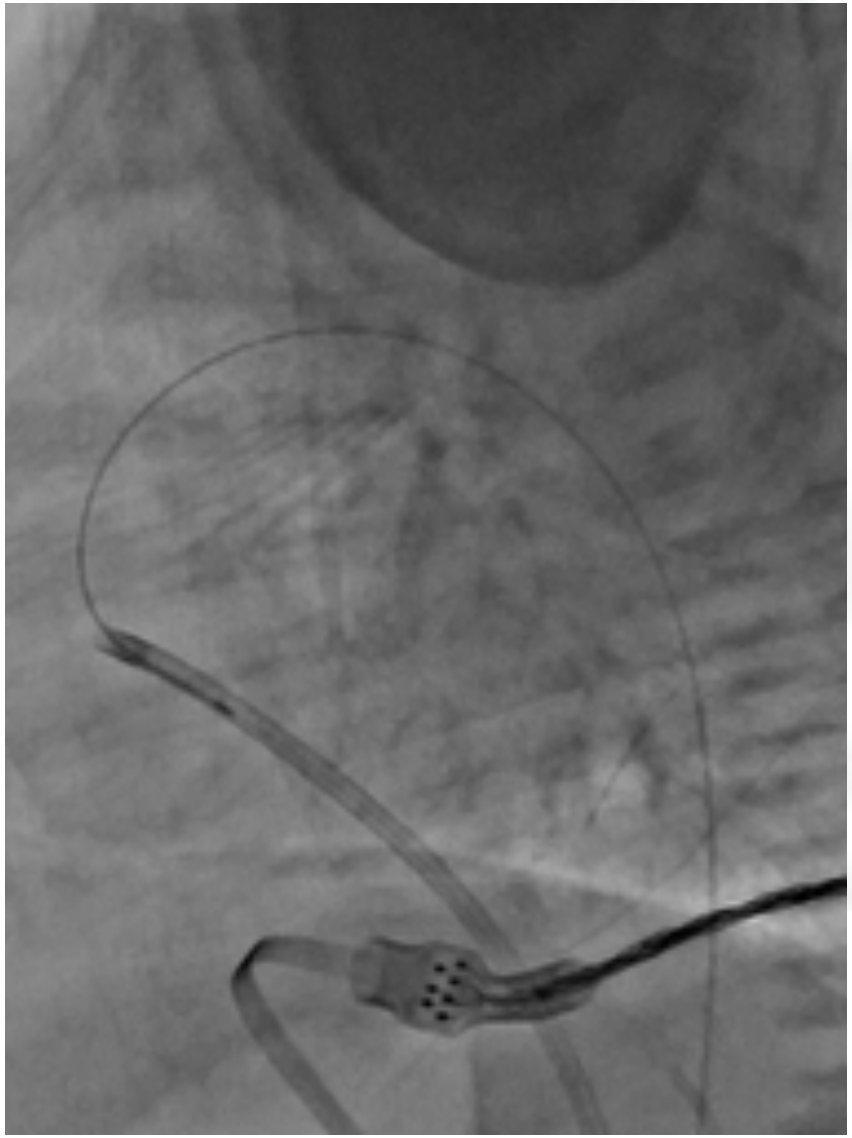

CAS CLINIQUE

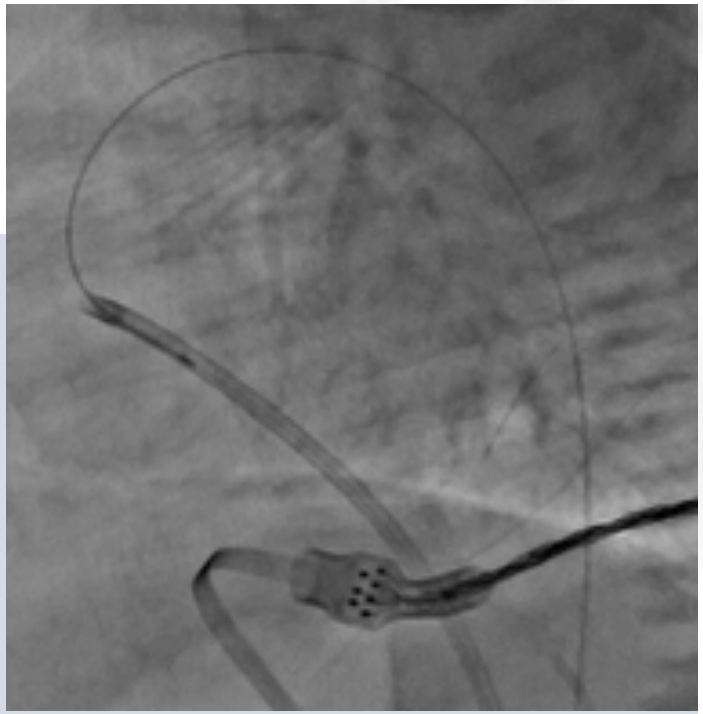

- Suites simples
- Sevrage PGE1 à J5
- Sortie à J15, Sat=90%
- Procédure de dilatation pulmonaire à M6 pour resténose
- Evolution favorable, circulation bi ventriculaire

PERFORATION APSI - RESULTATS

Outcomes of Transcatheter Approach for Initial Treatment of Pulmonary Atresia with Intact Ventricular Septum

Transcatheter pulmonary valvuloplasty in neonates with pulmonary atresia and intact ventricular septum

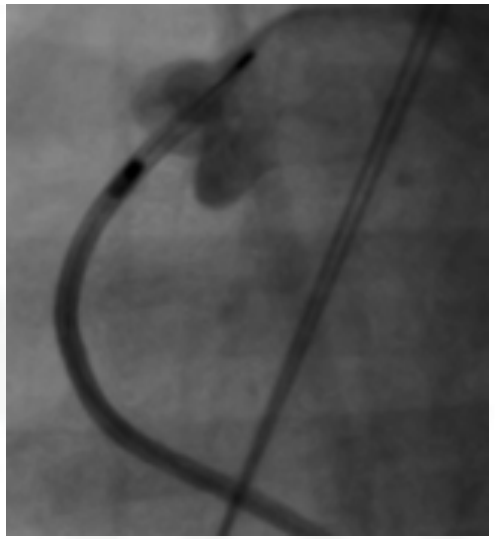

- Séries modestes: n=26 à 29 patients
- 79 à 87% de succès
- Complications :
  - 0 à 24% de mortalité péri-interventionnelle
  - 17 à 25% de complications (perforation infundibulum, perforation TAP, tamponnade)

Hasan et al.CCI 2013
Hascoet et al. ACVD 2019

PERFORATION APSI - RESULTATS

Outcomes of Transcatheter Approach for Initial Treatment of Pulmonary Atresia with Intact Ventricular Septum

Transcatheter pulmonary valvuloplasty in neonates with pulmonary atresia and intact ventricular septum

- Nécessité d'une chirurgie malgré succès de perforation: 23 à 62%
- Facteur pronostic: Z- score de l'anneau tricusupide
- Circulation biventriculaire finale: 81 à 91%
- Données encore peu nombreuses et disparates

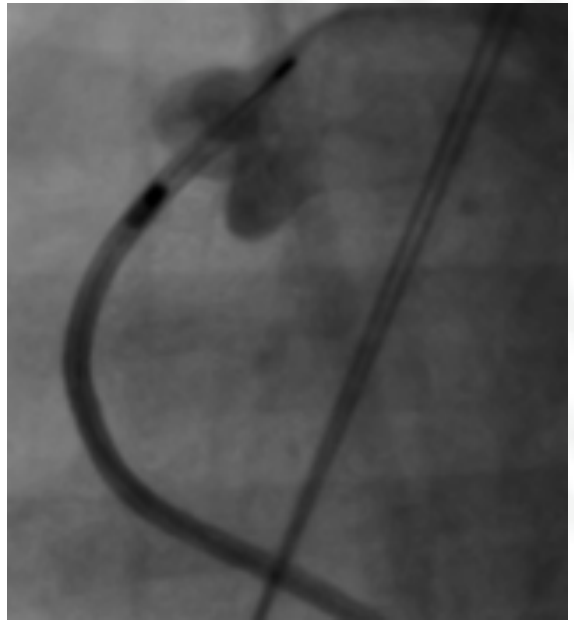

Hasan et al.CCI 2013
Hascoet et al. ACVD 2019

SHUNT

SIÈGE DE L'OBSTACLE

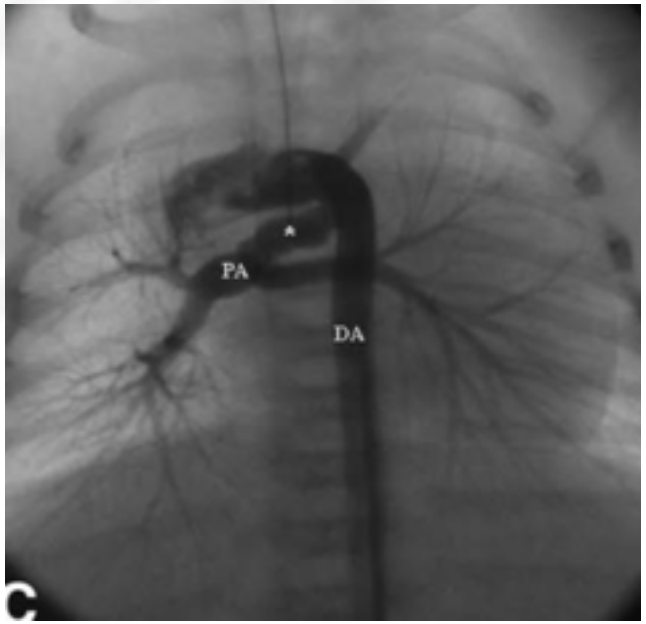

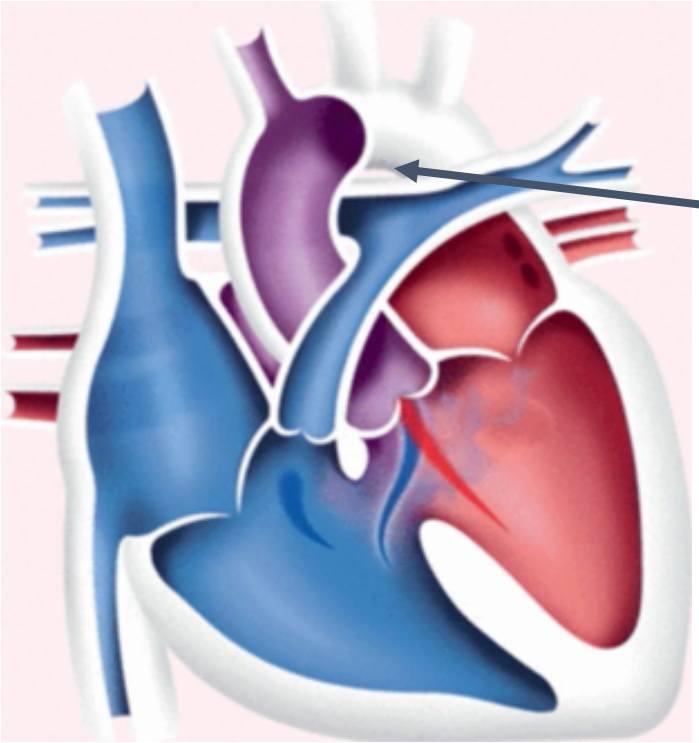

SHUNT
Stenting Canal Artériel

STENTING DU CANAL ARTÉRIEL

Recommendations for PDA Stenting for the Purpose of Augmenting Pulmonary Blood Flow

Class IIa

1. It is reasonable to stent an anatomically suitable ductus arteriosus in an infant with cyanotic CHD who has >1 source of pulmonary blood flow (eg, antegrade pulmonary blood flow or collateral blood flow) but who requires additional pulmonary blood flow from the stented ductus for a relatively short period of time (3 to 6 months) (*Level of Evidence: B*).

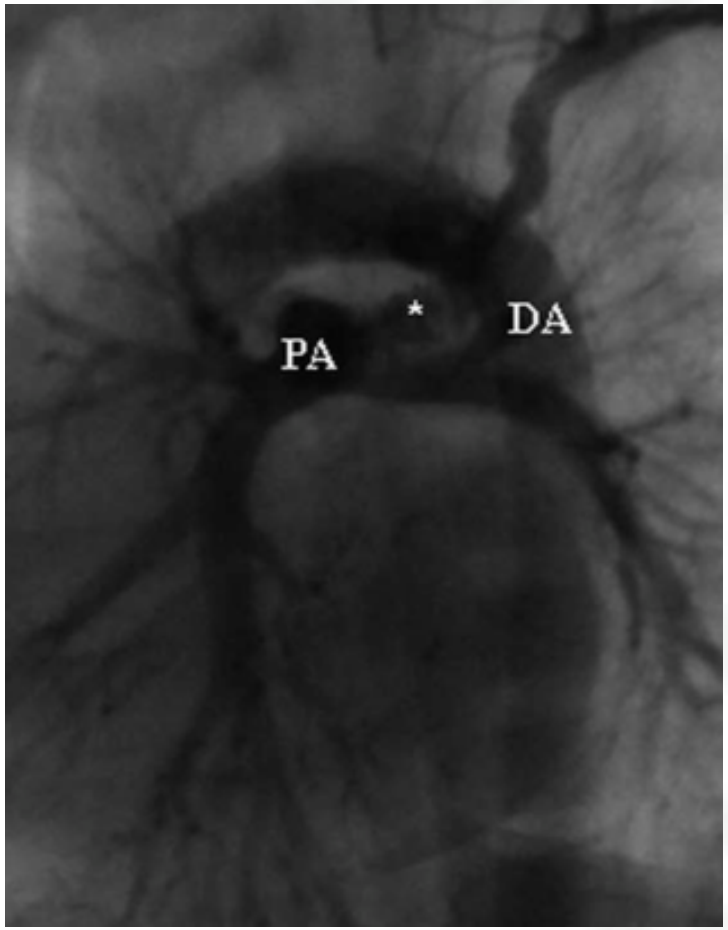

STENTING DU CANAL ARTÉRIEL

RATIONNEL

- Stratégie moins invasive
- Eviter complications liées au BTS
- Stent redilatable

LIMITES

- Anatomie du CA
- Autre source de flux pulmonaire?
- Mortalité comparable au BTS

STENTING DU CANAL ARTÉRIEL

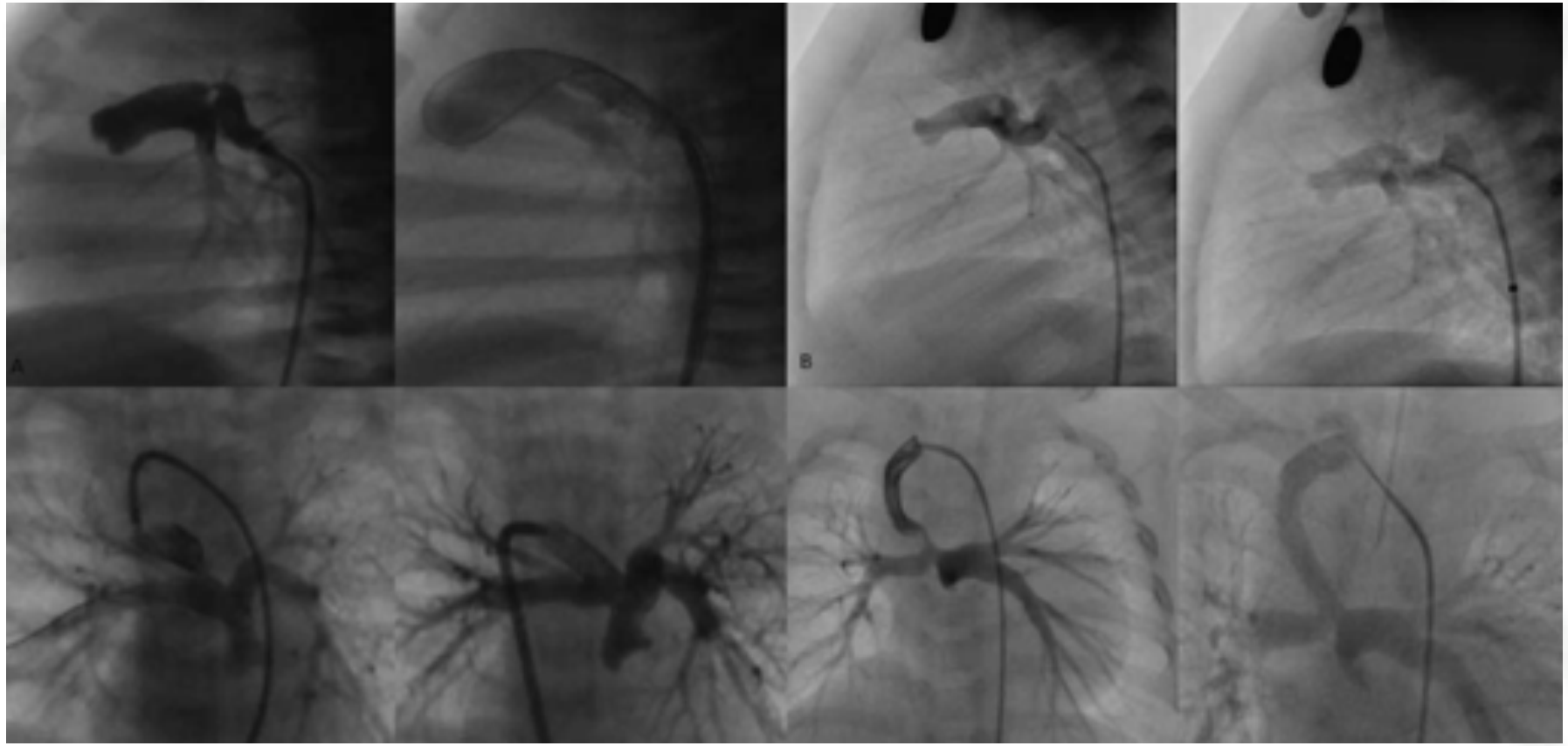

ANATOMIE DU CANAL ARTÉRIEL

SUCCÈS DE PROCÉDURE

VOIE D'ABORD

CAS CLINIQUE

Atrésie pulmonaire à septum intact avec VD unipartite, PN=2.2 kg, Sat sous PGE1=88%

Stenting à J15 de vie

Arrêt PGE1 6h avant procédure

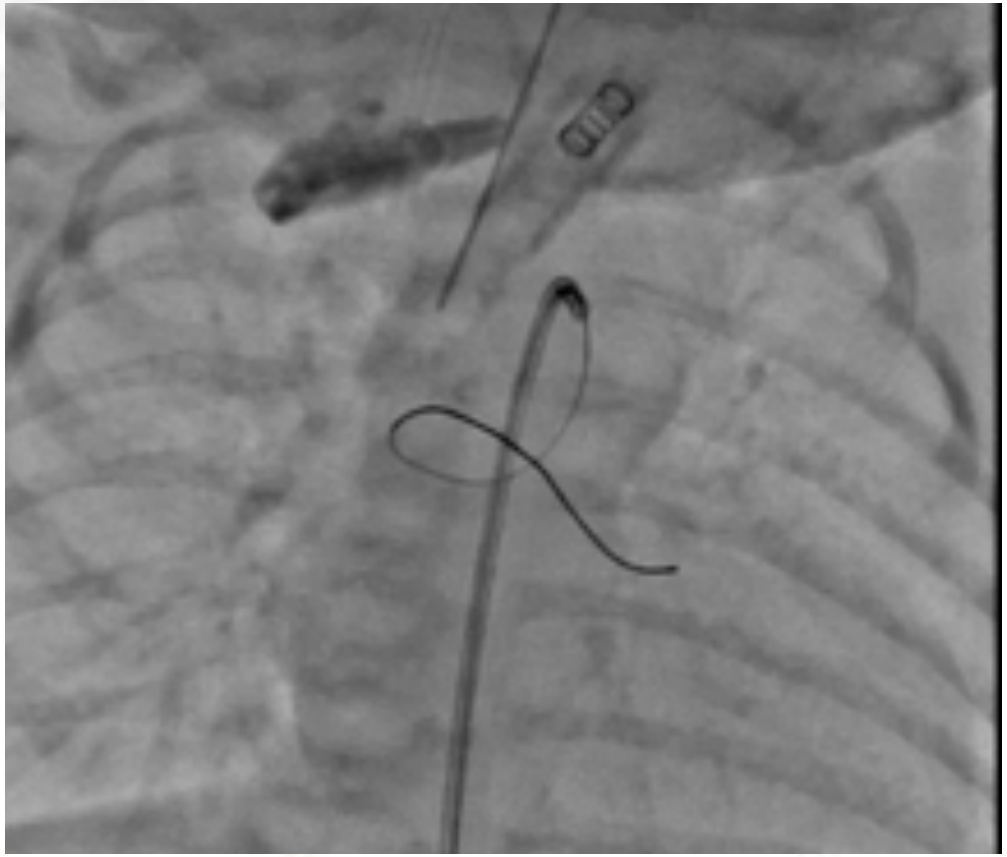

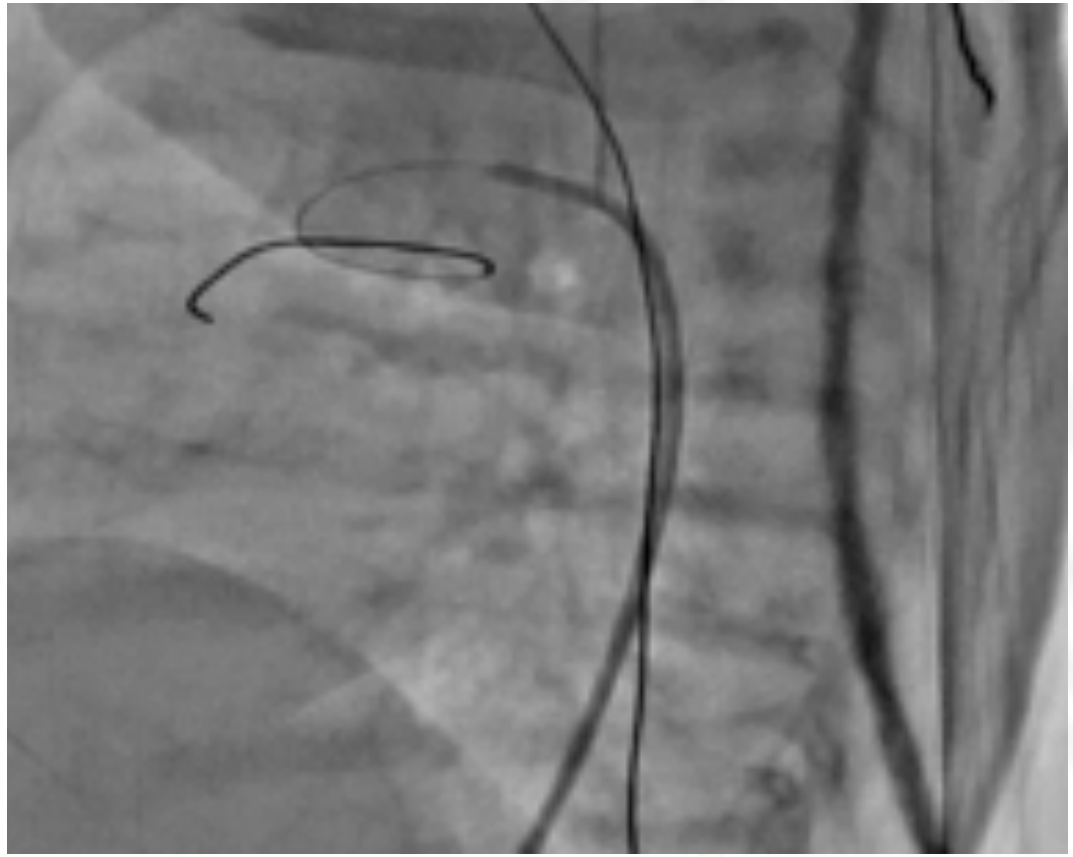

CAS CLINIQUE

Stent coronaire 3.5 x 16mm

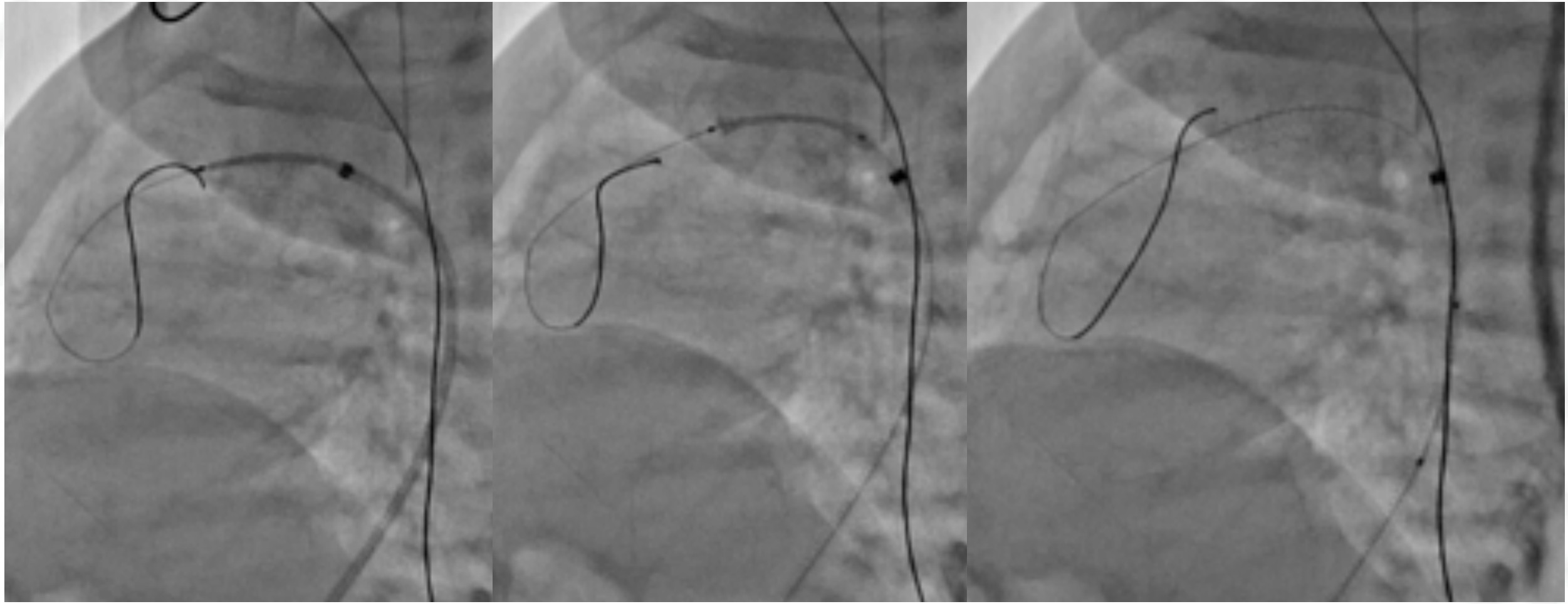

Sortie J7 sous Kardegic Plavix – Sat85-90%

CAS CLINIQUE

3 mois pot KT: épisodes de désaturations aigues à 60%

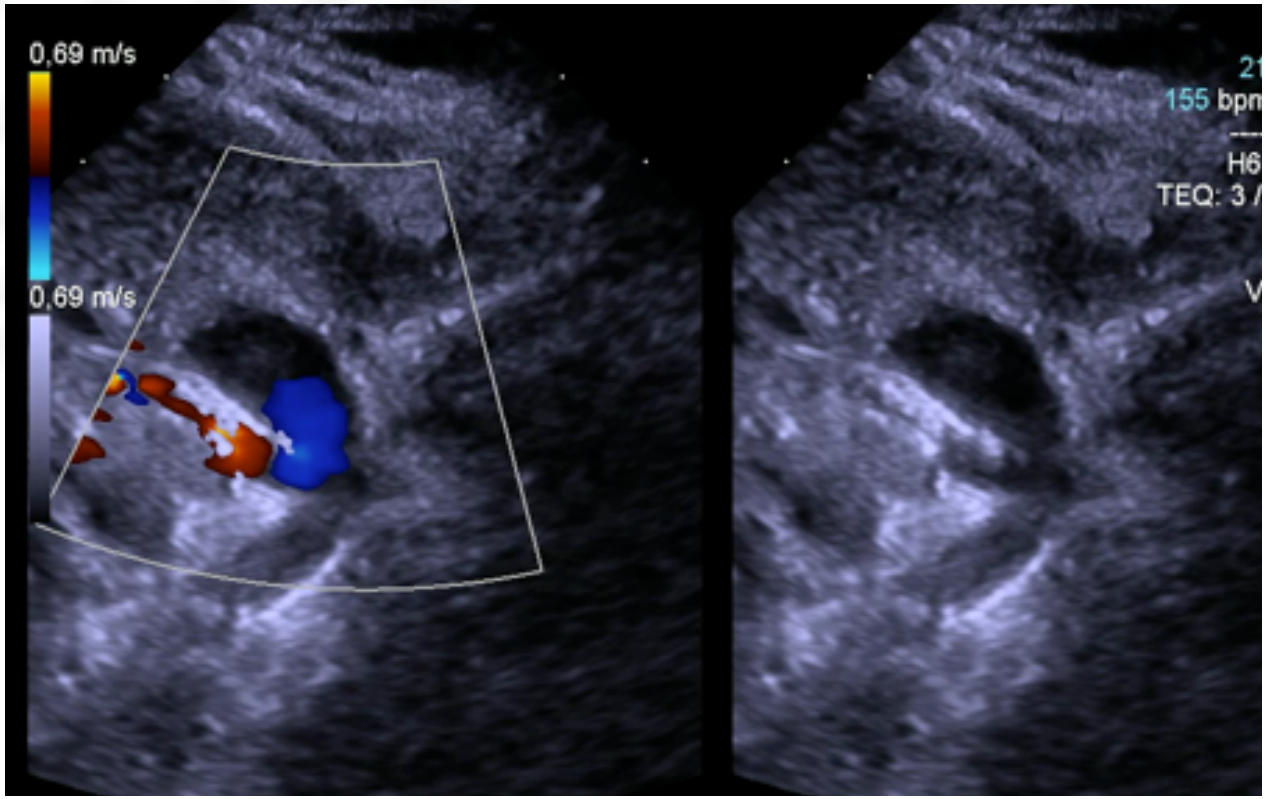

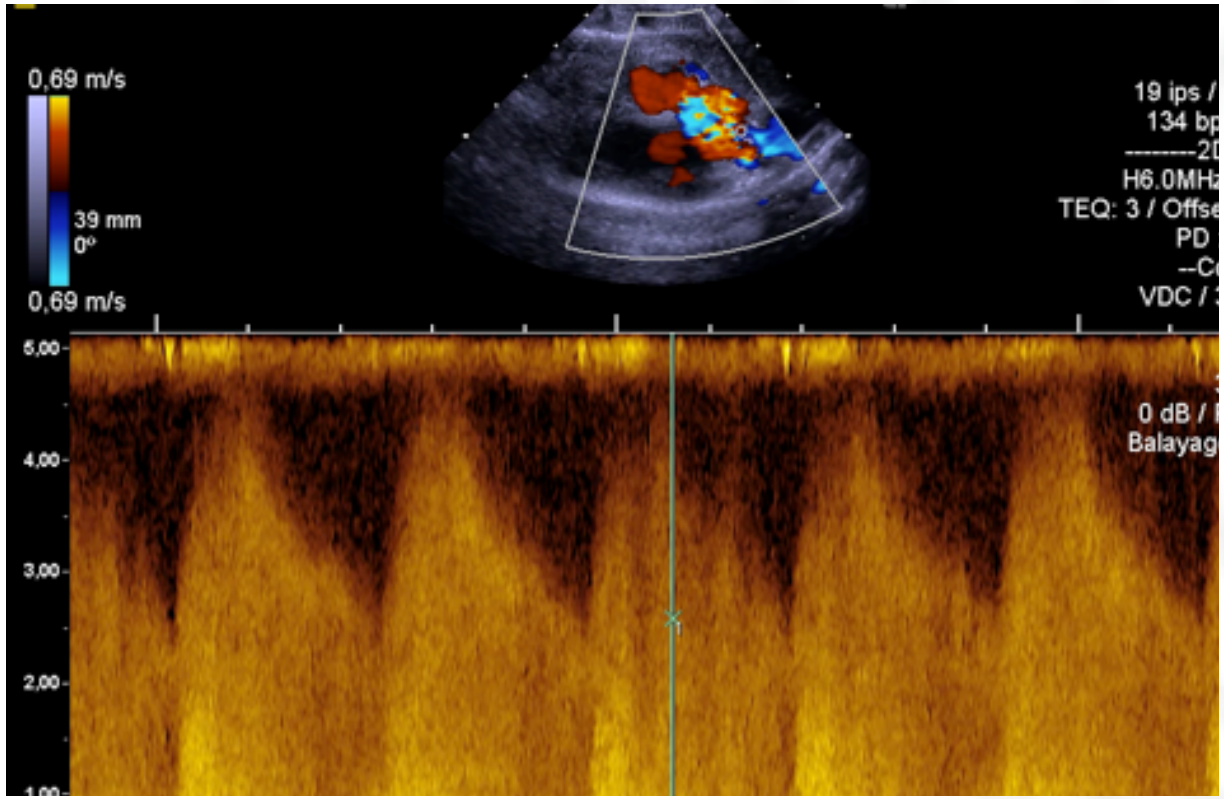

Sténose du canal sur l'abouchement aortique => Nouvelle procédure

CAS CLINIQUE

Mise en place d'un 2nd stent coronaire de 4x10-mm

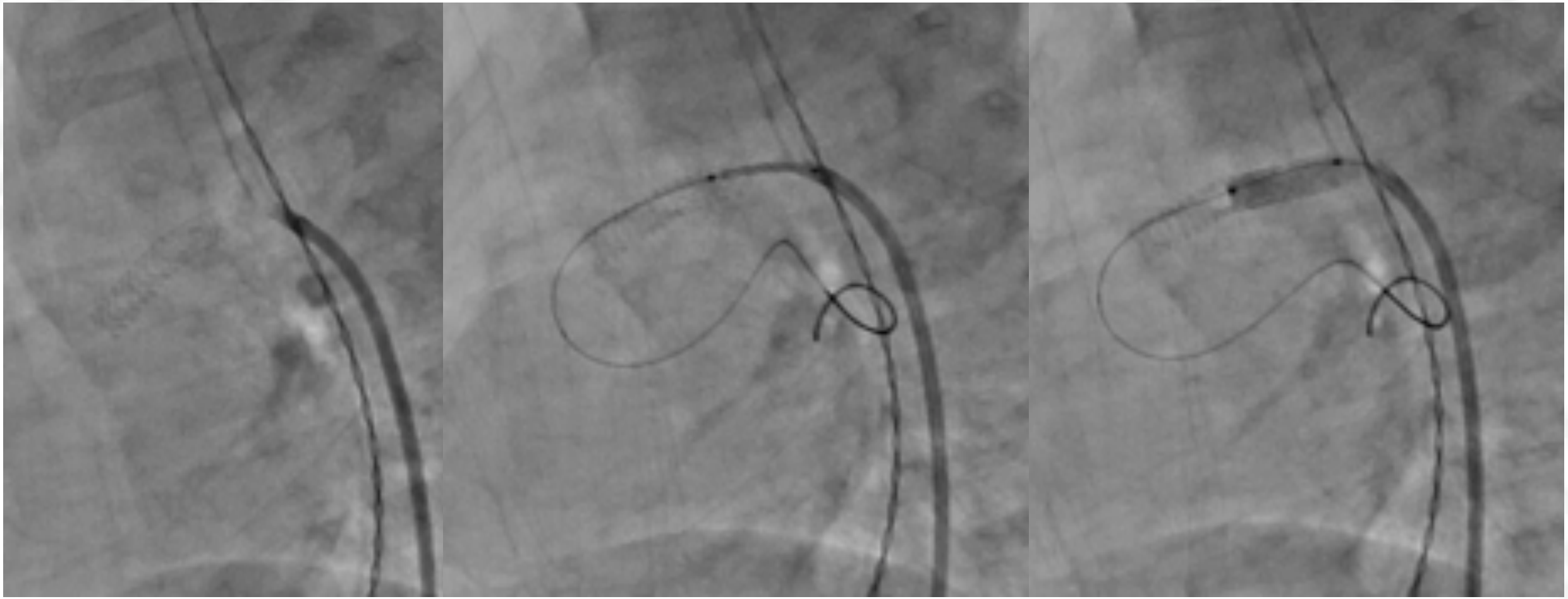

CAS CLINIQUE

DCPP à 10 mois de vie, pas de complication liée à la présence des stents
Suivi 6 mois post op: RAS

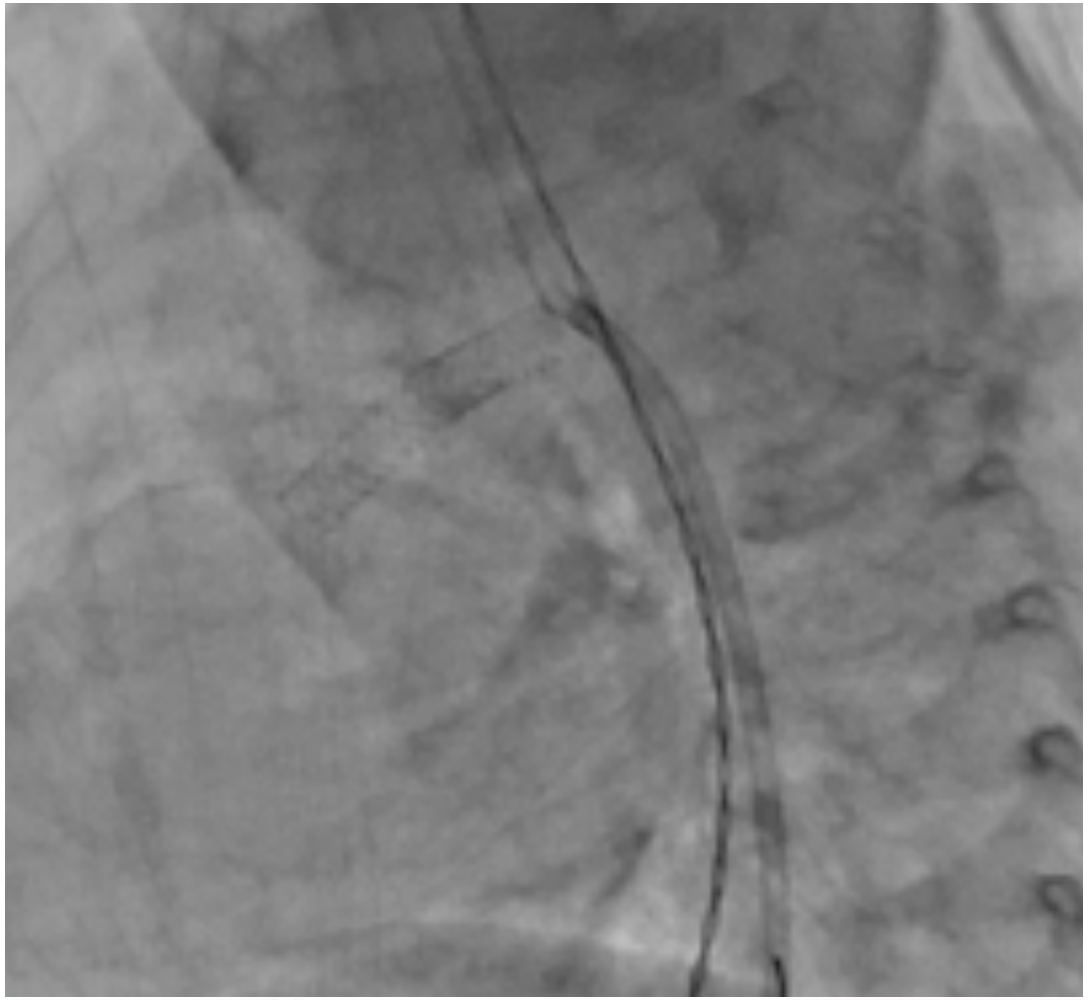

CAS CLINIQUE 2

Tétralogie de Fallot, DAN: Accouchement par voie basse, Poids=3kg, Sat=76%

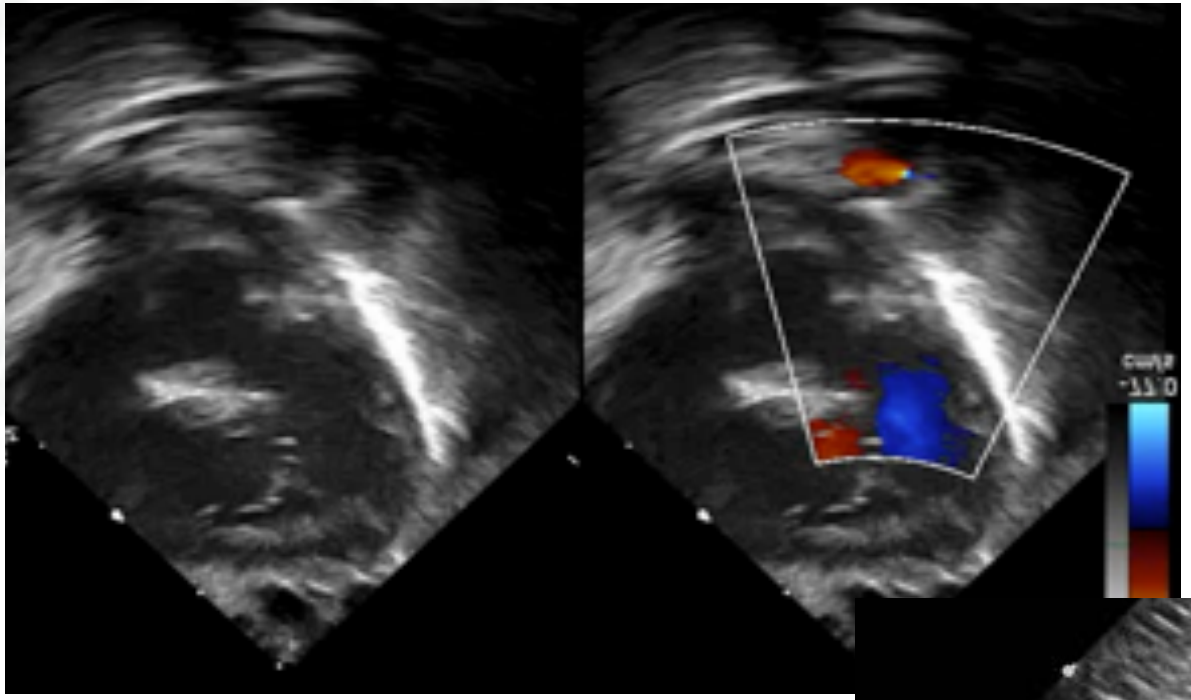

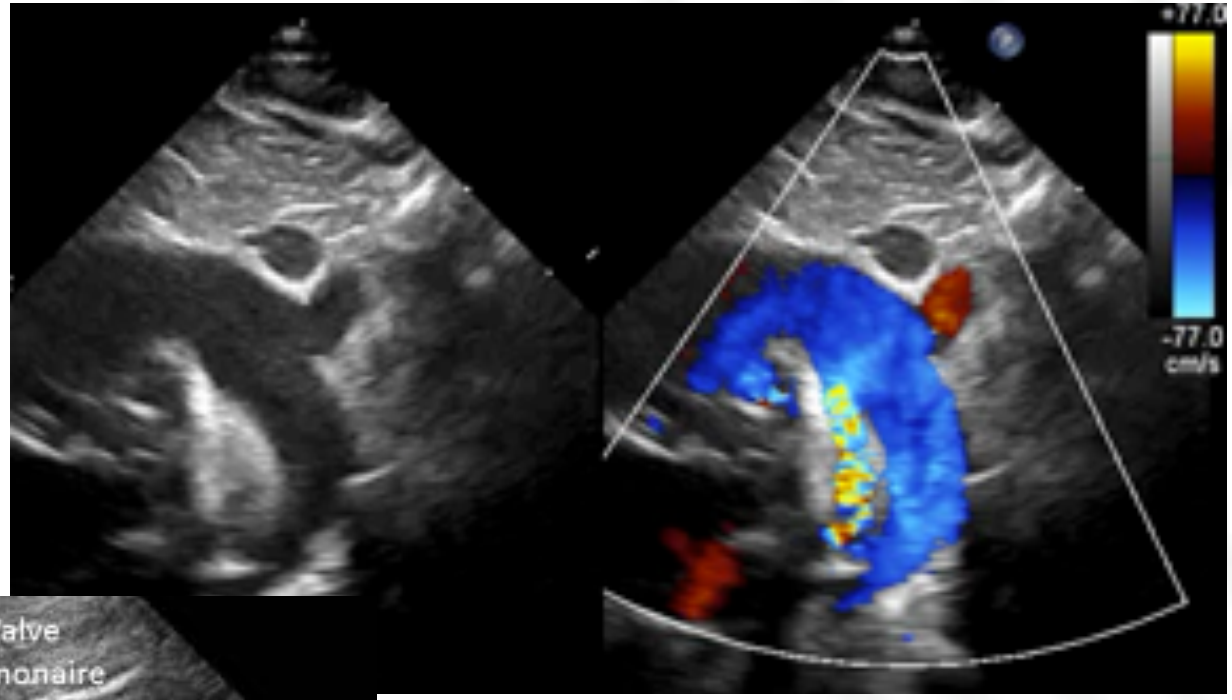

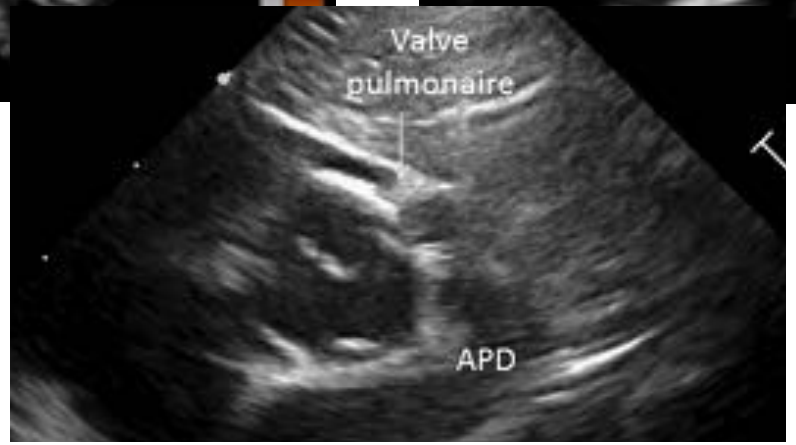

CAS CLINIQUE 2

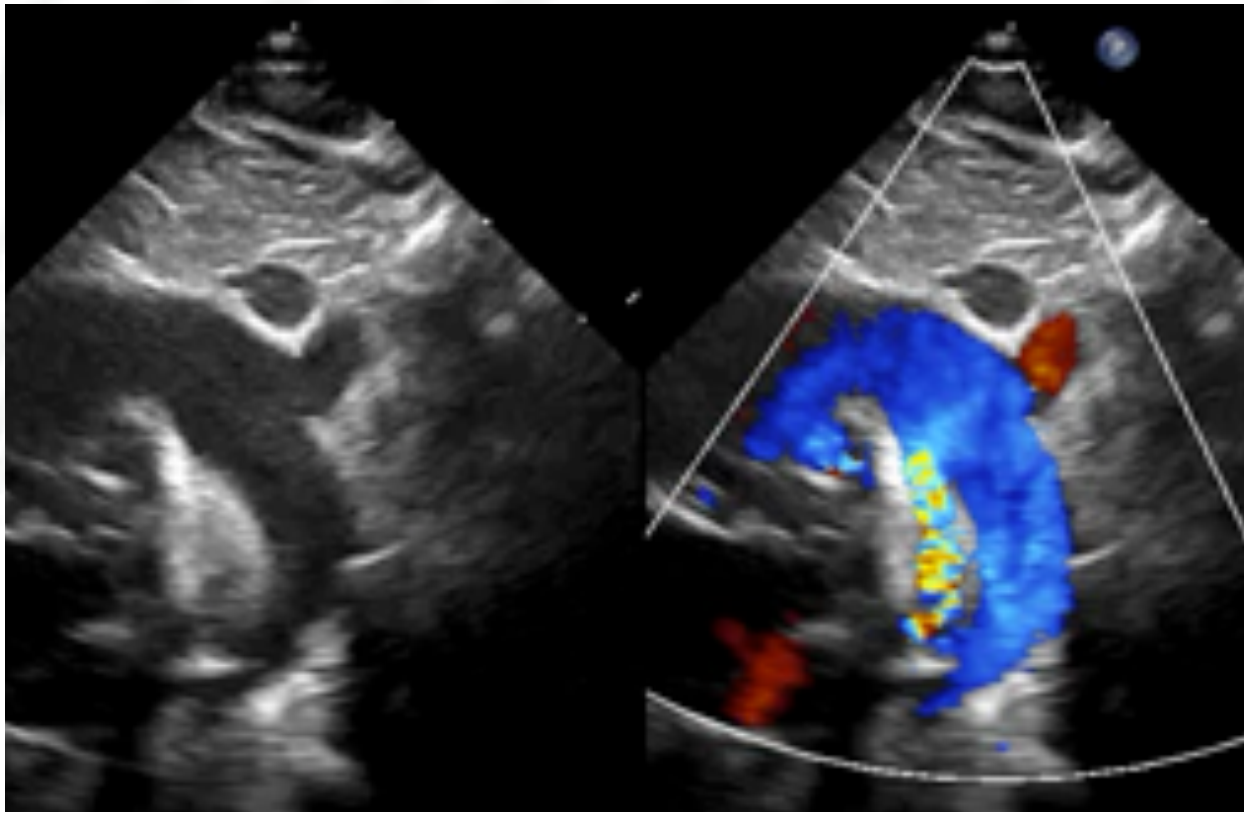

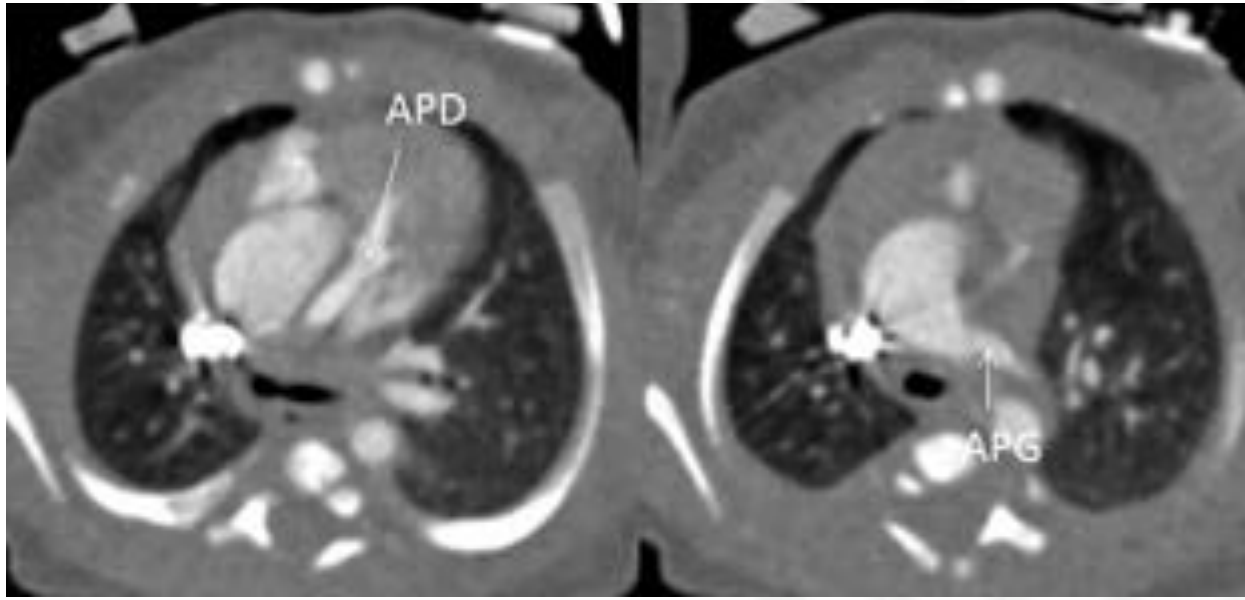

APG DÉCONNECTÉE NAISSANT DU CANAL ARTÉRIEL => DUCTO-DÉPENDANCE

STENTING CANAL ARTÉRIEL

CAS CLINIQUE 2

Naissance verticale du canal depuis la concavité de la crosse = > Abord Carotide Gauche

CAS CLINIQUE 2

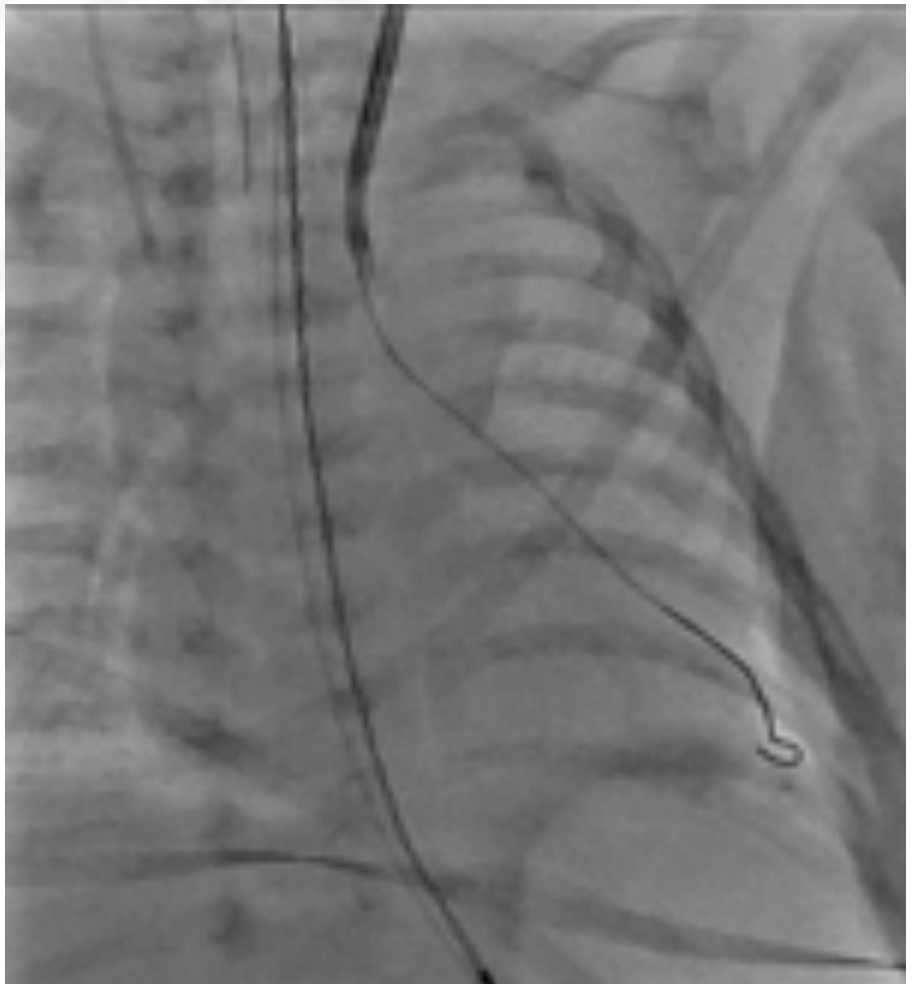

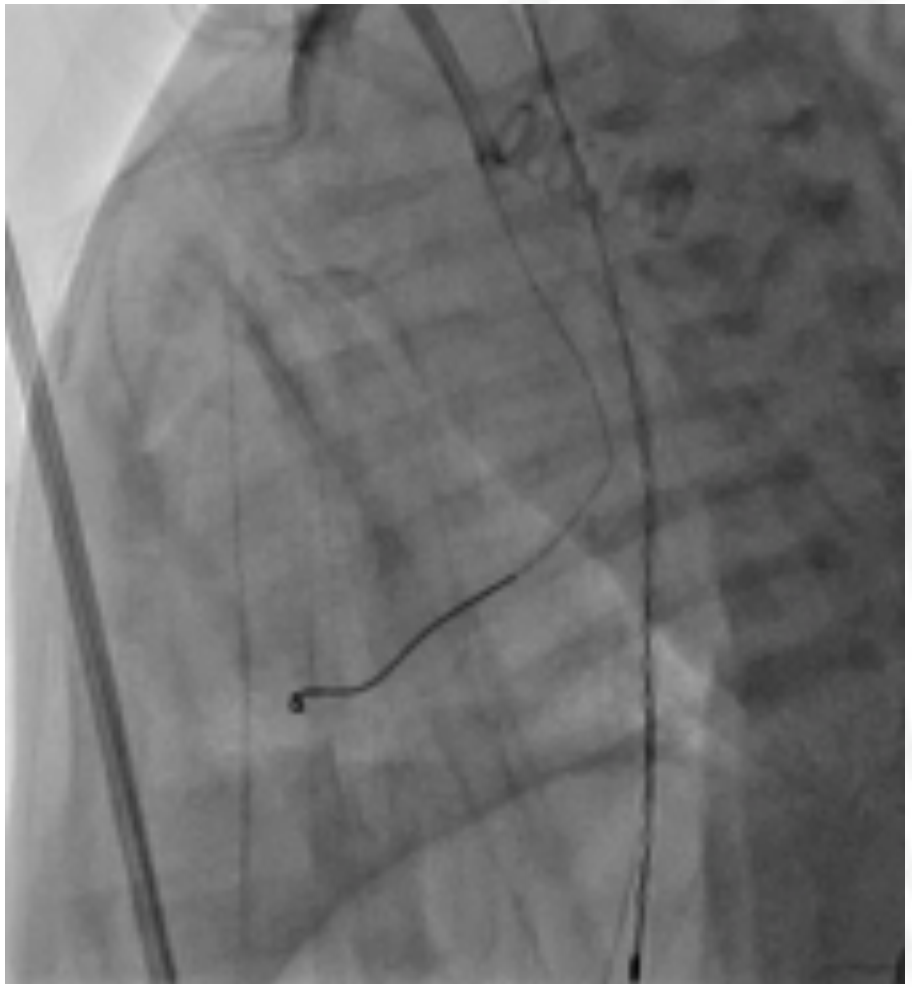

CAS CLINIQUE 2

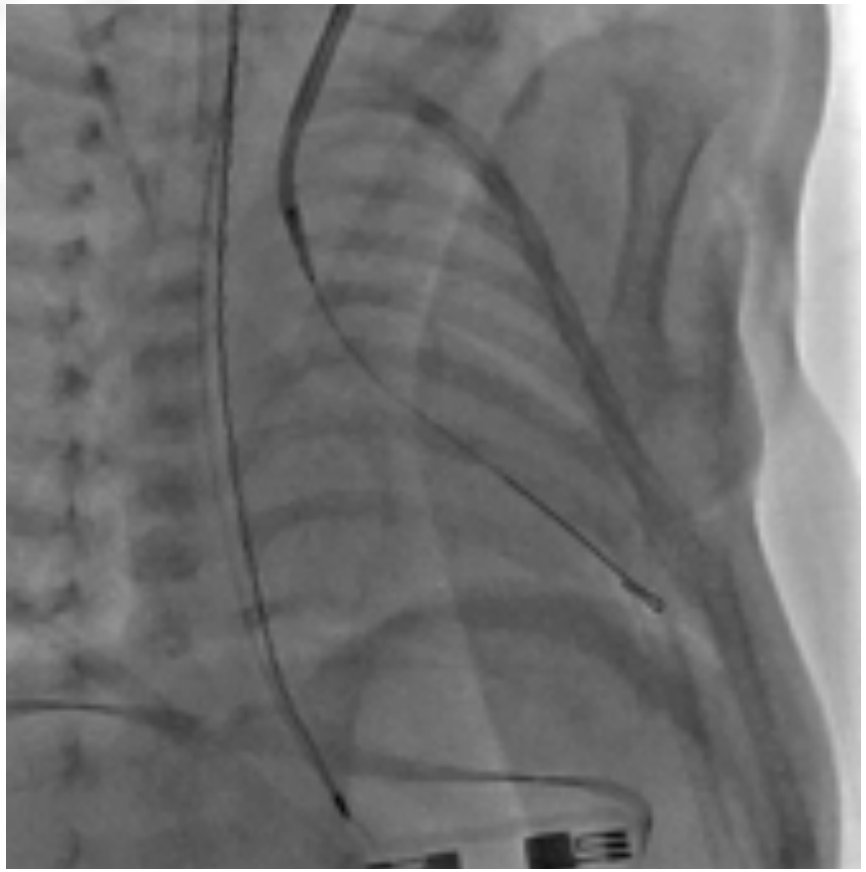

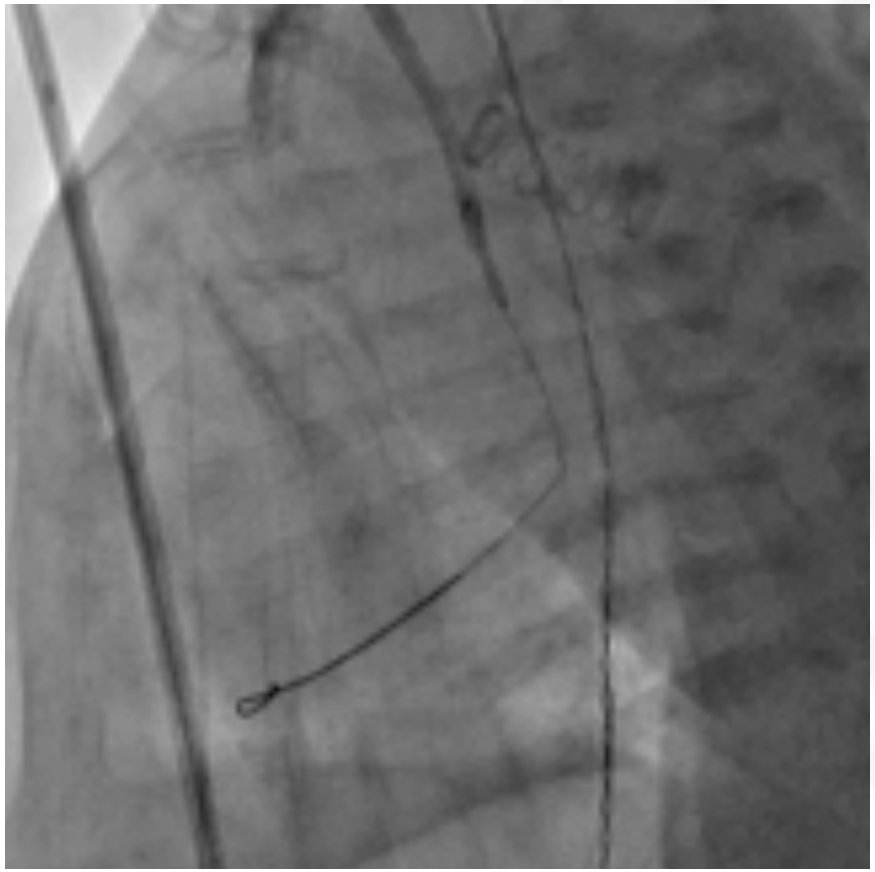

CAS CLINIQUE 2

Stent coronaire de 3.5 x 12-mm

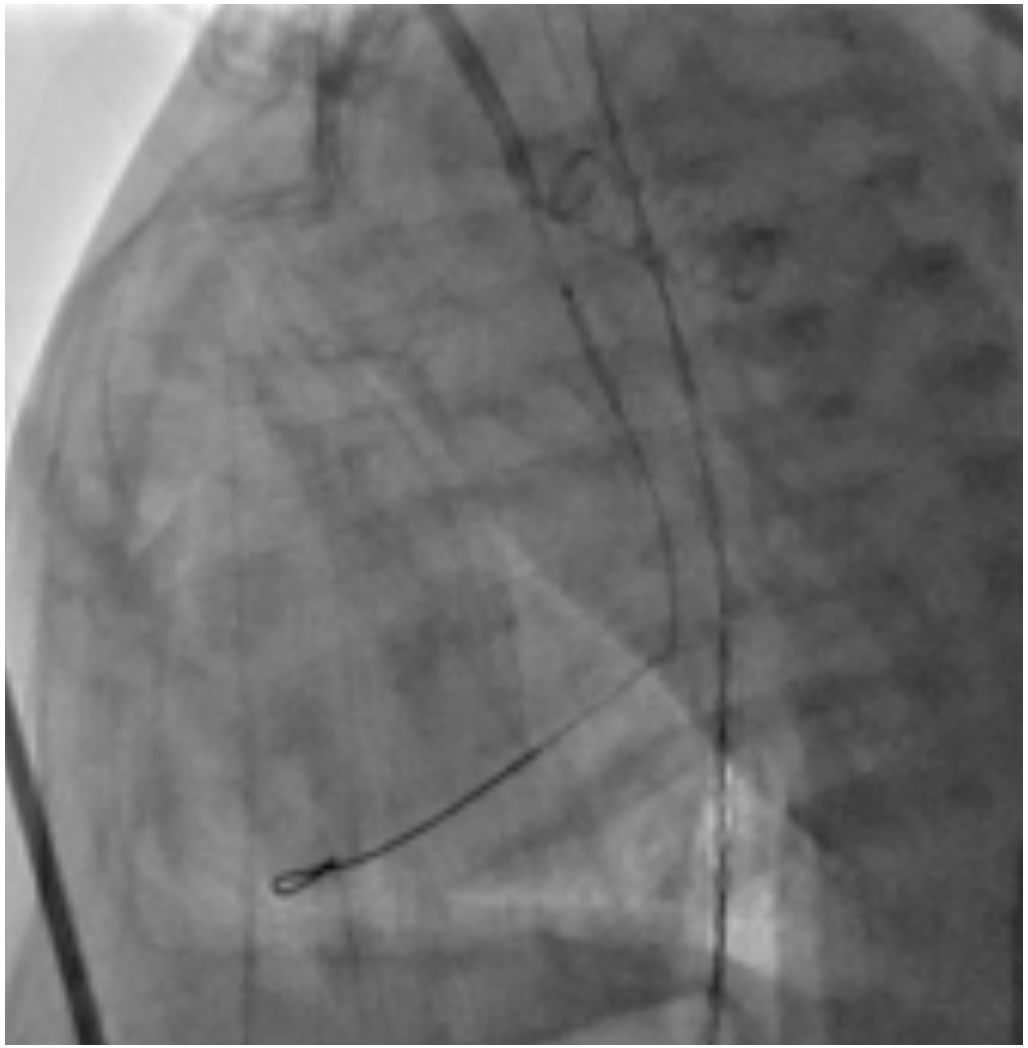

CAS CLINIQUE 2

RÉSULTAT POST-STENTING

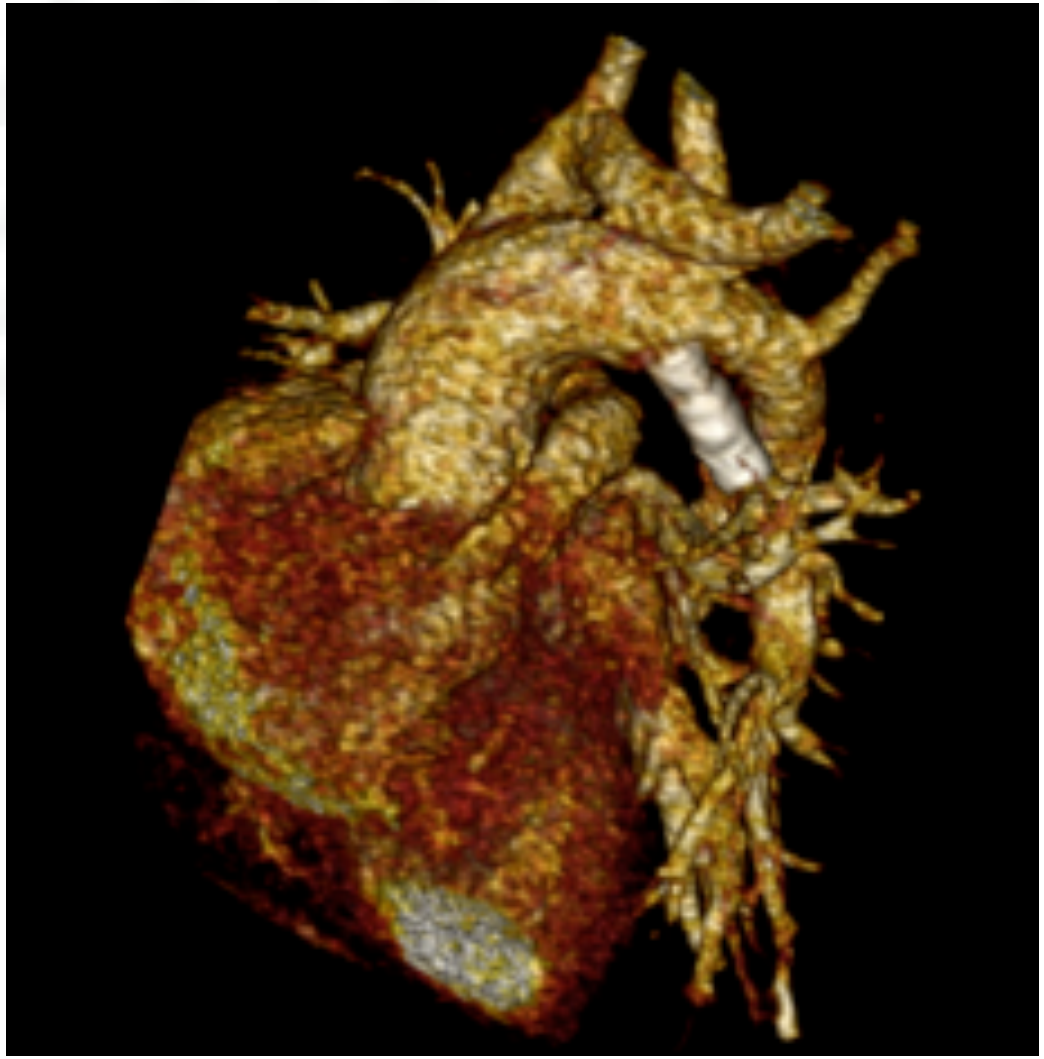

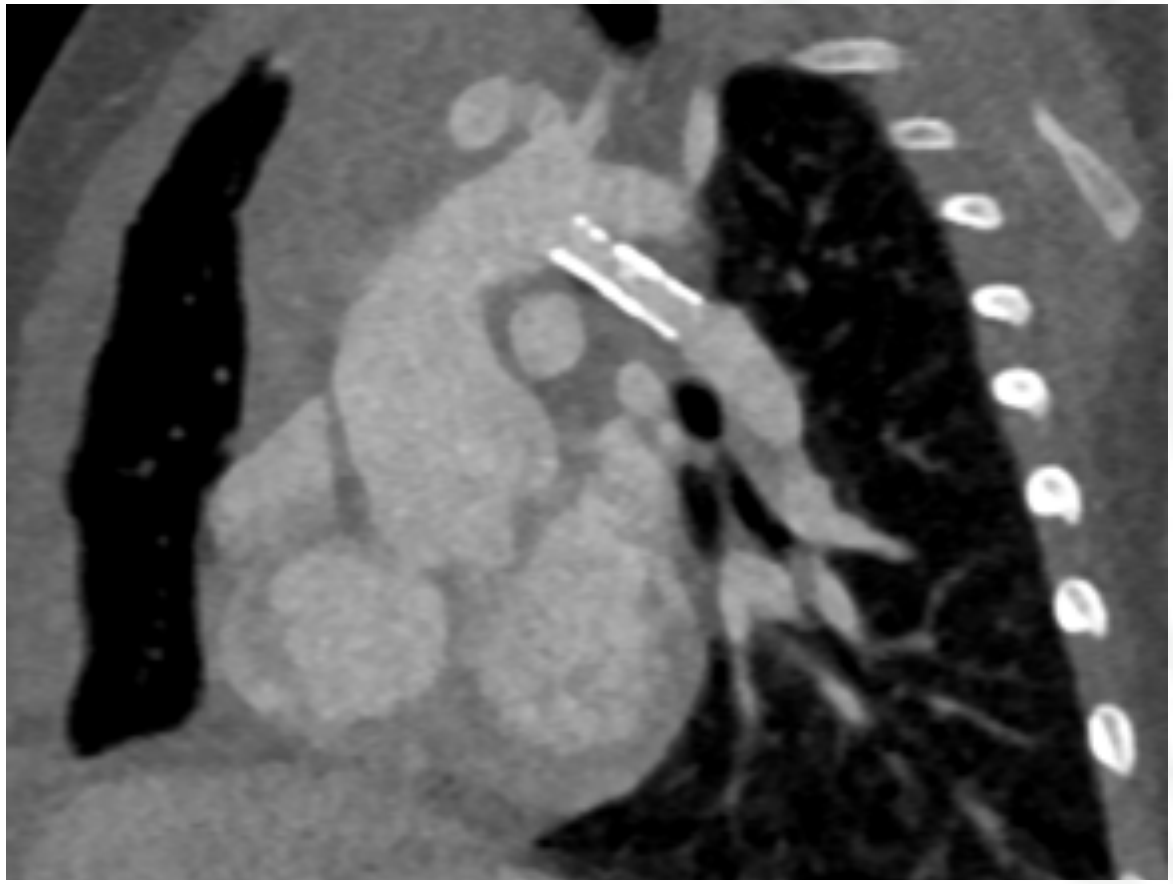

CAS CLINIQUE 2

- Signes d'hyperdébit contrôlés par diurétiques
- Chirurgie à 8 mois de vie (6.7 kg, Sat=80%)
- Cure complète avec fermeture CIV, plastie APG, Patch transannulaire + monocusp
- Suivi: 1 an post-opératoire: 7.5 kg, bonne évolution

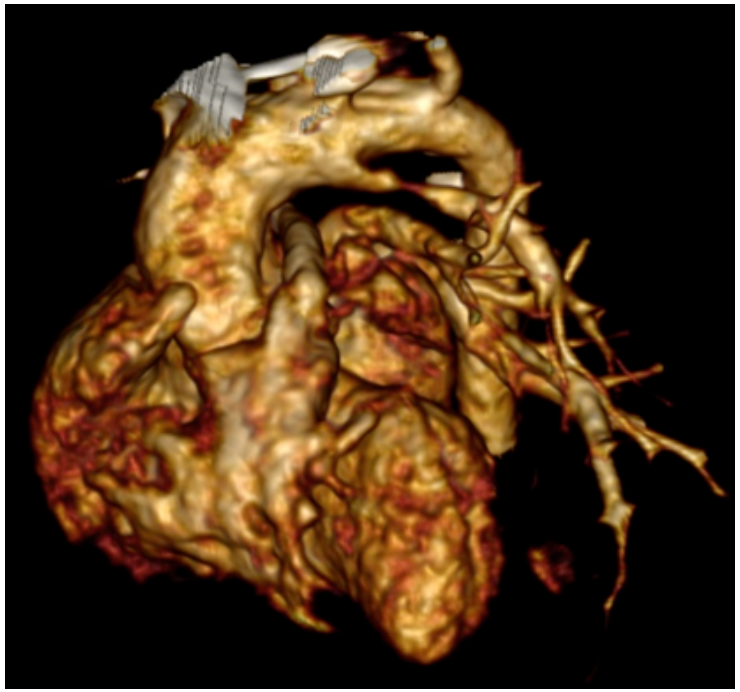

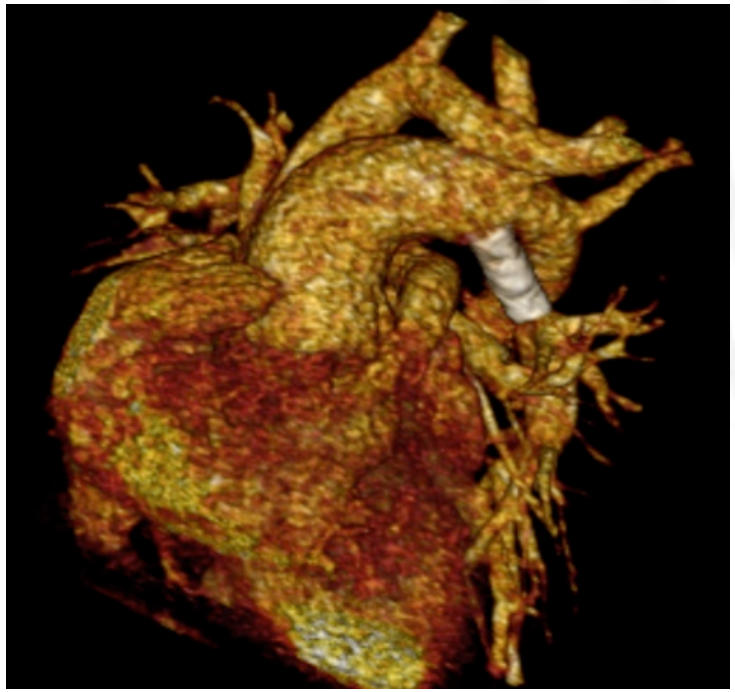

STENTING CANAL - RESULTATS

Duct Stenting Versus Modified Blalock-Taussig Shunt in Neonates With Duct-Dependent Pulmonary Blood Flow

Associations With Clinical Outcomes in a Multicenter National Study

Comparison Between Patent Ductus Arteriosus Stent and Modified Blalock-Taussig Shunt as Palliation for Infants With Ductal-Dependent Pulmonary Blood Flow

- Etudes multicentriques, prospectives non randomisées
- Comparant DS et BTS (106 vs 251 et 83 vs 171)
- Succès de procédures DS: 83%
- Groupes DS:
  - Moins de décès, Moins d'ECMO
  - Durée d'hospitalisation plus courte
  - Plus de réinterventions

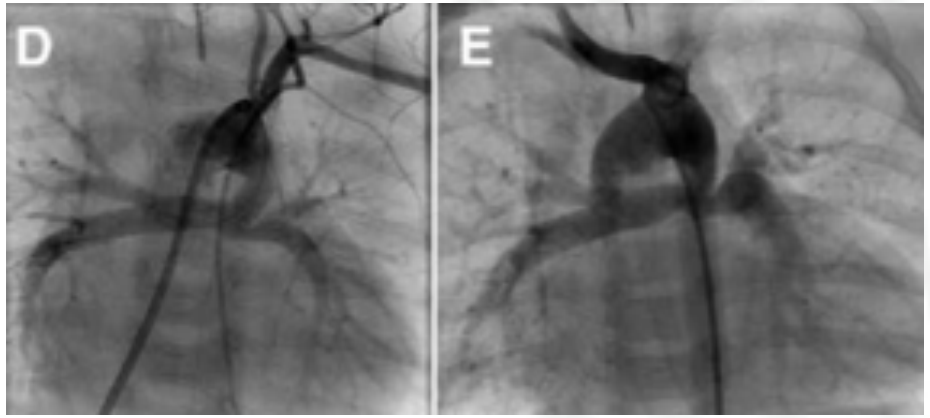

Bentham et al. Circulation 2018
Glatz et al. Circulation 2018

CAS CLINIQUE

- Diagnostic anténatal de VU avec sténose pulmonaire
- Naissance à 36 SA, PN = 3.6kg, $SatO^2$ = 86%

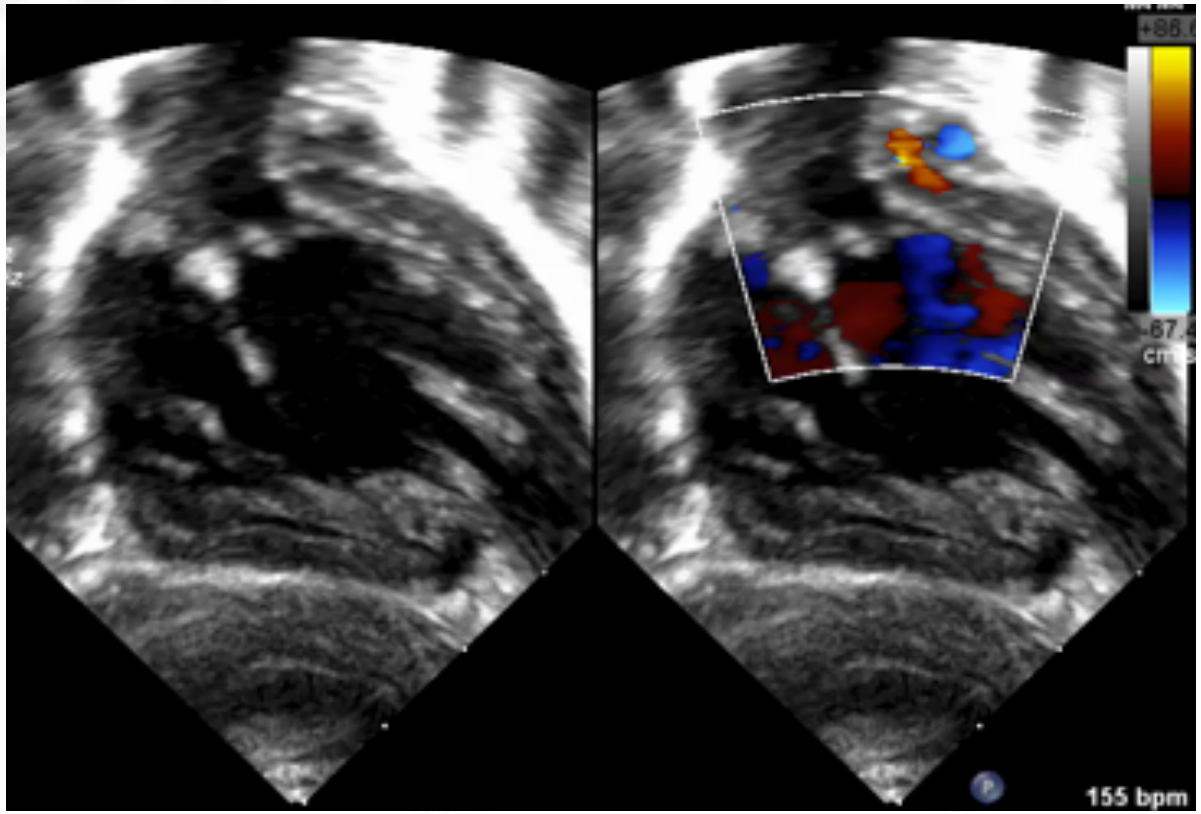

Post natal:

- VU type gauche à double entrée
- Vaisseaux normo posés
- Foramen bulbo-ventriculaire restrictif:

sténose sous valvulaire pulmonaire

S4: P=4kg, Sat=70%, malaises

BT droit 3.5mm, sternotomie

CAS CLINIQUE

- Suites HD et respiratoires simples
- Désunion cicatrice: soins locaux + ATB
- J15 PO: retrait VVC jugulaire droite -> Désaturation à 40-50 %
- Souffle de BT disparu, BT non visible en ETT

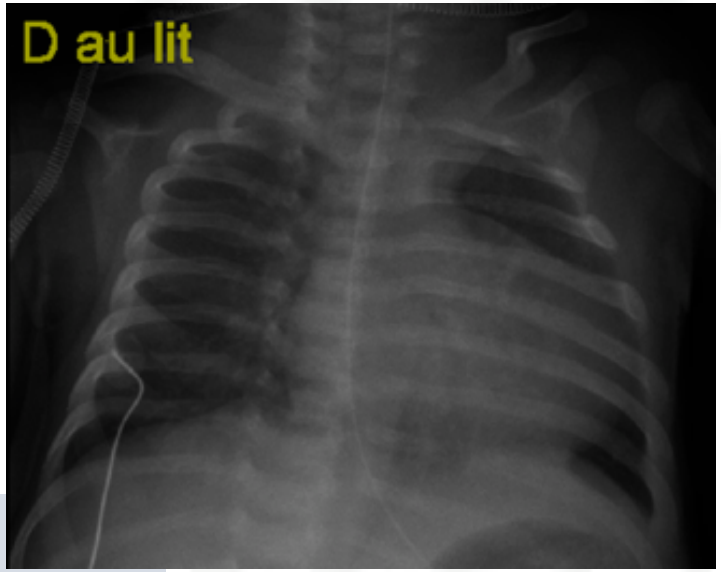

Suspicion de thrombose aigue de BT

Embole systémique sur thrombose VVC?

- HNF Bolus puis IVSE, Aspirine IV, Remplissage

Pas d'effet, signes d'insuffisance circulatoire

Attitude?

CAS CLINIQUE

Thrombose aigue, caillot frais

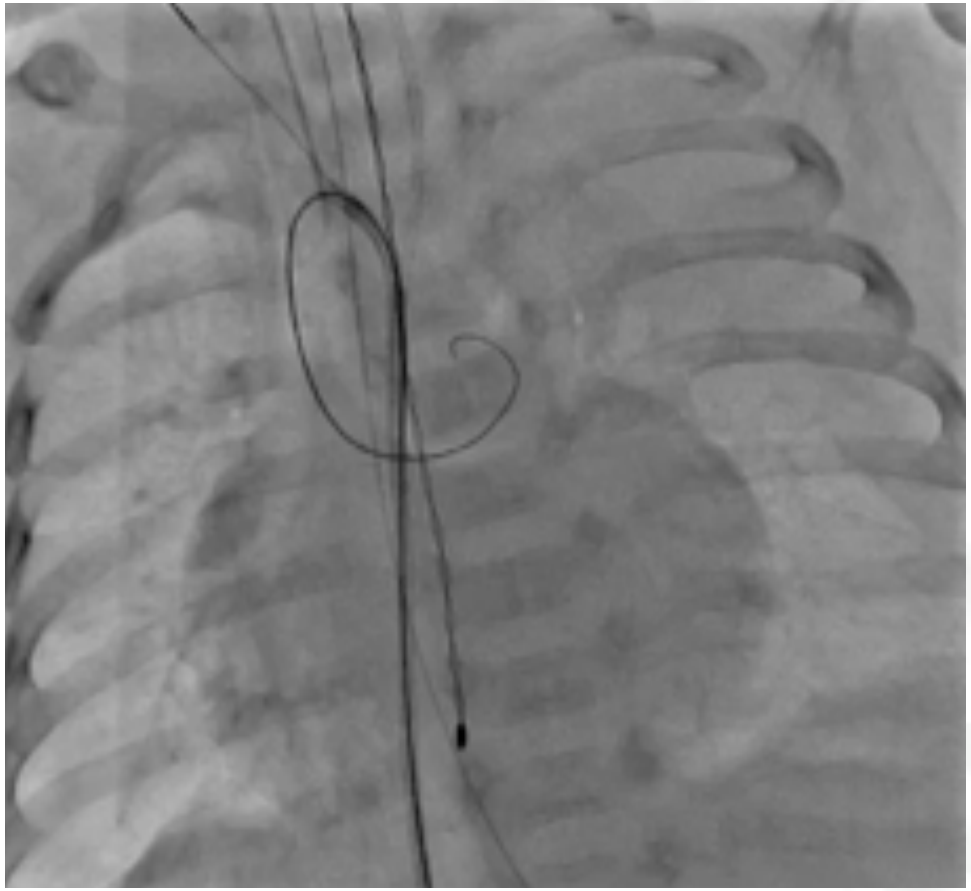

Désobstruction

CAS CLINIQUE

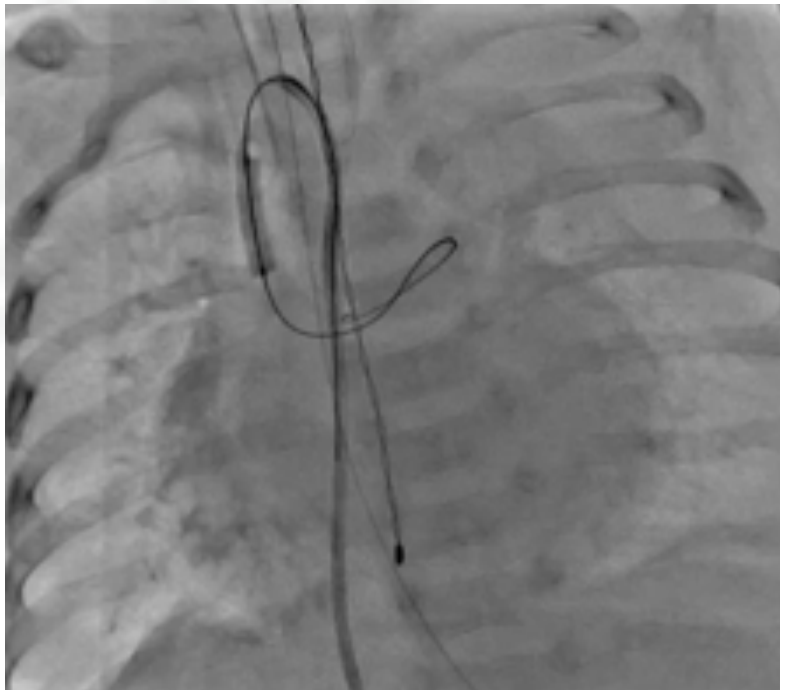

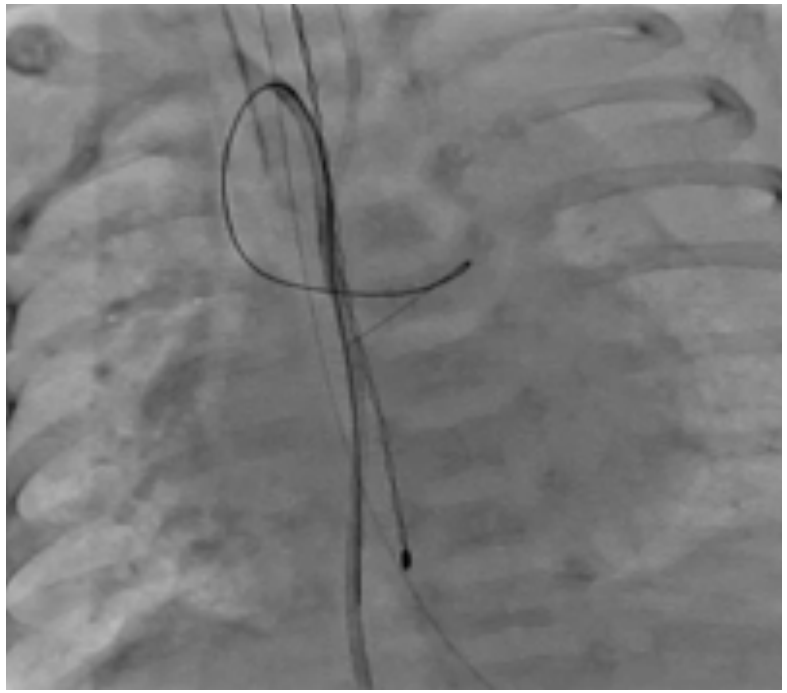

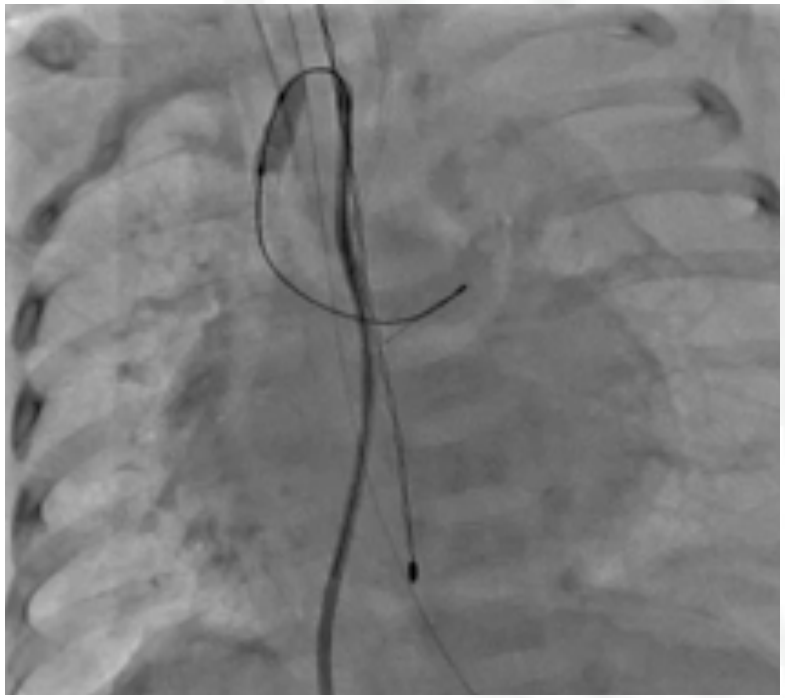

Implantation de 2 stents coronaires (3.5mm)

CAS CLINIQUE

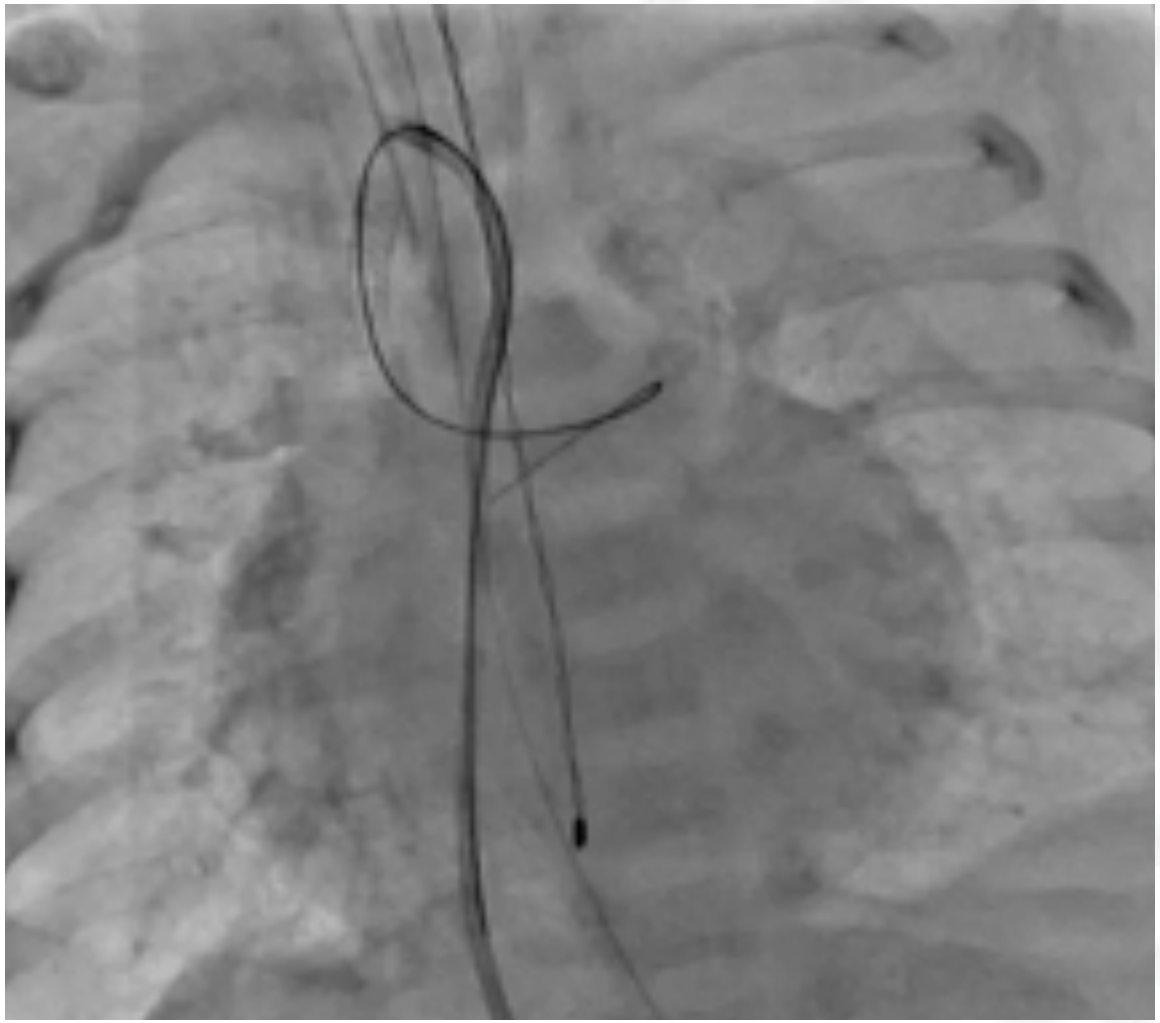

STÉNOSE DES BRANCHES PULMONAIRES

SIÈGE DE L'OBSTACLE

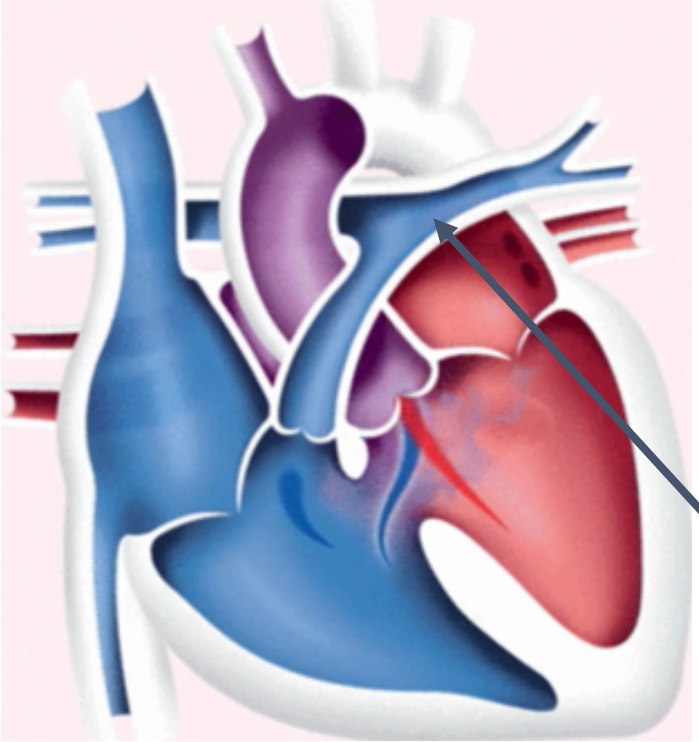

ARTÈRES PULMONAIRES

Dilatation

Stenting

STÉNOSE DES BRANCHES PULMONAIRES

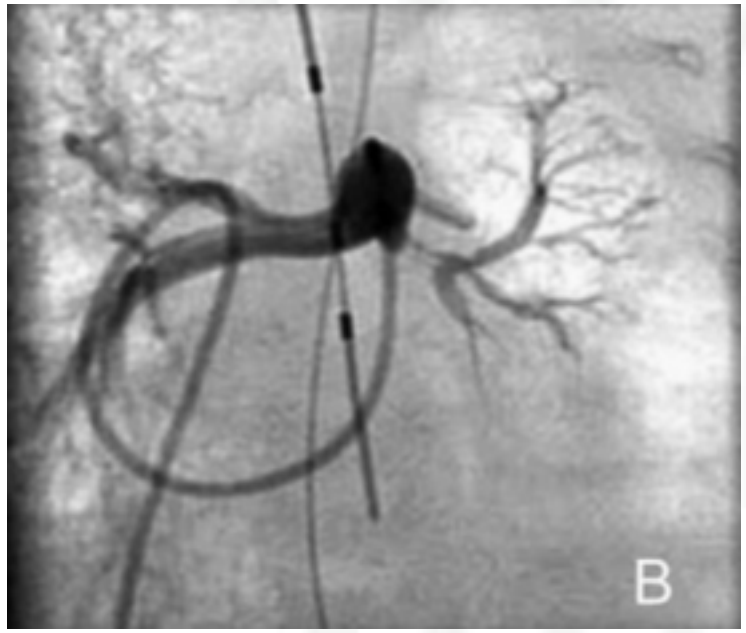

- **Indications admises:**
  - Gradient pic à pic > 20mmHg
  - PSVD > 50% Pressions systémiques
  - Disparité de perfusion des 2 poumons au-delà de 35%/65%

STÉNOSE DES BRANCHES PULMONAIRES

Recommendations for Pulmonary Angioplasty

Class I

1. Pulmonary angioplasty is indicated for the treatment of significant peripheral branch pulmonary artery stenosis (see text for definition of "significant" stenosis) or for pulmonary artery stenosis in very small patients in whom primary stent implantation is not an option (*Level of Evidence: B*).

Recommendations for Pulmonary Artery Stent Placement

Class I

1. Primary intravascular stent implantation is indicated for the treatment of significant proximal or distal branch pulmonary artery stenosis when the vessel/patient is large enough to accommodate a stent that is capable of being dilated to the adult diameter of that vessel (*Level of Evidence: B*).

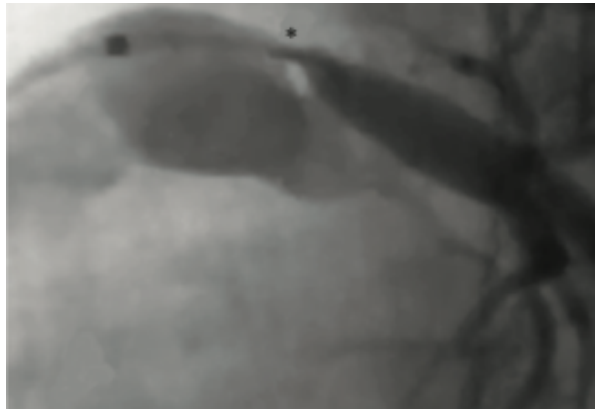



STÉNOSE DES BRANCHES PULMONAIRES

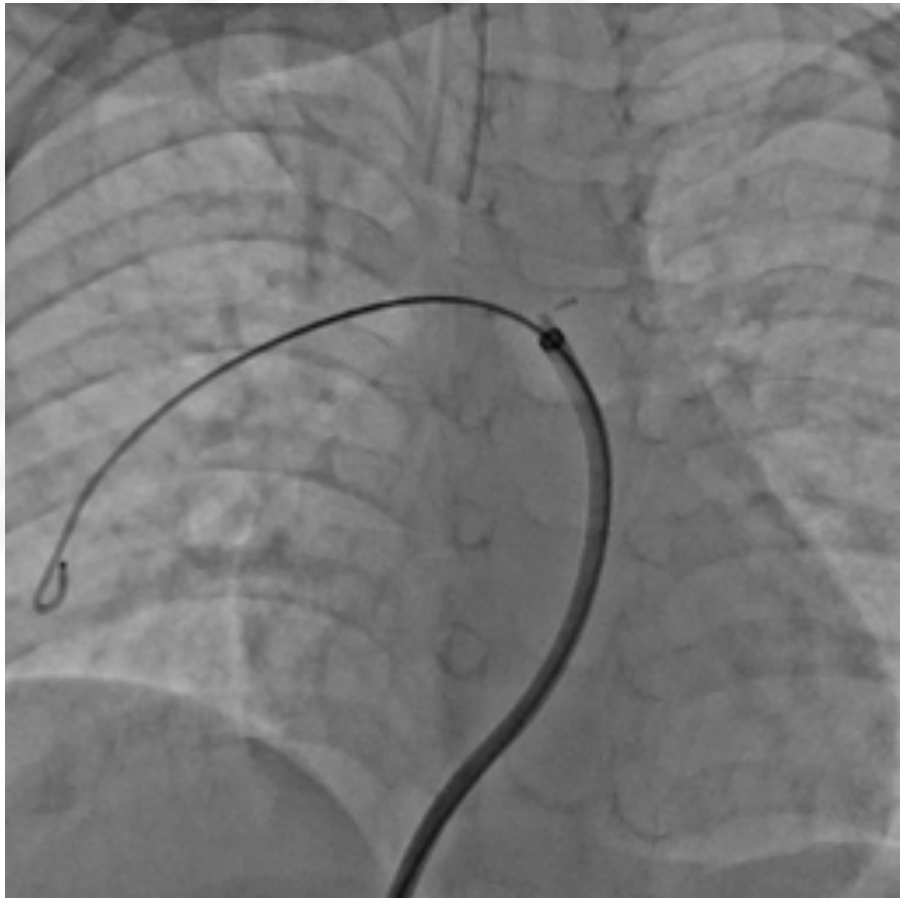

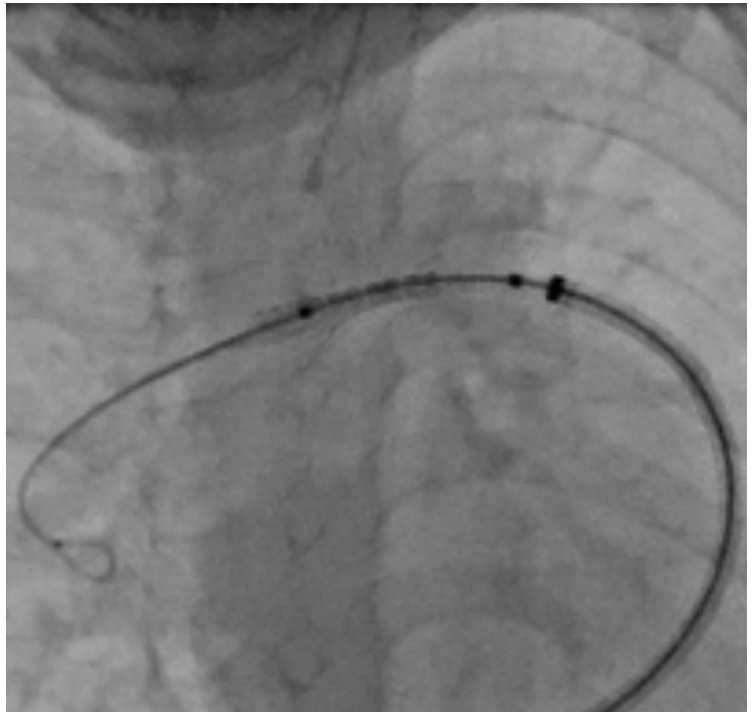

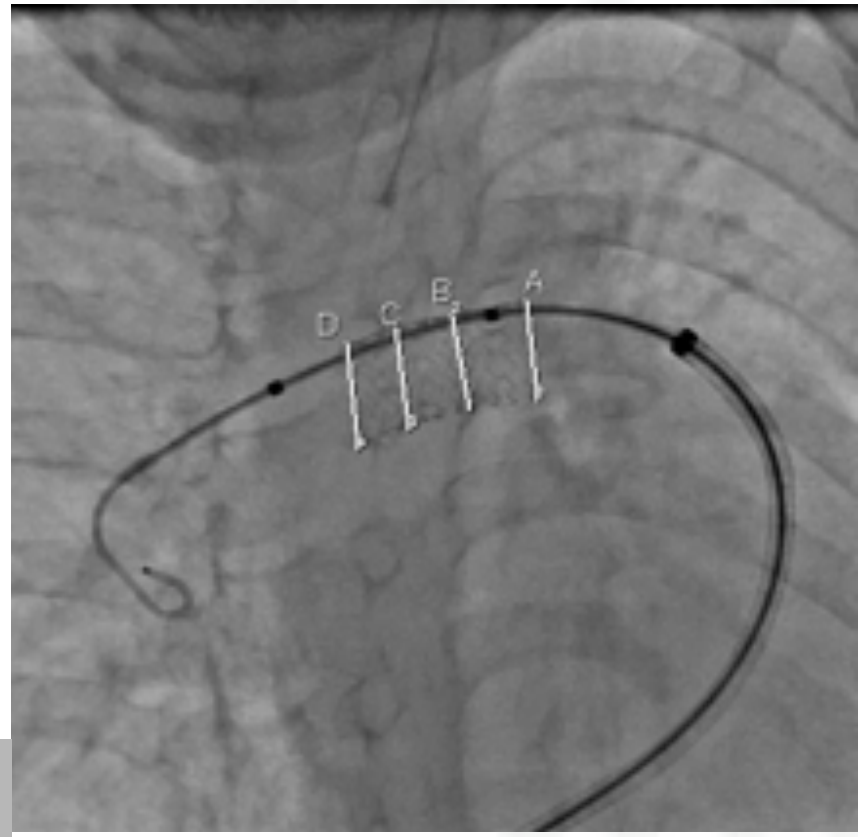



CHALLENGES DU STENTING

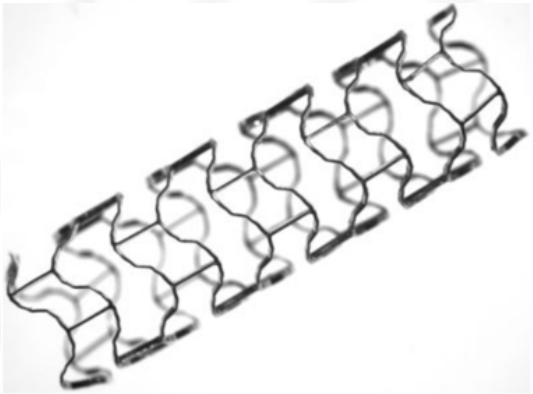

Fig. 2. Strut design of the 3 mm magnesium stent.

HEALING

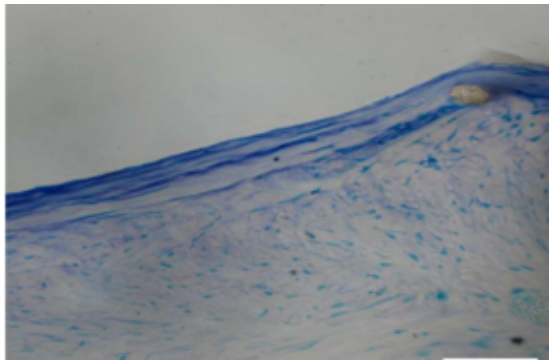

REMODELLING

GROWTH

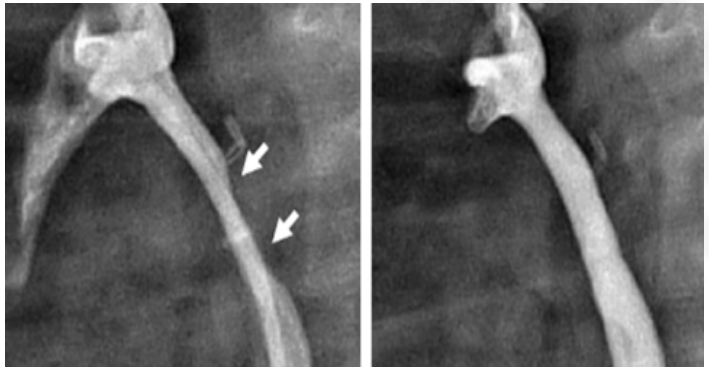

VALVES

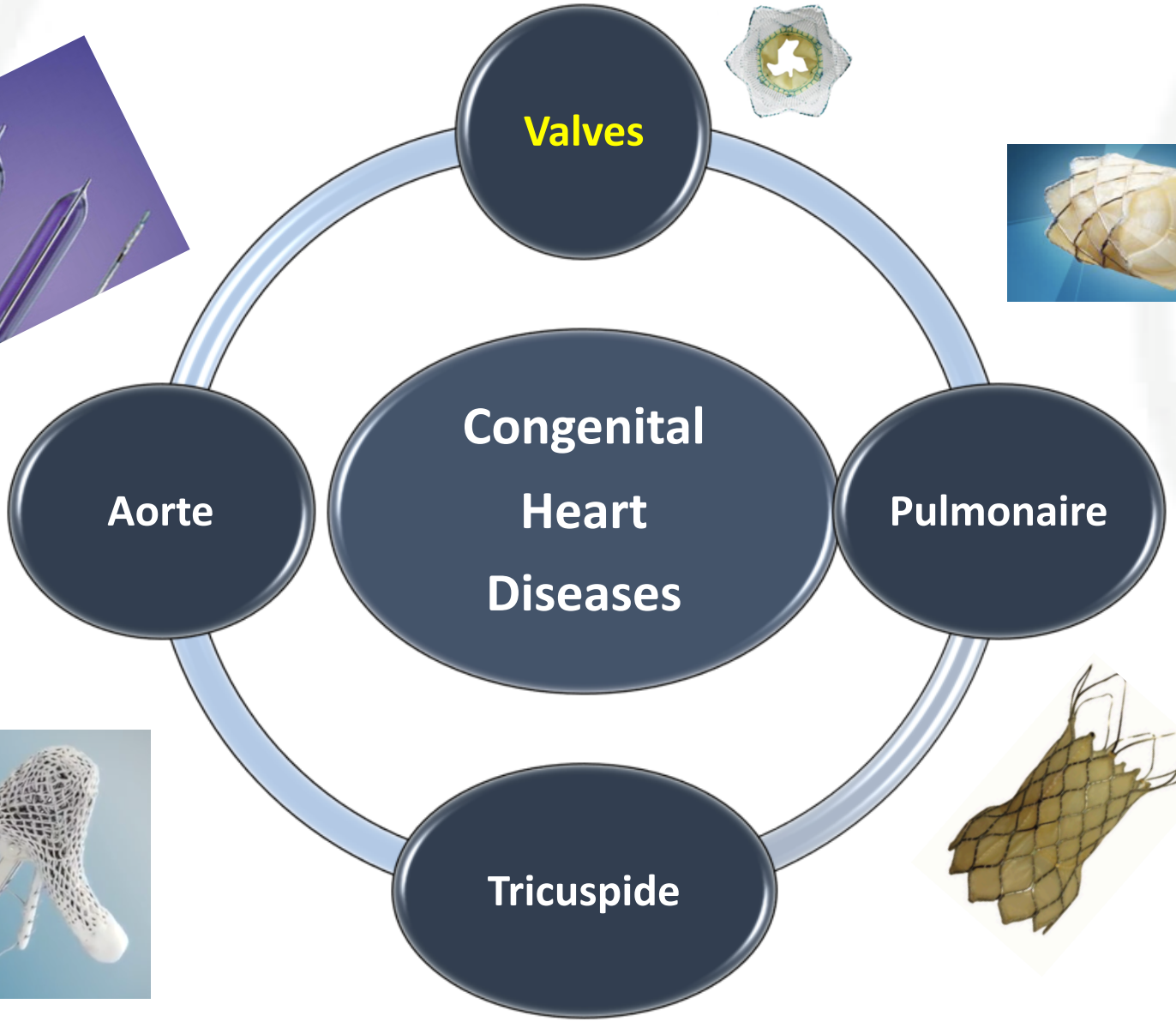
Valves
Aorte
Congenital Heart Diseases
Pulmonaire
Tricuspide

VALVE AORTIQUE

AORTIC STENOSIS

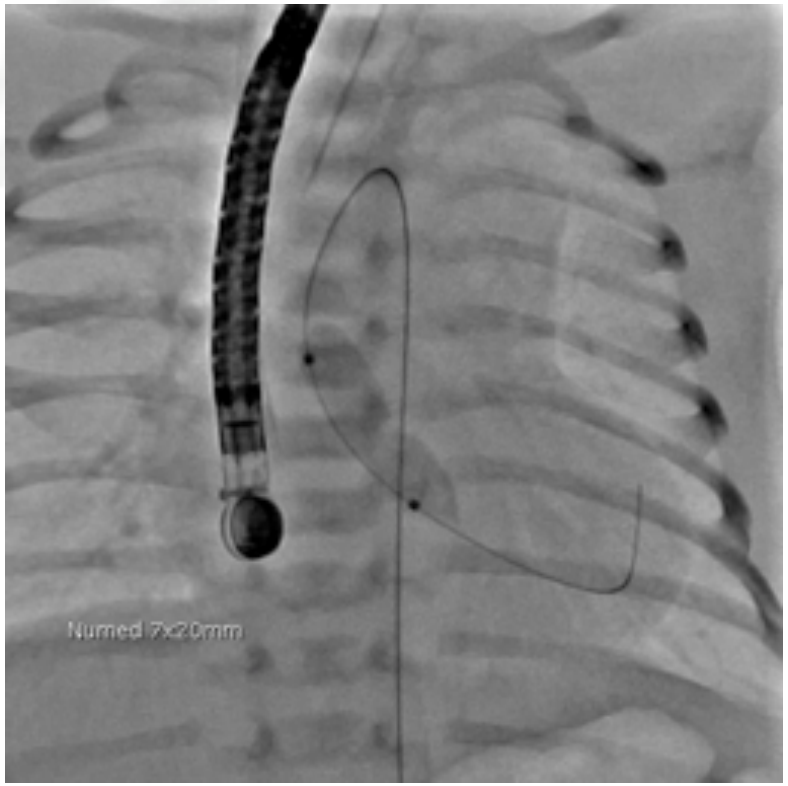

Recommendations for Aortic Valvuloplasty

Class I

1. Aortic valvuloplasty is indicated regardless of valve gradient in the newborn with isolated critical valvar AS who is ductal dependent or in children with isolated valvar AS who have depressed left ventricular systolic function *(Level of Evidence: B)*.
2. Aortic valvuloplasty is indicated in children with isolated valvar AS who have a resting peak systolic valve gradient (by catheter) of ≥50 mm Hg† *(Level of Evidence: B)*.
3. Aortic valvuloplasty is indicated in children with isolated valvar AS who have a resting peak systolic valve gradient (by catheter) of ≥40 mm Hg† if there are symptoms of angina or syncope or ischemic ST-T-wave changes on electrocardiography at rest or with exercise *(Level of Evidence: C)*.

VALVE PULMONAIRE

2000

Implantation chez l'homme

Faisabilité

Succès technique

Excellent résultats hémodynamiques

Peu de complications aigues

Marquage CE
FDA Approval

2008-2010

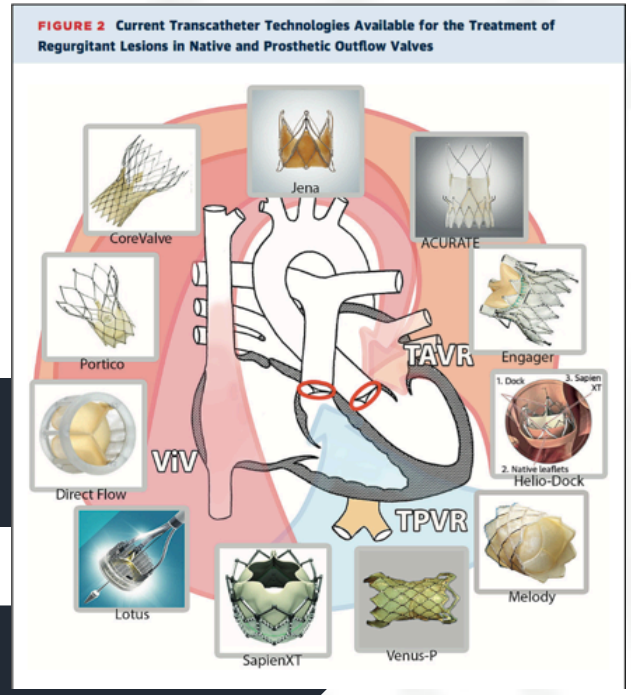

MELODY - Veine jugulaire de bœuf

16 – 22 mm ⦸

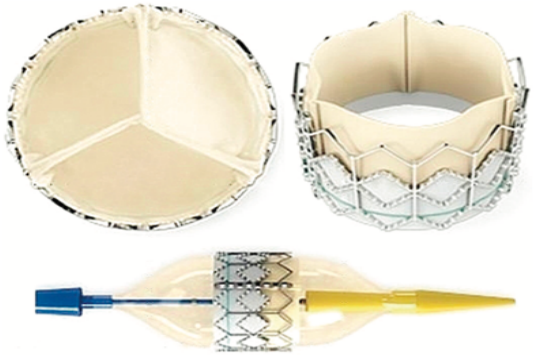

SAPIEN XT – Péricarde bovin

(20) – 23 – 26 – 29 mm ⦸

VALVE MELODY

Munich Comparative Study

Prospective Long-Term Outcome of the Transcatheter Melody Valve Versus Surgical Pulmonary Bioprosthesis With Up to 12 Years of Follow-Up

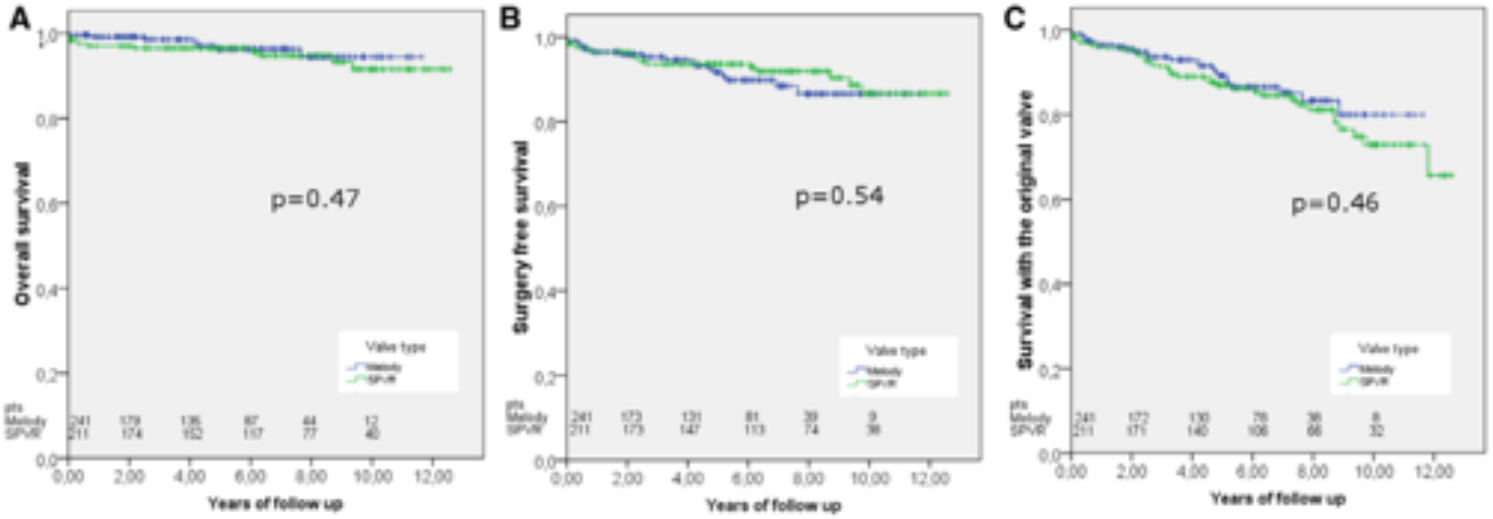

- Prospective, monocentric,
- 241 PPVI Melody and 211 surgical valves
- Median FU 5.4 years (3 m - 12.5 years), 2449 patient-years
- 10 years survival and freedom of surgery comparable : 94% vs 92%, 87% vs 87%.
- Annualized incidence of IE = 1.6% Melody group and 0.5% surgical group,
- But estimated survival free of IE did not differ significantly

Georgiev et al. Circ Cardiovasc Intrv 2020

VALVE MELODY

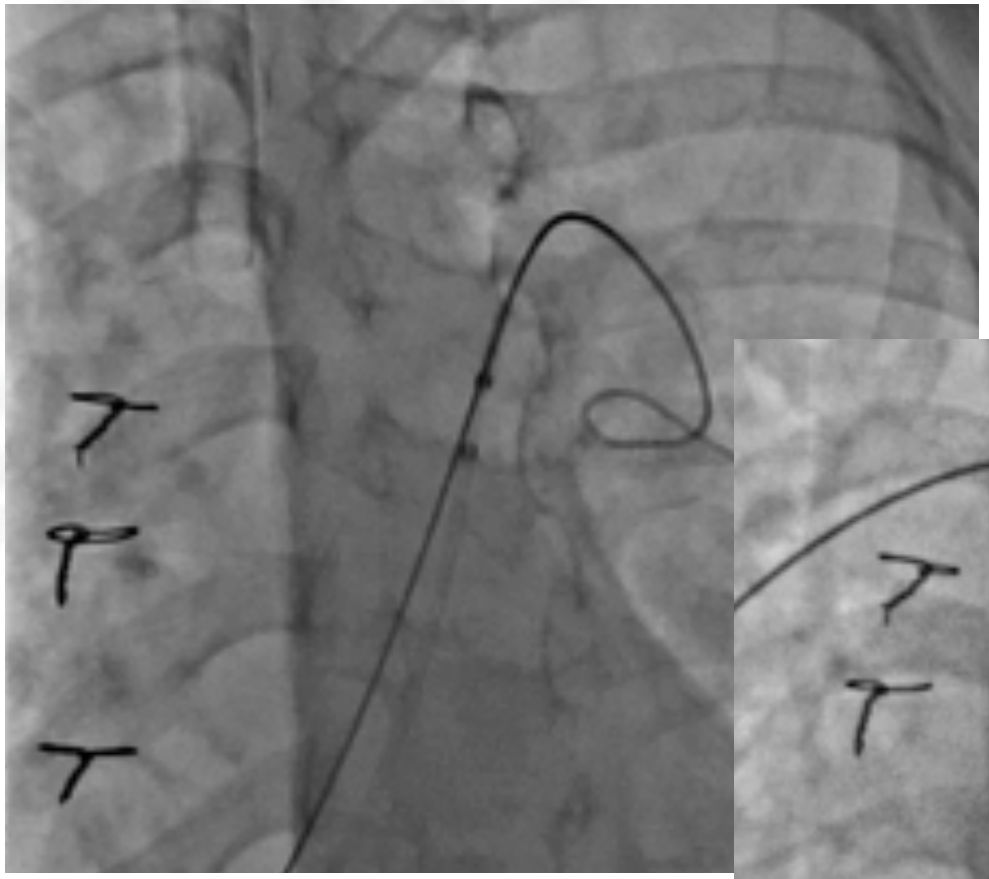

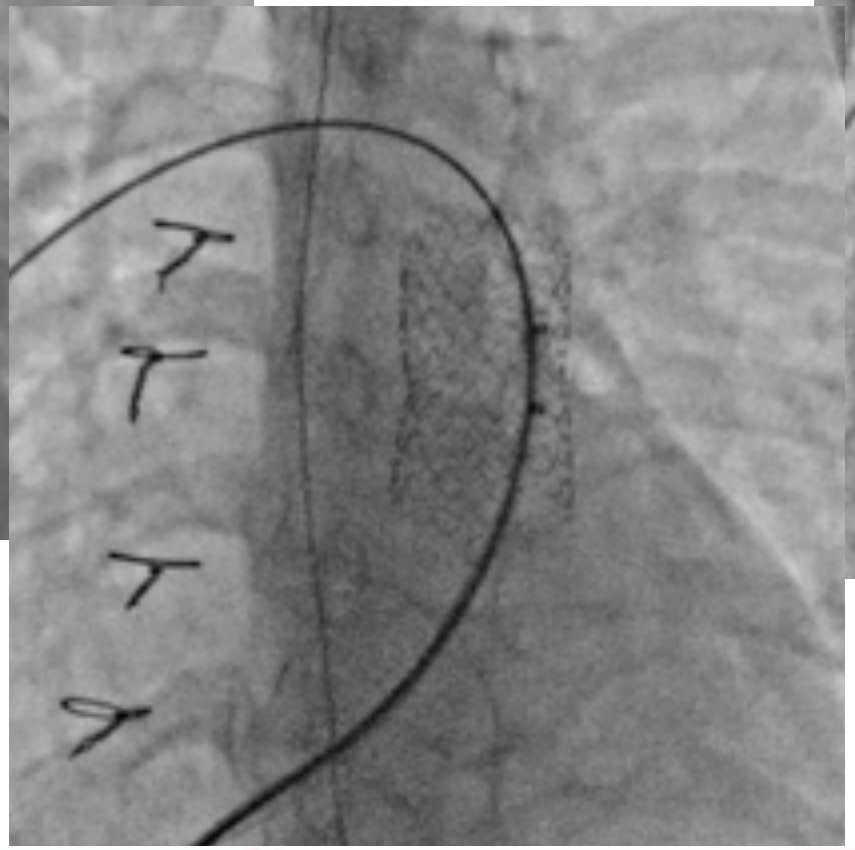

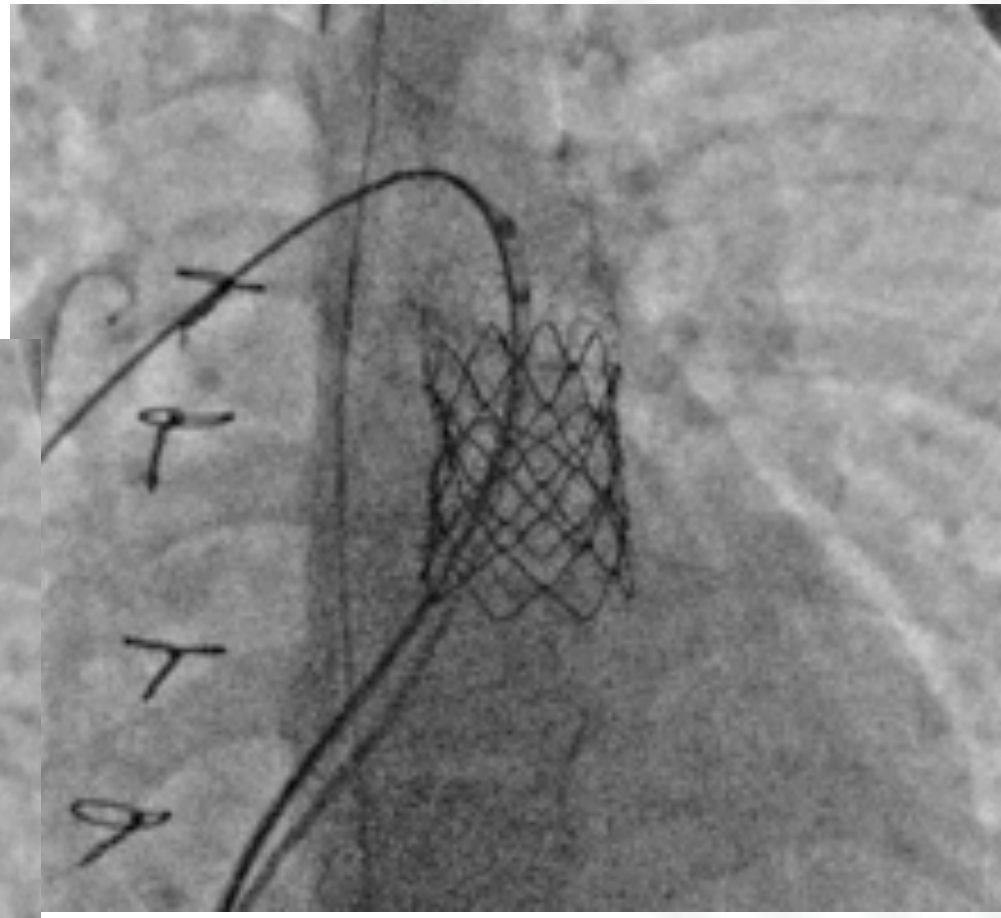

VALVE SAPIEN

Transcatheter Pulmonary Valve Replacement With the Sapien Prosthesis

- Multicentre registry, 774 patients:
- Technical sucess: 97.4% patients.
- Serious adverse events 67 patients (10%)
- Median follow-up : 12 months
- IE: 1.6% patient/year
- Reinterventions: 4.8%
- PR moderate/severe: 5.5%

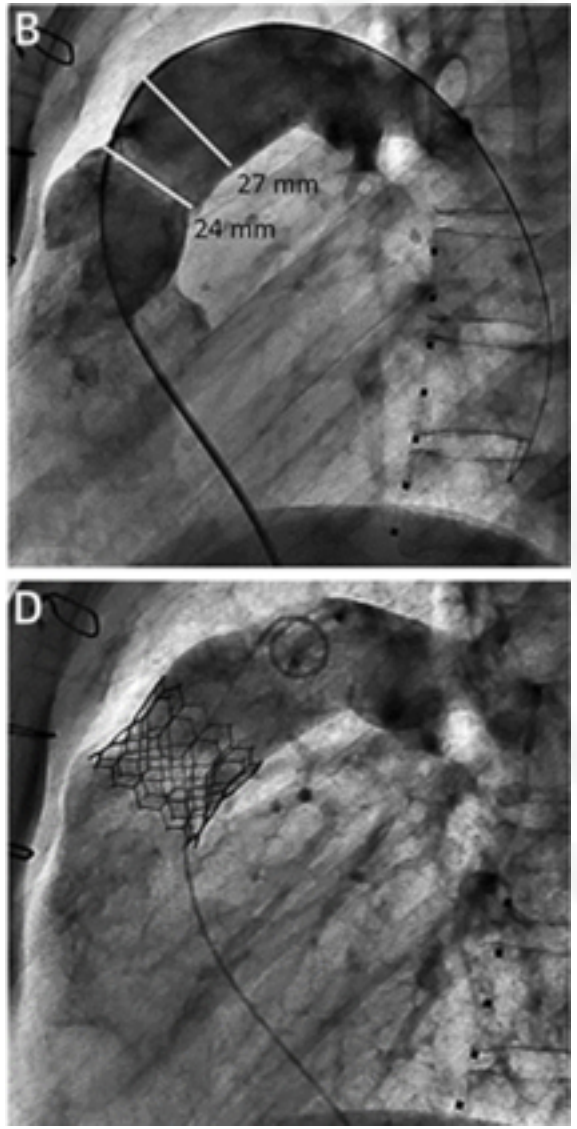

Shahanavaz et al. JACC 2020

SUBSTRATS CHIRURGICAUX

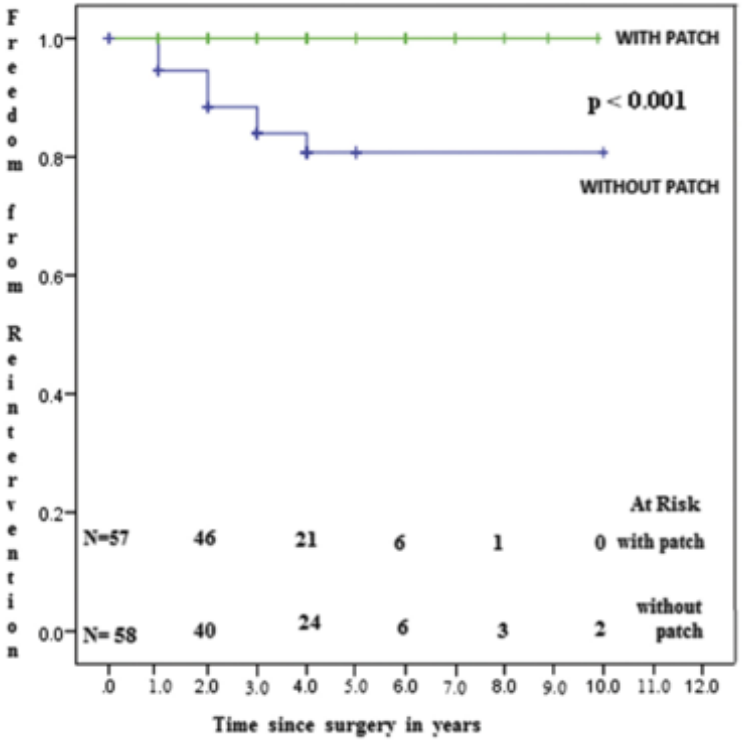

115 patients
Survie sans réintervention:
87% à 5 ans

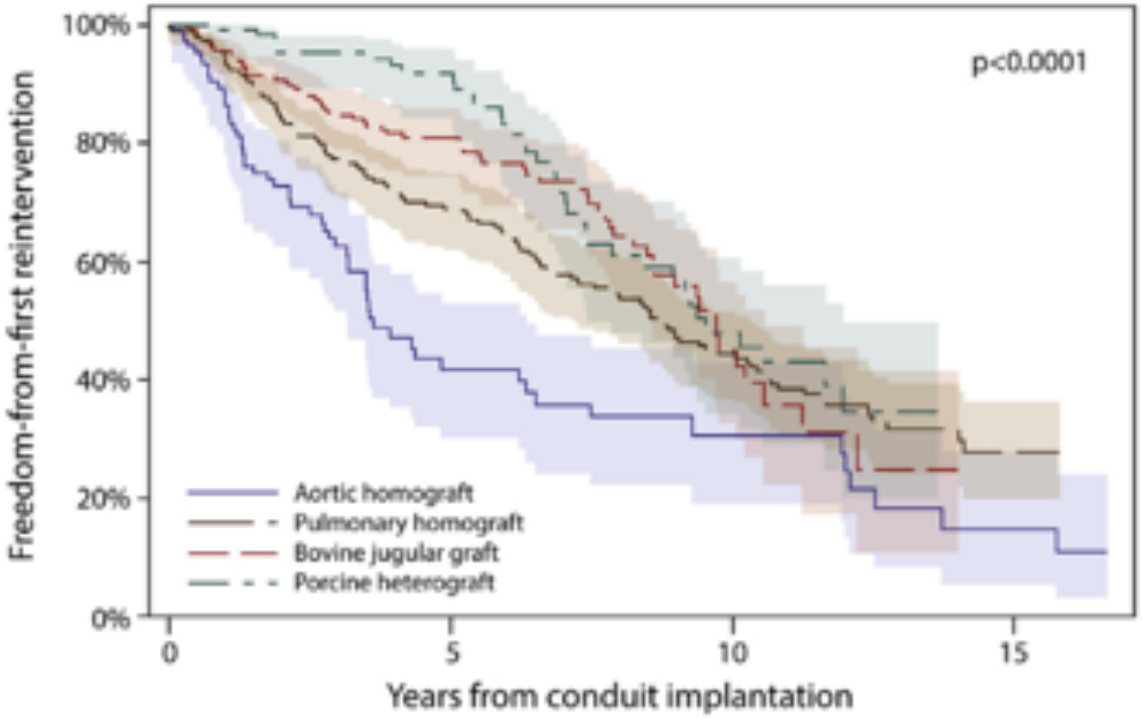

Aortic homograft	121	23	10	4
Pulmonary homograft	289	128	61	10
Bovine jugular graft	245	101	18	0
Porcine heterograft	137	65	20	0

586 patients
Survie sans réintervention:
73% à 5 ans

Ramanan et al. Ann Thorac Surg 2015
Mery et al. JTCS 2016

ENDOCARDITE INFECTIEUSE

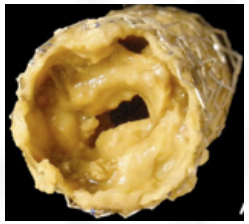

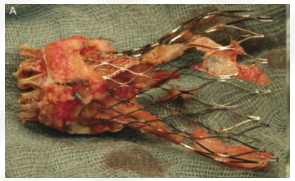

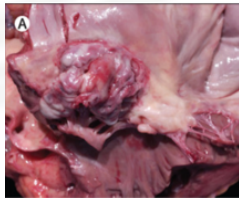

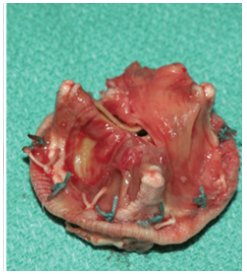

Valve Melody : **0.8 – 3% pt-année**

Valves/conduits pulmonaire chir : **0.5 - 3% pt-année**

TAVI: **0.67 – 2.1% pt-année**

Valves Ao/mitrale chir : **0.3 – 1.2% pt-année**

Dispositifs electroniques implantables : **1.9/1000 device-année**

Patients avec CC: **0.4 – 1.33 / 1000 pt-année**

Population générale : **30 -100/ million pt-année**

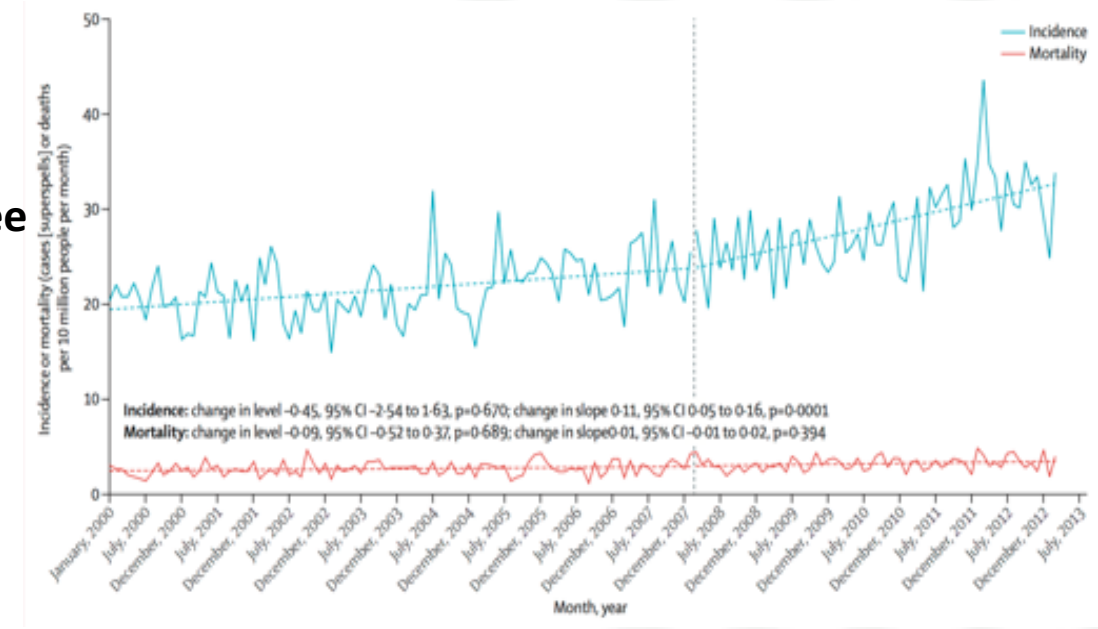

Miranda et al. Eur Heart Jour 2016
Wang et al. JAMA 2007
Rushani et al. Circulation 2013
Habib et al. Eur Heart Jour 2015
Dayer et al. Lancet 2015

ENDOCARDITE INFECTIEUSE

A Systematic Review of Infective Endocarditis in Patients With Bovine Jugular Vein Valves Compared With Other Valve Types

Méta-analyse sur IE chez les patients avec RVP chirurgical ou percutané

7063 patients

Incidence cumulative globale = 2.5%

VJB vs autres substituts : 5.4% vs 1.2%; p < 0.0001

FIGURE 2 Incidence of Infective Endocarditis in BJV Compared to Other Valves

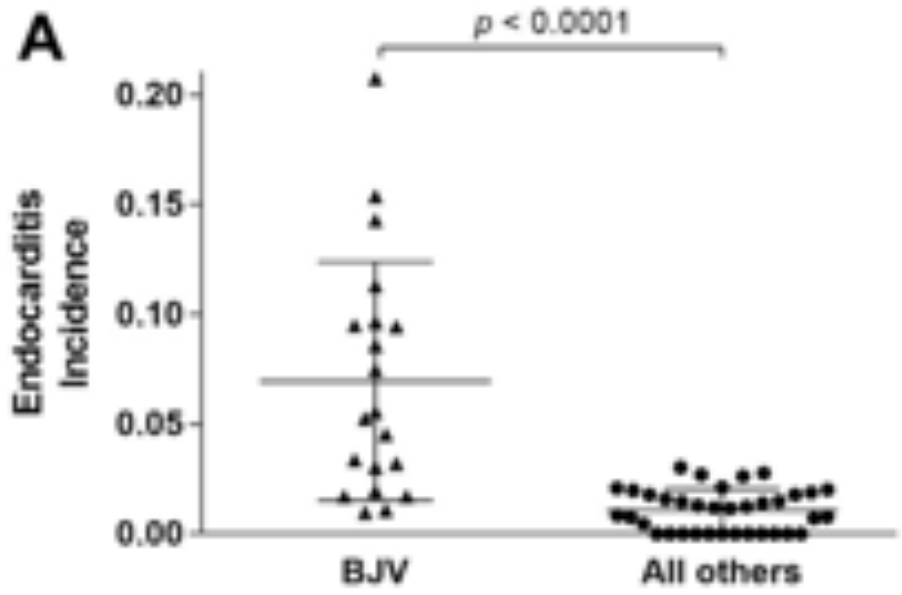

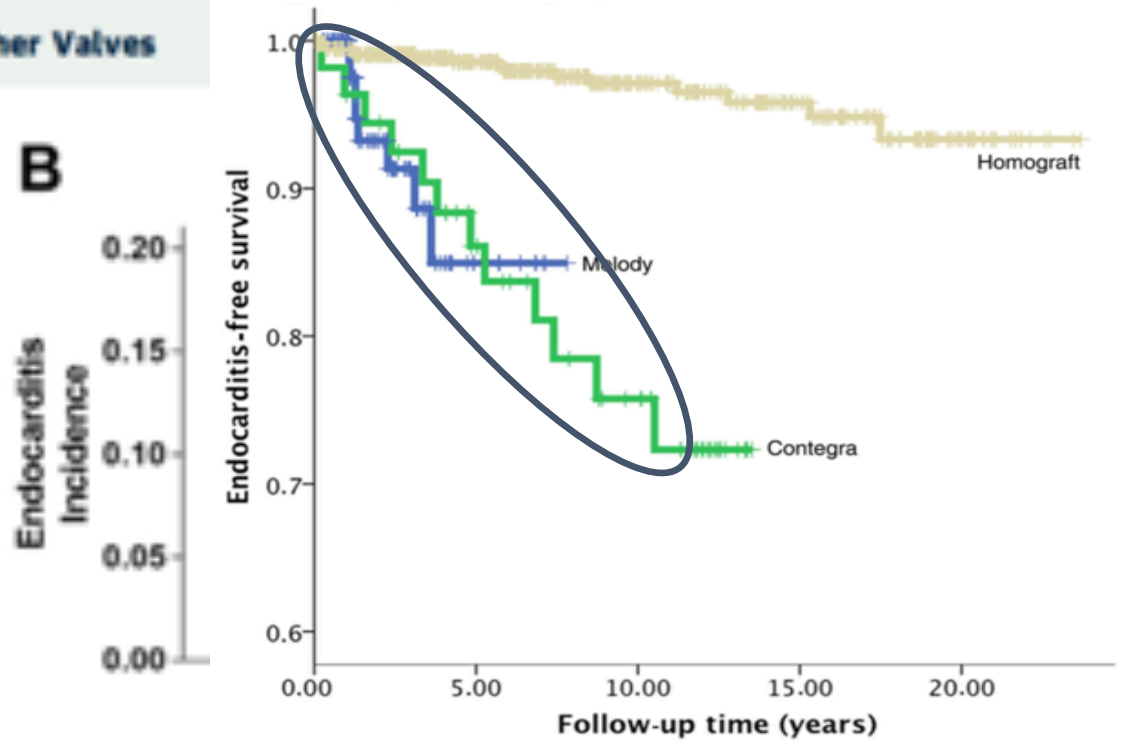

Sharma et al. JACC Int. 2017

PERSPECTIVES

MODELISATION GUIDANCE

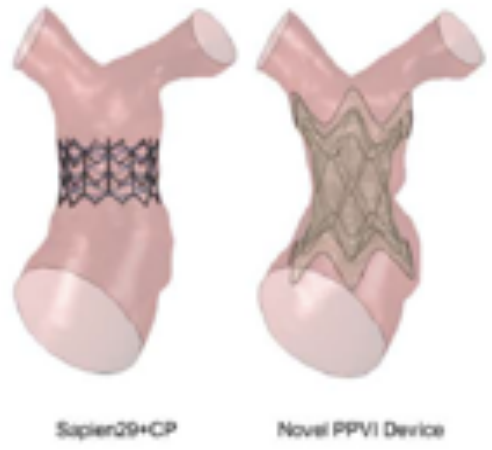

NEW DEVICES

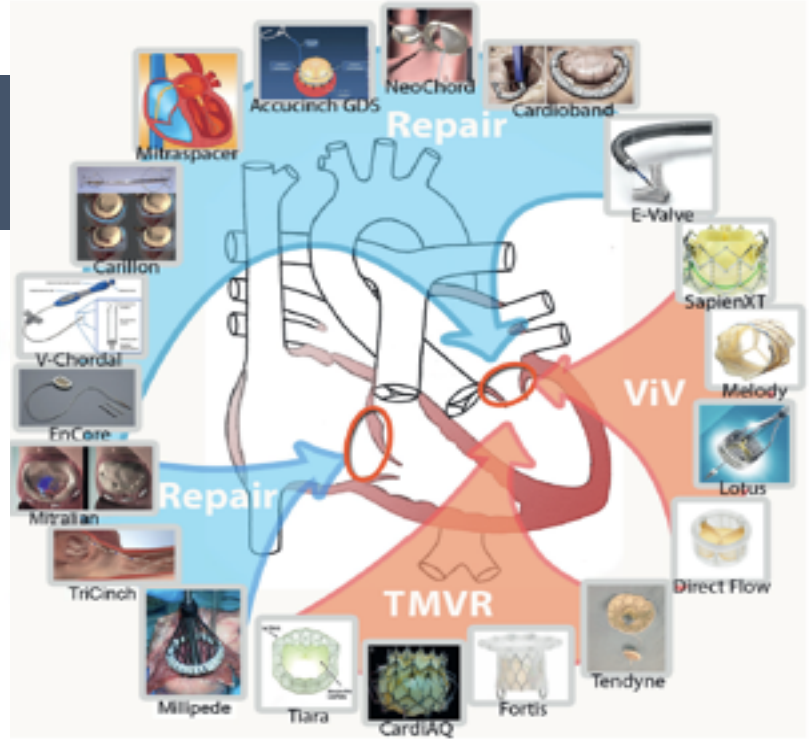

BIORESORBABLES MATERIALS

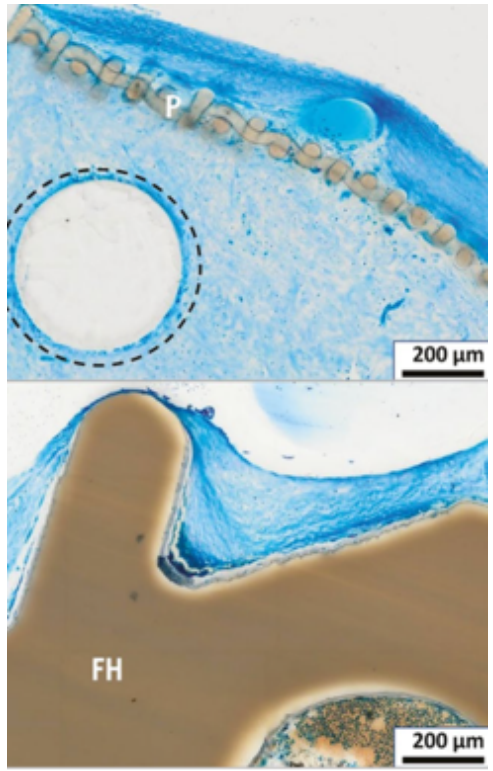

BIO ENGINEERING

NOUVEAUX DISPOSITIFS - VOIES LARGES

VENUS

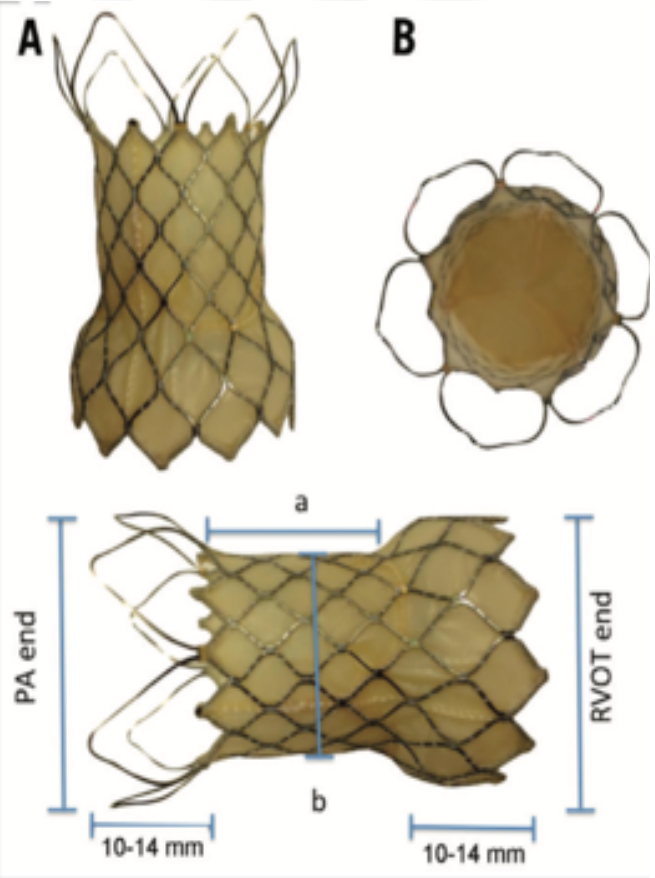

Promphan et al. Cardiol Young 2016
Husain et al. EuroIntervention 2016
Bergensen et al. JACC Intrv 2017

HARMONY



ALTERRA

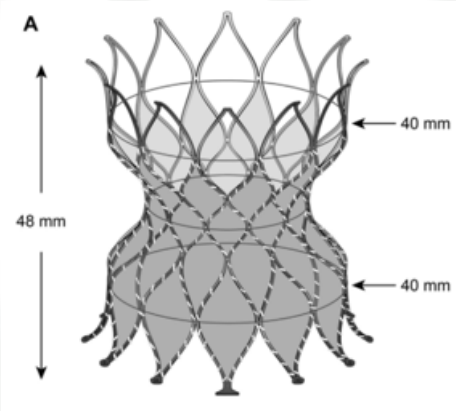

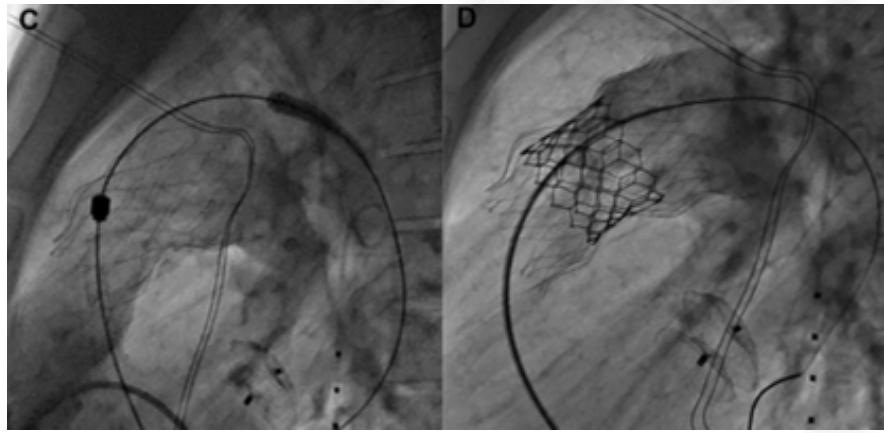

VALVES POLYMERIQUES

e-PTFE

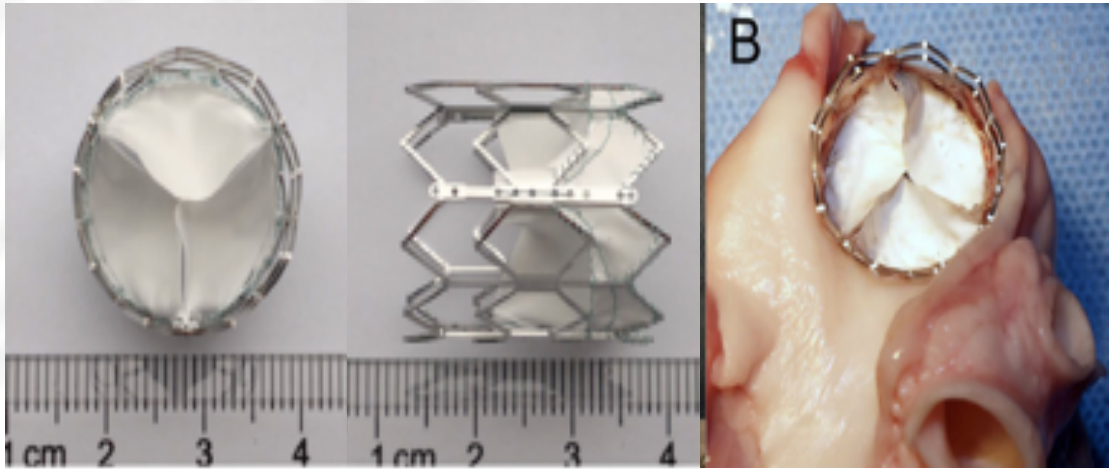

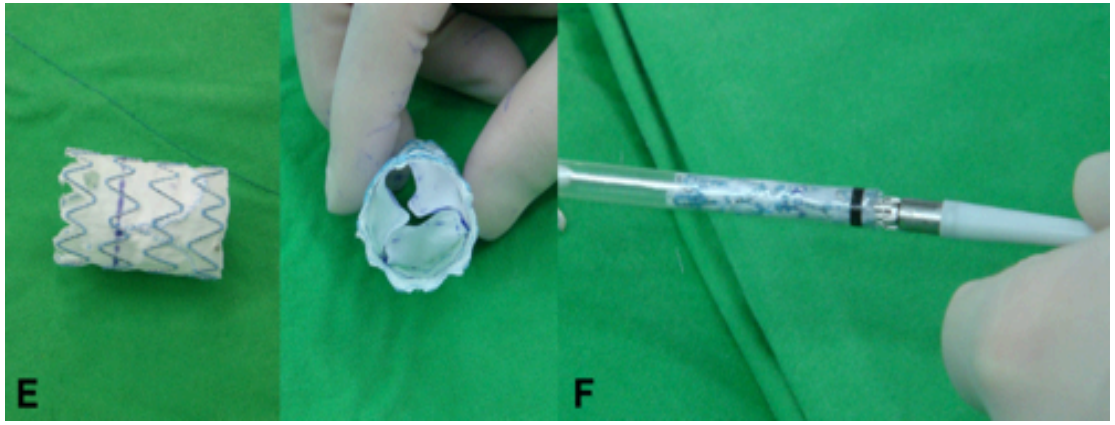

Lin et al. JTCS 2014
Claiborne et al. Expert Rev Med Devices. 2012

« Valves Biomécaniques »

- Durabilité des valves mécaniques mais pas d'AC
- Faisabilité/Court terme: satisfaisant
- Moyen terme: durabilité décevante

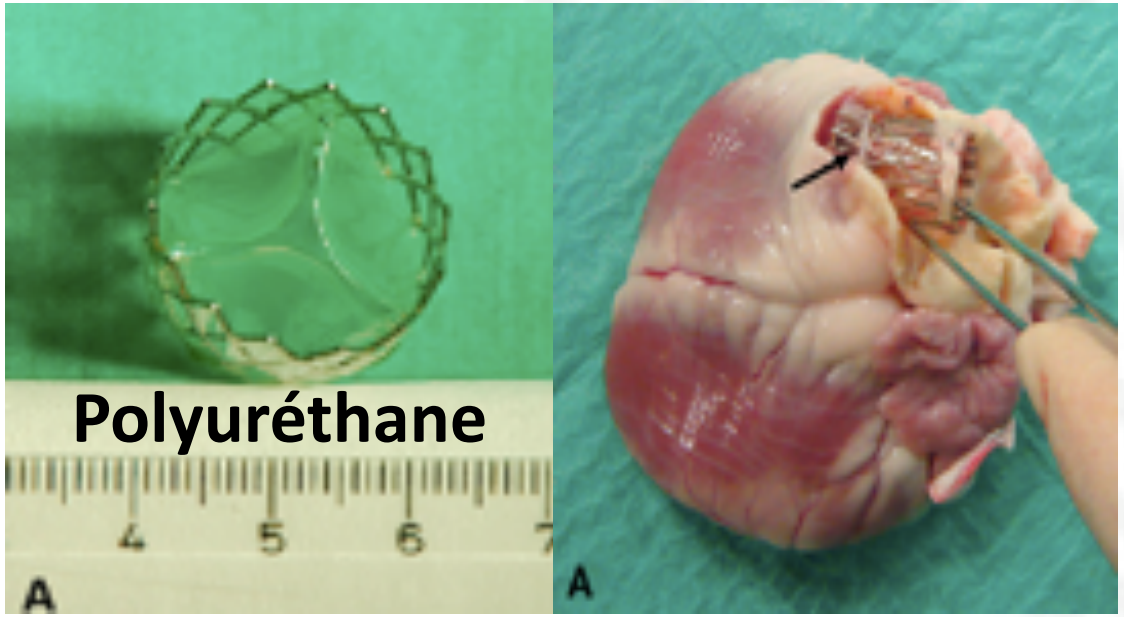

Zhang et al. PLoS ONE 2014
Metzner et al. JTCS 2010

INGENIERIE TISSULAIRE

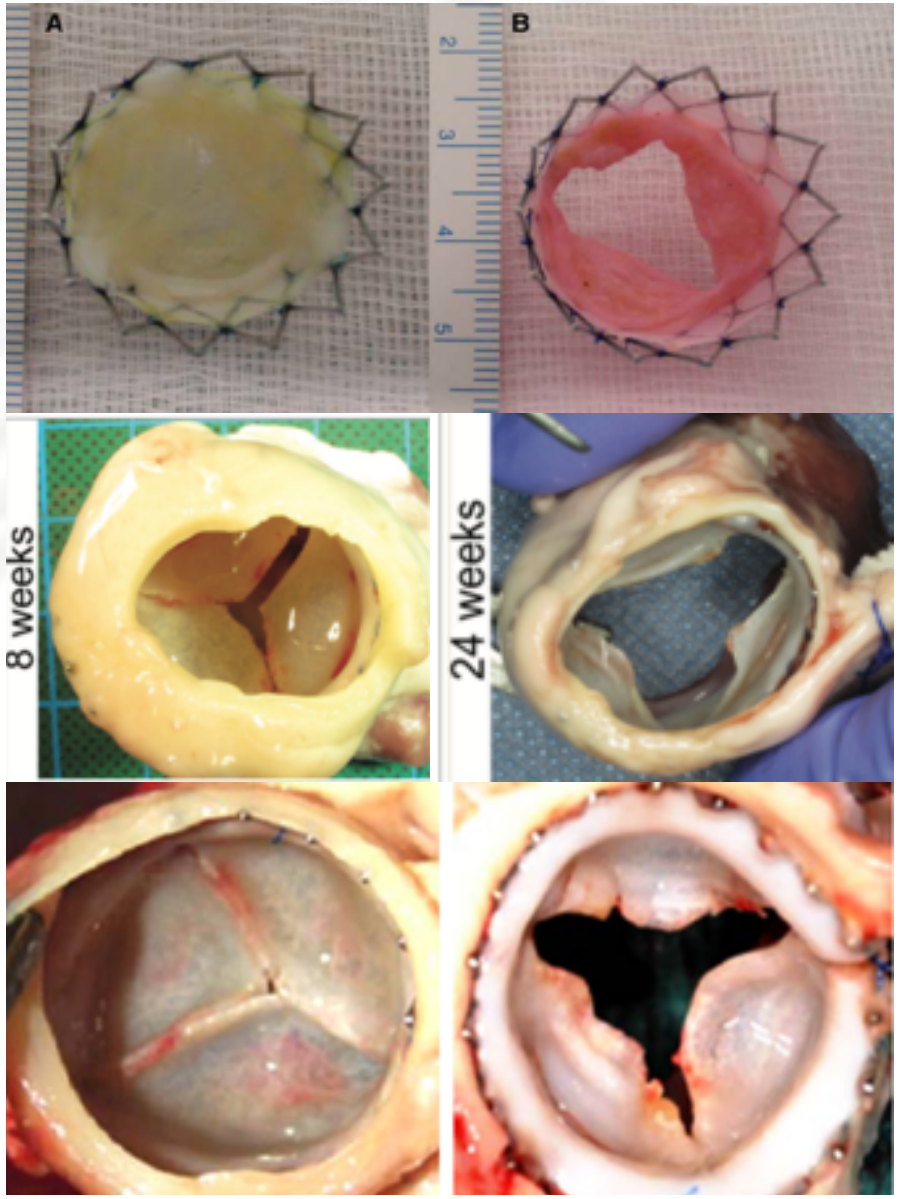

- Cellules autologues ➔scaffold décellularisé
  - valve porcine
  - polymère dégradable
- Avantages théoriques:
  - Biocompatibilité
  - Durabilité
  - Pas de thrombogénicité
- Bonne fonction initiale, endothélialisation
- **Rétraction des feuillets ➔Fuite**

Metzner et al. Eur. Heart J 2010
Driessen-Mol et al. JACC 2014
Schmitt et al. EuroIntervention 2016

VALVE TRICUSPIDE

NATIVE VALVES

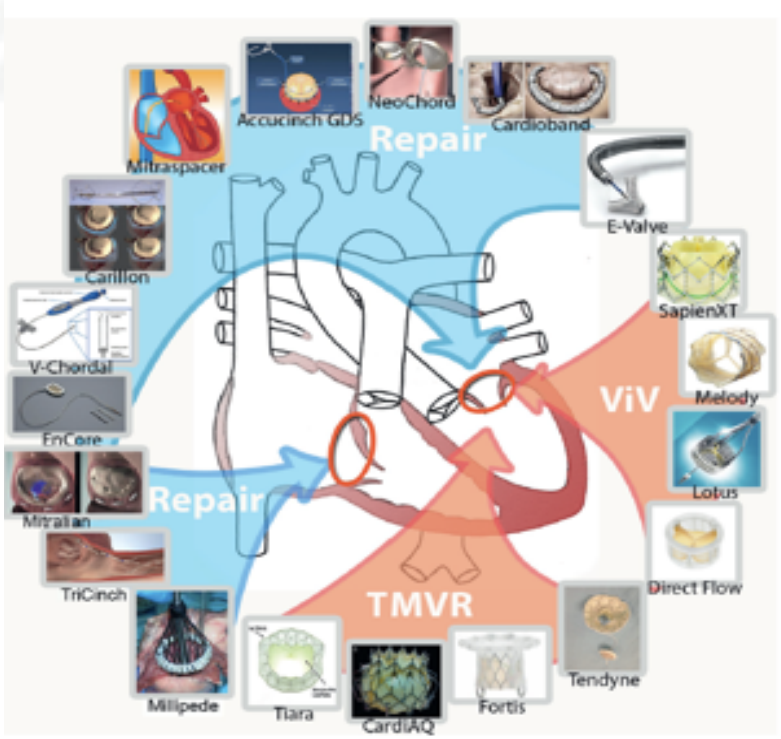

BIOPROSTHESES

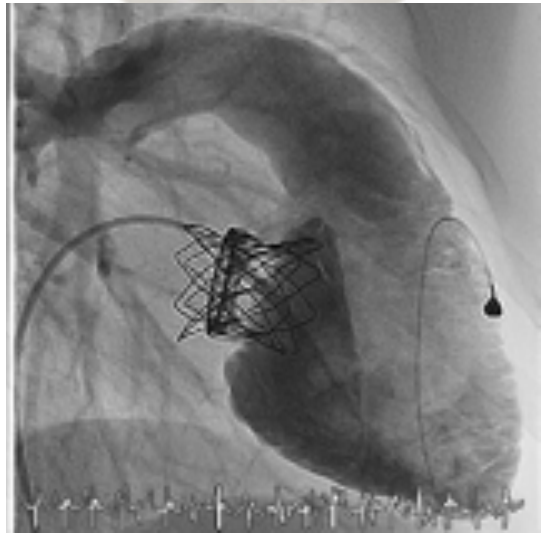

ANNULAR RINGS

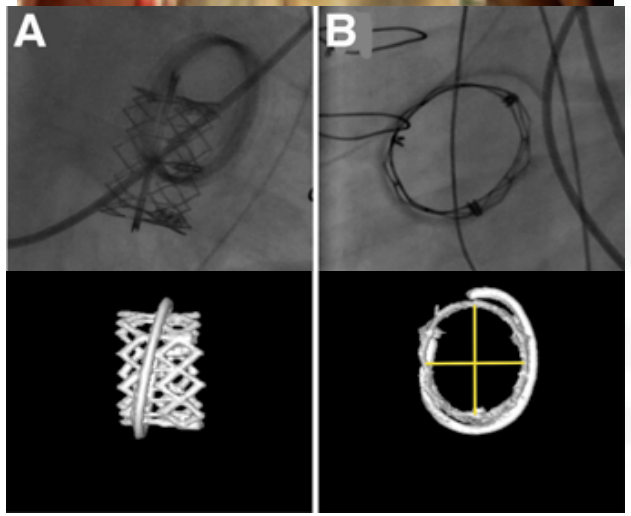

VALVE TRICUSPIDE

Transcatheter tricuspid valve replacement

Orthotopic and Heterotrophic

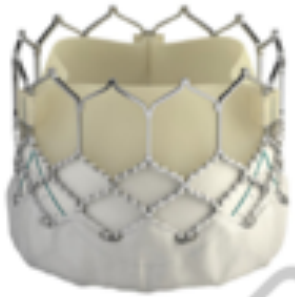

Sapien 3 valve

Orthotopic



NaviGate Valve

LUX Valve

Trisol valve

TriCares valve

Heterotrophic

TricValve

Transcatheter tricuspid valve repair

Leaflet

MitraClip

PASCAL

FORMA

Annuloplasty

Trialign

Trialign

TriCinch

PASTA

Cardioband

VALVE TRICUSPIDE

48 ANS, MUSTARD, IT SEVÈRE

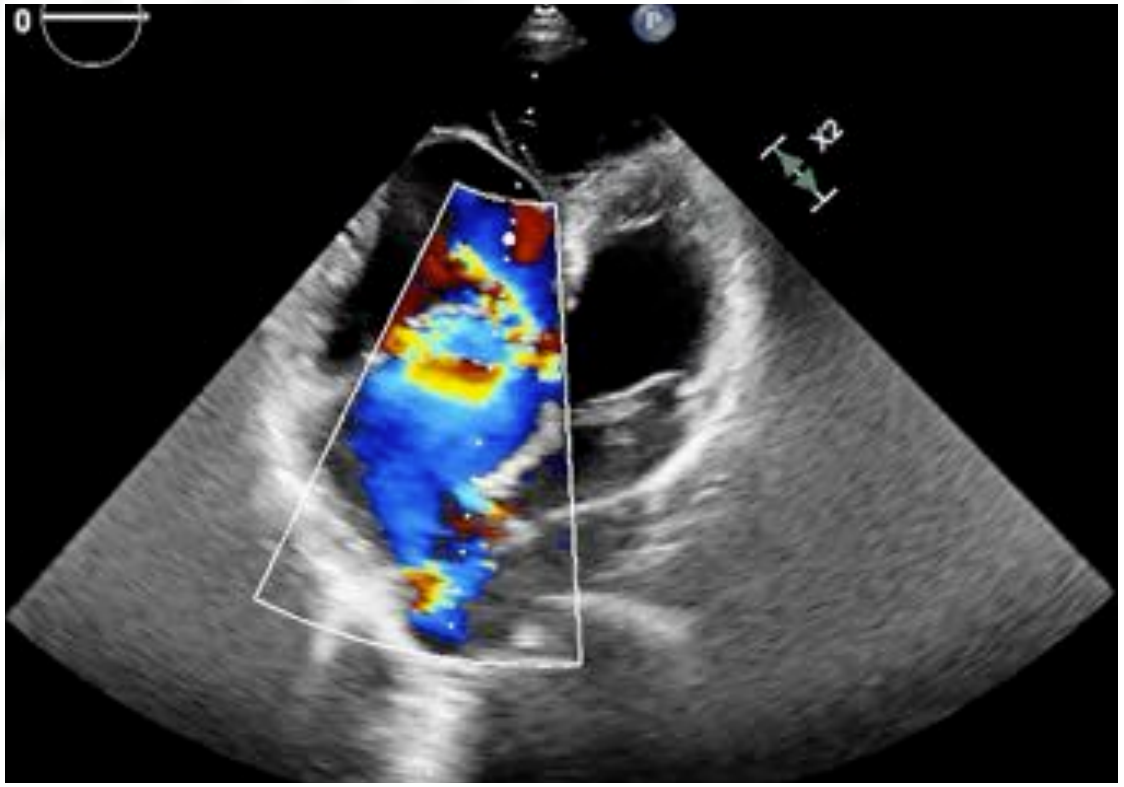

Ponction trans-baffle

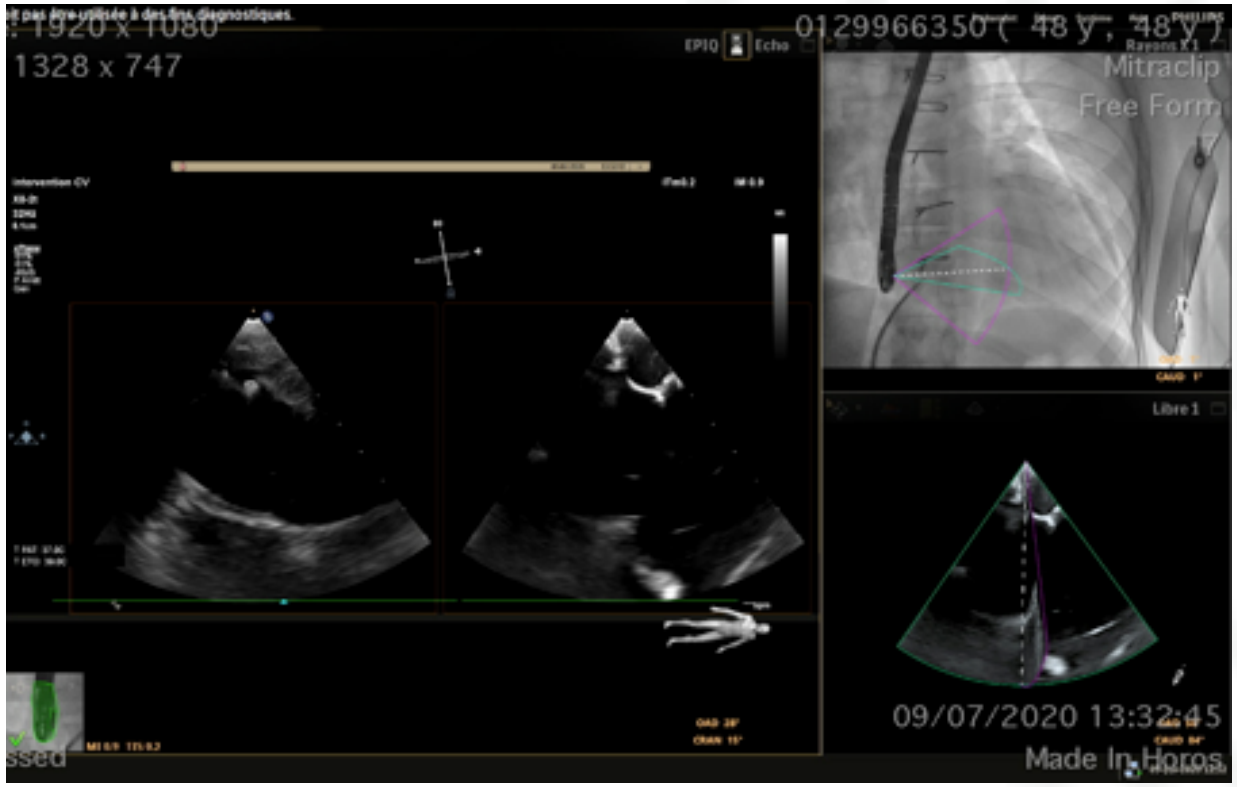

VALVE TRICUSPIDE

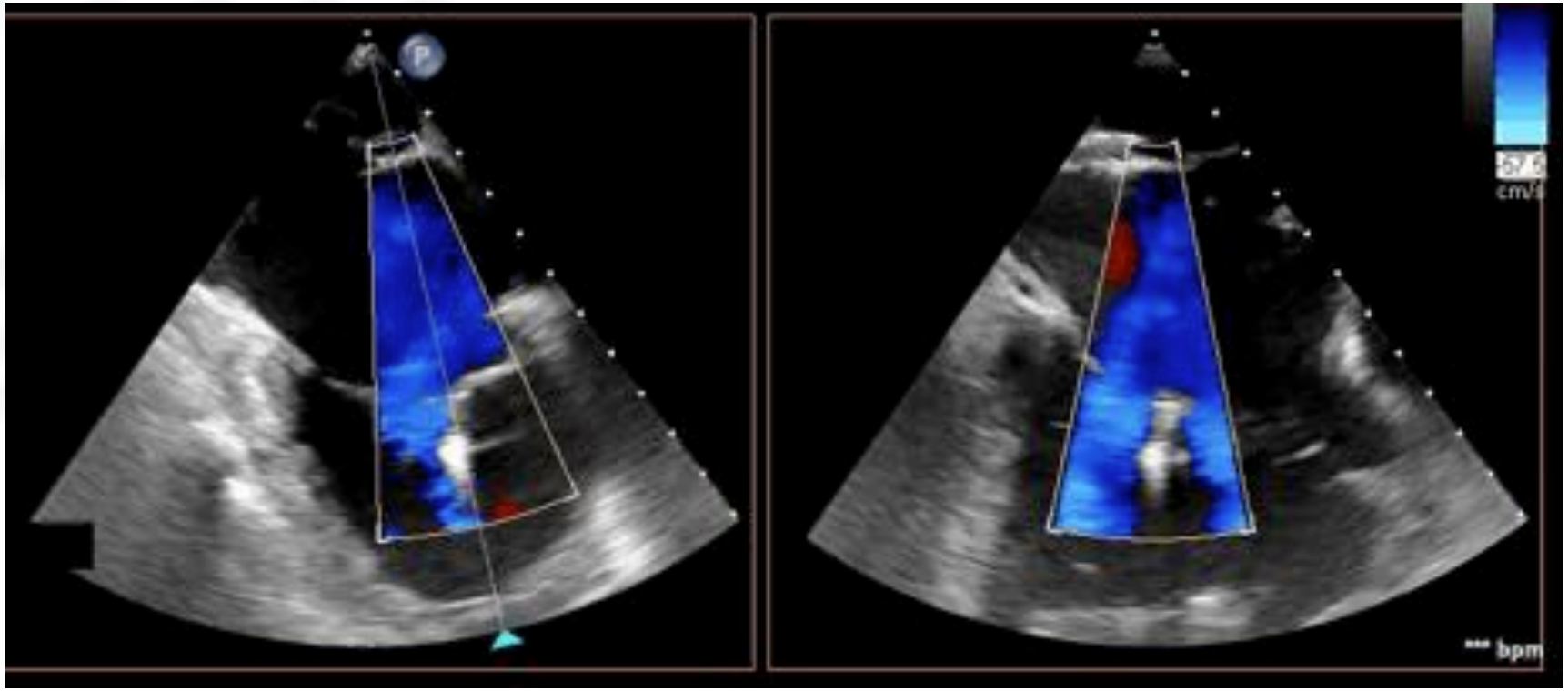

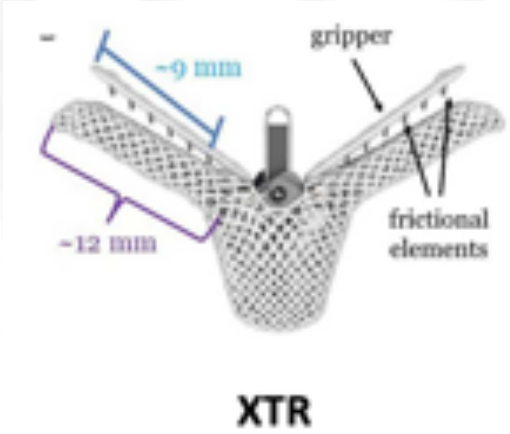

VALVE TRICUSPIDE

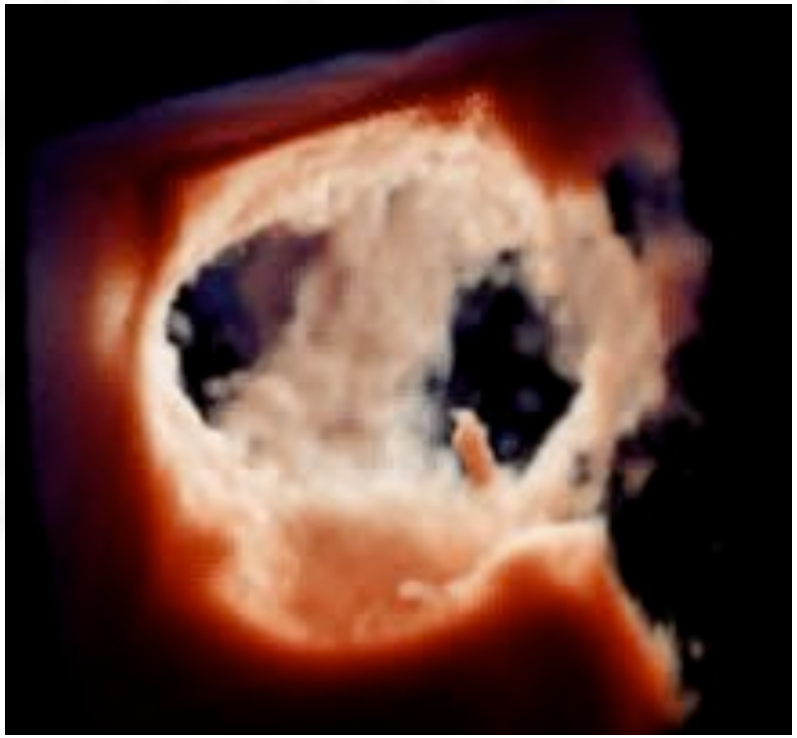

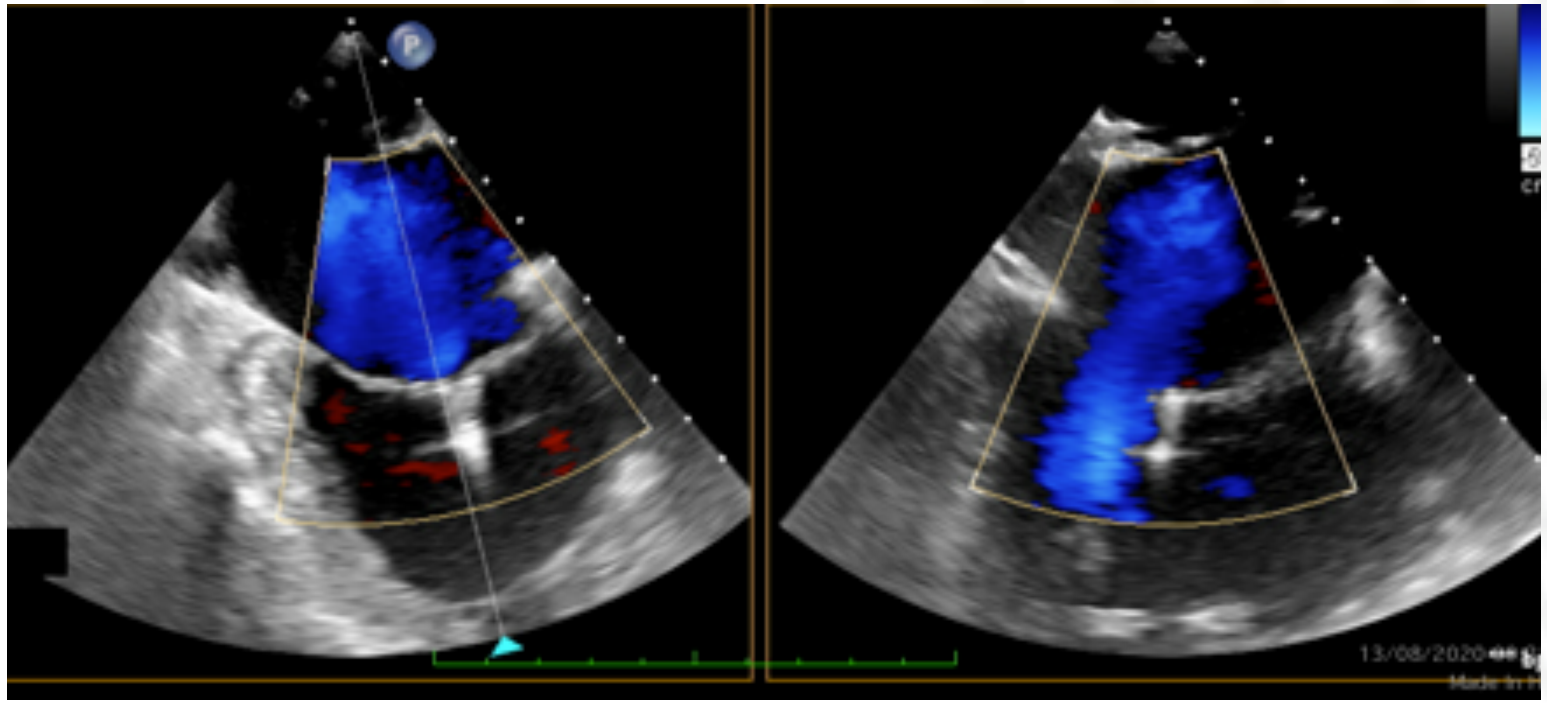

EXPECTATIONS

First-in-Human Closed-Chest Transcatheter Superior Cavopulmonary Anastomosis

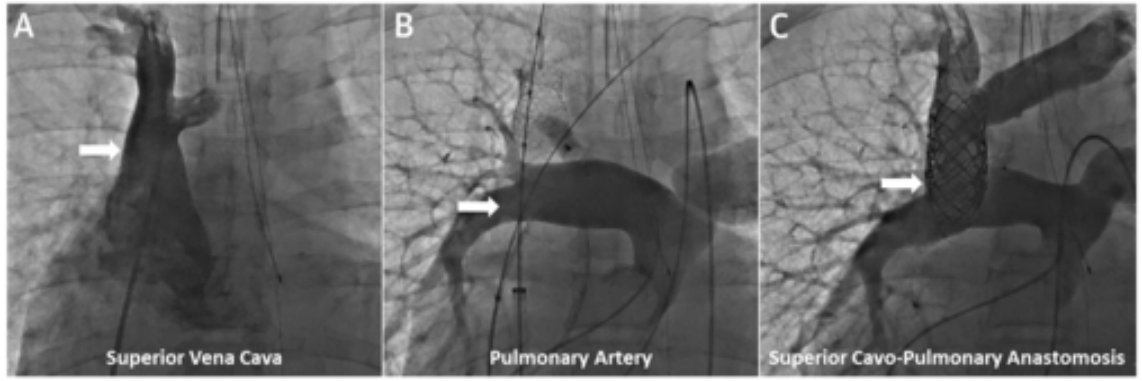

POTTS

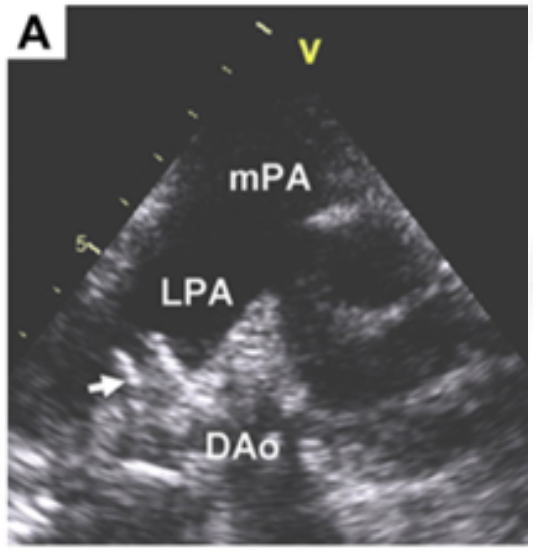

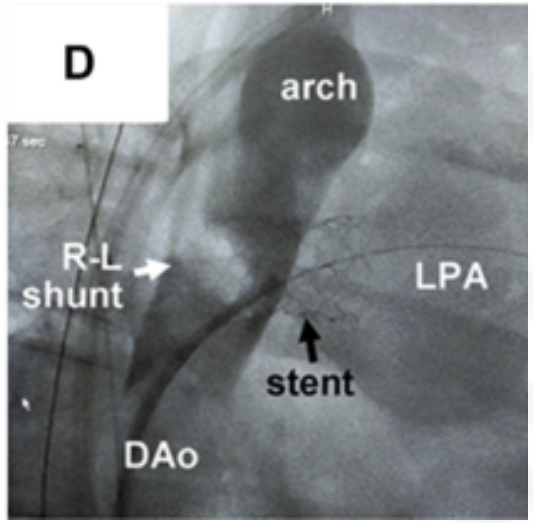

FONTAN

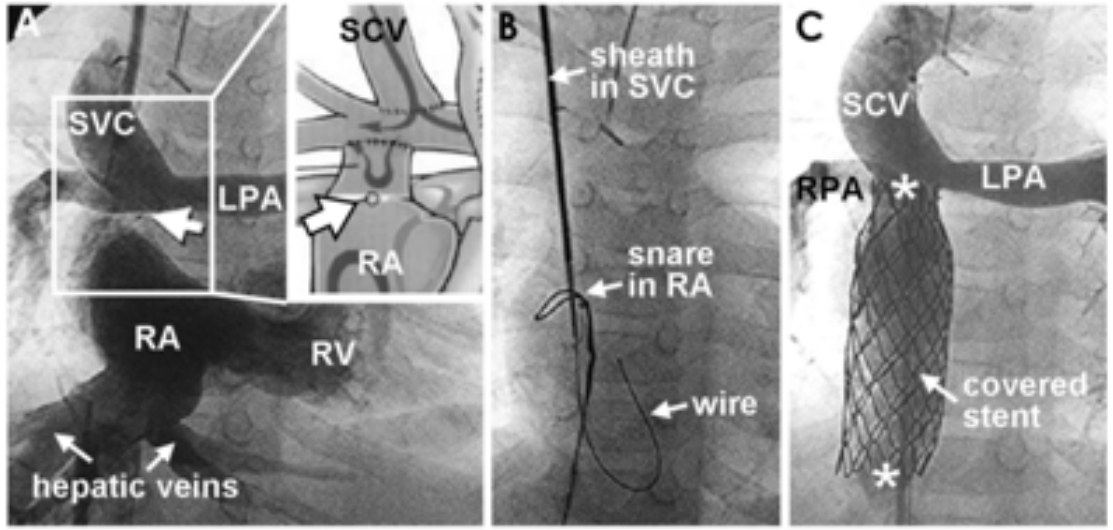

CONCLUSION

- New devices
- Dedicated material
- Extending indications
- Exponential
- Bioresorbable, BioEngineering
- Growing heart








L'INSTITUT DE RYTHMOLOGIE ET MODÉLISATION CARDIAQUE
BORDEAUX

MERCI POUR VOTRE ATTENTION

université de BORDEAUX
CHU Hôpitaux de Bordeaux
Inserm Institut national de la santé et de la recherche médicale
cnrs
Inria INVENTEURS DU MONDE NUMÉRIQUE