Persistance du canal artériel
Fenêtre aorto-pulmonaire

DIU réanimation des cardiopathies congénitales

Janvier 2021

Dr Amandine Martin – chirurgie cardiaque congénitale CHU Bordeaux

Canal artériel

Canal artériel : anatomie

- Communication aorte isthmique / toit de l'artère pulmonaire

- Environnement
  - Vaisseaux : aorte, artères pulmonaires
  - Nerfs : phrénique gauche, récurrent
  - Médiastin : ganglions, thymus
  - Poumon

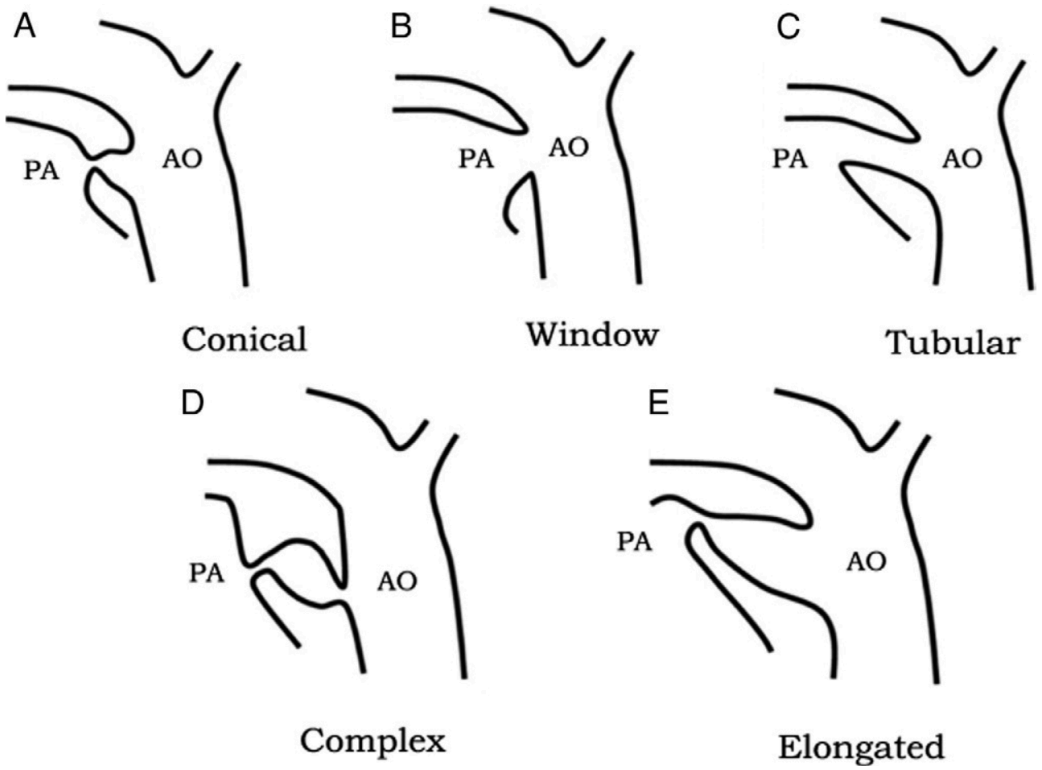

Figure 2 Variations in patent ductus arteriosus (PDA) configuration illustrated using the classification of Krichenko et al.[9] (A) Type A (conical) ductus, with well-defined aortic ampulla and constriction near the pulmonary artery end. (B) Very large type B (window) ductus, with very short length. (C) Type C (tubular) ductus, which is without constrictions. (D) Type D (complex) ductus, which has multiple constrictions. (E) Type E (elongated) ductus, with the constriction remote from the anterior edge of the trachea.

2012 Seminars in Perinatalogy Schneider

Canal artériel : indications

- Perméabilité du canal artériel
  - A l'adolescence : 25% endartérite

M.Abbott
Persistant patency of ductus arteriosus 1937

- Hyperdébit pulmonaire +/- hypodébit systémique
- Insuffisance cardiaque

- Perméabilité du canal artériel et prématuré
  - Si échec traitement médical

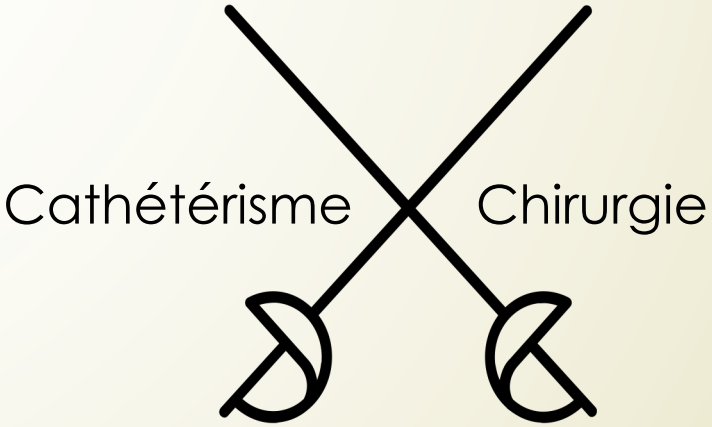

Canal artériel : indications

Schneider 2006 Circulation

- Perméabilité du canal artériel
  - A l'adolescence : 25% endartérite

M.Abbott
Persistant patency of ductus arteriosus 1937

- Hyperdébit pulmonaire +/- hypodébit systémique
- Insuffisance cardiaque

- Perméabilité du canal artériel et prématuré
  - Si échec traitement médical

Fermeture canal artériel : prématuré

- En réanimation néonatale
- Chirurgien pédiatrique général ou chirurgien cardiaque pédiatrique ou chirurgien cardiaque adulte

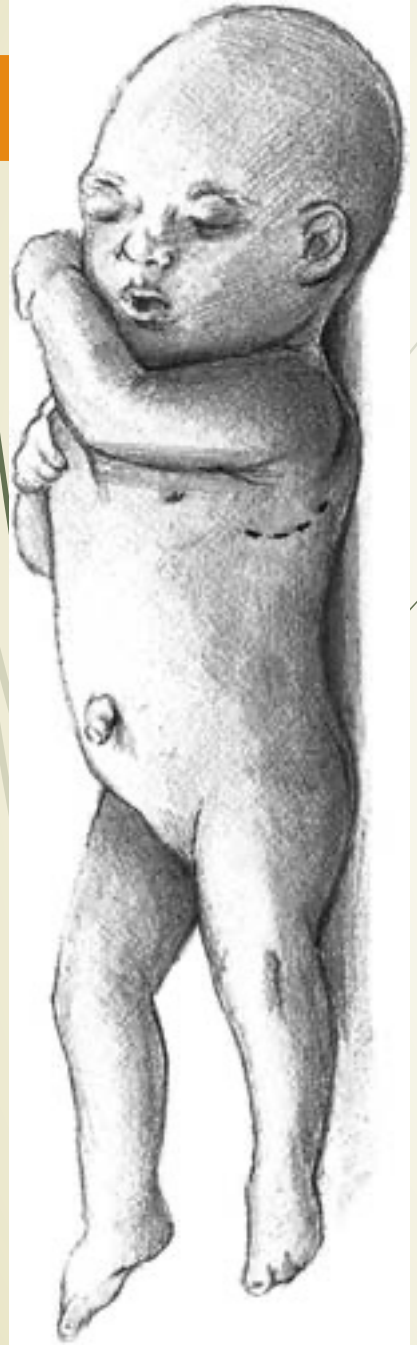

Canal artériel : chirurgie

- 1ère fermeture chirurgicale par Gross en 1937
  - Thoracotomie antéro-latérale gauche
- Thoracotomie postéro-latérale gauche +++
  - Installation en décubitus latéral droit, billot sous le thorax
  - Ouverture plèvre gauche vs voie extrapleurale
  - Poumon gauche comprimé pour l'exposition

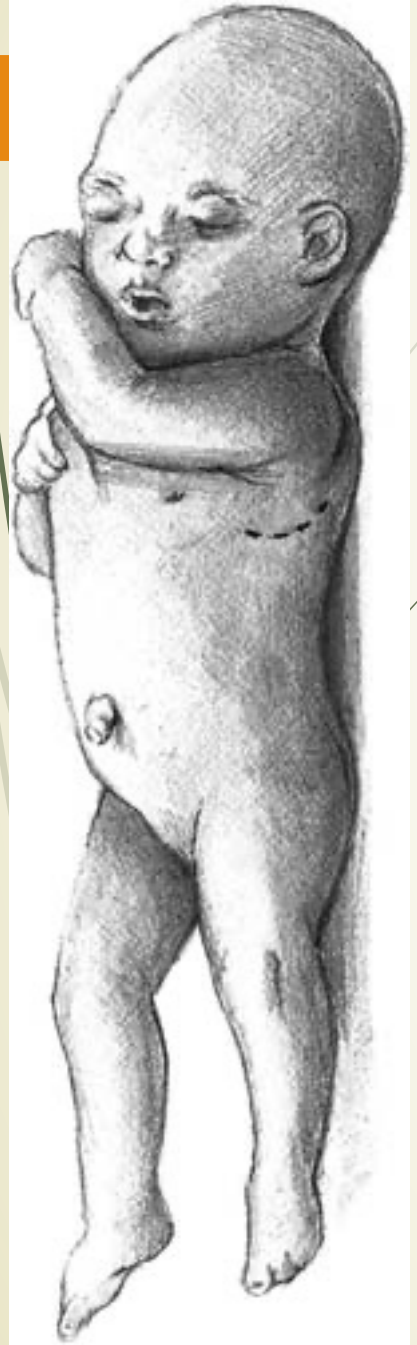

Canal artériel : chirurgie

- 1ère fermeture chirurg
  - Thoracotomie anté
- Thoracotomie postér
  - Installation en décu
  - Ouverture plèvre g
  - Poumon gauche c

Comprehensive surgical management of congenital heart disease
Jonas

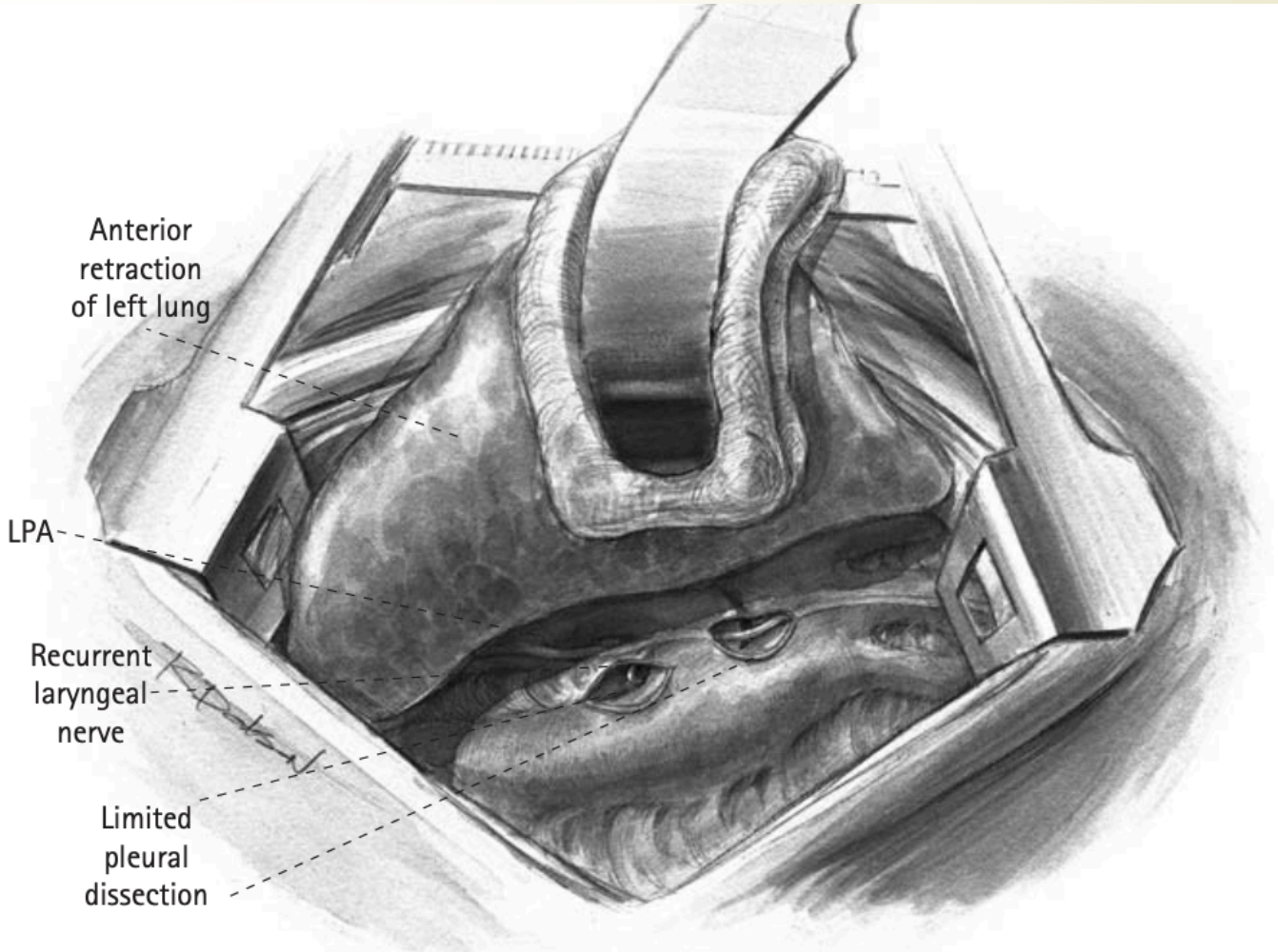

Canal artériel : chirurgie

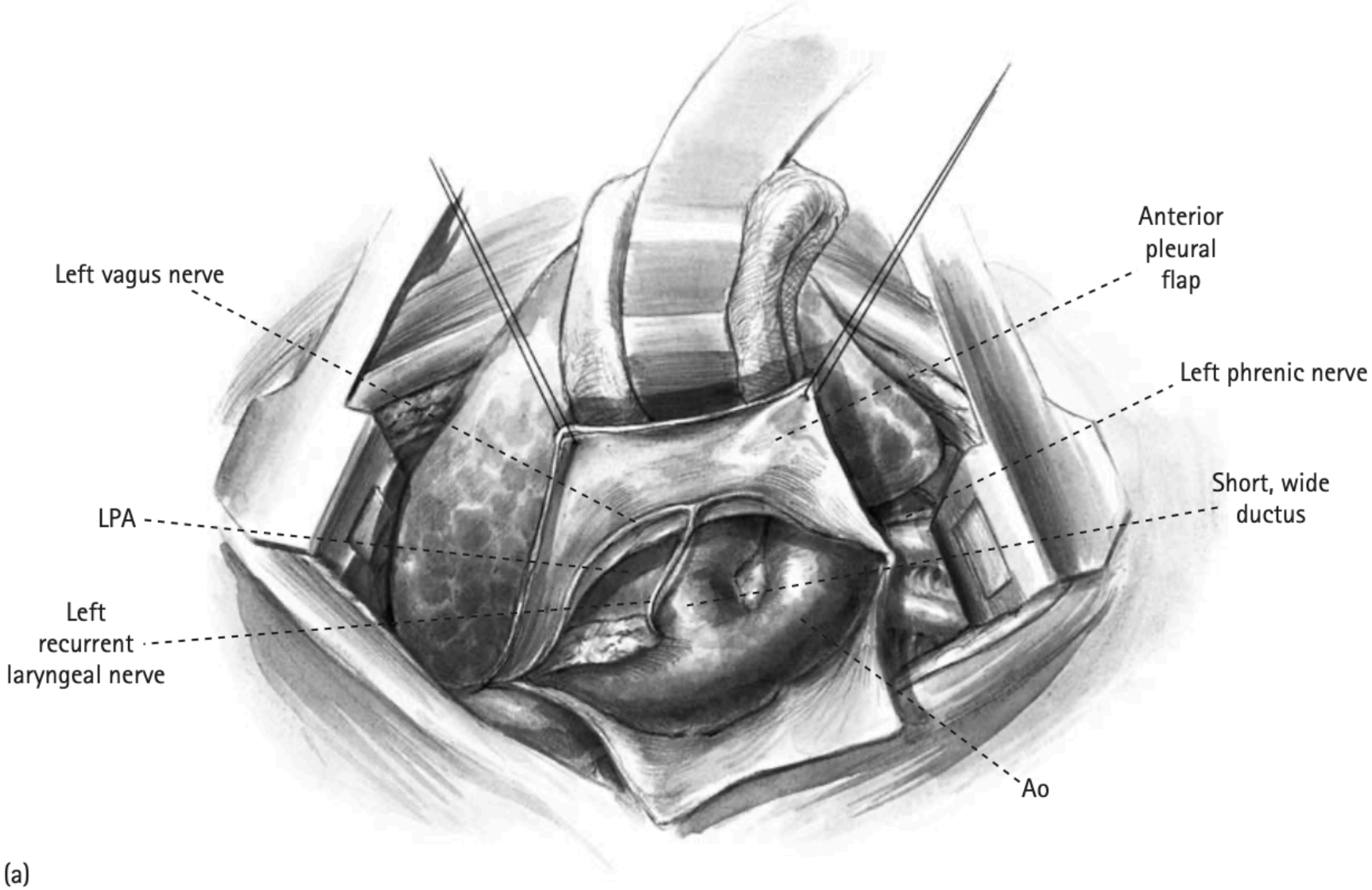

Comprehensive surgical management of congenital heart disease
Jonas

Canal artériel : chirurgie

Complications

- ***Hémorragie/Plaie canal artériel***
- Pneumothorax
- Chylothorax
- Paralysie corde vocale gauche
- Sténose APD
- Coarctation aortique
- Ligature aorte descendante ou APG
- Shunt résiduel

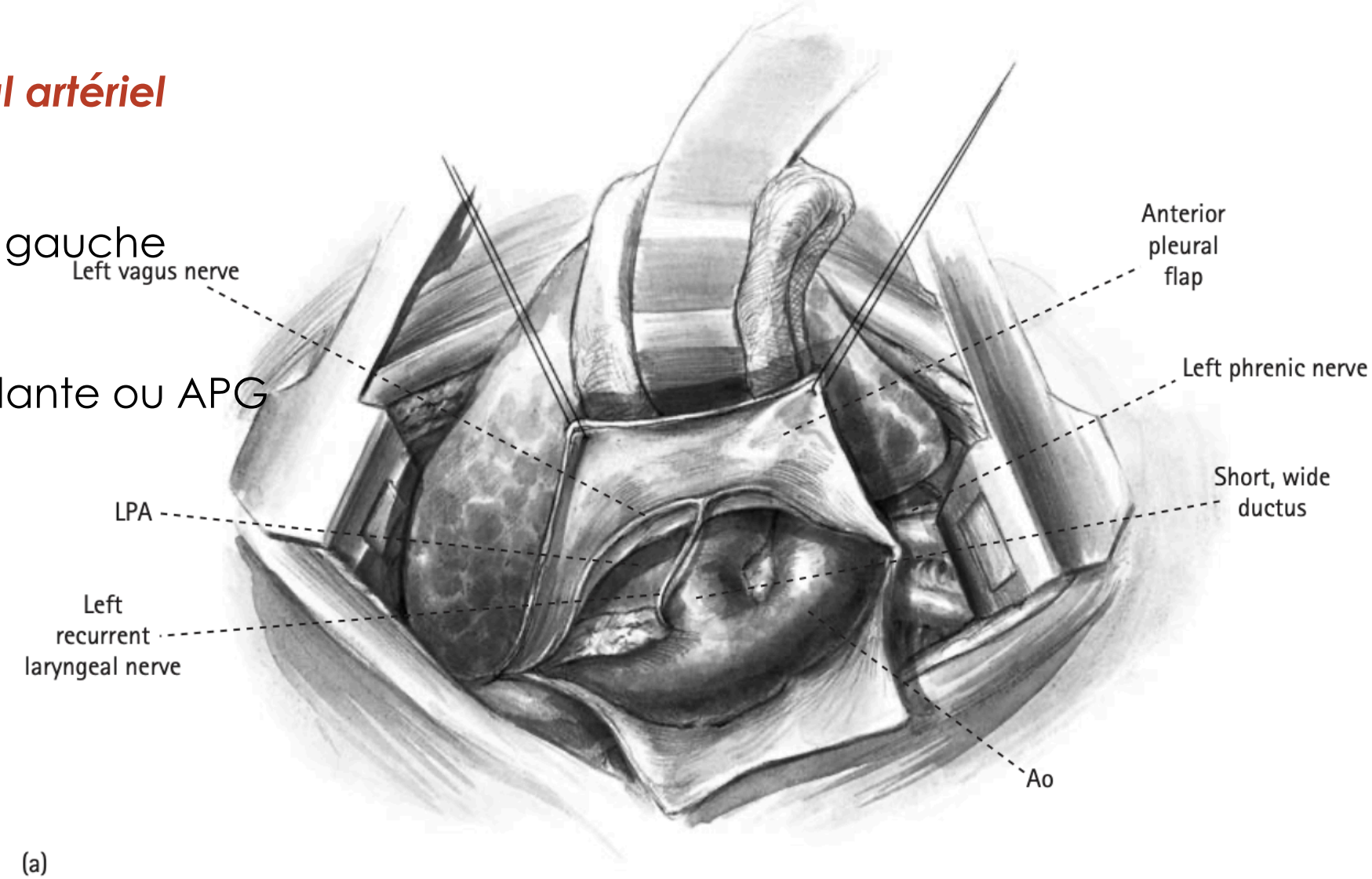

Comprehensive surgical management of congenital heart disease
Jonas

Canal artériel : chirurgie

Complications

- ***Hémorragie/Plaie canal artériel***
- Pneumothorax
- Chylothorax
- Paralysie corde vocale gauche
- Sténose APD
- Coarctation aortique
- Ligature aorte descendante ou APG
- Shunt résiduel

Comprehensive surgical management of congenital heart disease
Jonas

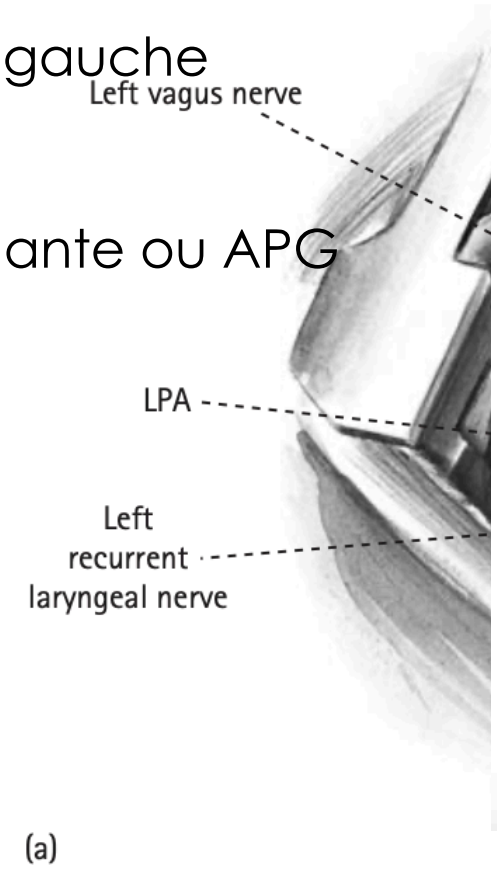

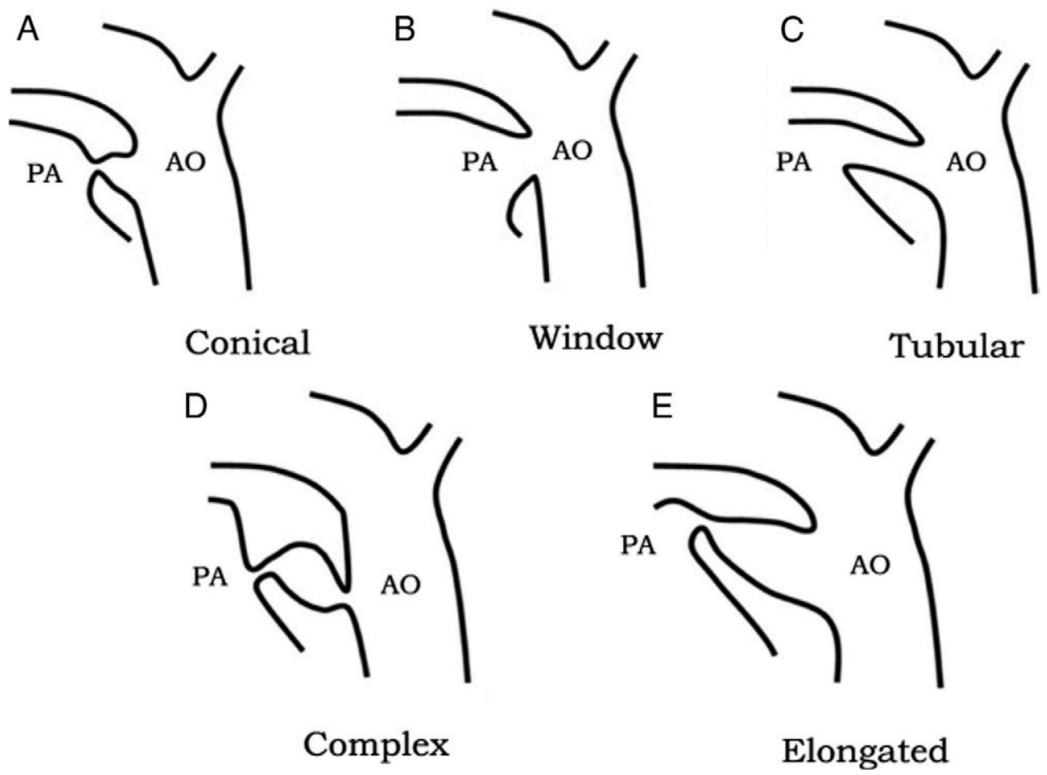

Figure 2 Variations in patent ductus arteriosus (PDA) configuration illustrated using the classification of Krichenko et al.[9] (A) Type A (conical) ductus, with well-defined aortic ampulla and constriction near the pulmonary artery end. (B) Very large type B (window) ductus, with very short length. (C) Type C (tubular) ductus, which is without constrictions. (D) Type D (complex) ductus, which has multiple constrictions. (E) Type E (elongated) ductus, with the constriction remote from the anterior edge of the trachea.

2012 Seminars in Perinatalogy Schneider

Fermeture canal artériel : chirurgie

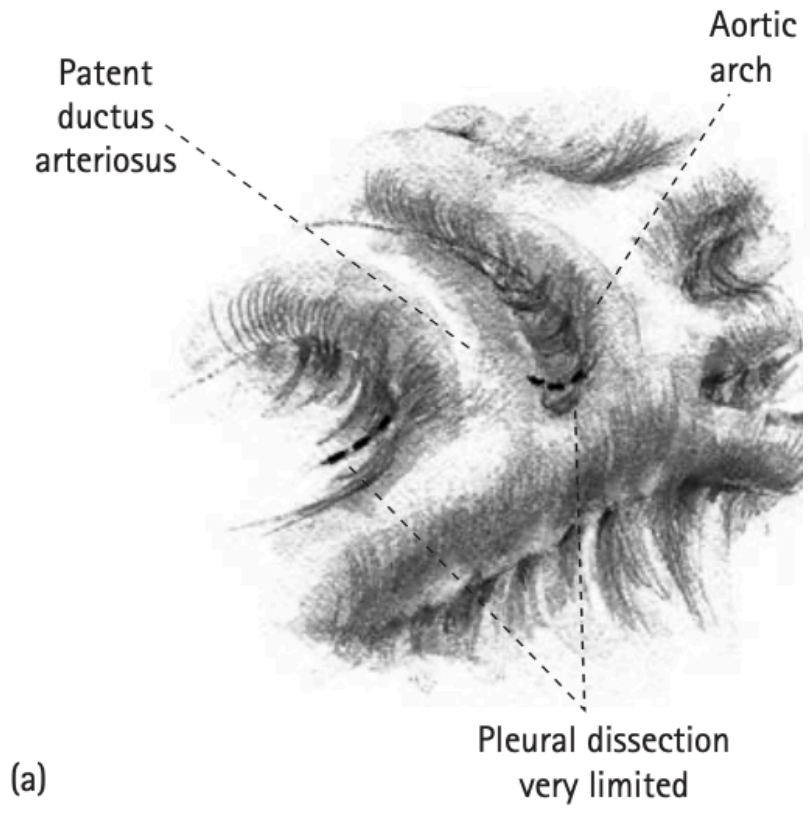

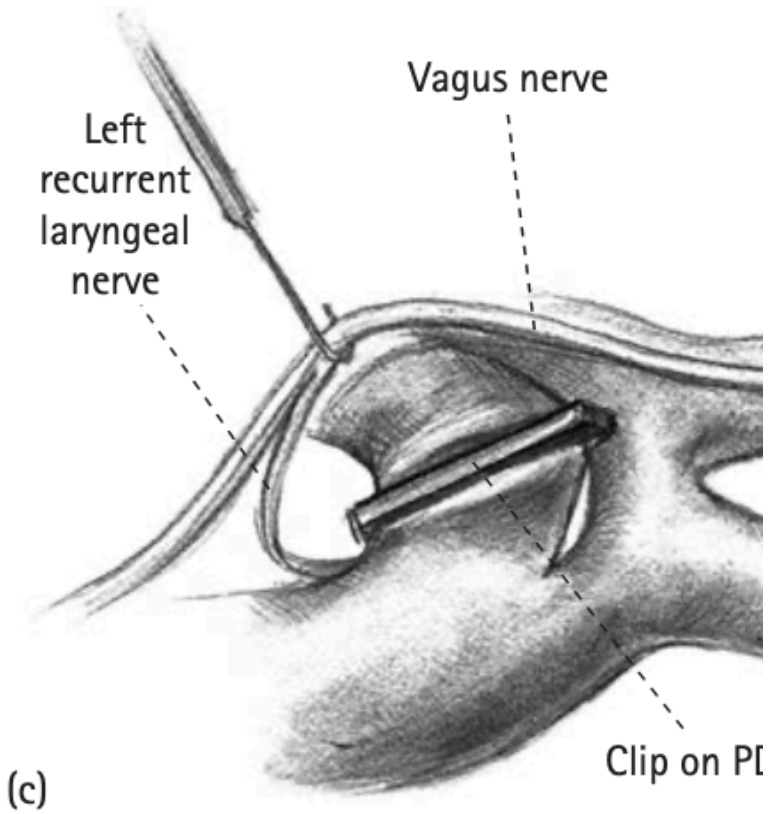

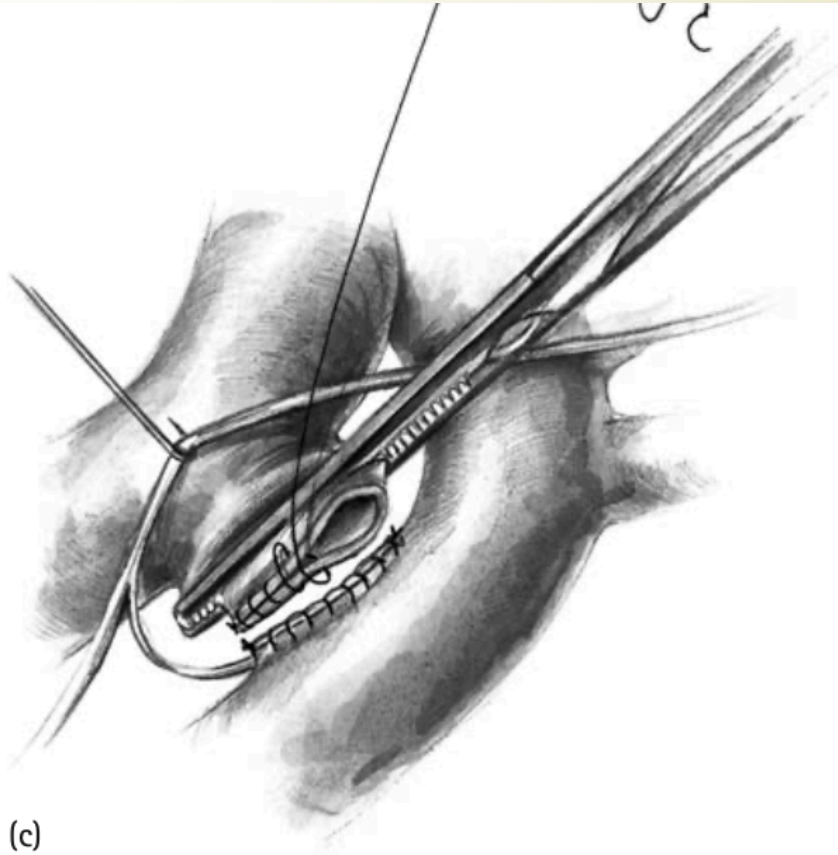

Comprehensive surgical management of congenital heart disease
Jonas

Canal artériel : voie antérieure

- Accessible prématurés
- Thoracotomie antérieure gauche 3ème espace intercostal (décubitus dorsal)
- Ouverture pleurale gauche

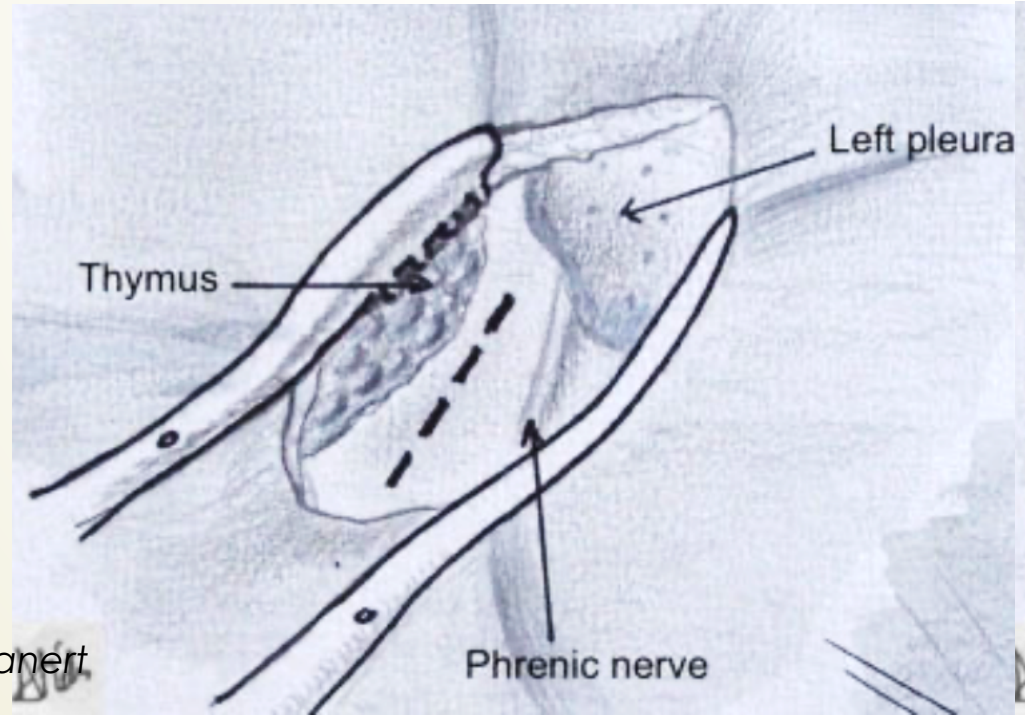

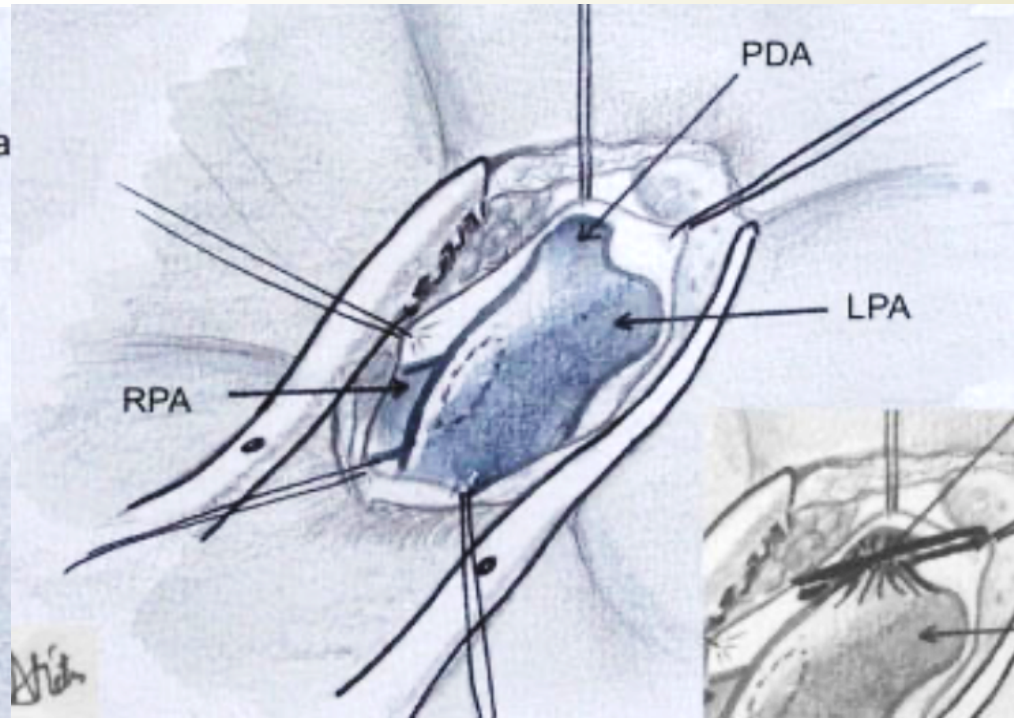

2014 Eur J Ped Surg, Fouilloux
2020 Arch Cardiovasc Dis, Wanert

Canal artériel : chirurgie mini-invasive

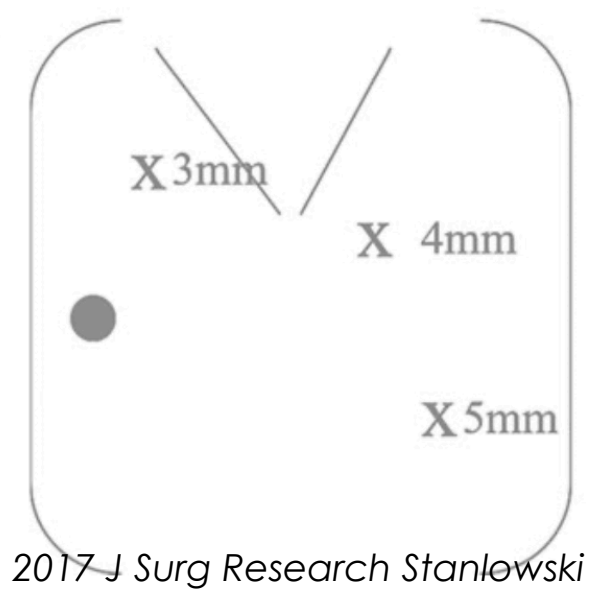

2017 J Surg Research Stanlowski

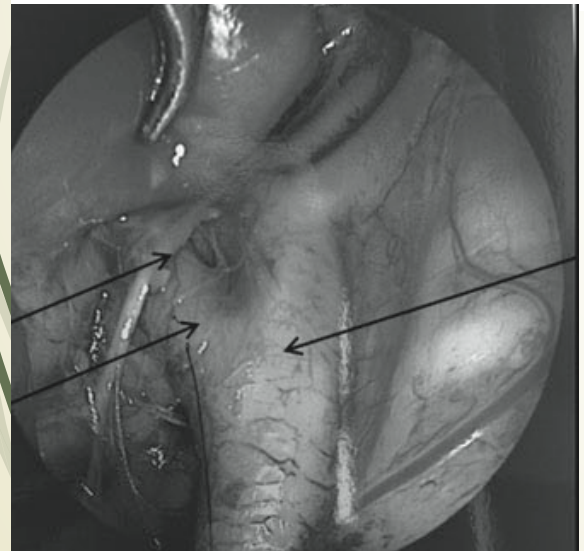

- 3 à 4 petites incisions
- Temps opératoires augmentés

- Poids > 3kg
- Matériel adapté

Canal artériel : chirurgie mini-invasive

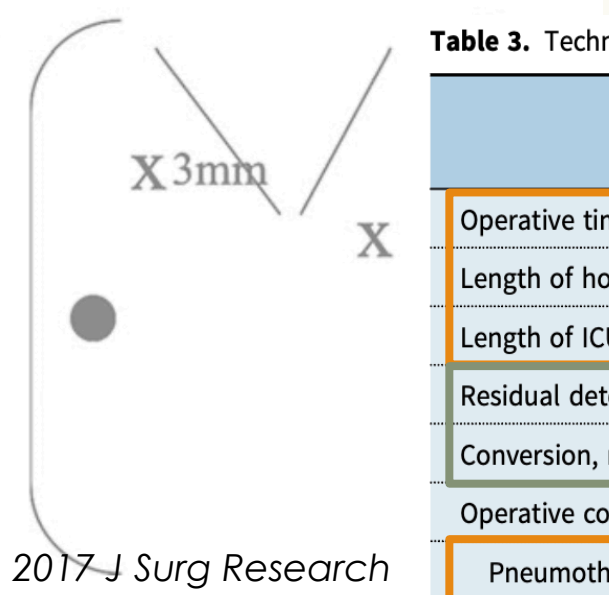

2017 J Surg Research

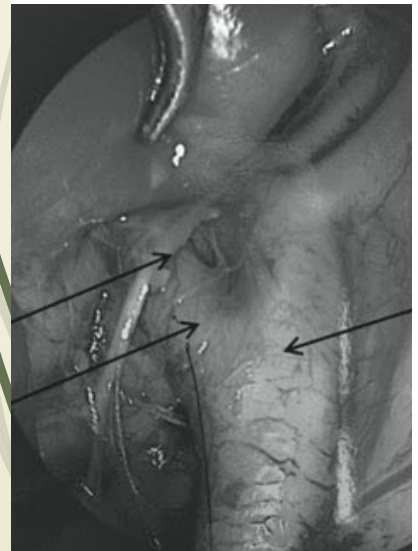

Table 3. Technical indices

	Unmatched cohorts (n)			Matched cohorts (n)		
	VATS (127)	Thoracotomy (46)	p-value	VATS (69)	Thoracotomy (20)	p-value
Operative time (minutes), median (IQR)	87 (56–103)	56 (40–69)	<0.001	81 (56–101)	56 (42–83)	0.007
Length of hospital stay (days), median (IQR)	1.05 (0.91–1.31)	2.41 (1.99–3.84)	<0.001	1.25 (1–2.03)	2.27 (2.02–3.22)	<0.001
Length of ICU stay (days), median (IQR)	0.00 (0.00–0.00)	0.75 (0.00–1.07)	<0.001	0.00 (0.00–0.06)	0.86 (0–1.01)	0.01
Residual detected during hospitalisation, n (%)	7 (6)	0 (0)	0.192	4 (6)	0 (0)	0.571
Conversion, n (%)	7 (6)	N/A	N/A	6 (8.7)	N/A	N/A
Operative complications						
Pneumothorax, n (%)	4 (3)	1 (2)	0.735	4 (6)	1 (5)	0.999
Pleural effusion, n (%)	0 (0)	0 (0)	0.999	0 (0)	0 (0)	N/A
Chylothorax, n (%)	2 (2)	0 (0)	0.999	2 (3)	0 (0)	0.999
Isolated chest tube placement, n (%)	14 (11)	23 (50)	<0.001	12 (17)	12 (60)	<0.001
Transfusion, n (%)	0 (0)	2 (4)	0.070	0 (0)	1 (5)	0.223
Infection, n (%)	1 (1)	0	0.999	1 (1)	0 (0)	0.999
Vocal cord injury, n (%)	0 (0)	1 (2)	0.266	0 (0)	1 (5)	0.225
Other, n (%)	1 (1)*	1 (2)**	0.462	1 (1)*	1 (5)**	0.345
Total, n (%)	8 (6)	5 (11)	0.335	8 (11.6)	4 (20)	0.456

Abbreviations: VATS = video-assisted thoracoscopic surgery; IQR = interquartile range.
*Ductal bleeding.

2020 Wei Cardiology in the Young

Fenêtre aorto-pulmonaire

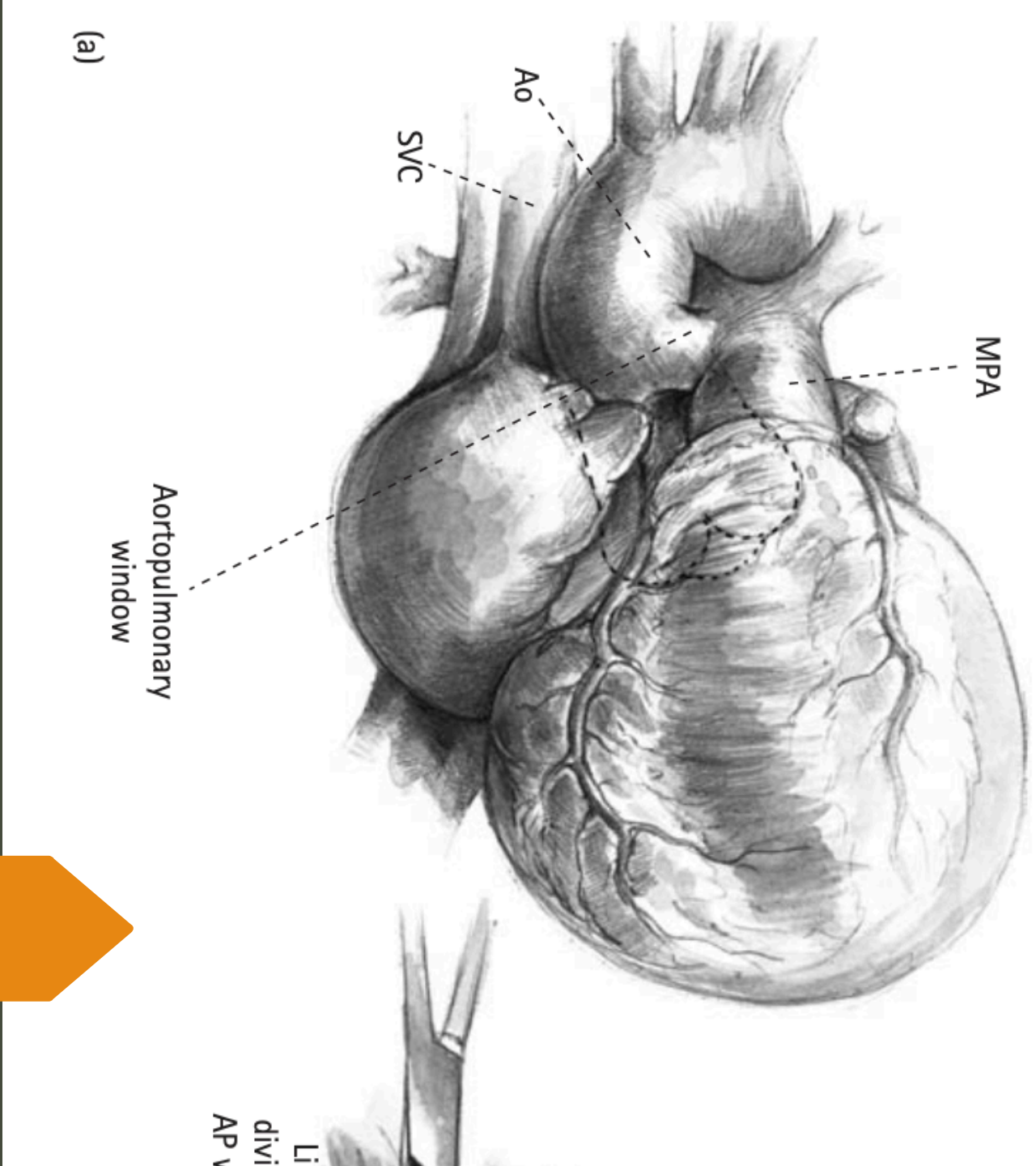

Fenêtre aorto-pulmonaire : classification

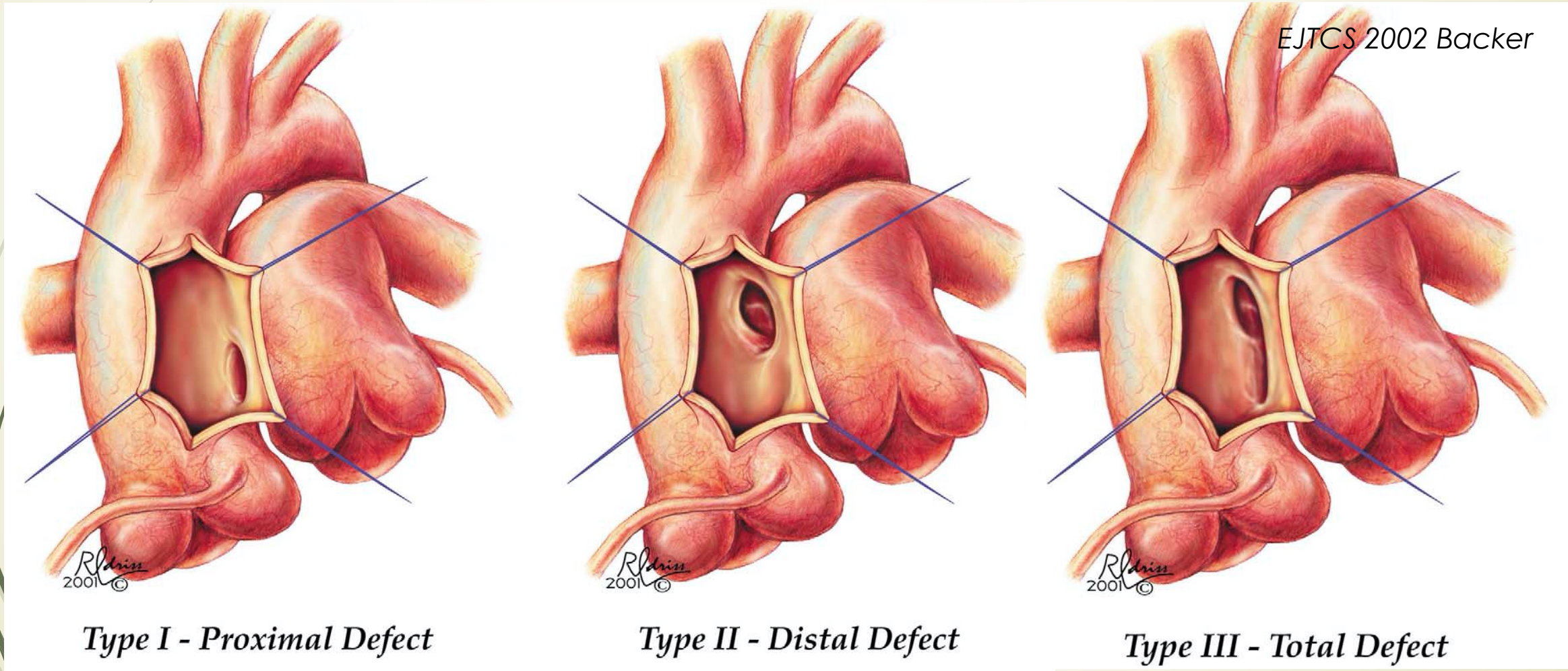

Fenêtre aorto-pulmonaire : indications

- Sa présence !

- Insuffisance cardiaque gauche
- Hyperdébit pulmonaire

- Lésions associées (50%)
  - Interruption de l'arche aortique
  - CIA, CIV

Fenêtre

- Ligature simple (Gross 1952)
- Clamp-and-Sew (1953)
- Abord fenêtre AP
- Abord aortique
- Abord pulmonaire

- ***Non utilisé***

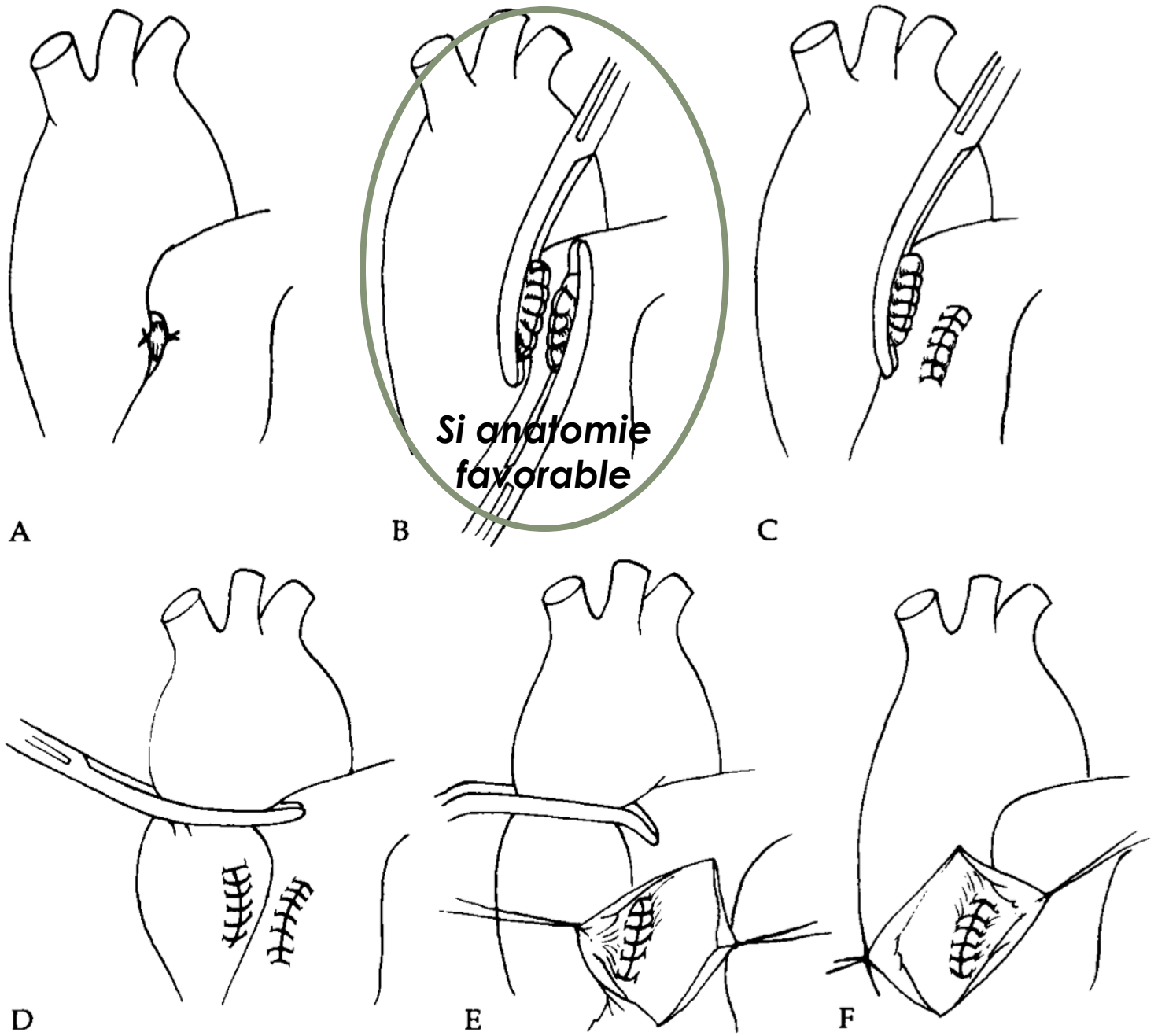

1978 Ann Thor Surg Johansson

Fenêtre aorto-pulmonaire : chirurgie

- Sternotomie
- Observation
  - Fenêtre aorto-pulmonaire
  - Origine des artères pulmonaires
  - Origine des artères coronaires
- Circulation extra-corporelle OD-Aorte
- Cardioplégie antérograde dans l'aorte ascendante
  - Clampage des artères pulmonaires droite et gauche
  - Ligature du canal artériel si perméable

Fenêtre aorto-pulmonaire : chirurgie

- Sternotomie
- Observation
  - Fenêtre aorto-pulmonaire
  - Origine des artères pulmonaires
  - Origine des artères coronaires
- Circulation extra-corporelle OD-
- Cardioplégie antérograde dans
  - Clampage des artères pulmonc
  - Ligature du canal artériel si perr

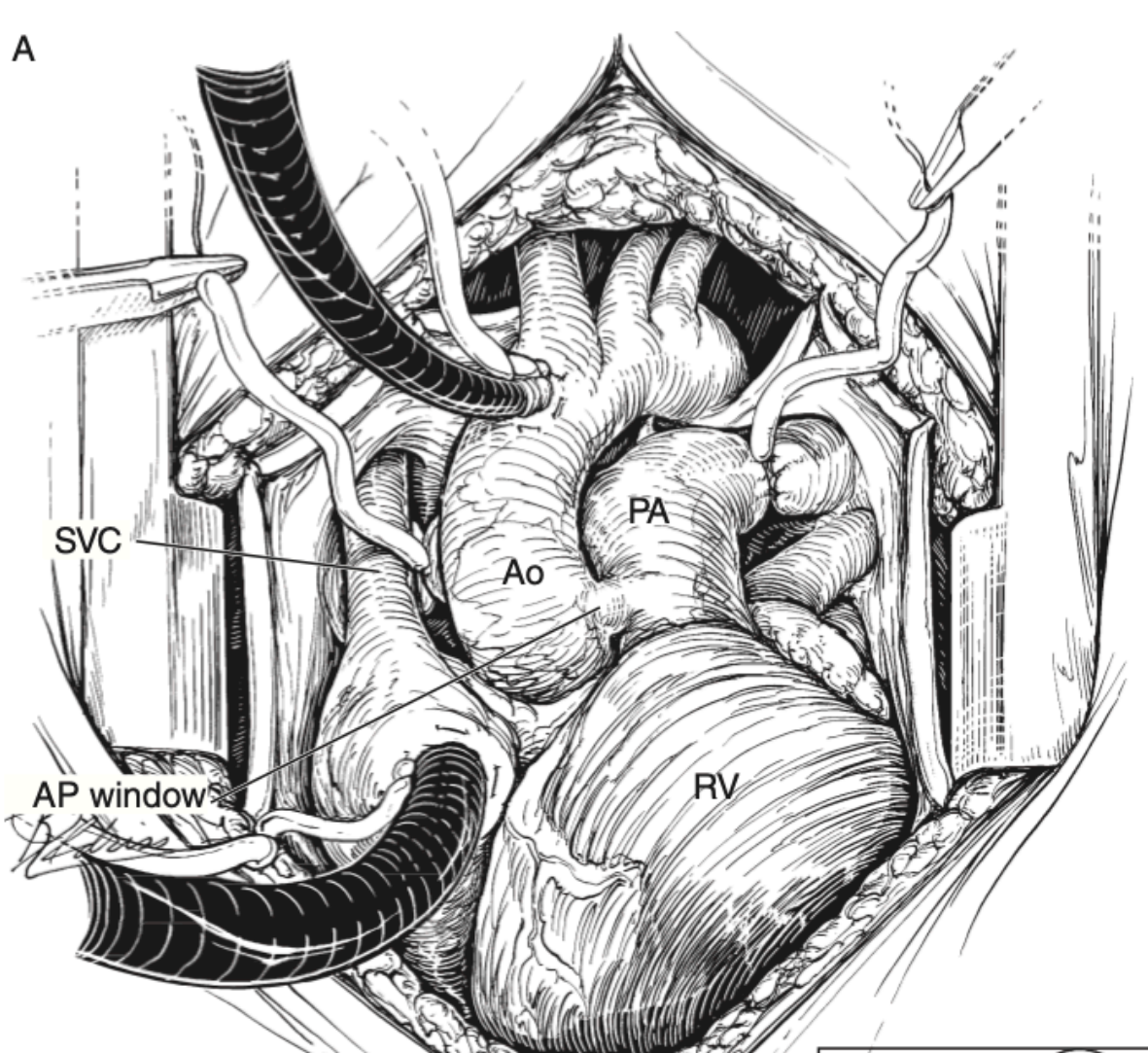

Fenêtre aorto-pulmonaire : chirurgie

- Ouverture de la fenêtre aorto-pulmonaire
- Fermeture de la communication par un patch de cloisonnement (« sandwich »)

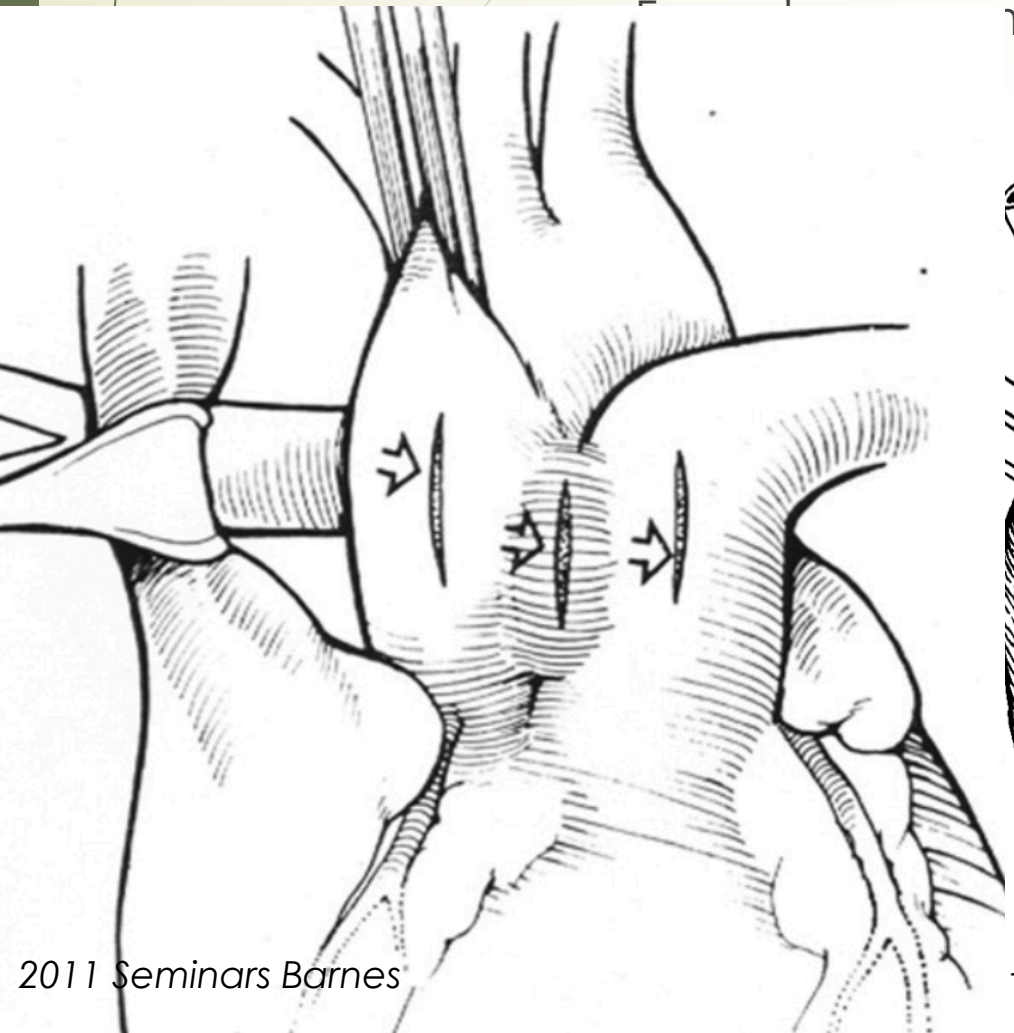

2011 Seminars Barnes

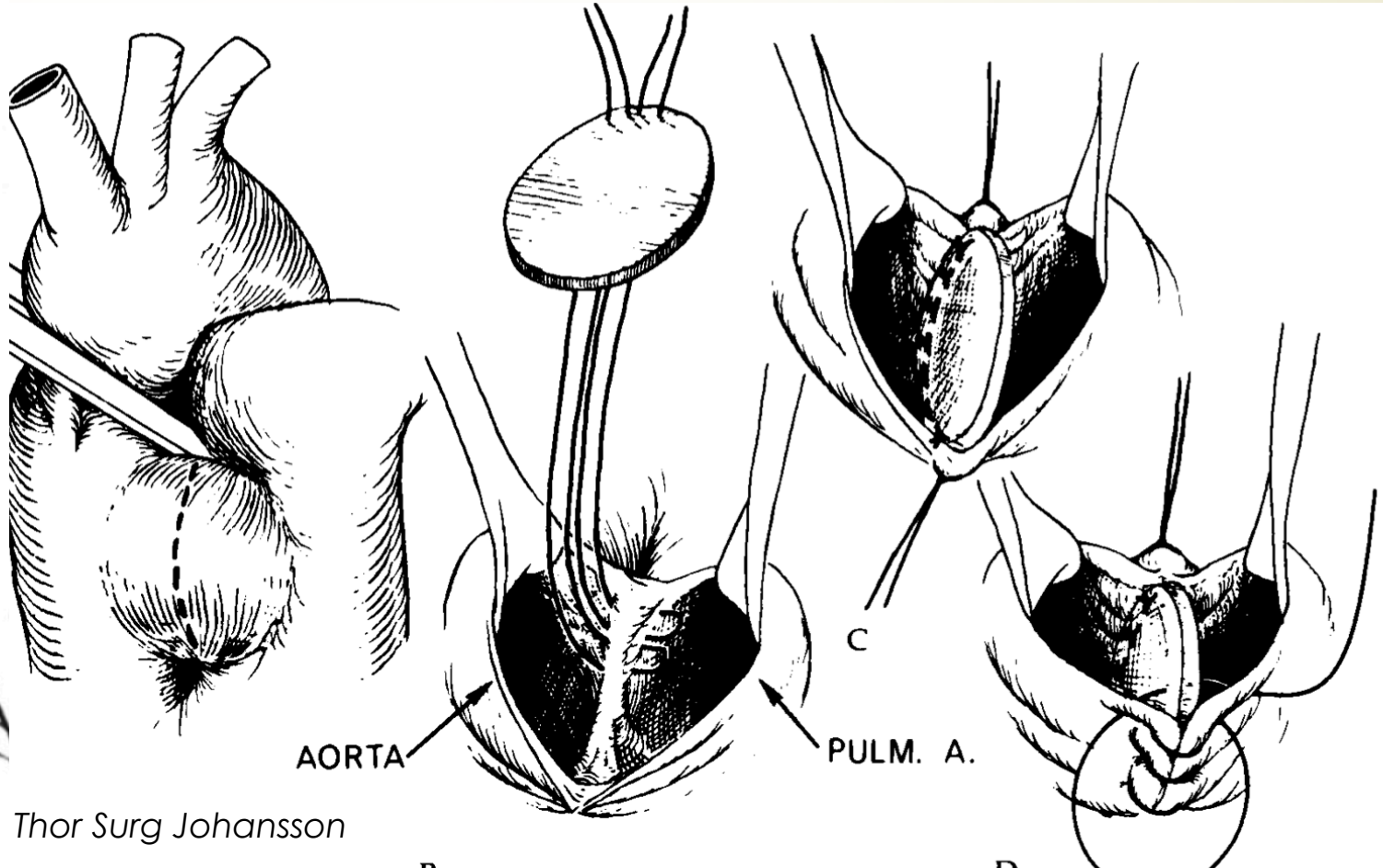

Thor Surg Johansson

Fenêtre aorto-pulmonaire : chirurgie

- Ouverture de la fenêtre aorto-pulmonaire
- munication par un patch de cloisonnement (« sandwich »)

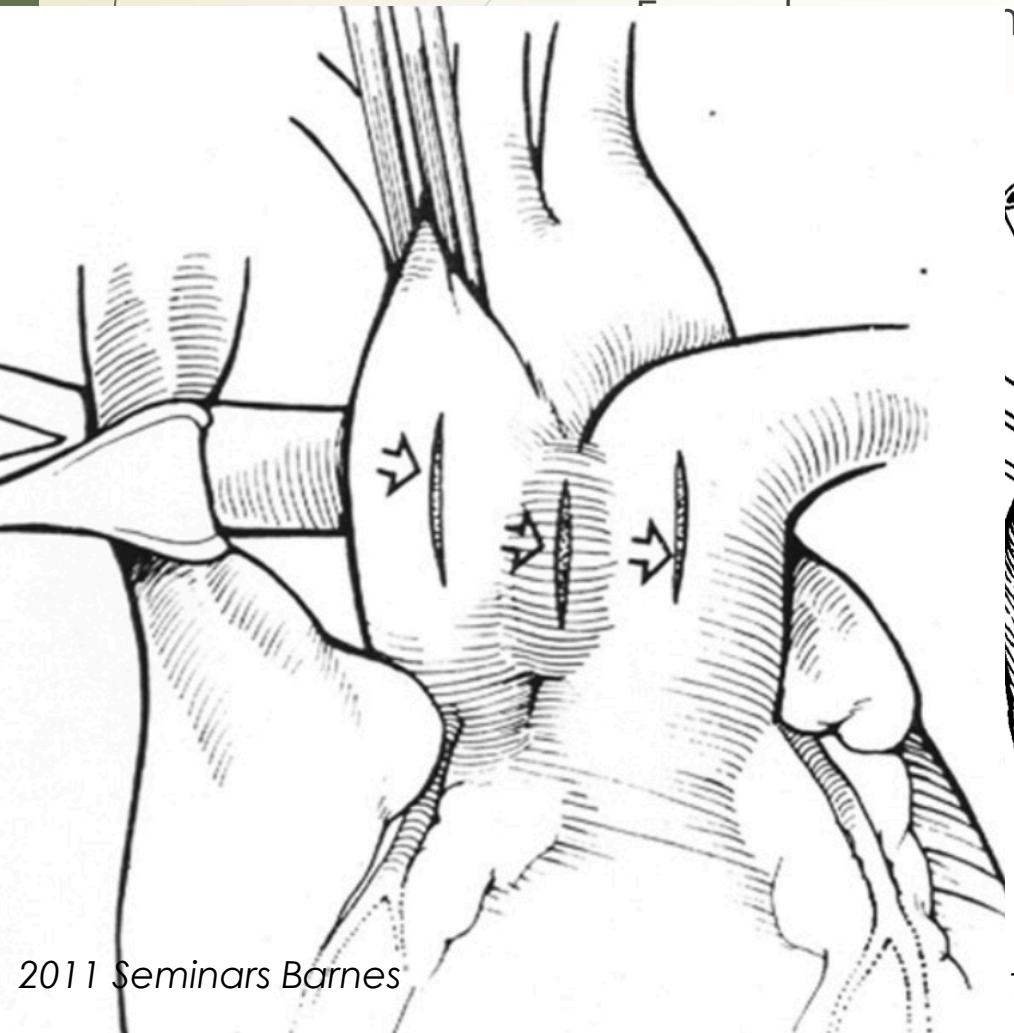

2011 Seminars Barnes

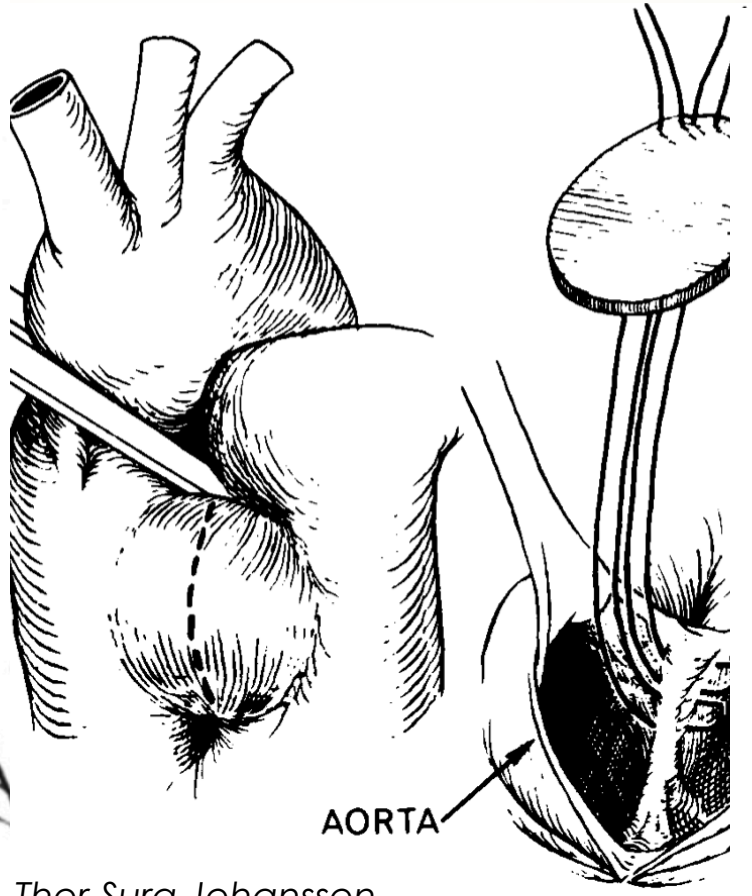

Thor Surg Johansson

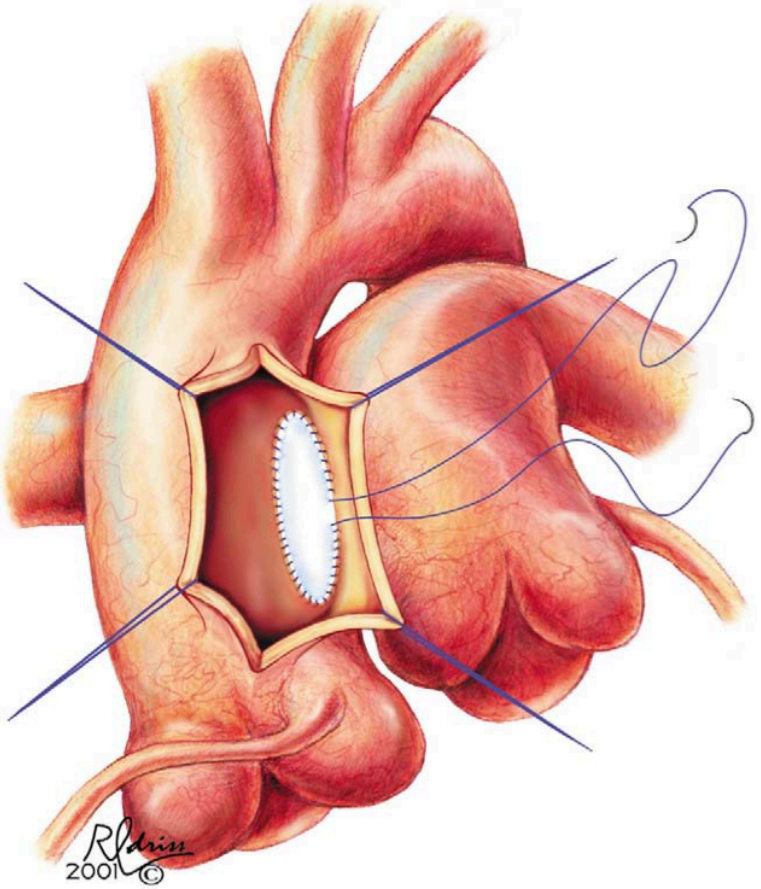

Fenêtre aorto-pulmonaire : chirurgie

- Ouverture de la fenêtre aorto-pulmonaire
- Fermeture communication par deux patchs

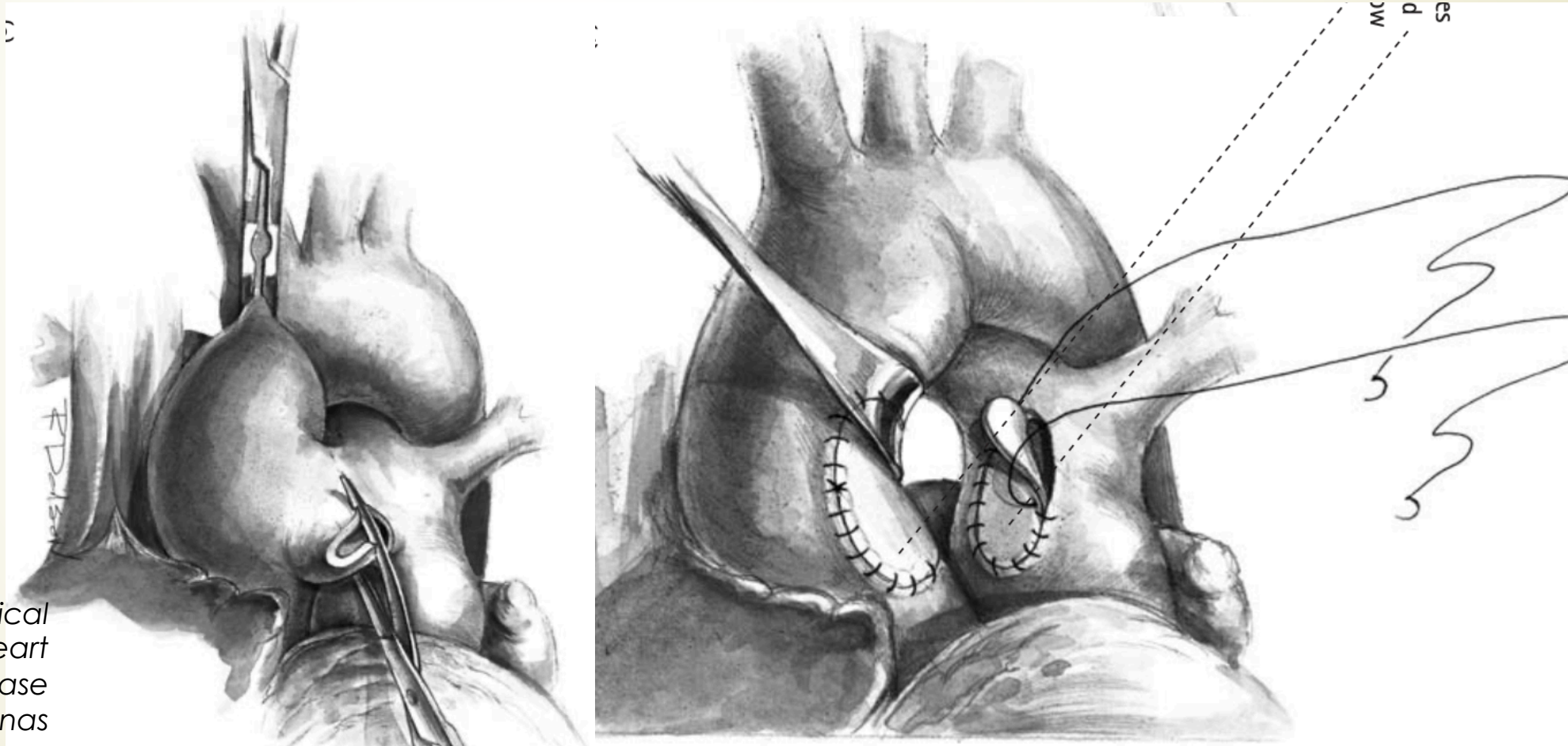

Comprehensive surgical management of congenital heart disease
Jonas

Fenêtre aorto-pulmonaire : chirurgie

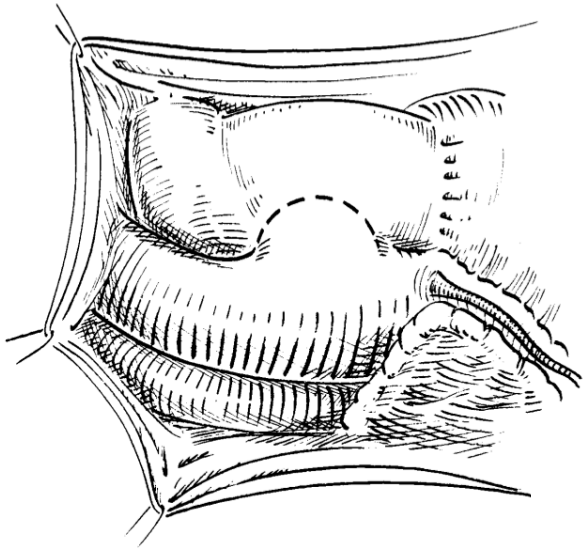

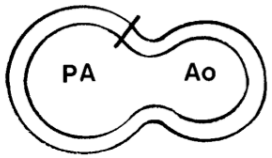

Fig 1. Line of incision on the main pul
cending aorta; PA = *main pulmonary*

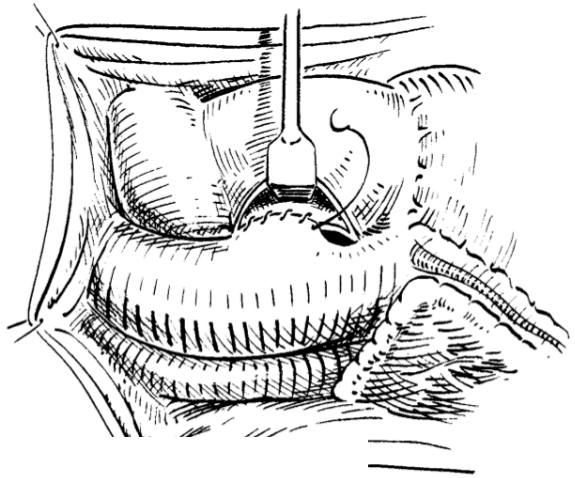

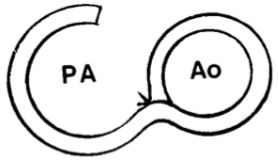

is sutured to the posterior margin of the
Ao = ascending aorta; PA = *main pul-*

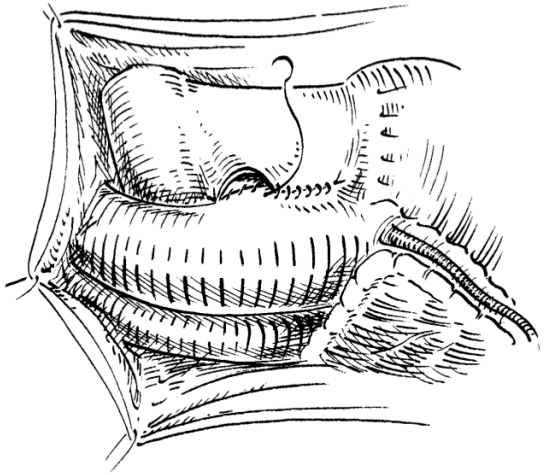

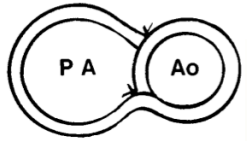

*Fig 3. The cut edge of the pulmonary artery is sutured to the adventitia of the aortic wall. (*Ao = *ascending aorta;* PA = *main pulmonary artery.)*

1998 Ann Thor Surg Di Bello

Fenêtre aorto-pulmonaire et interruption de l'arche aortique

2015 Ann Thor Surg Roubertie

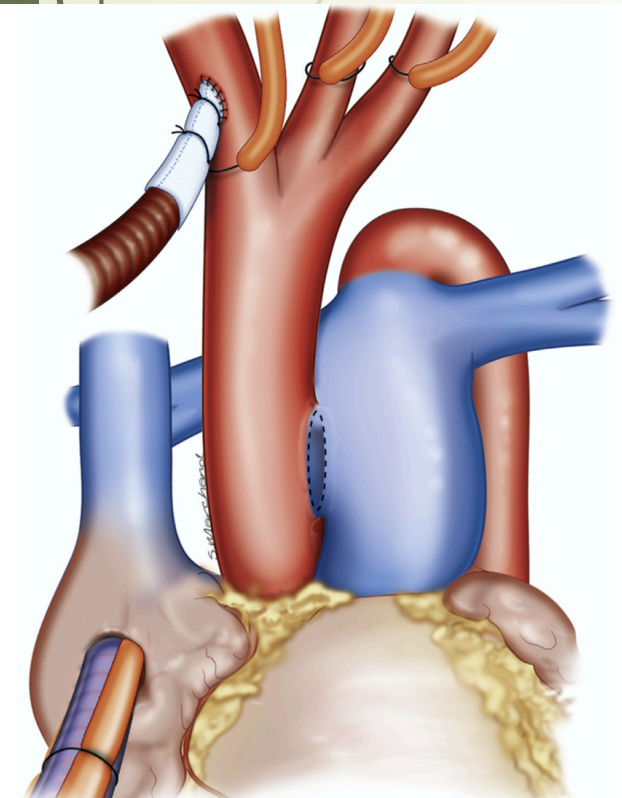

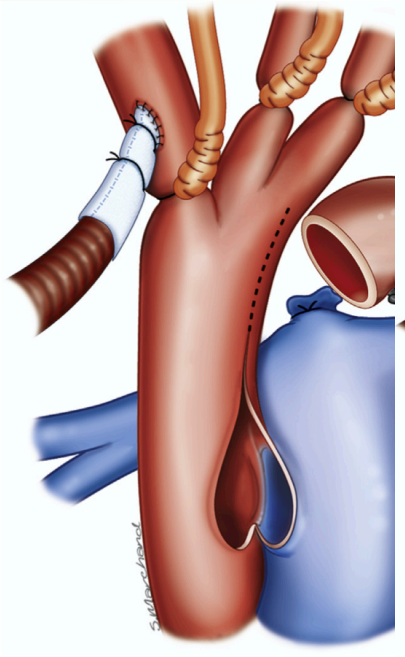

Fig 2. The arch vessels are occluded with sna
rebral perfusion is performed.The aortopulmor
and the incision is continued on to the ascendin
(dashed line).

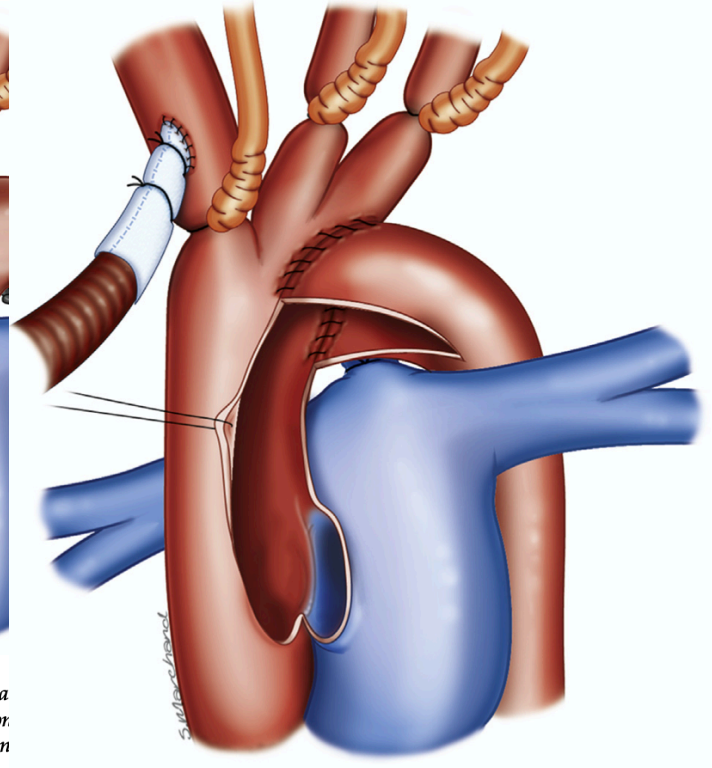

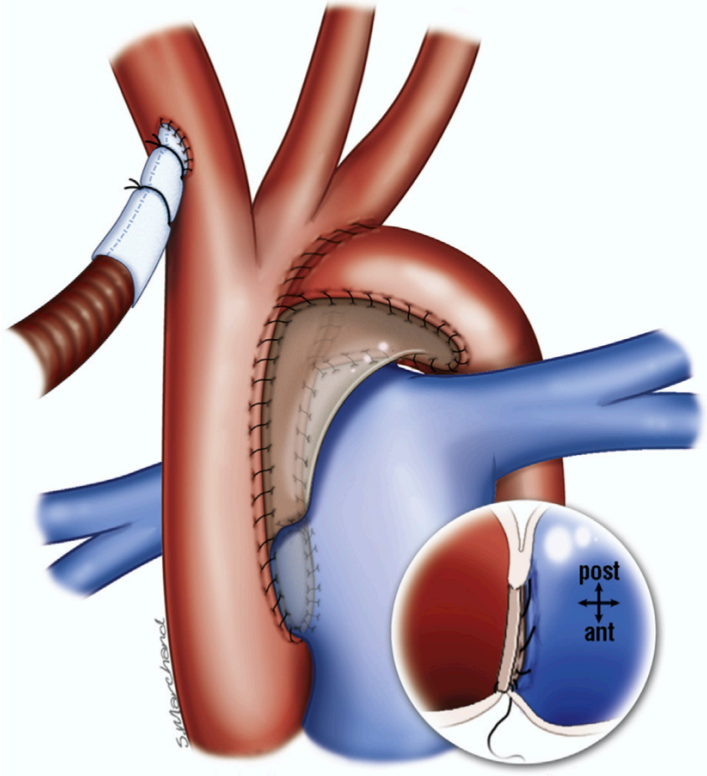

Fenêtre aorto-pulmonaire : complications

- **Sténose artère pulmonaire (droite)**
- Sténose aorte ascendante ou coarctation
- Coronaires
- Fuite valvulaire aortique ou pulmonaire

- Shunt résiduel

Fenêtre aorto-pulmonaire : complications
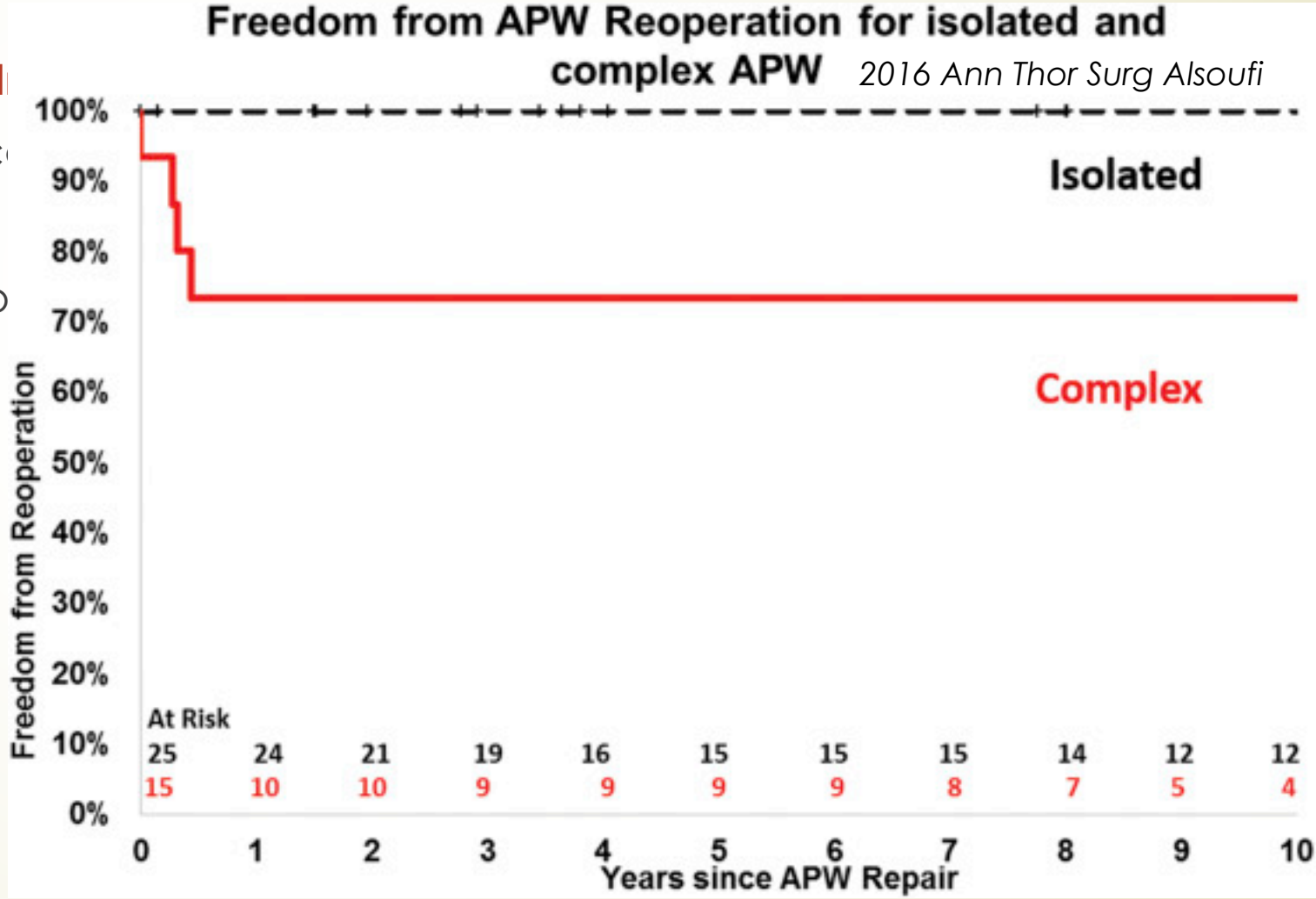
- **Sténose artère pul**
- Sténose aorte asc
- Coronaires
- Fuite valvulaire ao
- Shunt résiduel