Mitrale et Ebstein

les valves auriculo-ventriculaires

Bernard Kreitmann

Mitrale et Ebstein

: les valves auriculo-ventriculaires

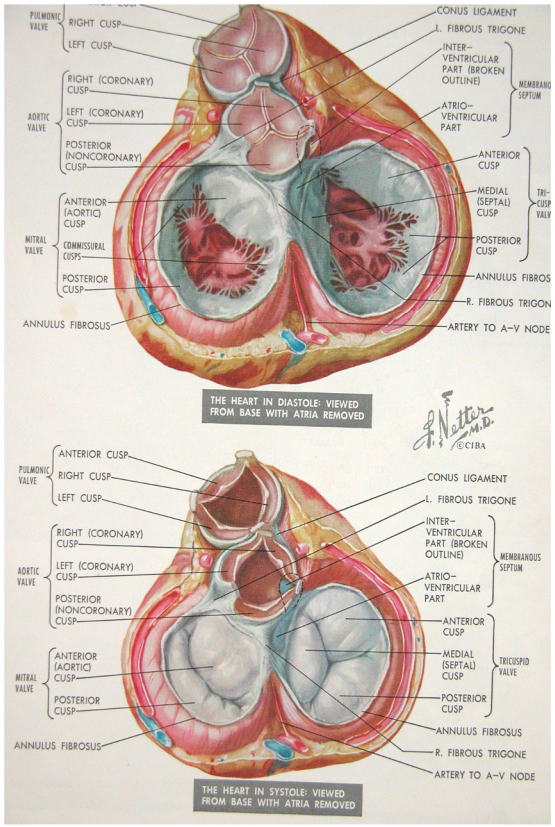

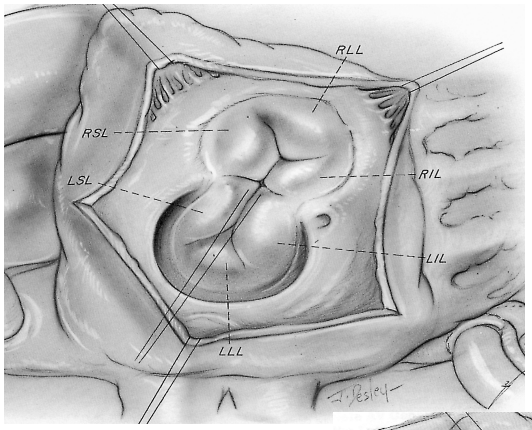

VAV
Malformatives
Hors CAV

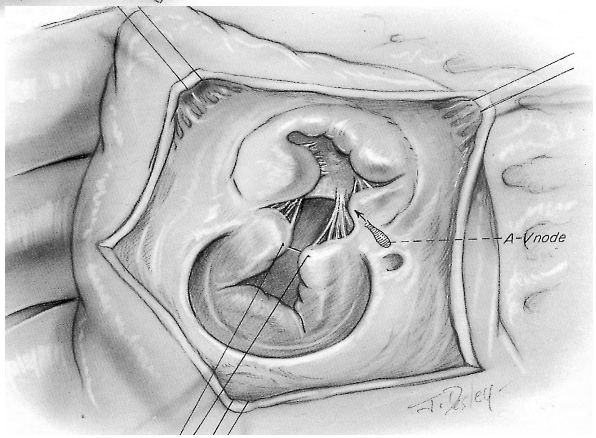

Mitrale
la valve auriculo-ventriculaire systémique

Mitrale (gauche/systémique) : insuffisance

plastie
très bonne tolérance
Interventions différées

Sténose mitrale congénitale

plastie(s)
cathéterisme interventionnel
Chirurgie palliative (ventricule unique)
transplantation
remplacement

Anneau supravalvulaire mitral

Epaissisement des feuillets valvulaires

cordages courts, voire absents

Espaces entre les cordages rétrécis

Anomalies des piliers

Anatomie ; dimensions ; exposition

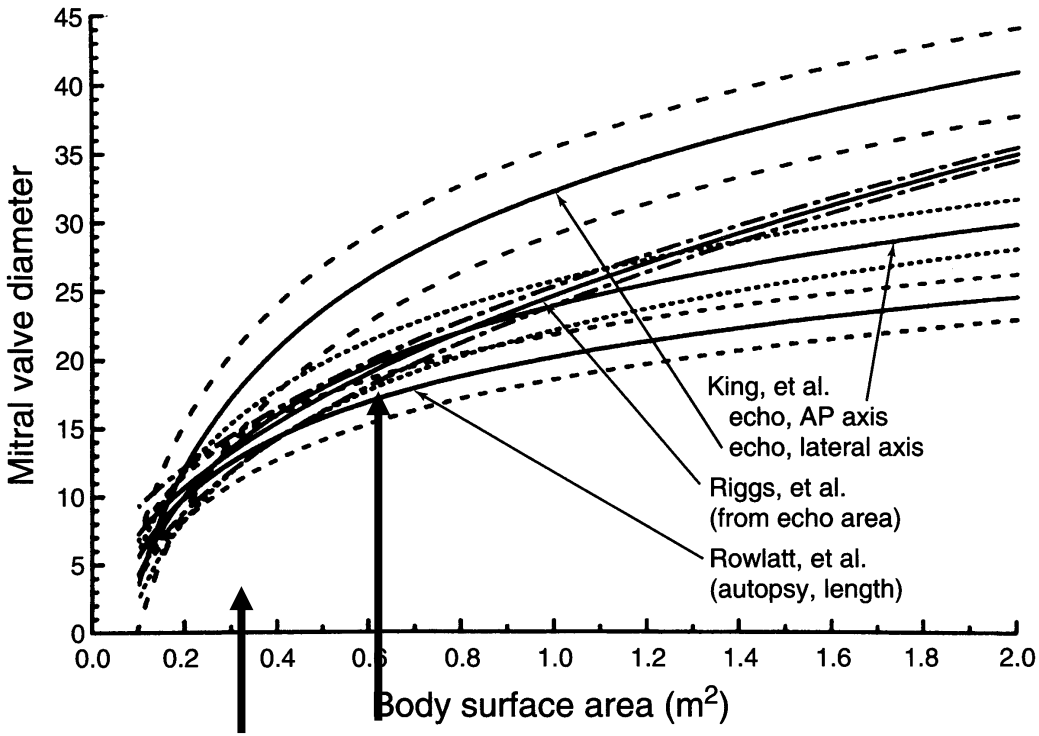

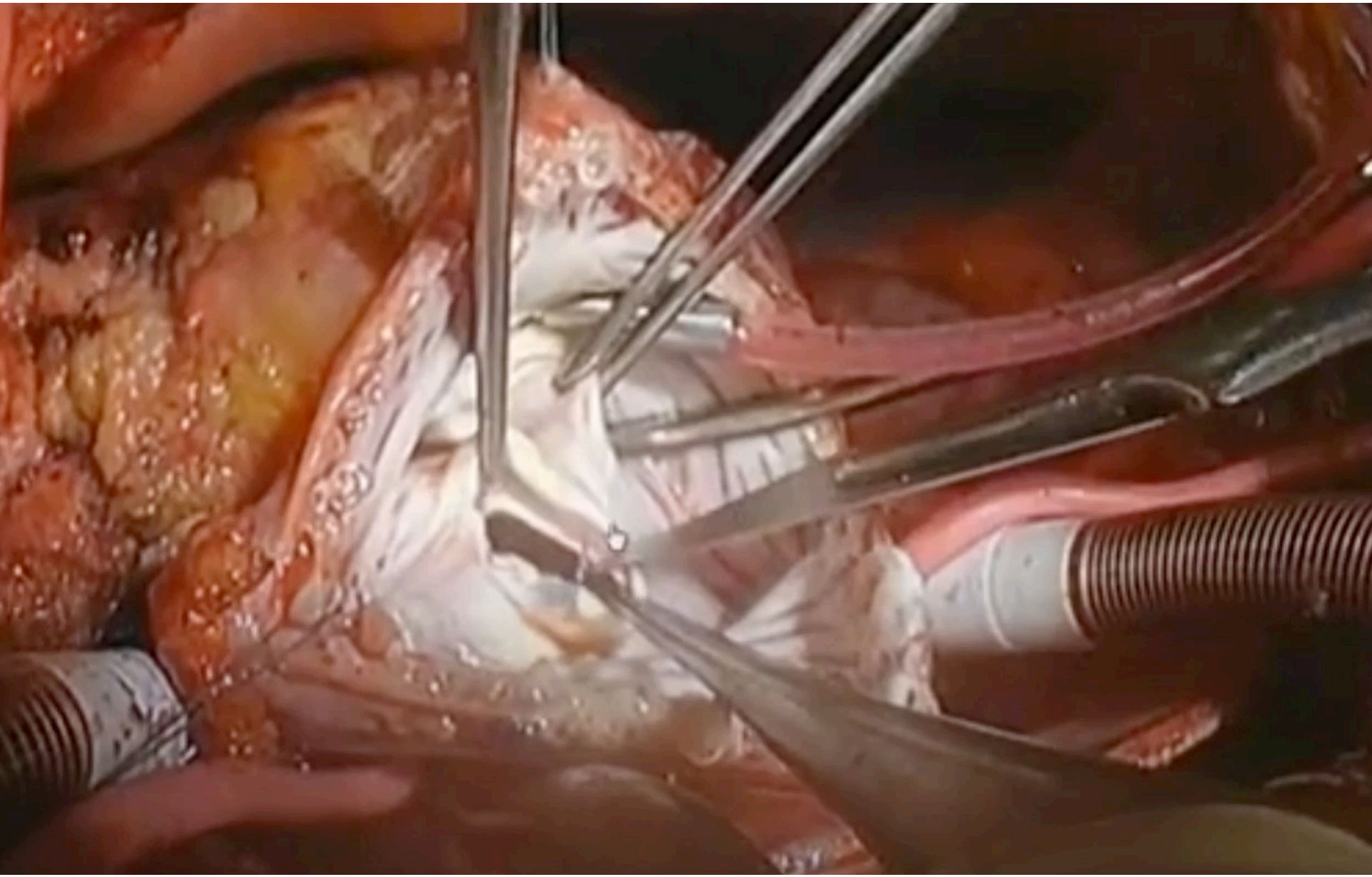

Insuffisance mitrale congénitale pure

- **Dilatation annulaire (svt secondaire)**
- **Prolapsus valvulaires (souvent portion postérieure à mobilité réduite)**
- **Commissures accessoires**
- **Orifice accessoire**

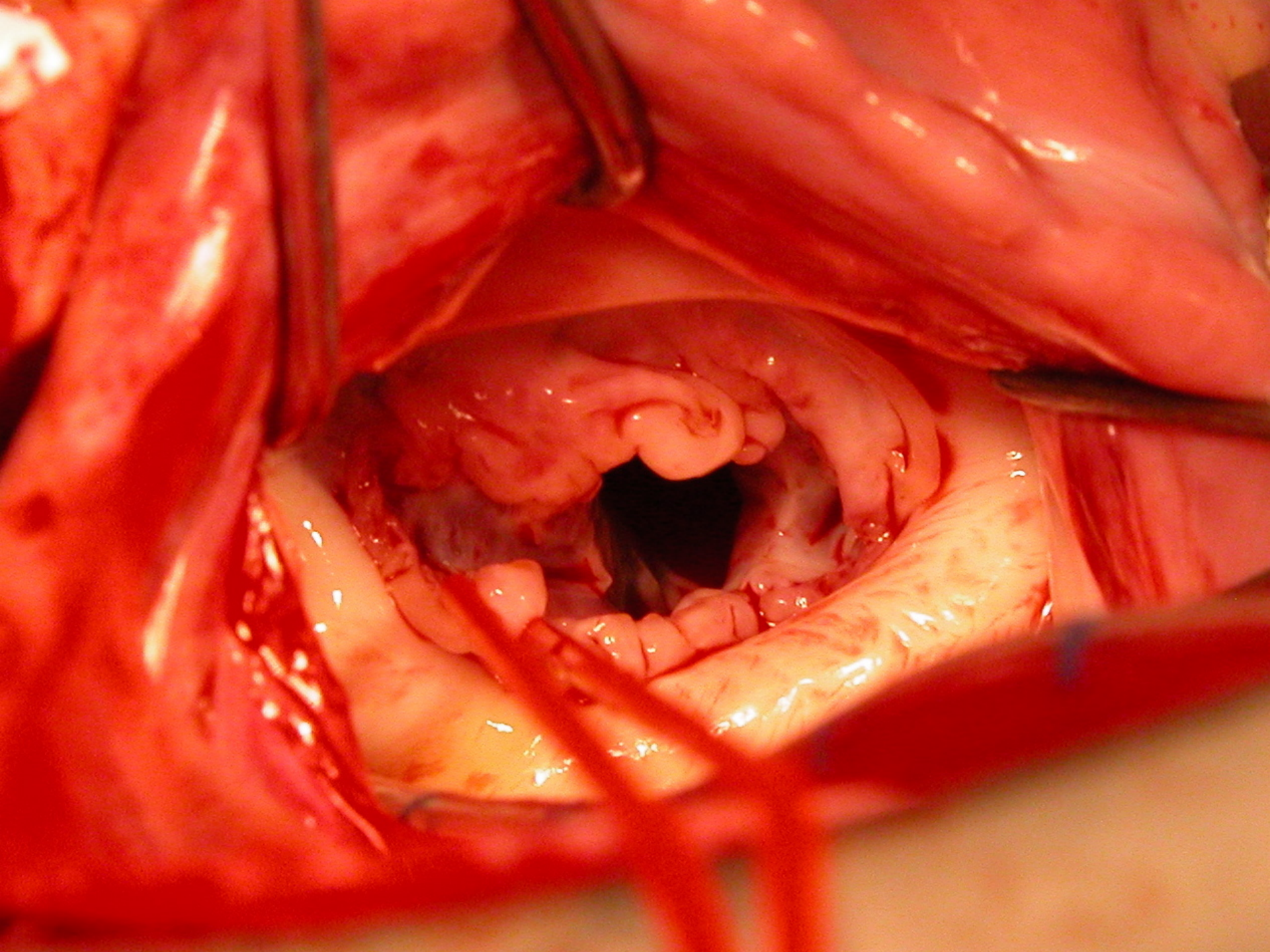

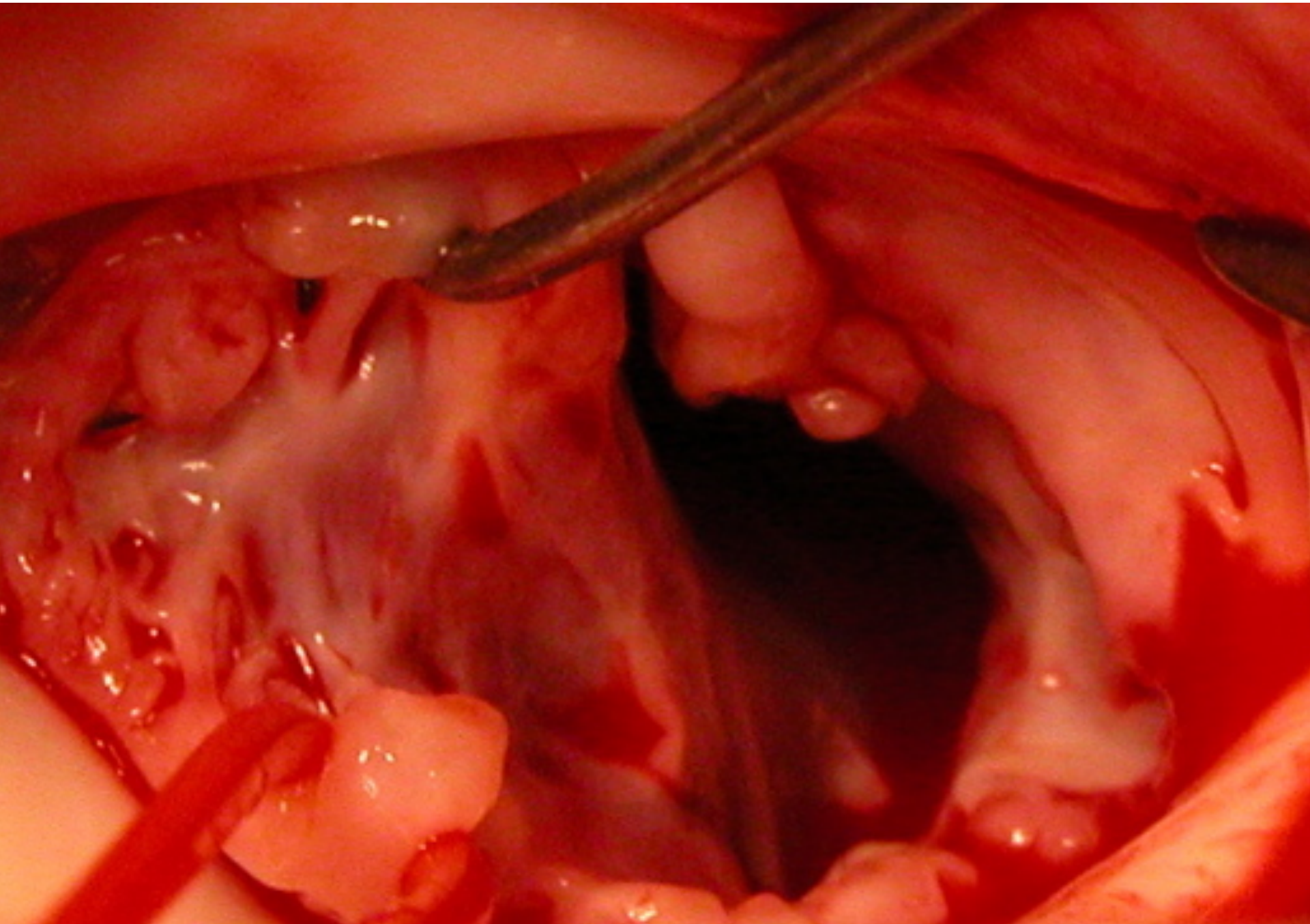

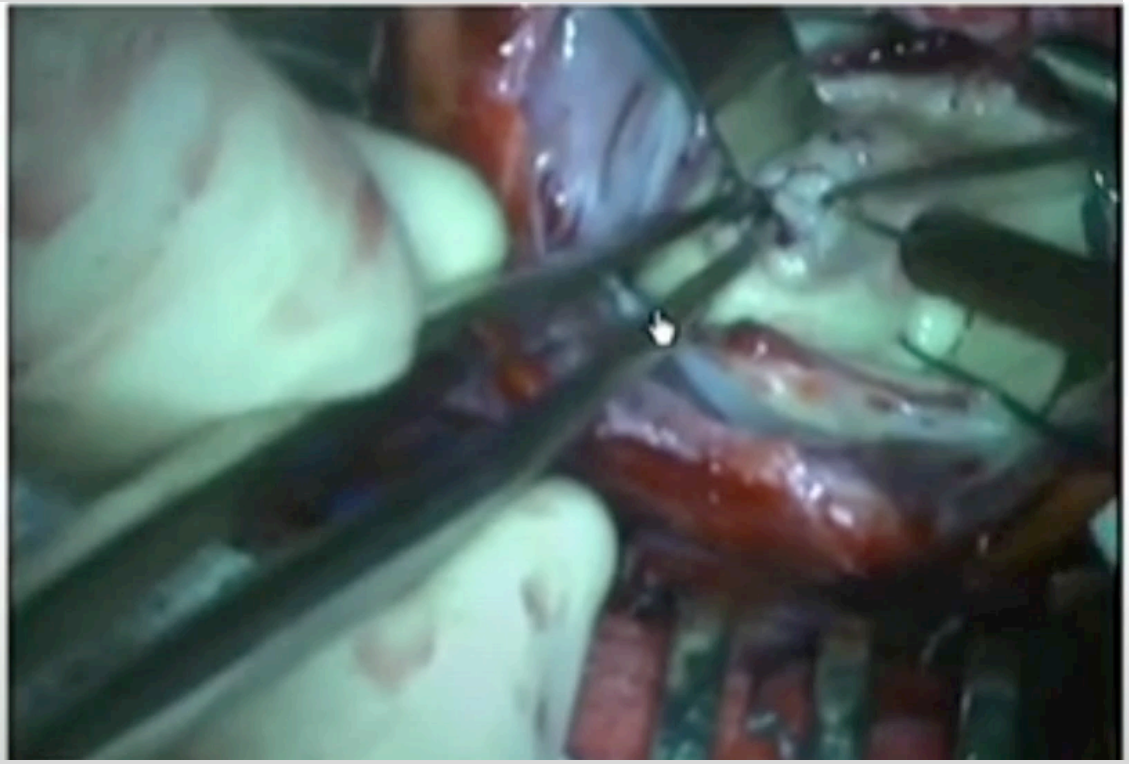

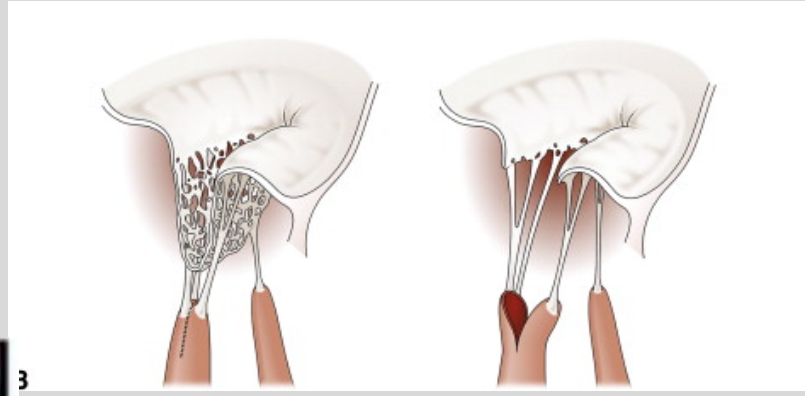
B

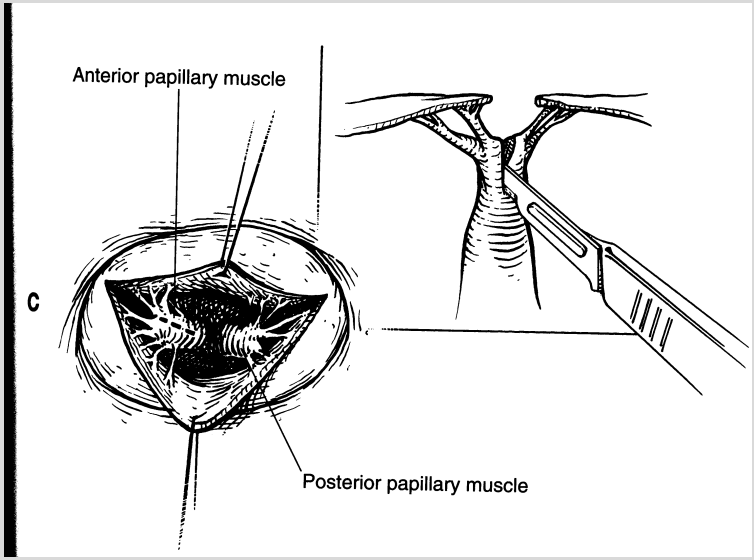
Anterior papillary muscle
C
Posterior papillary muscle

Annuloplastie

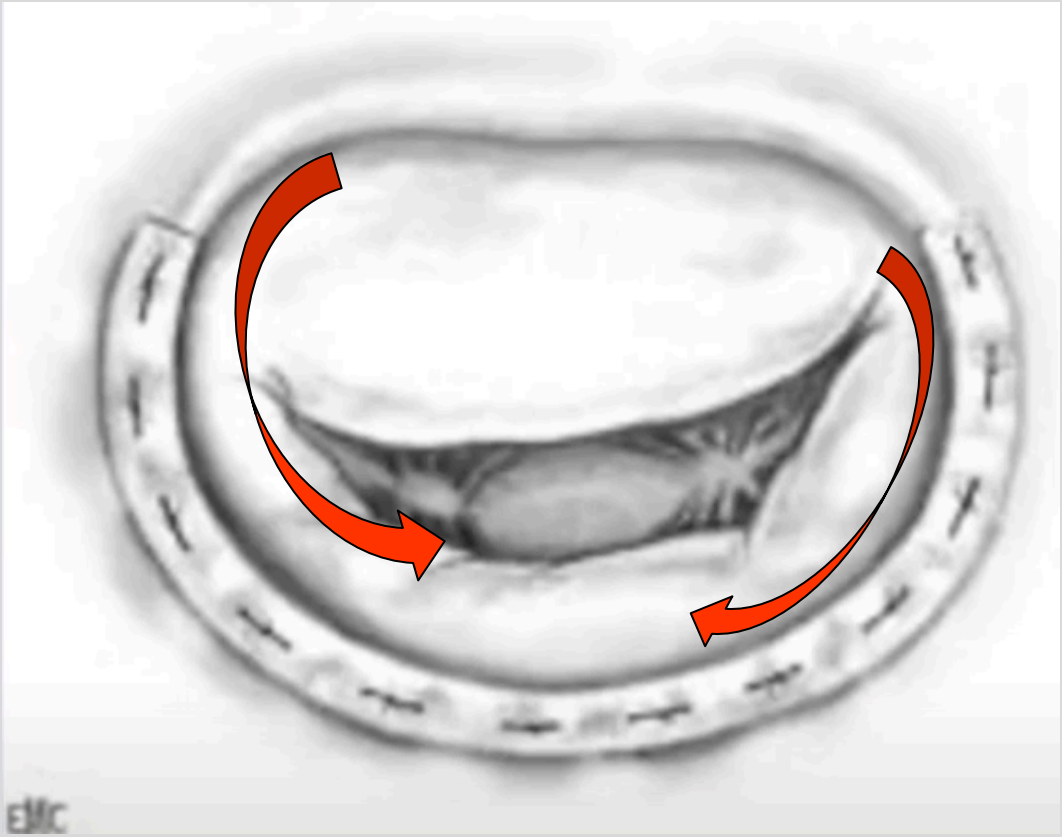

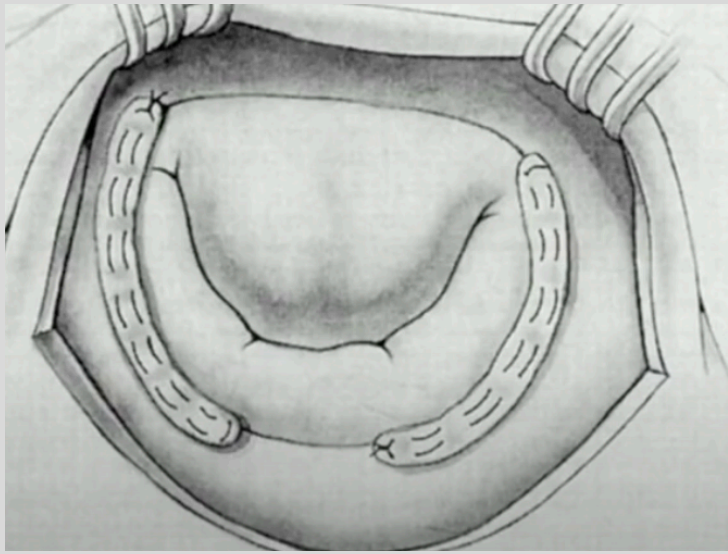

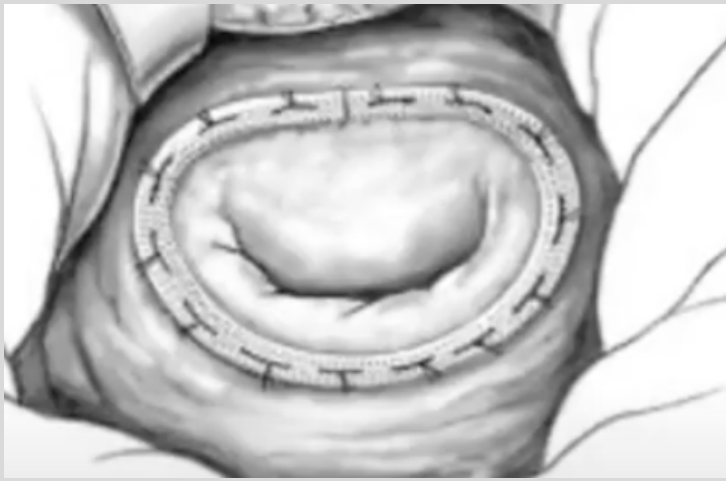

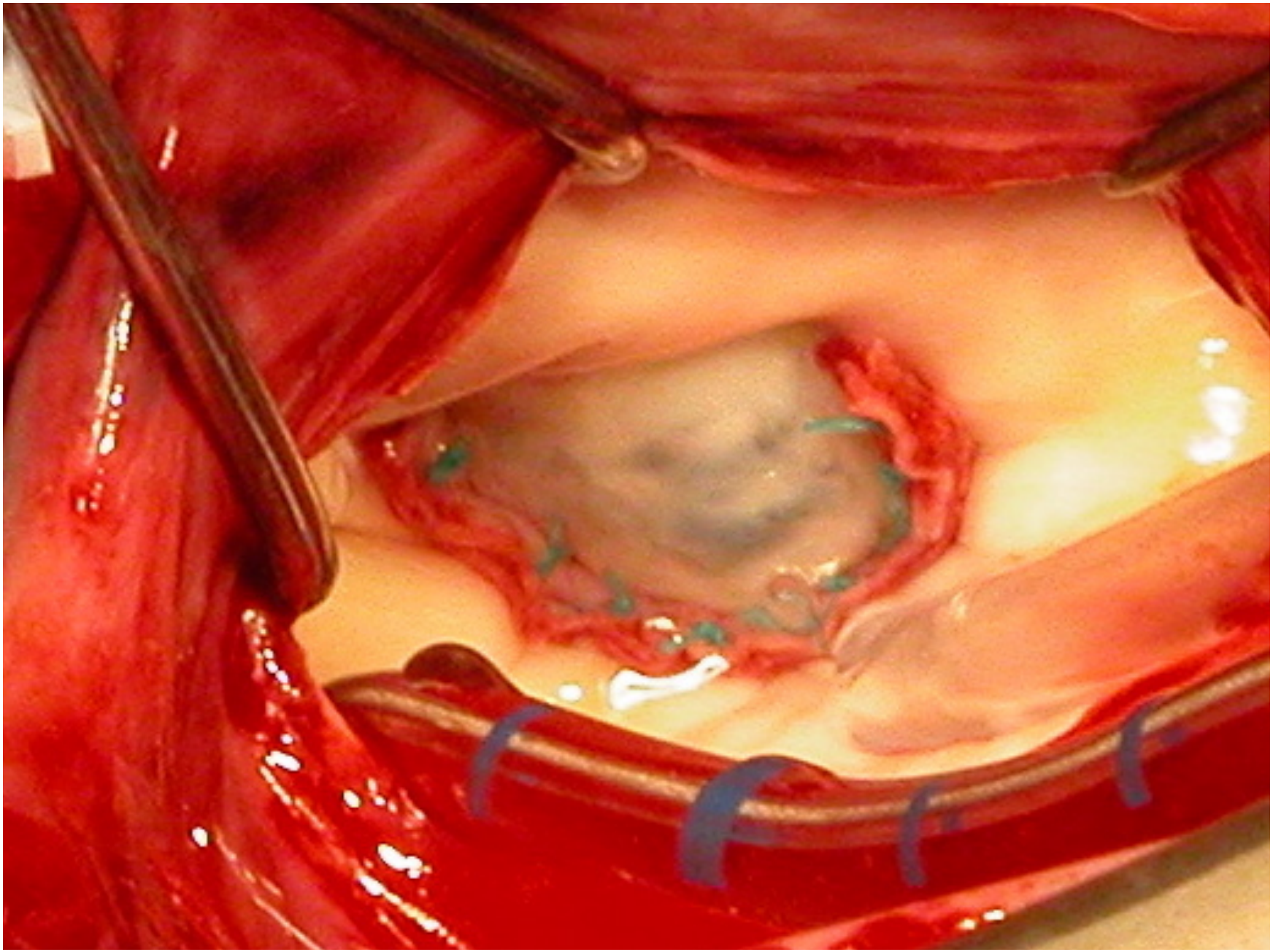

Néo cordages

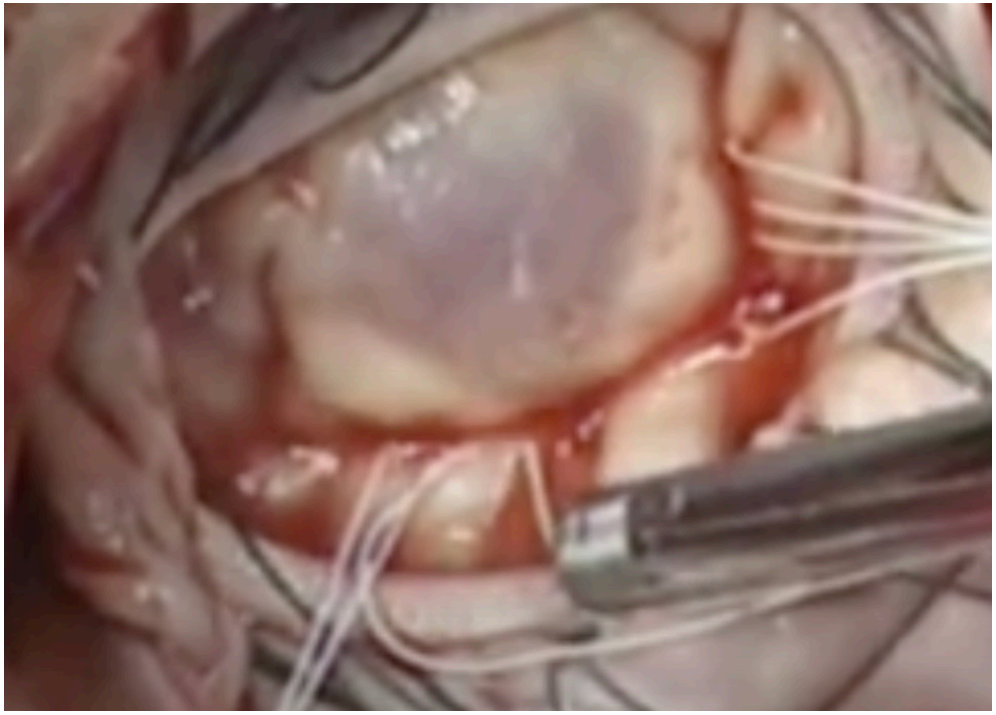

Insuffisance mitrale congénitale pure

- **Indication opératoire ?**
- **Toute insuffisance mitrale plus que minime, si elle est accessible à un trt chirurgical… ce qui est probable**
- **Toute IM avec un retentissement**
  dilatation VG > + 2 DS
  P VD > 50 % systémiques
- **Plastie aboutissant toujours à mieux**
- **Suites simples si timing opératoire normal**

Sténose (et maladie mitrale) congénitale

Anneau supravalvulaire mitral

Epaississement des feuillets valvulaires
cordages courts, voire absents
Espaces entre les cordages rétrécis
Anomalies des piliers

- Valve en hamac, arcade, en parachute…

Tout ceci avec un anneau hypoplasique

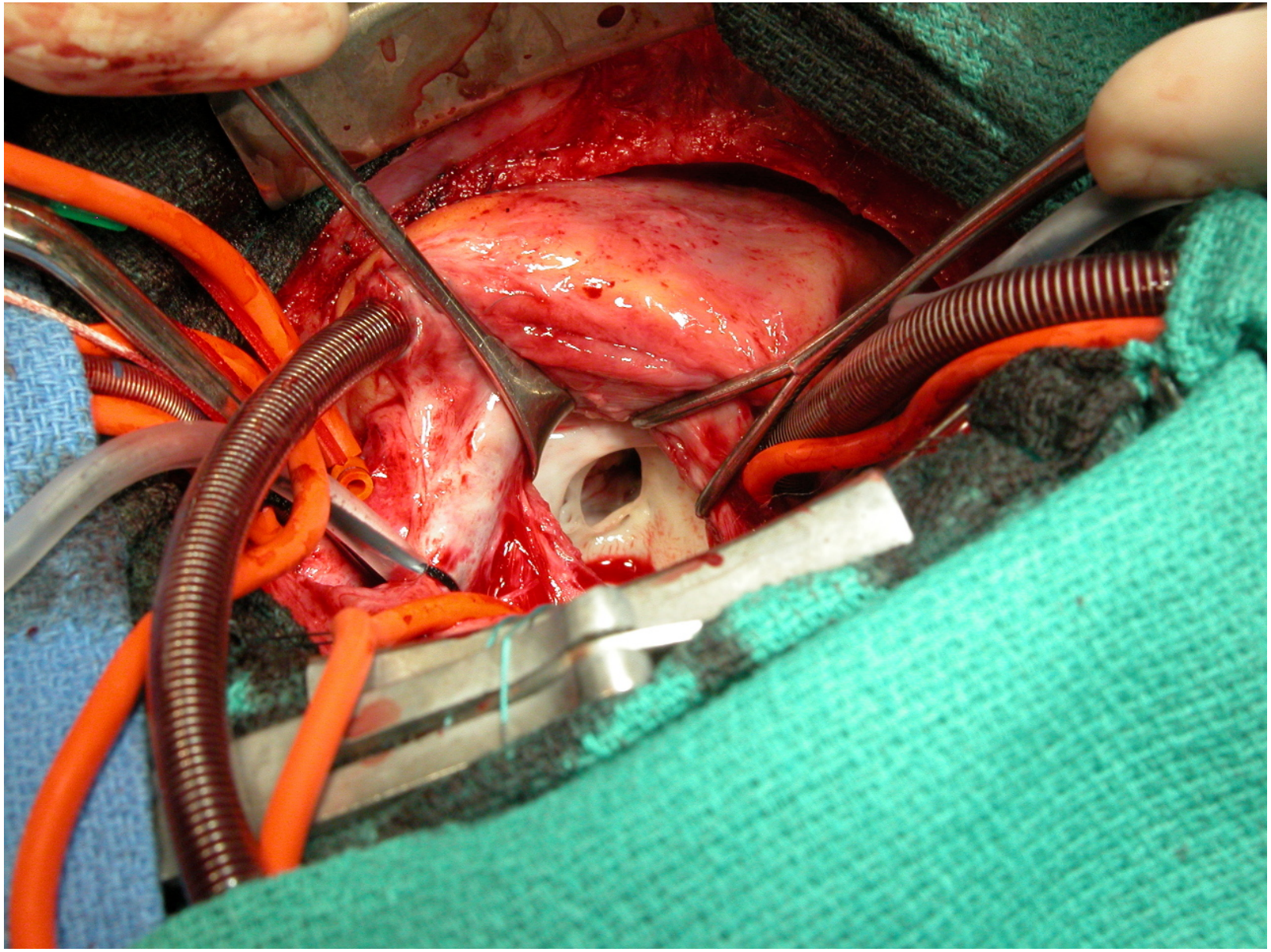

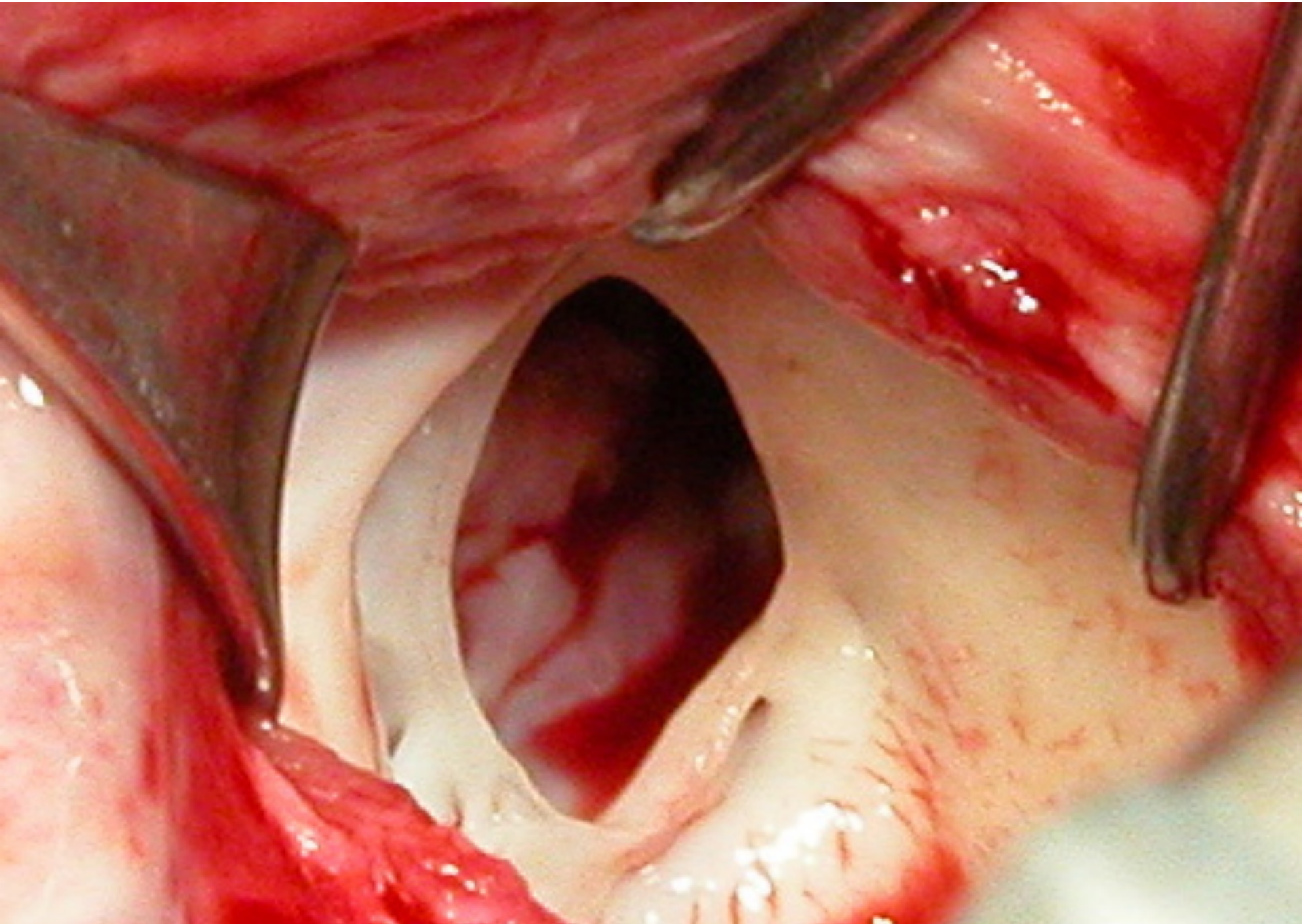

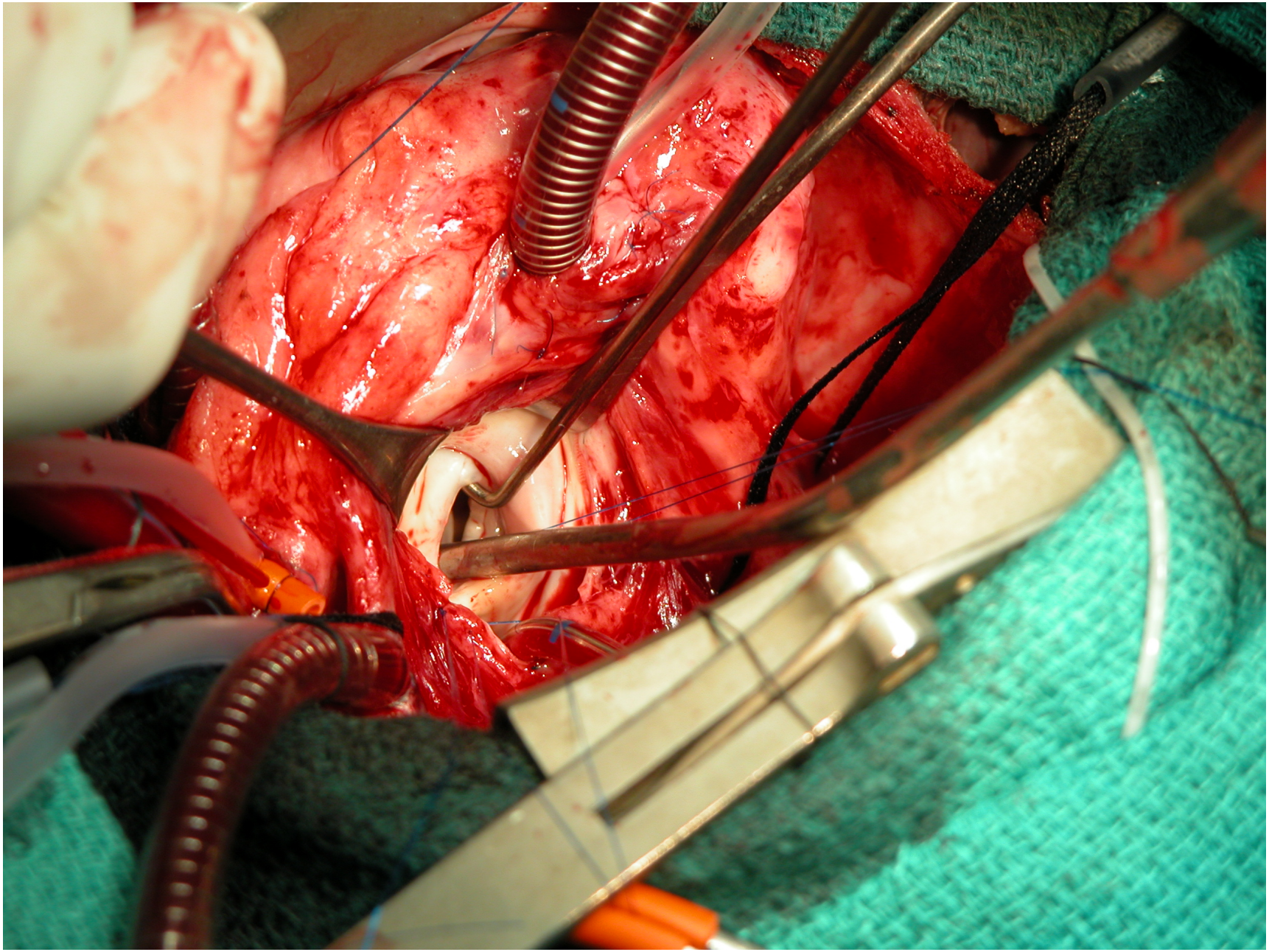

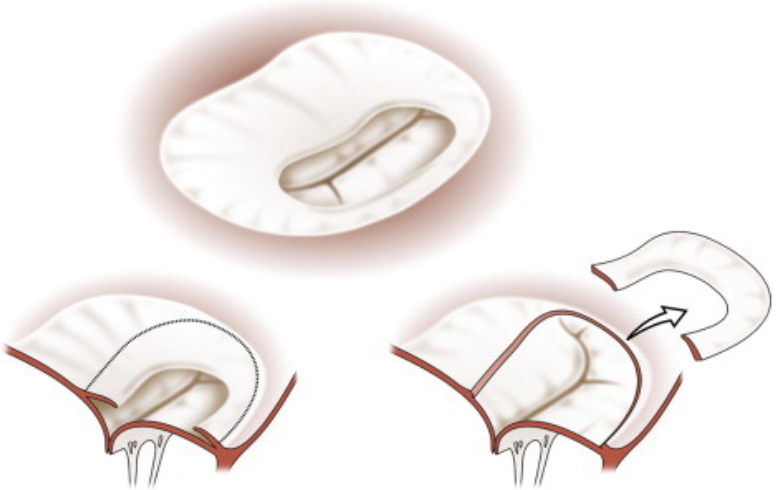

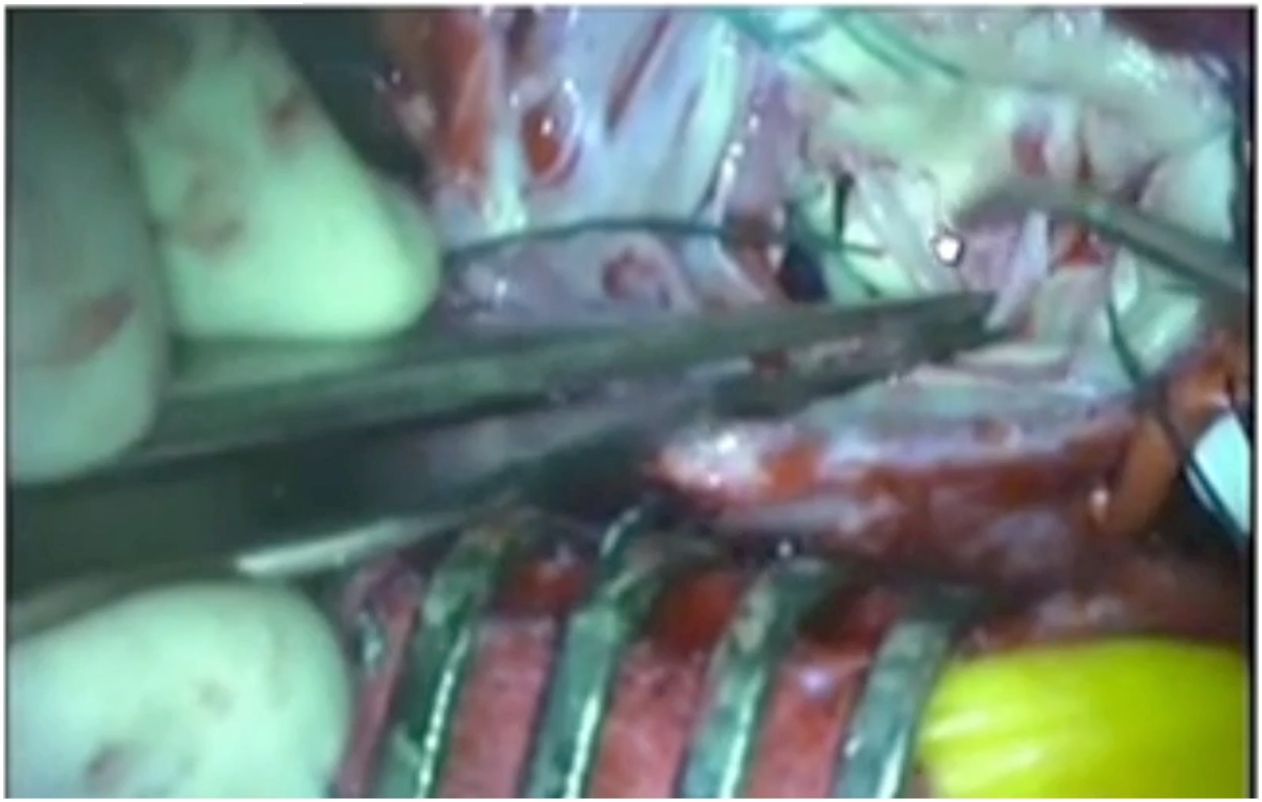

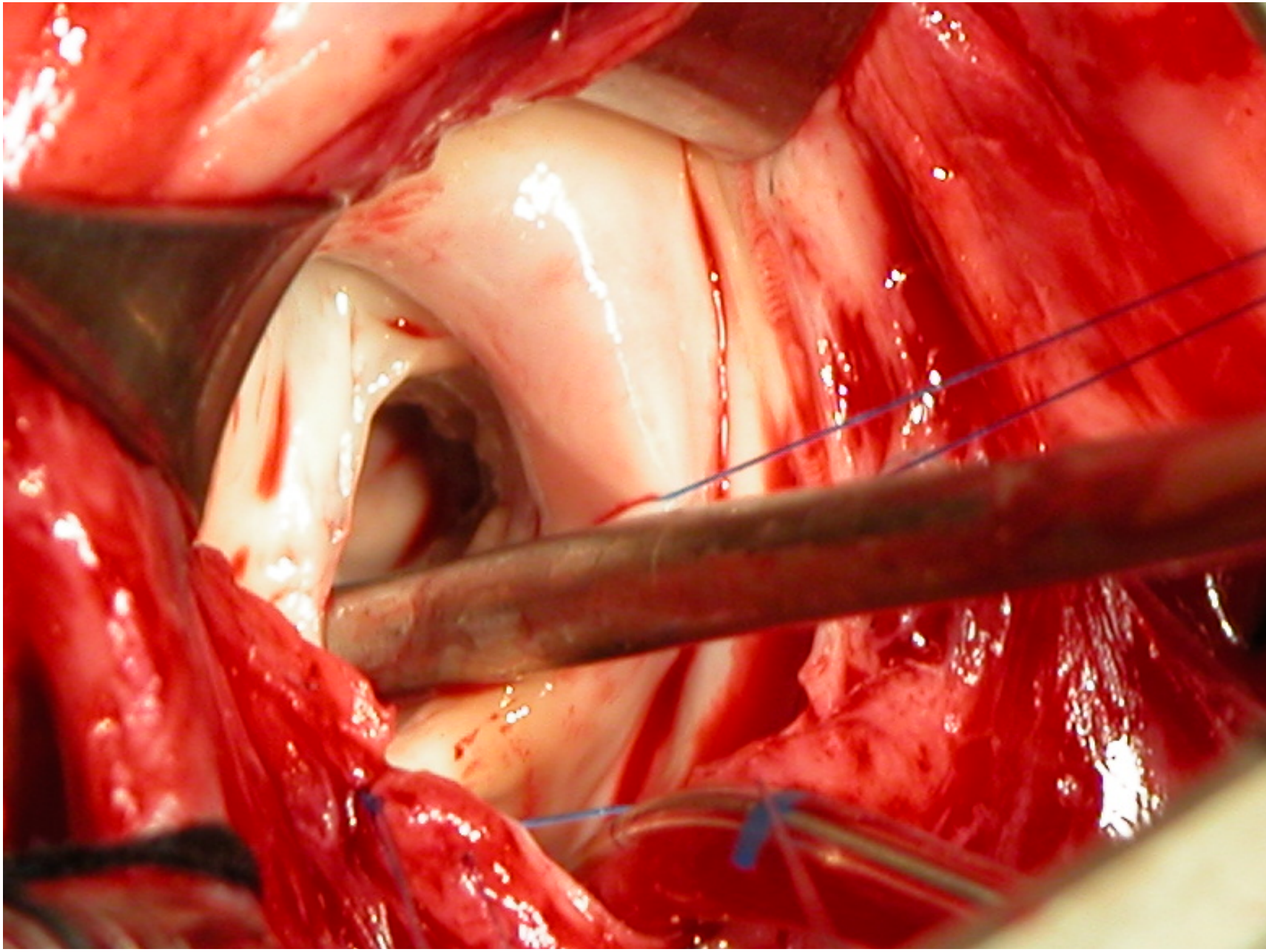

- Résection d'un ann

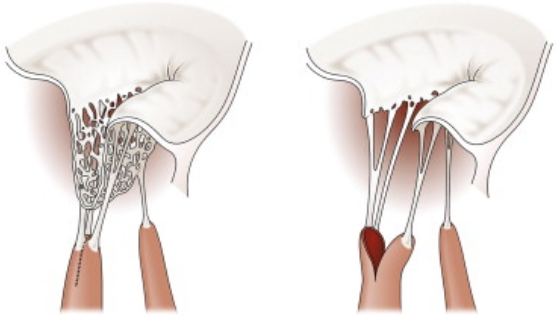

- Commissurotomies
- Libération des corda

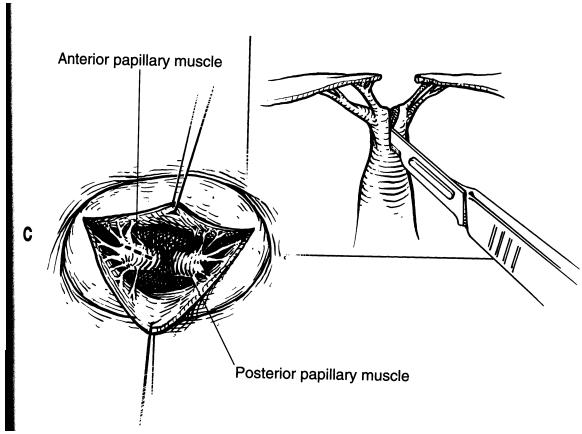

- Incisions des (ou du) piliers
- Patches valvulaires

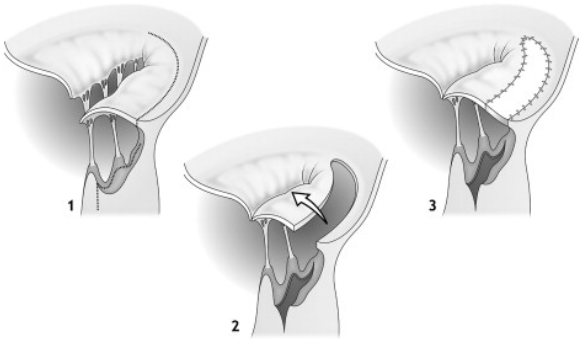

- C'est de la chirurgie palliative !
  - La demi vie est de l'ordre de 5 à 7 ans
- C'est de la chirurgie risquée
  - Mortalité rarement < 10%

- Equilibre fuite/sténose résiduelle
- HTAP
- Bas débit
- BAV

- **Et si … malgré toute tentative de plastie…**
- **Essayer encore … risque de décès par HTAP**
- **Chirurgie uni ventriculaire … oui, mais HTAP**
- **Transplantation … bof, et HTAP!**
- **Et le remplacement valvulaire?**

Valves mécaniques (petits diamètres) utilisables en position mitrale et/ou aortique

Nom	Taille	Mit/Aort.	*diamètres*			*surface valv.*		*références*
			anneau tissu	orifice interne	hors-tout	géométrique	effective	mitrale
			1	2	4	(calculée)	(mesurée)	
			mm	mm	mm	cm2	cm2	
Carbomedics 7	16	Mitrale	16,2	14,7	20,8	1,59	1	M7-016
Bicarbon Slimli	17	Mitrale	17,2	15,2	23,5	1,76	1,58	ICV0248
Carbomedics 7	18	Mitrale	18,8	14,7	21,6	1,59	1	M7-018
Bicarbon Fitlin	19	Mitrale	19	15,2	25,5	1,76	1,58	ICV0924
Carbomedics 7	23	Mitrale	23,8	18,5	31,6	2,56		M7-023

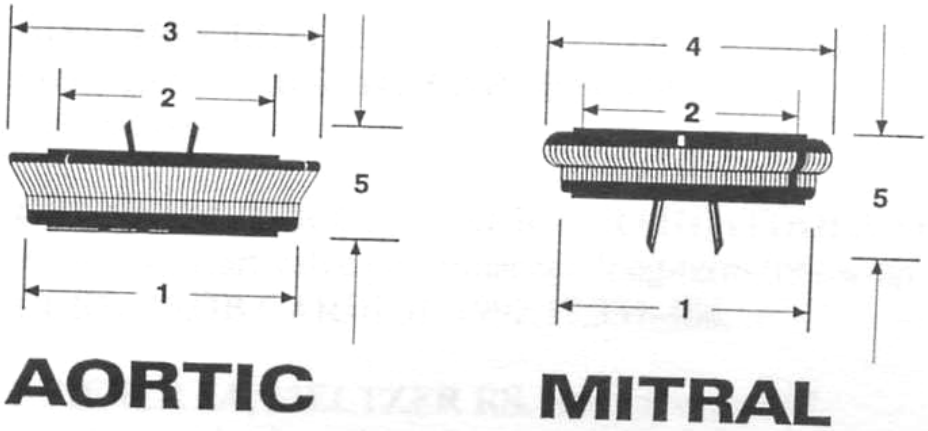

VALVE MÉCANIQUE MASTERS HP DE 15MM

DIMENSIONS PAR RÉFÉRENCE

RÉFÉRENCE	DIAMÈTRE DE L'ANNEAU TISSULAIRE (MM)[1]	GOA (CM^2)	HAUTEUR DES AILETTES EN POSITION OUVERTE (MM)[2]	HAUTEUR GLOBALE EN POSITION OUVERTE (MM)[3]	DIAMÈTRE EXTÉRIEUR DE LA COLLERETTE (MM)[4]
15 MHPJ-505 (position mitrale)	15	1,3	2,2	8,5	20
15 AHPJ-505 (position aortique)	15	1,3	4,6	8,5	20

MESURES POUR LA POSITION MITRALE

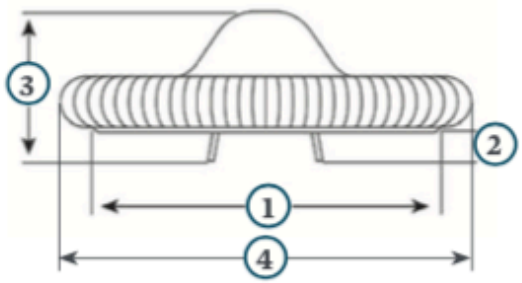

MESURES POUR LA POSITION AORTIQUE

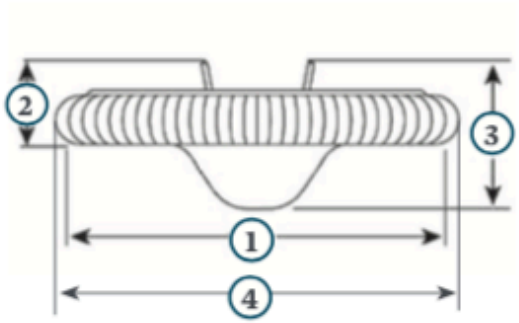

1. Diamètre de l'anneau tissulaire
2. Hauteur des ailettes en position ouverte
3. Hauteur globale en position ouverte
4. Diamètre extérieur de la collerette

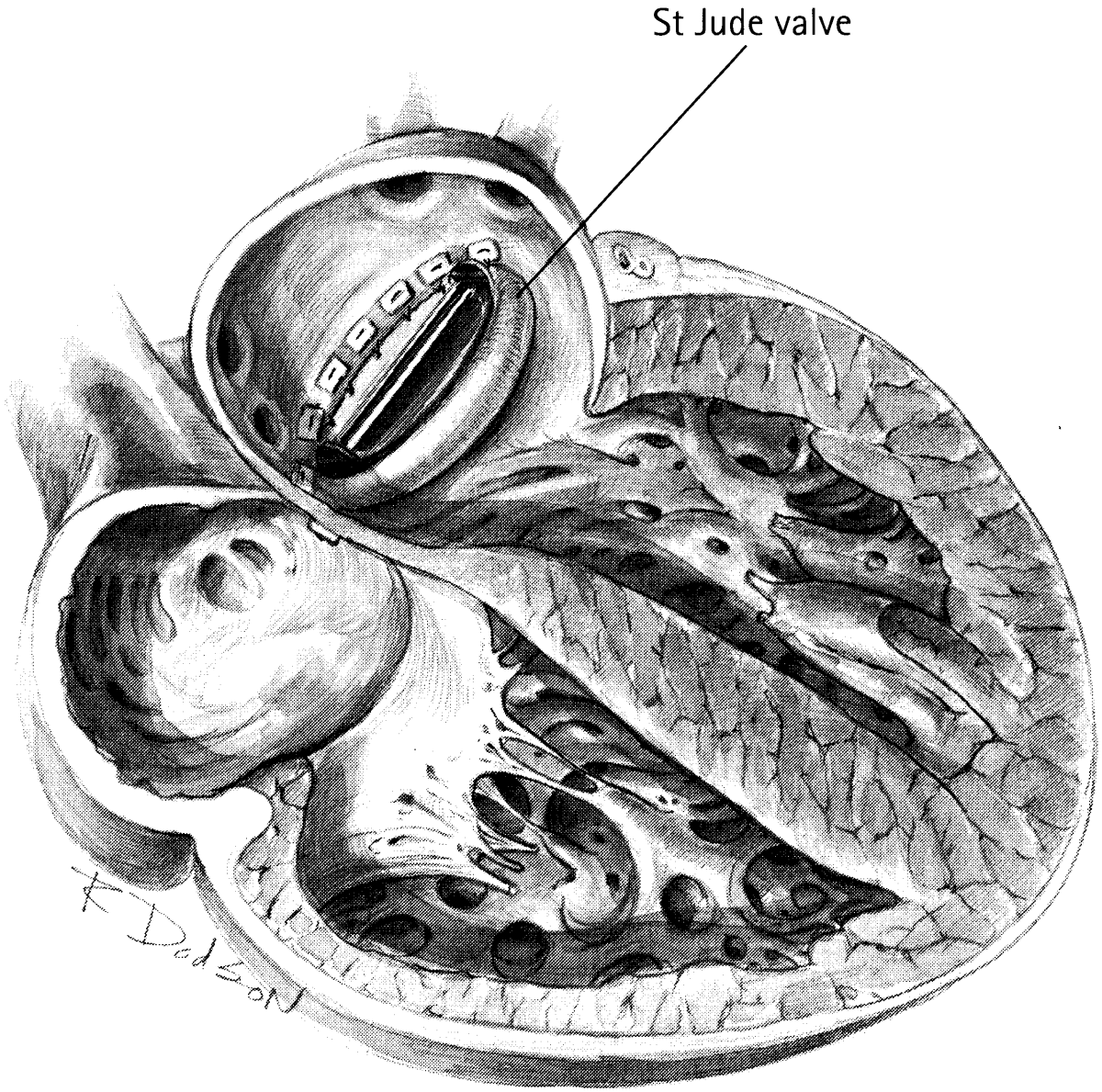
St Jude valve

Long term survival after MVR in children aged < 5 years
A multi institutional study
139 patients

Caldarone et al. Circulation 2001 ; 104 : 143-7

Operative mortality 20 %
risk factors: **Shone's syndrome (3.68 X)**
AV Canal anatomy (4.76 X)
associated extra cardiac lesions

AV Block 16 %

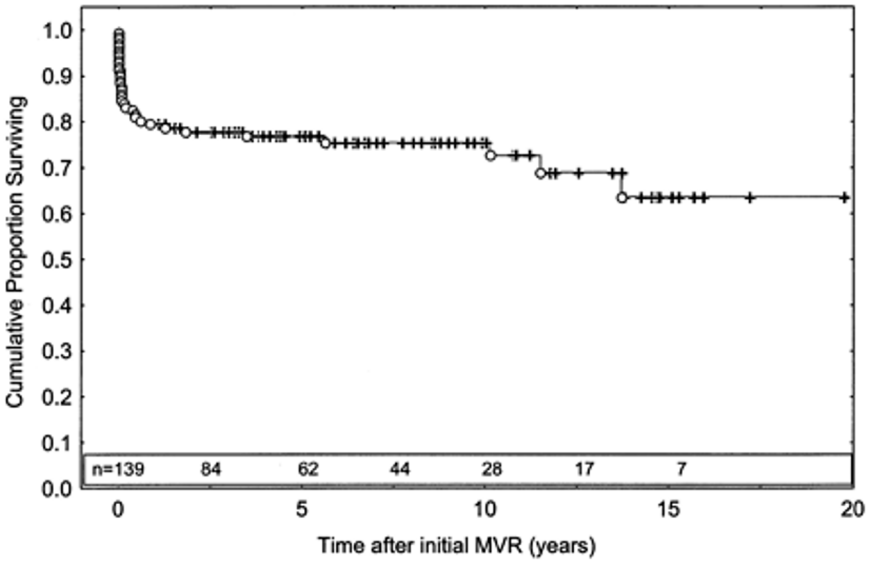

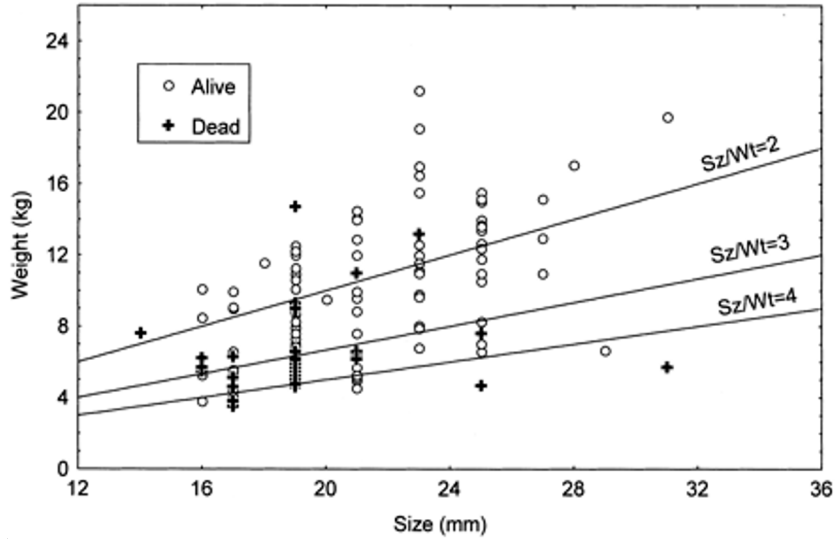

« The availability of a smaller prosthesis should be expected to decrease operative mortality »

Figure 4a

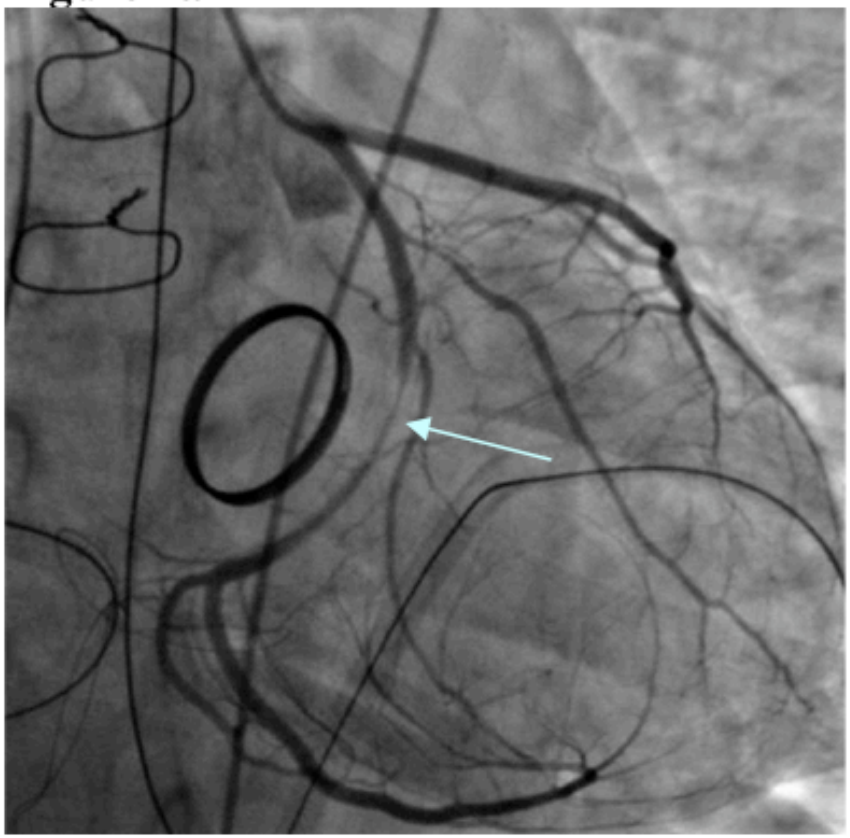

Figure 4b

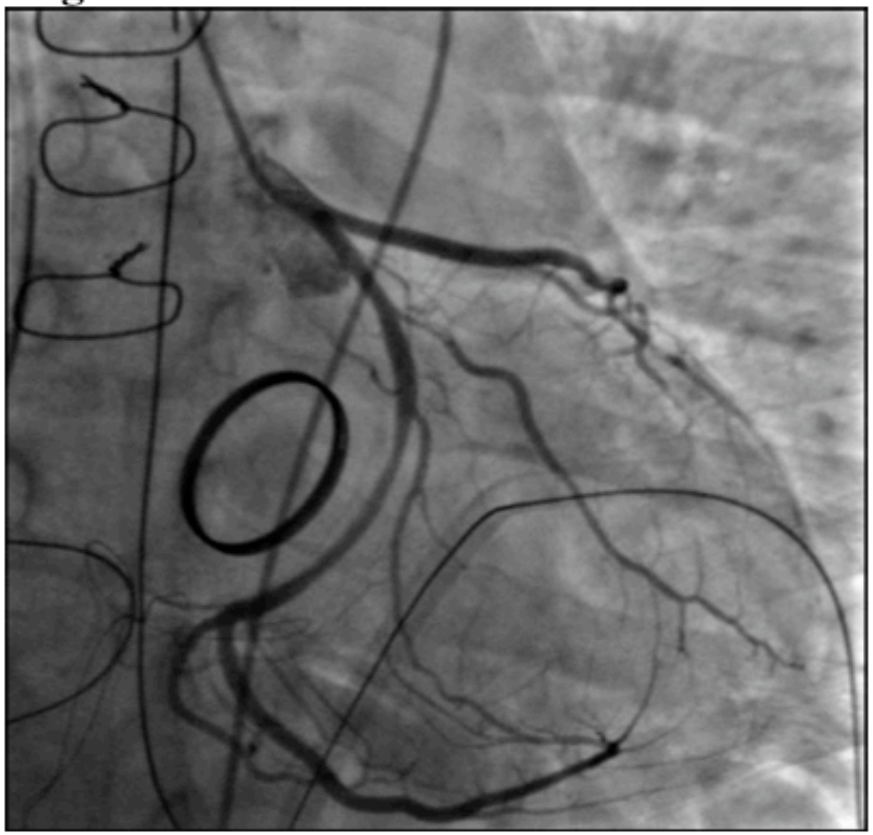

JET A1
ST 71373

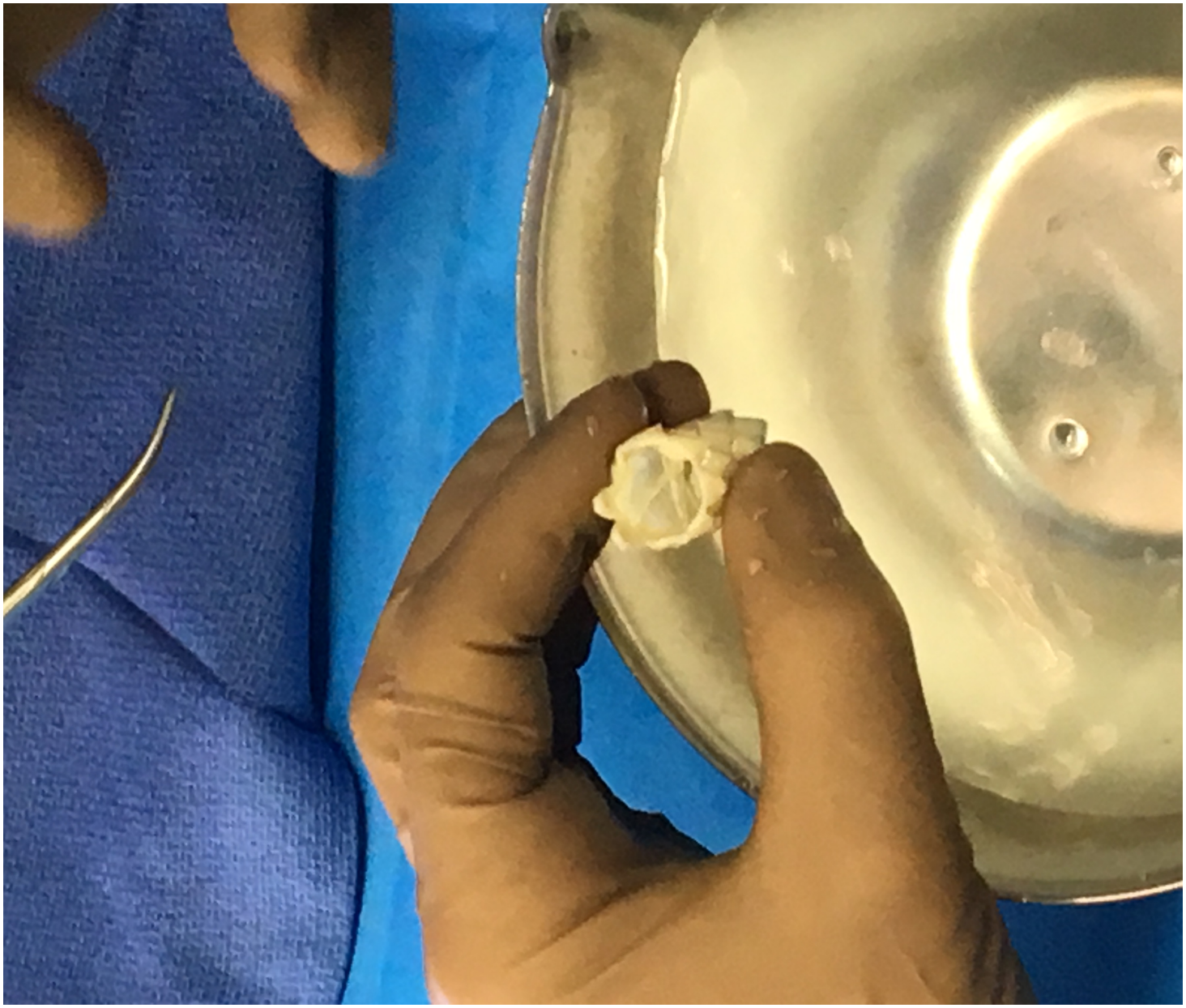

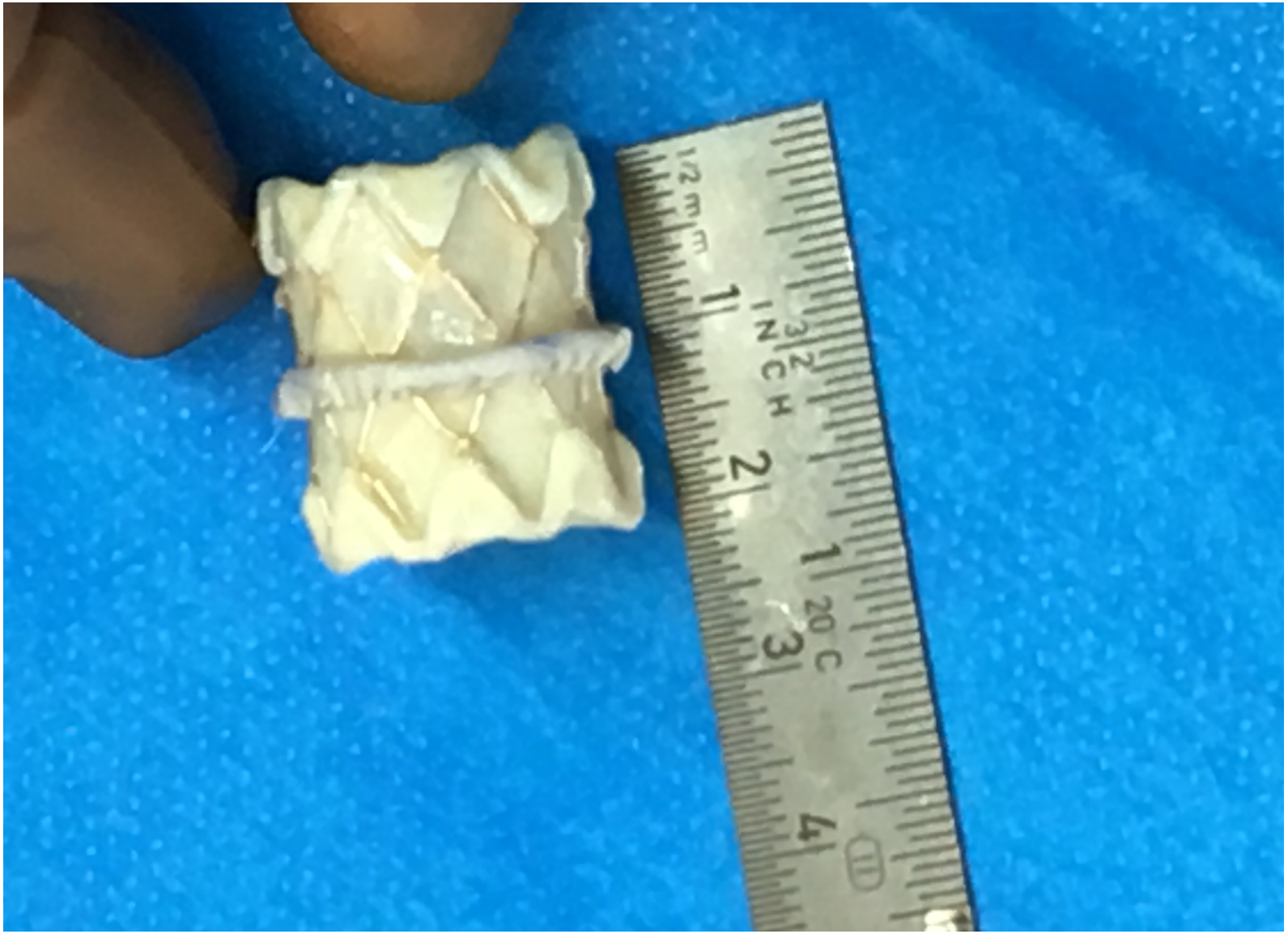
12 mm
1
2
3
4
1/2
1
2
3
INCH
20 C

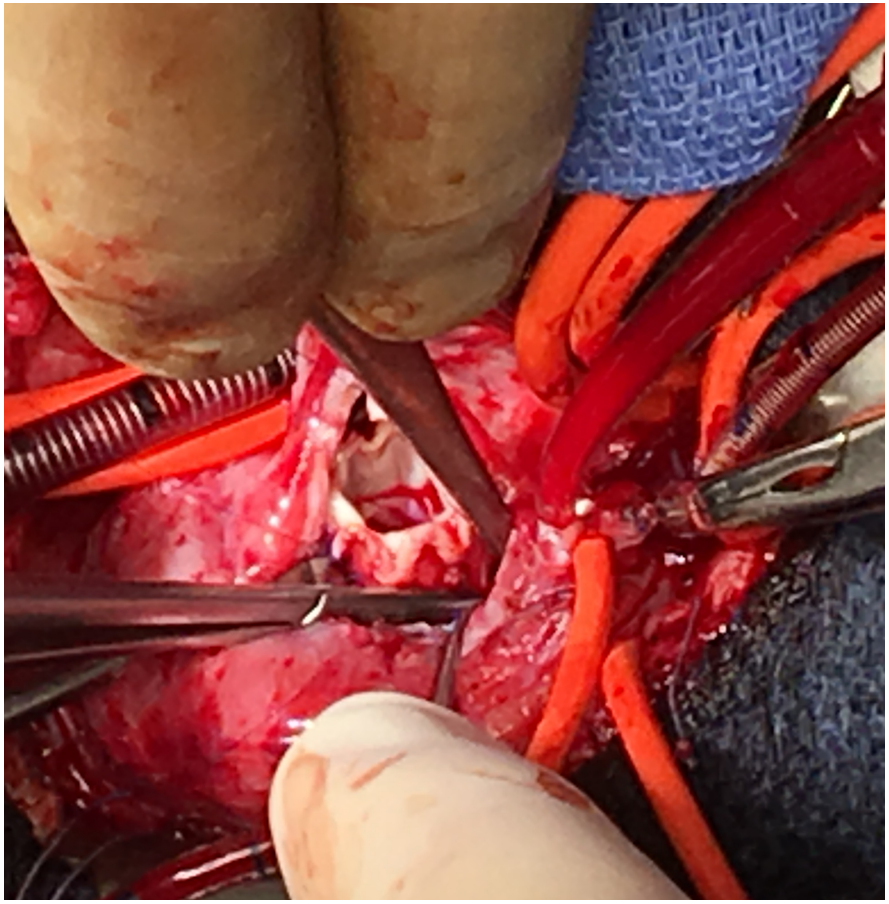

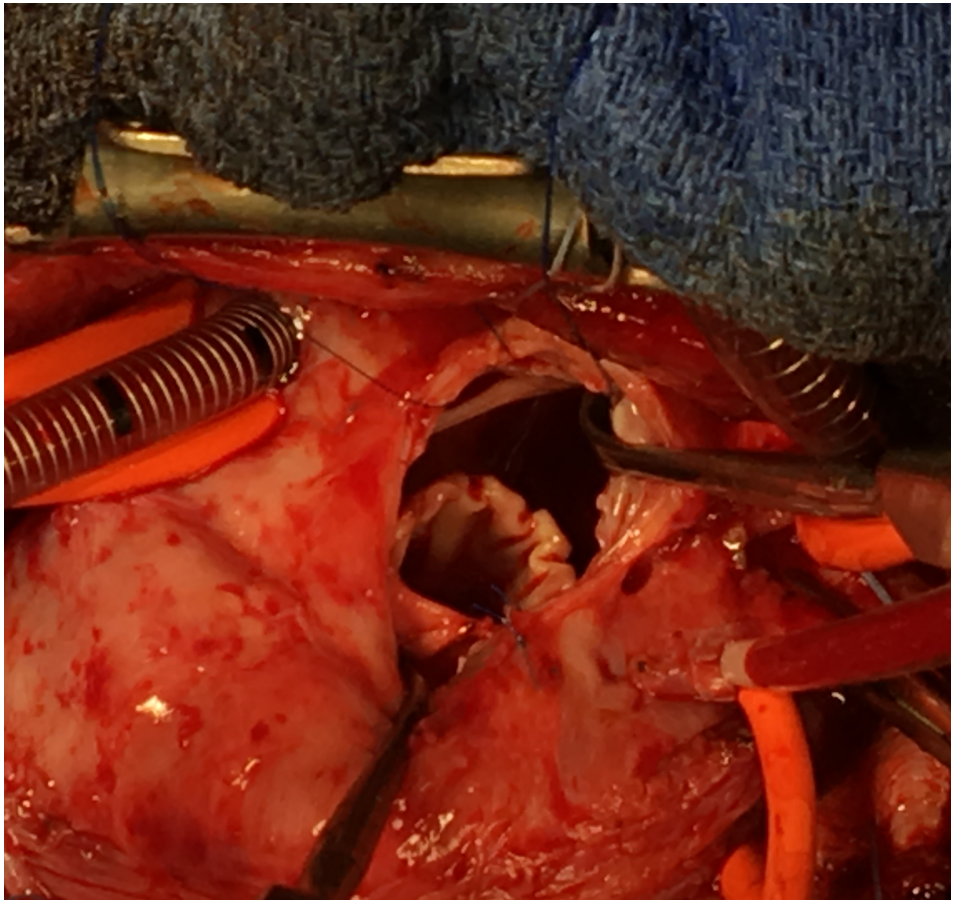

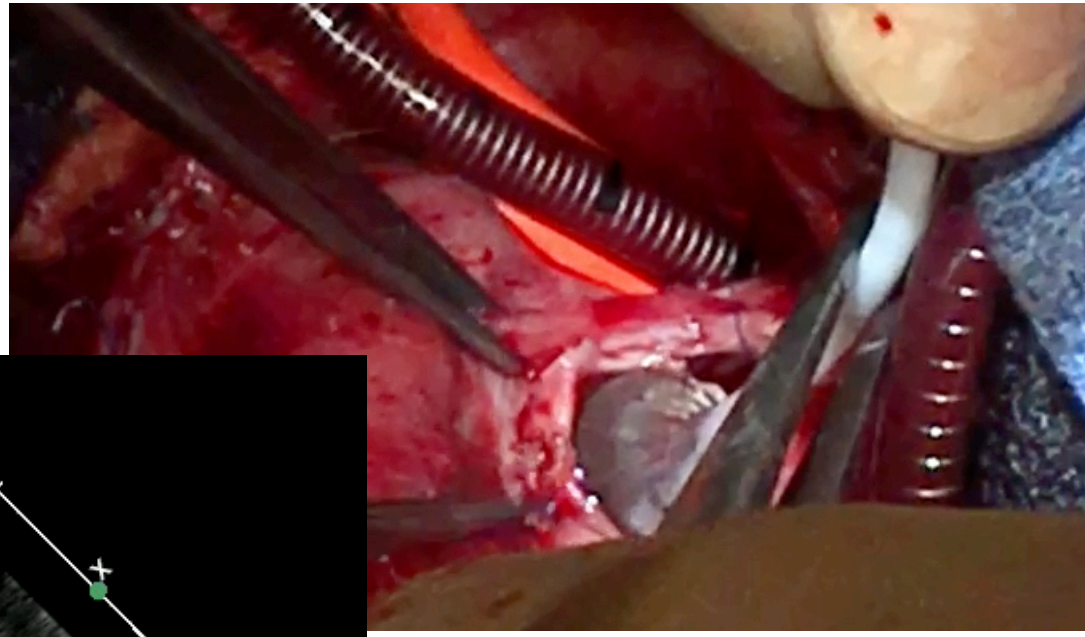

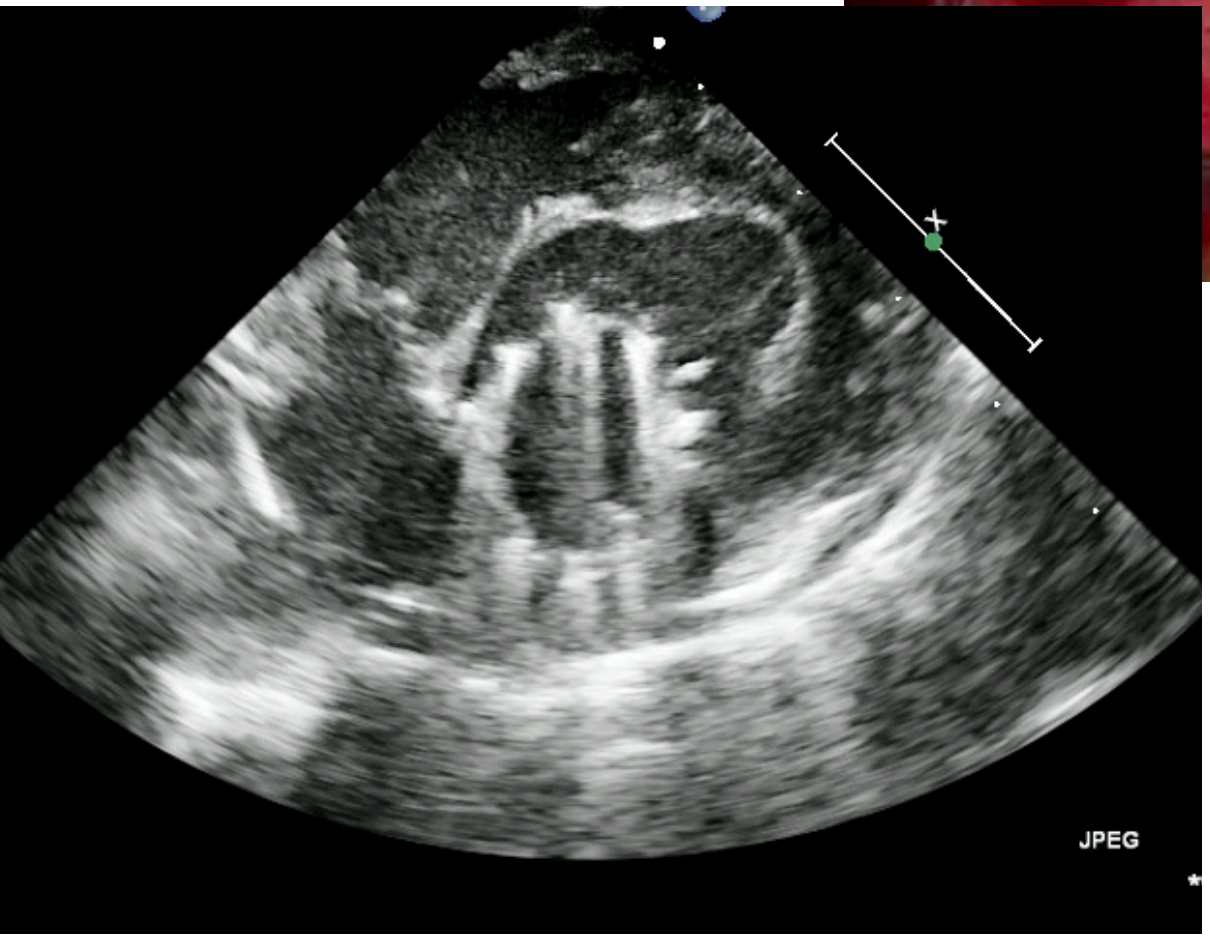
JPEG

- C'est de la chirurgie palliative !
  - La demi vie est de l'ordre de 5 à 7 ans

- C'est de la chirurgie risquée
  - Mortalité rarement < 10%

- Equilibre fuite/sténose résiduelle
- HTAP
- Bas débit
- BAV

Mitrale et Ebstein

: les valves auriculo-ventriculaires

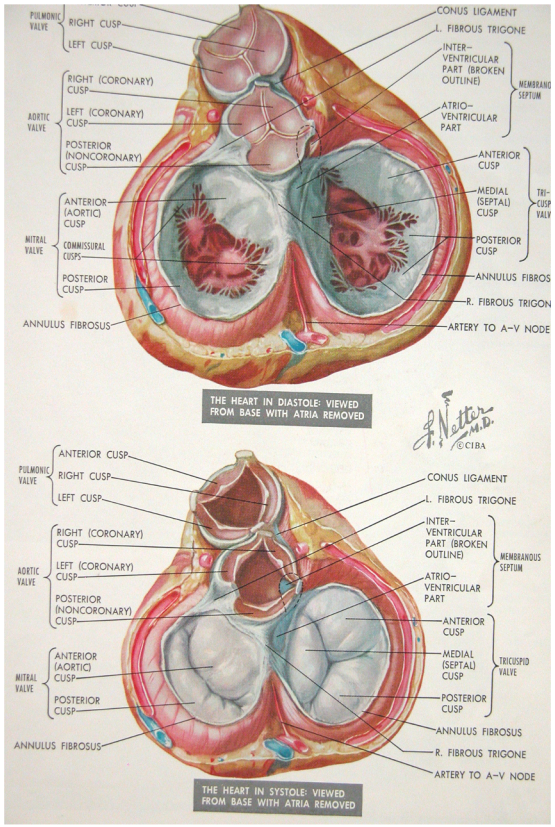

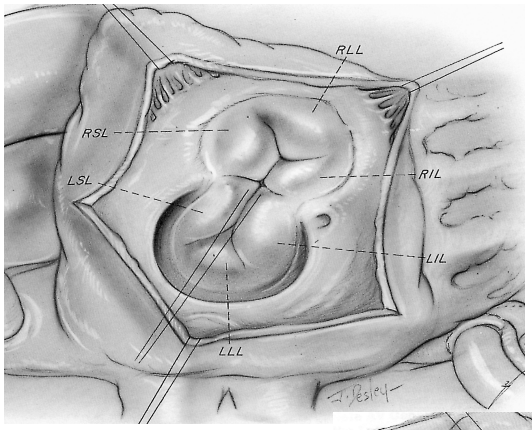

VAV
Malformatives
Hors CAV

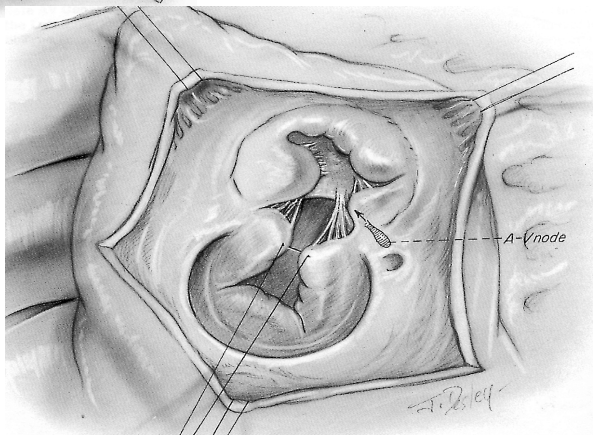

Ebstein…the tricuspid valve complex

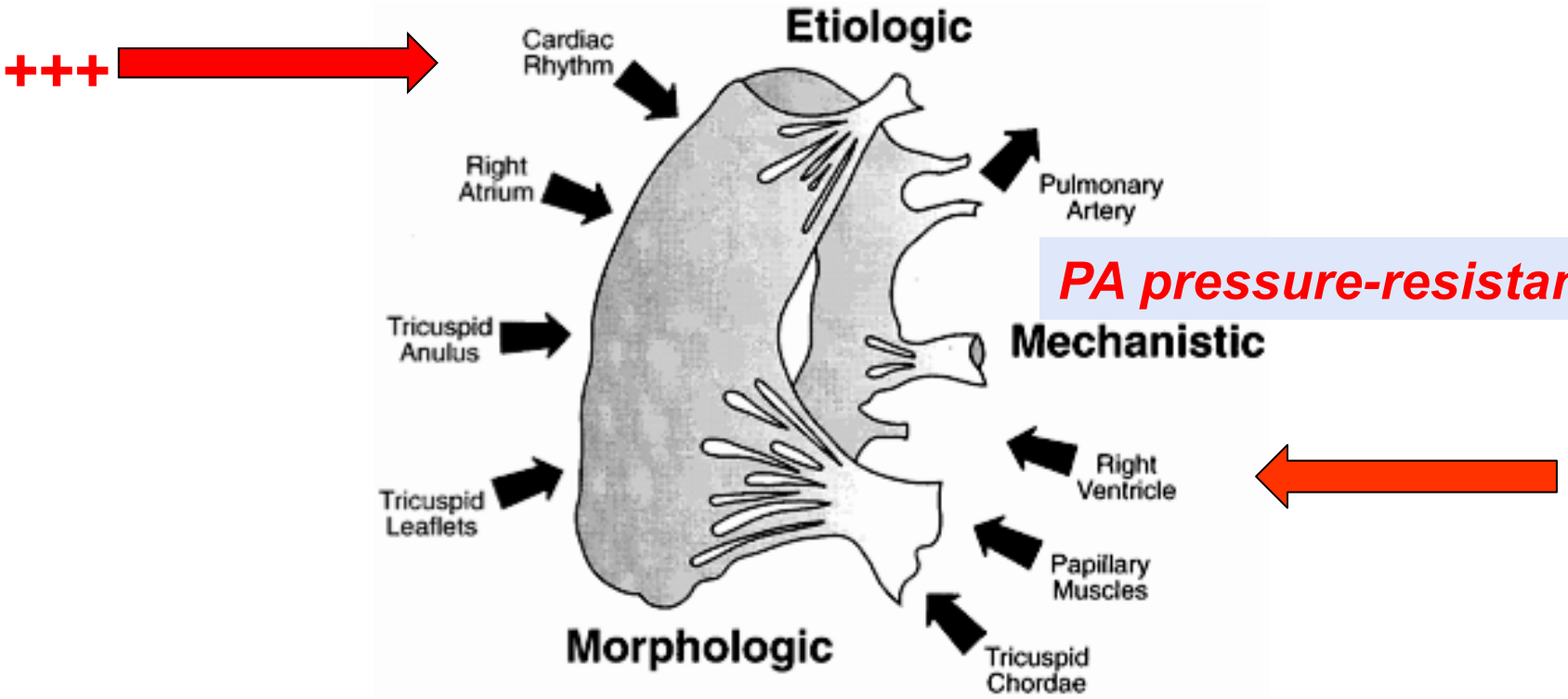

Tricuspid Valve Disease:
Tricuspid Valve Complex Perspective

Curr Probl Cardiol 2002;27:97-144.

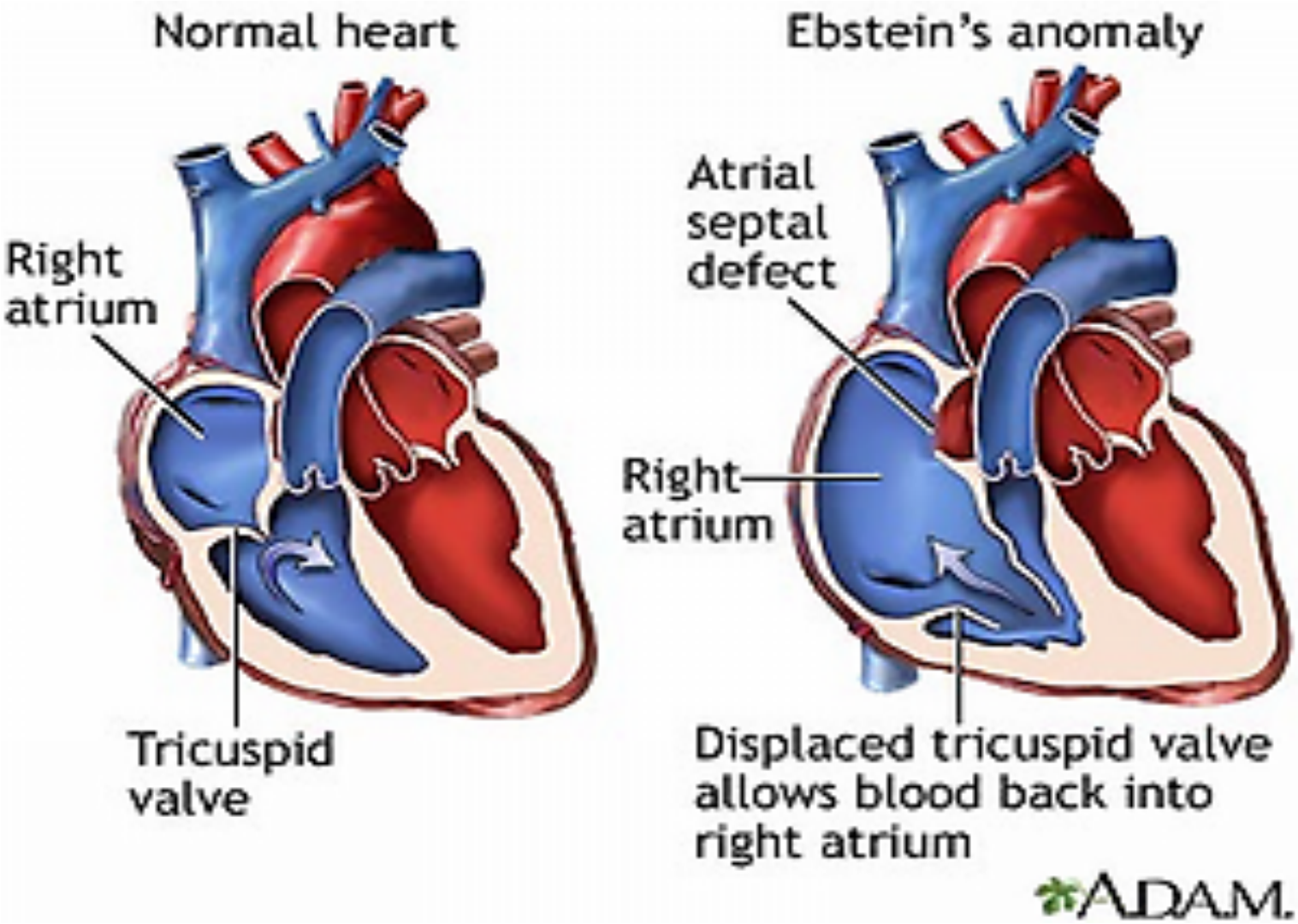
Normal heart
Right atrium
Tricuspid valve
Ebstein's anomaly
Atrial septal defect
Right atrium
Displaced tricuspid valve allows blood back into right atrium
A.D.A.M.

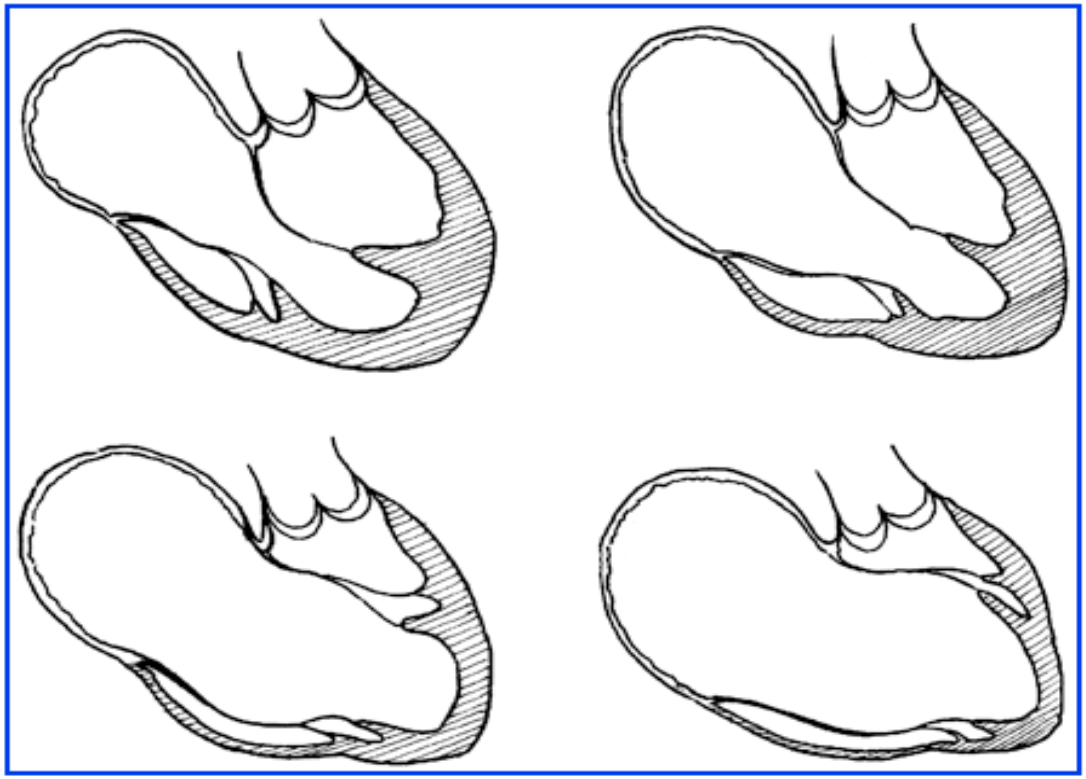

Schematic 1 Ebstein classification according to Carpentier and co-workers [10].

Type A (top left): the volume of the true right ventricle is adequate; type B (top right), there is a large atrialised component of the right ventricle but the anterior leaflet moves freely; type C (bottom left), the anterior leaflet is severely restricted in its movement and may cause significant obstruction of the right ventricular outflow tract; and type D (bottom right), almost complete atrialisation of the right ventricle with the exception of a small infundibular component.

Ebstein

1970: Danielson
Atrialized RV plicature

1980: Carpentier
RV and valvar mobilisation

1990: Da Silva
Extensive valvar mobilisation

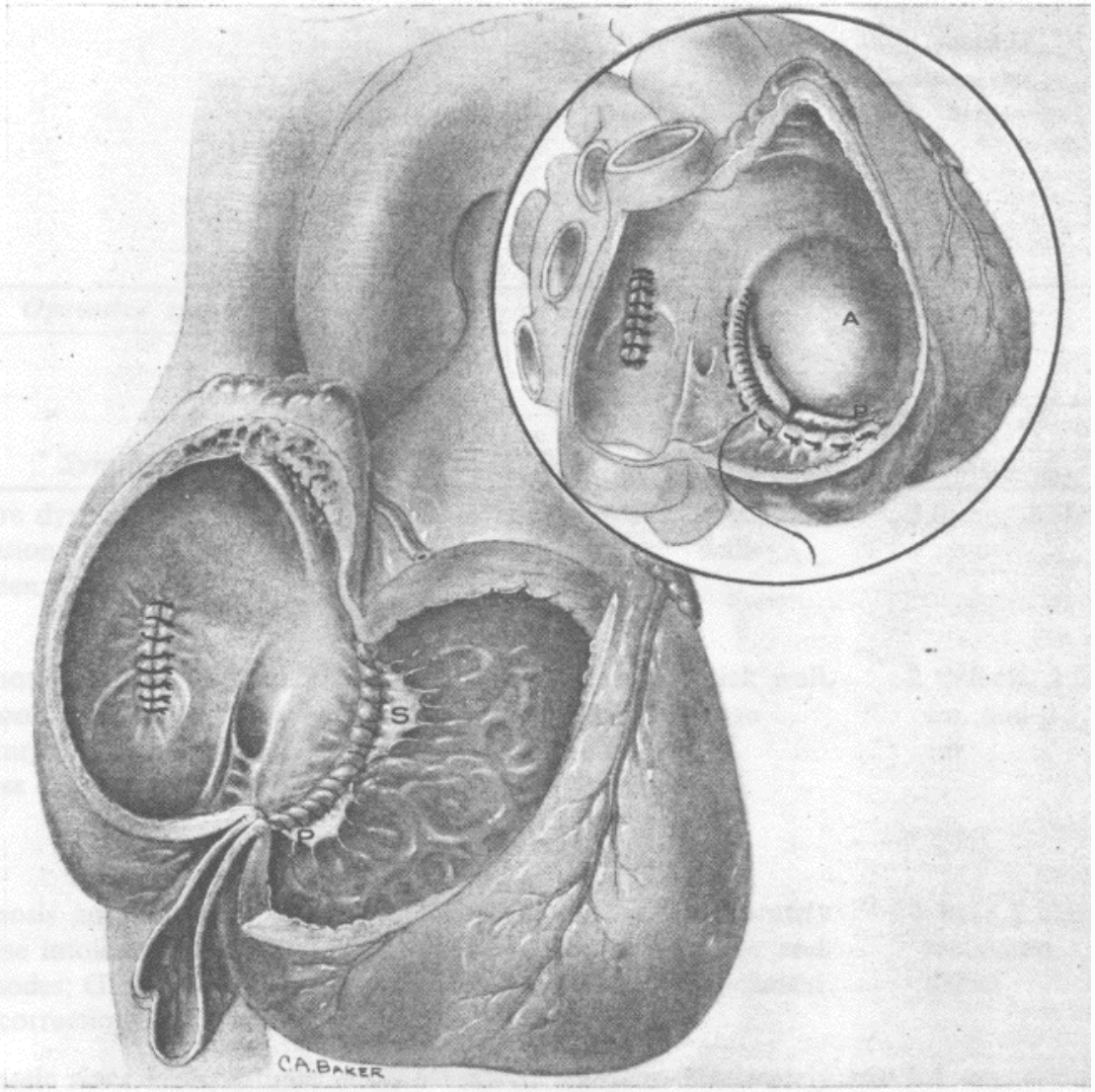

Fig. 5. (1) Abnormal leaflets transposed to normal functional position. (2) Annulus red

Surgery for Ebstein's anomaly: the clinical and echocardiographic evaluation of a new technique.

Quaegebeur JM, Sreeram N, Fraser AG, Bogers AJ, Stümper OF, Hess J, Bos E, Sutherland GR.

J Am Coll Cardiol. 1991 Mar 1;17(3):722-8.

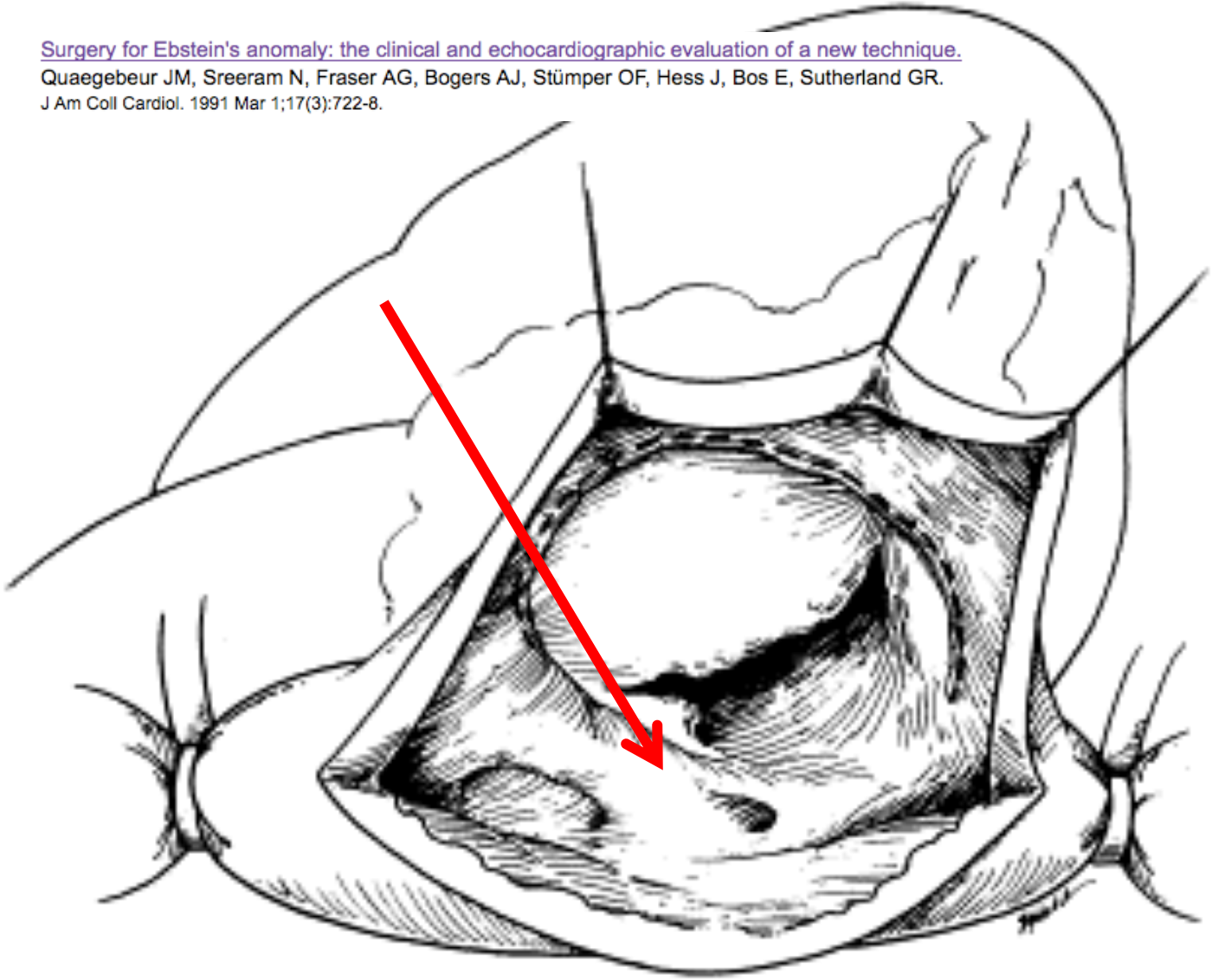

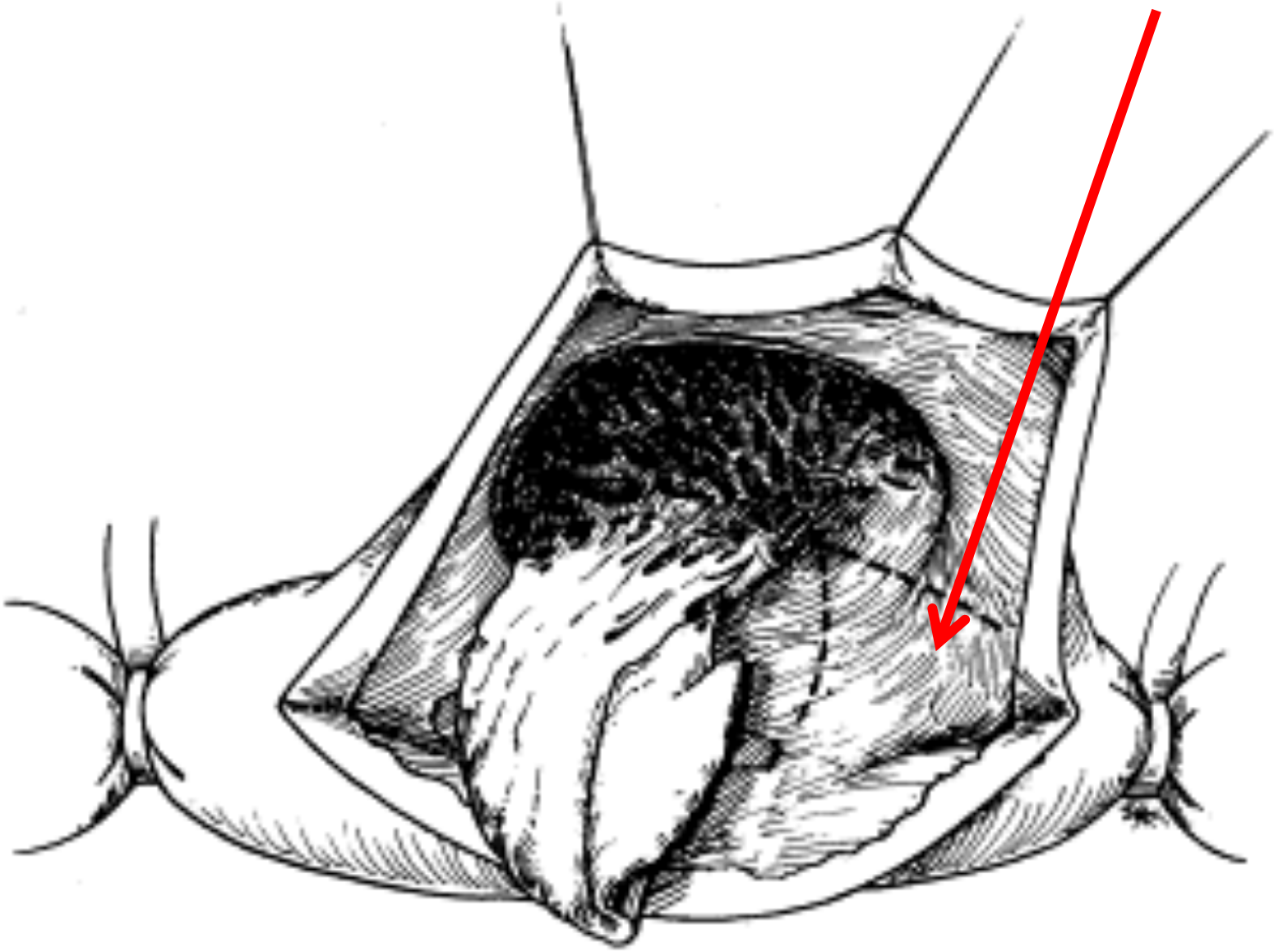

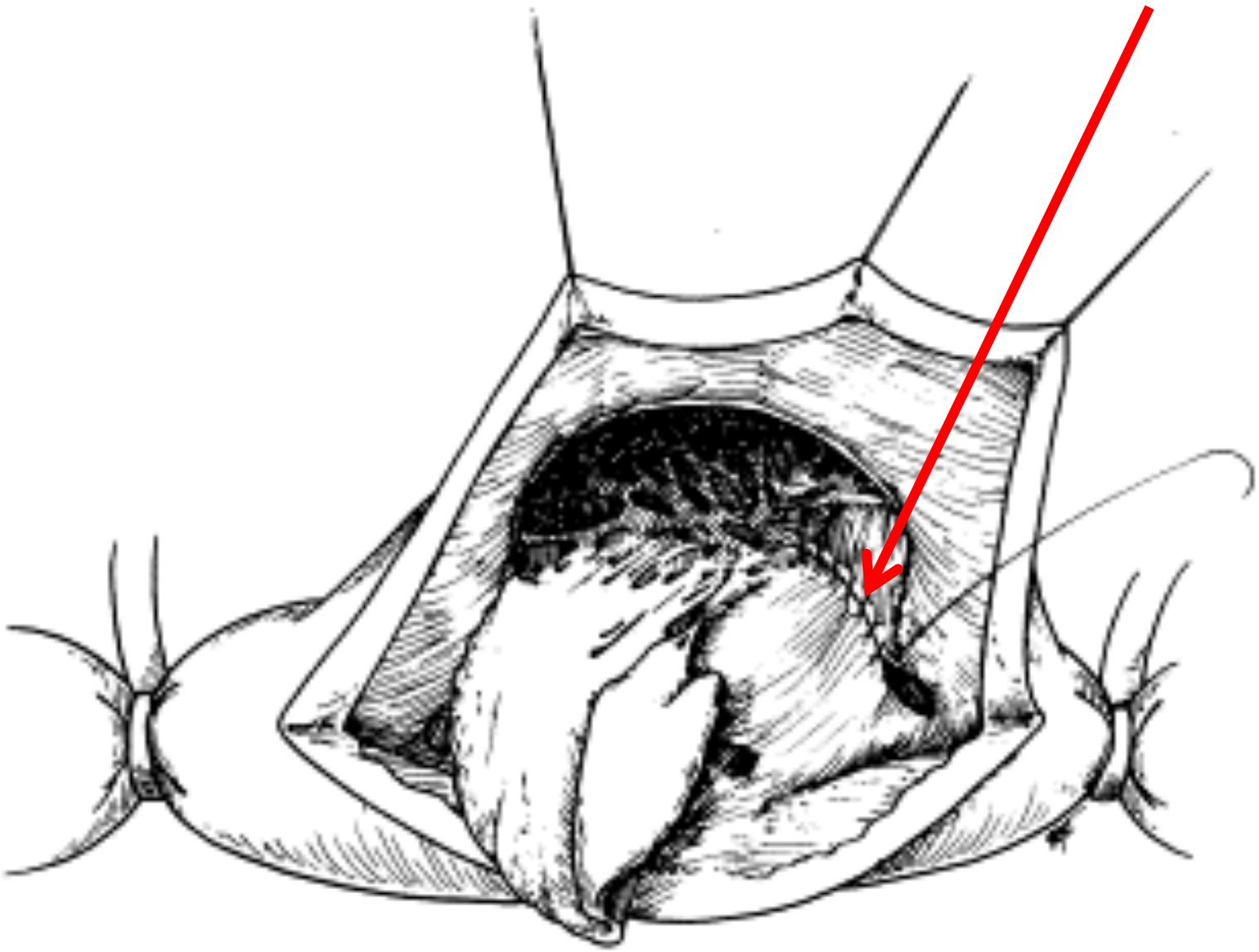

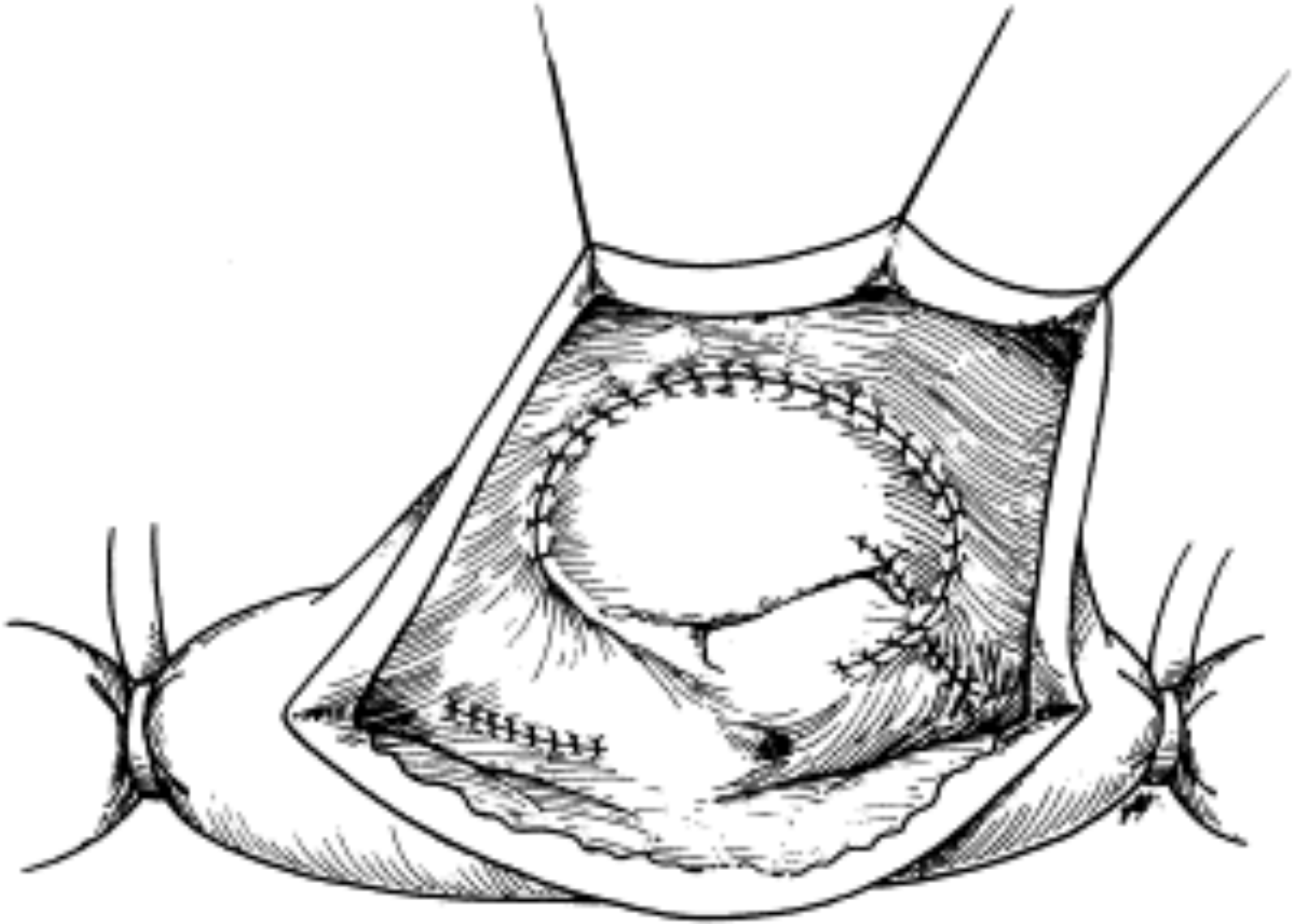

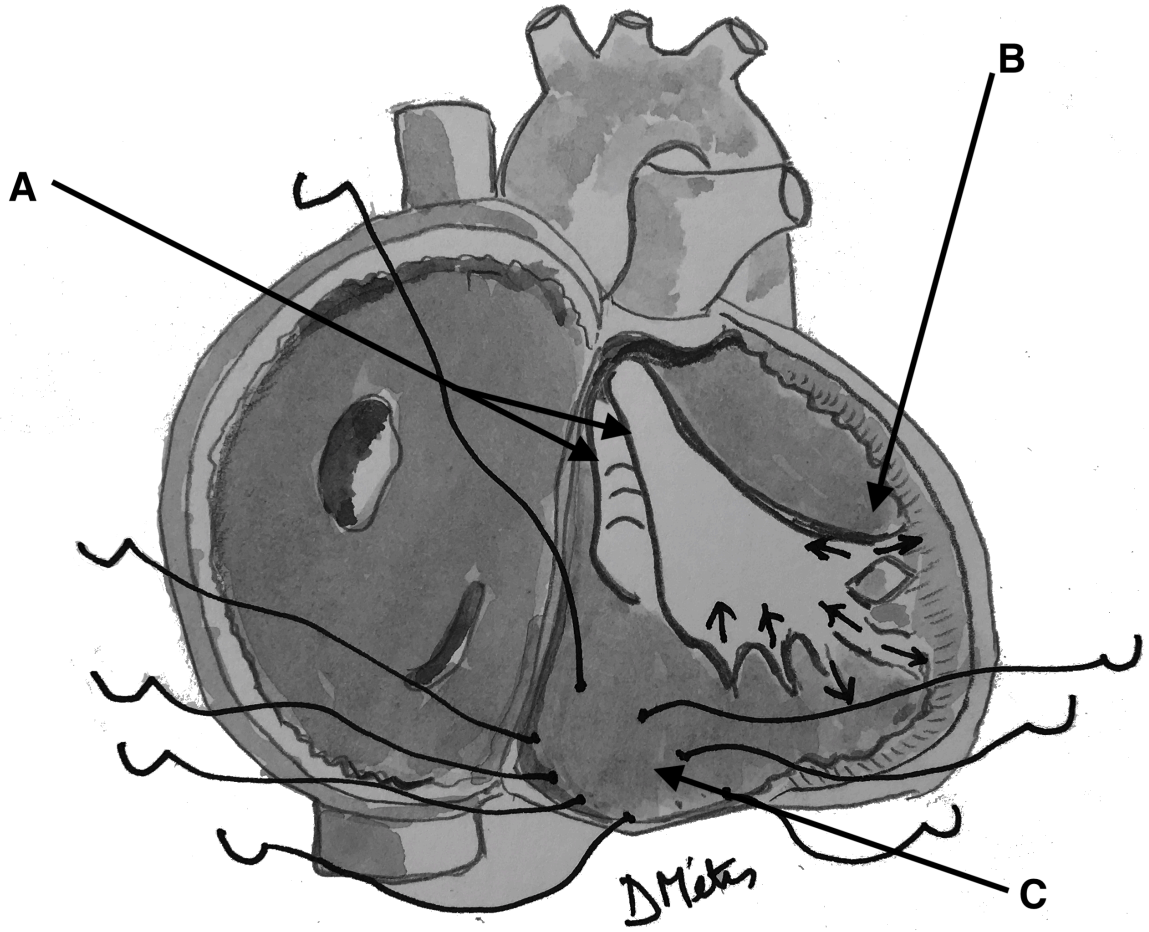

da Silva JP, Baumgratz JF, da Fonseca L. The cone reconstruction of the tricuspid valve in Ebstein's anomaly. The operation: early and midterm results. J Thorac Cardiovasc Surg 2007;133:221–3.

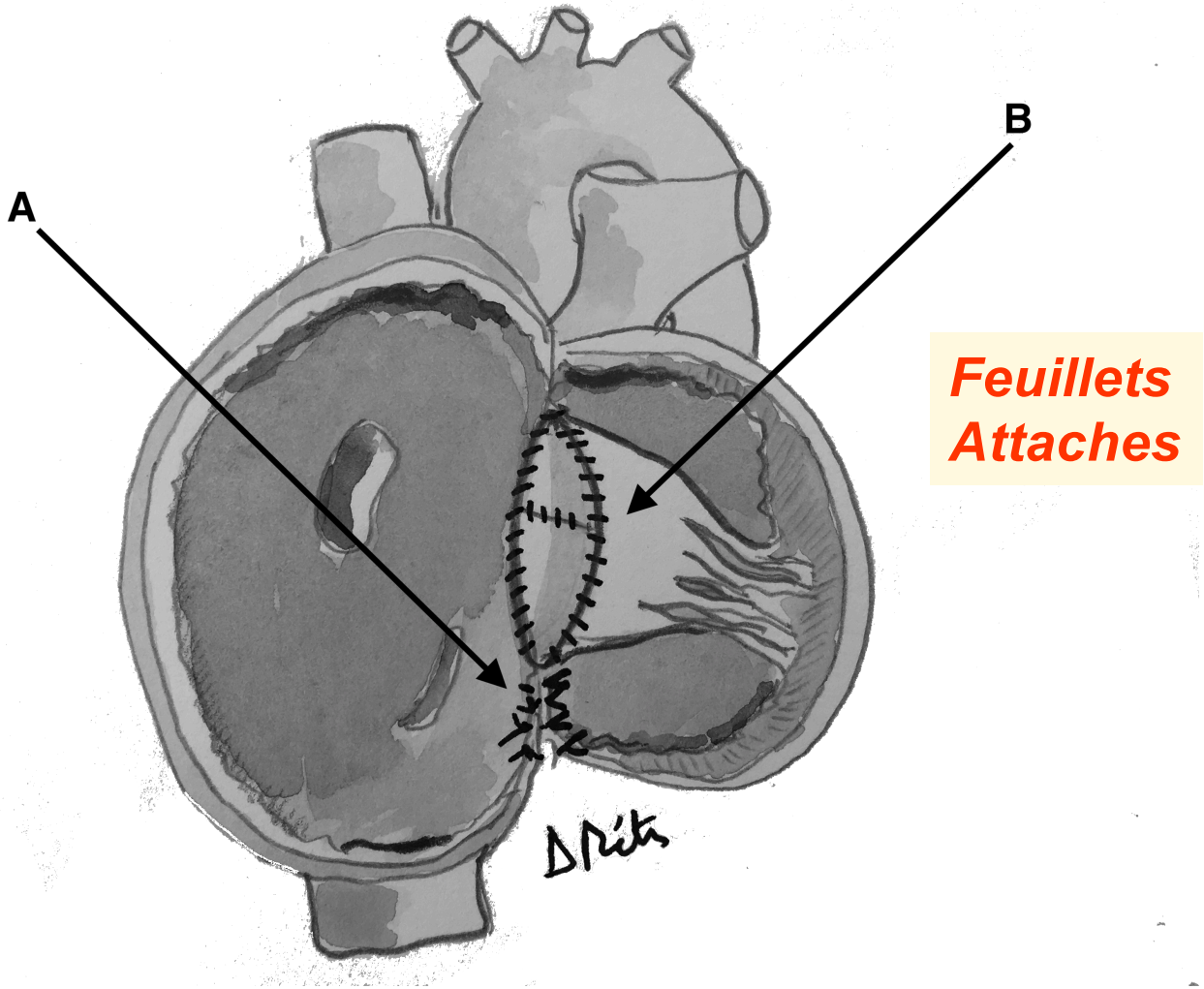

da Silva JP, Baumgratz JF, da Fonseca L. The cone reconstruction of the tricuspid valve in Ebstein's anomaly. The operation: early and midterm results. J Thorac Cardiovasc Surg 2007;133:221–3.

Operative steps for Ebstein's anomaly repair

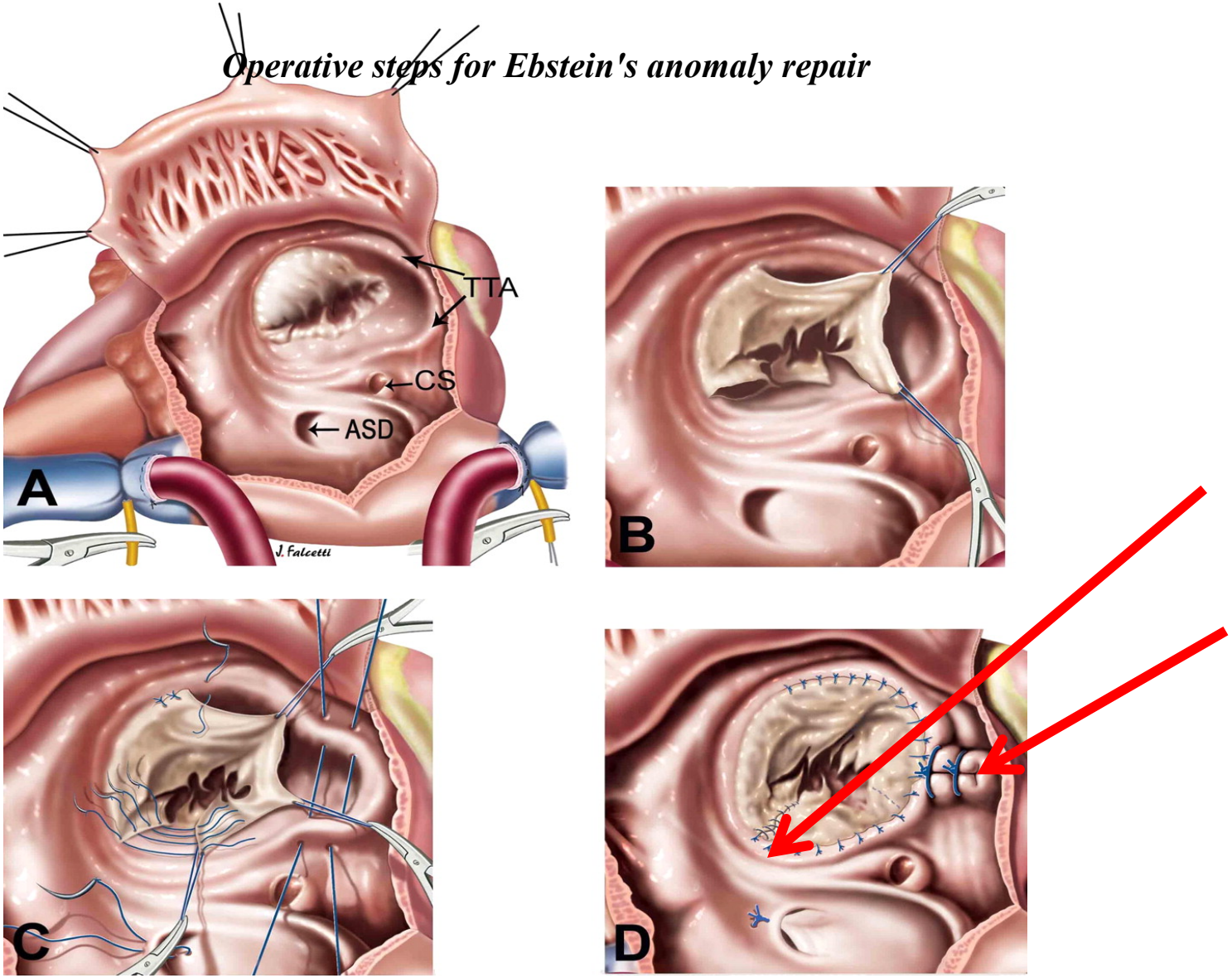

Copyright ©2007 The American Association for Thoracic Surgery

The Journal of
THORACIC AND
CARDIOVASCULAR SURGERY

Surgical sequence of tricuspid valve repair with incorporation of the septal leaflet

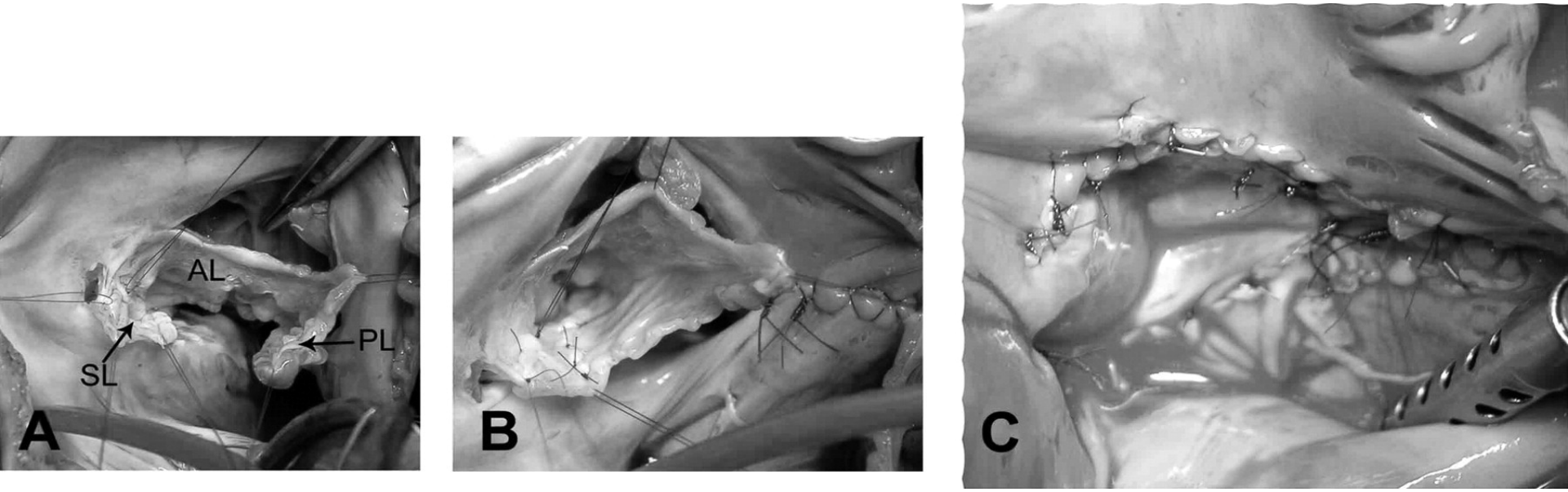

da Silva J. P. et al.; J Thorac Cardiovasc Surg 2007;133:215-223

The Journal of
THORACIC AND
CARDIOVASCULAR SURGERY

Copyright ©2007 The American Association for Thoracic Surgery

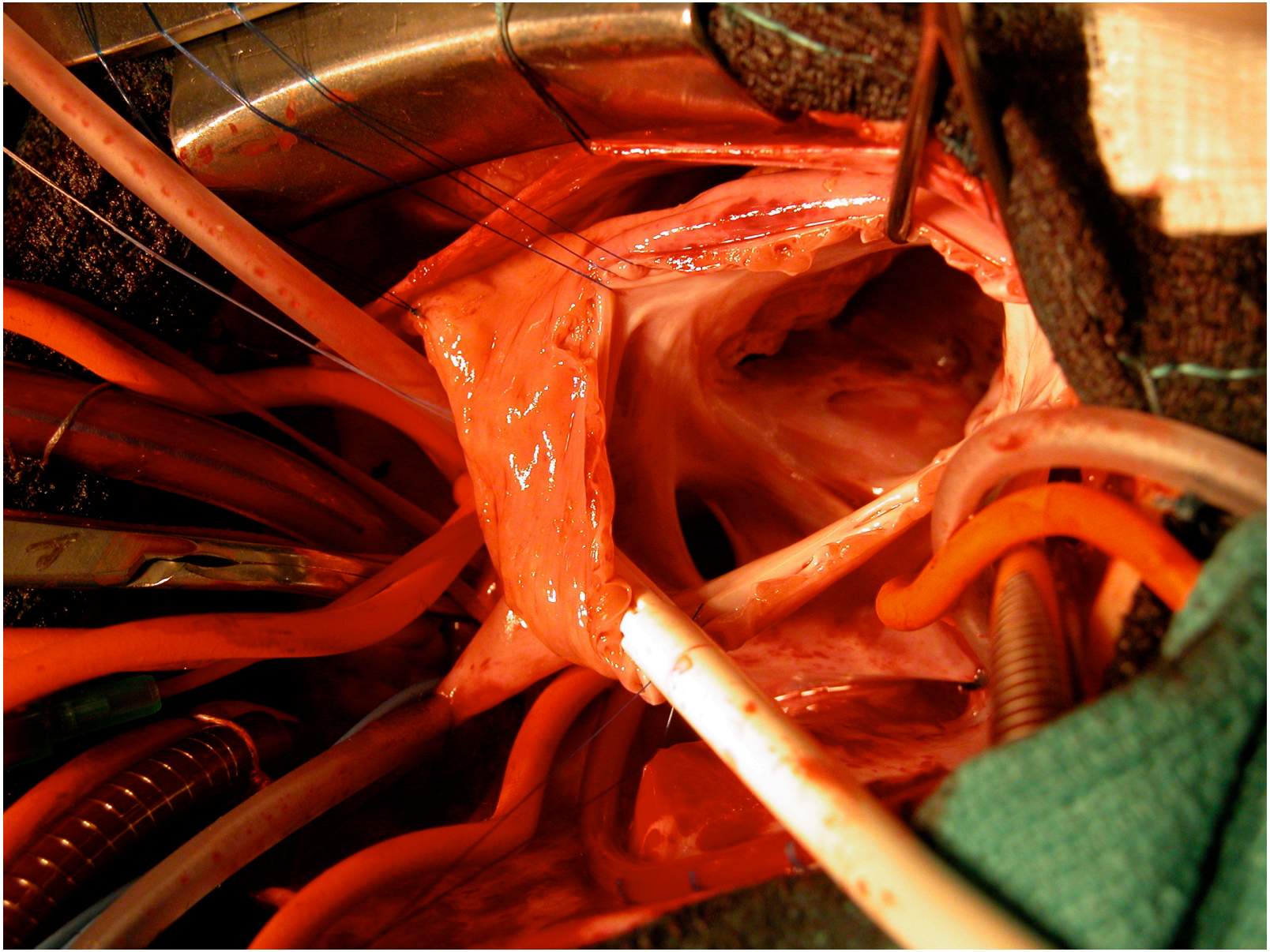

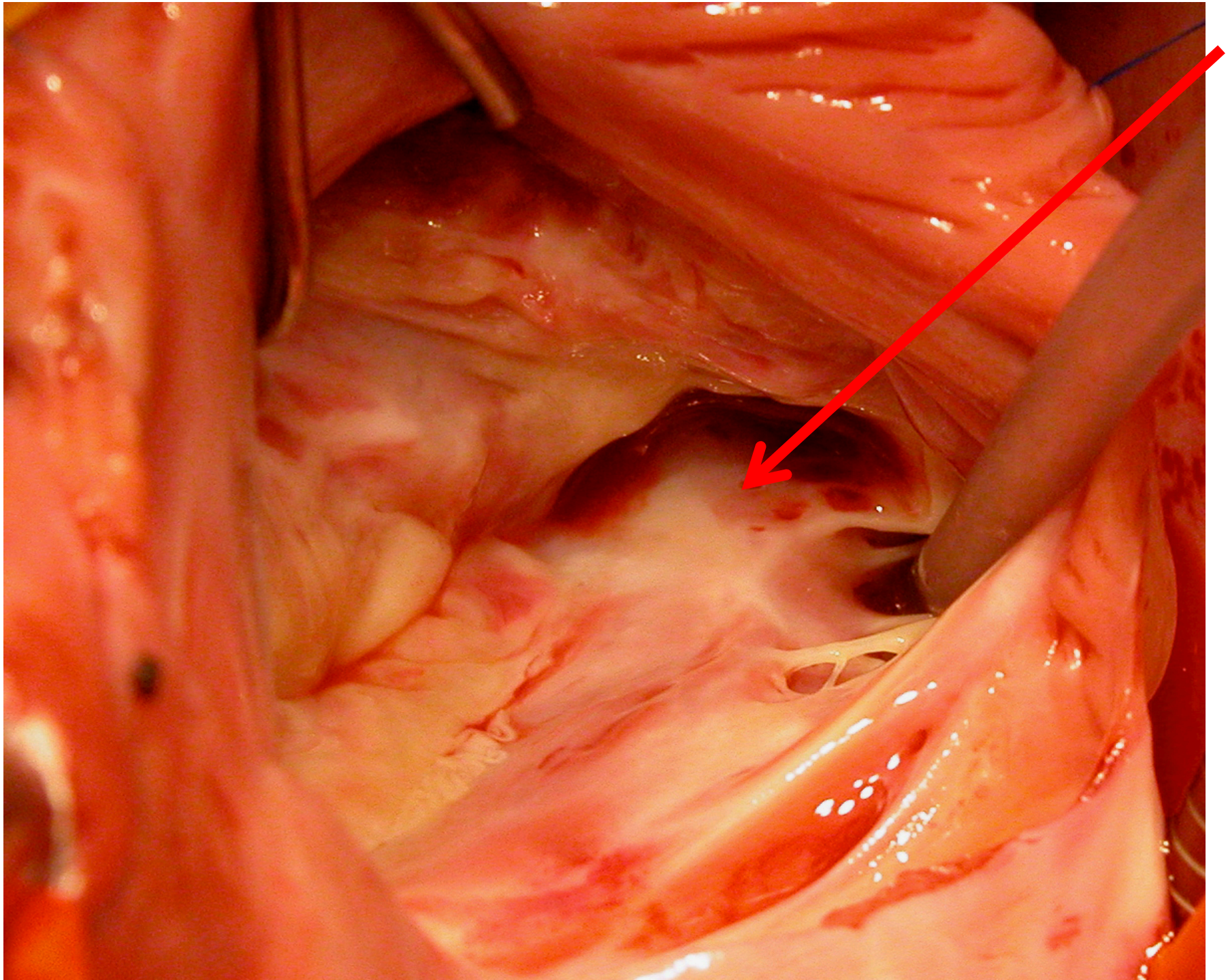

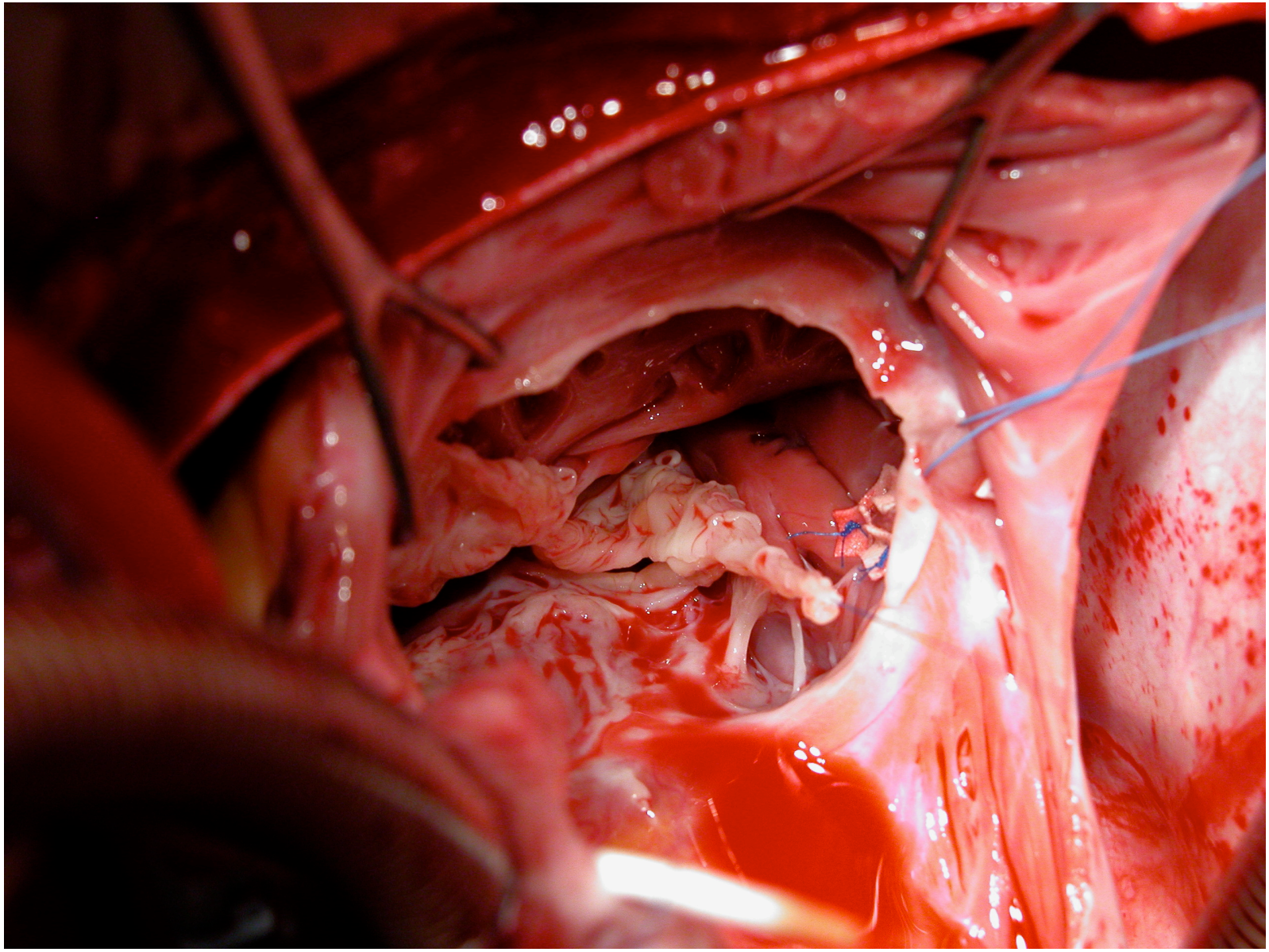

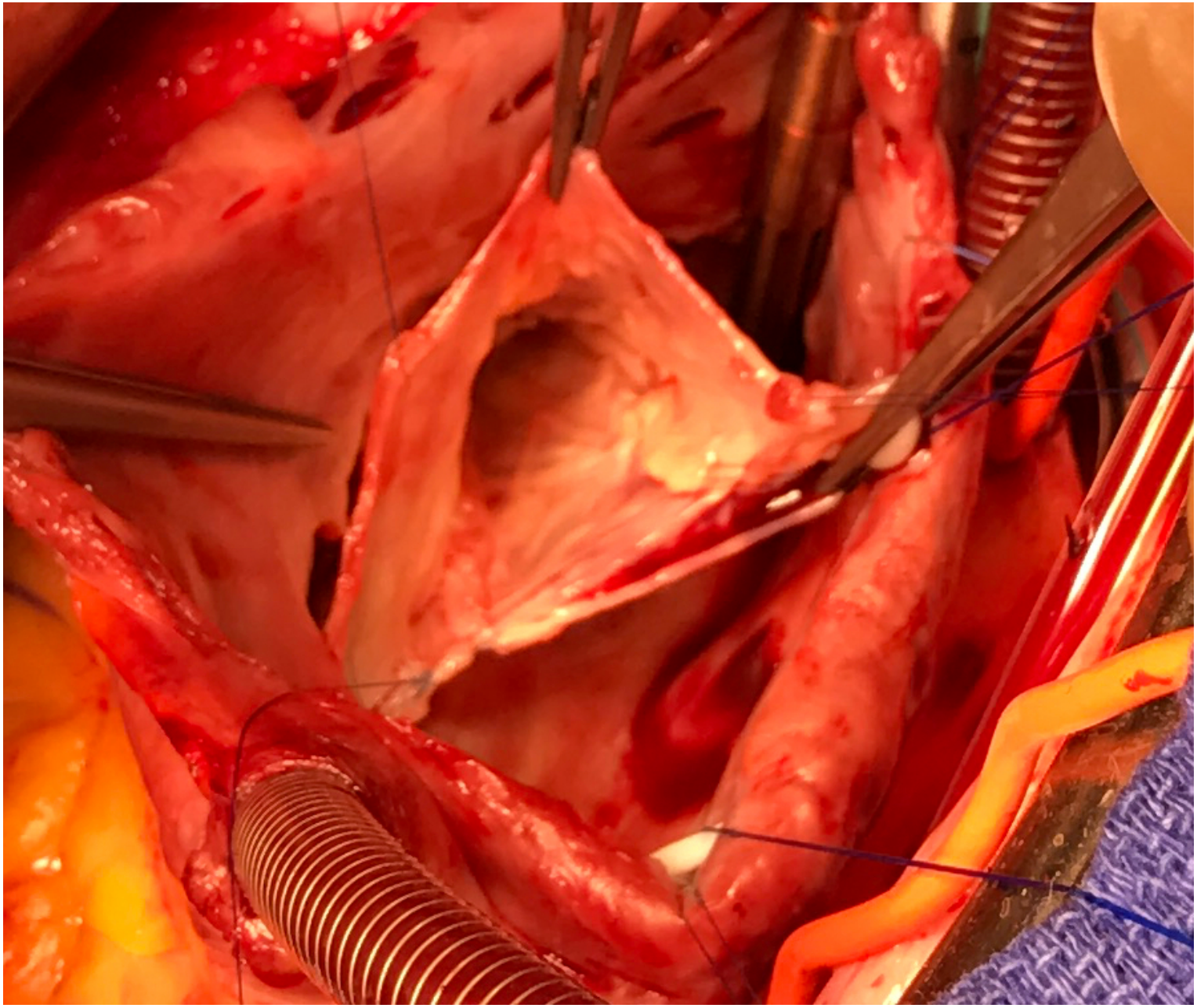

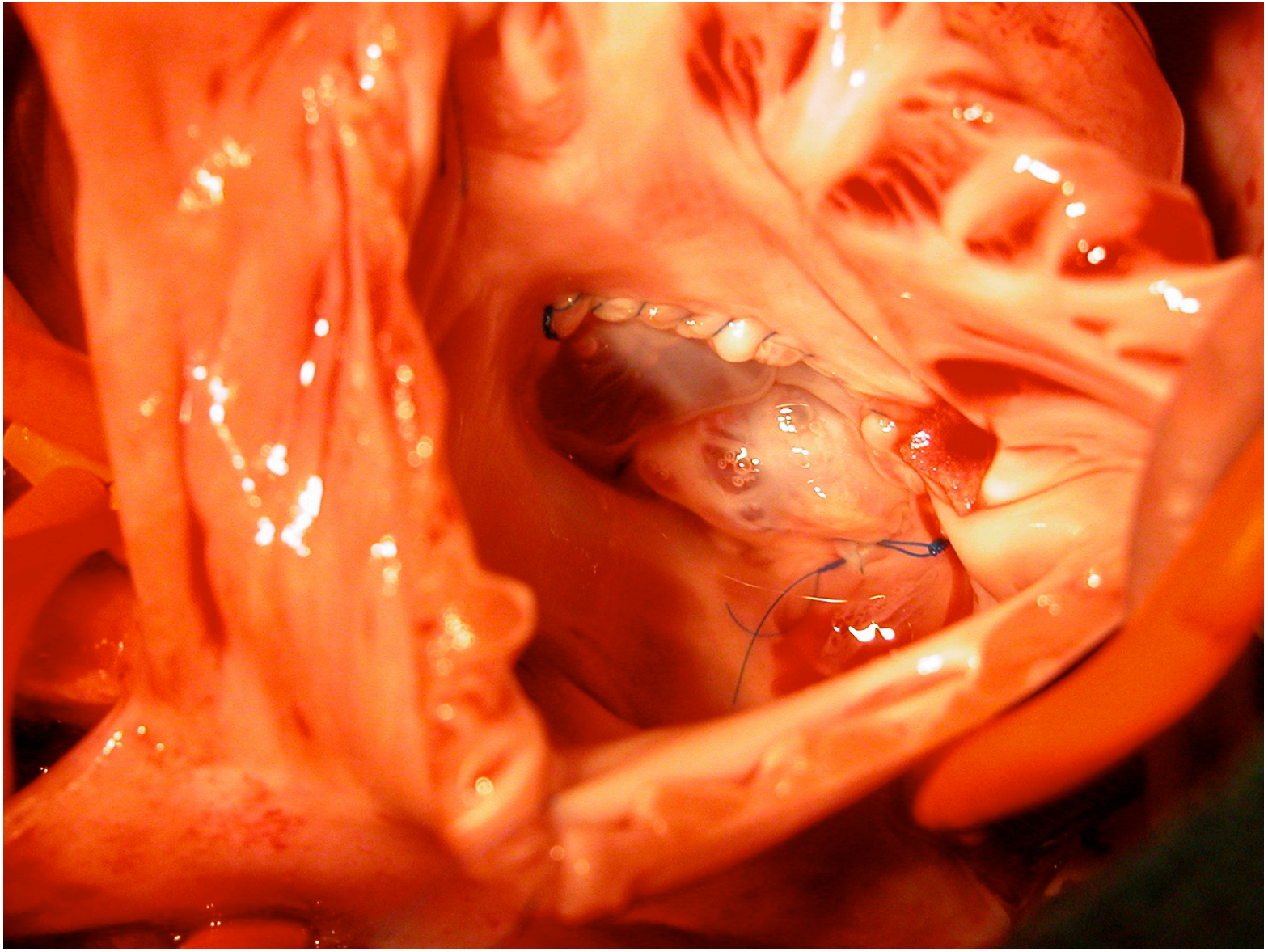

Risque de BAV

Sténose tricuspide rarement rapportée

Fuite résiduelle +/- importante selon type anatomique

Suites habituellement simples sauf si pb post charge VD

- *Sténoses anatomiques (enfant petit, né)*
- *Résistances (rares, thrombophlébites)*
- *VG+++ (HTAP post capillaire masquée)*

Si on opère trop tard…

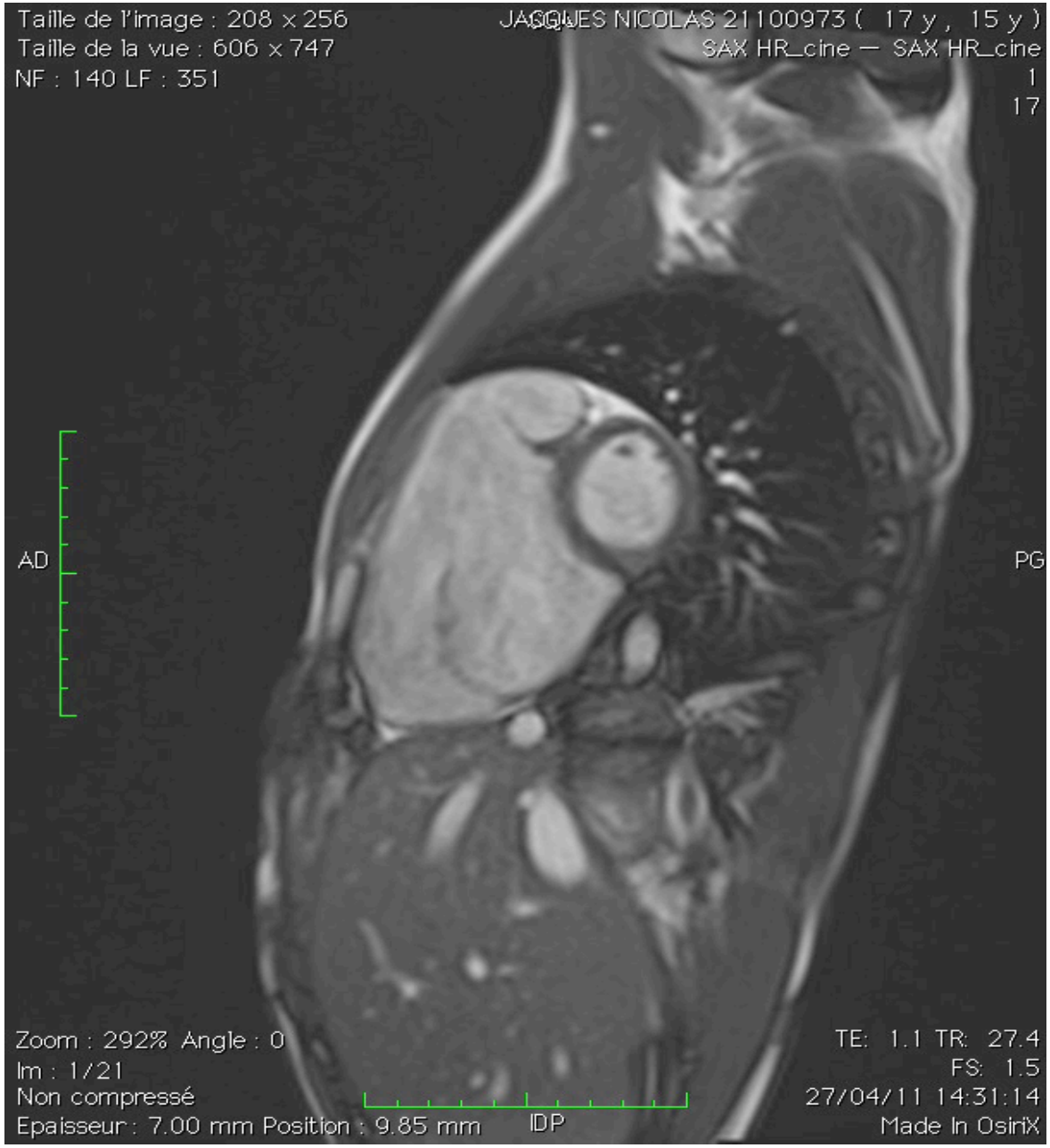
Taille de l'image : 208 x 256
Taille de la vue : 606 x 747
NF : 140 LF : 351
JACQUES NICOLAS 21100973 (17 y , 15 y)
SAX HR_cine — SAX HR_cine
1
17
AD
PG
Zoom : 292% Angle : 0
Im : 1/21
Non compressé
Epaisseur : 7.00 mm Position : 9.85 mm
IDP
TE: 1.1 TR: 27.4
FS: 1.5
27/04/11 14:31:14
Made In OsiriX

Combien de temps est-on asymptomatique avec une maladie d'Ebstein?

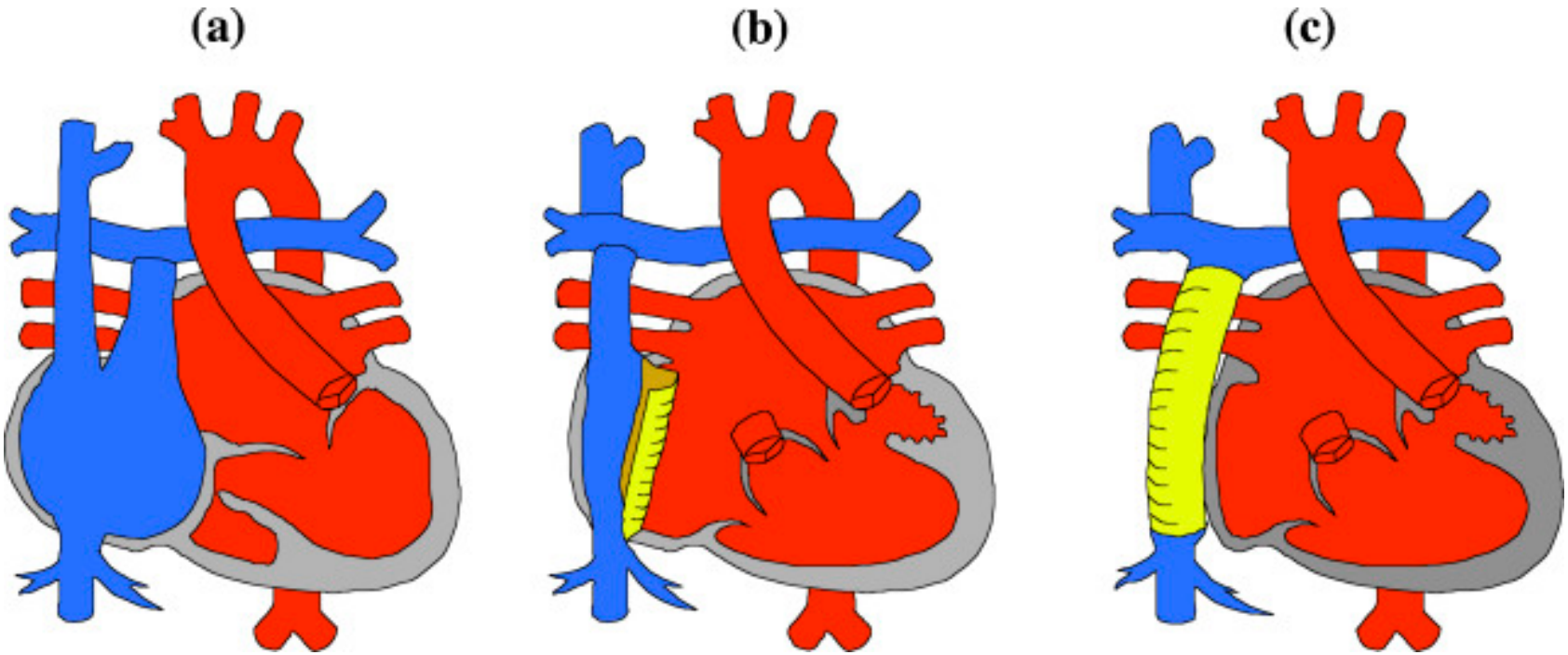

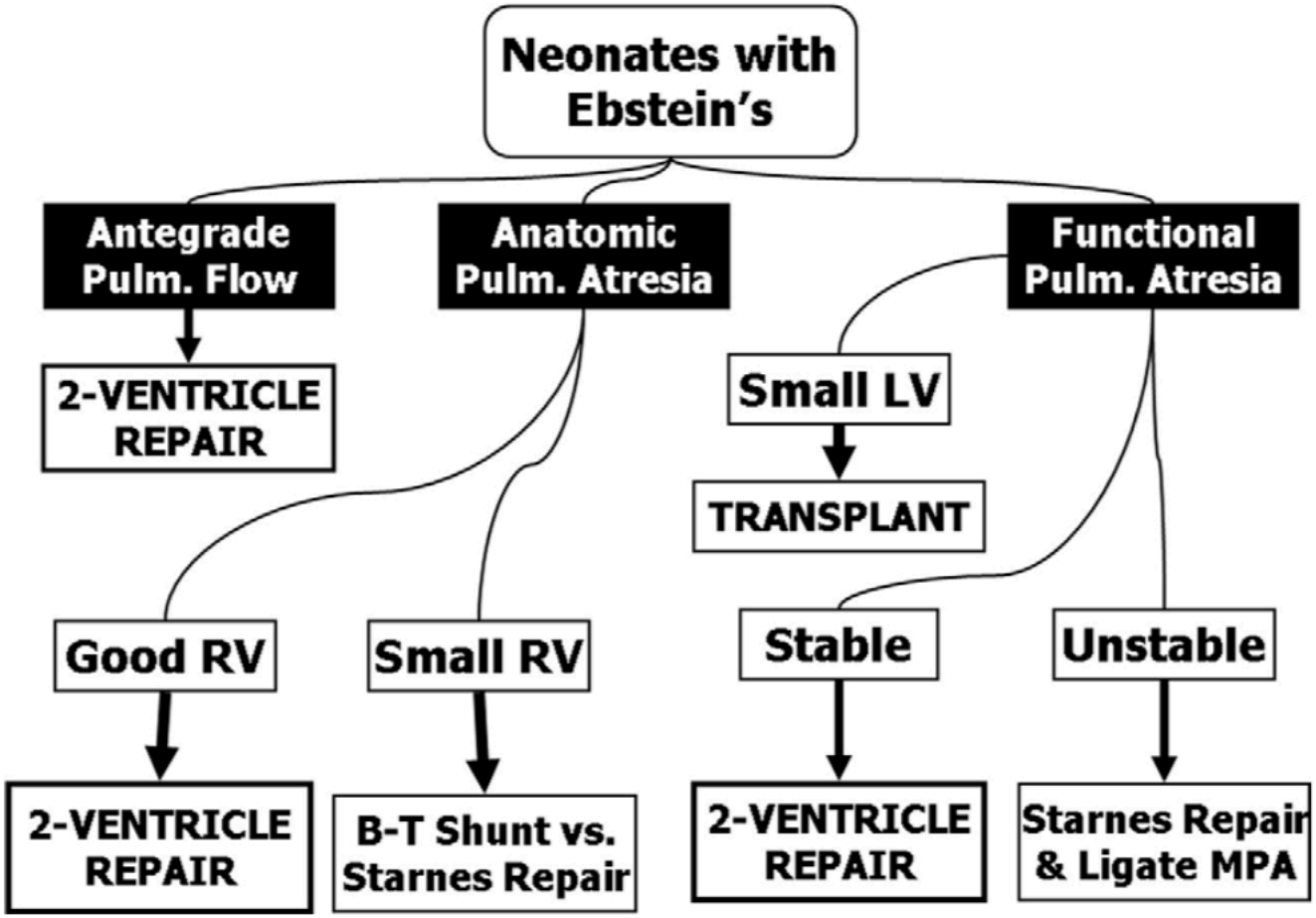
Neonates with Ebstein's
Antegrade Pulm. Flow
Anatomic Pulm. Atresia
Functional Pulm. Atresia
2-VENTRICLE REPAIR
Small LV
TRANSPLANT
Good RV
Small RV
Stable
Unstable
2-VENTRICLE REPAIR
B-T Shunt vs. Starnes Repair
2-VENTRICLE REPAIR
Starnes Repair & Ligate MPA
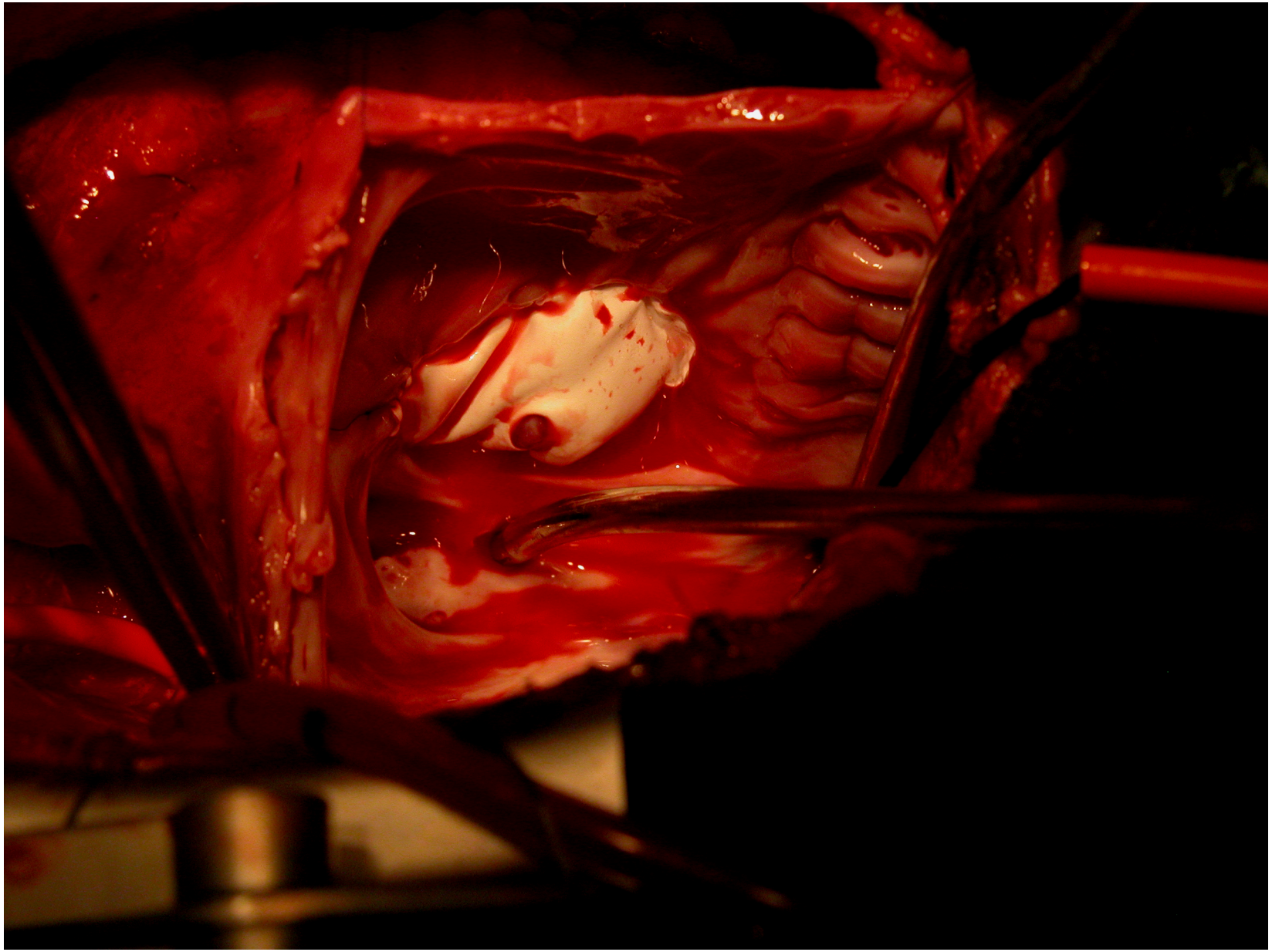
Starnes?