Anaesth Crit Care Pain Med 40 (2021) 100844

Contents lists available at ScienceDirect

Anaesthesia Critical Care & Pain Medicine

journal homepage: www.elsevier.com

Editorial

Radial artery puncture and ultrasound imaging: Three reasons why

In this issue of ACCPM, Kumar et al. conducted an anatomo-physiological study about the effect of different peripheral nerve blocks on radial artery blood flow [1]. This study encompasses several fields of anaesthetists' daily activity, including anatomy, regional anaesthesia, ultrasonography and haemodynamics. They reported that blocking the median nerve at the forearm level increases radial artery cross-sectional area (CSA) by 82% and significantly improves blood flow. A radial nerve block alone also increased blood flow but to a much lesser extent (+ 20%) and when combined with a median nerve block, it had no additional effect. This means that the radial artery is mainly innervated by the median nerve rather than by the radial nerve.

As reminded by the authors of this study, the radial artery has an important alpha 1 innervation [2] leading to a vasospastic reaction when contact with a foreign body occurs. Latham et al. have shown in children that a first unsuccessful cannulation compromises subsequent attempts, as the artery is intensely vasoconstricted [3]. Even in case of first attempt successful cannulation, radial blood flow diminishes for at least five to ten minutes, while ulnar arterial blood flow increases concomitantly [4]. This means that failure of the first attempt to cannulate the radial artery will compromise subsequent attempts. Besides, cannulation of the radial artery may be associated with radial artery occlusion in more than 5% of cases [5] and at times can lead to hand pain, reflex sympathetic dystrophy or loss of hand function.

Means to prevent or treat radial artery spasm to facilitate cannulation are not clearly established [5]. When facing a radial artery vasospasm, the possible therapeutic options are systemic administration of a vasodilator with the subsequent risk of systemic hypotension. Topical or periarterial infiltration of nitroglycerin, with or without local anaesthetic added also increases the vessel diameter without affecting blood pressure [6,7]. Nitroglycerin can rapidly alleviate the vasospasm and re-establish a radial pulse. Kumar et al. showed that a median nerve block increases radial artery blood flow by inducing vasodilation and it is hoped that a median nerve block could also suppress puncture-induced vasospasm [1].

So, why using ultrasound to cannulate the radial artery?

First, because ultrasound imaging can provide an image of the artery in its actual position and its real conformation. The radial artery is not always a straight and linear vessel, especially in the elderly, and the risk of transfixing the artery is very important. As reported by Lee et al., the radial artery is a thin vessel with a mean diameter of 2.2 mm (1.5–3 mm), which is very superficial and can be found at a mean depth of 2 mm in adults [8]. This can make this vessel sometimes difficult to cannulate. In addition, routine preoperative Doppler ultrasound examination of the vascular artery may uncover peripheral arterial disease and lead to alter the puncture site [9].

Secondly, because real-time ultrasound-guided puncture improves the first attempt success rate of radial artery cannulation. White et al. indeed performed a systematic review in adults and children and demonstrated strong evidence that ultrasound guidance improves the success rate of the first attempt to cannulate the radial artery [10]. A significant reduction in time to cannulation with ultrasound guidance is also demonstrated. Ultrasound-guidance does however neither improve the overall cannulation success rate [11] nor lead to a reduced rate of complications [10]. A similar benefit is also observed in paediatrics.

Thirdly, because blocking the median nerve increases the radial artery CSA, which may be helpful in the cannulation process and increase the success rate of the first attempt that may vary between 20% and 80% [11]. It could perhaps also relieve puncture-related arterial spam by blocking the neutrally supplied vaso-reactivity of the radial artery. Furthermore, ultrasound imaging may help to visualise changes in radial artery diameter and Doppler imaging can objectively disclose arterial blood flow before and after treatment.

Finally, USG could perhaps improve modified Allen's test reliability before cannulation of the radial artery. Allen's test, as modified by Wright aims to demonstrate how an altered radial blood flow (which may compromise hand blood flow) can be substituted by the ulnar artery. This clinical test should thus be performed before every radial cannulation. The results of this test are however sometimes inconclusive. Doppler imaging could improve the performance of this test showing, without possible contestation, that the ulnar artery can maintain hand blood flow when the radial artery is occluded. As shown in Fig. 1, when the palmar arterial arch in the hand is not effective enough, ulnar blood flow immediately compensates the radial blood flow when the radial artery is interrupted by a firm compression or occlusion. As the direction of the flow is reversed, we can affirm that it is indeed a compensation provided by the ulnar artery. If such reversed flow is poor or absent, then the ulnar artery supply is likely not sufficient or even absent, and it may not be safe to cannulate the radial artery. In addition, a more distal cannulation site is now often chosen, especially for percutaneous coronary angiography. This puncture

https://doi.org/10.1016/j.accpm.2021.100844

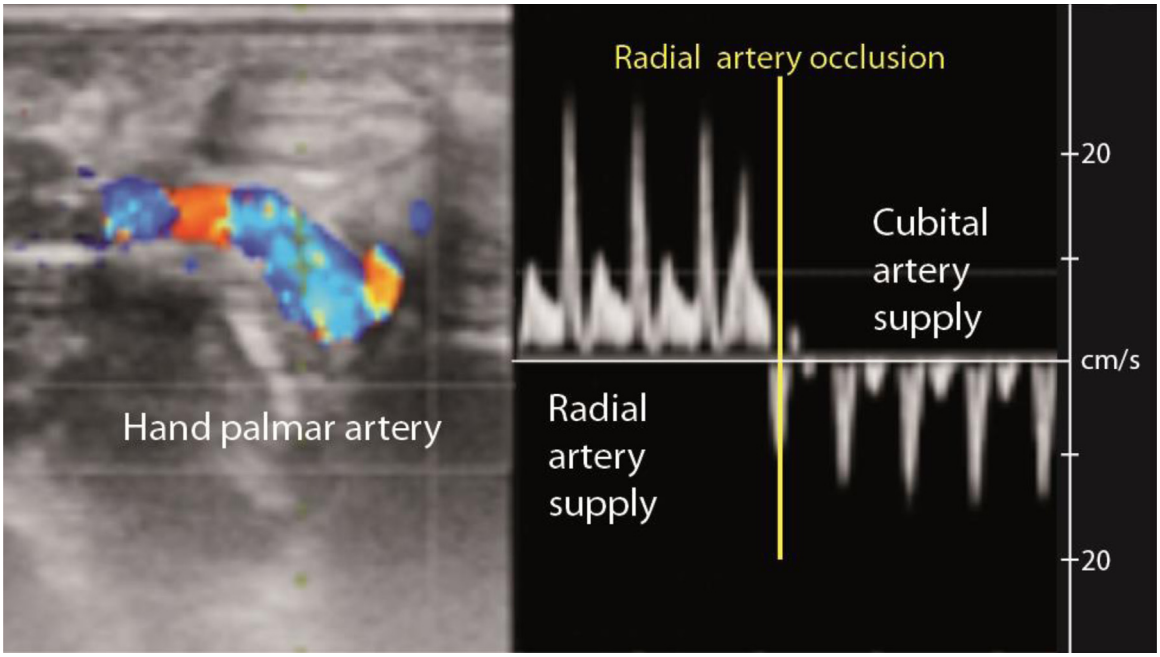

Fig. 1. Substitution by the ulnar artery after interruption of the radial arterial supply of the hand. Pulsed Doppler shows that the cubital artery immediately compensates when the radial artery blood flow is absent (P. Zetlaoui's Personal data).

site, distal to the palmar arch, maintains hand blood flow even if occlusion occurs, as also shown by Doppler imaging [12].

By showing actual position, trajectory and shape of the artery, improving first attempt rate and objectively assessing the modified Allen's test, ultrasounds are probably the best friend of the radial artery.

Ethics

None declared.

Declaration of interest

The authors declare that they have no competing interest.

References

[1] Sinha C, Kumar A, Kumari P, Kumar A, Bhar D, Singh V. Does radial or median nerve blocks affect the area and blood flow of radial artery? Anaesth Crit Care Pain Med 2021;40(2):100831. http://dx.doi.org/10.1016/j.accpm.2021.100831.
[2] He GW, Yang CQ. Characteristics of adrenoceptors in the human radial artery: clinical implications. J Thorac Cardiovasc Surg 1998;115(5):1136–41.
[3] Latham GJ, Bosenberg AT, Low DK. Images in anesthesiology: radial artery spasm in an infant as documented by high-frequency micro-ultrasound. Anesthesiology 2014;120:1254.
[4] Kim SY, Lee JS, Kim WO, Sun JM, Kwon MK, Kil HK. Evaluation of radial and ulnar blood flow after radial artery cannulation with 20- and 22-gauge cannulae using duplex Doppler ultrasound. Anaesthesia 2012;67:1138–45.
[5] Ferreira-Martins J, Lim PO. Two-step distal radial artery cannulation for challenging radial anatomies. Cardiology 2020;16:1–7.
[6] Pancholy SB, Coppola J, Patel T:. Subcutaneous administration of nitroglycerin to facilitate radial artery cannulation. Catheter Cardiovasc Interv 2006;68:389–91.
[7] Majure DT, Hallaux M, Yeghiazarians Y, Boyle AJ. Topical nitroglycerin and lidocaine locally vasodilate the radial artery without affecting systemic blood pressure: a dose-finding phase I study. J Crit Care 2012;27(532):e9–13.
[8] Lee D, Kim JY, Kim HS, Lee KC, Lee SJ, Kwak HJ. Ultrasound evaluation of the radial artery for arterial catheterization in healthy anesthetized patients. J Clin Monit Comput 2016;30:215–9.
[9] Chakravarthy M, Prabhakumar D, Shivalingappa B, Rao S, Padgaonkar S, Hosur R, et al. Routine preoperative Doppler ultrasound examination of arterial system in patients undergoing cardiac surgery is beneficial: a retrospective study. Ann Card Anaesth 2020;23:298–301.
[10] Ligh White L, Halpin A, Turner M, Wallace L. Ultrasound-guided radial artery cannulation in adult and paediatric populations: a systematic review and meta-analysis. Br J Anaesth 2016;116:610–7.
[11] Bhattacharjee S, Maitra S, Baidya DK. Comparison between ultrasound guided technique and digital palpation technique for radial artery cannulation in adult patients: an updated meta-analysis of randomized controlled trials. J Clin Anesth 2018;47:54–9.
[12] Sgueglia GA, Di Giorgio A, Gaspardone A, Babunashvili A. Anatomic basis and physiological rationale of distal radial artery access for percutaneous coronary and endovascular procedures. JACC Cardiovasc Interv 2018;11:2113–9.

Paul J. Zetlaoui*, Dan Benhamou
Département d'Anesthésie-réanimation, Hôpital Bicêtre AP-HP, Le Kremlin-Bicêtre Cedex, France

*Corresponding author at: Département d'Anesthésie-réanimation, Hôpital Bicêtre AP-HP, 78, Rue du Général Leclerc, 94270 Le Kremlin-Bicêtre Cedex, France
E-mail address: paul.zetlaoui@aphp.fr (P.J. Zetlaoui)

Available online 24 March 2021