L'INSTITUT DE RYTHMOLOGIE ET MODÉLISATION CARDIAQUE BORDEAUX

CIA - CAV partiel - RVPA partiel

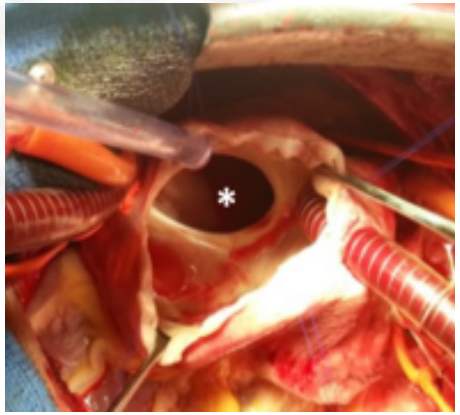

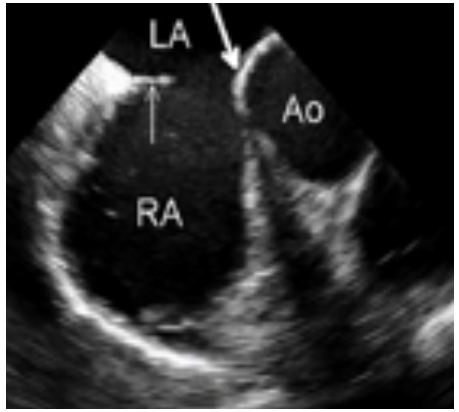

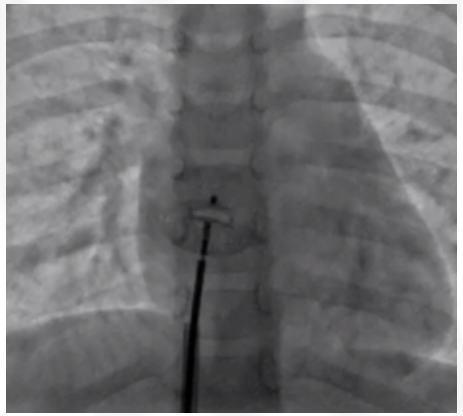

Zakaria Jalal – MD, PhD

Service des cardiopathies congénitales de l'enfant et de l'adulte

Hôpital cardiologique Haut Lévêque- Bordeaux

université de BORDEAUX · CHU Hôpitaux de Bordeaux · Inserm Institut national de la santé et de la recherche médicale · cnrs · Inria INVENTEURS DU MONDE NUMÉRIQUE

INTRODUCTION

- 1/1500 naissances (10% des MCC)
- Associée à environ 50% des autres CC
- Diagnostic fréquent à l'âge adulte
- Types anatomiques:
  - CIA ostium primum (15%) => CAV
  - CIA ostium secondum (80%)
  - CIA sinus venosus (5%) => RVPAp
  - CIA sinus coronaire (rare)

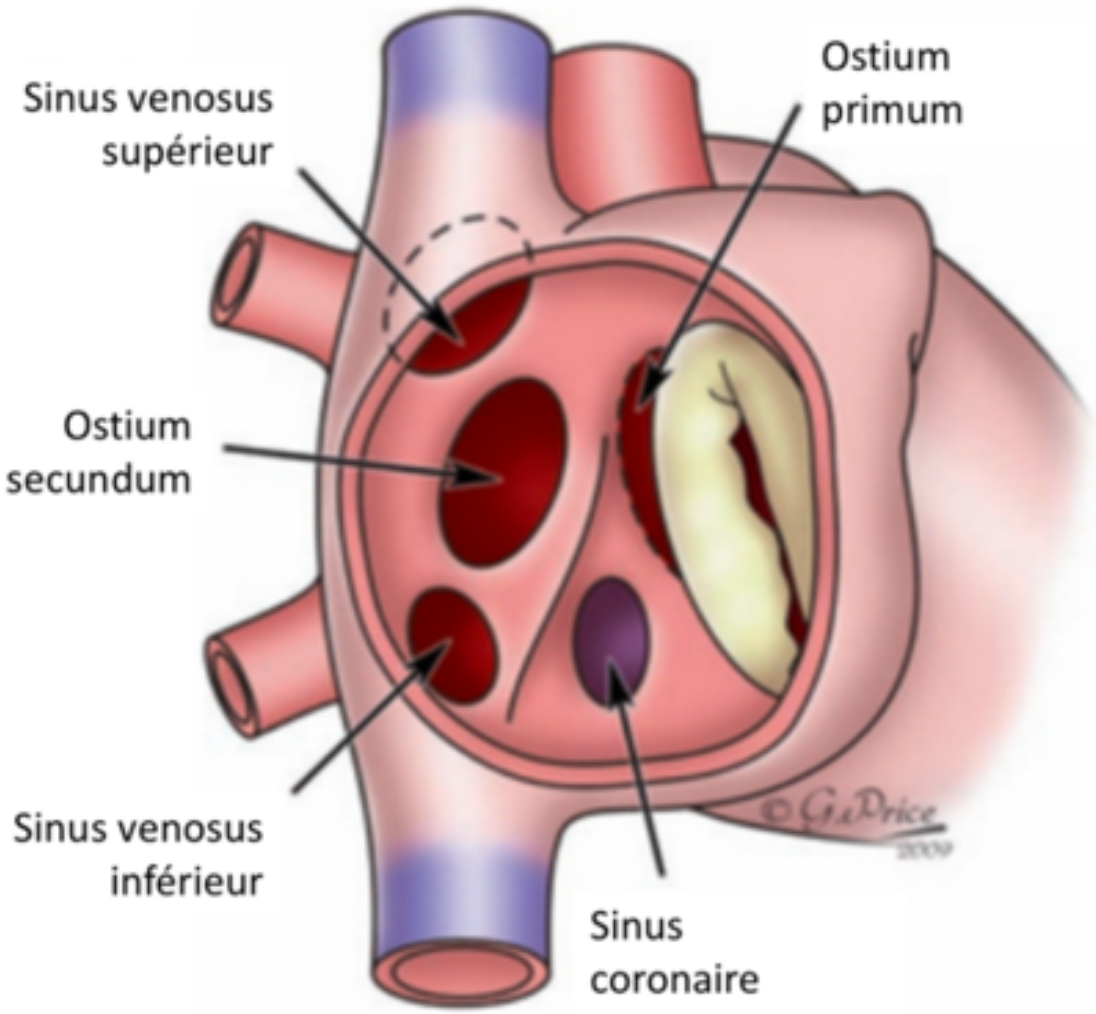

GENETIQUE

- CIA ostium primum : T21
- CIA ostium secundum:
  - Holt Oram (TBX5, malformation MS)
  - NKX2.5 (CIA + BAV)
  - Elis Van Creveld (EVC1/EVC2, polydactylie, côtes courtes)

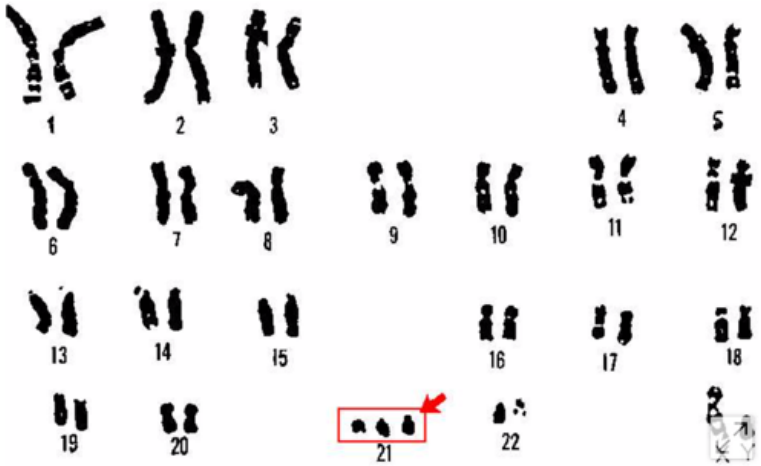

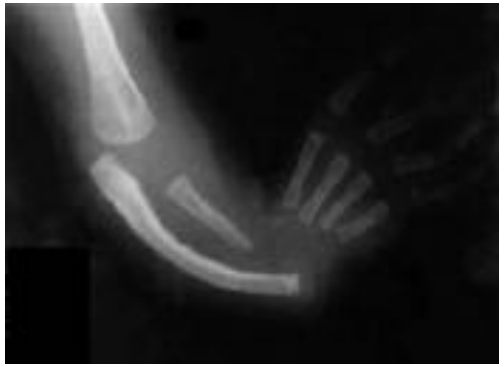

CANAL ATRIO-VENTRICULAIRE PARTIEL

ANOMALIE DES BOURGEONS ENDOCARDIQUES ET DE LA SEPTATION

- Non fermeture de l'ostium primum
  - ⇨ CIA
- Persistance d'une jonction auriculoventriculaire commune
  - ⇨ un seul anneau valvulaire
- Développement anormal du septum d'admission
  - ⇨ CIV

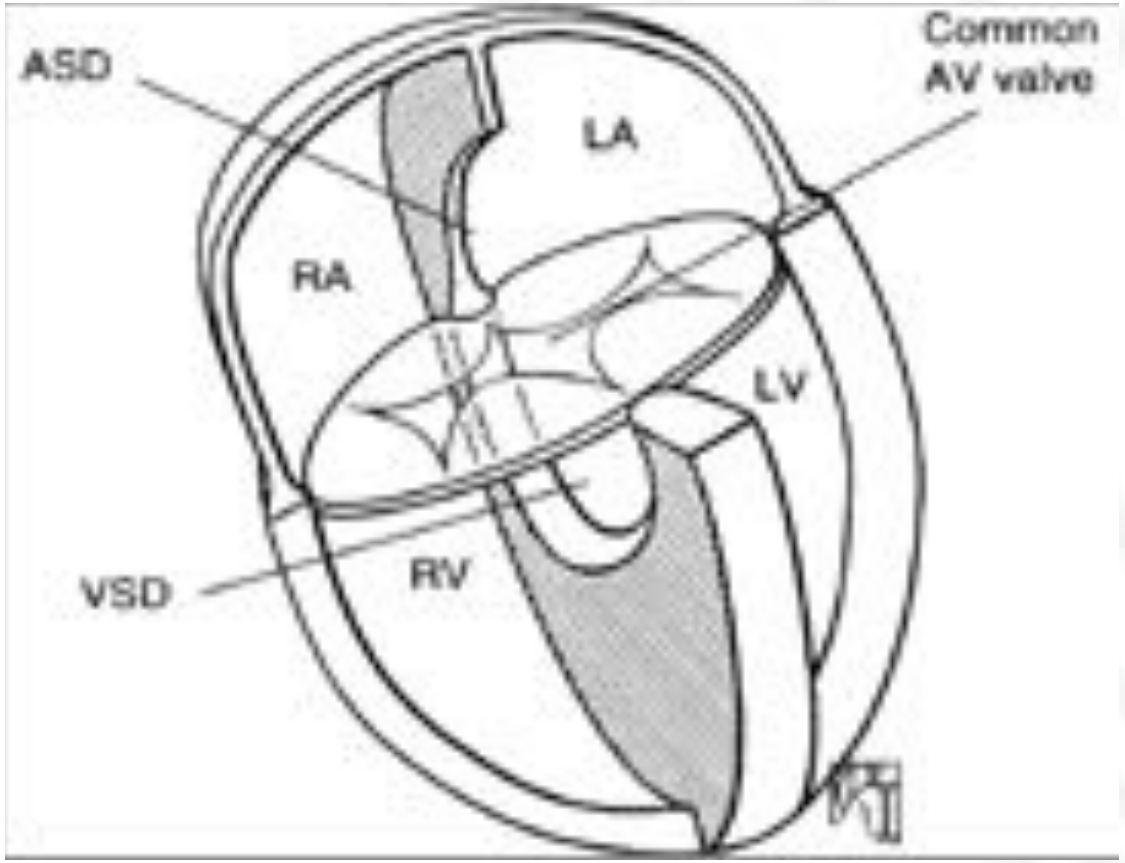

CANAL ATRIO-VENTRICULAIRE PARTIEL

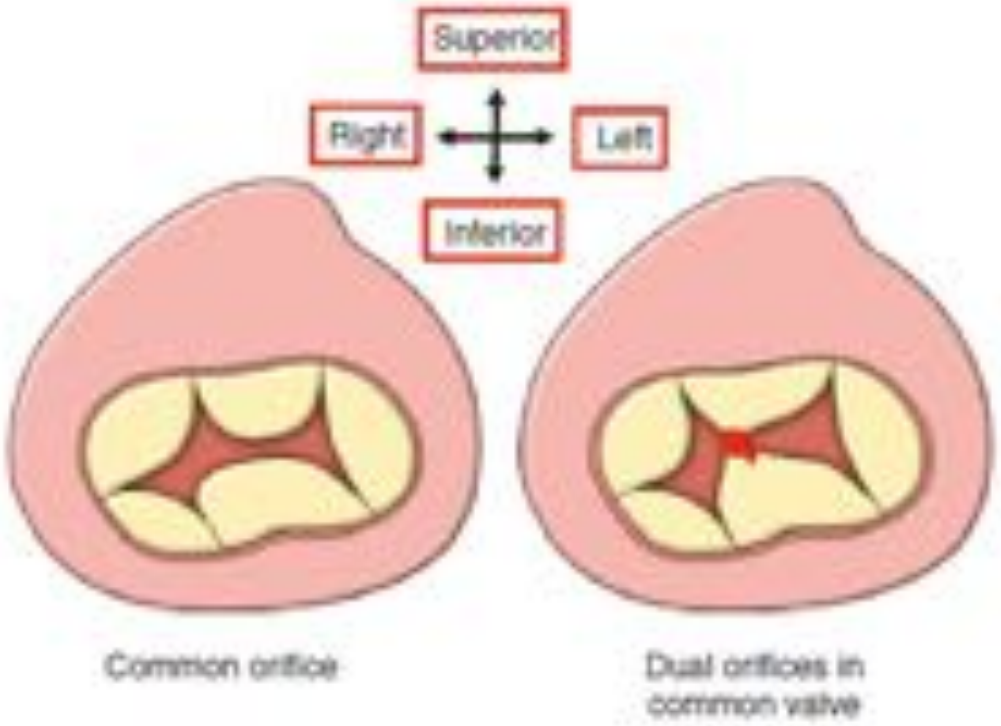

1 anneau auriculoventriculaire

1 orifice valvulaire (CIV)

2 orifices valvulaires (CIV fermée)

CAV complet

A

B

C

CAV intermédiaire (CIV restrictive)

CAV partiel

RVPAP

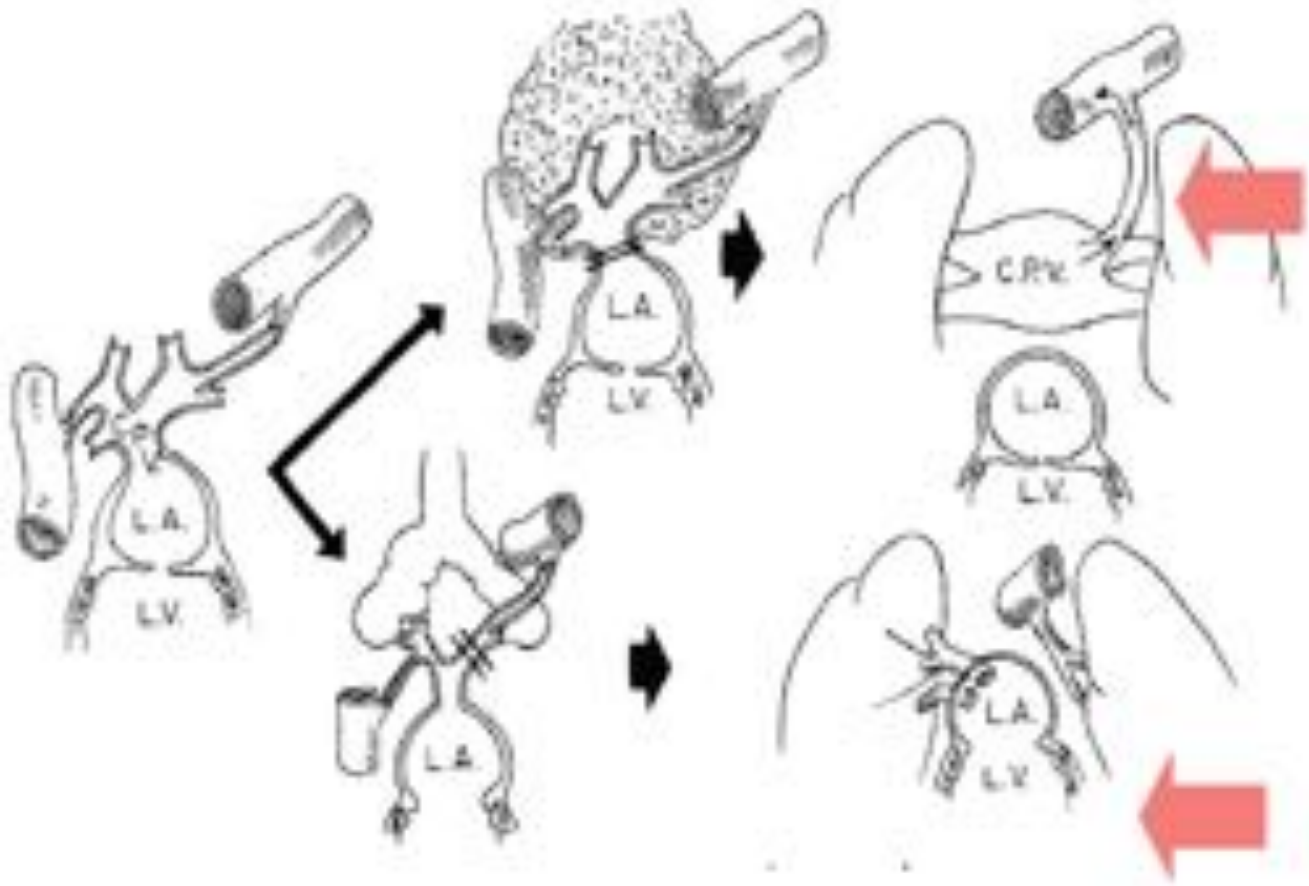

Atrésie de la veine pulmonaire commune : RVPA total avec persistance d ' une connexion (v. verticale)

Atrésie d' une branche de la VP commune : RVPA partiel

RVPAP

VP DROITES

VCS

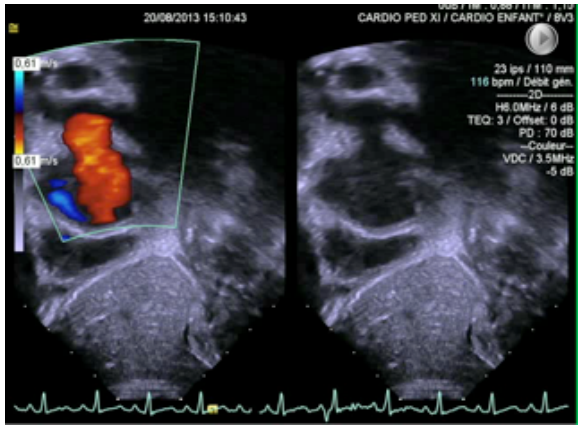

VCI

VP GAUCHES

TVI

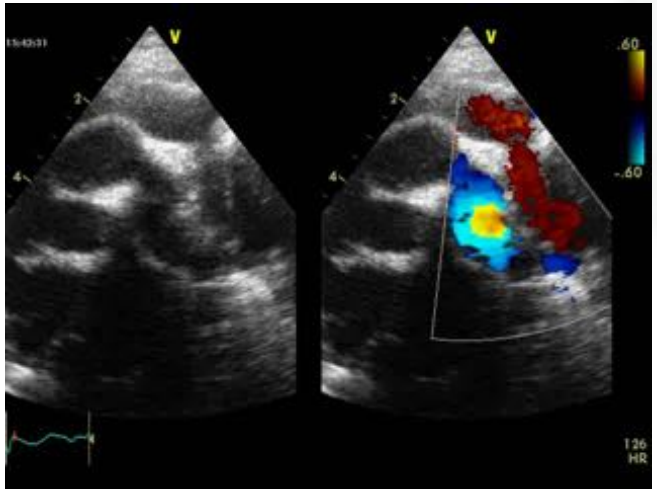

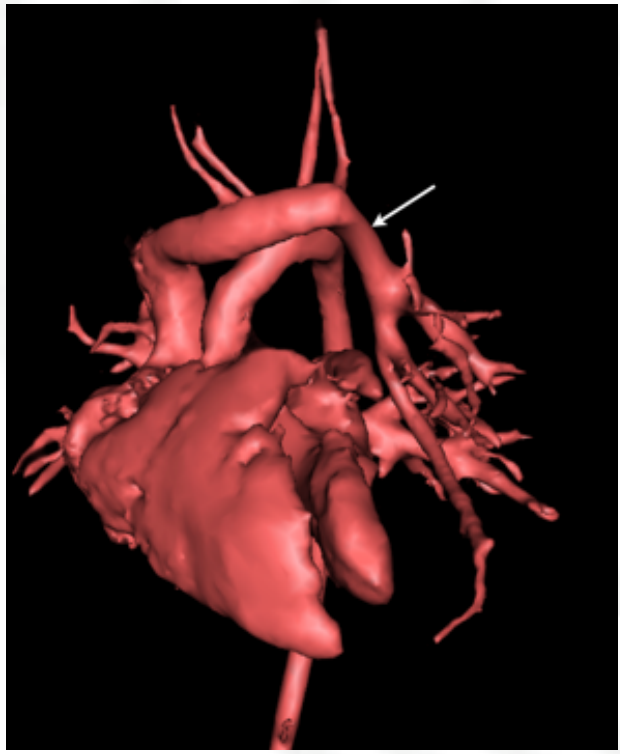

SYNDROME DE CIMETERRE

- RVPAP poumon D => VCI
- Hypoplasie pulmonaire droite
- Artère sequestrante poumon droit
- HTAP

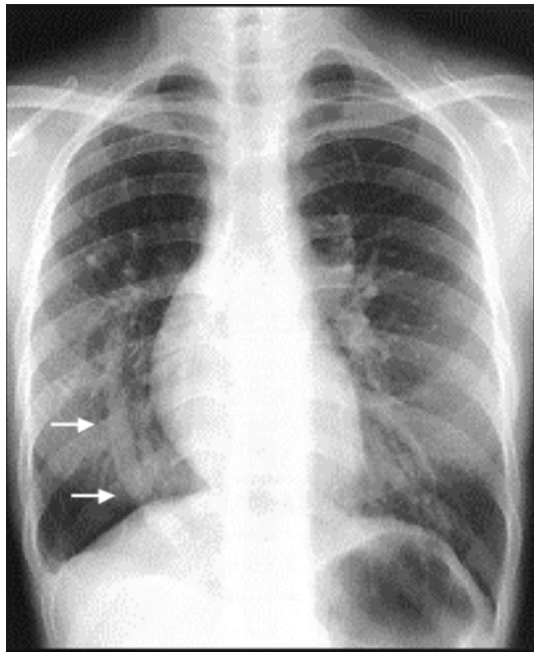

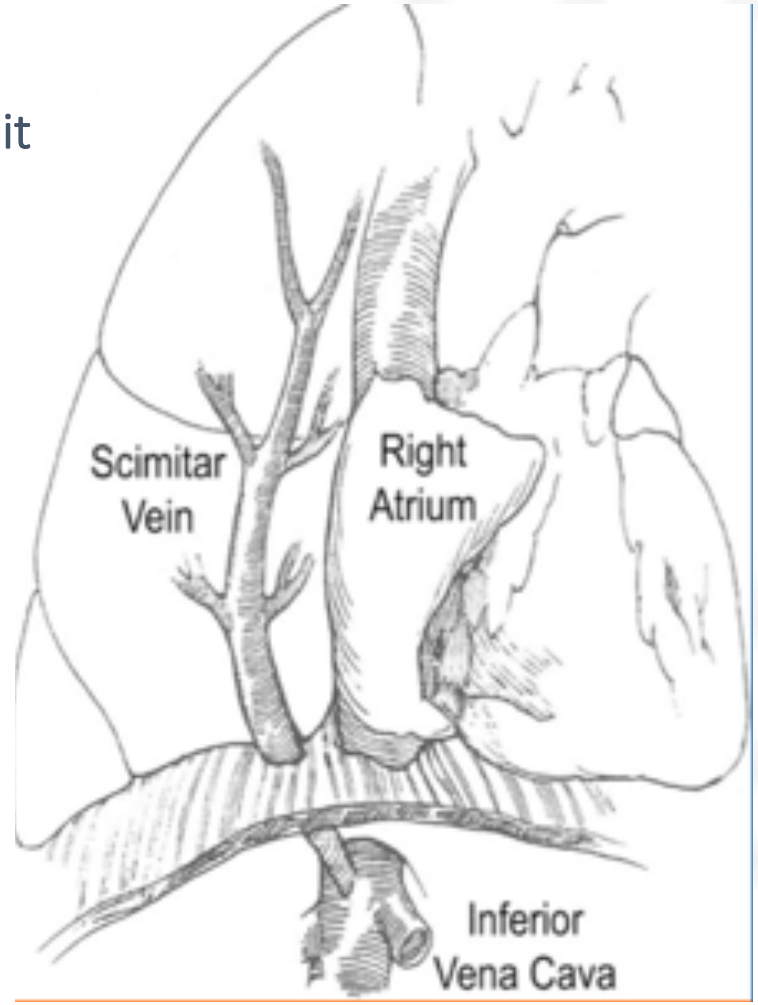

SYNDROME DE CIMETERRE

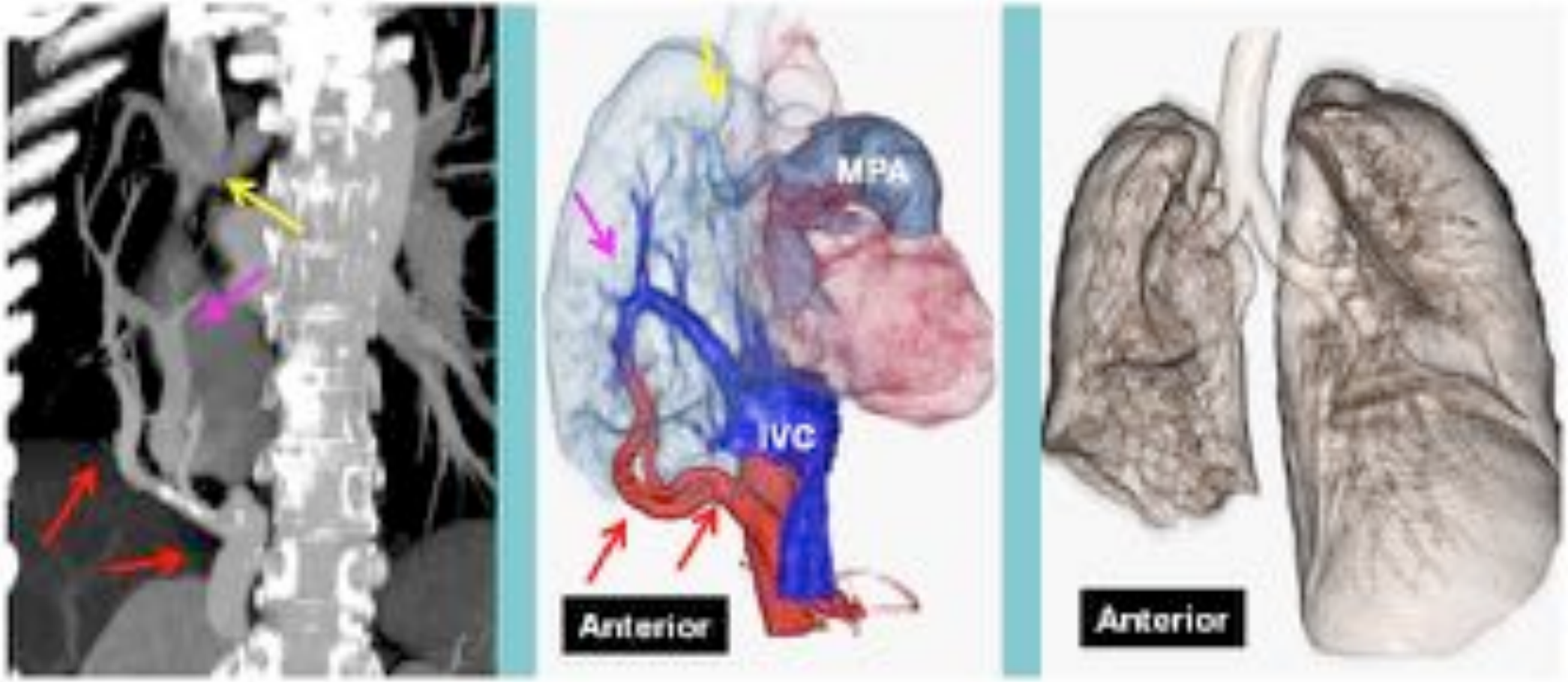

PHYSIOPATHOLOGIE

- Shunt dépendant des **compliances ventriculaires**
- Classiquement VD>VG => **Shunt G-D pré-tricuspide**
- **Surcharge volumique** cavités droites
- **Hyper débit** pulmonaire
- **Arythmies atriales**
- Syndrome **d'Eisenmenger**
- **Shunt D-G** d'emblée si SVP, anomalie tricuspide, HTAP

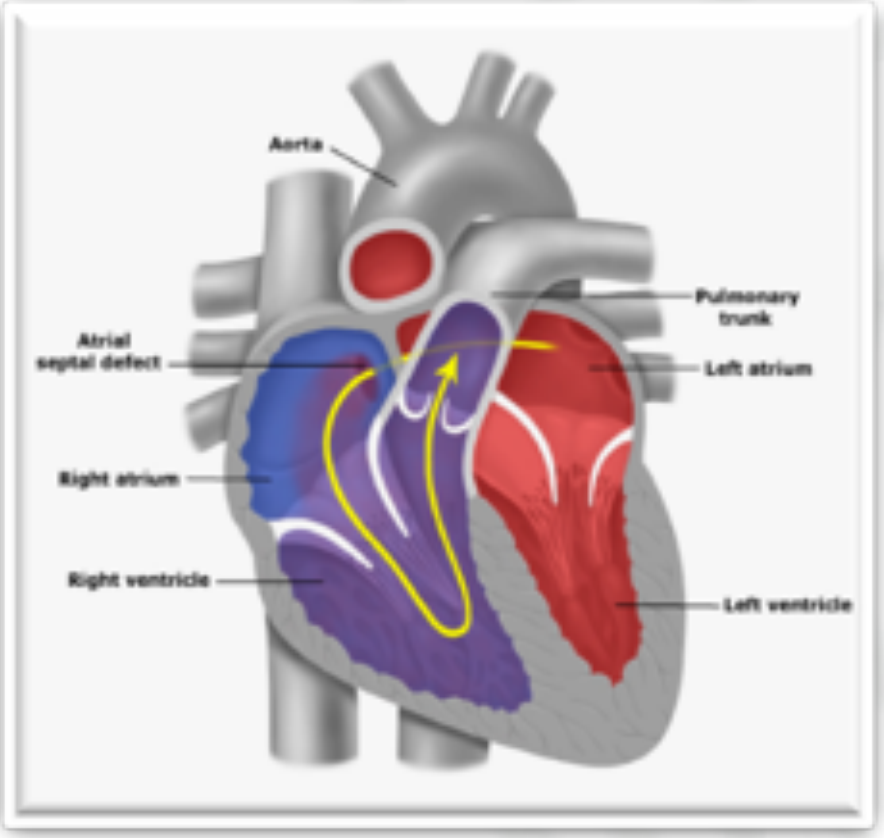

CLINIQUE

- Souvent **asymptomatique** (découverte fortuite adulte)
- **Hyperdébit pulmonaire** => Dyspnée, retard croissance, infections respiratoires
- **Arythmies** => Palpitations révélant une FA/Flutter/TA
- Embolie paradoxale
- Insuffisance cardiaque droite
- Cyanose

ECHOCARDIOGRAPHIE

- Diagnostic anatomique
- Retentissement:
  - Dilatation cavités droites
  - PAP
  - Qp/Qs
- Lésions associées (Valves AV, voie sous aortique, etc.)
- Possibilité de fermeture percutanée

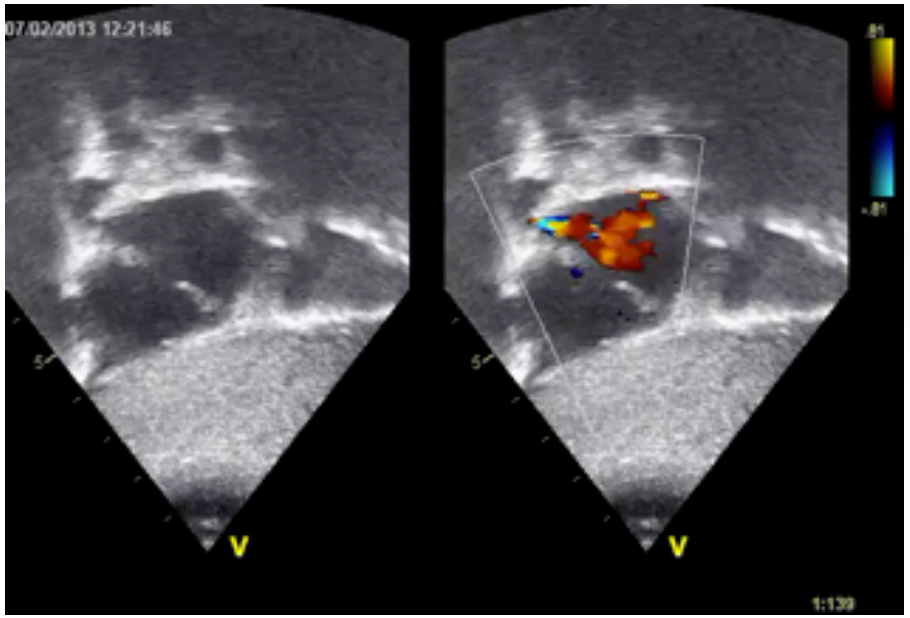

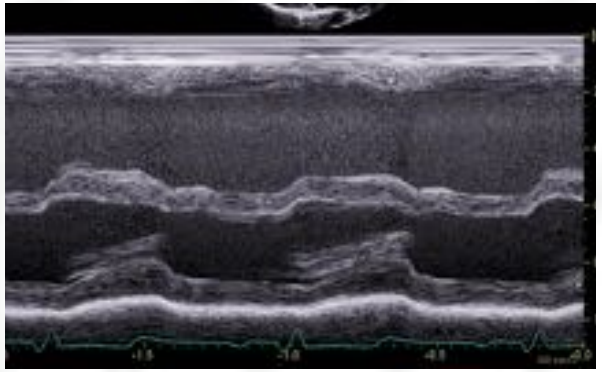

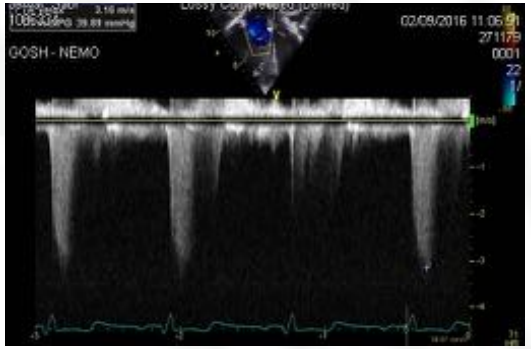

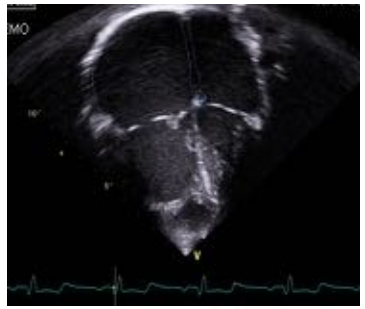

ECHOCARDIOGRAPHIE

CANAL ATRIO-VENTRICULAIRE PARTIEL

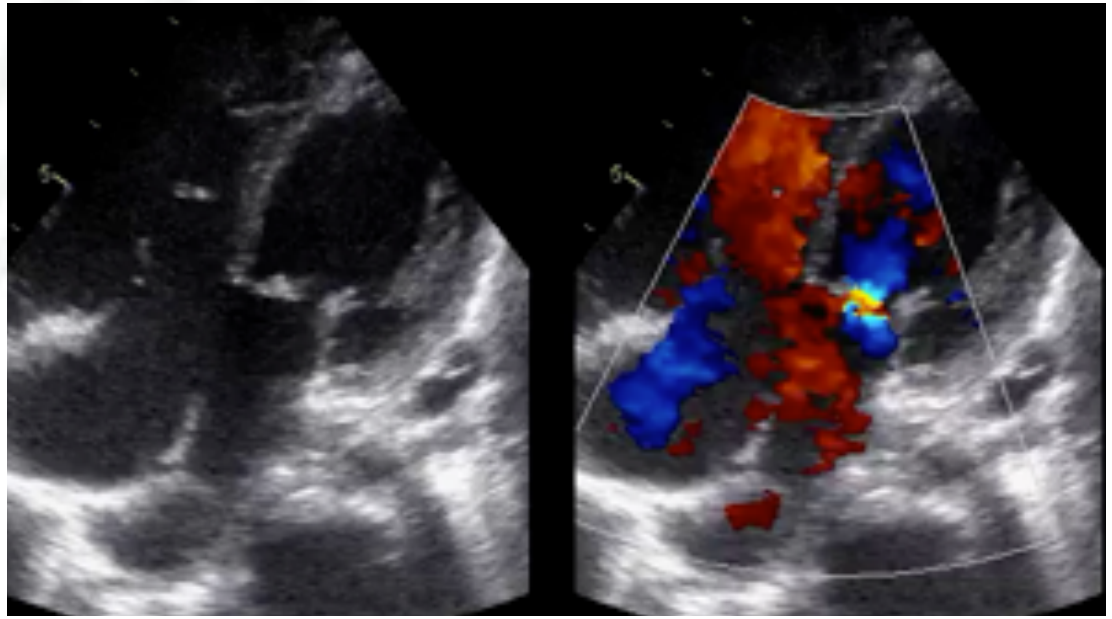

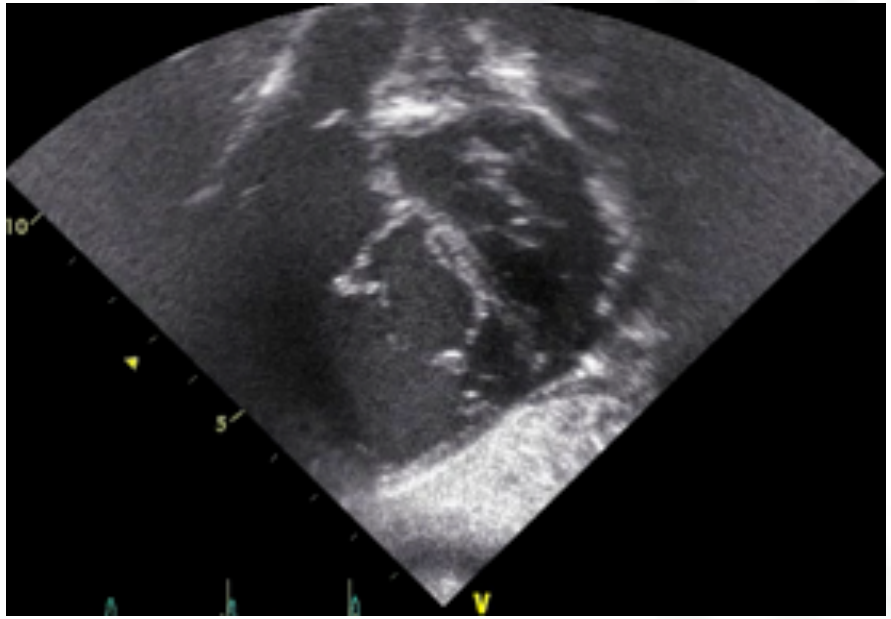

Un seul anneau valvulaire

CIA Ostium Primum

Fente VAV gauche

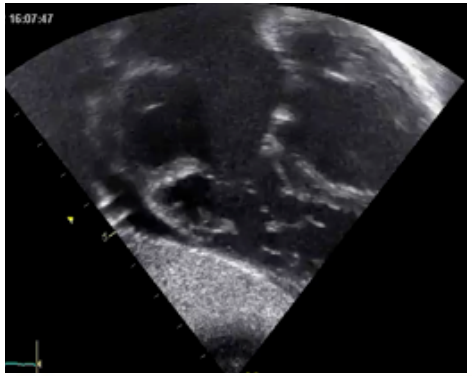

ECHOCARDIOGRAPHIE

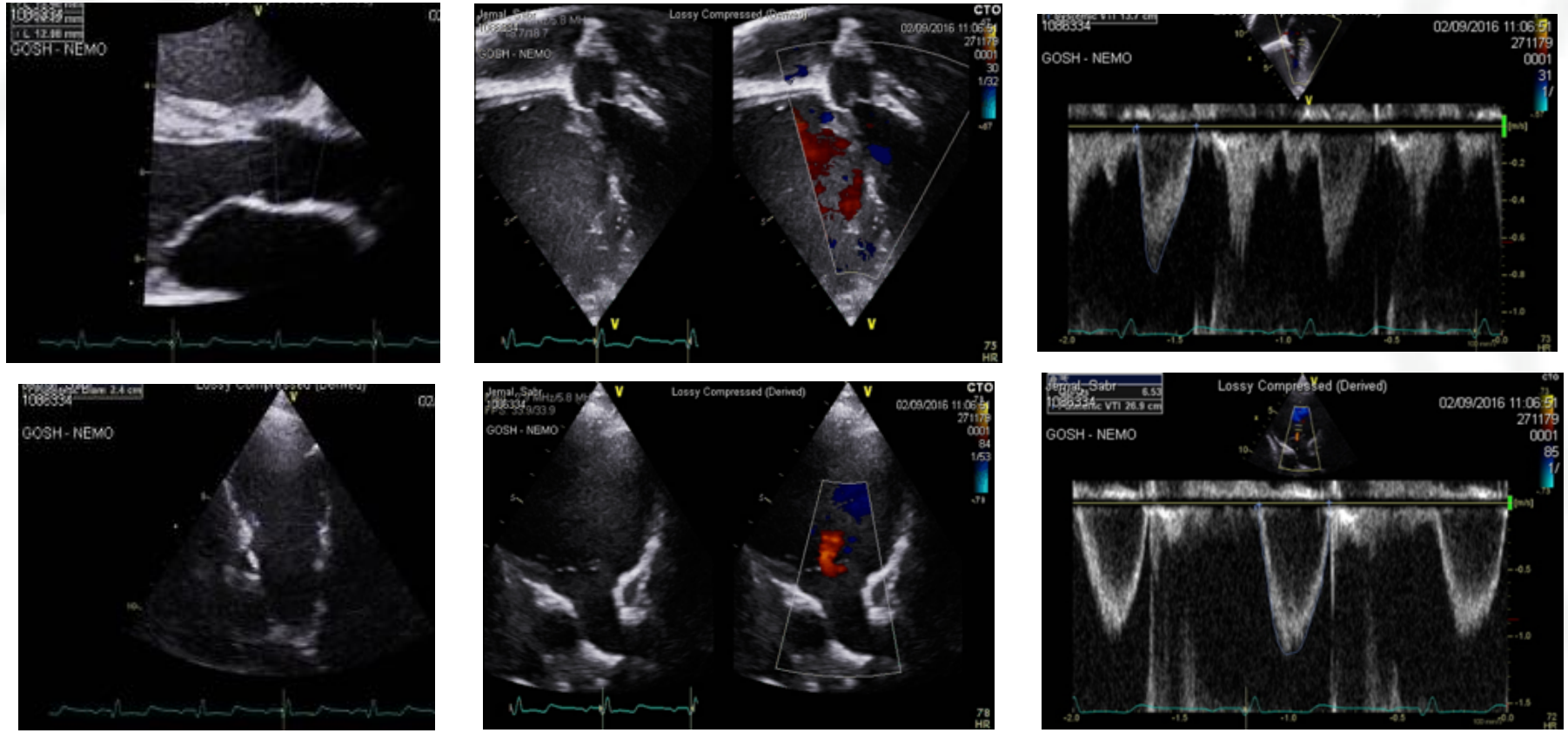

$$Qp/Qs = \frac{CSA\ (RVOT) \times VTI\ (RVOT)}{CSA\ (LVOT) \times VTI\ (LVOT)}$$

AUTRES EXAMENS COMPLEMENTAIRES

TDM/IRM

Anomalies du retour veineux pulmonaire

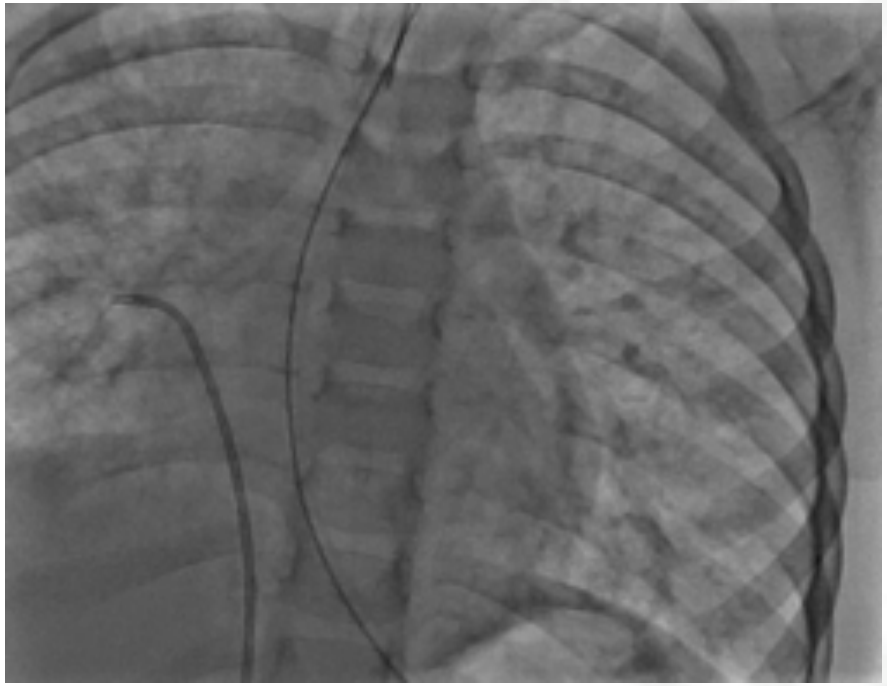

KT

Si HTAP en ETT

Mesure Pressions; Qp/Qs

Résistances pulmonaires+++

TRAITEMENT

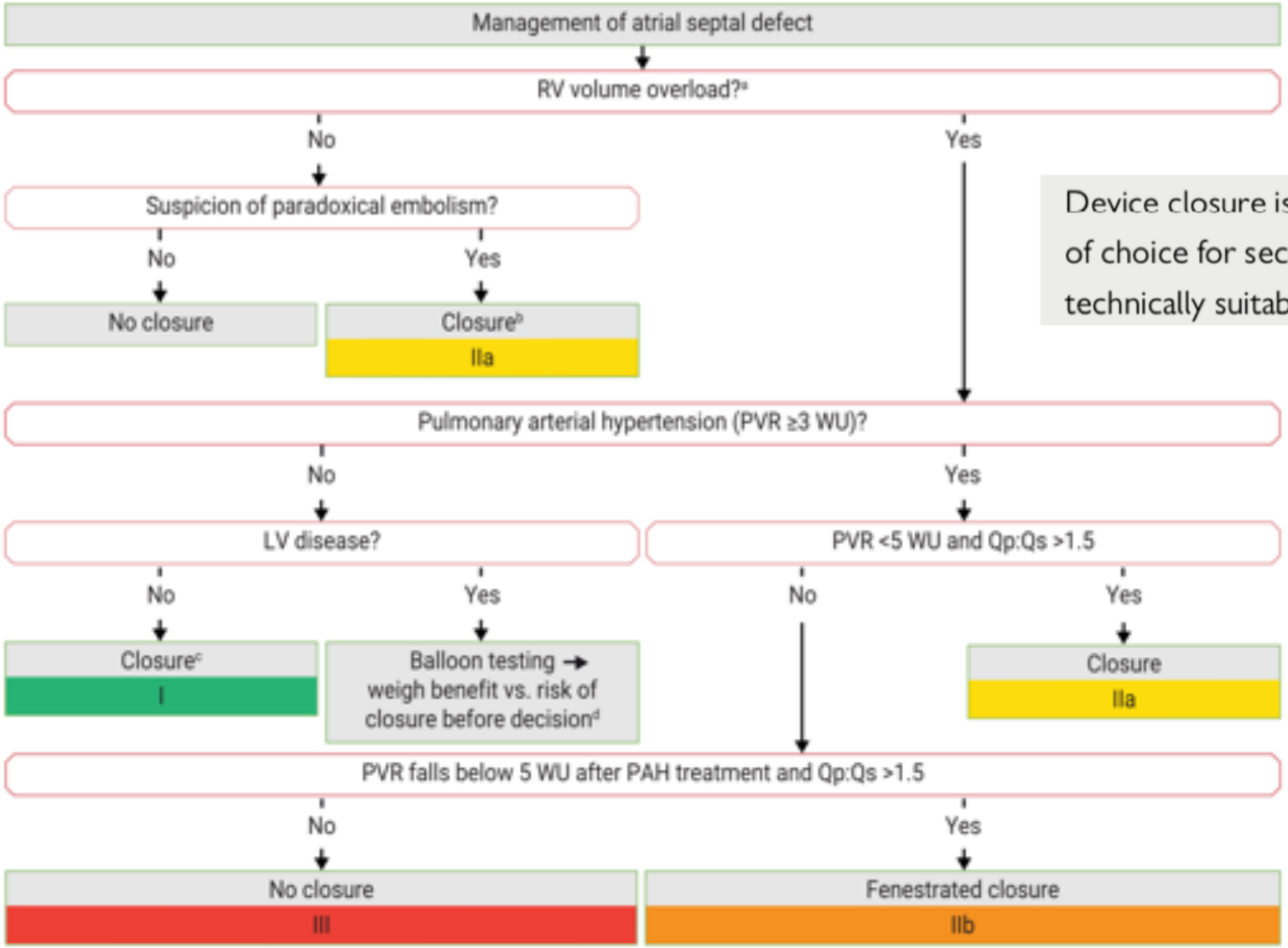

Device closure is recommended as the method of choice for secundum ASD closure when technically suitable.	I	C

Baumgartner et al. Eur Heart Jour 2020

TRAITEMENT

CANAL ATRIO-VENTRICULAIRE PARTIEL

Partial AVSD (primum ASD)		
Surgical closure is recommended in patients with significant RV volume overload and should only be performed by a congenital cardiac surgeon.	I	C
For further details see recommendations for intervention in ASD (*section 4.1*).		
AV valve regurgitation		
Valve surgery, preferably AV valve repair, is recommended in symptomatic patients with moderate to severe AV valve regurgitation and should be performed by a congenital cardiac surgeon.	I	C
In asymptomatic patients with severe left-sided AV valve regurgitation, valve surgery is recommended when LVESD ≥45 mm[d] and/or LVEF ≤60% provided other causes of LV dysfunction are excluded.	I	C

RVPAP

4.1.5 Specific aspects of isolated anomalous pulmonary venous connections

Indications for surgery follow the principals of recommendation for ASD closure, but technical suitability for repair and operative risk must be weighed against the potential benefit of intervention. It is unusual for a single anomalous pulmonary venous connection of only one pulmonary lobe to result in a sufficient volume load to justify surgical repair.

Baumgartner et al. Eur Heart Jour 2020

FERMETURE PERCUTANÉE – LES PIONNIERS

Secundum Atrial Septal Defect

Nonoperative Closure During Cardiac Catheterization

Terry D. King, MD; Sandra L. Thompson, RN; Charles Steiner, MD; Noel L. Mills, MD

• A 17-year-old girl had clinical and cardiac catheterization findings compatible with a secundum atrial septal defect. During cardiac catheterization, the atrial septal defect was sized and closed using a transvenous umbrella technique.

(*JAMA* 235:2506-2509, 1976)



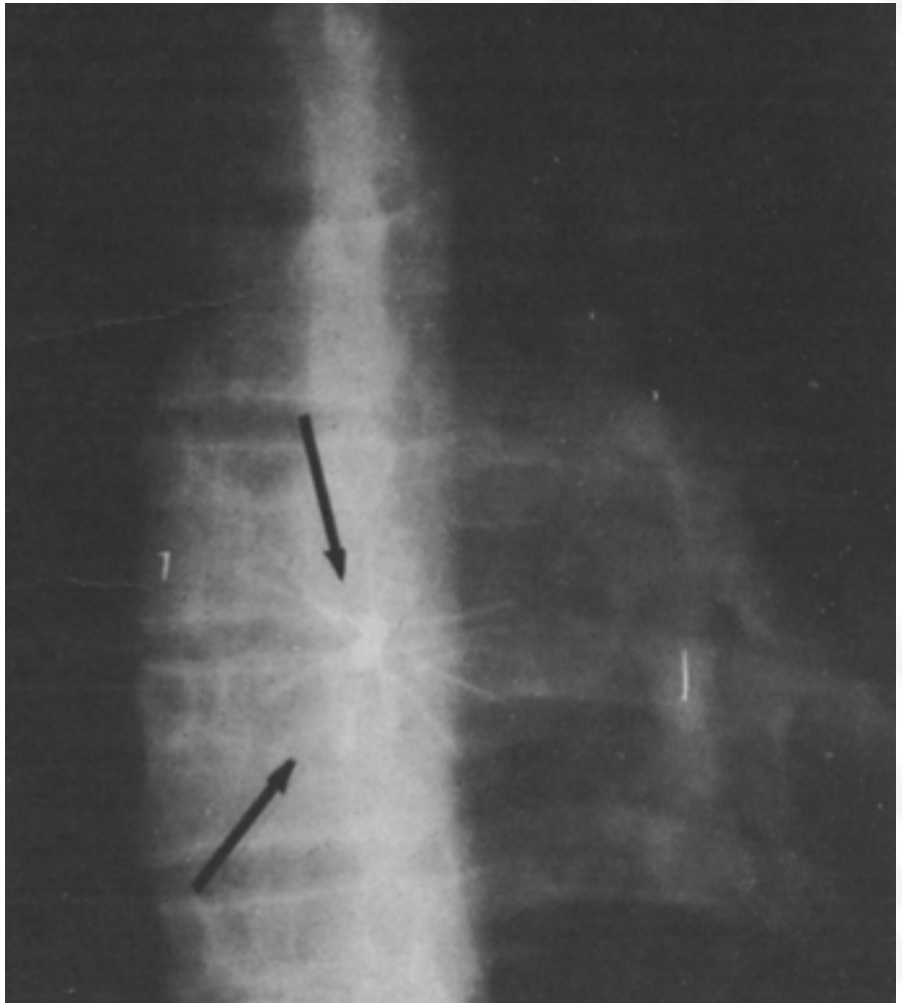

King et al. JAMA 1976

FERMETURE PERCUTANÉE – LA RUPTURE





AMPLATZER SEPTAL OCCLUDER





Nitinol (55% Ni + 45 % Ti)
+
Polyéthylène téréphtalate

Mémoire de forme
Recapturable
Biocompatibilité
Profil

EVALUTATION ETT

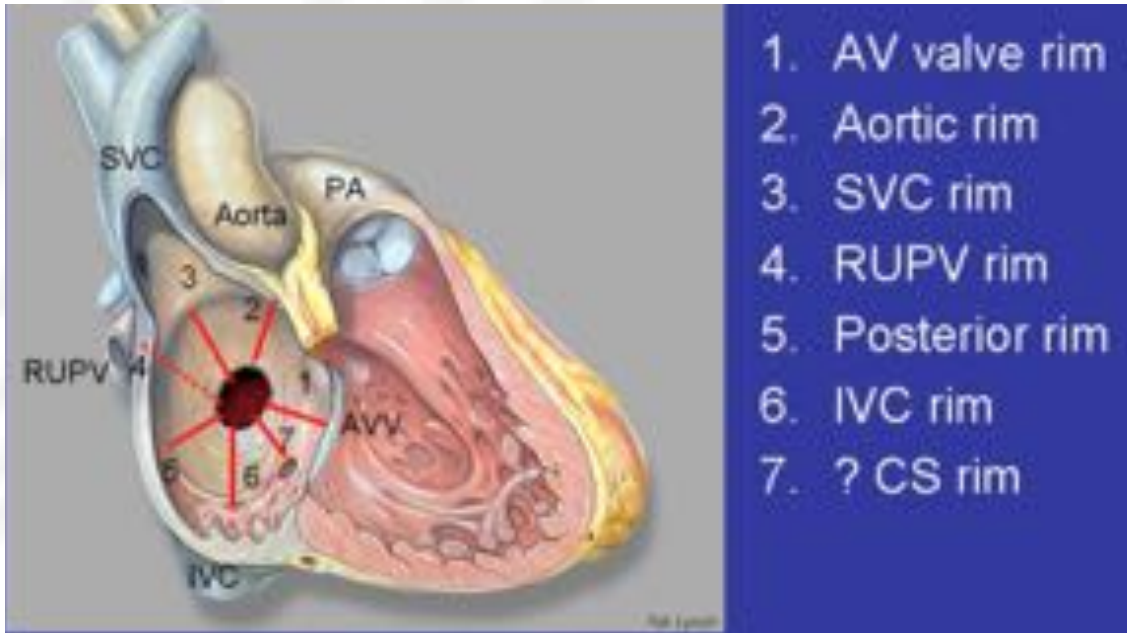

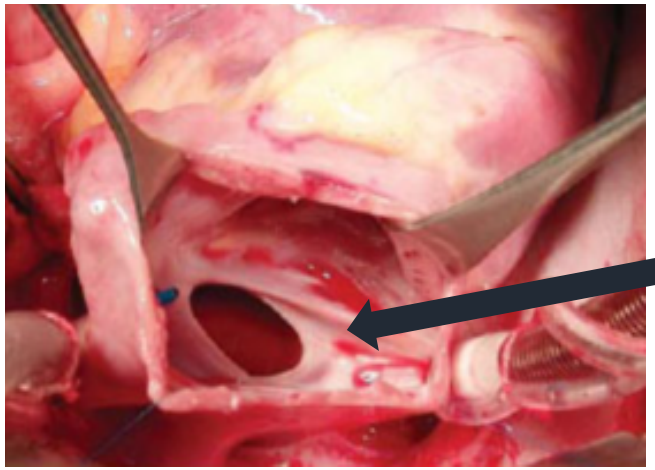

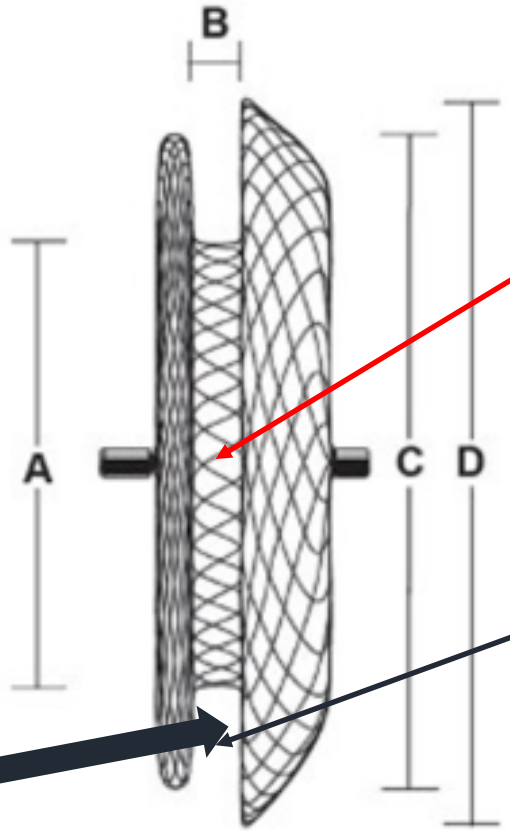

Size (central waist)	4-40 mm (every 1 mm up to 20 mm, > 20 mm, every 2 mm)
Central waist length	3-4 mm
Difference between disc and central waist	8/12 mm (ASO 4-10), 10/14 mm (ASO > 11), 10/16 mm (ASO > 34)
Release sheath size	6-12 Fr

BERGES > 5-mm

EVALUTATION ETT

Vue sous costale

BERGES CAVES

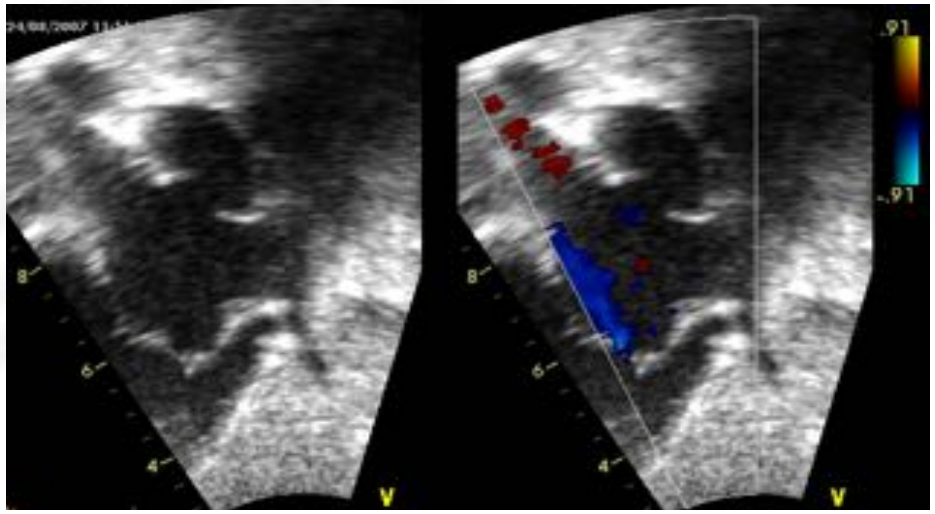

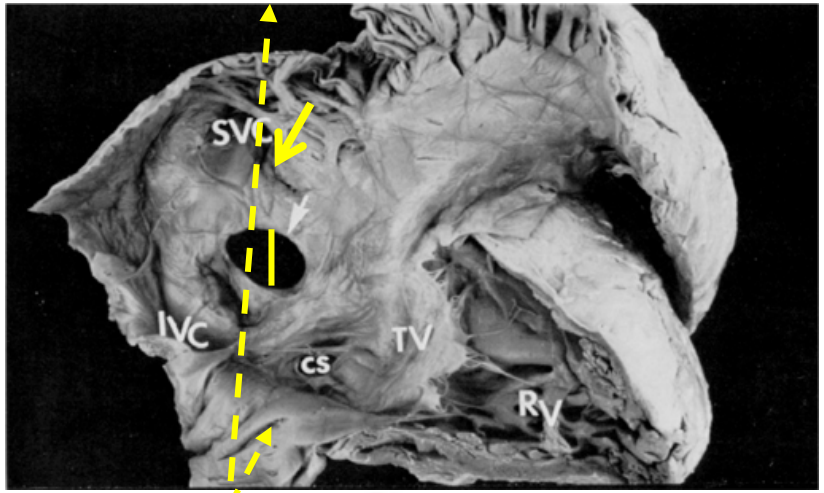

AC4 -> A5C

BERGES POST et ANT

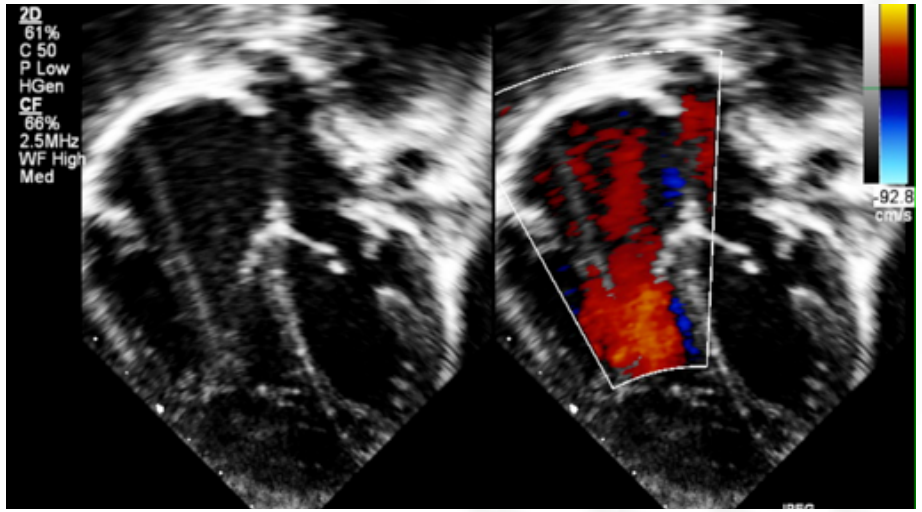

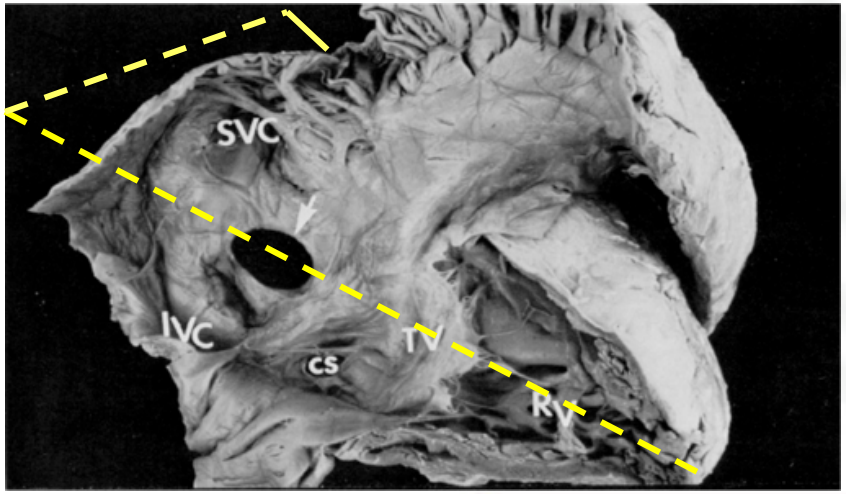

Courtesy X. Iriart

EVALUTATION ETT

PSPA

BERGES RETRO-Ao

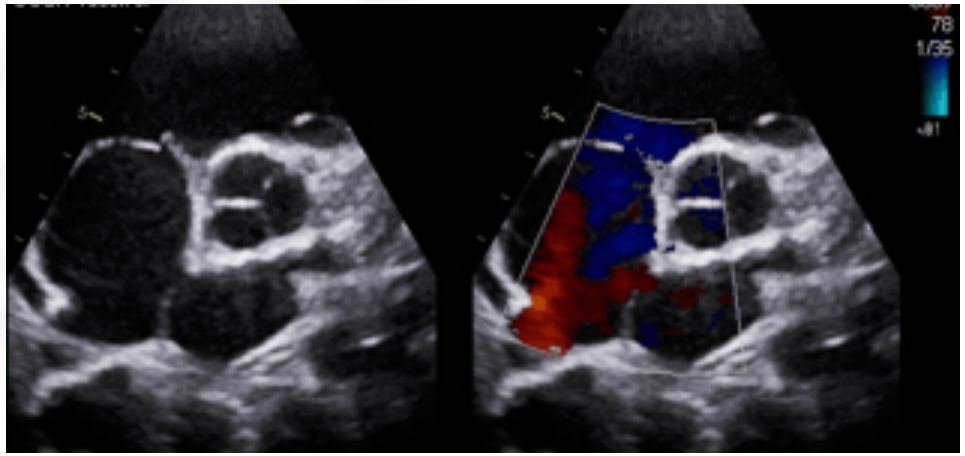

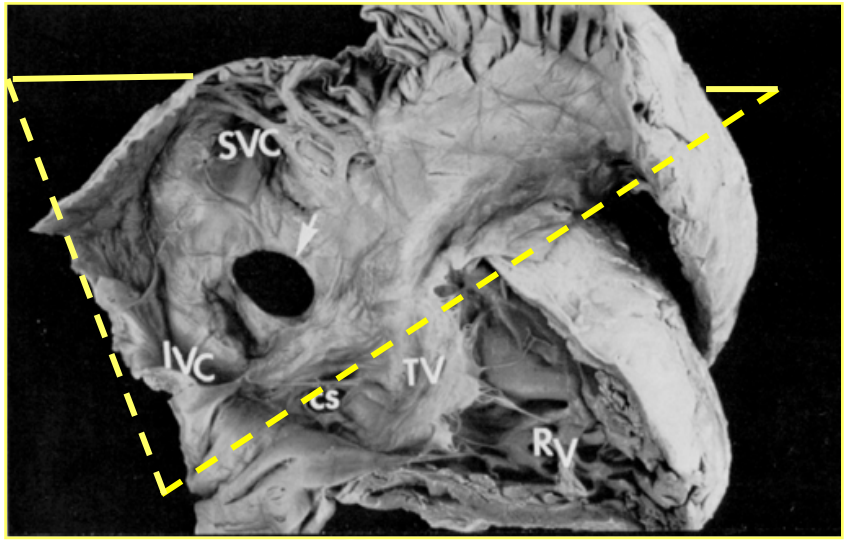

TAILLE ET MORPHOLOGIE DU SHUNT

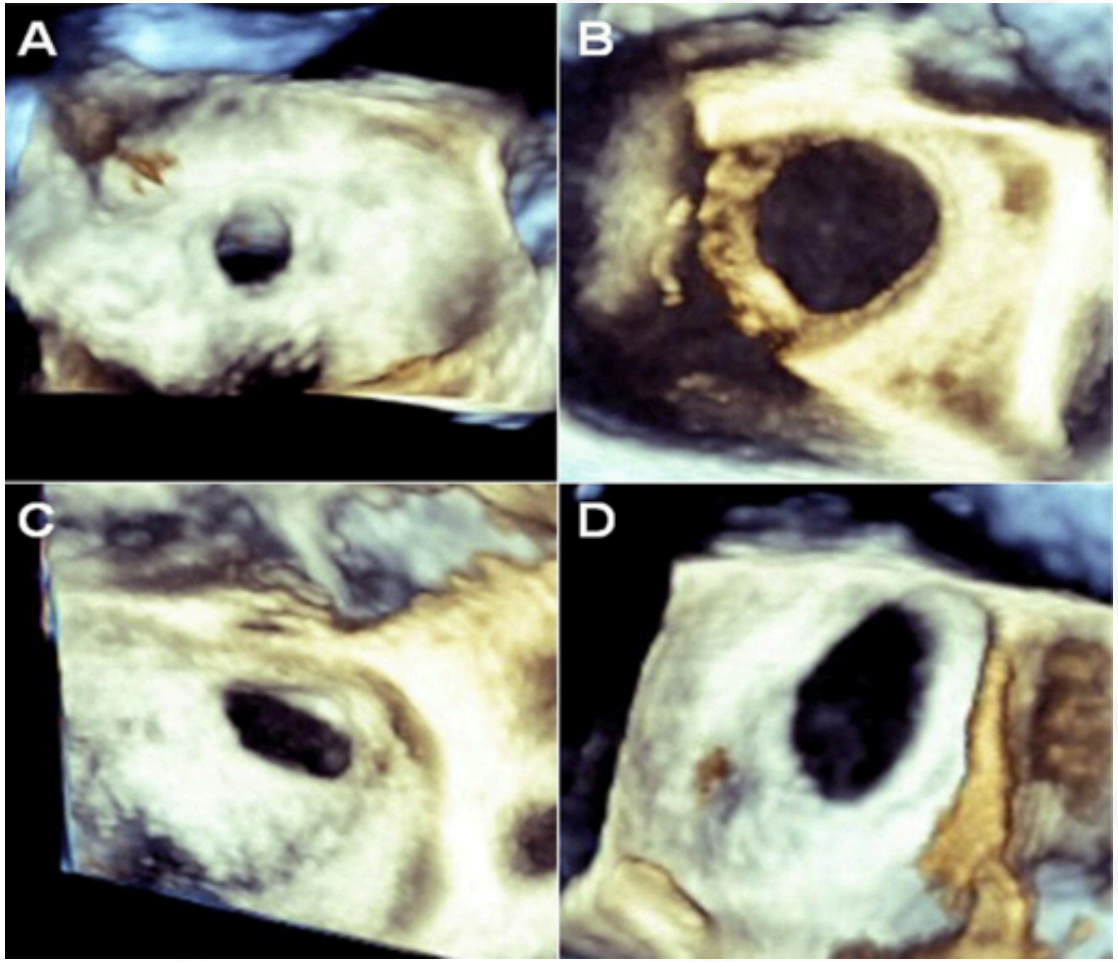

FERMETURE PERCUTANÉE - PROCÉDURE

- Sous AG/AL
- Contrôle ETO (ETT, ICE)
- Accès veine fémorale
- Traitement anti-thrombotique (HNF, AAP)
- Trajet: VFD-OD-CIA-OG-VP => guide VP
- Calibration au ballon et/ou échographique
- Taille prothèse = taille défect + 2-4mm
- Déploiement
- Test stabilité prothèse

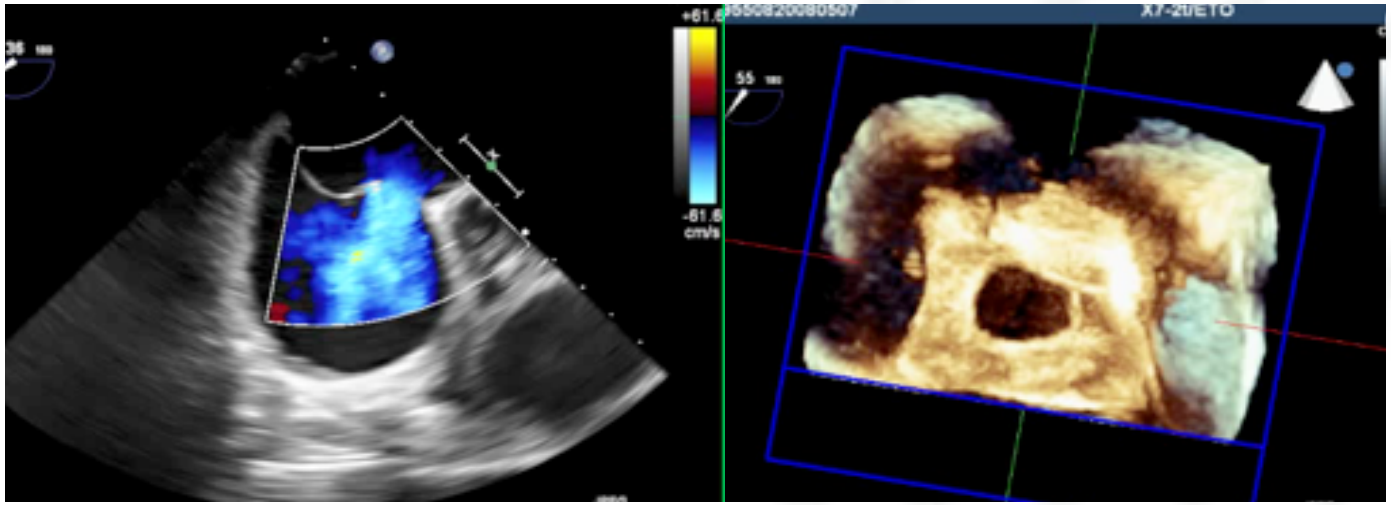

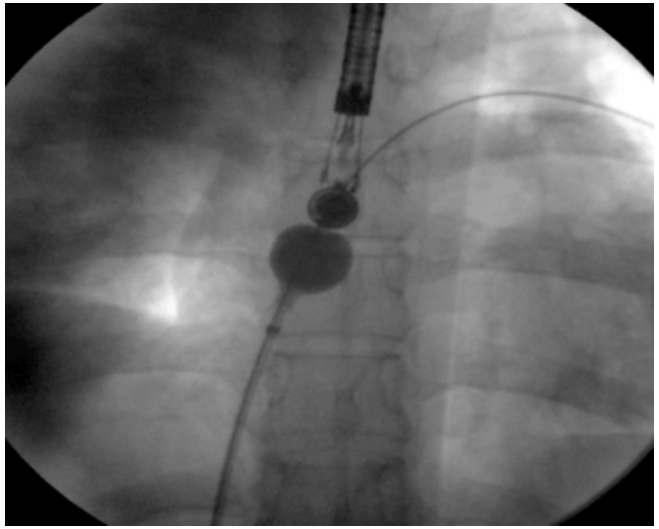

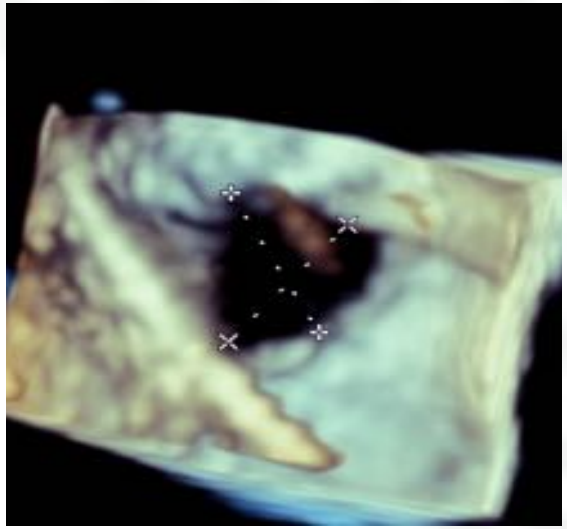

FERMETURE PERCUTANÉE - PROCÉDURE

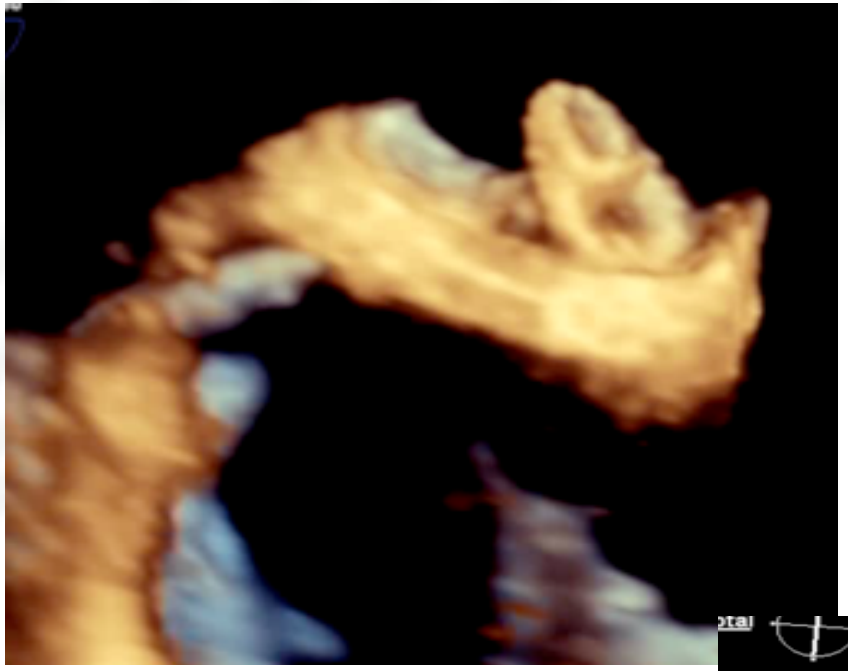

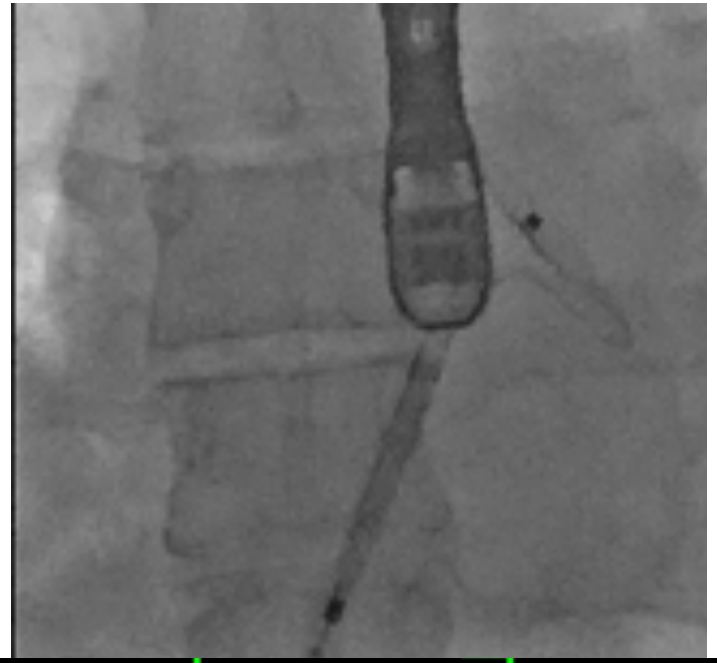

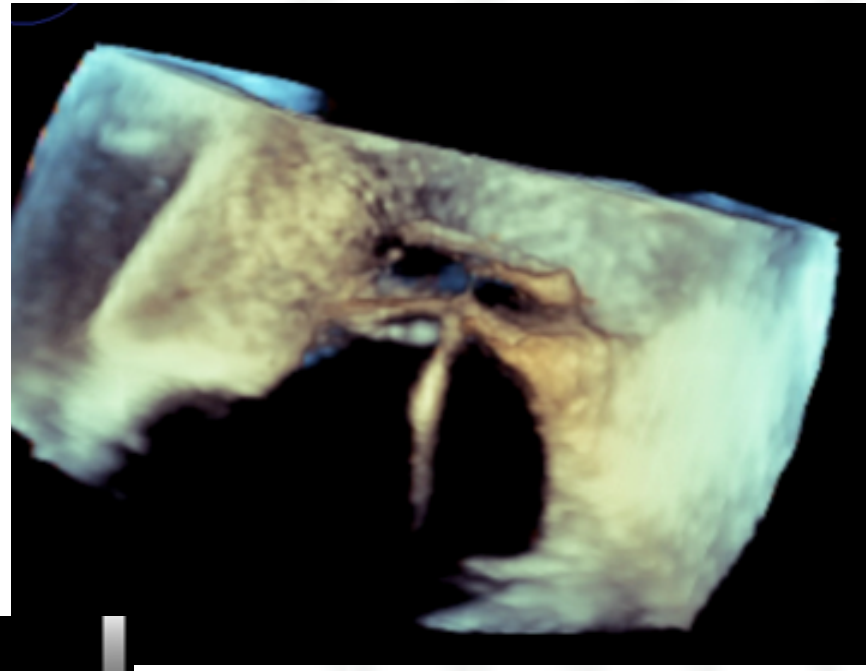

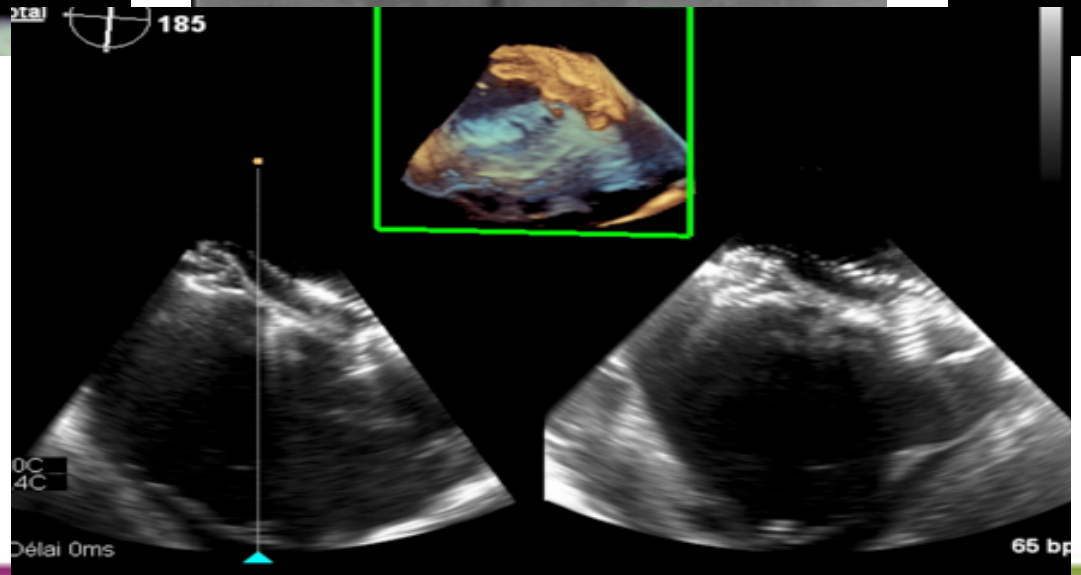

FERMETURE PERCUTANÉE - RÉSULTATS

ÉTUDE RÉTROSPECTIVE MULTICENTRIQUE NATIONALE , 9 CENTRES, (1998-2016)

- Inclusion: enfants < 18 ans, tentative de fermeture de CIA par ASO
- Caractéristiques démographiques
- Evaluation Anatomique du shunt (taille, berges)
- Procédure (guidance, succès, complications)
- Suivi à long terme (Statut fonctionnel, Complications)

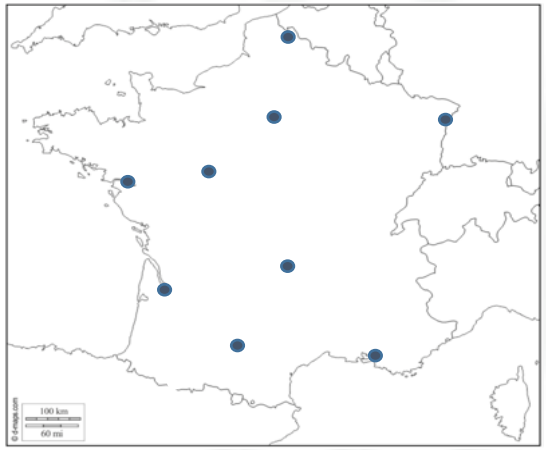

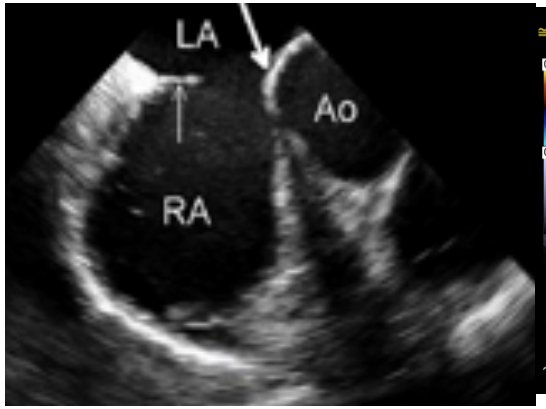

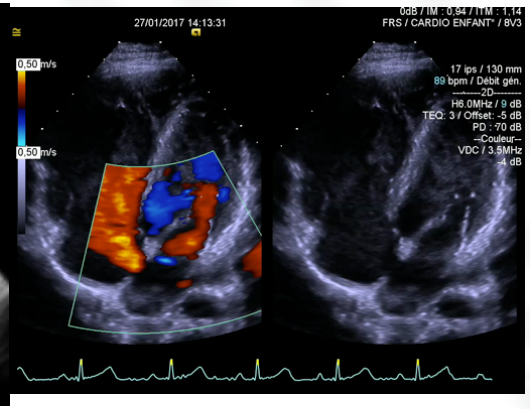

FERMETURE PERCUTANÉE - RÉSULTATS

RÉSULTATS

- 1326 patients (exclusion de 69 patients)
- Age: 9 ans (0.7-18);
- Poids: 28 kg (3.6 – 92)
- ≤ 15 kg: 95 (7%)
- Lésions cardiaques associées: 137 (10.3%)
- Pathologies extracardiaques: 62 (4.6%)

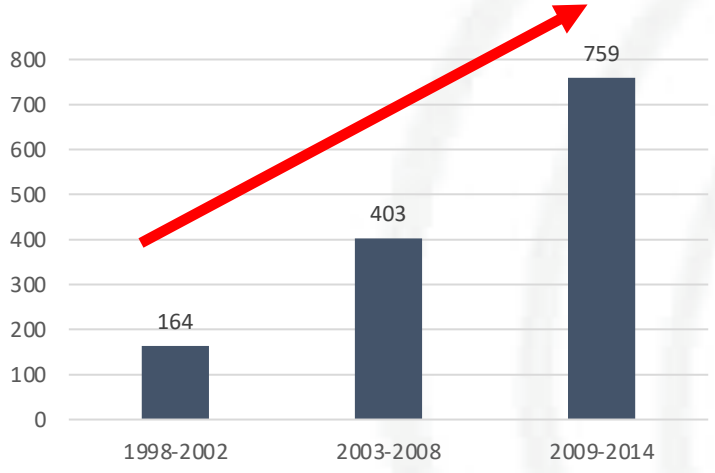

ASO implantés entre 1998 et 2016

TABLE 3 ASD Characteristics and Procedural Data

Preprocedural ASD assessment	
ASD echographic diameter, mm	15 (3-41)
Indexed diameter (ASD/body surface area, mm/m²)	14.8 (3.5-48.6)
Large ASD (≥20 mm/m²)	254 (19.1)
Deficient rims (n = 1,133)	
Aortic	321 (28.3)

Jalal et al. J Am Coll Cardiol Intv - 2018

FERMETURE PERCUTANÉE - RÉSULTATS

RÉSULTATS

Succès 95.3% (95%CI: 93.9%–96.3%)

Successful implantation	1,264 (95.1)
ASO device size, mm	18 (4-40; IQR: 15-24)
Reason for occlusion failure	62 (4.7)
Defect was considered too large to be closed with the ASO	47
ASO embolization	7
Unstable device	5
Atrioventricular valve damage	2
Atrioventricular block	1

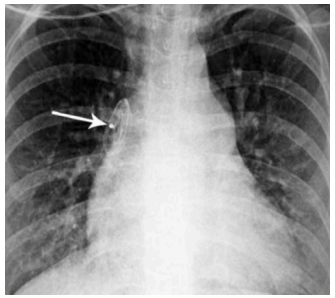

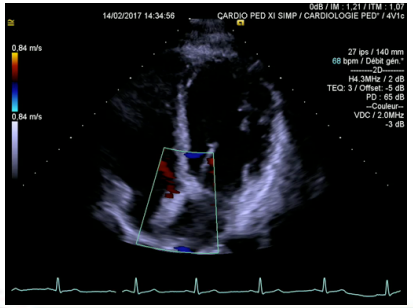

Complications	24pts (1.8 %)
Embolisation dispositif	10 (0.8%)
Régurgitation mitrale	1 (0.07 %)
Régurgitation aortique	0 (0)
Hémolyse	1 (0.07 %)
Erosion	0 (0)
Épanchement péricardique	6 (0.5%)
OAP	0 (0)
Embolie gazeuse	1 (0.07 %)
AVC	0 (0)
Bloc auriculo-ventriculaire	5 (0.4%)
Arythmies supra-ventriculaires	0 (0)
Arythmies ventriculaires	0 (0)
Endocardite Infectieuse	0 (0)
Hypertension pulmonaire	0 (0)

FERMETURE PERCUTANÉE - RÉSULTATS

CIA OS de 20-mm
FERMETURE par ASO 24mm

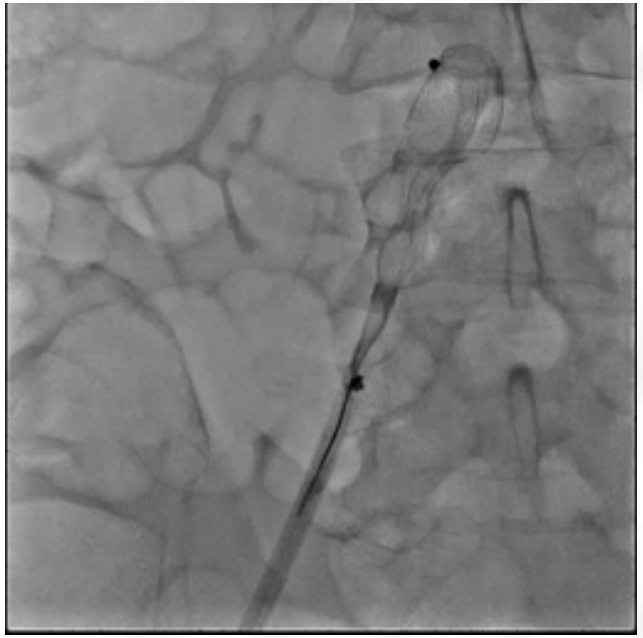

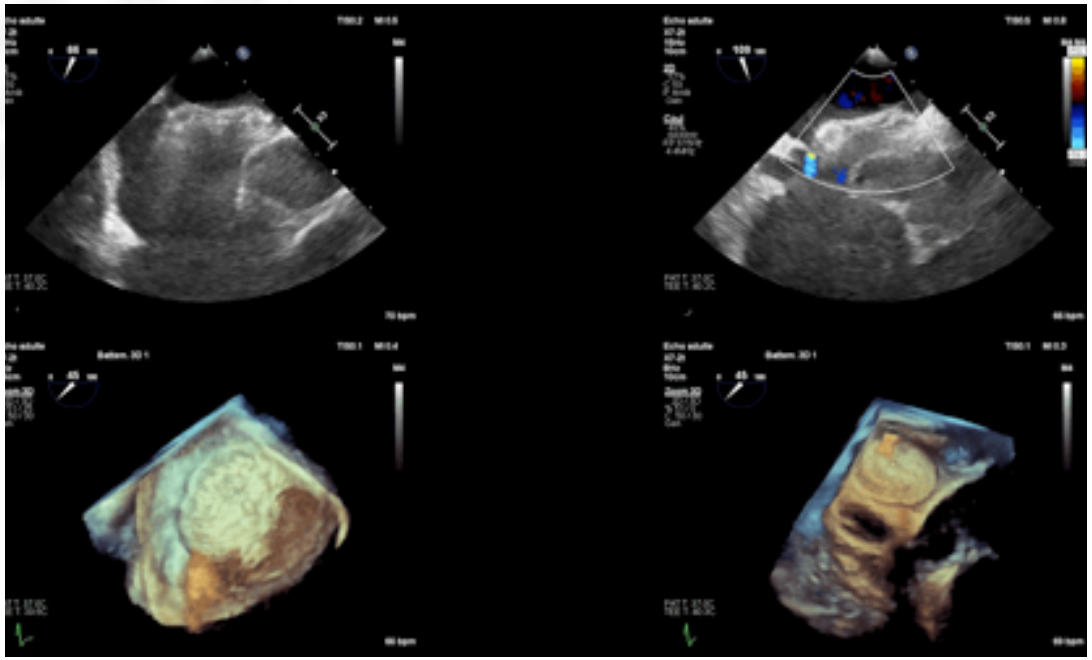

EMBOLISATION AIGÜE (ETT À H2)
PROTHÈSE DANS L'AORTE
RECAPTURÉE VIA ABORD ARTÉRIEL

FERMETURE PERCUTANÉE - RÉSULTATS

RÉSULTATS

Patients n = 1158 (91.6%) Suivi Médian : 3.5 ans (0.5 – 18; IQR: 1 – 7; 13% > 10 ans)	
Vivants (n, %)	1158 (100)
Asymptomatique (n, %)	1118 (96)
Érosion cardiaque	0 (0)
Arythmies	8 (0.69)
AVC	2 (0.17)
Bloc atrio-ventriculaire	0 (0)
Insuffisance cardiaque	0 (0)
Endocardite infectieuse	0 (0)
Hypertension pulmonaire	2 (0.17)

COMPLICATIONS À LONG TERME

(n=12; 1.04%; 95% CI: 0.5% - 1.6%)

GROSSESSE

- 69 femmes (8.5%) => 78 grossesses
- Délai Médian 10 ans (2 – 15)
- Pas de complications péri-partum

COMPLICATIONS AU LONG COURS

Review

Long-term Complications After Transcatheter Atrial Septal Defect Closure: A Review of the Medical Literature

Zakaria Jalal, MD,[a,b,c] Sebastien Hascoet, MD,[a,d] Alban-Elouen Baruteau, MD, PhD,[a,e] Xavier Iriart, MD,[b] Bernard Kreitmann, MD, PhD,[b] Younes Boudjemline, MD, PhD,[a,f,g] and Jean-Benoit Thambo, MD, PhD[a,b,c]

ÉROSION CARDIAQUE

VALVULOPATHIES

TROUBLES CONDUCTIFS

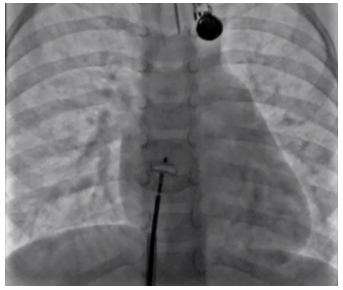

THROMBOSES

ARYTHMIES ATRIALES

AVC

ENDOCARDITE

ALLERGIE AU NICKEL

Table 1. Summary of the main long-term complications after percutaneous ASD

Complication	Incidence	Delay from closure	Complications
Cardiac erosion	0.04%-0.28%	Up to 9 y	Death (0.05%) Stroke
Device thrombosis	0.8%-1.2%	Up to 2 y	Stroke (10%-15%)
Atrial arrhythmias	11% 10 years after closure	—	Stroke
Complete AV block	5 published cases	Up to 4 y	—
Infective endocarditis	6 published cases	Up to 4 y	—

Jalal et al. Can Jour Cardiol 2016

PROBLÉMATIQUE

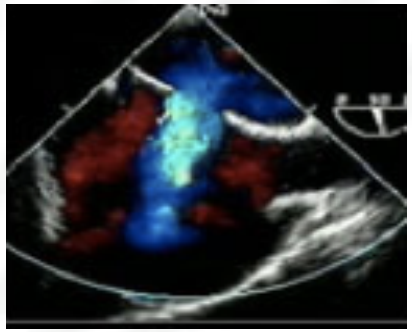



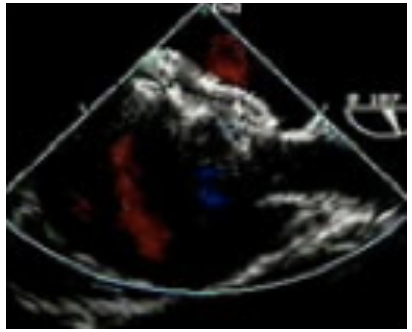

Aspirine
+
Prophylaxie EI

6 MOIS

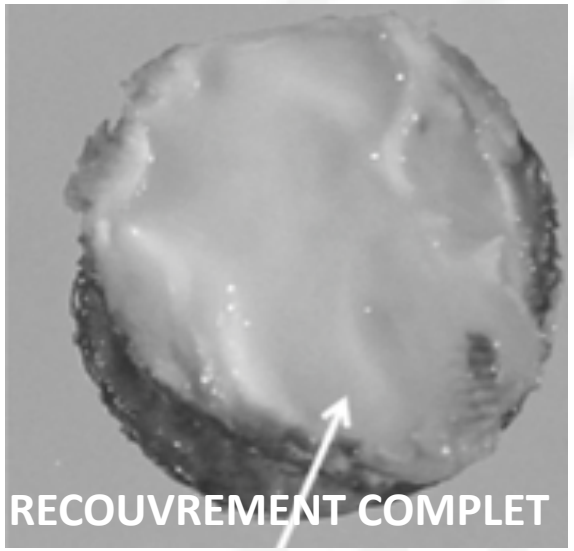

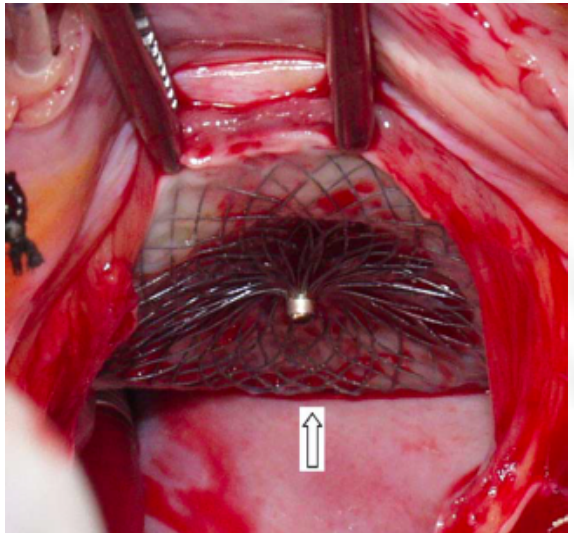

RECOUVREMENT INCOMPLET

QUESTIONS SANS RÉPONSES

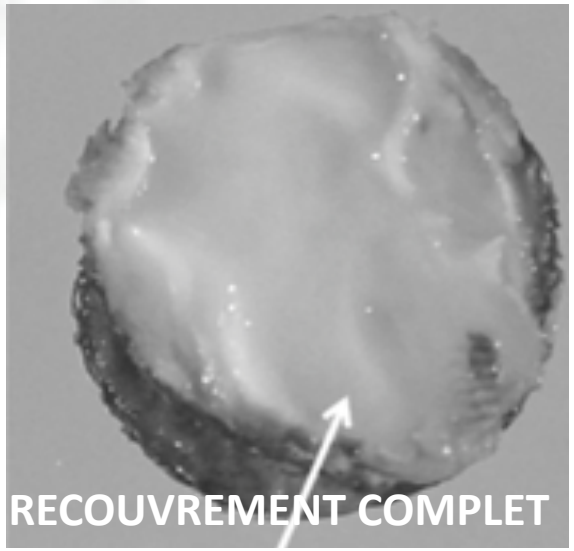

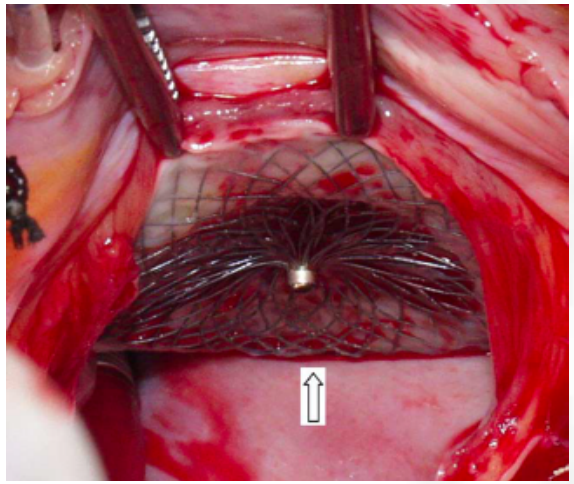

RECOUVREMENT INCOMPLET

- Peut-on étudier le recouvrement prothétique en utilisant des cellules humaines?
- Le phénomène de recouvrement diffère-t-il entre différents dispositifs commercialisés?
- Pourrait-on réaliser une évaluation individuelle du recouvrement par méthodes non invasives?

PROJETS DE RECHERCHE EN COURS

ÉVALUATION MULTIMODALE DU RECOUVREMENT DES PROTHÈSES

Travaux Fondamentaux

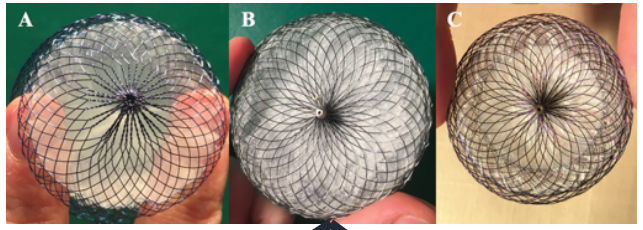

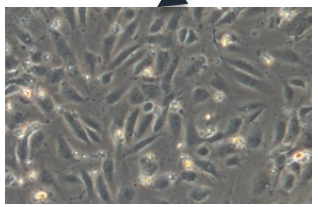

Travaux Clinique

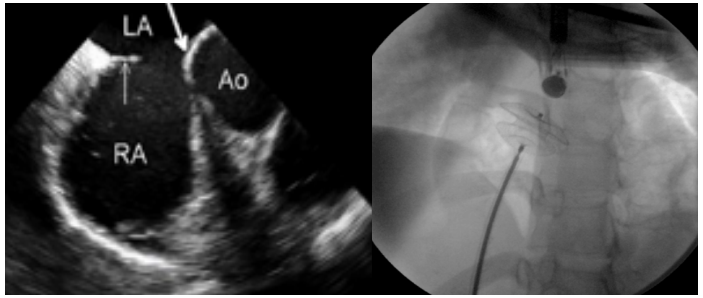

Imagerie du recouvrement

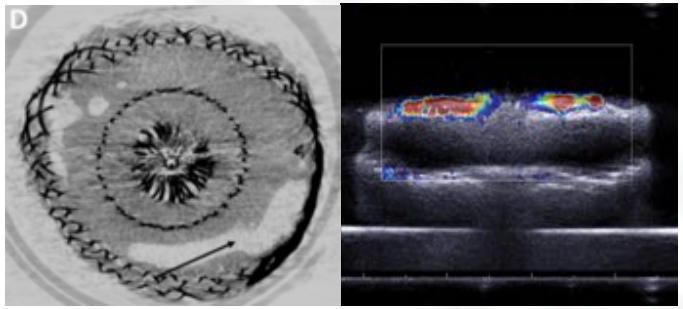

PERSPECTIVES

DISPOSITIF IDÉAL

- Si les tissus du patient prennent la place et la fonction du dispositif => indispensable?
- DISPOSITIFS BIORÉSORBABLE
- Résorption partielle ou totale

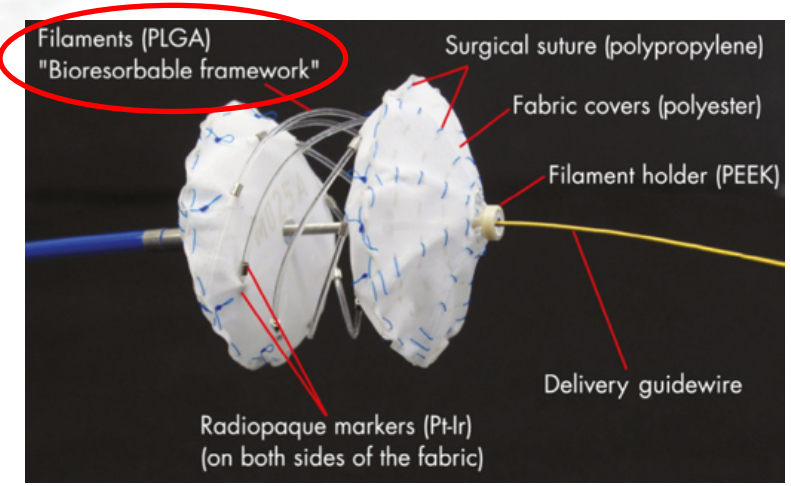

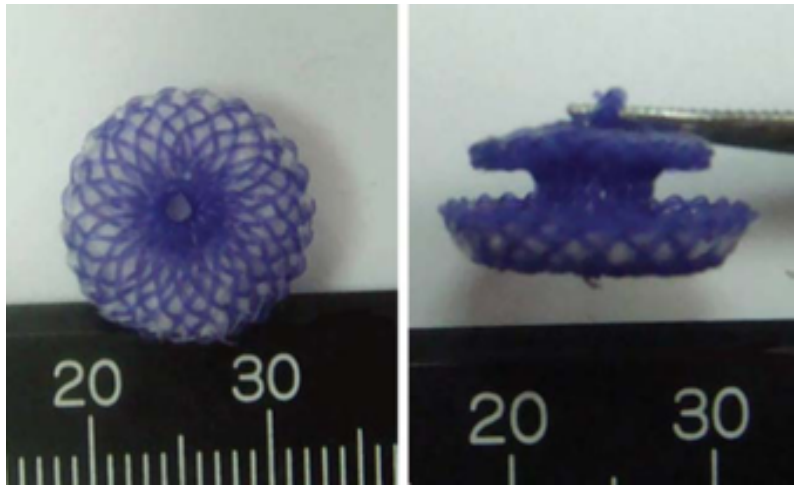

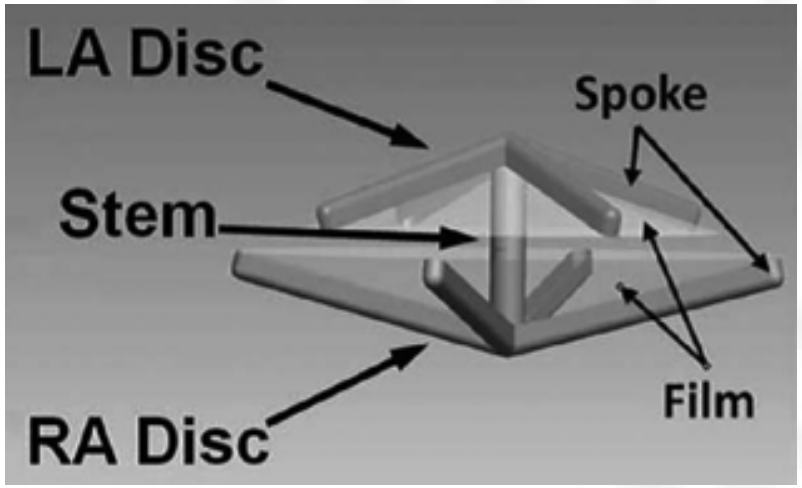

Sigler et al. EuroIntervention 2018
Duong-Hong et al. CCI 2010
Zhu et al. J Biomed Biotechnol. 2012

CIA SINUS VENOSUS – APPROCHE PERCUTANEE

STENT COUVERT JONCTION SVC - OD

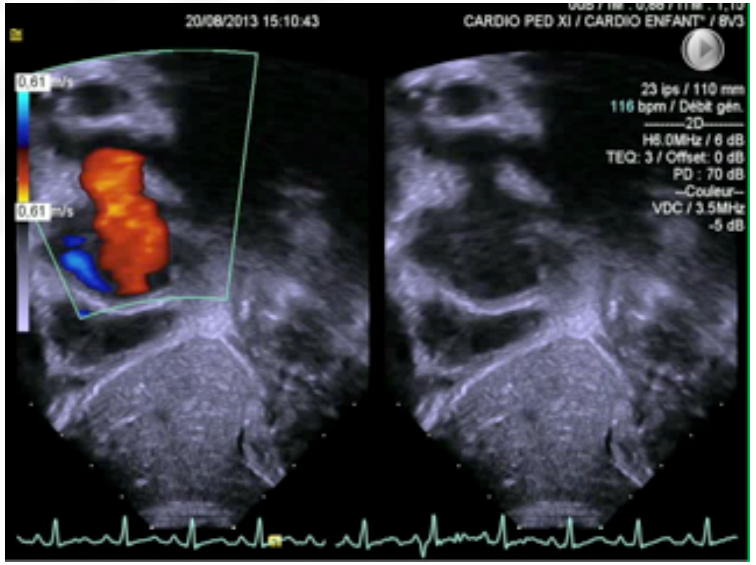

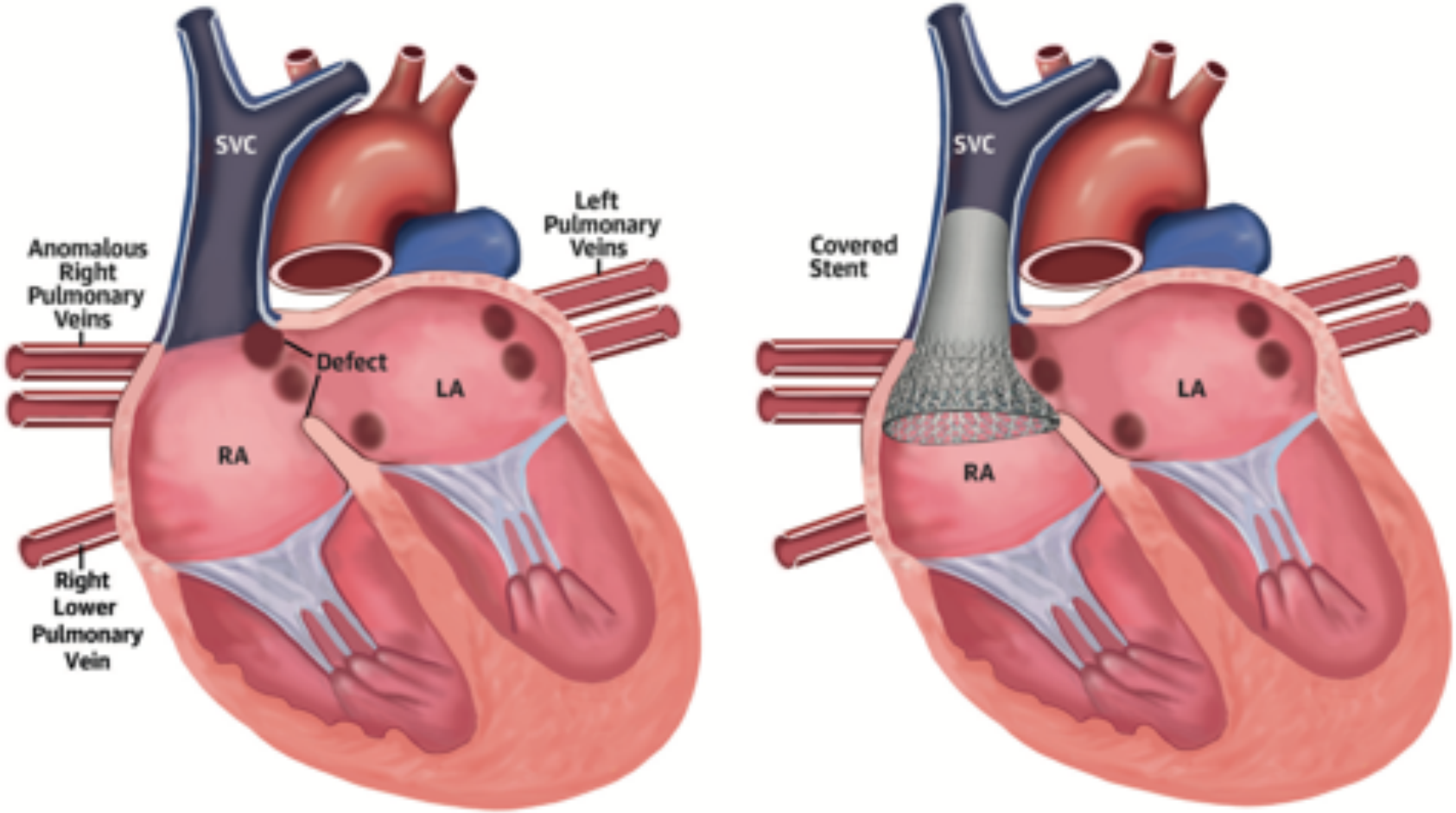

Hansen et al. JACC 2020

CIA SINUS VENOSUS – APPROCHE PERCUTANEE

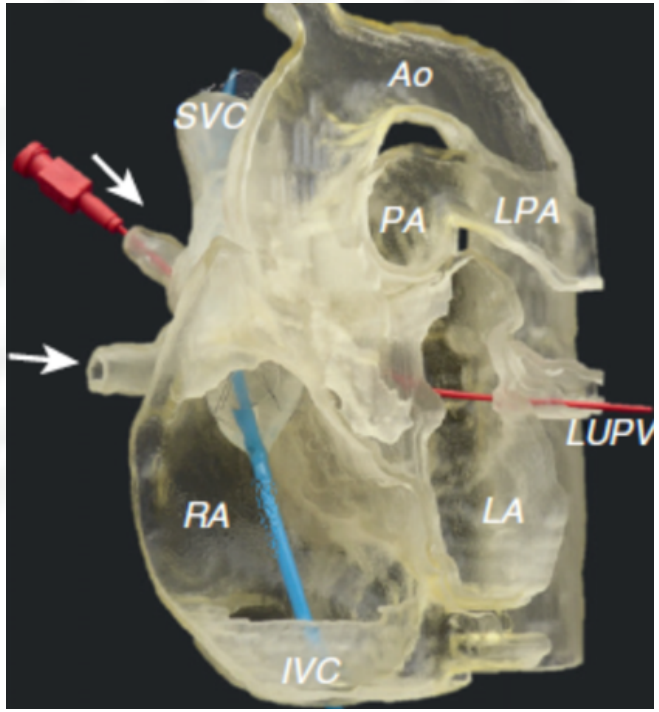

3D-PRINTED MODEL

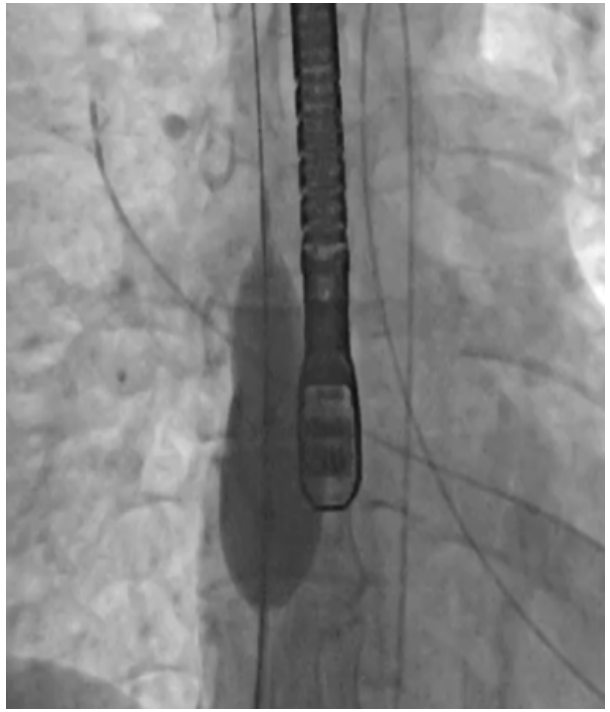

IN-VIVO ASSESSEMENT

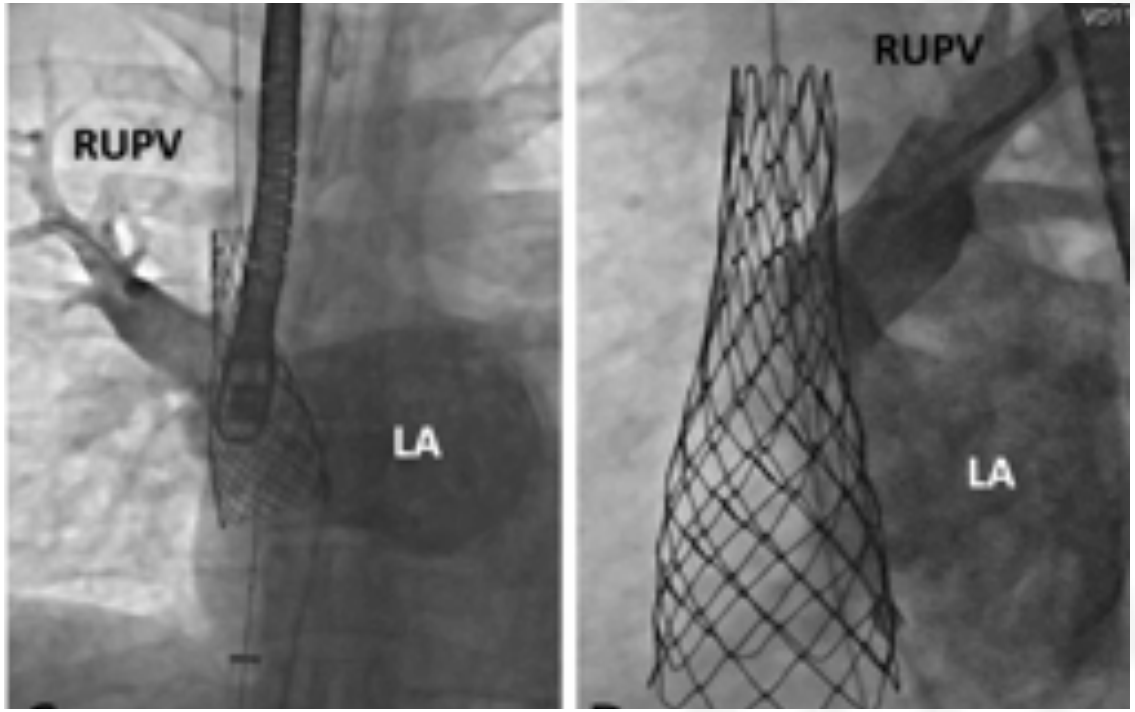

SHUNT CLOSURE RUPV PATENCY

Courtesy A. Baruteau

Hansen et al. JACC 2020

CIA SINUS VENOSUS – APPROCHE PERCUTANEE

25 patients , 45 ans (33–54)

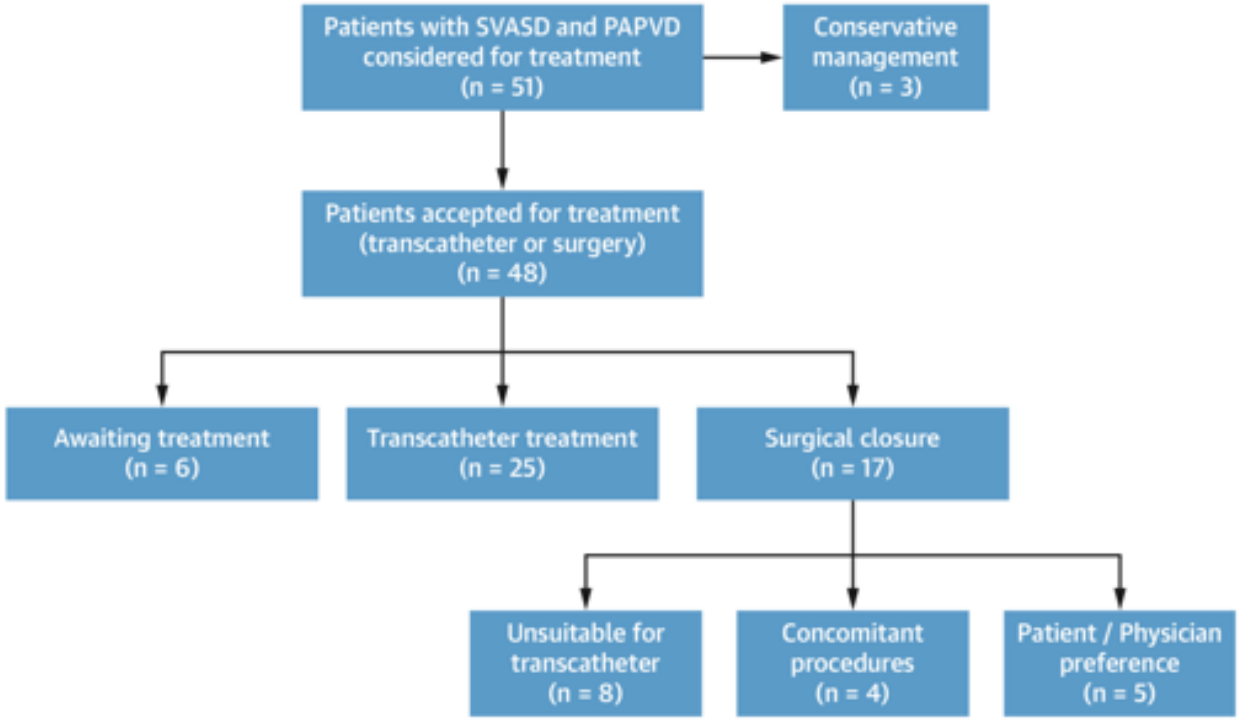

- Succès: 100%
- 1 hémopericarde, 1 embolisation précoce de stent
- Aspirine-Clopidogrel 2 mois puis Aspirine 4 mois
- Suivi: 1.4 ans: pas de shunt résiduel, 0 complications
- 100% VPSD perméable

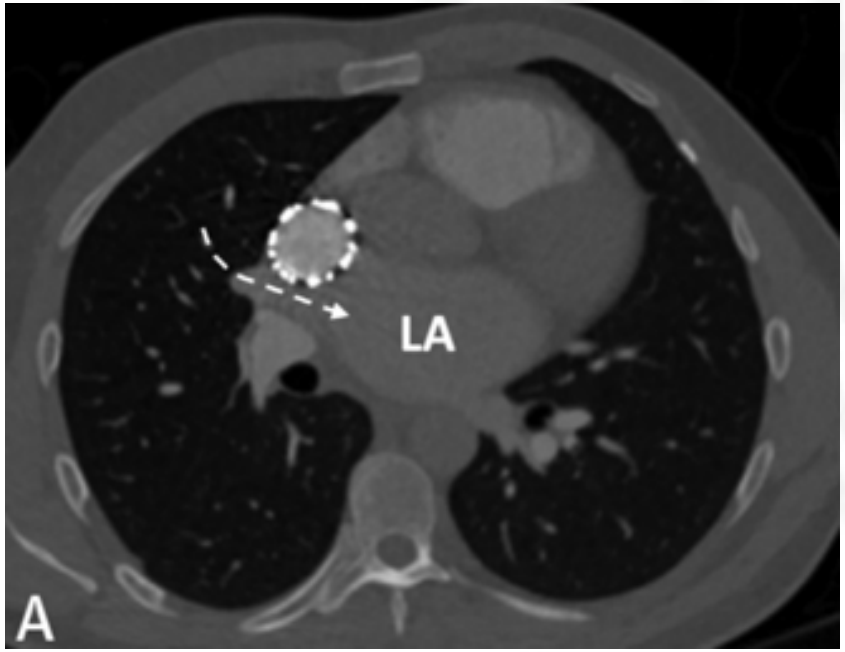

Hansen et al. JACC 2020

REPARATION CHIRURGICALE - WARDEN

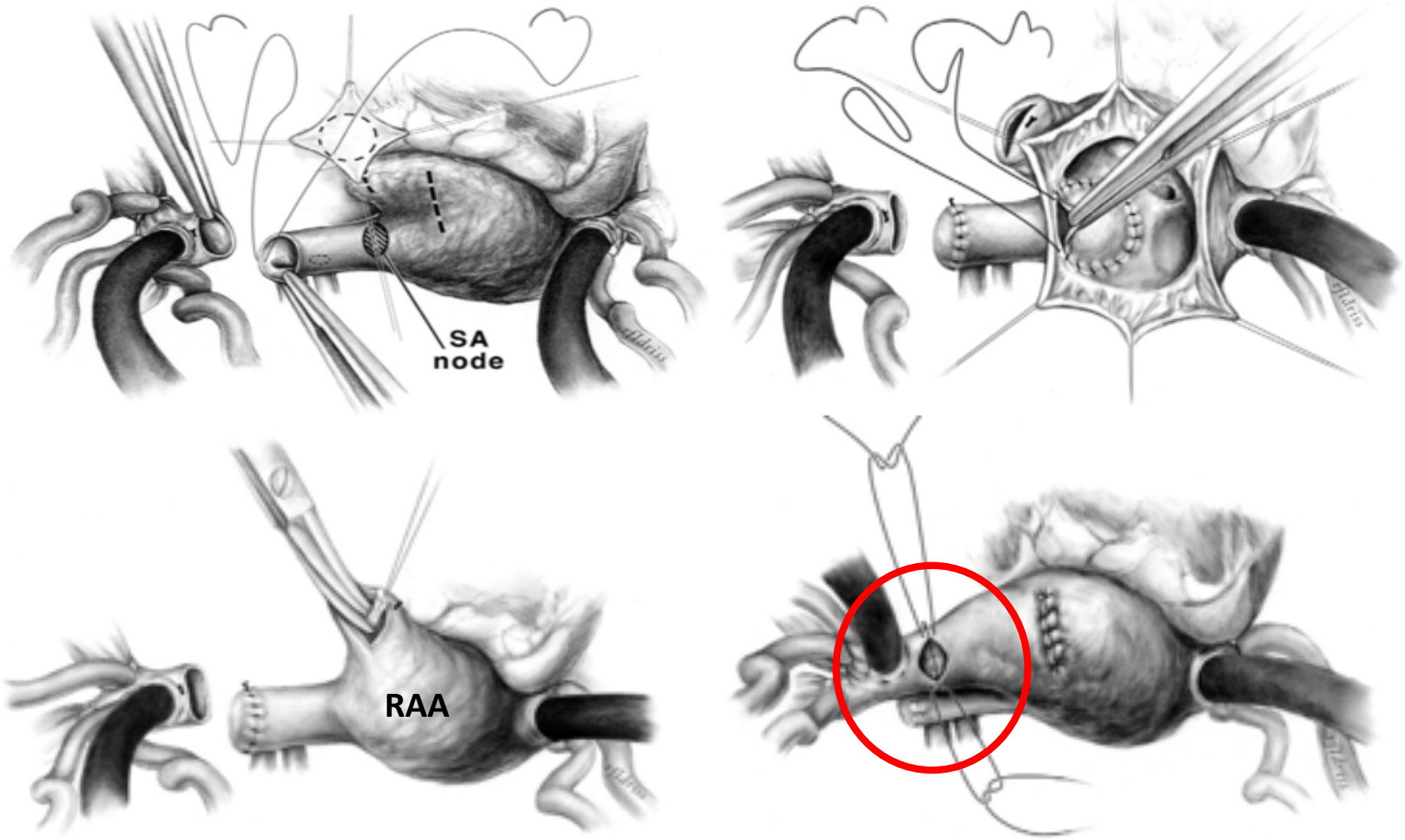

Stewart et al. Ann Thorac Surg 2007

COMPLICATION POST-OPERATOIRE

- Garçon de 7 ans
- 2017: Cure chirurgicale CIA-SV (Warden)
- 2019: Œdème facial, circulation veineuse collatérale
- TDM: Sténose suture VCS-OD

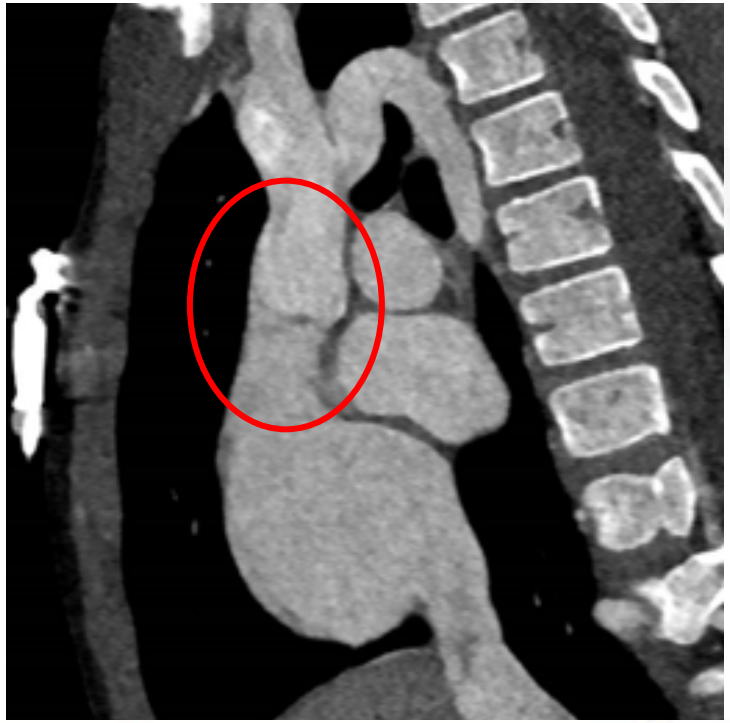

COMPLICATION POST-OPERATOIRE

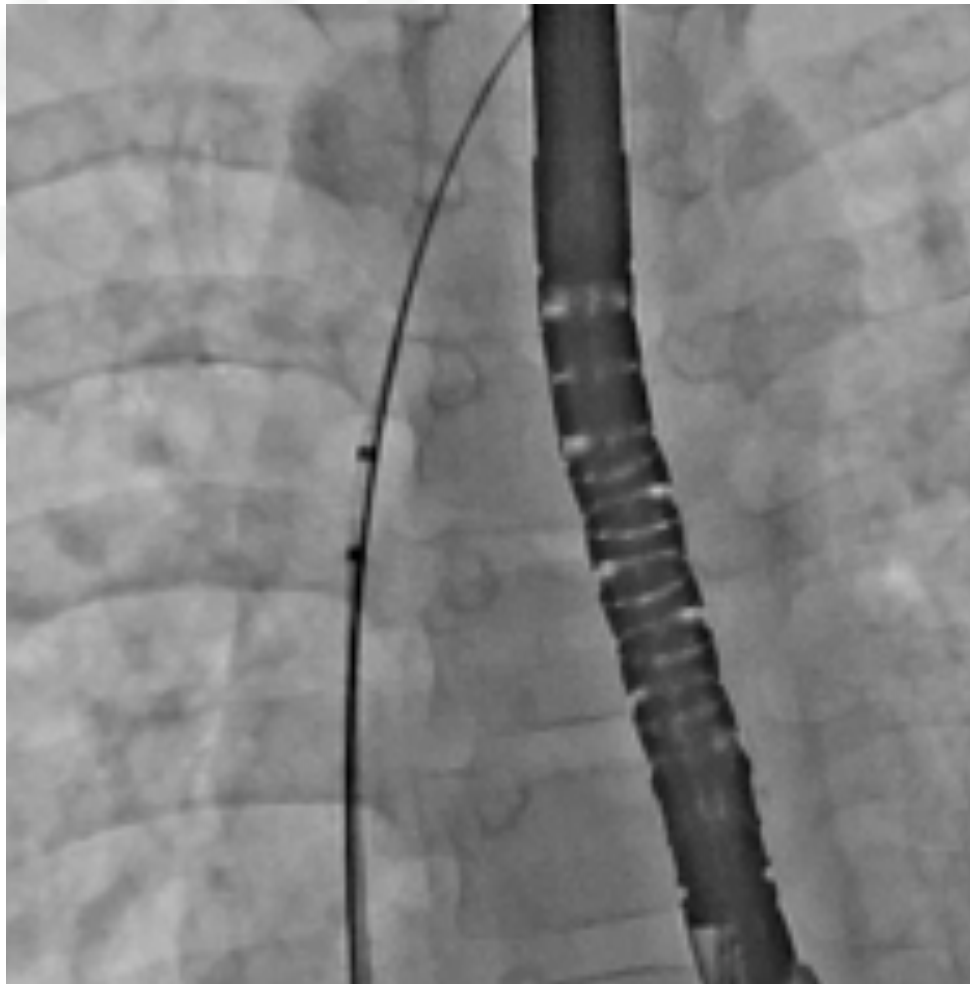

Pressions: VCS = 28-mmHg; OD= 10-mmHg

COMPLICATION POST-OPERATOIRE

34mm Coverer CP-Stent – 15x40mm Balloon

COMPLICATION POST-OPERATOIRE

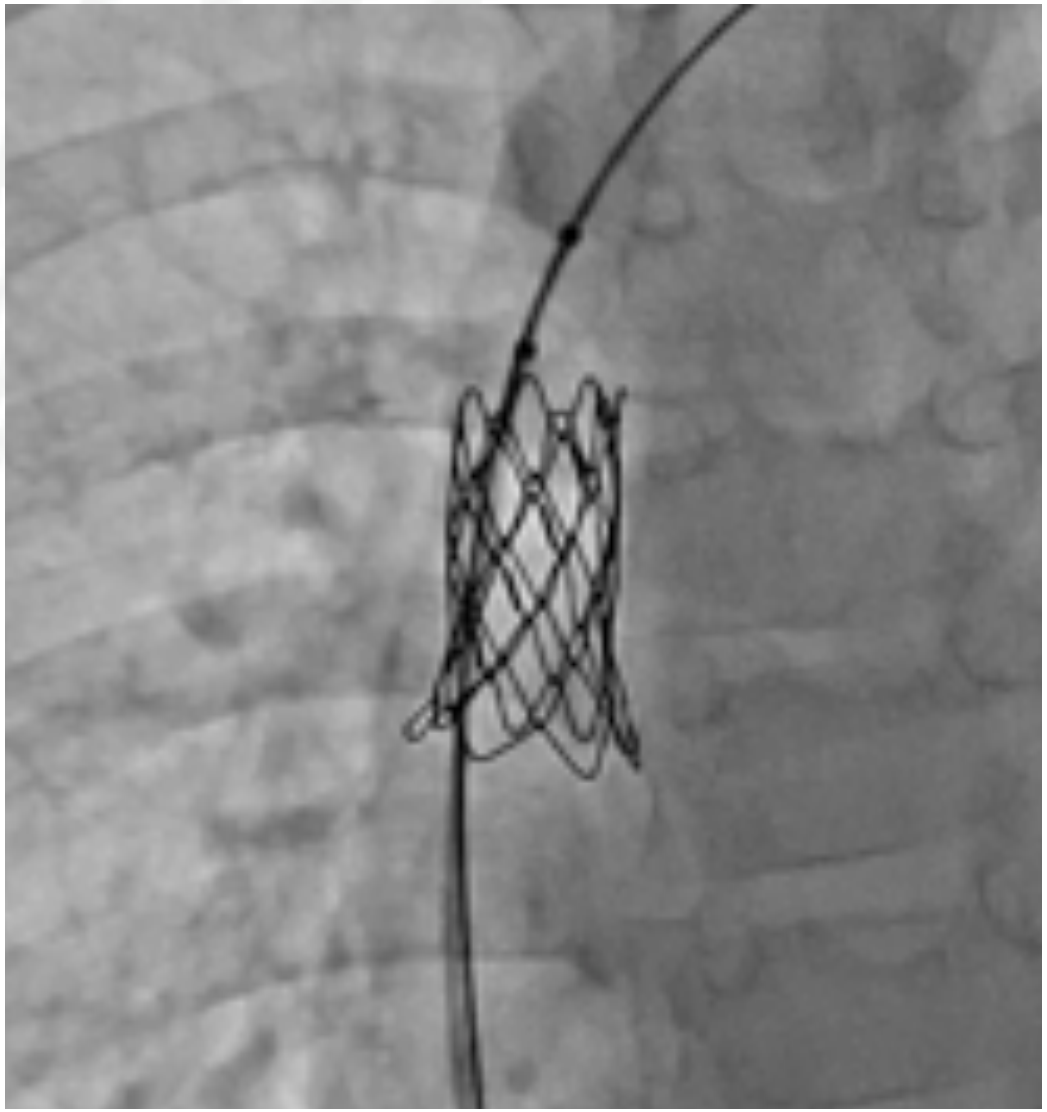

- Sortie J2 sous Aspirine
- 3 mois: disparition symptômes
- Croissance => post-dilatation stent

L'INSTITUT DE RYTHMOLOGIE ET MODÉLISATION CARDIAQUE BORDEAUX

MERCI POUR VOTRE ATTENTION

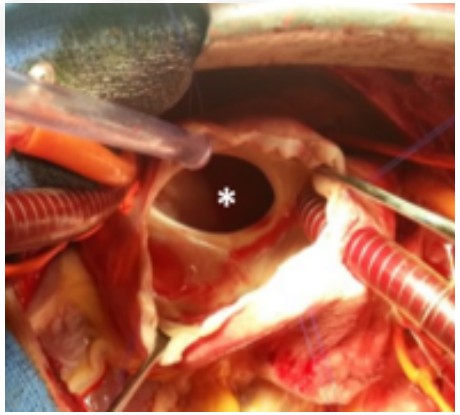

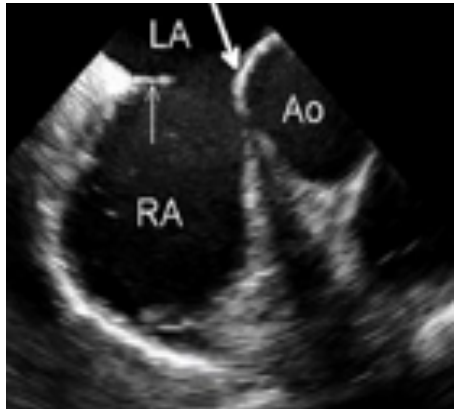

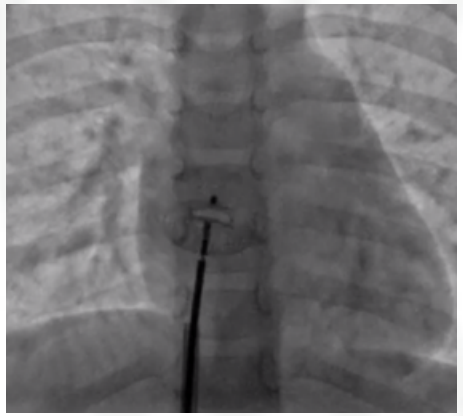

Zakaria Jalal – MD, PhD

Service des cardiopathies congénitales de l'enfant et de l'adulte

Hôpital cardiologique Haut Lévêque - Bordeaux